

# World Journal of *Clinical Cases*

*World J Clin Cases* 2020 May 26; 8(10): 1756-2065



**GUIDELINES**

- 1756** French Spine Surgery Society guidelines for management of spinal surgeries during COVID-19 pandemic  
*Prost S, Charles YP, Allain J, Barat JL, d'Astorg H, Delhaye M, Eap C, Zairi F, Guigui P, Ilharreborde B, Meyblum J, Le Huec JC, Lonjon N, Lot G, Hamel O, Riouallon G, Litrico S, Tropiano P, Blondel B, the French Spine Surgery Society*

**OPINION REVIEW**

- 1763** Needs and concerns of patients in isolation care units - learnings from COVID-19: A reflection  
*Fan PEM, Aloweni F, Lim SH, Ang SY, Perera K, Quek AH, Quek HKS, Ayre TC*

**REVIEW**

- 1767** Prophylactic and therapeutic roles of oleanolic acid and its derivatives in several diseases  
*Sen A*
- 1793** Macrophage regulation of graft-vs-host disease  
*Hong YQ, Wan B, Li XF*

**MINIREVIEWS**

- 1806** Antiphospholipid syndrome and its role in pediatric cerebrovascular diseases: A literature review  
*Sarecka-Hujar B, Kopyta I*
- 1818** Remotely monitored telerehabilitation for cardiac patients: A review of the current situation  
*Batalik L, Filakova K, Batalikova K, Dosbaba F*
- 1832** Keystone design perforator island flap in facial defect reconstruction  
*Lim SY, Yoon CS, Lee HG, Kim KN*

**ORIGINAL ARTICLE****Clinical and Translational Research**

- 1848** Cross electro-nape-acupuncture ameliorates cerebral hemorrhage-induced brain damage by inhibiting necroptosis  
*Cai GF, Sun ZR, Zhuang Z, Zhou HC, Gao S, Liu K, Shang LL, Jia KP, Wang XZ, Zhao H, Cai GL, Song WL, Xu SN*

**Retrospective Study**

- 1859** Evaluation of ischemic lesions after carotid artery stenting with diffusion-weighted imaging  
*Beyhan M, Acu B, Gökçe E, Fırat MM*
- 1871** Transjugular intrahepatic portosystemic shunt and splenectomy are more effective than endoscopic therapy for recurrent variceal bleeding in patients with idiopathic noncirrhotic portal hypertension  
*He FL, Qi RZ, Zhang YN, Zhang K, Zhu-Ge YZ, Wang M, Wang Y, Jia JD, Liu FQ*

- 1878** Liglipatin for treatment of type 2 diabetes mellitus with early renal injury: Efficacy and impact on endogenous hydrogen sulfide and endothelial function  
*Zhang J, Du YL, Zhang H, Sui H, Hou WK*
- 1887** Outcomes of patients with pelvic leiomyosarcoma treated by surgery and relevant auxiliary diagnosis  
*Sun Q, Yang X, Zeng Z, Wei X, Li KZ, Xu XY*
- 1897** Defecation function and quality of life in patients with slow-transit constipation after colectomy  
*Tian Y, Wang L, Ye JW, Zhang Y, Zheng HC, Shen HD, Li F, Liu BH, Tong WD*
- 1908** Risk factors, incidence, and morbidity associated with antibiotic-associated diarrhea in intensive care unit patients receiving antibiotic monotherapy  
*Zhou H, Xu Q, Liu Y, Guo LT*
- Observational Study**
- 1916** Serum von Willebrand factor for early diagnosis of lung adenocarcinoma in patients with type 2 diabetes mellitus  
*Zhou YY, Du X, Tang JL, Wang QP, Chen K, Shi BM*
- 1923** Four-microRNA signature for detection of type 2 diabetes  
*Yan LN, Zhang X, Xu F, Fan YY, Ge B, Guo H, Li ZL*

**CASE REPORT**

- 1932** Isolated colonic neurofibroma, a rare tumor: A case report and review of literature  
*Ghoneim S, Sandhu S, Sandhu D*
- 1939** Helmet-based noninvasive ventilation for acute exacerbation of chronic obstructive pulmonary disease: A case report  
*Park MH, Kim MJ, Kim AJ, Lee MJ, Kim JS*
- 1944** Appendectomy in patient with suspected COVID-19 with negative COVID-19 results: A case report  
*Kim C, Kim JK, Yeo IH, Choe JY, Lee JE, Kang SJ, Park CS, Kwon KT, Hwang S*
- 1950** T4 cervical esophageal cancer cured with modern chemoradiotherapy: A case report  
*Lee CC, Yeo CM, Ng WK, Verma A, Tey JC*
- 1958** Lumbar disc rehydration in the bridged segment using the BioFlex dynamic stabilization system: A case report and literature review  
*Li YC, Feng XF, Pang XD, Tan J, Peng BG*
- 1966** Traditional investigation and management for recurrent hemarthrosis after total knee arthroplasty: A case report  
*Geng X, Li Y, He X, Tian H*

- 1973** Positron emission tomography/computed tomography findings of multiple cystic lymphangiomas in an adult: A case report  
*Sun MM, Shen J*
- 1979** Heterotopic pancreas adenocarcinoma in the stomach: A case report and literature review  
*Xiong Y, Xie Y, Jin DD, Wang XY*
- 1988** Early-onset refractory diarrhea due to immune dysregulation, polyendocrinopathy, enteropathy, X-linked syndrome associated with a novel mutation in the *FOXP3* gene: A case report  
*Su N, Chen C, Zhou X, Ma GD, Chen RL, Tian C*
- 1995** Tuberous sclerosis complex presenting as primary intestinal lymphangiectasia: A case report  
*Lin WH, Zhang ZH, Wang HL, Ren L, Geng LL*
- 2001** Gilbert's syndrome coexisting with hereditary spherocytosis might not be rare: Six case reports  
*Kang LL, Liu ZL, Zhang HD*
- 2009** Effective combined therapy for pulmonary epithelioid hemangioendothelioma: A case report  
*Zhang XQ, Chen H, Song S, Qin Y, Cai LM, Zhang F*
- 2016** Unexplained huge liver infarction presenting as a tumor with bleeding: A case report  
*Wang FH, Yang NN, Liu F, Tian H*
- 2023** Rare recurrent gallstone ileus: A case report  
*Jiang H, Jin C, Mo JG, Wang LZ, Ma L, Wang KP*
- 2028** Treating severe periodontitis with staged load applied implant restoration: A case report  
*Wang SH, Ni WC, Wang RF*
- 2038** Cryptococcal pneumonia in a human immunodeficiency virus-negative patient: A case report  
*Jiang XQ, Zhang YB*
- 2044** Ileocecal intussusception caused by two different tumors - which is the culprit lesion? A case report  
*Fan WF, Ma G, Li GC, Long J, Xu YH, Guo KJ, Liu Z*
- 2050** Robot-assisted retroperitoneal laparoscopic excision of perirenal vascular tumor: A case report  
*Zhang C, Fu B, Xu S, Zhou XC, Cheng XF, Fu WQ, Wang GX*
- 2056** Successful use of plasma exchange in fulminant lupus myocarditis coexisting with pneumonia: A case report  
*Xing ZX, Yu K, Yang H, Liu GY, Chen N, Wang Y, Chen M*

**ABOUT COVER**

Editorial Board Member of *World Journal of Clinical Cases*, Preet M Chaudhary, MD, PhD, Professor, Department of Medicine, Jane Anne Nohl Division of Hematology and Center for the Study of Blood Diseases, University of Southern California, Los Angeles, CA 90033, United States

**AIMS AND SCOPE**

The primary aim of *World Journal of Clinical Cases* (WJCC, *World J Clin Cases*) is to provide scholars and readers from various fields of clinical medicine with a platform to publish high-quality clinical research articles and communicate their research findings online.

WJCC mainly publishes articles reporting research results and findings obtained in the field of clinical medicine and covering a wide range of topics, including case control studies, retrospective cohort studies, retrospective studies, clinical trials studies, observational studies, prospective studies, randomized controlled trials, randomized clinical trials, systematic reviews, meta-analysis, and case reports.

**INDEXING/ABSTRACTING**

The WJCC is now indexed in PubMed, PubMed Central, Science Citation Index Expanded (also known as SciSearch®), and Journal Citation Reports/Science Edition. The 2019 Edition of Journal Citation Reports cites the 2018 impact factor for WJCC as 1.153 (5-year impact factor: N/A), ranking WJCC as 99 among 160 journals in Medicine, General and Internal (quartile in category Q3).

**RESPONSIBLE EDITORS FOR THIS ISSUE**

Responsible Electronic Editor: Ji-Hong Liu

Proofing Production Department Director: Xiang Li

Responsible Editorial Office Director: Jin-Lai Wang

**NAME OF JOURNAL**

*World Journal of Clinical Cases*

**ISSN**

ISSN 2307-8960 (online)

**LAUNCH DATE**

April 16, 2013

**FREQUENCY**

Semimonthly

**EDITORS-IN-CHIEF**

Dennis A Bloomfield, Bao-Gan Peng, Sandro Vento

**EDITORIAL BOARD MEMBERS**

<https://www.wjgnet.com/2307-8960/editorialboard.htm>

**PUBLICATION DATE**

May 26, 2020

**COPYRIGHT**

© 2020 Baishideng Publishing Group Inc

**INSTRUCTIONS TO AUTHORS**

<https://www.wjgnet.com/bpg/gerinfo/204>

**GUIDELINES FOR ETHICS DOCUMENTS**

<https://www.wjgnet.com/bpg/GerInfo/287>

**GUIDELINES FOR NON-NATIVE SPEAKERS OF ENGLISH**

<https://www.wjgnet.com/bpg/gerinfo/240>

**PUBLICATION ETHICS**

<https://www.wjgnet.com/bpg/GerInfo/288>

**PUBLICATION MISCONDUCT**

<https://www.wjgnet.com/bpg/gerinfo/208>

**ARTICLE PROCESSING CHARGE**

<https://www.wjgnet.com/bpg/gerinfo/242>

**STEPS FOR SUBMITTING MANUSCRIPTS**

<https://www.wjgnet.com/bpg/GerInfo/239>

**ONLINE SUBMISSION**

<https://www.f6publishing.com>



## Robot-assisted retroperitoneal laparoscopic excision of perirenal vascular tumor: A case report

Cheng Zhang, Bin Fu, Song Xu, Xiao-Chen Zhou, Xiao-Feng Cheng, Wen-Qing Fu, Gong-Xian Wang

**ORCID number:** Cheng Zhang (0000-0001-5741-8457); Bin Fu (0000-0001-5318-3873); Song Xu (0000-0002-5483-8816); Xiao-Chen Zhou (0000-0001-5877-1770); Xiao-Feng Cheng (0000-0002-3364-529X); Wen-Qing Fu (0000-0002-2653-150X); Gong-Xian Wang (0000-0002-1911-1515).

**Author contributions:** Zhang C and Fu B conceived and supervised the study; Xu S and Zhou XC wrote the manuscript; Fu WQ and Cheng XF were responsible for the collection of information; Wang GX revised the manuscript; all authors reviewed the results and approved the final version of the manuscript.

**Informed consent statement:** Informed written consent was obtained from the patient for publication of this report and any accompanying images.

**Conflict-of-interest statement:** The authors declare that they have no conflict of interest.

**CARE Checklist (2016) statement:** The authors have read the CARE Checklist (2016), and the manuscript was prepared and revised according to the CARE Checklist (2016).

**Open-Access:** This article is an open-access article that was selected by an in-house editor and fully peer-reviewed by external reviewers. It is distributed in accordance with the Creative Commons Attribution NonCommercial (CC BY-NC 4.0) license, which permits others to distribute, remix, adapt, build upon this work non-commercially,

**Cheng Zhang, Bin Fu, Song Xu, Xiao-Chen Zhou, Xiao-Feng Cheng, Wen-Qing Fu, Gong-Xian Wang,** Department of Urology, The First Affiliated Hospital of Nanchang University, Nanchang 330000, JiangXi Province, China

**Corresponding author:** Gong-Xian Wang, PhD, Chief Doctor, Department of Urology, The First Affiliated Hospital of Nanchang University, 17 Yongwaizheng Street, Donghu District, Nanchang 330000, JiangXi Province, China. [wanggx-mr@126.com](mailto:wanggx-mr@126.com)

### Abstract

#### BACKGROUND

A vascular tumor is a benign tumor with unique clinical and pathological features. Perirenal vascular tumor is extremely rare and has not yet been reported. Clinically, it manifests as soreness and swelling. Color ultrasound and renal angiography illustrated the perirenal mass, which was closely connected with the kidney and the surrounding tissues and organs. Histology showed extensive embedded perirenal fat, and thin-walled vascular tissue displayed a pink stain due to red blood cells.

#### CASE SUMMARY

Herein, a case of robot-assisted retroperitoneal laparoscopic excision of a perirenal vascular tumor is reported. Analysis of the clinical, biological, and histological features of the perirenal vascular tumor can provide an in-depth understanding of the disease, which provides a theoretical and practical basis for better diagnosis and treatment.

#### CONCLUSION

This study contributes to a practical basis for the diagnosis and treatment of perirenal hemangioma.

**Key words:** Kidney; Vascular tumor; Treatment; Robot-assisted surgery

©The Author(s) 2020. Published by Baishideng Publishing Group Inc. All rights reserved.

**Core tip:** Perirenal vascular tumor is an extremely rare disease. We summarized the clinical manifestations, imaging features, and pathological characteristics of a perirenal vascular tumor in a clinical case, and successfully removed the tumor using robotic surgery without complications. This provides a practical model for the diagnosis and treatment of this disease.



and license their derivative works on different terms, provided the original work is properly cited and the use is non-commercial. See: <http://creativecommons.org/licenses/by-nc/4.0/>

**Manuscript source:** Unsolicited manuscript

**Received:** December 31, 2019

**Peer-review started:** December 31, 2019

**First decision:** March 5, 2020

**Revised:** April 1, 2020

**Accepted:** April 24, 2020

**Article in press:** April 24, 2020

**Published online:** May 26, 2020

**P-Reviewer:** Mogulkoc R, Tsoulfas G

**S-Editor:** Wang YQ

**L-Editor:** Webster JR

**E-Editor:** Qi LL



**Citation:** Zhang C, Fu B, Xu S, Zhou XC, Cheng XF, Fu WQ, Wang GX. Robot-assisted retroperitoneal laparoscopic excision of perirenal vascular tumor: A case report. *World J Clin Cases* 2020; 8(10): 2050-2055

**URL:** <https://www.wjgnet.com/2307-8960/full/v8/i10/2050.htm>

**DOI:** <https://dx.doi.org/10.12998/wjcc.v8.i10.2050>

## INTRODUCTION

Vascular tumors are rare benign cystic tumors that commonly occur in the mouth and face. Originating from the mesenchymal tissue, vascular tumors are mostly microvascular lymphatic malformations caused by dysplasia in the embryonic stage or residual tissue, resulting in the obstruction of fluid reflux, expansion, and protrusion, and are classified as hemangiomas and lymphangiomas. These tumors are mostly benign, and no malignant or invasive characteristics have been observed<sup>[1]</sup>. The majority of vascular tumors have a slow growth rate, and the size of the tumor increases with age. Typically, they do not regress spontaneously. The most common complications include spontaneous or traumatic hemorrhage, rupture, and infection<sup>[2]</sup>. According to trauma or surgical history, they are classified into primary and secondary vascular tumors<sup>[3]</sup>. Primary vascular tumors constitute the most commonly reported type in the clinic. Vascular tumors are common in children and adolescents with a reported hemolymphangioma incidence of 1.2%-2.8% in newborns. The incidence before the age of 2 years was > 90%, while 60% of newborns showed symptoms at birth<sup>[4,5]</sup>. Lesions can be single, multiple, or diffused, occurring in any part of the body, especially in the loose connective tissue.

Herein, we report the case of a primary perirenal vascular tumor, which is a rare occurrence in the clinic. Only 2 cases of retroperitoneal angiocarcinoma were reported previously<sup>[6,7]</sup>. Such cases are often subjected to surgical excision in the clinic<sup>[8,9]</sup>. Currently, experience in the diagnosis and treatment of perirenal vascular tumors is lacking. Herein, we report a case of perirenal vascular tumor from clinical, imaging, and pathological aspects, which could provide elaborate information regarding the study and treatment of vascular tumors.

## CASE PRESENTATION

### Chief complaints

A 38-year-old female was admitted to the Urological Department of the First Affiliated Hospital of Nanchang University after 37 d of soreness and swelling in the left waist.

### History of present illness

The patient initially showed symptoms on November 13, 2018, which were not relieved with the change in body posture. The patient experienced radiating pain, nausea, vomiting, frequent urination, urgent urination, and gross hematuria. She underwent an abdominal color ultrasound at the Jiangxi Provincial Breast Hospital (ultrasound No. 9000022433). The compression type change of the cystic mass in the left middle upper abdominal region and the left side of the abdominal aorta seemed to be connected with the left kidney. On November 27, double renal computed tomography (CT) angiography was performed and routine blood and biochemical examinations were conducted on December 20 at the First Affiliated Hospital of Nanchang University. Subsequently, robot-assisted retroperitoneal laparoscopic excision was performed to excise the perirenal vascular mass on December 25 under general anesthesia.

### History of past illness

She was healthy without any previous history of surgery, hypertension, or diabetes.

### Physical examination

Physical examination indicated no pressing or percussion pain in both kidneys.

### Laboratory examinations

Routine blood and biochemical examinations to assess tumor markers showed no obvious abnormalities (Table 1).

**Table 1 Preoperative laboratory test results**

Laboratory examination			
Hemoglobin	134 g/L	Globulin	24.7 g/L
Red blood cells	$4.64 \times 10^{12}/L$	Alanine aminotransferase	11.0 U/L
White blood cells	$5.21 \times 10^9/L$	Aspartate aminotransferase	18.0 U/L
Neutrophilic granulocytes	$2.56 \times 10^9/L$	Alpha fetoprotein	1.36 ng/mL
Lymphocytes	$2.28 \times 10^9/L$	Carcinoembryonic antigen	0.60 ng/mL
Blood platelets	$316 \times 10^9/L$	Carbohydrate antigen 12-5	41.63 U/mL
Urea	3.9 mmol/L	Carbohydrate antigen 15-3	12.30 U/mL
Cr	52.4 $\mu$ mol/L	Carbohydrate antigen 19-9	10.54 U/mL
Na	138.0 mmol/L	Carbohydrate antigen 724	7.19 U/mL
K	4.0 mmol/L	Prothrombin time	9.9 s
Albumin	45.3 g/L	Thrombin time	17.7 s

### Imaging examinations

Imaging illustrated a low-density cystic shadow in the left kidney hilus with a lacy edge and a maximum size of approximately 7.7 cm  $\times$  10.1 cm (Figure 1A). The density was uniform, the surroundings were compressed, the adjacent left upper ureter was compressed, and left hydronephrosis showed dilation (Figure 1B); this was considered to be a lymphangioma.

## FINAL DIAGNOSIS

Preoperative diagnosis was a left perirenal mass. Pathological diagnosis was a perirenal vascular tumor.

## TREATMENT

As the patient's left perirenal mass was huge and closely related to the left kidney, the upper segment of the left ureter, and the left abdominal aorta, the Da Vinci robotic surgical system was selected as it is characterized by a wide operating range, high operating accuracy, and a flexible manipulator operation. Intraoperatively, the mass showed irregular cystic growth close to the surrounding organs and tissues, and was approximately 10 cm  $\times$  8 cm in size (Figure 1). Using the flexible mechanical arm of the Da Vinci surgical robotic system, caution was taken to avoid damage to the left kidney, left ureter, abdominal aorta, and peritoneum. The tumor was cystic in the field of view, a small cut was made, the clear cystic fluid was aspirated, and the tumor was completely removed. The wound was repeatedly rinsed with distilled water, and sufficient hemostasis was achieved. After the specimen was excised, a drainage tube was placed beside the left kidney, and the incision was sutured to complete the operation. Intraoperative blood loss was 30 mL, and postoperative routine blood and biochemical results were normal. The drainage tube in the left kidney was removed after 3 d, and the patient was discharged 6 d after surgery. Postoperative pathology showed a perirenal vascular tumor (Figure 2).

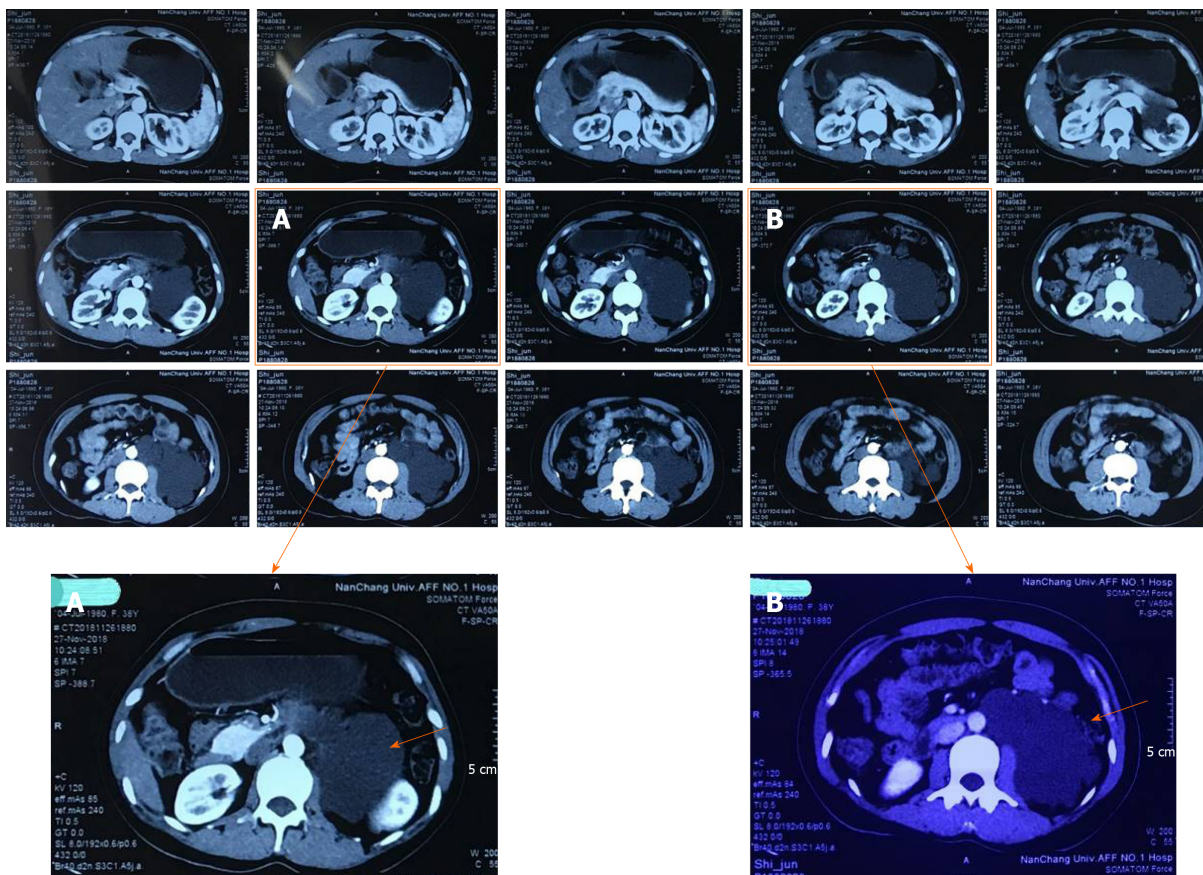
## OUTCOME AND FOLLOW-UP

Reexamination was performed at 7 mo postoperatively. Color Doppler ultrasound was performed at the Nanchang Kangqiao Health Physical Examination Center on July 30, 2019, which illustrated a crystal in the left kidney (Figure 3).

## DISCUSSION

In the early stage, vascular tumors are usually asymptomatic; however, most are detected due to their enlarged size leading to compression in the affected site. Diagnosis revealed clearly defined hypoechoic cystic masses by B-ultrasound in a honeycomb or septum formation. CT scan showed a relatively low-density uniform





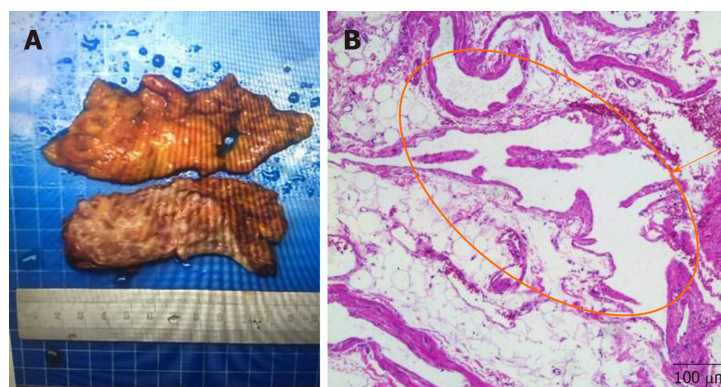
**Figure 1** Preoperative angiography of the double renal artery. A: Cystic low-density shadow in the left renal hilum with a lacy edge; B: Mass adjacent to the abdominal aorta, wrapping the left side, compressing the surrounding tissue, the upper segment of the left ureter, and dilated hydronephrosis in the left kidney.

lesion. In the vascular tumor mainly with lymph, CT showed a clear boundary without obvious enhancement. In the vascular tumor mainly with vessels, CT displayed an unclear boundary, and an enhancement in the arterial stage of different degrees was observed. With regard to treatment, surgery is the first option for almost all vascular tumors to prevent or relieve the symptoms of tumor compression.

Our patient with a perirenal vascular tumor is extremely rare. Due to enlargement of the tumor and compression on adjacent organs, the corresponding symptoms were an abdominal mass, soreness, and swelling at the waist. The putative mechanisms are as follows: (1) Congenital malformation of the vascular system; (2) Mutation or deletion of gene expression in the body; and (3) Related to the pathogenesis of previous renal diseases, but the specific mechanism requires further investigation. As the disease is rare, preoperative diagnosis is difficult. Currently, ultrasound and CT are mainly used to determine the range of the mass and its correlation with adjacent organs<sup>[10]</sup>. If the mass is rich in blood supply, further identification by magnetic resonance imaging is required. In this case, color ultrasound and abdominal CT were the first options for the diagnosis and localization of the perirenal vascular tumor. During imaging, perirenal vascular tumors have pathological features of benign tumors. Therefore, only a few cases have been reported, and different manifestations are essential to further clarify the imaging features of the disease.

Perirenal vascular tumors are benign lesions which develop slowly. If the tumor is small, and the patient does not present obvious clinical symptoms, conservative treatment, such as anti-infective agents can be administered, and when renal function is normal, this is followed by regular observation. If the tumor volume is large, and the renal parenchyma is compressed, hydronephrosis, renal hypertension, and other complications are actively treated by surgery<sup>[11]</sup>. Surgical excision is the most effective treatment for perirenal vascular tumors. The principle of surgery is to completely excise the lesion and to maximally retain normal renal tissue. Nonetheless, regular reexamination and follow-up are recommended despite the benign nature of vascular tumors.

Since the first Da Vinci robotic surgery in 1988, robotic surgery has been rapidly promoted and applied<sup>[12]</sup>. It is a favored method in urology due to the small incision, accuracy, and flexible and a stable intraoperative procedure<sup>[13]</sup>. A recent study



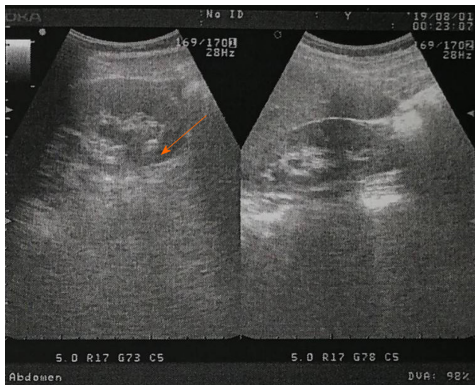
**Figure 2** Perirenal vascular tumor specimen and microscopic image. A: Grayish yellow irregular fat tissue 9 cm × 7 cm × 1.2 cm in size was visualized; B: Cystic cavity tissue of different sizes, containing eosin or red blood cells, vascular hyperplasia, partial dilatation, and deformity were observed under the microscope (HE, × 100).

reported that the Da Vinci robot could effectively reduce the incidence of perioperative complications in urology and improve the safety and feasibility of surgery<sup>[14,15]</sup>. When the tumor is large and the base is wide, the Da Vinci robot can expose a wider visual field than traditional surgery, overcoming the disadvantages of traditional deep surgery where the tumor and anatomical space cannot be observed from multiple angles. The lesion can be removed more precisely and steadily, avoiding the difference between the handwork and feel in traditional surgery. This technique greatly reduces surgical trauma and hastens postoperative recovery<sup>[16]</sup>. The Da Vinci robot results in excellent 3D vision with a flexible and super artificial manual operating system and a novel surgical mode, cooperating with increasingly updated artificial intelligence to continuously promote the development of surgery.

---

## CONCLUSION

A perirenal vascular tumor is a rare disease. We summarized the clinical manifestations, ultrasound, CT imaging, and pathological features of a perirenal vascular tumor, and recommended surgical excision. The present study provides a theoretical and practical basis for the recognition and diagnosis of perirenal vascular tumors.



**Figure 3** Re-examination results of color ultrasound six months postoperatively. Both kidneys were of normal size and shape and had a clear outline. The bright spot in the left kidney did not show a posterior acoustic shadow. No dilatation was observed in the double ureters.

## REFERENCES

- 1 **Chen YA**, Li HN, Wang RC, Hung SW, Chiu KY. Malignant Glomus Tumor of the Kidney: A Case Report and Review of the Literature. *Clin Genitourin Cancer* 2017; **15**: e151-e153 [PMID: [27349133](#) DOI: [10.1016/j.clgc.2016.05.018](#)]
- 2 **Omiyale AO**, Carton J. Clinical and Pathologic Features of Primary Angiosarcoma of the Kidney. *Curr Urol Rep* 2018; **19**: 4 [PMID: [29383452](#) DOI: [10.1007/s11934-018-0755-6](#)]
- 3 **Figueroa RM**, Lopez GJ, Servin TE, Esquinca MH, Gómez-Pedraza A. Pancreatic hemolymphangioma. *JOP* 2014; **15**: 399-402 [PMID: [25076353](#) DOI: [10.6092/1590-8577/2649](#)]
- 4 **Fang YF**, Qiu LF, Du Y, Jiang ZN, Gao M. Small intestinal hemolymphangioma with bleeding: a case report. *World J Gastroenterol* 2012; **18**: 2145-2146 [PMID: [22563205](#) DOI: [10.3748/wjg.v18.i17.2145](#)]
- 5 **Zhang X**, Sheng X, Liu F, Jian R, Li L, Luo R. Hemolymphangioma of the chest wall: A rare case report. *Oncol Lett* 2012; **3**: 816-818 [PMID: [22740999](#) DOI: [10.3892/ol.2012.591](#)]
- 6 **Filston HC**. Hemangiomas, cystic hygromas, and teratomas of the head and neck. *Semin Pediatr Surg* 1994; **3**: 147-159 [PMID: [7987630](#)]
- 7 **Toyoki Y**, Hakamada K, Narumi S, Nara M, Kudoh D, Ishido K, Sasaki M. A case of invasive hemolymphangioma of the pancreas. *World J Gastroenterol* 2008; **14**: 2932-2934 [PMID: [18473426](#) DOI: [10.3748/wjg.14.2932](#)]
- 8 **Chen Q**, Xia J. A giant hemolymphangioma of the pancreas: A case report and literature review. *Medicine (Baltimore)* 2018; **97**: e12599 [PMID: [30313046](#) DOI: [10.1097/MD.00000000000012599](#)]
- 9 **Zhang DY**, Lu Z, Ma X, Wang QY, Sun WL, Wu W, Cui PY. Multiple Hemolymphangioma of the Visceral Organs: A Case Report and Review of the Literature. *Medicine (Baltimore)* 2015; **94**: e1126 [PMID: [26166115](#) DOI: [10.1097/MD.0000000000001126](#)]
- 10 **Kosmidis I**, Vlachou M, Koutroufinis A, Filiopoulos K. Hemolymphangioma of the lower extremities in children: two case reports. *J Orthop Surg Res* 2010; **5**: 56 [PMID: [20704732](#) DOI: [10.1186/1749-799X-5-56](#)]
- 11 **Bigot P**, Bouvier A, Panayotopoulos P, Aubé C, Azzouzi AR. Partial nephrectomy after selective embolization of tumor vessels in a hybrid operating room: A new approach of zero ischemia in renal surgery. *J Surg Oncol* 2016; **113**: 135-137 [PMID: [26659385](#) DOI: [10.1002/jso.24120](#)]
- 12 **Autorino R**, Kaouk JH, Stolzenburg JU, Gill IS, Motttrie A, Tewari A, Cadeddu JA. Current status and future directions of robotic single-site surgery: a systematic review. *Eur Urol* 2013; **63**: 266-280 [PMID: [22940173](#) DOI: [10.1016/j.eururo.2012.08.028](#)]
- 13 **Novara G**, Catto JW, Wilson T, Annerstedt M, Chan K, Murphy DG, Motttrie A, Peabody JO, Skinner EC, Wiklund PN, Guru KA, Yuh B. Systematic review and cumulative analysis of perioperative outcomes and complications after robot-assisted radical cystectomy. *Eur Urol* 2015; **67**: 376-401 [PMID: [25560798](#) DOI: [10.1016/j.eururo.2014.12.007](#)]
- 14 **Agarwal DK**, Sharma V, Toussi A, Viers BR, Tollefson MK, Gettman MT, Frank I. Initial Experience with da Vinci Single-port Robot-assisted Radical Prostatectomies. *Eur Urol* 2020; **77**: 373-379 [PMID: [31010600](#) DOI: [10.1016/j.eururo.2019.04.001](#)]
- 15 **Dobbs RW**, Halgrimson WR, Madueke I, Vigneswaran HT, Wilson JO, Crivellaro S. Single-port robot-assisted laparoscopic radical prostatectomy: initial experience and technique with the da Vinci® SP platform. *BJU Int* 2019; **124**: 1022-1027 [PMID: [31301693](#) DOI: [10.1111/bju.14864](#)]
- 16 **Rogers CG**, Laungani R, Bhandari A, Krane LS, Eun D, Patel MN, Boris R, Shrivastava A, Menon M. Maximizing console surgeon independence during robot-assisted renal surgery by using the Fourth Arm and TilePro. *J Endourol* 2009; **23**: 115-121 [PMID: [19178173](#) DOI: [10.1089/end.2008.0416](#)]



Published by Baishideng Publishing Group Inc  
7041 Koll Center Parkway, Suite 160, Pleasanton, CA 94566, USA  
Telephone: +1-925-3991568  
E-mail: [bpgoffice@wjgnet.com](mailto:bpgoffice@wjgnet.com)  
Help Desk: <https://www.f6publishing.com/helpdesk>  
<https://www.wjgnet.com>

