

# World Journal of *Clinical Cases*

*World J Clin Cases* 2021 September 16; 9(26): 7614-7962



## Contents

Thrice Monthly Volume 9 Number 26 September 16, 2021

## EDITORIAL

- 7614 Advances in deep learning for computed tomography denoising  
*Park SB*

## REVIEW

- 7620 Spirituality, religiousness, and mental health: A review of the current scientific evidence  
*Lucchetti G, Koenig HG, Lucchetti ALG*
- 7632 Role of hospitalization for inflammatory bowel disease in the post-biologic era  
*Soriano CR, Powell CR, Chiorean MV, Simianu VV*

## MINIREVIEWS

- 7643 Combined targeted therapy and immunotherapy for cancer treatment  
*Guo CX, Huang X, Xu J, Zhang XZ, Shen YN, Liang TB, Bai XL*

## ORIGINAL ARTICLE

## Basic Study

- 7653 Mechanism of Jianpi Qingchang Huashi Recipe in treating ulcerative colitis: A study based on network pharmacology and molecular docking  
*Zheng L, Wen XL, Dai YC*

## Case Control Study

- 7671 Common bile duct morphology is associated with recurrence of common bile duct stones in Billroth II anatomy patients  
*Ji X, Jia W, Zhao Q, Wang Y, Ma SR, Xu L, Kan Y, Cao Y, Fan BJ, Yang Z*

## Retrospective Cohort Study

- 7682 Efficacy of roxadustat in treatment of peritoneal dialysis patients with renal anaemia  
*Zhu XW, Zhang CX, Xu TH, Jiang GN, Yao L*

## Retrospective Study

- 7693 Clinical metagenomic sequencing for rapid diagnosis of pneumonia and meningitis caused by *Chlamydia psittaci*  
*Yin XW, Mao ZD, Zhang Q, Ou QX, Liu J, Shao Y, Liu ZG*
- 7704 Evaluation of the etiology and risk factors for maternal sepsis: A single center study in Guangzhou, China  
*Lin L, Ren LW, Li XY, Sun W, Chen YH, Chen JS, Chen DJ*

- 7717 Influencing factors for hepatic fat accumulation in patients with type 2 diabetes mellitus

Wu MJ, Fang QL, Zou SY, Zhu Y, Lu W, Du X, Shi BM

- 7729 Clinical effect of peripheral capsule preservation in eyes with silicone oil tamponade

Jiang B, Dong S, Sun MH, Zhang ZY, Sun DW

- 7738 Potential effects of the nursing work environment on the work-family conflict in operating room nurses

Fu CM, Ou J, Chen XM, Wang MY

### Observational Study

- 7750 Effect and satisfaction of outpatient services by precision valuation reservation registration

Jin HJ, Cheng AL, Qian JY, Lin LM, Tang HM

### Randomized Controlled Trial

- 7762 Impact of intravenous dexmedetomidine on postoperative bowel movement recovery after laparoscopic nephrectomy: A consort-prospective, randomized, controlled trial

Huang SS, Song FX, Yang SZ, Hu S, Zhao LY, Wang SQ, Wu Q, Liu X, Qi F

### META-ANALYSIS

- 7772 Comparison of different methods of nasogastric tube insertion in anesthetized and intubated patients: A meta-analysis

Ou GW, Li H, Shao B, Huang LM, Chen GM, Li WC

### CASE REPORT

- 7786 Secondary injuries caused by ill-suited rehabilitation treatments: Five case reports

Zhou L, Zhou YQ, Yang L, Ma SY

- 7798 Gastric syphilis mimicking gastric cancer: A case report

Lan YM, Yang SW, Dai MG, Ye B, He FY

- 7805 Low-grade chondrosarcoma of the larynx: A case report

Vučković L, Klisic A, Filipović A, Popović M, Čulafić T

- 7811 Pediatric temporal fistula: Report of three cases

Gu MZ, Xu HM, Chen F, Xia WW, Li XY

- 7818 Treatment for CD57-negative  $\gamma\delta$  T-cell large granular lymphocytic leukemia with pure red cell aplasia: A case report

Xiao PP, Chen XY, Dong ZG, Huang JM, Wang QQ, Chen YQ, Zhang Y

- 7825 Rare neonatal malignant primary orbital tumors: Three case reports

Zhang Y, Li YY, Yu HY, Xie XL, Zhang HM, He F, Li HY

- 7833 Carbon ion radiotherapy for bladder cancer: A case report

Zhang YS, Li XJ, Zhang YH, Hu TC, Chen WZ, Pan X, Chai HY, Wang X, Yang YL

- 7840** Extravasation of chemotherapeutic drug from an implantable intravenous infusion port in a child: A case report  
*Ly DN, Xu HZ, Zheng LL, Chen LL, Ling Y, Ye AQ*
- 7845** Chronic active Epstein-Barr virus infection treated with PEG-asparaginase: A case report  
*Song DL, Wang JS, Chen LL, Wang Z*
- 7850** Omental mass combined with indirect inguinal hernia leads to a scrotal mass: A case report  
*Liu JY, Li SQ, Yao SJ, Liu Q*
- 7857** Critical lower extremity ischemia after snakebite: A case report  
*Lu ZY, Wang XD, Yan J, Ni XL, Hu SP*
- 7863** Migration of the localization wire to the back in patient with nonpalpable breast carcinoma: A case report  
*Choi YJ*
- 7870** Uniportal video-assisted thoracoscopic surgery for complex mediastinal mature teratoma: A case report  
*Hu XL, Zhang D, Zhu WY*
- 7876** Congenital disorder of glycosylation caused by mutation of *ATP6AP1* gene (c.1036G>A) in a Chinese infant: A case report  
*Yang X, Lv ZL, Tang Q, Chen XQ, Huang L, Yang MX, Lan LC, Shan QW*
- 7886** Rare monolocular intrahepatic biliary cystadenoma: A case report  
*Che CH, Zhao ZH, Song HM, Zheng YY*
- 7893** Hepatocellular carcinoma with inferior vena cava and right atrium thrombus: A case report  
*Liu J, Zhang RX, Dong B, Guo K, Gao ZM, Wang LM*
- 7901** Delayed diagnosis of ascending colon mucinous adenocarcinoma with local abscess as primary manifestation: Report of three cases  
*Han SZ, Wang R, Wen KM*
- 7909** Gastrointestinal bleeding caused by syphilis: A case report  
*Sun DJ, Li HT, Ye Z, Xu BB, Li DZ, Wang W*
- 7917** Transient involuntary movement disorder after spinal anesthesia: A case report  
*Yun G, Kim E, Do W, Jung YH, Lee HJ, Kim Y*
- 7923** Diagnosis and treatment of an inborn error of bile acid synthesis type 4: A case report  
*Wang SH, Hui TC, Zhou ZW, Xu CA, Wu WH, Wu QQ, Zheng W, Yin QQ, Pan HY*
- 7930** Malignant fibrous histiocytoma of the bone in a traumatic amputation stump: A case report and review of the literature  
*Zhao KY, Yan X, Yao PF, Mei J*

- 7937** Rare complication of acute adrenocortical dysfunction in adrenocortical carcinoma after transcatheter arterial chemoembolization: A case report  
*Wang ZL, Sun X, Zhang FL, Wang T, Li P*
- 7944** Peripherally inserted central catheter placement in neonates with persistent left superior vena cava: Report of eight cases  
*Chen Q, Hu YL, Li YX, Huang X*
- 7954** Subcutaneous angiolipoma in the scrotum: A case report  
*Li SL, Zhang JW, Wu YQ, Lu KS, Zhu P, Wang XW*

**LETTER TO THE EDITOR**

- 7959** Should people with chronic liver diseases be vaccinated against COVID-19?  
*Chen LP, Zeng QH, Gong YF, Liang FL*

**ABOUT COVER**

Editorial Board Member of *World Journal of Clinical Cases*, Alessandro Leite Cavalcanti, DDS, MSc, PhD, Associate Professor, Department of Dentistry, State University of Paraiba, Campina Grande 58429500, Paraiba, Brazil. alessandrouepb@gmail.com

**AIMS AND SCOPE**

The primary aim of *World Journal of Clinical Cases* (WJCC, *World J Clin Cases*) is to provide scholars and readers from various fields of clinical medicine with a platform to publish high-quality clinical research articles and communicate their research findings online.

WJCC mainly publishes articles reporting research results and findings obtained in the field of clinical medicine and covering a wide range of topics, including case control studies, retrospective cohort studies, retrospective studies, clinical trials studies, observational studies, prospective studies, randomized controlled trials, randomized clinical trials, systematic reviews, meta-analysis, and case reports.

**INDEXING/ABSTRACTING**

The WJCC is now indexed in Science Citation Index Expanded (also known as SciSearch®), Journal Citation Reports/Science Edition, Scopus, PubMed, and PubMed Central. The 2021 Edition of Journal Citation Reports® cites the 2020 impact factor (IF) for WJCC as 1.337; IF without journal self cites: 1.301; 5-year IF: 1.742; Journal Citation Indicator: 0.33; Ranking: 119 among 169 journals in medicine, general and internal; and Quartile category: Q3. The WJCC's CiteScore for 2020 is 0.8 and Scopus CiteScore rank 2020: General Medicine is 493/793.

**RESPONSIBLE EDITORS FOR THIS ISSUE**

Production Editor: Jia-Hui Li; Production Department Director: Yun-Jie Ma; Editorial Office Director: Jin-Lei Wang.

**NAME OF JOURNAL**

*World Journal of Clinical Cases*

**ISSN**

ISSN 2307-8960 (online)

**LAUNCH DATE**

April 16, 2013

**FREQUENCY**

Thrice Monthly

**EDITORS-IN-CHIEF**

Dennis A Bloomfield, Sandro Vento, Bao-Gan Peng

**EDITORIAL BOARD MEMBERS**

<https://www.wjnet.com/2307-8960/editorialboard.htm>

**PUBLICATION DATE**

September 16, 2021

**COPYRIGHT**

© 2021 Baishideng Publishing Group Inc

**INSTRUCTIONS TO AUTHORS**

<https://www.wjnet.com/bpg/gerinfo/204>

**GUIDELINES FOR ETHICS DOCUMENTS**

<https://www.wjnet.com/bpg/GerInfo/287>

**GUIDELINES FOR NON-NATIVE SPEAKERS OF ENGLISH**

<https://www.wjnet.com/bpg/gerinfo/240>

**PUBLICATION ETHICS**

<https://www.wjnet.com/bpg/GerInfo/288>

**PUBLICATION MISCONDUCT**

<https://www.wjnet.com/bpg/gerinfo/208>

**ARTICLE PROCESSING CHARGE**

<https://www.wjnet.com/bpg/gerinfo/242>

**STEPS FOR SUBMITTING MANUSCRIPTS**

<https://www.wjnet.com/bpg/GerInfo/239>

**ONLINE SUBMISSION**

<https://www.f6publishing.com>



## Low-grade chondrosarcoma of the larynx: A case report

Ljiljana Vučković, Aleksandra Klisic, Aleksandar Filipović, Mirko Popović, Tatjana Čulafić

**ORCID number:** Ljiljana Vučković 0000-0002-7861-9001; Aleksandra Klisic 0000-0001-7870-0996; Aleksandar Filipović 0000-0002-2992-8318; Mirko Popović 0000-0002-8624-1520; Tatjana Čulafić 0000-0002-9111-1114.

**Author contributions:** Vučković L and Klisic A reviewed the literature and drafted the manuscript; Vučković L wrote the manuscript; Filipović A and Popović M performed the surgery, reviewed the literature and drafted the manuscript; Vučković L and Čulafić T performed the pathohistological analyses, interpreted the imaging findings and drafted the manuscript; Vučković L and Klisic A revised the manuscript and provided important intellectual content; all authors provided final approval for the final version of the manuscript.

**Informed consent statement:** Informed written consent was obtained from the patient for publication of this report and any accompanying images.

**Conflict-of-interest statement:** The authors declare that they have no conflict of interest.

**CARE Checklist (2016) statement:** The authors have read the CARE Checklist (2016), and the manuscript was prepared and revised according to the CARE

**Ljiljana Vučković**, Clinical Center of Montenegro, Department of Pathology, University of Montenegro-Faculty of Medicine, Podgorica 81000, Montenegro

**Aleksandra Klisic**, Primary Health Care Center, University of Montenegro-Faculty of Medicine, Podgorica 81000, Montenegro

**Aleksandar Filipović**, Clinical Center of Montenegro, Department of Endocrine Surgery, University of Montenegro-Faculty of Medicine, Podgorica 81000, Montenegro

**Mirko Popović**, Clinical Center of Montenegro, Clinic for Otorhinolaryngology and Maxillofacial Surgery, University of Montenegro-Faculty of Medicine, Podgorica 81000, Montenegro

**Tatjana Čulafić**, Department of Pathology, Clinical Center of Montenegro, Podgorica 81000, Montenegro

**Corresponding author:** Aleksandra Klisic, PhD, Chief Doctor, Research Scientist, Primary Health Care Center, University of Montenegro-Faculty of Medicine, Trg Nikole Kovacevica 6, Podgorica 81000, Montenegro. [aleksandraklisic@gmail.com](mailto:aleksandraklisic@gmail.com)

### Abstract

#### BACKGROUND

Chondrosarcomas of the larynx are malignant tumours that most commonly originate from the hyaline cartilage. Chondrosarcoma of the larynx, the most common type of low-grade tumour, accounts for 1% of all laryngeal neoplasms.

#### CASE SUMMARY

We present the case of a 60-year-old female patient who developed progressive hoarseness and shortness of breath over a 2-mo period. The patient had undergone resection of a laryngeal tumour 14 years before the aforementioned symptoms occurred, and histopathological analysis indicated that it was a chondroma. During the assessment of the patient, a submucosal, oval-shaped tumour was detected that was predominantly located on the left side of the larynx and was approximately 6 cm in size. The decision to perform left partial vertical laryngectomy was made. A pathohistological diagnosis of low-grade chondrosarcoma was made. Considering the results of pathohistological analysis and the positive margins of the resection, a total laryngectomy was performed. During the 12-mo follow-up, no local relapse or regional or distant metastases was detected.

#### CONCLUSION

Chondrosarcoma of the larynx must be considered in the differential diagnosis of laryngeal submucosal tumours. It is crucial to carefully sample of tumour tissue,

Checklist (2016).

**Open-Access:** This article is an open-access article that was selected by an in-house editor and fully peer-reviewed by external reviewers. It is distributed in accordance with the Creative Commons Attribution NonCommercial (CC BY-NC 4.0) license, which permits others to distribute, remix, adapt, build upon this work non-commercially, and license their derivative works on different terms, provided the original work is properly cited and the use is non-commercial. See: <http://creativecommons.org/licenses/by-nc/4.0/>

**Manuscript source:** Unsolicited manuscript

**Specialty type:**  
Otorhinolaryngology

**Country/Territory of origin:**  
Montenegro

**Peer-review report's scientific quality classification**

Grade A (Excellent): 0  
Grade B (Very good): 0  
Grade C (Good): C  
Grade D (Fair): 0  
Grade E (Poor): 0

**Received:** February 2, 2021

**Peer-review started:** February 2, 2021

**First decision:** April 25, 2021

**Revised:** April 25, 2021

**Accepted:** August 10, 2021

**Article in press:** August 10, 2021

**Published online:** September 16, 2021

**P-Reviewer:** Li XY

**S-Editor:** Liu M

**L-Editor:** A

**P-Editor:** Liu JH



differentiate chondroma and chondrosarcoma, and consider the possibility of malignant changes from chondroma to chondrosarcoma.

**Key Words:** Chondrosarcoma; Low grade; Larynx; Case report

©The Author(s) 2021. Published by Baishideng Publishing Group Inc. All rights reserved.

**Core Tip:** Chondrosarcomas (ChSs) of the larynx are malignant tumours with a mesenchymal origin that most commonly originate from the hyaline cartilage. Although high-grade ChS of the larynx has also been described, low-grade tumours are the most common form of this disease. They are much more common in Caucasians and the men. This case highlights the utmost importance of recognizing mesenchymal tumours, especially those with a cartilage origin, during differential diagnosis in cases of intramural pathological processes in the laryngeal wall with a preserved mucosa, as these tumours are rare. It is crucial to carefully sample the tumour tissue, differentiate chondroma and chondrosarcoma, and consider the possibility of malignant changes from chondroma to chondrosarcoma.

**Citation:** Vučković L, Klisic A, Filipović A, Popović M, Čulafić T. Low-grade chondrosarcoma of the larynx: A case report. *World J Clin Cases* 2021; 9(26): 7805-7810

**URL:** <https://www.wjgnet.com/2307-8960/full/v9/i26/7805.htm>

**DOI:** <https://dx.doi.org/10.12998/wjcc.v9.i26.7805>

## INTRODUCTION

Chondrosarcomas (ChSs) of the larynx are malignant tumours with a mesenchymal origin that most commonly originate from the hyaline cartilage[1]. These tumours represent 0.1% of all tumours of the head and neck region and may occur in the nasal cavity, maxilla, and mandible in addition to the larynx. In regard to the larynx, ChS accounts for 1% of all laryngeal neoplasms[2,3]. Although these tumours rarely occur in the larynx, they have the second highest frequency after tumours originating from epithelial tissue, squamous cell carcinoma and adenocarcinoma[4]. Although high-grade ChS of the larynx has also been described, low-grade tumours are the most common form of the disease[1,5].

These tumours most commonly occur in the cricoid cartilage[6]. The tumours most commonly present on the anterior surface of the posterior lamina of the cricoid cartilage. Cases of occurrence in the epiglottis have also been described (3%)[7,8]. ChS of the larynx often occurs in elderly individuals, usually in the seventh decade of life (average age of 63 years)[1]. These tumours are much more common in Caucasians[1] and men (male-to-female ratio = 3.2:1). These tumours rarely progress to regional and distant metastases, even in the T4 stage[9]. Symptoms depend on the location and size of the tumour. Most often, the clinical symptoms are dominated by dyspnoea, dysphasia, dysphonia, and cough with hoarseness. The aetiology of tumour formation remains unclear[1,2]. In addition to clinical examinations, computed tomography and magnetic resonance imaging are recommended as diagnostic imaging methods. A definitive diagnosis is made by histopathological analysis of the tumour tissue. In terms of differential diagnosis, it is necessary to exclude chondroma in cases of low-grade ChS. In cases of high-grade ChS, other types of poorly differentiated malignant tumours (primarily other sarcomas and poorly differentiated cancers) should be excluded.

Chondromas and ChSs are known to be found synchronously in the same tumour or metachronously as a consequence of the malignant transformation of chondroma into ChS, suggesting the enormous importance of adequate sampling of tumour tissue during a pathologic analysis[5]. Surgery is the treatment method of choice[7]. It is important to describe rare cases in clinical practice for the purpose of differential diagnostic assessment, with the aim of making an accurate diagnosis and selecting the proper treatment. Here, we present a case study of a patient treated for low-grade ChS of the larynx.



## CASE PRESENTATION

### **Chief complaints**

We present a case of a 60-year-old female patient who developed progressive hoarseness and shortness of breath.

### **History of present illness**

Hoarseness and shortness of breath developed progressively over a 2-mo period.

### **History of past illness**

The patient underwent resection of a laryngeal tumour 14 years before the aforementioned symptoms developed, and histopathological analysis indicated that it was a chondroma.

### **Personal and family history**

The patient had suffered from hypertension for many years, with no significant hereditary diseases. She worked in administrative jobs and never smoked cigarettes or consumed alcohol.

### **Physical examination**

Palpatory examination of the neck during patient assessment revealed an oval-shaped tumour, which was predominantly located on the left side, approximately 6 cm in size, and fixed to the larynx wall. No enlarged lymph nodes were found.

By indirect laryngoscopy, the left hemilarynx was found to be immobile and displaced medially, and the respiratory space was reduced. The mucous membrane was unchanged.

### **Laboratory examinations**

Laboratory analyses were within the reference values.

### **Imaging examinations**

A computed tomography examination of the neck found a hypodense tumour, permeated with calcifications, up to 5.6 cm in diameter on the left, in the laryngeal wall in the subglottic segment, with no clear boundaries. The tumour infiltrated and partially destroyed the cricoid and thyroid cartilage. The tumour asymmetrically and significantly narrowed the lumen of the subglottic laryngeal segment (**Figure 1**). On computed tomography, no enlarged and pathologically altered lymph nodes were found, and there were no pathological changes in bone structure.

A lung X-ray and abdominal ultrasound were performed, and no distant metastases were found.

### **Pathohistological analysis**

A portion of the larynx wall and a resected portion of the trachea were submitted for pathohistological analysis, with tumour tissue with a lobulated appearance, 6 cm × 4 cm × 2 cm in size, a whitish colour, homogeneous structure, and moderately solid consistency.

The histology of the tumour tissue was dominated by a moderately abundant basophilic extracellular matrix, part of which had a myxoid appearance. The cellularity of the tumour tissue was moderately focal, with atypical, individual or organized smaller clusters and smaller chondrocytes with rare mitoses present in extracellular matrix lacunae (**Figure 2**). The tumour growth was nodulo-infiltrative.

## FINAL DIAGNOSIS

A final diagnosis of low-grade ChS was made based on the morphological characteristics of the tumour tissue.

The tumour tissue was located focally on the resection line of the surgical specimen.

## TREATMENT

The decision to perform left partial vertical laryngectomy was made based on the

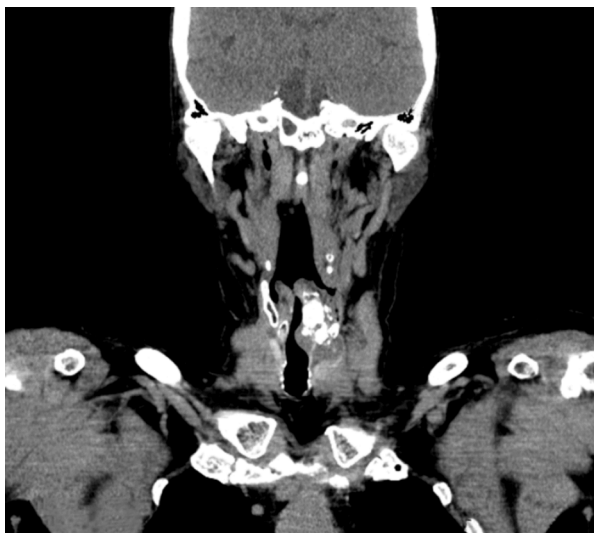

Figure 1 Computed tomography of laryngeal chondrosarcoma.

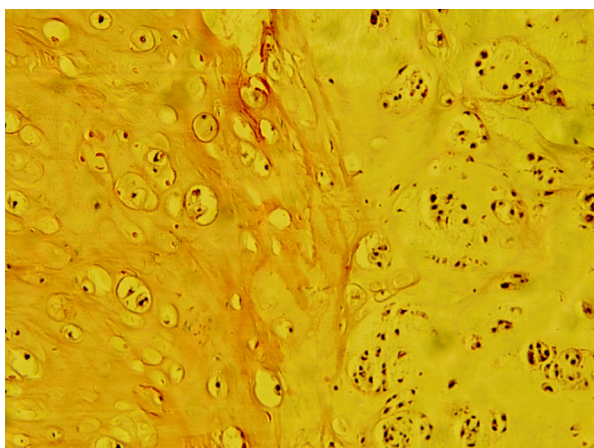


Figure 2 Fields with different cellularity and degrees of atypia of chondrosarcoma (hematoxylin-eosin, × 10).

previous diagnosis of chondroma and the size of the tumour, with the aim of preserving larynx function. Intraoperatively, a hard, nodular-infiltrative tumour was found, including the subglottis from the medial line to the left, as well as the first two tracheal rings. Subsequently, the tumour tissue infiltrated the left subglottis back to the medial line as well as up to the inferior horn of the infiltrated left thyroid cartilage. The tumour tissue was resected *en bloc*, including the surrounding larynx tissue (up to 5 mm wide), the left half of the trachea to the third ring, back along the medial line and up to the lower edge of the thyroid cartilage, with horn resection. A reconstruction of the defect was made with the perichondrium of the left thyroid plate and local mucous membrane.

## OUTCOME AND FOLLOW-UP

In consideration of the results of the pathohistological analysis and positive margins of the resection, a total laryngectomy was performed based on the decision of a multidisciplinary team. Low-grade ChS microscopic foci were found in the rest of the larynx wall. The operative and postoperative courses were regular.

During the 12-mo follow-up, no local relapse or regional or distant metastases were detected in the patient.

## DISCUSSION

Here, we present a case of a 60-year-old female patient who was diagnosed with low-grade ChS 14 years after the diagnosis of laryngeal chondroma of the cricoid cartilage. Considering that these tumours are extremely rare, it is of the utmost importance to recognize these types of cartilage-origin neoplasms. These facts should be taken into account when considering the differential diagnosis in cases of intramural pathological processes with a preserved laryngeal mucosa.

ChS is characterized primarily by the infiltration of surrounding tissues, although lymphogenic and haematogenous metastases have been reported in approximately 10% of cases. Metastases to the lymph nodes, lungs, bones, kidney, spleen and spinal cord have been described[5].

The risk factors are unknown. Recurrent laryngeal trauma, radiotherapy, Teflon injections and irregular ossification of the laryngeal cartilage are reported as possible causes. Recurrent ischaemia in chondroma has also been reported as a possible cause for the onset of this tumour[1]. In addition to abnormal cartilage ossification, Gao and co-workers proposed two additional theories: that the tumour is caused by congenital cartilage residues or that chondroplasia occurs due to chronic inflammation. In the literature review, this group of authors cited a case of the malignant transformation of chondroma into ChS within 6 years[10]. Wang *et al*[7] stated that no correlation between alcohol consumption and cigarette smoking with the onset of this tumour has been demonstrated.

The patient described in this study had been treated for hypertension for many years. She was a non-smoker and did not consume alcohol.

The clinical manifestations of laryngeal ChS may be nonspecific[2]. Symptoms of laryngeal ChS include dyspnoea (if intraluminal tumour growth is dominant), dysphagia (if pharynx infiltration is dominant), and progressive hoarseness. Considering that this is a slow-growing tumour, the patient can tolerate the narrowing airways for a long time, and therefore acute respiratory failure may be the first symptom to occur. In ChS with a thyroid cartilage origin, the clinical picture may also be dominated by a painless tumour mass[5].

The clinical manifestations of this patient were dominated by hoarseness and respiratory problems.

When a submucosal mass is found during endoscopic examination, most commonly infraglottic and posterior, soft tissue laryngeal tumours should be considered. Although the mucosa is usually smooth, it can be ulcerated in the case of larger tumours. Computed tomography and magnetic resonance imaging are recommended as radiological examinations. Each of these methods has advantages in the analysis of tumour tissue, as well as in the evaluation of the relationship of tumour tissue to the surrounding structures of the laryngeal wall[5,7]. Surgical excision is the treatment method of choice for ChS. Tumour resections must have clear margins. Based on the fact that cervical lymph node metastases are rare, neck dissection should be reserved for clinically or radiologically suspected lymph node metastases. The complex function of the larynx depends on the conservation of the cricoid cartilage[11]. Surgery that preserves laryngeal function is recommended whenever possible. Since 75% of laryngeal ChS forms in the cricoid cartilage, which is considered crucial for laryngeal function, its preservation is often not possible. Total laryngectomy is recommended in cases where more than half of the cricoid cartilage is destroyed by tumour tissue, as well as in cases involving relapse[2,7]. Nonsurgical treatment modalities are rarely used for the treatment of this tumour[8]. Radiotherapy does not seem to play a significant role in the treatment of laryngeal ChS. In the past, it was used to provide local disease control in cases of unresectable or recurrent disease. Chemotherapy has not been shown to be effective for laryngeal ChS, especially low-grade ChS[5,10]. Most authors report relapses in 16% to 50% of cases[1,2]. Regarding the prognosis of this disease, the expected one-year survival rate is 96.5%, the five-year survival rate is 88.6% and the ten-year survival rate is 84.8% of patients[1]. Definitive diagnosis is made by histopathological analysis. The histology of the tumour is dominated by a basophilic acellular matrix (on haematoxylin-eosin stained preparations) containing lacunae with cells[5]. Cell characteristics, nuclear characteristics, cellularity, and the mitotic index are important for histological analysis[1,7]. Macroscopic tumour tissue is solid and hard in consistency. However, it is possible to find softer and even cystic parts due to degenerative changes. In cases of resection of the laryngeal wall, smooth mucosa is often located above the tumour tissue[5].

Since most laryngeal ChSs are tumours with low-grade differentiation, they are characterized by a lobular-infiltrative growth pattern with cartilage destruction. Given that the most common case in practice is low-grade laryngeal ChS, the differential

diagnosis of chondroma and low-grade ChS is very important[5]. Microscopic chondromas are hypocellular (30 to 40 nuclei/HPF), with a homogenous structure and lobular growth pattern, with no cellular atypia or mitosis. Increased cellularity, cellular atypia, binucleation in lacunae, hyperchromasia, a prominent nucleolus, mitoses, and pleomorphism all suggest ChS. It is especially important to analyse parts of the tumour in the border zone compared to the preserved portions of the laryngeal wall[1,5,7]. Immunohistochemical analysis is rarely required. ChS tumour cells are positive for vimentin, S100 and D2-40[1,5]. In less differentiated ChS, cellularity increases and nuclear pleomorphism, hyperchromasia, and mitotic activity are increased[1]. In cases of poorly differentiated laryngeal ChSs, chondroblastic osteosarcoma, fibrosarcoma, myxoid liposarcoma, embryonic rhabdomyosarcoma, spindle cell squamous cell carcinoma with cartilaginous metaplasia should be included in differential diagnosis[5].

## CONCLUSION

It is important that mesenchymal tumours, especially those with a cartilage origin, are considered during differential diagnosis in cases of intramural pathological processes in the laryngeal wall with a preserved mucosa. Laryngeal ChS case reports are important because these tumours are rare. It is crucial to carefully sample the tumour tissue, differentiate chondroma and ChS, and consider the possibility of malignant changes from chondroma to ChS.

## REFERENCES

- 1 **El-Naggar A**, Chan JKC, Grandis JR, Tkata T, Slootweg P. WHO Classification of head and neck tumours. 4th ed. Lyon: IARC, 2017
- 2 **Zhou HW**, Wang J, Liu Y, Zhang HM. Recurrent chondrosarcoma of the larynx: A case report and literature review. *Medicine (Baltimore)* 2016; **95**: e4118 [PMID: 27399118 DOI: 10.1097/MD.00000000000004118]
- 3 **Cleven AHG**, Schreuder WH, Groen E, Kroon HM, Baumhoer D. Molecular findings in maxillofacial bone tumours and its diagnostic value. *Virchows Arch* 2020; **476**: 159-174 [PMID: 31838586 DOI: 10.1007/s00428-019-02726-2]
- 4 **Saraydaroglu O**, Narter S, Ozsen M, Coskun H. Non-epithelial tumors of the larynx: case series of 12 years. *Eur Arch Otorhinolaryngol* 2019; **276**: 2843-2847 [PMID: 31256243 DOI: 10.1007/s00405-019-05527-0]
- 5 **Ferlito A**, Devaney KO, Mäkitie AA. Differing characteristics of cartilaginous lesions of the larynx. *Eur Arch Otorhinolaryngol* 2019; **276**: 2635-2647 [PMID: 31338576 DOI: 10.1007/s00405-019-05563-w]
- 6 **Magliocca KR**, Edgar MA, Corey A, Villari CR. Dedifferentiated chondrosarcoma of the larynx: Radiological, gross, microscopic and clinical features. *Ann Diagn Pathol* 2017; **30**: 42-46 [PMID: 28965627 DOI: 10.1016/j.anndiagpath.2017.05.010]
- 7 **Wang Q**, Chen H, Zhou S. Chondrosarcoma of the larynx: report of two cases and review of the literature. *Int J Clin Exp Pathol* 2015; **8**: 2068-2073 [PMID: 25973106]
- 8 **Chin OY**, Dubal PM, Sheikh AB, Unsal AA, Park RC, Baredes S, Eloy JA. Laryngeal chondrosarcoma: A systematic review of 592 cases. *Laryngoscope* 2017; **127**: 430-439 [PMID: 27291822 DOI: 10.1002/lary.26068]
- 9 **Dubal PM**, Svider PF, Kanumuri VV, Patel AA, Baredes S, Eloy JA. Laryngeal chondrosarcoma: a population-based analysis. *Laryngoscope* 2014; **124**: 1877-1881 [PMID: 24474667 DOI: 10.1002/lary.24618]
- 10 **Gao CP**, Liu JH, Hou F, Liu H, Xu WJ. Low-grade chondrosarcoma of the cricoid cartilage: a case report and review of the literature. *Skeletal Radiol* 2017; **46**: 1597-1601 [PMID: 28756568 DOI: 10.1007/s00256-017-2731-5]
- 11 **Rovó L**, Bach Á, Sztanó B, Matievics V, Szegedi I, Castellanos PF. Rotational thyrotracheopexy after cricoideotomy for low-grade laryngeal chondrosarcoma. *Laryngoscope* 2017; **127**: 1109-1115 [PMID: 27364085 DOI: 10.1002/lary.26142]



Published by **Baishideng Publishing Group Inc**  
7041 Koll Center Parkway, Suite 160, Pleasanton, CA 94566, USA

**Telephone:** +1-925-3991568

**E-mail:** [bpgoffice@wjgnet.com](mailto:bpgoffice@wjgnet.com)

**Help Desk:** <https://www.f6publishing.com/helpdesk>

<https://www.wjgnet.com>

