Answering Reviewers

Authors: The reviewer to the MS "Carotid-Subclavian Bypass and Endovascular Aortic Repair of Kommerell's Diverticulum with Aberrant Left Subclavian Artery" as follows:

Question 3: This patient is asymptomatic, incidentally detected ectatic KD, no brachial-brachial or brachial-femoral pulse delay, could have been waited with beta blocker, the evidence based approach in the index case needs to be clarified.

- In the case of asymptomatic ectatic KD, the treatment modality between surgery and medical treatment with beta blockers, depends on numerous elements such as age, the severity of coronary artery dilation, any complications, and overall health status of the patient.

- Beta blockers are more effective in dealing with minor symptoms and in some cases, preventing the complications whereas surgical procedure is needed when there are any complications or significant dilatation of the arterial vessel.

- A collective approach via a multi-disciplinary team (MDT) of healthcare professionals involving vascular surgeons, cardiologists, and primary healthcare doctors must be done to find the best treatment option for each individual patient and reach an ultimate decision.

- To conclude, there is no clear agreement on the necessity for surgical intervention in patients with incidentally detected ectatic KD and no brachial-brachial or brachial-femoral pulse delay. Instead, a comprehensive literature review recommends that surgery may be necessary to avoid complications, and improving the symptoms and quality of life of these patients.

Question 4: The static CT; how could it diagnose subclavian artery steal syndrome (SASS)?

- Subclavian artery steal syndrome is defined as a state characterized by the backflow of blood in the vertebral artery as a result of occlusion or severe stenosis of the proximal subclavian artery. This backflow results as a compensatory mechanism to preserve the blood supply to the upper limbs, thereby leading to diminished blood flow to the brain. The clinical features are syncope, dizziness, vertigo, visual disturbances and claudication of the limbs.

- To diagnose this syndrome, a combination of detailed history, clinical examination, imaging studies, and functional tests are needed. In the overall diagnosis process, Doppler ultrasound is an initial tool to assess blood velocities, and any possibility for any stenosis, followed by static CT scan. Though, the precise anatomy of the subclavian artery is demonstrated by static computed tomography (CT), it may not be adequate to diagnose SASS on its own.

- More advanced dynamic imaging techniques such as digital subtraction angiography (DSA) or magnetic resonance angiography (MRA) are used to evaluate the anatomy and hemodynamics of the subclavian artery. In the DSA procedure, a contrast dye is injected into the subclavian artery

and X-ray images are captured to see the blood flow patterns. While in MRA, contrast dye is not used but magnetic fields and radio waves are used to create images of blood vessels.

- Furthermore, static CT provide high resolution images of the subclavian artery and the adjacent structures, thereby able to detect any stenosis or compression. Moreover, additional tests such as Allen's test and Adson's test.

- Allen's test assesses the collateral circulation in the hand by occluding both the radial and ulnar arteries and then releasing the pressure on one artery at a time to note for immediate refill. The other test is the reverse Adson's test, which involves the patient's head positioning in extension while measuring the blood pressure changes in the affected arm.

- To summarize, the static CT scan is one of the important investigation about the detection of subclavian artery steal syndrome supported by other imaging studies such as Doppler Ultrasound, DSA or MRA and clinical tests such as Allen's test and reverse Adson's test, thereby providing an accurate diagnosis.

5. Provide DSA image during placement of endovascular graft

DSA image during placement of endovascular graft

6. The case management style is good and would be interesting to the researchers.

Yes, the case report is an innovative one.

7. What was the necessity of carotid artery to LSCA graft when the authors have opine that the patient is clinically have no subclavian steal syndrome?

- The necessity of a carotid artery to left subclavian artery (LSCA) graft in patients without clinical subclavian steal syndrome (SSS) is a debatable topic that necessitates a broad understanding of the underlying pathophysiology and surgical considerations. To address this question, it is important to discuss the anatomy and function of the carotid artery and LSCA, as well as the potential indications for performing a carotid artery to LSCA graft. First of all, the severity and location of the stenosis or occlusion in the subclavian artery needs to be evaluated. If the stenosis is distal to the origin of the vertebral artery, the risk of subclavian steal syndrome is significantly reduced, and therefore, a carotid artery to LSCA graft may not be necessary.

- Next, the presence of collateral circulation should be evaluated. Collateral vessels develop over time to compensate for reduced blood flow in cases of subclavian artery stenosis or occlusion. If collateral circulation is not well-established and there is no adequate blood supply to the arm and brain, the need for a carotid artery to LSCA graft should be considered.

- Thirdly, the overall clinical status and symptoms of the patient are of concern. Even if a patient is clinically asymptomatic for subclavian steal syndrome, other comorbidities such as the presence of coronary artery disease or aortic arch pathology may affect the decision-making process. In such cases, a carotid artery to LSCA graft should be considered to safeguard optimum blood supply to both upper limbs and brain during surgical interventions.

8. Provide better image or a focused image for subclavian artery stenosis

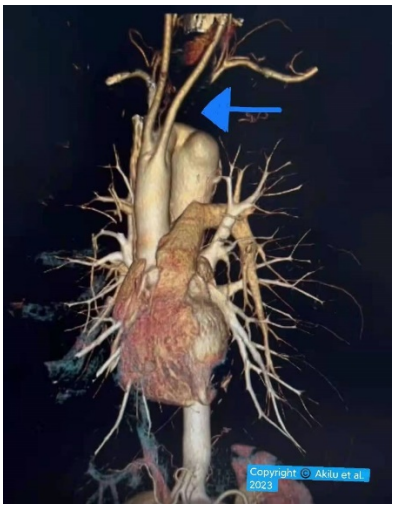

This image is the subclavian artery stenosis (blue arrow).

9. Provide a bit better captions for the images

DSA image during placement of endovascular graft.

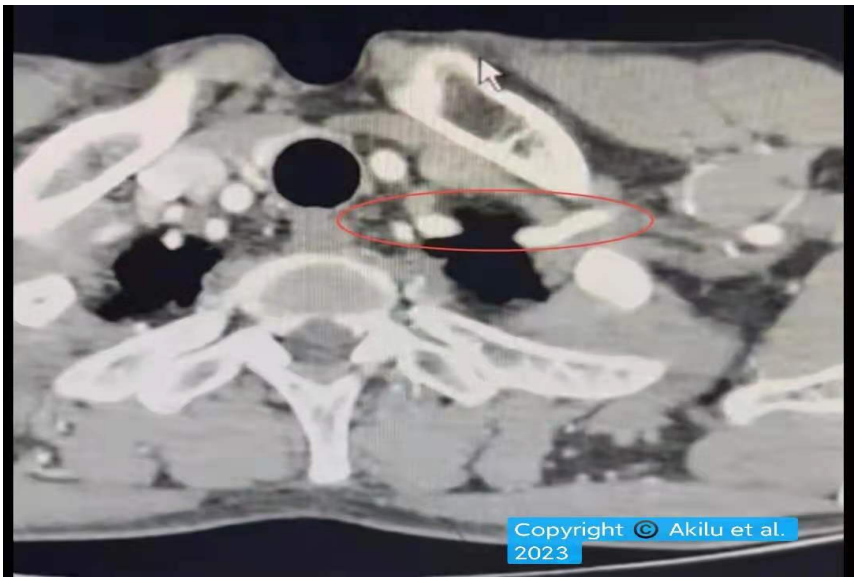

The location of Left Subclavian Artery (LSA) stenosis encircled.

DSA video during placement of endovascular graft.mp4