


World Journal of *Gastroenterology*

World J Gastroenterol 2023 April 7; 29(13): 1911-2063



REVIEW

- 1911 Application of nanotechnology in reversing therapeutic resistance and controlling metastasis of colorectal cancer

Ren SN, Zhang ZY, Guo RJ, Wang DR, Chen FF, Chen XB, Fang XD

MINIREVIEWS

- 1942 Interferon-lambda: New role in intestinal symptoms of COVID-19

Pan YY, Wang LC, Yang F, Yu M

- 1955 Comprehensive review on small common bile duct stones

Masuda S, Koizumi K, Shionoya K, Jinushi R, Makazu M, Nishino T, Kimura K, Sumida C, Kubota J, Ichita C, Sasaki A, Kobayashi M, Kako M, Haruki U

- 1969 Liver transplantation in the management of cholangiocarcinoma: Evolution and contemporary advances

Borakati A, Froghi F, Bhogal RH, Mavroeidis VK

- 1982 Research progress on the mitochondrial mechanism of age-related non-alcoholic fatty liver

Wang D, Ji DC, Yu CY, Wu DN, Qi L

ORIGINAL ARTICLE

Case Control Study

- 1994 Gut microbiota predicts the diagnosis of celiac disease in Saudi children

El Mouzan M, Assiri A, Al Sarkhy A

Retrospective Study

- 2001 Preoperative prediction of macrotrabecular-massive hepatocellular carcinoma through dynamic contrast-enhanced magnetic resonance imaging-based radiomics

Zhang Y, He D, Liu J, Wei YG, Shi LL

Observational Study

- 2015 Changes in characteristics of patients with hepatitis C virus-related cirrhosis from the beginning of the interferon-free era

Brzdek M, Zarębska-Michaluk D, Rzymiski P, Lorenc B, Kazek A, Tudrujek-Zdunek M, Janocha-Litwin J, Mazur W, Dybowska D, Berak H, Parfieniuk-Kowerda A, Klapaczyński J, Sitko M, Sobala-Szczygiel B, Piekarska A, Flisiak R

Randomized Clinical Trial

- 2034 Exploring choices of early nutritional support for patients with sepsis based on changes in intestinal microecology

Yang XJ, Wang XH, Yang MY, Ren HY, Chen H, Zhang XY, Liu QF, Yang G, Yang Y, Yang XJ

SYSTEMATIC REVIEWS

- 2050** Occam's razor or Hickam's dictum-COVID-19 is not a textbook aetiology of acute pancreatitis: A modified Naranjo Score appraisal

Teng TZJ, Chua BQY, Lim PK, Chan KS, Shelat VG

ABOUT COVER

Editorial Board Member of *World Journal of Gastroenterology*, Georgios Tsoulfas, AGAF, FACS, FICS, MD, PhD, Professor, Transplant Surgery, Aristotle University of Thessaloniki School of Medicine, Thessaloniki 54124, Greece. tsoulfasg@gmail.com

AIMS AND SCOPE

The primary aim of *World Journal of Gastroenterology* (WJG, *World J Gastroenterol*) is to provide scholars and readers from various fields of gastroenterology and hepatology with a platform to publish high-quality basic and clinical research articles and communicate their research findings online. WJG mainly publishes articles reporting research results and findings obtained in the field of gastroenterology and hepatology and covering a wide range of topics including gastroenterology, hepatology, gastrointestinal endoscopy, gastrointestinal surgery, gastrointestinal oncology, and pediatric gastroenterology.

INDEXING/ABSTRACTING

The WJG is now abstracted and indexed in Science Citation Index Expanded (SCIE, also known as SciSearch®), Current Contents/Clinical Medicine, Journal Citation Reports, Index Medicus, MEDLINE, PubMed, PubMed Central, Scopus, Reference Citation Analysis, China National Knowledge Infrastructure, China Science and Technology Journal Database, and Superstar Journals Database. The 2022 edition of Journal Citation Reports® cites the 2021 impact factor (IF) for WJG as 5.374; IF without journal self cites: 5.187; 5-year IF: 5.715; Journal Citation Indicator: 0.84; Ranking: 31 among 93 journals in gastroenterology and hepatology; and Quartile category: Q2. The WJG's CiteScore for 2021 is 8.1 and Scopus CiteScore rank 2021: Gastroenterology is 18/149.

RESPONSIBLE EDITORS FOR THIS ISSUE

Production Editor: *Ying-Yi Yuan*; Production Department Director: *Xiang Li*; Editorial Office Director: *Jia-Ru Fan*.

NAME OF JOURNAL

World Journal of Gastroenterology

ISSN

ISSN 1007-9327 (print) ISSN 2219-2840 (online)

LAUNCH DATE

October 1, 1995

FREQUENCY

Weekly

EDITORS-IN-CHIEF

Andrzej S Tarnawski

EDITORIAL BOARD MEMBERS

<http://www.wjgnet.com/1007-9327/editorialboard.htm>

PUBLICATION DATE

April 7, 2023

COPYRIGHT

© 2023 Baishideng Publishing Group Inc

INSTRUCTIONS TO AUTHORS

<https://www.wjgnet.com/bpg/gerinfo/204>

GUIDELINES FOR ETHICS DOCUMENTS

<https://www.wjgnet.com/bpg/GerInfo/287>

GUIDELINES FOR NON-NATIVE SPEAKERS OF ENGLISH

<https://www.wjgnet.com/bpg/gerinfo/240>

PUBLICATION ETHICS

<https://www.wjgnet.com/bpg/GerInfo/288>

PUBLICATION MISCONDUCT

<https://www.wjgnet.com/bpg/gerinfo/208>

ARTICLE PROCESSING CHARGE

<https://www.wjgnet.com/bpg/gerinfo/242>

STEPS FOR SUBMITTING MANUSCRIPTS

<https://www.wjgnet.com/bpg/GerInfo/239>

ONLINE SUBMISSION

<https://www.f6publishing.com>



Comprehensive review on small common bile duct stones

Sakue Masuda, Kazuya Koizumi, Kento Shionoya, Ryuhei Jinushi, Makomo Makazu, Takashi Nishino, Karen Kimura, Chihiro Sumida, Jun Kubota, Chikamasa Ichita, Akiko Sasaki, Masahiro Kobayashi, Makoto Kako, Uojima Haruki

Specialty type: Gastroenterology and hepatology

Provenance and peer review: Invited article; Externally peer reviewed.

Peer-review model: Single blind

Peer-review report's scientific quality classification

Grade A (Excellent): 0
Grade B (Very good): B
Grade C (Good): C
Grade D (Fair): 0
Grade E (Poor): 0

P-Reviewer: Huang Y, China; Miao G, China

Received: December 1, 2022

Peer-review started: December 1, 2022

First decision: January 14, 2023

Revised: January 22, 2023

Accepted: March 20, 2023

Article in press: March 20, 2023

Published online: April 7, 2023



Sakue Masuda, Kazuya Koizumi, Kento Shionoya, Ryuhei Jinushi, Makomo Makazu, Takashi Nishino, Karen Kimura, Chihiro Sumida, Jun Kubota, Chikamasa Ichita, Akiko Sasaki, Masahiro Kobayashi, Makoto Kako, Department of Gastroenterology, Shonan Kamakura General Hospital, Kanagawa 247-8533, Japan

Uojima Haruki, Department of Gastroenterology, Kitasato University School of Medicine, Kanagawa 252-0375, Japan

Corresponding author: Sakue Masuda, MD, Chief Doctor, Department of Gastroenterology, Shonan Kamakura General Hospital, 1370-1 Okamoto, Kamakura, Kanagawa 247-8533, Japan. sakue.masuda@tokushukai.jp

Abstract

Common bile duct stones are among the most common conditions encountered by endoscopists. Therefore, it is well researched; however, some items, such as indications for endoscopic papillary balloon dilatation (EPBD), safety of EPBD and endoscopic sphincterotomy in patients receiving dual antiplatelet therapy or direct oral anticoagulant, selection strategy for retrieval balloons and baskets, lack adequate evidence. Therefore, the guidelines have been updated with new research, while others remain unchanged due to weak evidence. In this review, we comprehensively summarize the standard methods in guidelines and new findings from recent studies on papillary dilation, stone retrieval devices, difficult-to-treat cases, troubleshooting during the procedure, and complicated cases of cholangitis, cholecystolithiasis, or distal biliary stricture.

Key Words: Choledocholithotomy; Choledocholithiasis; Common bile duct stones; Endoscopic papillary balloon dilation; Endoscopic sphincterotomy; Small common bile duct stones

©The Author(s) 2023. Published by Baishideng Publishing Group Inc. All rights reserved.

Core Tip: In this review, we comprehensively summarized the standard methods for patients with small common bile duct stones in guidelines and new findings from recent studies on papillary dilation, stone retrieval devices, difficult-to-treat cases, troubleshooting during the procedure, and complicated cases of cholangitis, cholecystolithiasis, or distal biliary stricture.

Citation: Masuda S, Koizumi K, Shionoya K, Jinushi R, Makazu M, Nishino T, Kimura K, Sumida C, Kubota J, Ichita C, Sasaki A, Kobayashi M, Kako M, Haruki U. Comprehensive review on small common bile duct stones. *World J Gastroenterol* 2023; 29(13): 1955-1968

URL: <https://www.wjgnet.com/1007-9327/full/v29/i13/1955.htm>

DOI: <https://dx.doi.org/10.3748/wjg.v29.i13.1955>

INTRODUCTION

Cholangitis is the second or third most common cause of community-acquired bacteremia, with common bile duct (CBD) stones being the most common[1,2]. Recurrence of CBD stones is common, with 111 (11.3%) of 983 patients who underwent endoscopic sphincterotomy (EST) recurred during a median follow-up of 7.5 years, and the cumulative recurrence rates at 5, 10, 15, and 20 years were 8.5%, 12.5%, 19.1%, and 24.2%, respectively[3]. It is frequently encountered by endoscopists, and it is important to improve short-term outcomes and prevent the long-term recurrence of cholelithiasis. This review focuses on small CBD stones. Although the international definition of small CBD stones has not been established, we have followed the standard of approximately 10 mm in some studies[4,5]. We described papillary dilation, stone extraction, difficult cases, troubleshooting during stone extraction in small CBD stones, and complicated cases of cholangitis, cholecystolithiasis, or distal biliary stricture and summarized the European, American, and Japanese guidelines. Moreover, this review addressed the novel literatures on endoscopic papillary balloon dilatation (EPBD) dilation times to prevent post-endoscopic retrograde cholangiopancreatography (ERCP) pancreatitis (PEP)[6], the duration of direct oral anticoagulants (DOAC) and dual antiplatelet therapy (DAPT) withdrawal to safely perform EST[7, 8], EST with balloon dilation (ESBD), and the comparison of the effects of retrieval balloon and basket catheters for small CBD stone extraction[9,10].

COMPARISON OF EPBD AND EST

Papillary dilation is divided into EST and EPBD, and a nationwide administrative database of 61000 hospitalized patients with CBD stones throughout Japan reported that EST was performed in 89% of patients and EPBD in 11%[11]. Knowledge of the success rate of CBD stone removal and the incidence of short- and long-term complications is important when deciding between EST and EPBD.

Success rates of CBD stones clearance

A meta-analysis reported that EPBD has a lower incidence of total clearance of CBD stones and more frequent lithotripsy basket use than EST[12]. However, 11 of 14 references in this study included cases of CBD stones larger than 10 mm. Conversely, there were no significant differences in total clearance of CBD stones in another meta-analysis by Liu *et al*[13].

Yu *et al*[6] reported that both EST and EPBD have obvious effects in the treatment of bile duct stones with minor diameters (< 10 mm) and small numbers (< 3). The EPBD balloons used in that study were mostly 8 and 10 mm in diameter, especially those with 8 mm in diameter. Because a typical papillary dilation balloon is 8 mm in diameter, the indication for EPBD may be CBD stones up to 10 mm in diameter, considering the flexibility of the papillae. However, even for CBD stones > 10 mm, EPBD combined with endoscopic mechanical lithotripsy may have a success rate of stone retrieval comparable to that of EST[13]. Therefore, EPBD may be useful in cases of coagulopathy in which CBD stones are larger than 10 mm.

There is lack of evidence for the possibility of very small stone extraction without EST or EPBD. It has been reported that if ESWL results in stone fragment size of 3 mm or less, there is a likelihood that the stone will be spontaneously discharged without EST. Therefore, it is possible that stone extraction can be performed without EST or EPBD if the size is less than approximately 3 mm[14], however, there are no studies that have directly examined this issue. Therefore, in principle, EST and EPBD are recommended for stone extraction of CBD stones, as recommended by the European Society of Gastrointestinal Endoscopy (ESGE) and Japan Gastroenterological Endoscopy Society (JGES) guidelines; however, it is at the endoscopist's discretion whether to perform stone extraction without these procedures for very small stones[15,16].

Incidence of short-term complications

In cases of EPBD compared to EST, post-ERCP pancreatitis increased, bleeding decreased, and there was no significant difference in perforation or post-ERCP cholangitis. PEP and hemorrhage are likely to occur especially in approximately 10% and less than 0.1% of patients in the EPBD group, respectively; and in approximately 3% and 3% of patients in the EST group, respectively[12]. The total data in the meta-analysis has variation in the patient's background; however, it is consistent with that of a previous report[17].

PEP: PEP may be a short-term complication when selecting EST/EPBD. ESGE describes the following risk factors for PEP:

Patient-related definite risk factors include suspected sphincter of Oddi dysfunction, female sex, previous pancreatitis, and previous PEP. Procedure-related definite risk factors, such as difficult cannulation, pancreatic guidewire passage > 1, and pancreatic injection. Patient-related risk factors include younger age, non-dilated extrahepatic bile duct, normal serum bilirubin, absence of chronic pancreatitis, and end-stage renal disease. Procedure-related risk factors include precut sphincterotomy, pancreatic sphincterotomy, failure to clear bile duct stones, intraductal ultrasound, and biliary balloon sphincter dilation[18]. ESGE especially recommends prophylactic pancreatic stenting in selected patients at high risk for PEP (inadvertent guidewire insertion/opacification of the pancreatic duct and double-guidewire cannulation).

In a multicenter randomized control study, 117 patients with bile duct stones were treated with EPBD; after treatment, the incidence of pancreatitis among those patients reached 15.4%, and two patients died from post-treatment complications[19]. Incomplete dilation of the papilla, intramucosal bleeding, and local edema were considered the main causes of PEP due to EPBD. Conversely, several reports of randomized control trials or network meta-analyses suggested that there is no direct consequence between PEP risk and EPBD[20,21], and PEP usually occurs in the mild or moderate stage [12]. Recently, a network meta-analysis reported that 2 to 5 min of EPBD could decrease the incidence of PEP compared to short-term (< 2 min) EPBD. In addition, it was also reported to reduce PEP without increasing the occurrence of other early complications by extending the duration of balloon dilatation [6]. However, the underlying mechanism for this result remains unclear. A possible reason could be that the dilatation with a small diameter balloon or short duration could result in inadequate papilla expansion; thus, the common discharge channel for bile and pancreatic juice tended to be narrow after the operation[6]. That study did not examine EPBD longer than 5 min; however, another study found that 5-min EPBD increases PEP compared to EPBD of 0.5-3 min[22]. Although this is a study of EPBD combined with small-incision EST, it may be advisable to avoid EPBD for more than 5 min[22]. Therefore, we use a 2-3 min EPBD.

In recent years, diclofenac or diclofenac and sublingual nitrates have been reported to be useful for the prevention of PEP[23,24]. ESGE also recommends routine rectal administration of 100 mg of diclofenac or indomethacin immediately before ERCP in all patients without contraindications to nonsteroidal anti-inflammatory drug administration[18]. These methods were not available in 2004 when EPBD was abandoned by many endoscopists, especially in America, and combining such methods may reduce the incidence of PEP due to EPBD. Furthermore, EPBD may be even safer in Asians, as some race-based studies have shown no increase in PEP in Asian populations[12].

Bleeding: ESGE guidelines suggest that patients should be considered at increased risk of post-EST bleeding if at least one of the following factors is present: anticoagulant intake, platelet count < 50000/mm³, cirrhosis, dialysis of end-stage renal disease, intraprocedural bleeding, and low endoscopist experience[18].

ESGE, JGES, and the American Society of Gastrointestinal Endoscopy (ASGE) guidelines treat antiplatelet medications almost similarly for EST/EPBD. DAPT is permitted in EPBD without drug withdrawal, whereas EST requires DAPT withdrawal. Withdrawal regimens are similar across guidelines, with thienopyridine requiring 5-7 day withdrawal and continuation of aspirin or cilostazol monotherapy[18,25,26]. However, each guideline treats anticoagulants in a slightly complex and different manner. Although it is necessary to evaluate the risk of embolism and procedural bleeding when antithrombotic agents are stopped in EPBD, warfarin can be continued if the PT-INR is within the therapeutic range. In EST, treatment with warfarin can be continued, whereas the PT-INR is within the therapeutic range in Japan and America. However, in Europe and America, it is recommended to discontinue warfarin 5 d before EST and replace it with heparin 2 d before EST, especially in patients at high risk of embolism in aortic or mitral valve replacement, atrial fibrillation, or any thromboembolic risk. Once hemostasis is confirmed, antithrombotic agents must be restarted postoperatively in America, the next day in Japan, and within 2 d in Europe. Warfarin should be resumed after the procedure, and heparin should be used in combination until the PT-INR returns to the therapeutic range[18,25,26]. However, it is difficult to summarize each country's guidelines accurately and concisely; therefore, please refer to each country's guidelines for details. In addition, in DAPT and DOAC, there is a paucity of evidence regarding the ability of guideline-guided withdrawal periods to prevent bleeding[7,8,25,27].

With regards to hemorrhage, Mirjalili and Stringer[28] identified 98 arteries near the major papilla and reported blood vessel distribution on endoscopy. According to their report, blood vessel distri-

bution in the 10 to 11 o'clock region was low at 10%-11%; thus, cutting in this region has a low risk of hemorrhage. The ESGE and Japanese EST guidelines have cited this article[16,18]. No trials have compared hemorrhage and perforation according to cutting direction; however, adding to the reports that bile ducts tend to run in the 11 to 12 o'clock direction in the papillary region, cutting in the 11 to 12 o'clock direction is considered safe, and thus recommended by Japanese EST guidelines[16].

Others: The superior sphincter extends to the bile duct on the lateral wall of the duodenum, and cutting beyond this area increases the risk of perforation. In relation to the papilla, it is believed that the superior margin of the papillary bulge coincides with the middle sphincter, which is considered the upper cutting limit (Figure 1). However, anatomical examinations may not necessarily be consistent with actual living bodies, and depending on the cutting direction, perforation can occur even if the superior margin of the papillary bulge is not reached; thus, due care should be exercised[16]. Moreover, there is no evidence comparing incision size to the incidence of procedural adverse events or therapeutic outcomes following EST[16].

The incidence of short-term cholecystitis after ERCP could be caused by resistance to initial antibiotics on admission[29], and the incidence of long-term cholecystitis and the recurrence of stones in CBD could be decreased by EPBD compared to EST[6,12]. EST causes significant damages to the Oddi sphincter, and post-EST sphincter dysfunction easily occurs[30]. Then, the reflux of intestinal contents such as digestive juices, food residue, and bacteria may increase the risk of biliary tract infection and stone recurrence[31,32].

To summarize the characteristics of EST and EPBD (Table 1), EST is superior in terms of PEP reduction and bile duct large stone retrieval, while EPBD is superior in terms of bleeding reduction, long-term cholecystitis, and bile duct stone recurrence. Based on these findings, we consider EPBD in cases of small bile duct stones, bleeding tendency, young age, and even in surgically altered anatomy in which EST is difficult.

ESBD: Ding *et al*[4] defined a tunnel from the distal bile duct to the papillary orifice as an extraction tunnel (SET). Based on the anatomical structure, the tunnel was divided into two segments, with the distal bile duct and the intradural portion of the sphincter of Oddi comprising the proximal segment, including the proximal ring, and the intraduodenal portion of the distal segment of the papillae, including the distal ring around the orifice. Conventional EST cuts the distal segment almost completely from the orifice to near the duodenal wall, EPBD extends the entire SET, and EST + EPBD (ESBD) shortens the SET by cutting the distal ring and extends the proximal ring. Therefore, this combination technique is suitable for accessing the wide opening of the SET from an anatomical perspective[4]. In this study, ESBD was reported to reduce the number of treatments for complete stone removal, procedure time, use of mechanical lithotripters, and bleeding rate, and the incidence of PEP was reported to be comparable to that of EST. It has been reported that a small incision did not increase the risk of bleeding compared with non-EST, which might be attributed to a lower chance of injury to the major vessel in the papillary roof[20]. ESBD limits EST to small incisions, which may be the reason for reduced bleeding after ERCP. In a network meta-analysis, ESBD tended to be superior to EST in terms of successful stone removal in the first endoscopic session, the need for mechanical lithotripsy, and the risk of bleeding or perforation. However, none of these variables showed statistical significance[20]. Thus, ESBD may be superior to EST in overall efficacy and short- and long-term complications, and ESBD may be recommended over EST in the future; however, there is insufficient evidence to recommend ESBD over EST. Therefore, to justify updating the current guidelines, researchers will require more evidence that ESBD is superior to EST in terms of overall efficacy[20] and that ESBD may reduce the long-term recurrence rate of bile duct stones[33]. At this time, it is up to each endoscopist to decide whether to perform ESBD or EST.

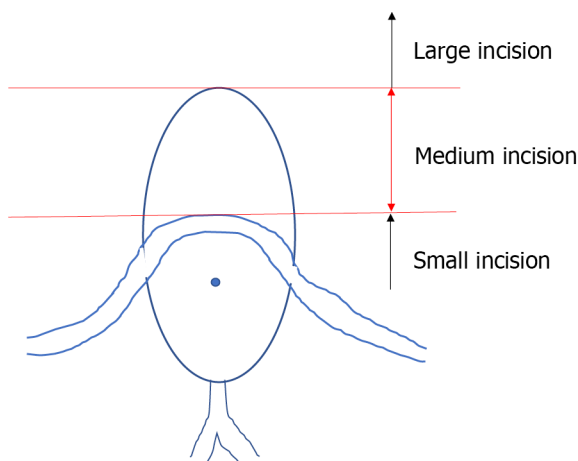
COMPARISON BETWEEN BALLOON AND BASKET CATHETER

A recent meta-analysis found that balloon catheters for cholelithiasis were superior to basket catheters for complete stone removal[9]. However, there are some limitations in the studies included in this meta-analysis. Three of the four studies included in the review were on small stones (≤ 10 -11 mm), and three of these articles used a four-wire retrieval basket catheter. Four-wire retrieval basket catheters are less suited to retrieve small stones than an eight-wire retrieval basket catheters and retrieval balloon catheters. Therefore, we cannot conclude that the basket catheter is inferior to a balloon catheter in the case of small CBD stones[5,34-36]. One meta-analysis study only included these three studies, but its conclusions were similar to those of a previous meta-analysis[10]. Ozawa *et al*[5] reported that small stones (maximum diameter, 6 mm) are an independent risk factor for failed stone removal; in their study, the basket failed to grasp a small stone in eight cases, and in four of which, the stones were successfully removed after an exchange with a balloon catheter. Therefore, they suggested that a retrieval balloon catheter may be more appropriate than a basket catheter for removing small stones[5]. However, Ozawa *et al*[5] also used a four-wire basket.

Table 1 Short- and long-term complications of endoscopic papillary balloon dilatation/endoscopic sphincterotomy

	Short-term complications			Long-term complications	
	Bleeding	PEP	Perforation	Cholecystitis	Recurrence of stones in CBD
Incidence					
EST	3%	3%	Rare	EST > EPBD	EST > EPBD
EPBD	Less than 0.1%	10%	Very rare		
Prophylactic methods	Cessation of anticoagulant and antiplatelet agents referred to each country's guidelines; EST with cutting at approximately 11 o'clock direction	Diclofenac; Pancreatic stenting in selected patients at high risk for PEP; 2-3 min EPBD in patients with EPBD	There is no evidence comparing incision size, the incidence of procedural adverse events, and therapeutic outcomes following EST	We consider EPBD in cases of small bile duct stones, bleeding tendency, young age, and even in surgically altered anatomy in which EST is difficult	We consider EPBD in cases of small bile duct stones, bleeding tendency, young age, and even in surgically altered anatomy in which EST is difficult

CBD: Common bile duct; EST: Endoscopic sphincterotomy; EPBD: Endoscopic papillary balloon dilatation; PEP: Post endoscopic retrograde cholangiopancreatography pancreatitis.



DOI: 10.3748/wjg.v29.i13.1955 Copyright ©The Author(s) 2023.

Figure 1 The oral protrusion. Endoscopic sphincterotomy incision size. The risk of perforation increases when the incision exceeds the superior margin of oral protrusion.

Once a stone is captured in a basket, reliable extraction is usually ensured. More reliable traction associated with the basket catheter is cited as the main reason for its preferential use in Japan and Europe[5,9]. In the study by Ozawa *et al*[5], the balloon slipped past the stones and could not provide a sufficient traction force for stone extraction within 10 min in four patients in the balloon group, and the stones were successfully captured and withdrawn after exchange to the basket in all cases. However, a basket with a captured stone may occasionally become impacted at the papilla during extraction if the sphincterotomy is insufficient or if the stone is larger than estimated. According to the ESGE guidelines, the difference between balloon and basket catheters is slightly minimal, so endoscopists can use any of the two; meanwhile, according to the ASGE guidelines, the balloon catheter is highly recommended for safety issues related to basket impaction[18,37].

REMOVAL OF DIFFICULT SMALL BILE DUCT STONES

There are two main operations when retrieving CBD stones with a retrieval balloon or basket. First, the catheter was pulled with the right hand. The other is to apply right rotation and push on the endoscope and use the down angle with dial control, if necessary. The difference between the two is the direction of the force on the retrieval balloon or the basket. In the former, the retrieval balloon or basket faces the forceps hole at the endoscope tip, whereas, in the latter, they face the tip of the endoscope that is pushed in (Figure 2). The important basic rule is that the direction of the force applied to the catheter should coincide with the long axis of the bile duct, and one can choose the easier of the two methods to accomplish this.

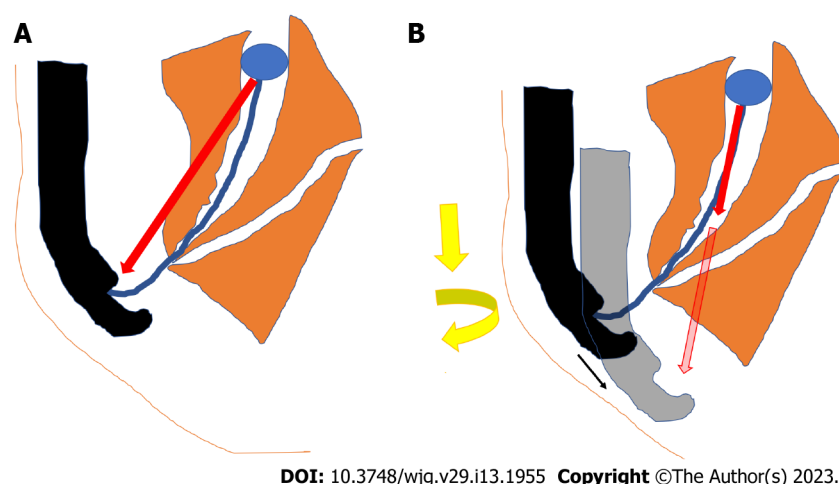


Figure 2 Basket/balloon catheter operations. A: Direction of force on the retrieval balloon or basket when pulling the catheter with the right hand; B: Direction of the force on the retrieval balloon or basket when applying right rotation and pushing the endoscope.

However, in cases with pockets in the lower part of the bile duct, stone extraction is difficult. Once a stone is impacted at the corner pocket, the balloon passes alongside the stone without removing it, and stone removal is often difficult, even after repeated attempts. Such cases can be handled by pushing the stone up to the middle of the bile duct and then grabbing it with a basket or by using a basket shaped to extract the stone out of the pocket, such as a disposable NT retrieval basket (VorticCatch V: Olympus Medical Systems, Japan) (Figure 3).

Furthermore, stones near the bifurcation of the gallbladder duct are difficult to grasp using a retrieval balloon or basket (Figure 4). Surgery is considered in these cases; however, they can be addressed with cholangioscopy, such as when in conjunction with electronic hydraulic lithotripsy (EHL)[15]. When it is difficult to grasp a CBD stone, a basket that directly grasps the stone under cholangioscopy is available [38].

Enteroscopy-assisted ERCP (eERCP) is often difficult in cases of surgically altered anatomy (SAA). In cases of SAA, endoscopic ultrasound-guided transmural drainage (EUS-TD) or percutaneous transhepatic biliary drainage (PTBD) may be effective alternatives (Figure 5)[39].

In a multicenter retrospective cohort study involving 98 patients (49 EUS-TD and 49 eERCP groups), technical success was achieved in 98% of patients in the EUS-TD group compared to 65.3% of patients in the eERCP group (OR 12.48, $P = 0.001$). EUS-TD had a significantly shorter procedural time (55 *vs* 95 min, $P < 0.001$). However, more complications of mild/moderate severity occurred in the EUS-TD group (20% *vs* 4%, $P = 0.01$). The length of stay was significantly longer in the EUS-TD group (6.6 *vs* 2.4 d, $P < 0.001$)[40]. PTBD is also a useful alternative, with a reported success rate of approximately 97%, but this method of stone removal may cause problems, such as drainage tube trouble or an increased number of sessions[41].

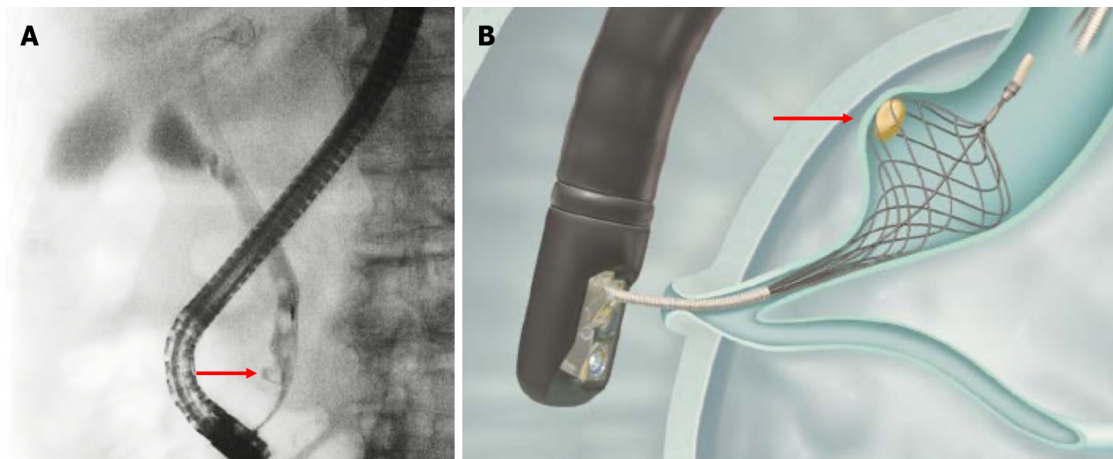
TROUBLESHOOTING DURING STONE REMOVAL

A serious drawback of basket catheters is that during stone extraction, the basket with the captured stone is impacted in the lower bile duct or papilla. When basket impaction occurs, the basket must first be opened and pushed upwards into the hepatic hilum. An attempt was made to curl the basket wires back and disengage the stone (Figure 6). If this technique fails, more complicated techniques, such as mechanical lithotripsy and intra-extracorporeal lithotripsy, are required[5]. To use a lithotripter, such as BML-110A-1 (Olympus Medical Systems, Tokyo) (Figure 7), which can be retrofitted to a basket catheter, the basket catheter is cut outside the body, the endoscope is removed from the body, and the wires of the basket catheter from the mouth are wrapped around the lithotripter. However, if the basket cannot be unmated even with a lithotripter, a cholangioscope can be helpful. The basket and grasped stone were visualized under the cholangioscope and crushed by an EHL or YAG laser (Figure 8).

SPECIFIC SITUATION

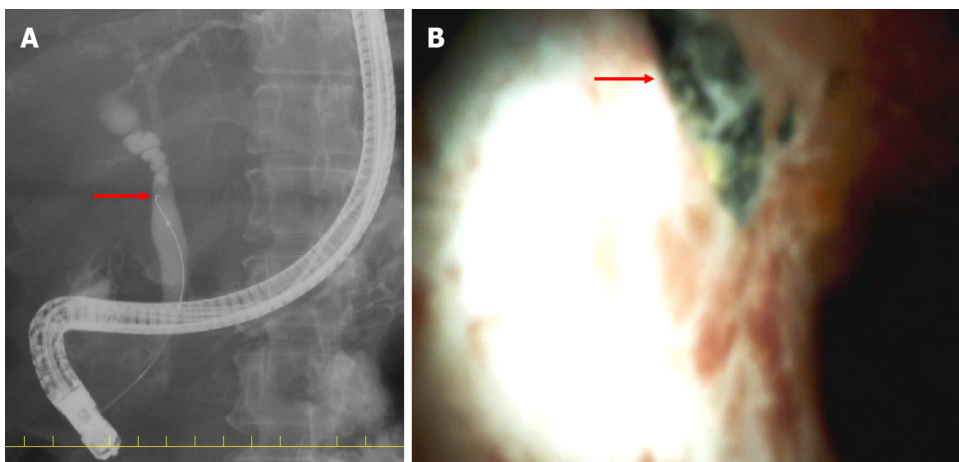
CBD stones complicated with cholangitis

The Tokyo Guidelines 2018 (TG18) and ASGE suggest that bile duct stone removal following EST in a single session may be considered in patients with mild or moderate acute cholangitis[42,43]. However,



DOI: 10.3748/wjg.v29.i13.1955 Copyright ©The Author(s) 2023.

Figure 3 Stone in the lower common bile duct pocket. Red arrows indicate a stone in the lower common bile duct pocket. A: A case with stone in the lower common bile duct pocket; B: Disposable NT retrieval basket (VorticCatch V: Olympus Medical Systems, Japan).



DOI: 10.3748/wjg.v29.i13.1955 Copyright ©The Author(s) 2023.

Figure 4 Stone stuck in the bifurcation of the gallbladder duct. Red arrows indicate a stone stuck in the bifurcation of the gallbladder duct. A: The stone got stuck in the bifurcation of the gallbladder duct, as seen by endoscopic retrograde cholangiopancreatography. The guidewire could not be inserted into the gallbladder duct because of the obstruction by a stone; B: A stone stuck in the bifurcation of the gallbladder duct as observed by cholangioscopy.

given that hemodynamically unstable or coagulopathy patients might not tolerate procedural bleeding or adverse events, decompression alone should be considered in this group[42,43]. PEP does not increase even in cases of complicated cholangitis[43]. TG18 suggested that endoscopic nasobiliary drainage (ENBD) or endoscopic biliary stenting (EBS) may be considered for biliary drainage according to the patient's background and preference. It should be borne in mind that if patients experience discomfort from transnasal tube placement, they are likely to remove the tube themselves, particularly in elderly patients. EBS is an internal drainage technique that does not cause discomfort or loss of electrolytes or fluids. In contrast, ENBD is an external drainage technique that allows monitoring or washing of bile *via* the transnasal tube, particularly if the bile is purulent[42]. The ESGE did not provide any recommendations for these[15]. We present a table summarizing each guideline, focusing on key points (Table 2).

CBD stones complicated with cholecystolithiasis

In the general population, CBD stones complicated with cholecystolithiasis commonly occurs. The established gold standard for the treatment of symptomatic cholecystolithiasis is laparoscopic cholecystectomy (LC), but the treatment option for CBD stones is yet to be clarified. CBD stones complicated with cholecystolithiasis can be treated with two-session minimally invasive and one-session feasible strategies. The former requires pre- or post-LC ERCP, whereas the latter requires LC plus intraoperative laparoscopic CBD exploration (LCBDE) or LC with intraoperative ERCP[44]. As per efficacy, morbidity, or mortality endoscopic and surgical techniques for extracting these stones are equally suitable[45]. However, one-session procedures usually result in a shorter hospital stay[15].

Table 2 Key points of each guideline

	JGES/TG18	ESGE	ASGE
Papillary dilatation	EST is standard EPBD is determined by age, scheduled RFA, antithrombotic medications, parapancreatic diverticulum, reconstructed bowel, and stone diameter and number	EST is standard In anticoagulant users and in cases of SAA, EPBD is an option for stones smaller than 8 mm	EST is standard In anticoagulant users, in cases of SAA, and in cases of intradiverticular papilla, EPBD is an option
Cases of antithrombotic agents use (EST, high bleeding risk procedures)	ASA or CLZ alone may be continued Thienopyridines discontinued for 5-7 d or replaced with ASA or CLZ Warfarin may be continued if in therapeutic range; DOAC is withdrawn on the EST day only Resumed the next day	ASA or CLZ alone may be continued Thienopyridines discontinued for 5-7 d or replaced with ASA or CLZ Warfarin stopped 5 d ago and LMWH was started 2 d ago (LMWH also stopped 24 h ago). DOAC stopped 48 h ago Warfarin or DOAC resume within 48 h. Warfarin is used with LMWH until the optimal concentration is reached	ASA or CLZ alone may be continued Thienopyridines discontinued for 5-7 d or replaced with ASA or CLZ Warfarin users can be treated urgently if INR < 2.5. DOACs should be discontinued prior to treatment, with a discontinuation period of twice the half-life. Heparin replacement is recommended in patients at high risk of thrombosis Resume at the end of the procedure if hemostasis is confirmed. However, evidence for DOACs and APAs are scant
Stone retrieval	No superiority of balloons and baskets is noted	Efficacy of balloons and baskets is almost equal	Recommend using balloons rather than baskets
Complicated cases of cholangitis	Patients who are hemodynamically unstable, coagulopathic, or receiving antithrombotic agents; it was believed that decompression alone should be considered. EBS and ENBD are almost equal	Not stated	Given that hemodynamically unstable patients might not tolerate procedural bleeding or adverse events, it was believed that decompression alone should be considered in this group as well as for patients who are coagulopathic and/or are receiving antithrombotic agents and those who would need to have anticoagulation resumed immediately after sphincterotomy (<i>e.g.</i> , patients with mechanical heart valves)

APA: Antiplatelet agent; ASA: Acetylsalicylic acid; ASGE: American Society for Gastrointestinal Endoscopy; CLZ: Cilostazol; DOAC: Direct oral anticoagulant; EBS: Endoscopic biliary stent; ENBD: Endoscopic nasobiliary drainage; EPBD: Endoscopic papillary balloon dilation; ESGE: European Society of Gastrointestinal Endoscopy; EST: Endoscopic sphincterotomy; JGES: Japan Gastroenterological Endoscopy Society; LMWH: Low-molecular-weight heparin; SAA: Surgically altered anatomy; TG18: Tokyo guideline 2018.

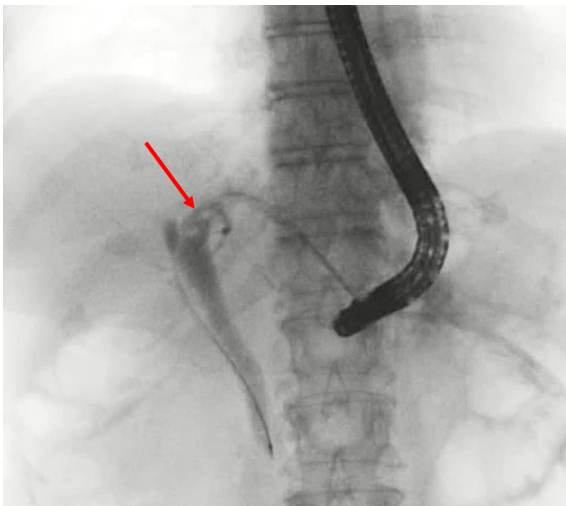
Moreover, a recent meta-analysis has demonstrated that the one-session procedure has a higher success rate than the two-session procedure[46].

For one-session procedures, many surgeons prefer the less invasive and less complicated transcystectomy approach, however, bile duct incision is recommended for dilated CBD, large diameter and multiple stones, impacted stones, and stones with intrahepatic localization[47,48]. It is recommended to start with transcystectomy and move onto exploration by bile duct incision if difficult[44,49]. Laparoscopic stone removal can be performed fluoroscopically or cholangioscopically. The use of a flexible cholangioscope is the most preferred method because of its accuracy and direct visual control. However, one-session procedure requires advanced laparoscopic techniques, a long learning curve, and specialized equipment, and these qualities may not exist in all treatment facilities[50-52]. ESGE recommends that transcystic or transductal exploration of the CBD is a safe and effective technique for removal of CBD stones in patients undergoing laparoscopic cholecystectomy, provided that local expertise and resources are adequate[15]. It is of note that results of surgical treatment of CBD stones, which are generally excellent in published reports, are usually from laparoscopic centers of excellence, however, there are hardly reports by less experienced surgeons. Therefore, the ESGE does not clearly state whether one-session or two-session procedure should be preferred.

There are no recent reports on laparoscopic surgery for small CBD stones, however, Huang *et al*[53], in their report on laparoscopic surgery for small CBD with CBD stones, indicated that it is safe and feasible for small CBD patients to perform LCBDE.

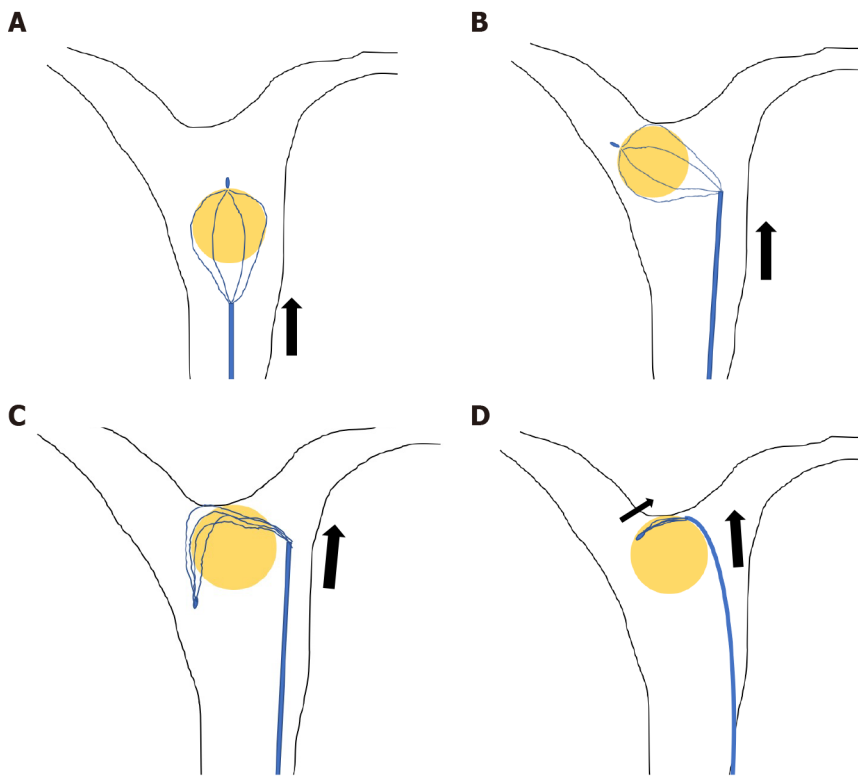
CBS stones complicated with distal biliary stricture

Few reports have been published on CBD stones extraction with distal biliary stricture[54,55], however, plastic stent(s)[56,57], covered self-expandable metallic stent(s) (cSEMS)[56-58], balloon dilation[59], and surgery[60] have been used for dilating bile duct stenosis. However, balloon dilation carries the risk of



DOI: 10.3748/wjg.v29.i13.1955 Copyright ©The Author(s) 2023.

Figure 5 Case of total gastrectomy with RY reconstruction. Enteroscopy-assisted endoscopic retrograde cholangiopancreatography was unsuccessful; therefore, an endoscopic ultrasound-guided hepaticogastrostomy was performed. The red arrow indicates bile duct stones.



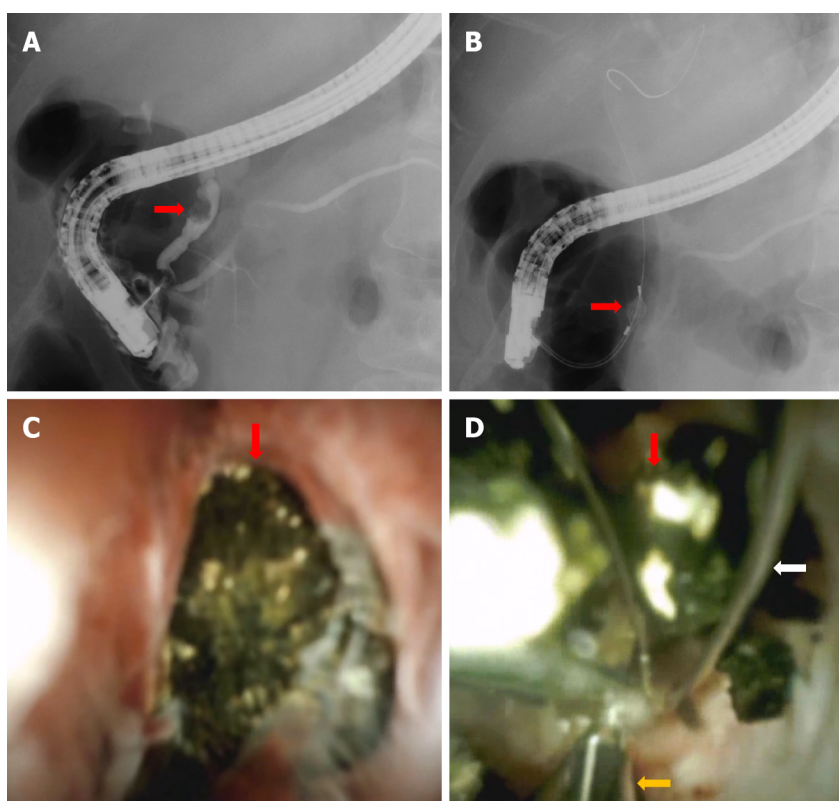
DOI: 10.3748/wjg.v29.i13.1955 Copyright ©The Author(s) 2023.

Figure 6 Release of grasped stones. A: Push the basket catheter up into the hepatic hilum; B: Push further to invert the grasped stone; C: Push and deflect the basket wire; D: Close the basket while pushing the catheter.

bile duct injury. Therefore, when endoscopic stone extraction is performed for CBD stones with benign biliary stricture, it may be advisable to use multiple plastic stents or cSEMS for several months and perform endoscopic stone extraction after bile duct dilation is achieved[61]. Combining them with mechanical lithotripsy may also be useful[54]. Ogura *et al*[55] reported that transluminal stone extraction passing through the EUS-TD route, without passing through the distal bile duct might be useful. Reports of CBD stones with malignant biliary stricture are even more scarce, however, the safety of 6-8 mm balloon dilation for malignant biliary stricture has been reported[62]. In malignant biliary stricture with limited prognosis, stenting alone may be sufficient and stone extraction may not be necessary, however, balloon dilation for stone extraction may be considered in cases of short-term stent obstruction.



Figure 7 BML-110A-1 (Olympus Medical Systems, Tokyo). The authors have obtained the permission for figure using from the Olympus (Supplementary material).



DOI: 10.3748/wjg.v29.i13.1955 Copyright ©The Author(s) 2023.

Figure 8 The case in which the basket could not be unmated even with the lithotripter. The basket and grasped stone were visualized under cholangioscopy and crushed using electronic hydraulic lithotripsy (EHL). The red arrows indicate common bile duct (CBD) stones, white arrow basket catheter, and orange arrow EHL probe. A: CBD stone; B: CBD stone grasped by basket; C: CBD stone grasped by basket as seen by cholangioscopy; D: CBD stone crushed with EHL.

CONCLUSION

While EST is the standard treatment for papillary dilatation, EPBD is also a viable option for younger patients who wish to reduce the risk of long-term recurrence and patients with coagulopathy. EPBD is considered to have a lower risk of bleeding and perforation than EST. Several methods have been recently proposed to reduce PEP, the greatest weakness of EPBD. We would also like to focus on ESD, which should be the subject of future research.

For small stones in the CBD, it is not necessary to strictly distinguish between the retrieval balloon and the basket; however, if one device cannot remove the stone, it is recommended to use the other. In cases of pockets in the lower bile duct, Voltic catch V is also useful. It is also important to gain experience in the use of EUS-TD, lithotripter, and cholangioscopy to deal with troubleshooting such as stones stuck in the basket and difficult cases of stone retrieval.

In cases of complicated cholangitis, stone retrieval can be performed in mild or moderate cases in a single session. In severe cases, decompression alone should be considered, and EBS is generally

recommended. Cases of CBD stones complicated with cholecystolithiasis that are scheduled for one-session surgical treatment or CBD stones complicated with distal biliary stricture should be treated in facilities with adequate experience and equipment.

FOOTNOTES

Author contributions: Masuda S and Koizumi K were major contributors to writing the manuscript; Shionoya K, Jinushi R, Makazu M, Nishino T, and Kimura K designed the outline and coordinated the writing of the manuscript; Sumida C, Kubota J, Ichita C, Sasaki A, Kobayashi M, Kako M, and Haruki U provided input for writing the paper.

Conflict-of-interest statement: The authors declare that there are no conflicts of interests.

Open-Access: This article is an open-access article that was selected by an in-house editor and fully peer-reviewed by external reviewers. It is distributed in accordance with the Creative Commons Attribution NonCommercial (CC BY-NC 4.0) license, which permits others to distribute, remix, adapt, build upon this work non-commercially, and license their derivative works on different terms, provided the original work is properly cited and the use is non-commercial. See: <https://creativecommons.org/licenses/by-nc/4.0/>

Country/Territory of origin: Japan

ORCID number: Sakue Masuda 0000-0002-8127-0154; Kazuya Koizumi 0000-0002-3677-5030; Kento Shionoya 0000-0002-8399-4797; Takashi Nishino 0000-0002-6717-1096; Karen Kimura 0000-0001-8165-1777; Chihiro Sumida 0000-0002-4616-6407; Chikamasa Ichita 0000-0001-9210-7371; Akiko Sasaki 0000-0003-4219-554X; Makoto Kako 0000-0002-6447-8471; Uojima Haruki 0000-0003-1719-1352.

Corresponding Author's Membership in Professional Societies: Japan Gastroenterological Endoscopy Society; The Japanese Society of Gastroenterology; Japan Biliary Association; The Japan society of hepatology; Japan Pancreas Society; The Japanese Society of Internal Medicine; Japanese society of interventional radiology.

S-Editor: Yan JP

L-Editor: A

P-Editor: Yan JP

REFERENCES

1. **Melzer M**, Toner R, Lacey S, Bettany E, Rait G. Biliary tract infection and bacteraemia: presentation, structural abnormalities, causative organisms and clinical outcomes. *Postgrad Med J* 2007; **83**: 773-776 [PMID: 18057178 DOI: 10.1136/pgmj.2007.064683]
2. **Kimura Y**, Takada T, Strasberg SM, Pitt HA, Gouma DJ, Garden OJ, Büchler MW, Windsor JA, Mayumi T, Yoshida M, Miura F, Higuchi R, Gabata T, Hata J, Gomi H, Dervenis C, Lau WY, Belli G, Kim MH, Hilvano SC, Yamashita Y. TG13 current terminology, etiology, and epidemiology of acute cholangitis and cholecystitis. *J Hepatobiliary Pancreat Sci* 2013; **20**: 8-23 [PMID: 23307004 DOI: 10.1007/s00534-012-0564-0]
3. **Ando T**, Tsuyuguchi T, Okugawa T, Saito M, Ishihara T, Yamaguchi T, Saisho H. Risk factors for recurrent bile duct stones after endoscopic papillotomy. *Gut* 2003; **52**: 116-121 [PMID: 12477771 DOI: 10.1136/gut.52.1.116]
4. **Ding J**, Li F, Zhu HY, Zhang XW. Endoscopic treatment of difficult extrahepatic bile duct stones, EPBD or EST: An anatomic view. *World J Gastrointest Endosc* 2015; **7**: 274-277 [PMID: 25789099 DOI: 10.4253/wjge.v7.i3.274]
5. **Ozawa N**, Yasuda I, Doi S, Iwashita T, Shimizu M, Mukai T, Nakashima M, Ban T, Kojima I, Matsuda K, Matsuda M, Ishida Y, Okabe Y, Ando N, Iwata K. Prospective randomized study of endoscopic biliary stone extraction using either a basket or a balloon catheter: the BasketBall study. *J Gastroenterol* 2017; **52**: 623-630 [PMID: 27631594 DOI: 10.1007/s00535-016-1257-2]
6. **Yu ZY**, Liang C, Yang SY, Zhang X, Sun Y. The therapeutic effect of balloon dilatation with different duration for biliary duct calculi: A network meta-analysis. *J Minim Access Surg* 2022; **18**: 327-337 [PMID: 35708376 DOI: 10.4103/jmas.JMAS_304_20]
7. **Masuda S**, Koizumi K, Nishino T, Tazawa T, Kimura K, Tasaki J, Ichita C, Sasaki A, Kako M, Uojima H, Sugitani A. Direct oral anticoagulants increase bleeding risk after endoscopic sphincterotomy: a retrospective study. *BMC Gastroenterol* 2021; **21**: 401 [PMID: 34689751 DOI: 10.1186/s12876-021-01980-6]
8. **Bhurwal A**, Mutneja H, Goel A, Bansal V, Patel A, Brahmabhatt B, Sarkar A. No Significant Difference in Post-ERCP Bleeding Rates Between Dual Antiplatelet Agents and Aspirin Alone: A Systematic Review and Meta-analysis. *J Clin Gastroenterol* 2022; **56**: 546-551 [PMID: 34028396 DOI: 10.1097/MCG.0000000000001559]
9. **Elsnhory AB**, Mandour OA, Montaser AG, Kereet IM, Rezk HS, Madhoun HW, Rabea RK, Ragab KM, Gbreel MI. A Systematic Review and Meta-analysis of Basket or Balloon Catheter for the Retrieval of Choledocholithiasis. *Indian J Surg* 2022 [DOI: 10.1007/s12262-022-03435-y]
10. **Sharma R**, Sharma V, Singhal U, Sanaka M. Outcomes of balloon vs basket catheter for clearance of choledocholithiasis: a systematic review and meta-analysis. *Endosc Int Open* 2022; **10**: E1447-E1453 [PMID: 36397864 DOI: 10.1055/a-1905-0251]

- 11 **Hamada T**, Yasunaga H, Nakai Y, Isayama H, Matsui H, Horiguchi H, Fushimi K, Koike K. Bleeding after endoscopic sphincterotomy or papillary balloon dilatation among users of antithrombotic agents. *Endoscopy* 2015; **47**: 997-1004 [PMID: 26126160 DOI: 10.1055/s-0034-1392408]
- 12 **Zhao HC**, He L, Zhou DC, Geng XP, Pan FM. Meta-analysis comparison of endoscopic papillary balloon dilatation and endoscopic sphincterotomy. *World J Gastroenterol* 2013; **19**: 3883-3891 [PMID: 23840129 DOI: 10.3748/wjg.v19.i24.3883]
- 13 **Liu Y**, Su P, Lin S, Xiao K, Chen P, An S, Zhi F, Bai Y. Endoscopic papillary balloon dilatation versus endoscopic sphincterotomy in the treatment for choledocholithiasis: a meta-analysis. *J Gastroenterol Hepatol* 2012; **27**: 464-471 [PMID: 21913984 DOI: 10.1111/j.1440-1746.2011.06912.x]
- 14 **Yasuda I**, Tomita E. Extracorporeal shockwave lithotripsy of common bile duct stones without preliminary endoscopic sphincterotomy. *Scand J Gastroenterol* 1996; **31**: 934-939 [PMID: 8888444 DOI: 10.3109/00365529609052005]
- 15 **Manes G**, Paspatis G, Aabakken L, Anderloni A, Arvanitakis M, Ah-Soune P, Barthet M, Domagk D, Dumonceau JM, Gigot JF, Hritz I, Karamanolis G, Laghi A, Mariani A, Paraskeva K, Pohl J, Ponchon T, Swahn F, Ter Steege RWF, Tringali A, Vezakis A, Williams EJ, van Hooft JE. Endoscopic management of common bile duct stones: European Society of Gastrointestinal Endoscopy (ESGE) guideline. *Endoscopy* 2019; **51**: 472-491 [PMID: 30943551 DOI: 10.1055/a-0862-0346]
- 16 **Ryozawa S**, Itoi T, Katanuma A, Okabe Y, Kato H, Horaguchi J, Fujita N, Yasuda K, Tsuyuguchi T, Fujimoto K. Japan Gastroenterological Endoscopy Society guidelines for endoscopic sphincterotomy. *Dig Endosc* 2018; **30**: 149-173 [PMID: 29247546 DOI: 10.1111/den.13001]
- 17 **Weinberg BM**, Shindy W, Lo S. Endoscopic balloon sphincter dilation (sphincteroplasty) versus sphincterotomy for common bile duct stones. *Cochrane Database Syst Rev* 2006; **2006**: CD004890 [PMID: 17054222 DOI: 10.1002/14651858.CD004890.pub2]
- 18 **Dumonceau JM**, Kapral C, Aabakken L, Papanikolaou IS, Tringali A, Vanbiervliet G, Beyna T, Dinis-Ribeiro M, Hritz I, Mariani A, Paspatis G, Radaelli F, Lakhtakia S, Veitch AM, van Hooft JE. ERCP-related adverse events: European Society of Gastrointestinal Endoscopy (ESGE) Guideline. *Endoscopy* 2020; **52**: 127-149 [PMID: 31863440 DOI: 10.1055/a-1075-4080]
- 19 **Disario JA**, Freeman ML, Bjorkman DJ, Macmathuna P, Petersen BT, Jaffe PE, Morales TG, Hixson LJ, Sherman S, Lehman GA, Jamal MM, Al-Kawas FH, Khandelwal M, Moore JP, Derfus GA, Jamidar PA, Ramirez FC, Ryan ME, Woods KL, Carr-Locke DL, Alder SC. Endoscopic balloon dilation compared with sphincterotomy for extraction of bile duct stones. *Gastroenterology* 2004; **127**: 1291-1299 [PMID: 15520997 DOI: 10.1053/j.gastro.2004.07.017]
- 20 **Park CH**, Jung JH, Nam E, Kim EH, Kim MG, Kim JH, Park SW. Comparative efficacy of various endoscopic techniques for the treatment of common bile duct stones: a network meta-analysis. *Gastrointest Endosc* 2018; **87**: 43-57.e10 [PMID: 28756105 DOI: 10.1016/j.gie.2017.07.038]
- 21 **Bergman JJ**, Rauws EA, Fockens P, van Berkel AM, Bossuyt PM, Tijssen JG, Tytgat GN, Huibregtse K. Randomised trial of endoscopic balloon dilation versus endoscopic sphincterotomy for removal of bileduct stones. *Lancet* 1997; **349**: 1124-1129 [PMID: 9113010 DOI: 10.1016/S0140-6736(96)11026-6]
- 22 **Meng W**, Leung JW, Zhang K, Zhou W, Wang Z, Zhang L, Sun H, Xue P, Liu W, Wang Q, Zhang J, Wang X, Wang M, Shao Y, Cai K, Hou S, Li Q, Zhu K, Yue P, Wang H, Zhang M, Sun X, Yang Z, Tao J, Wen Z, Chen B, Shao Q, Zhao M, Zhang R, Jiang T, Liu K, Chen K, Zhu X, Zhang H, Miao L, Li J, Yan X, Wang F, Suzuki A, Tanaka K, Nur U, Weiderpass E, Li X. Optimal dilation time for combined small endoscopic sphincterotomy and balloon dilation for common bile duct stones: a multicentre, single-blinded, randomised controlled trial. *Lancet Gastroenterol Hepatol* 2019; **4**: 425-434 [PMID: 31003961 DOI: 10.1016/S2468-1253(19)30075-5]
- 23 **Tomoda T**, Kato H, Ueki T, Akimoto Y, Hata H, Fujii M, Harada R, Ogawa T, Wato M, Takatani M, Matsubara M, Kawai Y, Okada H. Combination of Diclofenac and Sublingual Nitrates Is Superior to Diclofenac Alone in Preventing Pancreatitis After Endoscopic Retrograde Cholangiopancreatography. *Gastroenterology* 2019; **156**: 1753-1760.e1 [PMID: 30772342 DOI: 10.1053/j.gastro.2019.01.267]
- 24 **Luo H**, Zhao L, Leung J, Zhang R, Liu Z, Wang X, Wang B, Nie Z, Lei T, Li X, Zhou W, Zhang L, Wang Q, Li M, Zhou Y, Liu Q, Sun H, Wang Z, Liang S, Guo X, Tao Q, Wu K, Pan Y, Fan D. Routine pre-procedural rectal indometacin versus selective post-procedural rectal indometacin to prevent pancreatitis in patients undergoing endoscopic retrograde cholangiopancreatography: a multicentre, single-blinded, randomised controlled trial. *Lancet* 2016; **387**: 2293-2301 [PMID: 27133971 DOI: 10.1016/S0140-6736(16)30310-5]
- 25 **ASGE Standards of Practice Committee**, Acosta RD, Abraham NS, Chandrasekhara V, Chathadi KV, Early DS, Eloubeidi MA, Evans JA, Faulx AL, Fisher DA, Fonkalsrud L, Hwang JH, Khashab MA, Lightdale JR, Muthusamy VR, Pasha SF, Saltzman JR, Shaikat A, Shergill AK, Wang A, Cash BD, DeWitt JM. The management of antithrombotic agents for patients undergoing GI endoscopy. *Gastrointest Endosc* 2016; **83**: 3-16 [PMID: 26621548 DOI: 10.1016/j.gie.2015.09.035]
- 26 **Fujimoto K**, Fujishiro M, Kato M, Higuchi K, Iwakiri R, Sakamoto C, Uchiyama S, Kashiwagi A, Ogawa H, Murakami K, Mine T, Yoshino J, Kinoshita Y, Ichinose M, Matsui T; Japan Gastroenterological Endoscopy Society. Guidelines for gastroenterological endoscopy in patients undergoing antithrombotic treatment. *Dig Endosc* 2014; **26**: 1-14 [PMID: 24215155 DOI: 10.1111/den.12183]
- 27 **Veitch AM**, Vanbiervliet G, Gershlick AH, Boustiere C, Baglin TP, Smith LA, Radaelli F, Knight E, Gralnek IM, Hassan C, Dumonceau JM. Endoscopy in patients on antiplatelet or anticoagulant therapy, including direct oral anticoagulants: British Society of Gastroenterology (BSG) and European Society of Gastrointestinal Endoscopy (ESGE) guidelines. *Gut* 2016; **65**: 374-389 [PMID: 26873868 DOI: 10.1136/gutjnl-2015-311110]
- 28 **Mirjalili SA**, Stringer MD. The arterial supply of the major duodenal papilla and its relevance to endoscopic sphincterotomy. *Endoscopy* 2011; **43**: 307-311 [PMID: 21455871 DOI: 10.1055/s-0030-1256229]
- 29 **Masuda S**, Koizumi K, Uojima H, Kimura K, Nishino T, Tasaki J, Ichita C, Sasaki A. Effect of Antibiotic Resistance of Pathogens on Initial Antibiotic Therapy for Patients With Cholangitis. *Cureus* 2021; **13**: e18449 [PMID: 34650837 DOI: 10.7759/cureus.18449]

- 30 **Goong HJ**, Moon JH, Lee YN, Choi HJ, Choi SY, Choi MH, Kim MJ, Lee TH, Park SH, Lee HK. The Role of Endoscopic Biliary Drainage without Sphincterotomy in Gallstone Patients with Cholangitis and Suspected Common Bile Duct Stones Not Detected by Cholangiogram or Intraductal Ultrasonography. *Gut Liver* 2017; **11**: 434-439 [PMID: 28104896 DOI: 10.5009/gnl16234]
- 31 **Yasuda I**, Fujita N, Maguchi H, Hasebe O, Igarashi Y, Murakami A, Mukai H, Fujii T, Yamao K, Maeshiro K, Tada T, Tsujino T, Komatsu Y. Long-term outcomes after endoscopic sphincterotomy versus endoscopic papillary balloon dilation for bile duct stones. *Gastrointest Endosc* 2010; **72**: 1185-1191 [PMID: 20869711 DOI: 10.1016/j.gie.2010.07.006]
- 32 **Cai JS**, Qiang S, Bao-Bing Y. Advances of recurrent risk factors and management of choledocholithiasis. *Scand J Gastroenterol* 2017; **52**: 34-43 [PMID: 27610642 DOI: 10.1080/00365521.2016.1224382]
- 33 **Ji X**, Yang Z, Ma SR, Jia W, Zhao Q, Xu L, Kan Y, Cao Y, Wang Y, Fan BJ. New common bile duct morphological subtypes: Risk predictors of common bile duct stone recurrence. *World J Gastrointest Surg* 2022; **14**: 236-246 [PMID: 35432763 DOI: 10.4240/wjgs.v14.i3.236]
- 34 **Takeshita K**, Asai S, Fujimoto N, Ichinona T, Akamine E. Comparison of the effects of retrieval balloons and basket catheters for bile duct stone removal on the rate of post-ERCP pancreatitis. *Hepatobiliary Pancreat Dis Int* 2021; **20**: 203-204 [PMID: 32430257 DOI: 10.1016/j.hbpd.2020.04.004]
- 35 **Ishiwatari H**, Kawakami H, Hisai H, Yane K, Onodera M, Eto K, Haba S, Okuda T, Ihara H, Kukitsu T, Matsumoto R, Kitaoka K, Sonoda T, Hayashi T; Hokkaido Interventional EUS/ERCP Study (HONEST) Group. Balloon catheter versus basket catheter for endoscopic bile duct stone extraction: a multicenter randomized trial. *Endoscopy* 2016; **48**: 350-357 [PMID: 26760604 DOI: 10.1055/s-0035-1569573]
- 36 **Ekmektzoglu K**, Apostolopoulos P, Dimopoulos K, Tsibouris P, Kalantzis C, Vlachou E, Kalafatis E, Alexandrakis G. Basket versus balloon extraction for choledocholithiasis: a single center prospective single-blind randomized study. *Acta Gastroenterol Belg* 2020; **83**: 577-584 [PMID: 33321014]
- 37 **ASGE Standards of Practice Committee**, Maple JT, Ikenberry SO, Anderson MA, Appalaneni V, Decker GA, Early D, Evans JA, Fanelli RD, Fisher D, Fisher L, Fukami N, Hwang JH, Jain R, Jue T, Khan K, Krinsky ML, Malpas P, Ben-Menachem T, Sharaf RN, Dominitz JA. The role of endoscopy in the management of choledocholithiasis. *Gastrointest Endosc* 2011; **74**: 731-744 [PMID: 21951472 DOI: 10.1016/j.gie.2011.04.012]
- 38 **Ogura T**, Okuda A, Miyano A, Nishioka N, Higuchi K. Intrahepatic bile duct stone removal through endoscopic ultrasound-guided hepaticogastrostomy using novel basket catheter under digital cholangioscopy guidance. *Endoscopy* 2018; **50**: E301-E303 [PMID: 30089326 DOI: 10.1055/a-0658-0927]
- 39 **van der Merwe SW**, van Wanrooij RLJ, Bronswijk M, Everett S, Lakhtakia S, Rimbaz M, Hucl T, Kunda R, Badaoui A, Law R, Arcidiacono PG, Larghi A, Giovannini M, Khashab MA, Binmoeller KF, Barthet M, Perez-Miranda M, van Hooft JE. Therapeutic endoscopic ultrasound: European Society of Gastrointestinal Endoscopy (ESGE) Guideline. *Endoscopy* 2022; **54**: 185-205 [PMID: 34937098 DOI: 10.1055/a-1717-1391]
- 40 **Khashab MA**, El Zein MH, Sharzei K, Marson FP, Haluszka O, Small AJ, Nakai Y, Park DH, Kunda R, Teoh AY, Peñas I, Perez-Miranda M, Kumbhari V, Van der Merwe S, Artifon EL, Ross AS. EUS-guided biliary drainage or enteroscopy-assisted ERCP in patients with surgical anatomy and biliary obstruction: an international comparative study. *Endosc Int Open* 2016; **4**: E1322-E1327 [PMID: 27995197 DOI: 10.1055/s-0042-110790]
- 41 **Iwashita T**, Uemura S, Mita N, Iwasa Y, Ichikawa H, Mukai T, Yasuda I, Shimizu M. Endoscopic ultrasound guided-antegrade biliary stenting vs percutaneous transhepatic biliary stenting for unresectable distal malignant biliary obstruction in patients with surgically altered anatomy. *J Hepatobiliary Pancreat Sci* 2020; **27**: 968-976 [PMID: 32896998 DOI: 10.1002/jhbp.823]
- 42 **Mukai S**, Itoi T, Baron TH, Takada T, Strasberg SM, Pitt HA, Ukai T, Shikata S, Teoh AYW, Kim MH, Kiriya S, Mori Y, Miura F, Chen MF, Lau WY, Wada K, Supe AN, Giménez ME, Yoshida M, Mayumi T, Hirata K, Sumiyama Y, Inui K, Yamamoto M. Indications and techniques of biliary drainage for acute cholangitis in updated Tokyo Guidelines 2018. *J Hepatobiliary Pancreat Sci* 2017; **24**: 537-549 [PMID: 28834389 DOI: 10.1002/jhbp.496]
- 43 **Buxbaum JL**, Buitrago C, Lee A, Elmunzer BJ, Riaz A, Ceppa EP, Al-Haddad M, Amateau SK, Calderwood AH, Fishman DS, Fujii-Lau LL, Jamil LH, Jue TL, Kwon RS, Law JK, Lee JK, Naveed M, Pawa S, Sawhney MS, Schilperoort H, Storm AC, Thosani NC, Qumsey B, Wani S. ASGE guideline on the management of cholangitis. *Gastrointest Endosc* 2021; **94**: 207-221.e14 [PMID: 34023065 DOI: 10.1016/j.gie.2020.12.032]
- 44 **Cianci P**, Restini E. Management of cholelithiasis with choledocholithiasis: Endoscopic and surgical approaches. *World J Gastroenterol* 2021; **27**: 4536-4554 [PMID: 34366622 DOI: 10.3748/wjg.v27.i28.4536]
- 45 **Williams EJ**, Green J, Beckingham I, Parks R, Martin D, Lombard M; British Society of Gastroenterology. Guidelines on the management of common bile duct stones (CBDS). *Gut* 2008; **57**: 1004-1021 [PMID: 18321943 DOI: 10.1136/gut.2007.121657]
- 46 **Singh AN**, Kilambi R. Single-stage laparoscopic common bile duct exploration and cholecystectomy versus two-stage endoscopic stone extraction followed by laparoscopic cholecystectomy for patients with gallbladder stones with common bile duct stones: systematic review and meta-analysis of randomized trials with trial sequential analysis. *Surg Endosc* 2018; **32**: 3763-3776 [PMID: 29603004 DOI: 10.1007/s00464-018-6170-8]
- 47 **Berthou JCh**, Dron B, Charbonneau P, Moussalier K, Pellissier L. Evaluation of laparoscopic treatment of common bile duct stones in a prospective series of 505 patients: indications and results. *Surg Endosc* 2007; **21**: 1970-1974 [PMID: 17522929 DOI: 10.1007/s00464-007-9387-5]
- 48 **Martin IJ**, Bailey IS, Rhodes M, O'Rourke N, Nathanson L, Fielding G. Towards T-tube free laparoscopic bile duct exploration: a methodologic evolution during 300 consecutive procedures. *Ann Surg* 1998; **228**: 29-34 [PMID: 9671063 DOI: 10.1097/0000658-199807000-00005]
- 49 **Decker G**, Borie F, Millat B, Berthou JC, Deleuze A, Drouard F, Guillon F, Rodier JG, Fingerhut A. One hundred laparoscopic choledochotomies with primary closure of the common bile duct. *Surg Endosc* 2003; **17**: 12-18 [PMID: 12364990 DOI: 10.1007/s00464-002-9012-6]
- 50 **Cuschieri A**, Croce E, Faggioni A, Jakimowicz J, Lacy A, Lezoche E, Morino M, Ribeiro VM, Toouli J, Visa J, Wayand W. EAES ductal stone study. Preliminary findings of multi-center prospective randomized trial comparing two-stage vs

- single-stage management. *Surg Endosc* 1996; **10**: 1130-1135 [PMID: 8939828 DOI: 10.1007/s004649900264]
- 51 **Tranter SE**, Thompson MH. Comparison of endoscopic sphincterotomy and laparoscopic exploration of the common bile duct. *Br J Surg* 2002; **89**: 1495-1504 [PMID: 12445057 DOI: 10.1046/j.1365-2168.2002.02291.x]
 - 52 **Poulose BK**, Speroff T, Holzman MD. Optimizing choledocholithiasis management: a cost-effectiveness analysis. *Arch Surg* 2007; **142**: 43-8; discussion 49 [PMID: 17224499 DOI: 10.1001/archsurg.142.1.43]
 - 53 **Huang XX**, Wu JY, Bai YN, Lv JH, Chen WZ, Huang LM, Huang RF, Yan ML. Outcomes of laparoscopic bile duct exploration for choledocholithiasis with small common bile duct. *World J Clin Cases* 2021; **9**: 1803-1813 [PMID: 33748229 DOI: 10.12998/wjcc.v9.i8.1803]
 - 54 **Tringali A**, Costa D, Fugazza A, Colombo M, Khalaf K, Repici A, Anderloni A. Endoscopic management of difficult common bile duct stones: Where are we now? *World J Gastroenterol* 2021; **27**: 7597-7611 [PMID: 34908801 DOI: 10.3748/wjg.v27.i44.7597]
 - 55 **Ogura T**, Kawai J, Nishiguchi K, Yamamoto Y, Higuchi K. Transluminal intrahepatic bile duct stone removal using a novel spiral basket catheter via the endoscopic ultrasound-guided hepaticogastrostomy route (with video). *Dig Endosc* 2022; **34**: 234-237 [PMID: 34459031 DOI: 10.1111/den.14121]
 - 56 **Siiki A**, Helminen M, Sand J, Laukkanen J. Covered self-expanding metal stents may be preferable to plastic stents in the treatment of chronic pancreatitis-related biliary strictures: a systematic review comparing 2 methods of stent therapy in benign biliary strictures. *J Clin Gastroenterol* 2014; **48**: 635-643 [PMID: 24275713 DOI: 10.1097/MCG.000000000000020]
 - 57 **Haapamäki C**, Kylänpää L, Udd M, Lindström O, Grönroos J, Saarela A, Mustonen H, Halttunen J. Randomized multicenter study of multiple plastic stents vs. covered self-expandable metallic stent in the treatment of biliary stricture in chronic pancreatitis. *Endoscopy* 2015; **47**: 605-610 [PMID: 25590182 DOI: 10.1055/s-0034-1391331]
 - 58 **Devière J**, Nageshwar Reddy D, Püspök A, Ponchon T, Bruno MJ, Bourke MJ, Neuhaus H, Roy A, González-Huix Lladó F, Barkun AN, Kortan PP, Navarrete C, Peetermans J, Blero D, Lakhtakia S, Dolak W, Lepilliez V, Poley JW, Tringali A, Costamagna G; Benign Biliary Stenoses Working Group. Successful management of benign biliary strictures with fully covered self-expanding metal stents. *Gastroenterology* 2014; **147**: 385-95; quiz e15 [PMID: 24801350 DOI: 10.1053/j.gastro.2014.04.043]
 - 59 **Bonnel DH**, Fingerhut AL. Percutaneous transhepatic balloon dilatation of benign bilioenteric strictures: long-term results in 110 patients. *Am J Surg* 2012; **203**: 675-683 [PMID: 22643036 DOI: 10.1016/j.amjsurg.2012.02.001]
 - 60 **Quintero GA**, Patiño JF. Surgical management of benign strictures of the biliary tract. *World J Surg* 2001; **25**: 1245-1250 [PMID: 11596883 DOI: 10.1007/s00268-001-0103-7]
 - 61 **Kitano M**, Gress TM, Garg PK, Itoi T, Irisawa A, Isayama H, Kanno A, Takase K, Levy M, Yasuda I, Lévy P, Isaji S, Fernandez-Del Castillo C, Drewes AM, Sheel ARG, Neoptolemos JP, Shimosegawa T, Boermeester M, Wilcox CM, Whitcomb DC. International consensus guidelines on interventional endoscopy in chronic pancreatitis. Recommendations from the working group for the international consensus guidelines for chronic pancreatitis in collaboration with the International Association of Pancreatology, the American Pancreatic Association, the Japan Pancreas Society, and European Pancreatic Club. *Pancreatol* 2020; **20**: 1045-1055 [PMID: 32792253 DOI: 10.1016/j.pan.2020.05.022]
 - 62 **Shen ZY**, Wang JJ, Lu LG, Wan R, Wan XJ, Cai XB. The efficacy and safety of balloon dilation for unresectable malignant biliary obstruction before placement of self-expanding metal stents. *J Dig Dis* 2020; **21**: 293-300 [PMID: 32279460 DOI: 10.1111/1751-2980.12864]



Published by **Baishideng Publishing Group Inc**
7041 Koll Center Parkway, Suite 160, Pleasanton, CA 94566, USA

Telephone: +1-925-3991568

E-mail: bpgoffice@wjgnet.com

Help Desk: <https://www.f6publishing.com/helpdesk>

<https://www.wjgnet.com>

