

# World Journal of *Clinical Cases*

*World J Clin Cases* 2018 December 6; 6(15): 869-1072





### REVIEW

- 869 Biomarkers in colorectal cancer: Current clinical utility and future perspectives  
*Vacante M, Borzi AM, Basile F, Biondi A*
- 882 Inflammation and de-differentiation in pancreatic carcinogenesis  
*Seimiya T, Otsuka M, Iwata T, Tanaka E, Suzuki T, Sekiba K, Yamagami M, Ishibashi R, Koike K*

### MINIREVIEWS

- 892 Management of gastroesophageal reflux disease: Patient and physician communication challenges and shared decision making  
*Klenzak S, Danelisen I, Brannan GD, Holland MA, van Tilburg MA*
- 901 Non-small bowel lesion detection at small bowel capsule endoscopy: A comprehensive literature review  
*Koffas A, Laskaratos FM, Epstein O*

### ORIGINAL ARTICLE

#### Case Control Study

- 908 Genetic associations of inflammatory bowel disease in a South Asian population  
*Niriella MA, Liyanage IK, Kodisinghe SK, De Silva AP, Rajapakshe N, Nanayakkara SD, Luke D, Silva T, Nawarathne M, Peiris RK, Kalubovila UP, Kumarasena SR, Dissanayake VH, Jayasekara RW, de Silva HJ*
- 916 Clinical relevance of atrial septal aneurysm and patent foramen ovale with migraine  
*He L, Cheng GS, Du YJ, Zhang YS*

#### Retrospective Study

- 922 Current trends of liver cirrhosis in Mexico: Similitudes and differences with other world regions  
*Méndez-Sánchez N, Zamarripa-Dorsey F, Panduro A, Purón-González E, Coronado-Alejandro EU, Cortez-Hernández CA, Higuera de la Tijera F, Pérez-Hernández JL, Cerda-Reyes E, Rodríguez-Hernández H, Cruz-Ramón VC, Ramírez-Pérez OL, Aguilar-Olivos NE, Rodríguez-Martínez OF, Cabrera-Palma S, Cabrera-Álvarez G*
- 931 Retrograde intrarenal surgery vs miniaturized percutaneous nephrolithotomy to treat lower pole renal stones 1.5-2.5 cm in diameter  
*Li MM, Yang HM, Liu XM, Qi HG, Weng GB*

### Clinical Trials Study

- 936 Comparative study on operative trauma between microwave ablation and surgical treatment for papillary thyroid microcarcinoma  
*Xu B, Zhou NM, Cao WT, Gu SY*

### Observational Study

- 944 Association between functional abdominal pain disorders and asthma in adolescents: A cross-sectional study  
*Kumari MV, Devanarayana NM, Amarasiri L, Rajindrajith S*

### Prospective Study

- 952 Evaluating mucosal healing using colon capsule endoscopy predicts outcome in patients with ulcerative colitis in clinical remission  
*Takano R, Osawa S, Uotani T, Tani S, Ishida N, Tamura S, Yamade M, Iwaizumi M, Hamaya Y, Furuta T, Miyajima H, Sugimoto K*

### META-ANALYSIS

- 961 Probiotic Medilac-S® for the induction of clinical remission in a Chinese population with ulcerative colitis: A systematic review and meta-analysis  
*Sohail G, Xu X, Christman MC, Tompkins TA*
- 985 Impact of body mass index on short-term outcomes of laparoscopic gastrectomy in Asian patients: A meta-analysis  
*Chen HK, Zhu GW, Huang YJ, Zheng W, Yang SG, Ye JX*
- 995 Scoring systems for prediction of mortality in decompensated liver cirrhosis: A meta-analysis of test accuracy  
*Wu SL, Zheng YX, Tian ZW, Chen MS, Tan HZ*

### CASE REPORT

- 1007 Gangrenous cholecystitis: A silent but potential fatal disease in patients with diabetic neuropathy. A case report  
*Mehrzad M, Jehle CC, Roussel LO, Mehrzad R*
- 1012 Successful endovascular treatment of endoscopically unmanageable hemorrhage from a duodenal ulcer fed by a renal artery: A case report  
*Anami S, Minamiguchi H, Shibata N, Koyama T, Sato H, Ikoma A, Nakai M, Yamagami T, Sonomura T*

- 1018** Didactic surgical experience of thyroid metastasis from renal cell carcinoma: A case report  
*Yamauchi M, Kai K, Shibamiya N, Shimazu R, Monji M, Suzuki K, Kakinoki H, Tobu S, Kuratomi Y*
- 1024** Gastric cancer with severe immune thrombocytopenia: A case report  
*Zhao ZW, Kang WM, Ma ZQ, Ye X, Yu JC*
- 1029** Injury to the axillary artery and brachial plexus caused by a closed floating shoulder injury: A case report  
*Chen YC, Lian Z, Lin YN, Wang XJ, Yao GF*
- 1036** Pancreatic panniculitis and solid pseudopapillary tumor of the pancreas: A case report  
*Zhang MY, Tian BL*
- 1042** Intermittent abdominal pain accompanied by defecation difficulties caused by Chilaiditi syndrome: A case report  
*Luo XG, Wang J, Wang WL, Yu CZ*
- 1047** Endoscopic titanium clip closure of gastric fistula after splenectomy: A case report  
*Yu J, Zhou CJ, Wang P, Wei SJ, He JS, Tang J*
- 1053** Successful steroid treatment for acute fibrinous and organizing pneumonia: A case report  
*Ning YJ, Ding PS, Ke ZY, Zhang YB, Liu RY*
- 1059** Sub-Tenon's urokinase injection-assisted vitrectomy in early treatment of suprachoroidal hemorrhage: Four cases report  
*Chai F, Ai H, Deng J, Zhao XQ*
- 1067** Plexiform fibromyxoma of the small bowel: A case report  
*Zhang WG, Xu LB, Xiang YN, Duan CH*

**ABOUT COVER**

Editorial Board Member of *World Journal of Clinical Cases*, Steven M Schwarz, MD, Professor, Department of Pediatrics, Children's Hospital at Downstate, SUNY-Downstate Medical Center, Brooklyn, NY 11203, United States

**AIM AND SCOPE**

*World Journal of Clinical Cases* (*World J Clin Cases*, *WJCC*, online ISSN 2307-8960, DOI: 10.12998) is a peer-reviewed open access academic journal that aims to guide clinical practice and improve diagnostic and therapeutic skills of clinicians.

The primary task of *WJCC* is to rapidly publish high-quality Autobiography, Case Report, Clinical Case Conference (Clinicopathological Conference), Clinical Management, Diagnostic Advances, Editorial, Field of Vision, Frontier, Medical Ethics, Original Articles, Clinical Practice, Meta-Analysis, Minireviews, Review, Therapeutics Advances, and Topic Highlight, in the fields of allergy, anesthesiology, cardiac medicine, clinical genetics, clinical neurology, critical care, dentistry, dermatology, emergency medicine, endocrinology, family medicine, gastroenterology and hepatology, geriatrics and gerontology, hematology, immunology, infectious diseases, internal medicine, obstetrics and gynecology, oncology, ophthalmology, orthopedics, otolaryngology, pathology, pediatrics, peripheral vascular disease, psychiatry, radiology, rehabilitation, respiratory medicine, rheumatology, surgery, toxicology, transplantation, and urology and nephrology.

**INDEXING/ABSTRACTING**

*World Journal of Clinical Cases* (*WJCC*) is now indexed in PubMed, PubMed Central, Science Citation Index Expanded (also known as SciSearch®), and Journal Citation Reports/Science Edition. The 2018 Edition of Journal Citation Reports cites the 2017 impact factor for *WJCC* as 1.931 (5-year impact factor: N/A), ranking *WJCC* as 60 among 154 journals in Medicine, General and Internal (quartile in category Q2).

**EDITORS FOR THIS ISSUE**

**Responsible Assistant Editor:** *Xiang Li*  
**Responsible Electronic Editor:** *Wen-Wen Tan*  
**Proofing Editor-in-Chief:** *Lian-Sheng Ma*

**Responsible Science Editor:** *Ying Dou*  
**Proofing Editorial Office Director:** *Jin-Lei Wang*

**NAME OF JOURNAL**  
*World Journal of Clinical Cases*

**ISSN**  
ISSN 2307-8960 (online)

**LAUNCH DATE**  
April 16, 2013

**FREQUENCY**  
Semimonthly

**EDITORS-IN-CHIEF**  
**Sandro Vento, MD**, Department of Internal Medicine, University of Botswana, Private Bag 00713, Gaborone, Botswana

**EDITORIAL BOARD MEMBERS**  
All editorial board members resources online at <http://www.wjnet.com/2307-8960/editorialboard.htm>

**EDITORIAL OFFICE**  
Jin-Lei Wang, Director

*World Journal of Clinical Cases*  
Baishideng Publishing Group Inc  
7901 Stoneridge Drive, Suite 501, Pleasanton, CA 94588, USA  
Telephone: +1-925-2238242  
Fax: +1-925-2238243  
E-mail: [editorialoffice@wjnet.com](mailto:editorialoffice@wjnet.com)  
Help Desk: <http://www.f6publishing.com/helpdesk>  
<http://www.wjnet.com>

**PUBLISHER**  
Baishideng Publishing Group Inc  
7901 Stoneridge Drive, Suite 501, Pleasanton, CA 94588, USA  
Telephone: +1-925-2238242  
Fax: +1-925-2238243  
E-mail: [bpgoffice@wjnet.com](mailto:bpgoffice@wjnet.com)  
Help Desk: <http://www.f6publishing.com/helpdesk>  
<http://www.wjnet.com>

**PUBLICATION DATE**  
December 6, 2018

**COPYRIGHT**

© 2018 Baishideng Publishing Group Inc. Articles published by this Open Access journal are distributed under the terms of the Creative Commons Attribution Non-commercial License, which permits use, distribution, and reproduction in any medium, provided the original work is properly cited, the use is non commercial and is otherwise in compliance with the license.

**SPECIAL STATEMENT**

All articles published in journals owned by the Baishideng Publishing Group (BPG) represent the views and opinions of their authors, and not the views, opinions or policies of the BPG, except where otherwise explicitly indicated.

**INSTRUCTIONS TO AUTHORS**

<http://www.wjnet.com/bpg/gerinfo/204>

**ONLINE SUBMISSION**

<http://www.f6publishing.com>

# Gangrenous cholecystitis: A silent but potential fatal disease in patients with diabetic neuropathy. A case report

Meliorin Mehrzad, Charles C Jehle, Lauren O Roussel, Raman Mehrzad

Meliorin Mehrzad, Charles C Jehle, Lauren O Roussel, Raman Mehrzad, Department of Plastic and Reconstructive Surgery, Rhode Island Hospital, Brown University, Providence, RI 02903, United States

ORCID number: Meliorin Mehrzad (0000-0002-7578-2720); Charles C Jehle (0000-0001-7780-1074); Lauren O Roussel (0000-0001-5991-3478); Raman Mehrzad (0000-0002-7578-2719).

Author contributions: All authors contributed equally to the manuscript.

**Informed consent statement:** A signed consent was obtained and saved for this case report by the patient through the standard institutional consent document and saved by the institution. Most importantly, there are no patient identifiers on the case or the images. In American institutions, medical record from a patient is not allowed to print out and give to anyone else. This is according to the law of HIPPA. Again, there is no patient identifier on the entire case so this patient is completely anonymous.

**Conflict-of-interest statement:** Nothing to disclose.

**CARE Checklist (2013) statement:** The guidelines of the CARE Checklist (2013) have been adopted.

**Open-Access:** This article is an open-access article which was selected by an in-house editor and fully peer-reviewed by external reviewers. It is distributed in accordance with the Creative Commons Attribution Non Commercial (CC BY-NC 4.0) license, which permits others to distribute, remix, adapt, build upon this work non-commercially, and license their derivative works on different terms, provided the original work is properly cited and the use is non-commercial. See: <http://creativecommons.org/licenses/by-nc/4.0/>

**Manuscript source:** Invited manuscript

**Corresponding author to:** Raman Mehrzad, MD, Academic Fellow, Staff Physician, MD, MHL, Department of Plastic and Reconstructive Surgery, Rhode Island Hospital, Brown University, 235 Plain St., Providence, RI 02903, United States. [raman\\_ml@hotmail.com](mailto:raman_ml@hotmail.com)

Telephone: +1-774-2400060

Received: September 19, 2018

Peer-review started: September 19, 2018

First decision: October 4, 2018

Revised: November 8, 2018

Accepted: November 14, 2018

Article in press: November 15, 2018

Published online: December 6, 2018

## Abstract

Gangrenous cholecystitis (GC) is a severe and potentially deadly complication of acute cholecystitis. We present a 83-year-old gentleman with a past medical history of type 2 diabetes mellitus with significant associated neuropathy, presenting to a community hospital in a major metropolitan area with 10 days nausea and vomiting and a benign abdominal exam. While the patient was admitted for hyperglycemia, he was subsequently found to have severe GC requiring urgent surgical intervention.

**Key words:** Gangrenous cholecystitis; Diabetes mellitus; Hyperglycemia; Complications; Case report

© **The Author(s) 2018.** Published by Baishideng Publishing Group Inc. All rights reserved.

**Core tip:** We present an 83-year-old gentleman with type 2 diabetes mellitus and associated neuropathy who was found to have severe gangrenous cholecystitis (GC) requiring urgent surgical intervention but without any of the cardinal symptoms of GC.

Mehrzad M, Jehle CC, Roussel LO, Mehrzad R. Gangrenous cholecystitis: A silent but potential fatal disease in patients with diabetic neuropathy. A case report. *World J Clin Cases* 2018;



## INTRODUCTION

Diabetes mellitus (DM) is a chronic disease caused by deficiency in production of insulin by the pancreas, or by of the insulin produced. This subsequently leads to an increased concentrations of glucose in the blood<sup>[1]</sup>. The prevalence of DM has markedly increased over the past few decades with nearly 300 million people worldwide with the disease today<sup>[2]</sup>. DM is itself a specific group of metabolic disorders that share common phenotype of hyperglycemia. The two broad categories, or types, of DM are classified by the underlying pathogenic process leading to elevated blood sugar levels. Type 1 DM exhibits almost complete insulin deficiency, while type 2 DM is an intricate constellation of pathology including insulin resistance, increased glucose production and impaired insulin secretion<sup>[3]</sup>. Important complications from DM include cardiovascular disease, stroke, diabetes retinopathy, renal failure and neuropathy<sup>[4]</sup>.

Gangrenous cholecystitis (GC) is a severe and potentially deadly progression of acute cholecystitis that occurs in up to 30% of cases<sup>[5]</sup>. It is the end result of persistent and severe inflammation, where there is such significant distension of the gallbladder that the wall becomes ischemic<sup>[6]</sup>. Risk factors include male gender, age > 45 years, history of diabetes and heart disease<sup>[7]</sup>. Although clinical signs of peritonitis are sometimes absent, these patients typically present with at least one or more of the following symptoms: right upper quadrant abdominal pain, loss of appetite, jaundice, and/or fever<sup>[8]</sup>. These patients almost universally undergo emergent cholecystectomy to avoid fatal complications<sup>[6]</sup>.

Diabetic neuropathy is among the most common complications of DM, and is clinically important because it can diminish symptoms of life-threatening such as myocardial ischemia<sup>[9]</sup>. We present an 83-year-old gentleman who was admitted for hyperglycemia but was later found to have a severe GC without an exam findings concerning for peritonitis. To our knowledge, this is the fourth case ever reported of GC in a patient with DM presenting with non-specific abdominal symptoms and reassuring physical exam<sup>[10-12]</sup>.

## CASE PRESENTATION

An 83-year-old male with a 20 year history of type 2 DM, with advanced diabetic neuropathy, hypertension and hyperlipidemia presented to his primary care physician's office with a chief complaint of nausea, vomiting, and diarrhea for 10 d. Point of care glucose monitor showed the patient's blood sugar to be > 600 mg/dL, and the patient was transferred to

the emergency department (ED) of the associated community hospital.

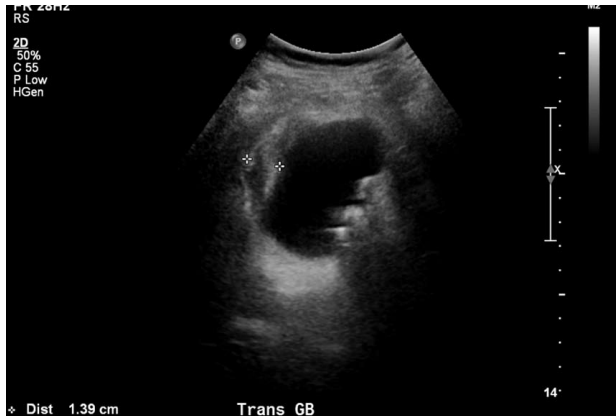The patient attributed the nausea and vomiting to a beef sandwich he ate four days preceding the symptoms. He had not been able tolerate food and reported very limited fluid intake. Additionally, the patient noted three loose brown bowel movements daily without gross blood or melena which resolved three days prior to admission. The patient denied abdominal pain, hematemesis, chest pain, shortness of breath or any other associated symptoms. A complete review of systems was otherwise negative.

The patient had a strong family history of both type 1 and 2 DM including his mother, two brothers, and other distant relatives. The patient's social history was significant for occasional alcohol use of 2-3 beers per month. The patient denied tobacco and illicit drug use. The patient's home medications were Pravastatin 20 mg PO daily, Glyburide 1.25 mg PO daily, Lisinopril 10 mg PO daily, and Omeprazole 20 mg PO daily.

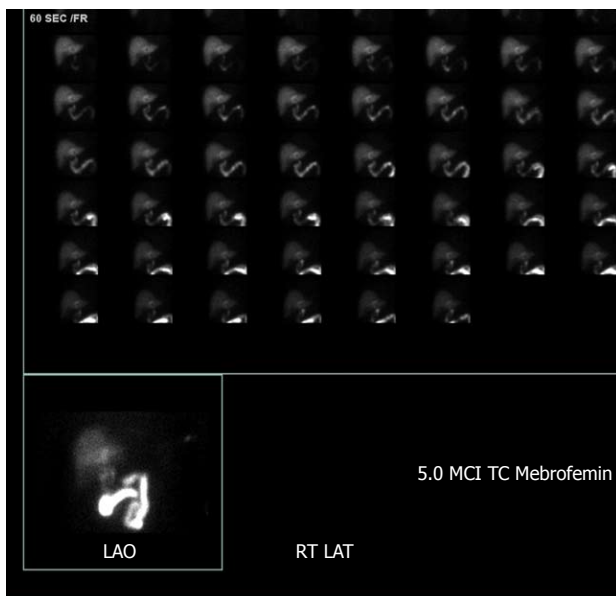
In the ED his vital signs were a temperature of 98.2 F, heart rate of 89/min, respiratory rate of 18/min, blood pressure 147/79 mmHg, and O2 Saturation by pulse oximetry 93% on room air. Laboratory results were significant for a white blood count (WBC) of 16.5 k/uL, Sodium 132 mmol/L, Chloride 93 mmol/L, Glucose 598 mg/dL, AST 49 U/L, Alkaline Phosphatase 196 U/L, Albumin 3.1 g/dL, Albumin/Globulin Ratio 0.6 L. Other labs were within normal limits, and urinalysis was negative for ketones.

Physical examination was documented as normal. The patient was alert and oriented to person, time and place. Respiratory exam was clear to auscultation bilaterally. Cardiovascular exam revealed regular rate and rhythm, with no murmurs, rubs or gallop. Abdomen was soft, non-tender, non-distended, with normal bowel sounds, and no organomegaly. Neurological exam showed intact cranial nerves 2-12, reflexes were 2+ and symmetric at the biceps, triceps, knees, and ankles. Plantar responses for flexor, light touch, pinprick, position sense, and vibration sense was impaired in fingers and toes, Rapid alternating movements and fine finger movements are intact. There was no dysmetria on finger-to-nose and heel-knee-shin. There were no abnormal or extraneous movements. Romberg was absent. The skin was warm, dry, with no identified rashes. Imaging in the ED was limited to a plain film of the chest which demonstrated atelectasis vs scarring in the lateral left base, without infiltrates.

The patient was admitted to the general medicine ward for treatment of hyperglycemia. He was initially given 0.2 units/kg of Lantus once, and then put on insulin sliding scale with blood glucose measurements every 6 h. A second abdominal examination was performed several hours after admission because of an elevated alkaline phosphatase, without any concerning findings. Additionally, an abdominal ultrasound was performed which exhibited hepatomegaly with the



**Figure 1** Ultrasound image demonstrating a pronounced gallbladder wall thickening and stones, consistent with acute colecystitis.



**Figure 2** HIDA scan image demonstrates non-visualization of the gallbladder one hour after radiotracer injection, consistent with cystic duct obstruction.

liver measuring to 18 cm in length. While no hepatic biliary tract obstruction was noted on ultrasound, his gallbladder was found to have a thickened wall, with pericholecystic fluid and multiple hyper-echoic calculi (Figure 1). These findings were strongly concerning for acute cholecystitis.

The patient was started on 3.375 g of Piperacillin/Tazobactam, every 6 h. The patient's condition improved overall by hospital day two. He denied nausea, vomiting and abdominal pain. Given his reassuring vials, exam and symptomatology in the face of an abnormal ultrasound, a HIDA scan was performed which also suggested acute cholecystitis (Figure 2).

Soon after, the patient developed a low-grade fever of 100.4 F, with chills and rigors. A set of blood cultures was obtained, and general surgery was consulted. They recommended continuing IV antibiotics and preparation for surgery. Demerol (Meperidine) and Tylenol

(acetaminophen) were added for fever and pain.

The patient thereafter underwent a laparoscopic cholecystectomy. The findings were significant for a severely gangrenous gallbladder, with copious purulent drainage from gallbladder, subhepatic abscess, and cholelithiasis, and this was confirmed in post-operative histopathology. The patient's abdomen was irrigated copiously during the procedure. There were no peri-operative complications.

On the next hospital day, the patient was feeling well without complaints including no abdominal pain, fevers, rigors or chills. Abdominal examination continued to be benign, and the surgical wound was well approximated. WBC trended down to normal limits. Alkaline phosphatase had down trended from 196 U/L on admission to as low as 127 U/L post-operatively. The patient's diet was advanced to regular diabetic diet, which he tolerated well, and he was later discharged home.

The hyperglycemia seen in this patient was likely multifactorial, due to chronically poor compliance with diabetic medications and diet as well as acute infection. The patient's HbA1c was 10.5% during this hospitalization and an endocrinologist was consulted who started the patient on an insulin regimen on discharge with regular follow ups.

## FINAL DIAGNOSIS

Gangrenous cholecystitis.

## TREATMENT

Cholecystectomy.

## OUTCOME AND FOLLOW-UP

Clinic follow up.

## DISCUSSION

This case illustrates the sometimes difficult nature of identifying underlying diseases in patients with severe diabetes and associated complications. This patient had an elevated Alkaline Phosphatase and a mild leukocytosis in the setting of nausea and vomiting. This prompted further investigation in the form of medical imaging despite benign abdominal exam ultimately leading to diagnosis of acute cholecystitis with gangrenous gallbladder. This joins the ranks of three similar cases which have been reported in the literature, all with a history of DM<sup>[10-12]</sup>.

Fagan *et al.*<sup>[13]</sup> asserted that several variables, including WBC > 15000, history of diabetes, African American race, abnormal liver function tests (elevated ALT, AST, ALP, lipase levels) and pericholecystic fluid were associated with GC. An additional study found after multivariate analysis that in patients with cholecystitis those with history of diabetes and leukocytosis were



significantly more likely to have a gangrenous gallbladder. Finally, Contini *et al.*<sup>[7]</sup> have implicated that WBC count was the strongest predictor for presence of gangrene. The patient reported appears to support these findings given his history of diabetes as well as leukocytosis and elevated alkaline phosphatase on presentation.

It is important to recognize the natural history and life-threatening complications of GC. A gangrenous gallbladder almost invariably goes on to perforate and once gangrenous, the overall complication rate approaches 25%. Perforation can lead to abscess formation and peritonitis. Ultimately, mortality rates in GC are reported to be as high as 22%<sup>[7,14]</sup>. Accordingly, early diagnosis and surgical treatment is critical to mitigate serious complications including mortality in these patients<sup>[7,14]</sup>.

The reason for the insidious nature of this patient's presentation was presumably driven by his neuropathy. Neuropathy leads to a host of consequences including intrabdominal manifestations such as impaired gastric motility and inability to appreciate abdominal pain. While not fully understood, diabetics exhibit complex changes of metabolic, vascular and hormonal factors which both increase nerve fiber damage and diminish the body's ability to repair these nerves<sup>[15,16]</sup>. Nerve damage from ischemia is thought to contribute to the development of diabetic neuropathy. In autopsies of patients with diabetic neuropathy thickened endoneurial blood vessel walls and vascular occlusions are commonly found<sup>[17]</sup>. This is also supported by decreased endoneurial oxygen tension measured in sural nerves of the patients with advanced polyneuropathy<sup>[18]</sup>.

Impaired neuronal repair is also thought to contribute to diabetic neuropathy<sup>[19,20]</sup>. This may be due in part to a decrease of neurotrophic peptides which mediate nerve maintenance, repair and regeneration. Specifically, nerve growth factor, brain-derived neurotrophic factor, neurotrophin-3, insulin-like growth factors, and vascular endothelial growth factor have all found to contribute to nerve health<sup>[20]</sup>. Moreover, insulin itself plays an important role as a neurotrophic factor to peripheral neurons; and the low insulin state present in type 1 diabetes may be particularly detrimental to overall nerve health<sup>[15,21]</sup>.

In conclusion, this case illustrates the insidious presentation of a life-threatening surgical disease in a patient admitted for medical management of hyperglycemia. Gangrenous gallbladder is a serious complication of acute cholecystitis which was largely masked by a benign abdominal exam in a patient with severe diabetic neuropathy. This is similar to diabetic patients presenting with "silent" acute coronary syndrome. In conclusion, it is important that in patients with a history of poorly controlled diabetes, a higher index of suspicion should be raised for severe intraabdominal pathology even in the setting of a benign abdominal exam.

## EXPERIENCES AND LESSONS

GC is a severe and potentially life-threatening complication of acute cholecystitis that occurs in up to 30% of cases. Risk factors of GC include male gender, age > 45 years, history of diabetes and heart disease. GC can be asymptomatic in patients with DM. Patients with leukocytosis and/or abnormal liver function tests with a history of DM should be considered for further work up, regardless of symptoms or physical examination.

## REFERENCES

- 1 **Kumar V**, Abbas AK, Aster JC. Robbins and Cotran Pathologic Basis of Disease. 7th ed. Philadelphia, Pa: Saunders, 2005: 1194-1195
- 2 **Smyth S**, Heron A. Diabetes and obesity: the twin epidemics. *Nat Med* 2006; **12**: 75-80 [PMID: 16397575 DOI: 10.1038/nm0106-75]
- 3 **Powers AC**. Harrison's Principles of Internal medicine. In: Braunwald BE, Fauci AS, Kasper DL, Hauser SL (eds). 18<sup>th</sup> ed. Chapter 344-Classification. New York: McGraw Hill, 2012
- 4 **Centers for Disease Control and Prevention**. National diabetes fact sheet: national estimates and general information on diabetes and prediabetes in the United States, Atlanta, GA, 2011. Available from: URL: [http://www.cdc.gov/diabetes/pubs/pdf/ndfs\\_2011.pdf](http://www.cdc.gov/diabetes/pubs/pdf/ndfs_2011.pdf)
- 5 **Bingener J**, Stefanidis D, Richards ML, Schwesinger WH, Sirinek KR. Early conversion for gangrenous cholecystitis: impact on outcome. *Surg Endosc* 2005; **19**: 1139-1141 [PMID: 16021370 DOI: 10.1007/s00464-004-8190-9]
- 6 **Bennett GL**, Rusinek H, Lisi V, Israel GM, Krinsky GA, Slywotzky CM, Megibow A. CT findings in acute gangrenous cholecystitis. *AJR Am J Roentgenol* 2002; **178**: 275-281 [PMID: 11804880 DOI: 10.2214/ajr.178.2.1780275]
- 7 **Contini S**, Corradi D, Busi N, Alessandri L, Pezzarossa A, Scarpignato C. Can gangrenous cholecystitis be prevented?: a plea against a "wait and see" attitude. *J Clin Gastroenterol* 2004; **38**: 710-716 [PMID: 15319657 DOI: 10.1097/01.mcg.0000135898.68155.88]
- 8 **Joshi N**, Caputo GM, Weitekamp MR, Karchmer AW. Infections in patients with diabetes mellitus. *N Engl J Med* 1999; **341**: 1906-1912 [PMID: 10601511 DOI: 10.1056/nejm199912163412507]
- 9 **Chico A**, Tomás A, Novials A. Silent myocardial ischemia is associated with autonomic neuropathy and other cardiovascular risk factors in type 1 and type 2 diabetic subjects, especially in those with microalbuminuria. *Endocrine* 2005; **27**: 213-217 [PMID: 16230776 DOI: 10.1385/ENDO:27:3:213]
- 10 **Chaudhry S**, Hussain R, Rajasundaram R, Corless D. Gangrenous cholecystitis in an asymptomatic patient found during an elective laparoscopic cholecystectomy: a case report. *J Med Case Rep* 2011; **5**: 199 [PMID: 21600009 DOI: 10.1186/1752-1947-5-199]
- 11 **Nidimusili AJ**, Alraies MC, Eisa N, Alraiyes AH, Shaheen K. Leukocytosis of unknown origin: gangrenous cholecystitis. *Case Rep Med* 2013; **2013**: 418014 [PMID: 23606852 DOI: 10.1155/2013/418014]
- 12 **Grant RL**, Tie ML. False negative biliary scintigraphy in gangrenous cholecystitis. *Australas Radiol* 2002; **46**: 73-75 [PMID: 11966592 DOI: 10.1046/j.1440-1673.2001.00998.x]
- 13 **Fagan SP**, Awad SS, Rahwan K, Hira K, Aoki N, Itani KM, Berger DH. Prognostic factors for the development of gangrenous cholecystitis. *Am J Surg* 2003; **186**: 481-485 [PMID: 14599611 DOI: 10.1016/j.amjsurg.2003.08.001]
- 14 **Yamashita Y**, Noritomi T, Matsuoka N, Sinya T, Sugi Y, Higa K, Kusumoto G, Nitahara K. [Surgical treatment of acute cholecystitis]. *Masui* 2012; **61**: 944-950; discussion 951-952 [PMID: 23012831]
- 15 **Edwards JL**, Vincent AM, Cheng HT, Feldman EL. Diabetic neuropathy: mechanisms to management. *Pharmacol Ther* 2008; **120**: 1-34 [PMID: 18616962 DOI: 10.1016/j.pharmthera.2008.05.005]

- 16 **Callaghan BC**, Cheng HT, Stables CL, Smith AL, Feldman EL. Diabetic neuropathy: clinical manifestations and current treatments. *Lancet Neurol* 2012; **11**: 521-534 [PMID: 22608666 DOI: 10.1016/S1474-4422(12)70065-0]
- 17 **Feldman EL**. Pathogenesis and prevention of diabetic polyneuropathy. Available from: URL: <https://www.uptodate.com/contents/pathogenesis-and-prevention-of-diabetic-polyneuropathy/print>
- 18 **Newrick PG**, Wilson AJ, Jakubowski J, Boulton AJ, Ward JD. Sural nerve oxygen tension in diabetes. *Br Med J (Clin Res Ed)* 1986; **293**: 1053-1054 [PMID: 3094772 DOI: 10.1136/bmj.293.6554.1053]
- 19 **Kennedy JM**, Zochodne DW. The regenerative deficit of peripheral nerves in experimental diabetes: its extent, timing and possible mechanisms. *Brain* 2000; **123** ( Pt 10): 2118-2129 [PMID: 11004128 DOI: 10.1093/brain/123.10.2118]
- 20 **Kennedy JM**, Zochodne DW. Impaired peripheral nerve regeneration in diabetes mellitus. *J Peripher Nerv Syst* 2005; **10**: 144-157 [PMID: 15958126 DOI: 10.1111/j.1085-9489.2005.0010205.x]
- 21 **Brussee V**, Cunningham FA, Zochodne DW. Direct insulin signaling of neurons reverses diabetic neuropathy. *Diabetes* 2004; **53**: 1824-1830 [PMID: 15220207 DOI: 10.2337/diabetes.53.7.1824]

**P- Reviewer:** Avtanski D, Sahoo J, Saisho Y **S- Editor:** Ji FF  
**L- Editor:** A **E- Editor:** Wu YXJ





Published by **Baishideng Publishing Group Inc**  
7901 Stoneridge Drive, Suite 501, Pleasanton, CA 94588, USA  
Telephone: +1-925-223-8242  
Fax: +1-925-223-8243  
E-mail: [bpgoffice@wjgnet.com](mailto:bpgoffice@wjgnet.com)  
Help Desk: <http://www.f6publishing.com/helpdesk>  
<http://www.wjgnet.com>

