

Direct anterior total hip arthroplasty: Literature review of variations in surgical technique

Keith P Connolly, Atul F Kamath

Keith P Connolly, Atul F Kamath, Department of Orthopedic Surgery, Center for Hip Preservation, Pennsylvania Hospital, University of Pennsylvania, Philadelphia, PA 19107, United States

Author contributions: Connolly KP and Kamath AF equally contributed to this paper.

Conflict-of-interest statement: The authors have no conflicts of interest to disclose pertaining to the subject of this review manuscript.

Open-Access: This article is an open-access article which was selected by an in-house editor and fully peer-reviewed by external reviewers. It is distributed in accordance with the Creative Commons Attribution Non Commercial (CC BY-NC 4.0) license, which permits others to distribute, remix, adapt, build upon this work non-commercially, and license their derivative works on different terms, provided the original work is properly cited and the use is non-commercial. See: <http://creativecommons.org/licenses/by-nc/4.0/>

Correspondence to: Atul F Kamath, MD, Department of Orthopedic Surgery, Center for Hip Preservation, Pennsylvania Hospital, University of Pennsylvania, 800 Spruce Street, 8th Floor Preston, Philadelphia, PA 19107, United States. akamath@post.harvard.edu
Telephone: +1-215-6878169
Fax: +1-215-8292492

Received: May 27, 2015
Peer-review started: May 30, 2015
First decision: August 4, 2015
Revised: October 11, 2015
Accepted: November 3, 2015
Article in press: November 4, 2015
Published online: January 18, 2016

Abstract

The direct anterior approach to the hip has been suggested to have several advantages compared to previously popular approaches through its use of an intra-muscular and intra-nervous interval between

the tensor fasciae latae and sartorius muscles. Recent increased interest in tissue-sparing and minimally-invasive arthroplasty has given rise to a sharp increase in the utilization of direct anterior total hip arthroplasty. A number of variations of the procedure have been described and several authors have published their experiences and feedback to successfully accomplishing this procedure. Additionally, improved understanding of relevant soft tissue constraints and anatomic variants has provided improved margin of safety for patients. The procedure may be performed using specially-designed instruments and a fracture table, however many authors have also described equally efficacious performance using a regular table and standard arthroplasty tools. The capacity to utilize fluoroscopy intra-operatively for component positioning is a valuable asset to the approach and can be of particular benefit for surgeons gaining familiarity. Proper management of patient and limb positioning are vital to reducing risk of intra-operative complications. An understanding of its limitations and challenges are also critical to safe employment. This review summarizes the key features of the direct anterior approach for total hip arthroplasty as an aid to improving the understanding of this important and effective method for modern hip replacement surgeons.

Key words: Anterior hip arthroplasty; Anterior supine intramuscular approach; Total hip arthroplasty; Direct anterior approach

© **The Author(s) 2016.** Published by Baishideng Publishing Group Inc. All rights reserved.

Core tip: This review captures the most important concepts of direct anterior total hip arthroplasty as described by numerous surgeons' experiences with the procedure. It compares variations in surgical exposure and arthroplasty techniques, while identifying key elements of the anterior hip anatomy for performance of safe and efficient surgery. The review divides anterior hip arthroplasty into six distinct elements, citing the

most relevant pearls and pitfalls of previous publications and the most relied upon surgical methods. This concise summary can be beneficial to any level of surgeon desiring to enhance their understanding of direct anterior total hip arthroplasty.

Connolly KP, Kamath AF. Direct anterior total hip arthroplasty: Literature review of variations in surgical technique. *World J Orthop* 2016; 7(1): 38-43 Available from: URL: <http://www.wjgnet.com/2218-5836/full/v7/i1/38.htm> DOI: <http://dx.doi.org/10.5312/wjo.v7.i1.38>

INTRODUCTION

The direct anterior approach (DAA) to the hip was first described by Carl Hueter in 1881. However Marius Smith-Petersen is frequently credited with developing this technique due to his prolific use of the technique throughout his career, after initially publishing his description in 1917. Modern day literature frequently refers to this method interchangeably as both the Hueter and Smith-Petersen approach when identifying the anterior based incision that utilizes the interval to the hip joint through the tensor fasciae latae (TFL) and the sartorius muscles^[1]. Light and Keggi^[2] published their extensive experience using this approach for hip arthroplasty in 1980, and the Judets described the procedure with use of a fracture table in 1985^[1,2]. The modern day desire to perform hip reconstruction through less invasive and tissue sparing methods was the key driver in the newfound interest of the anterior approach. This has led to a surge in its proliferation over the past 15 years^[3]. During this time, numerous authors have described variations of the technique and key concepts to safe and successful performance of hip arthroplasty. Although many consider the DAA appropriate exclusively for primary joint replacement, several authors have noted routine use of this technique for complex revision surgery and bipolar hemiarthroplasty for hip fractures^[4-6]. This review seeks to summarize the published literature on the direct anterior total hip arthroplasty procedure with a focus on comparative key pearls and pitfalls.

INDICATIONS AND CHALLENGES

Several authors have recommended using the DAA in patients of nearly all body habitus and hip conditions^[4,7]. The ideal patient has been described as a flexible, non-muscular patient with valgus femoral neck and good femoral offset. It is reasonable to initially develop skills to perform the approach in slender patients with a body mass index of less than thirty^[8]. As achievement of appropriate exposure is gained with experience using the technique, it has also been suggested that lack of appropriate instrumentation designed for anterior supine intramuscular approach is a contraindication^[8]. Some anatomic features of the native hip and pelvis

are recognized to make the DAA more difficult. A wide or horizontal iliac wing limits access to the femoral canal for broaching and femoral component placement. Acetabular protrusion brings the femoral canal closer to pelvis and obstructs access to femur. A neck shaft angle with decreased offset positions the femoral canal deeper in the thigh, and anatomy associated with obese muscular males limits the space available to place components^[9]. One disadvantage of the anterior approach is diminished access to the posterior column. If the patient has a deficient posterior acetabular wall from previous hardware or trauma, or if posterior acetabular augmentation is contemplated, the anterior exposure may be unsuitable^[10].

SURGICAL TECHNIQUE

Patient positioning

The vast majority of authors describing the DAA position the patient supine on a fracture or regular table. Michel *et al*^[11] also proposed performing anterior total hip arthroplasty (THA) using lateral decubitus positioning. When using a regular table, the patient is positioned with the pelvis located over the table break, which can be angled to allow hyperextension at the hip joint (Figure 1A). A bump may be used placed under the sacrum, centered at the anterior superior iliac spine (ASIS) to further elevate the pelvis^[3]. Kennon *et al*^[12] recommends orienting the table at right angles to the walls for accurate referencing and anatomic orientation. The contralateral leg is frequently draped into the field, and an arm board may be placed alongside to allow for abduction during femoral exposure^[8]. Obese patients should have the pannus retracted with adhesive tape to avoid interference with exposure^[7]. With use a fracture table (Figure 1B), the peroneal post should be well-padded to avoid peroneal nerve neuropraxia^[13].

Surgical approach

The descriptions for skin incision vary by surgeon, however most authors rely on the ASIS and greater trochanter as anatomic landmarks for reference (Figure 2). An oblique incision is made originating 2-4 cm distal and lateral to the ASIS to a point a few finger breaths anterior to the greater trochanter^[4,7,8,11,14,15]. A cadaveric anatomy study showed that the zone immediately distal to the intertrochanteric line formed an anatomic barrier to protect neurovascular structures. Incision extension distal to this point risks damage to branches of the lateral femoral circumflex artery (LFCA) supplying the proximal quadriceps muscles and femoral nerve divisions to the vastus intermedius and lateralis^[16]. The incision is generally oriented in line with the TFL, which can also be delineated by a line from the ASIS to the patella or fibular head, or in line with the femoral neck^[17]. Fluoroscopy may be used to assist in identifying the femoral neck and midpoint for the incision^[18].

A well-recognized complication of this approach is the proximity of the incision to the lateral femoral

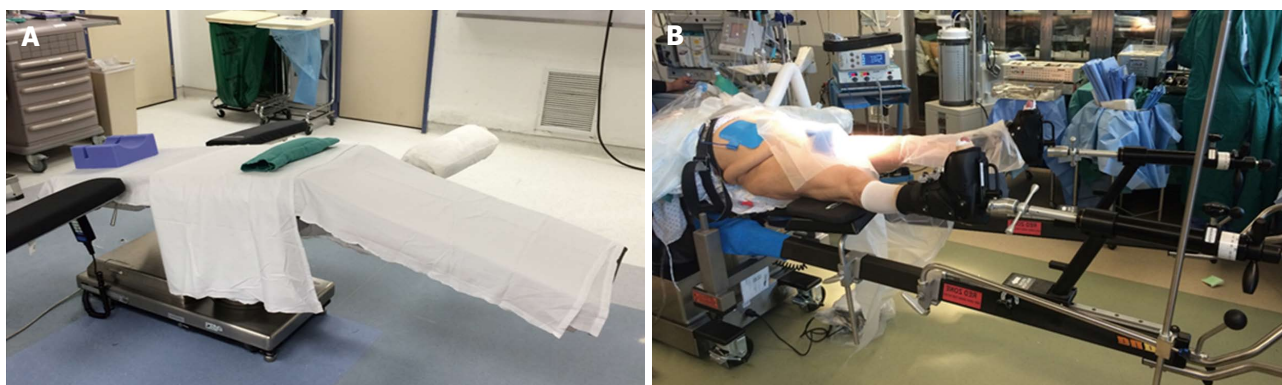


Figure 1 Patient positioning. A: Use of a regular table with bump under the sacrum and ability to lower the distal end of the bed down to afford better femoral exposure. An extra arm board can be placed on the contralateral distal end of the bed to support the contralateral leg while accessing the operative femoral canal; B: Patient positioning on a fracture-type table (Hana table, Mizuho Orthopedics Systems, Inc.).

cutaneous nerve (LFCN). Though it is commonly believed that remaining lateral to the TFL/sartorius interval reduces risk for injury to the nerve, a cadaveric study of LFCN arborization showed the gluteal branch crossed the anterior margin of the TFL at 44 mm from the ASIS; the femoral branch also crossed this margin in half of specimens, at an average of 46 mm distal to the ASIS^[19,20]. A 10% variation in branches was found in a study of 60 cadavers^[21]. De Geest *et al.*^[22] found a decreased incidence of LFCN injury by further lateralizing their incision. Blunt dissection through the subcutaneous fat is recommended to further minimize risk of nerve injury^[7]. Damage to the medial subcutaneous fat pad should be avoided to prevent injury to the trunk of the LFCN, which can result in meralgia paresthetica^[8].

The interval between the TFL and sartorius is entered by incising the fascia over the medial TFL muscle belly, retaining an adequate sleeve of tissue for closure and offering protection to the LFCN^[4,15,23]. Care should be taken to ensure the appropriate interval, as dissection through the lateral TFL and not in the intramuscular portal may result in damage to the motor branch of the superior gluteal nerve^[7]. If the exposure is too posterior, blood vessels will be seen entering the fascia and the fascia becomes denser as it overlies the gluteus medius, which should prompt recognition of the improper interval^[15]. Conversely, if the plane is developed too medially, dissection in to the femoral triangle will occur, risking injury to the femoral neurovascular bundle^[19]. Blunt dissection separates the TFL muscle belly from the fascia and facilitates entry into the interval for proper exposure of the hip capsule.

Hip exposure

A sharp retractor may be placed around the greater trochanter and the rectus femoris can be retracted medially with a rake or Hibbs retractor^[8]. The ascending branches of the LFCA usually lie in the distal portion of the approach, though can be somewhat variable in location and extent; these vessels should now be visualized and ligated with electrocautery or hand suture tie. Some surgeons have employed bipolar sealing technology

for the purposes of vessel coagulation and hemostasis throughout the procedure. The instrumentation is replaced with a curved retractor over the superior capsule to retract the TFL superiorly. A second cobra or Hohmann can be placed in a "soft spot" proximal to the vastus lateralis, on the medial of the neck to retract the rectus femoris and sartorius medially. Overzealous retraction should be avoided to minimize damage to the TFL and rectus, as well as to avoid neurovascular traction.

Specialized retractors with extra-depth blades and curved sides (Figure 3) are also available for minimally invasive surgery to facilitate gentle soft tissue handling^[19]. In muscular patients, the rectus femoris and TFL insertions near the ASIS may be elevated to facilitate exposure^[7]. A capsulotomy or capsulectomy of the anterior capsule have both been described. Some authors advocate removal of the capsule to facilitate exposure. However, retaining a medial portion may provide a sleeve of tissue between the iliopsoas tendon and acetabular rim to reduce irritation^[13,24,25]. Kennon *et al.*^[12] advised removal of a thick, contracted anterior capsule to prevent impingement possibly contributing to posterior dislocation. Positioning the operative leg in a figure-four position on a regular table can assist in release of the anterolateral and inferior capsule in the calcar region^[15,23]. Release of the superior capsule has been shown in a cadaveric study to be the most crucial in allowing elevation of the femur, which was not increased with release of the posterior capsule^[26]. Following capsular release, attention is then turned to the femoral neck and head.

The visible labrum and anterior osteophytes may be excised to assist in removal of the femoral head, but this is often not necessary. Medial and lateral retractors are repositioned within the capsule around the femoral neck. The head may be removed by performing a femoral neck cut and placing a corkscrew in the head, or by first excising a "napkin ring" section of the neck. Placement of a hip skid along the anterior acetabulum with a slightly distracted femoral head, *via* traction to the limb or instrumentation in the head, can facilitate head removal and transection of the ligamentum teres^[13,27]. Gentle

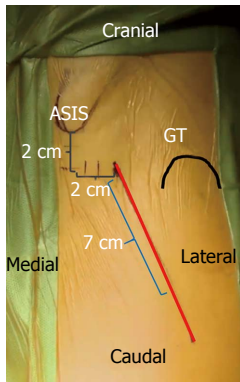


Figure 2 Surface anatomy for the direct anterior approach. A 6-8 cm oblique incision is typically used by the authors. This incision may be extended proximally and distally as needed along the Smith-Petersen interval for adequate femoral and acetabular exposure.

external rotation can help with dislocation. If not already done so, the femoral neck cut based on pre-operative planning is performed, with completion of the cut near the greater trochanter finished using an osteotome to reduce the risk of fracture by an oscillating saw.

Acetabulum

A sharp retractor may be inserted at the ventral acetabular rim, keeping the retractor immediately adjacent to the bone to avoid femoral nerve compression^[19]. Some surgeons use a light-mounted retractor in this position to improve visualization. Additional retractors are frequently placed at the posterior acetabulum and at the level of the transverse acetabular ligament. Remaining labrum and obstructing osteophytes are removed from the acetabulum, and reaming is commenced. Most surgeons performing this approach advocate use of specialized offset instruments. However, a straight reamer can be used with adequate exposure and careful attention to avoid leverage of the anterior acetabulum to prevent eccentric anterior reaming. Post *et al*^[3] also recommend positioning the reamer head first and then attaching the handle for challenging access. If performing the procedure in the lateral decubitus position, visualization of the anterior acetabulum is difficult and can complicate reaming and cup placement.

Assessing the native pelvis to assist proper cup positioning may be accomplished by palpating the anterior superior iliac spines^[19]. Although there is a tendency towards over-anteverting the cup with this approach by holding the cup positioner too vertical, an advantage of the supine DAA is the ability to utilize fluoroscopy intra-operatively^[19]. Many surgeons recommend reaming and cup placement using image guidance, particularly in initial adoption of the technique. A press-fit acetabular cup may be inserted with a target abduction angle of 35-45 degrees and anteversion of 10-20 degrees.

Of note, a study of fluoroscopy-guided anterior hip arthroplasty found an early higher rate of dislocation using a goal of 10-30 degrees of anteversion, which was improved by adjusting the target angle to 5-25

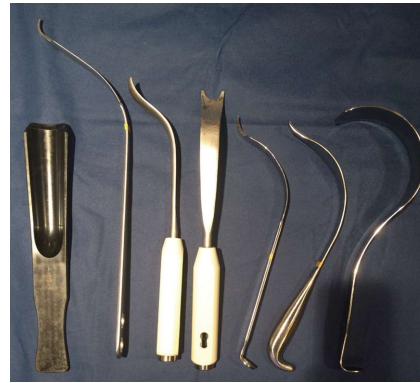

Figure 3 Selected retractors used for direct anterior approach. From left to right, hip skid for ceramic head reduction, greater trochanteric retractor/elevator, femoral elevator for medial/calcar exposure (front and side views), medial acetabular wall retractor, posterior acetabular wall retractor, and tensor fascia lata retractor.

degrees^[28]. Computer aided navigation has also been described to improve accuracy of cup placement. A study of computed tomography-based hip navigation comparing mini-anterior and mini-posterior found an accuracy of 2.0 degrees for abduction and 2.7 degrees for anteversion of cup placement with the anterior approach. Surface registration took one minute longer in the anterior approach but operative time was not significantly different^[29]. A review of 300 DAA hips, half performed with computer aided navigation, showed decreased operative times with navigation and greater accuracy of abduction angles^[30]. Following placement of the cup, an acetabular liner is inserted and acetabular retractors are removed.

Femur

The femur may be exposed on a fracture table by dropping the limb spar to the floor, with all traction removed, by a non-scrubbed assistant, along with external rotation and adduction of the limb. Adequate soft tissue capsular releases about the proximal femur should be performed prior to this maneuver. Matta *et al*^[27] utilized a scrubbed assistant to provide additional external rotation force at the femoral condyles using to reduce the stresses generated by the traction boots across the ankle, which can subject patients to iatrogenic ankle fracture. A retractor should be located at the calcar region, and a second retractor at the lateral greater trochanter during this maneuver. Release of the posterosuperior capsule will aid in clearance of the greater trochanter from behind the acetabular rim^[8].

Using a regular table, this exposure is performed by dropping the distal end of the table and by placing the bed in a Trendelenburg position, forming an inverted V-shape of the body for hyperextension at the hip. Trendelenburg positioning may alternatively be established at the onset of the case; however, patients undergoing general anesthesia may be at higher risk for gastrointestinal reflux^[13]. The contralateral leg may be placed on a mounted arm board or padded Mayo stand

to allow for adduction of the operative limb under the contralateral leg in a figure-of-four position on a regular table^[24]. For lateral decubitus positioning, the operative limb is abducted, hyperextended, externally rotated and flexed at the knee, with the foot positioned into a sterile bag posterior to the patient.

Elevation of the femur may be accomplished using a hydraulic lift hook or manual placement of a hook just distal to the vastus ridge around the posterior femur. Tension on the femur can be appreciated through tactile and visual feedback of the retractor behind the greater trochanter. In cases where the femur is unable to be appreciably exposed using these maneuvers, Moskal *et al*^[9] described sequential releases of soft tissue along the medial greater trochanter and femoral neck under tension, progressing through the release of hip capsule, piriformis, gemelli, and obturator internus. Posterior circumflex vessels should be identified and cauterized with these releases^[12]. The obturator externus provides hip stability through the most medial pull of the femur to the pelvis and should not be released unless necessary^[9]. Adequate entry to the femur should be verified with removal of interfering bone or tissue by rongeur or box cutter to prevent varus stem positioning^[13]. A high-speed burr may also be used as necessary.

Offset hand instruments may be preferred for broaching and stem placement. An alternative method to providing access utilizes a separate stab wound proximally in line with the femoral canal. This technique may be useful in large or muscular patients and for revision arthroplasty, and can prevent the need for extensive posterior releases^[12]. As femoral perforations are a known early complication of this approach, Post *et al*^[3] recommended identifying the trajectory of the canal through use of a guide wire on a T-handle. The femur is then broached and the trial component inserted. Reduction of the hip is performed by reversal of the steps utilized in exposing the femur. Fluoroscopy can be used to assess the adequacy of components, and a stability assessment is performed, emphasizing careful attention to extremes of external rotation and extension. Leg lengths may be compared directly on a regular table or by utilizing radiographic comparison to the contralateral limb with a fracture table^[13-15]. Final components are then placed in a similar fashion, and a final stability examination is performed.

Closure

The wound is thoroughly irrigated, and closure is performed according to surgeon preference. If capsulotomy was made, the flaps may be approximated. Hematoma prevention requires adequate hemostasis, as there is higher predilection for hematoma formation with less inherent gravity pressure over an anterior wound compared to other approaches. Furthermore, the risk for hematoma to track deeply exists as the only layer routinely closed is the tensor sheath^[31]. Suturing of the tensor fascia latae should be performed with care to avoid damage to the LFCN medially. The subcutaneous

tissue and skin are closed in a standard fashion. Many surgeons choose to leave a drain in place beneath the fascial layer; however, a study of 120 patients comparing drain utilization found that patients without drains had an earlier dry surgical site and were discharged from the hospital on average one day earlier. There was a non-significant trend toward high pain scores on post-operative day one, with increased thigh swelling on post-operative day two. There were no difference in transfusion requirements between the groups^[32].

CONCLUSION

All approaches to the hip have been shown to be safe and effective with proper training and meticulous technique. The DAA to the hip has gained significant popularity recently, and can be a valuable tool for hip replacement in most patients. This review examines the published variations of direct anterior THA, showing that several facets of the procedure can be tailored to a given surgeon's preference or the particular needs of the patient anatomy. Familiarity with the surgical anatomy and understanding the limitations of the anterior hip approach are key to successful execution. The growing desire for less invasive arthroplasty with improvement in functional results makes this approach an attractive choice for surgeons.

REFERENCES

- 1 **Rachbauer F**, Kain MS, Leunig M. The history of the anterior approach to the hip. *Orthop Clin North Am* 2009; **40**: 311-320 [PMID: 19576398 DOI: 10.1016/j.ocl.2009.02.007]
- 2 **Light TR**, Keggi KJ. Anterior approach to hip arthroplasty. *Clin Orthop Relat Res* 1980; (**152**): 255-260 [PMID: 7438611 DOI: 10.1097/00003086-198010000-00029]
- 3 **Post ZD**, Orozco F, Diaz-Ledezma C, Hozack WJ, Ong A. Direct Anterior Approach for Total Hip Arthroplasty: Indications, Technique, and Results. *J Am Acad Orthop Surg* 2014; **22**: 595-603 [PMID: 25157041 DOI: 10.5435/JAAOS-22-09-595]
- 4 **Kennon R**, Keggi J, Zatorski LE, Keggi KJ. Anterior approach for total hip arthroplasty: beyond the minimally invasive technique. *J Bone Joint Surg Am* 2004; **86-A** Suppl 2: 91-97 [PMID: 15691113]
- 5 **Mast NH**, Laude F. Revision total hip arthroplasty performed through the Hueter interval. *J Bone Joint Surg Am* 2011; **93** Suppl 2: 143-148 [PMID: 21543704 DOI: 10.2106/JBJS.J.01736]
- 6 **Unger AC**, Schulz AP, Paech A, Jürgens Ch, Renken FG. Modified direct anterior approach in minimally invasive hip hemiarthroplasty in a geriatric population: a feasibility study and description of the technique. *Arch Orthop Trauma Surg* 2013; **133**: 1509-1516 [PMID: 23979693 DOI: 10.1007/s00402-013-1831-5]
- 7 **Bal BS**, Vallurupalli S. Minimally invasive total hip arthroplasty with the anterior approach. *Indian J Orthop* 2008; **42**: 301-308 [PMID: 19753156 DOI: 10.4103/0019-5413.41853]
- 8 **Bender B**, Nogler M, Hozack WJ. Direct anterior approach for total hip arthroplasty. *Orthop Clin North Am* 2009; **40**: 321-328 [PMID: 19576399 DOI: 10.1016/j.ocl.2009.01.003]
- 9 **Moskal JT**, Capps SG, Scanelli JA. Anterior muscle sparing approach for total hip arthroplasty. *World J Orthop* 2013; **4**: 12-18 [PMID: 23362470 DOI: 10.5312/wjo.v4.i1.12]
- 10 **Barrett WP**, Turner SE, Leopold JP. Prospective randomized study of direct anterior vs postero-lateral approach for total hip arthroplasty. *J Arthroplasty* 2013; **28**: 1634-1638 [PMID:

- 23523485 DOI: 10.1016/j.arth.2013.01.034]
- 11 **Michel MC**, Witschger P. MicroHip: a minimally invasive procedure for total hip replacement surgery using a modified Smith-Peterson approach. *Ortop Traumatol Rehabil* 2007; **9**: 46-51 [PMID: 17514174]
- 12 **Kennon RE**, Keggi JM, Wetmore RS, Zatorski LE, Huo MH, Keggi KJ. Total hip arthroplasty through a minimally invasive anterior surgical approach. *J Bone Joint Surg Am* 2003; **85-A** Suppl 4: 39-48 [PMID: 14652392]
- 13 **Horne PH**, Olson SA. Direct anterior approach for total hip arthroplasty using the fracture table. *Curr Rev Musculoskelet Med* 2011; **4**: 139-145 [PMID: 21713379 DOI: 10.1007/s12178-011-9087-6]
- 14 **Alexandrov T**, Ahlmann ER, Menendez LR. Early clinical and radiographic results of minimally invasive anterior approach hip arthroplasty. *Adv Orthop* 2014; **2014**: 954208 [PMID: 24715984 DOI: 10.1155/2014/954208]
- 15 **Lovell TP**. Single-incision direct anterior approach for total hip arthroplasty using a standard operating table. *J Arthroplasty* 2008; **23**: 64-68 [PMID: 18922376 DOI: 10.1016/j.arth.2008.06.027]
- 16 **Grob K**, Monahan R, Gilbey H, Yap F, Filgueira L, Kuster M. Distal extension of the direct anterior approach to the hip poses risk to neurovascular structures: an anatomical study. *J Bone Joint Surg Am* 2015; **97**: 126-132 [PMID: 25609439 DOI: 10.2106/JBJS.N.00551]
- 17 **Alecci V**, Valente M, Crucil M, Minerva M, Pellegrino CM, Sabbadini DD. Comparison of primary total hip replacements performed with a direct anterior approach versus the standard lateral approach: perioperative findings. *J Orthop Traumatol* 2011; **12**: 123-129 [PMID: 21748384 DOI: 10.1007/s10195-011-0144-0]
- 18 **Seng BE**, Berend KR, Ajluni AF, Lombardi AV. Anterior-supine minimally invasive total hip arthroplasty: defining the learning curve. *Orthop Clin North Am* 2009; **40**: 343-350 [PMID: 19576401 DOI: 10.1016/j.ocl.2009.01.002]
- 19 **Barton C**, Kim PR. Complications of the direct anterior approach for total hip arthroplasty. *Orthop Clin North Am* 2009; **40**: 371-375 [PMID: 19576405 DOI: 10.1016/j.ocl.2009.04.004]
- 20 **Ropars M**, Morandi X, Hutten D, Thomazeau H, Berton E, Darnault P. Anatomical study of the lateral femoral cutaneous nerve with special reference to minimally invasive anterior approach for total hip replacement. *Surg Radiol Anat* 2009; **31**: 199-204 [PMID: 18982237 DOI: 10.1007/s00276-008-0433-3]
- 21 **Chen LH**, Huang QW, Wang WJ, He ZR, Ding WL. The applied anatomy of anterior approach for minimally invasive hip joint surgery. *Clin Anat* 2009; **22**: 250-255 [PMID: 19089989 DOI: 10.1002/ca.20750]
- 22 **De Geest T**, Vansintjan P, De Loore G. Direct anterior total hip arthroplasty: complications and early outcome in a series of 300 cases. *Acta Orthop Belg* 2013; **79**: 166-173 [PMID: 23821968]
- 23 **Leunig M**, Faas M, von Knoch F, Naal FD. Skin crease 'bikini' incision for anterior approach total hip arthroplasty: surgical technique and preliminary results. *Clin Orthop Relat Res* 2013; **471**: 2245-2252 [PMID: 23412730 DOI: 10.1007/s11999-013-2806-0]
- 24 **Berend KR**, Lombardi AV, Seng BE, Adams JB. Enhanced early outcomes with the anterior supine intermuscular approach in primary total hip arthroplasty. *J Bone Joint Surg Am* 2009; **91** Suppl 6: 107-120 [PMID: 19884418 DOI: 10.2106/JBJS.I.00525]
- 25 **Keggi KJ**, Huo MH, Zatorski LE. Anterior approach to total hip replacement: surgical technique and clinical results of our first one thousand cases using non-cemented prostheses. *Yale J Biol Med* 1993; **66**: 243-256 [PMID: 8209560]
- 26 **Matsuura M**, Ohashi H, Okamoto Y, Inori F, Okajima Y. Elevation of the femur in THA through a direct anterior approach: cadaver and clinical studies. *Clin Orthop Relat Res* 2010; **468**: 3201-3206 [PMID: 20405347 DOI: 10.1007/s11999-010-1349-x]
- 27 **Matta JM**, Shahrdar C, Ferguson T. Single-incision anterior approach for total hip arthroplasty on an orthopaedic table. *Clin Orthop Relat Res* 2005; **441**: 115-124 [PMID: 16330993 DOI: 10.1097/01.blo.0000194309.70518.cb]
- 28 **Rathod PA**, Bhalla S, Deshmukh AJ, Rodriguez JA. Does fluoroscopy with anterior hip arthroplasty decrease acetabular cup variability compared with a nonguided posterior approach? *Clin Orthop Relat Res* 2014; **472**: 1877-1885 [PMID: 24549773 DOI: 10.1007/s11999-014-3512-2]
- 29 **Hananouchi T**, Takao M, Nishii T, Miki H, Iwana D, Yoshikawa H, Sugano N. Comparison of navigation accuracy in THA between the mini-anterior and -posterior approaches. *Int J Med Robot* 2009; **5**: 20-25 [PMID: 19107818 DOI: 10.1002/rcs.226]
- 30 **Kreuzer S**, Leffers K. Direct anterior approach to total hip arthroplasty using computer navigation. *Bull NYU Hosp Jt Dis* 2011; **69** Suppl 1: S52-S55 [PMID: 22035486]
- 31 **Barton C**, Banga K, Beaulé PE. Anterior Hueter approach in the treatment of femoro-acetabular impingement: rationale and technique. *Orthop Clin North Am* 2009; **40**: 389-395 [PMID: 19576407 DOI: 10.1016/j.ocl.2009.03.002]
- 32 **Kleinert K**, Werner C, Mamisch-Saupe N, Kalberer F, Dora C. Closed suction drainage with or without re-transfusion of filtered shed blood does not offer advantages in primary non-cemented total hip replacement using a direct anterior approach. *Arch Orthop Trauma Surg* 2012; **132**: 131-136 [PMID: 21874574 DOI: 10.1007/s00402-011-1387-1]

P- Reviewer: Cui Q

S- Editor: Ji FF L- Editor: A E- Editor: Li D





Published by **Baishideng Publishing Group Inc**

8226 Regency Drive, Pleasanton, CA 94588, USA

Telephone: +1-925-223-8242

Fax: +1-925-223-8243

E-mail: bpgoffice@wjgnet.com

Help Desk: <http://www.wjgnet.com/esps/helpdesk.aspx>

<http://www.wjgnet.com>

