



## Diagnostic use of superb microvascular imaging in evaluating septic arthritis of the manubriosternal joint: A case report

Goda Seskute, Dominyka Kausaite, Ana Chalkovskaja, Egle Bulotaite, Irena Butrimiene

**Specialty type:** Rheumatology

**Provenance and peer review:**

Unsolicited article; Externally peer reviewed.

**Peer-review model:** Single blind

**Peer-review report's scientific quality classification**

Grade A (Excellent): 0  
Grade B (Very good): B, B  
Grade C (Good): 0  
Grade D (Fair): 0  
Grade E (Poor): 0

**P-Reviewer:** Mahmoud MZ, Saudi Arabia; Rezus E, Romania

**Received:** March 14, 2023

**Peer-review started:** March 14, 2023

**First decision:** April 19, 2023

**Revised:** April 28, 2023

**Accepted:** May 19, 2023

**Article in press:** May 19, 2023

**Published online:** June 26, 2023



**Goda Seskute, Dominyka Kausaite, Irena Butrimiene**, Clinic of Rheumatology, Orthopaedics Traumatology, and Reconstructive Surgery, Centre of Rheumatology, Institute of Clinical Medicine, Faculty of Medicine, Vilnius University, Vilnius 01513, Lithuania

**Ana Chalkovskaja**, Clinic of Internal Diseases, Family Medicine and Oncology, Institute of Clinical Medicine, Faculty of Medicine, Vilnius University, Vilnius 01513, Lithuania

**Egle Bulotaite**, Department of Radiology, Nuclear Medicine and Medical Physics, Institute of Biomedical Sciences, Faculty of Medicine, Vilnius University, Vilnius 01513, Lithuania

**Corresponding author:** Goda Seskute, MD, Academic Research, Doctor, Clinic of Rheumatology, Orthopaedics Traumatology, and Reconstructive Surgery, Centre of Rheumatology, Institute of Clinical Medicine, Faculty of Medicine, Vilnius University, Universiteto Street 3, Vilnius 01513, Lithuania. [goda.seskute@santa.lt](mailto:goda.seskute@santa.lt)

### Abstract

#### BACKGROUND

Septic arthritis of the manubriosternal joint is a diagnostic challenge due to its rarity and anatomical characteristic. Conventional ultrasound, plain radiographs, and computed tomography are not able to confirm or even suspect arthritis early. Superb microvascular imaging is a new advanced Doppler technique in evaluating low-flow microvascular patterns. The higher sensitivity for increased perisynovial vascularity helps to suspect septic arthritis and forms a methodical approach to using magnetic resonance imaging (MRI).

#### CASE SUMMARY

A 34-year-old immunocompetent woman presented with a fever and a dull ache in the chest radiating to the right arm. Traumatic injury and the most common respiratory and cardiac disorders were ruled out. Blood cultures came back positive for *Staphylococcus aureus*, and sepsis was confirmed. A small lump was noted on the chest during the first week of hospitalization. Superb microvascular imaging was performed and septic arthritis of the manubriosternal joint was detected. MRI confirmed the diagnosis and showed septic arthritis of the manubriosternal joint with several localized abscesses behind the sternum. The patient was treated for three weeks with intravenous antibiotics and the outcome was favorable: Inflammatory markers became normal, and the lump disappeared. Three months later, the patient was examined for a new episode of mild pain in the sternum and was diagnosed with persistent perichondritis by ultrasound in comparison with MRI.

## CONCLUSION

Superb microvascular imaging is a useful tool for the early diagnosis of septic arthritis of the manubriosternal joint and following-up.

**Key Words:** Power Doppler; Superb microvascular imaging; Ultrasound; Septic arthritis; Manubriosternal joint; Case report

©The Author(s) 2023. Published by Baishideng Publishing Group Inc. All rights reserved.

**Core Tip:** Septic arthritis is a diagnostic challenge and requires a methodical approach. The atypical course and rarity of septic arthritis of the manubriosternal joint are due to its anatomy (symphysis): The cartilaginous joint does not have a typical synovial lined capsule. Radiological imaging plays the most important role in the diagnosis. Chest X-ray and computed tomography is the least specific in the early stages. Superb microvascular imaging allows for clearer detection of synovial hypertrophy and slow flow vascularity at the early and late stages of the disease than power Doppler. Magnetic resonance imaging helps to exclude abscesses in cases with high inflammatory markers or sepsis.

**Citation:** Seskute G, Kausaite D, Chalkovskaja A, Bulotaite E, Butrimiene I. Diagnostic use of superb microvascular imaging in evaluating septic arthritis of the manubriosternal joint: A case report. *World J Clin Cases* 2023; 11(18): 4397-4405

**URL:** <https://www.wjgnet.com/2307-8960/full/v11/i18/4397.htm>

**DOI:** <https://dx.doi.org/10.12998/wjcc.v11.i18.4397>

## INTRODUCTION

Septic arthritis is a severe, life-threatening condition that is still a diagnostic challenge due to its unpredictable, acute onset and course. The incidence of septic arthritis is low, with only 4-10 new cases per 10000 population in Europe[1]. Septic arthritis of the manubriosternal (MS) joint is a rare pathology, with only thirteen cases identified in literature since 1985[2]. All of these cases could be classified into one of three groups: primary with risk factors[3-6], secondary due to other diseases[7-11], and completely idiopathic in immunocompetent patients[12-14]. Accurate and early diagnosis can be challenging and requires a methodic approach with various diagnostic measures. Early diagnosis and treatment can circumvent the need for surgical intervention. Sternal radiographs and/or computed tomography (CT) scans are the first usually performed tests, but the least sensitive in the early stages[6, 7,8-11,13,14]. Also, it is often mistaken for another disease process such as cardiac or pulmonary causes of chest pain and a lot of other tests are performed in parallel[4,10,13]. Due to wide differential diagnosis, magnetic resonance imaging (MRI) performing is commonly delayed[4,5,10,13]. Also, the use of MRI is often prohibited because of its high cost and limited availability. There is only one case that demonstrates the value of ultrasound for evaluating septic arthritis of the MS joint with massive effusion by B mode, but at the early stage of the disease[12].

Ultrasound imaging is increasingly effective in the diagnosis of musculoskeletal conditions when done by an experienced operator. It has many advantages including real-time and cross-sectional imaging with excellent spatial resolution. Compared to MRI, ultrasound assesses joint effusion, the severity of the Doppler-positive synovitis, and the presence of bone and cartilage damage or irregularity in the joint. Conventional Doppler techniques have limitations in detecting low-velocity blood flow[15]. Superb microvascular imaging (SMI) is a new Doppler technique that suppresses the noise caused by motion artifacts with an innovative filter system without removing the weak signal arising from small vessel blood flow, thus achieving a greater sensitivity than power Doppler (PD)[16,17]. SMI presents two modes: Color (cSMI, which demonstrates B-mode and color information simultaneously) and monochrome (mSMI, which focuses only on the vasculature). Growing evidence indicates that SMI imaging could provide a non-invasive and lower-cost tool for the assessment of inflammatory arthritides. There is limited data available on the use of SMI in evaluating septic arthritis.

Following is a case presentation of a young, previously healthy woman with severe chest pain without any clinical signs of arthritis. The role of SMI in the early diagnosis and follow-up of the patient is discussed.

## CASE PRESENTATION

### **Chief complaints**

In July 2021, a 34-year-old woman came to the emergency department with a five-day history of fever and a dull ache in the chest radiating to the right arm.

### **History of present illness**

She visited her family doctor one week before because the ache in the chest was given a visual analogue scale score of 9-10 and gradually worsened. There was no redness or irregularity in the skin of the chest area. Blood tests were normal. She was given nonsteroidal anti-inflammatory drugs and opioids for pain relief, but the condition did not improve, therefore she came to our hospital for emergency treatment.

### **History of past illness**

There is no relevant history of past illness, intravenous drug abuse, inflammatory joint alterations, trauma, and spreading from a source of infection (dental, skin areas).

### **Personal and family history**

The patient was a non-smoker. She claimed to have no allergies to food or medicines, no operations were performed. The patient denied any family history of arthritis.

### **Physical examination**

Body mass index - 22.4 kg/m<sup>2</sup>. The vital signs were as follows: Body temperature - 36.9°C; blood pressure - 98/60 mmHg; heart rate - 100 beats per minute; respiratory rate - 19 breaths per min. During palpation, there were no swollen or painful lumps and lymph nodes in the typical axilla, neck, or groin areas; the chest was painless.

### **Laboratory examinations**

Primary laboratory tests showed significantly increased inflammatory markers: C-reactive protein (CRP) 256.0 mg/L (Ref ≤ 5 mg/L), leukocytosis white blood cells (WBCs) -  $14.20 \times 10^9$ /L (Ref from  $4.5$  to  $11.0 \times 10^9$ /L); elevated procalcitonin 0.69 µg/L (Ref < 0.1 ng/mL) and liver enzymes: Aspartate aminotransferase - 239 U/L (Ref ≤ 40), alanine aminotransferase - 334 U/L (Ref ≤ 40); normal troponin - 0 ng/L (Ref ≤ 16), and elevated D-dimers 1725 µg/L (Ref < 250 µg/L). No abnormality was found in urine analyses.

### **Imaging examinations**

The electrocardiogram showed only sinus tachycardia - 103 bpm. Pulmonary embolism, aortic aneurysm, pneumonia, pneumothorax, and even rib fracture were suspected. Thoracic CT angiography, non-contrast chest CT, and X-ray of the thoracic spine, ribs, and sternum were performed, as well as diagnostic ultrasound with PD (by an abdominal sonographer) of the soft tissues at the sternum, but no pathology was detected.

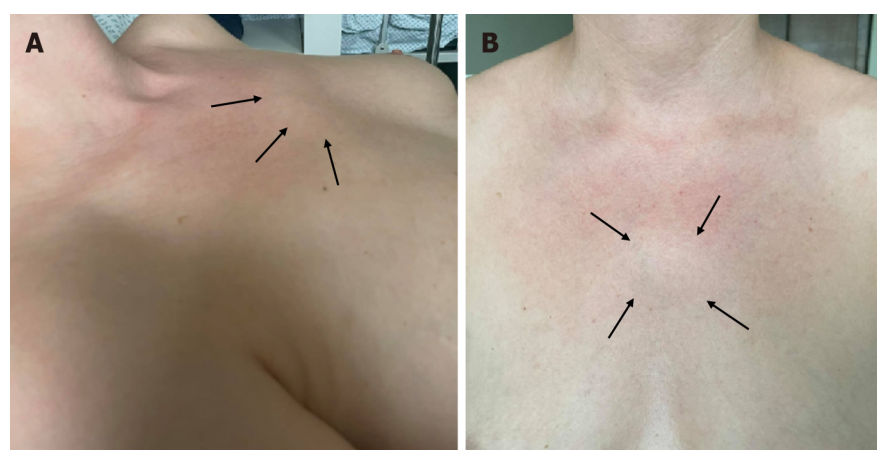
## PRIMARY DIAGNOSIS AND TREATMENT

The patient was hospitalized and an empiric course of intravenous antibiotic treatment (amoxicillin/clavulanic acid 1.2 g, q.i.d) was prescribed. During the second day of hospitalization, the blood culture showed growth of methicillin-susceptible *Staphylococcus aureus*, and sensitivity for empiric treatment was confirmed.

The patient was diagnosed with sepsis (fever, tachycardia, and leukocytosis), though the cause was unknown.

## FURTHER DIAGNOSTIC WORK-UP

During the third day of hospitalization, the patient experienced numbness on the left side of the face and began to feel dizzy. She felt a small and painless lump in the MS joint region with overlying erythema (Figure 1A and B). The pain in the chest progressed. She was consulted by a neurologist, who recommended CT angiography of the head to detect any ischemic changes due to venous sinus thrombosis or carotid artery dissection. However, the CT angiography was normal and the dizziness disappeared the next day. Serological testing for human immunodeficiency virus and hepatitis (B, and C virus) was negative. Infective endocarditis was ruled out by a transthoracic echocardiogram at the end of the first week of hospitalization. No other findings in the transthoracic echocardiogram were detected. The first soft tissue diagnostic - ultrasound in the sternum did not show any changes, but it



DOI: 10.12998/wjcc.v11.i18.4397 Copyright ©The Author(s) 2023.

**Figure 1** Physical examination of the sternum (manubriosternal joint) region. A: Lateral; B: Frontal views; A and B: Reddish, slightly protruding, small, painless 3 cm × 3 cm lump in the projection of the sternum (arrows).

was repeated five days later by a rheumatologist, and active MS joint arthritis was detected (Figure 2A, C and E). The pseudo-capsular layer formed by surrounded ligaments and soft tissues became separated from the irregular bone surface by intra-articular effusion and synovial hypertrophy with remarkable PD signals suggestive of active MS arthritis (Figure 2A). Colour SMI modes show higher vascularity (Figure 2C), and monochrome SMI focuses only on the vasculature, excluding artifacts (Figure 2E). A joint puncture was not performed due to minor fluid accumulation (approximately 3 mm × 0.6 mm in size).

Axial post-gadolinium contrast-enhanced sternal MRI was performed to rule out mediastinitis and showed signs of sternal arthritis with localized abscesses up to 12 mm × 4 mm × 44 mm in front of the left first rib and up to 8 mm × 5 mm × 18 mm in the MS joint (Figure 3A, C and E). After 10 days of antibiotic treatment, the patient's condition improved, with significantly less chest pain and decreased inflammatory markers (CRP 8.77 mg/L). The repeated blood cultures were negative.

## FINAL DIAGNOSIS

We diagnosed the patient with MS septic arthritis complicated by an abscess and sepsis.

## TREATMENT

She was advised to continue amoxicillin/clavulanic acid perorally for two weeks after hospitalization.

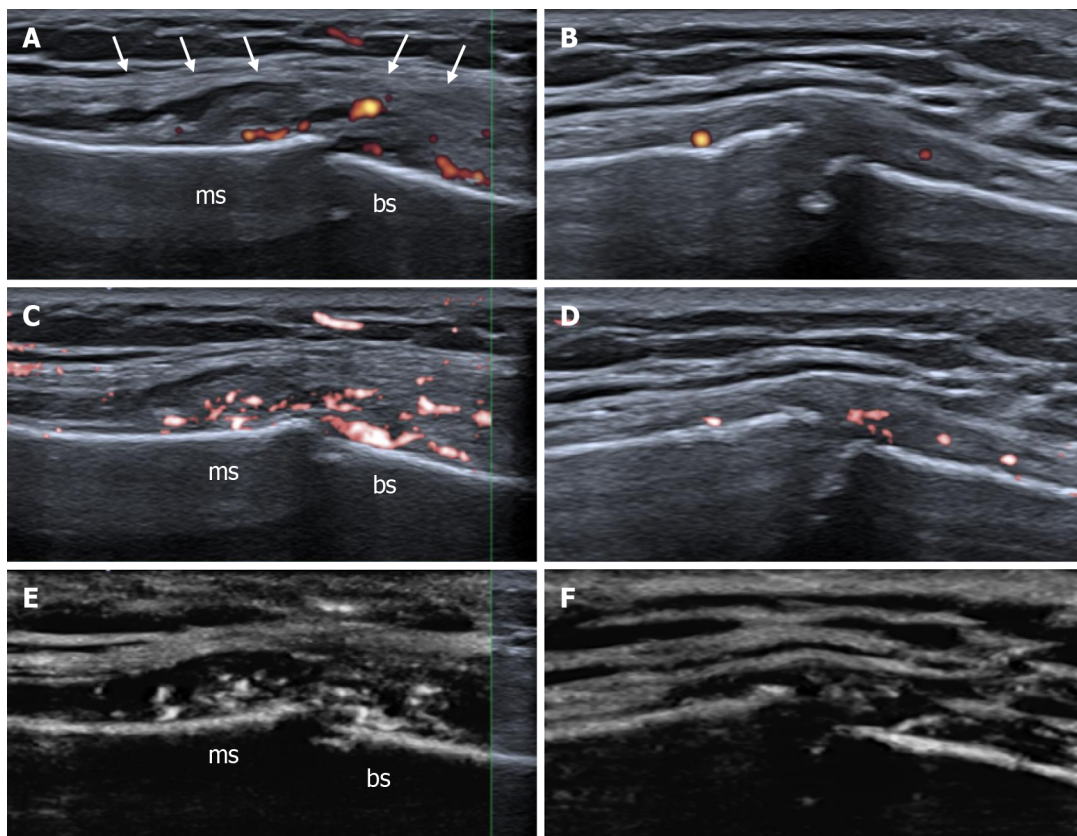
## OUTCOME AND FOLLOW-UP

Three months later, the patient began feeling mild pain in the MS region. During the physical examination, no objective signs of relapse were observed. X-ray of the sternum showed perichondritis and ultrasound imaging detected mild and residual joint synovial hypertrophy with vascularity and more eroded MS joint margins (Figure 2B, D and F). MRI showed positive dynamics (Figure 3B, D and F) with no signs of abscesses and confirmed ultrasound results because mild perichondritis with mild bone marrow was detected. Inflammatory markers were normal (CRP - 3.69 mg/L, WBCs -  $7.81 \times 10^9$ /L). A decision was taken to prescribe a three-week course of antibiotics (doxycycline 100 mg b.i.d) to avoid the relapsing course of arthritis.

## DISCUSSION

Septic arthritis usually presents with acute onset monoarticular joint pain and swelling, but in the present case, arthritis began without any objectively classical signs. The atypical course and rarity of septic arthritis in the MS joint are due to its anatomy: Being a symphysis, the rates of septic arthritis are massively lower than in synovial joints[18]. The joint does not have a capsule and is not attached by any





DOI: 10.12998/wjcc.v11.i18.4397 Copyright ©The Author(s) 2023.

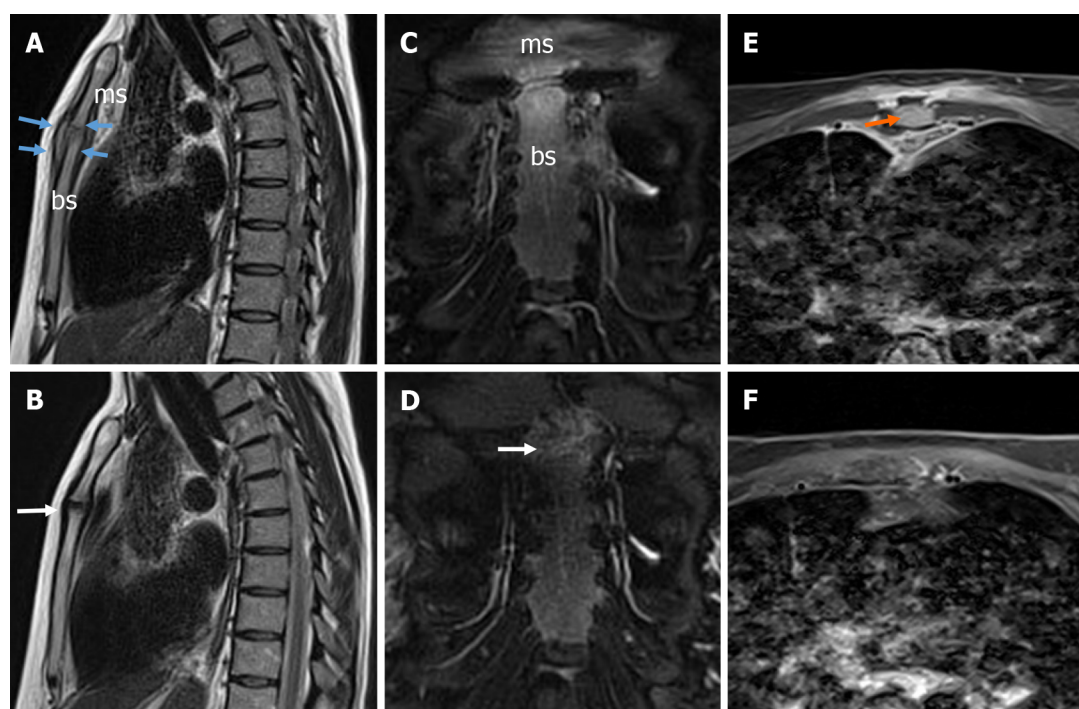
**Figure 2 High-resolution ultrasound images with superb microvascular imaging of the manubriosternal joint, longitudinal views.** A: The pseudo-capsular layer is separated by intra-articular effusion and synovial hypertrophy (white arrows) with remarkable power Doppler signals; B: Four-month follow-up by power Doppler; C: Color superb microvascular imaging (SMI) visualizes slow flow vascularity more sensitive than conventional power Doppler. Active synovial inflammation with subsequent effusion formation allows suspecting of septic arthritis; D: Four-month follow-up by color SMI; E: Monochrome SMI helps to catch the eye and highlights true flow signals of small vessels in the grey map. F: Four-month follow-up by monochrome SMI. There is still mild peri- and intra-articular vascularity or arthritis and more eroded joint margins. A diagnostic ultrasound system (CANON TUS-AI800, Canon medical systems corp, Shimoishigami, Otawara-shi, Japan) equipped with a linear transducer with the following settings (14 MHz frequency) was used; ms: Manubrium of the sternum; bs: Body of the sternum.

ligaments[19]. Sometimes, this joint is mistakenly described as a capsulated joint, which is anatomically incorrect. The pectoralis major and pectoralis fascia originate from the anterior surface of the sternum, and therefore, include the sternal angle[20]. It forms a pseudo capsule because it is separated from the irregular bone surface by intra-articular synovial hypertrophy and/or inflammatory fluid retention, as well as effusion. This explanation reveals the causes of mild and atypical clinical manifestations of arthritis.

Because of the rarity of this condition, little is known about its pathogenesis, and there are many possible causes. MS joint arthritis is common in healthy males with an average age of 44 and risk factors such as sports like rugby or working as a disc jockey[5,12]. Septic arthritis of the MS joint in an immunocompetent patient without any suspicion of trauma is a very rare phenomenon and there is only one published case[13]. Other causes that are written up are intravenous drug use and systemic lupus erythematosus[2,3,8]. Our patient was immunocompetent without any risk factors. The wide differential diagnosis of acute pain in the chest often delays clear diagnosis[21].

History and clinical examination findings alone have been found to be poorly sensitive for the diagnosis of acute septic arthritis[22]. Radiological imaging plays the most important role in the diagnosis of MS arthritis. Chest X-ray is the least specific in the early stages. CT scans are more likely to be positive at an advanced stage. Our case demonstrates the value of CT in the early stage of arthritis: only mild marginal erosions could be suspected and depend on the radiologist's accuracy. The findings were too mild to consider as a reason for strong pain in the chest. Ultrasound can detect early changes and be used to guide joint aspiration procedures but is often unsuccessful due to the paucity of fluid in the small MS joint[23]. Ultrasound is a cheaper, quicker, and more easily accessible tool for early diagnosis than MRI or CT.

Although ultrasound imaging of septic arthritis cannot be used as an absolute diagnostic modality, it enables early identification of both intra-articular and extra-articular abnormalities before significant cartilage lysis occurs. Ultrasound imaging or greyscale ultrasound of an intra-articular anechoic effusion of multiple internal echoes with distention of the joint capsule is highly suggestive of septic arthritis of the synovial joints[24,25]. The thickness of the synovia and the joint capsule is not specific to septic



DOI: 10.12998/wjcc.v11.i18.4397 Copyright ©The Author(s) 2023.

**Figure 3 Magnetic resonance imaging of the septic manubriosternal joint.** A: Magnetic resonance imaging (MRI) sagittal T2-weighted blade image. The surfaces of the manubriosternal (MS) joint are eroded in the margins, the joint is enlarged, and the pseudo-capsule is thickened (blue arrows), with visible arthritis; B: MRI sagittal T2-weighted blade image. Four-month follow-up results - the surfaces of the MS joint are further eroded in the margins, perichondritis (white arrow). The pseudo-capsule is thinned; C: MRI coronal T2-weighted blade fat-suppressed image. A mild bone marrow edema is detected; D: MRI coronal T2-weighted blade fat-suppressed image. Four-month follow-up results - a very mild bone marrow edema was detected (white arrow); E: MRI axial contrast-enhanced T1-weighted Dixon water-only image. Localized fluid collection (abscess) up to 12 mm × 4 mm × 44 mm in front of the left first rib was detected without any sign of mediastinitis (orange arrow); F: MRI axial contrast-enhanced T1-weighted Dixon water-only image. Abscesses were not detected; ms: Manubrium of the sternum; bs: Body of the sternum.

arthritis, but intra-articular synovial hypertrophy with remarkable PD signals suggests acute active synovitis[26,27]. Hypoechoogenicity of surrounding muscles with loss of normal muscular fibrillar pattern could be suggestive of early muscle affection[25]. The early appearance of bone erosion of the joint suggests that arthritis is suppurative[27]. To sum up, ultrasound findings such as joint effusion, intra-articular synovial hypertrophy with remarkable PD signals, and irregularity of the bony margins may support the clinical suspicion of infection[24-27].

Apart from the MS joint, there are more symphyses such as pubic, intervertebral, sacrococcygeal, mentalis, and xiphisternal. The pubic symphysis is readily visualized with ultrasound, yet the sonographic findings of septic arthritis in the joint have not been documented[28]. Septic arthritis of the pubic symphysis is mostly suspected or diagnosed by CT or MRI scans of the pelvis. Pelvic radiographs are relatively insensitive for the diagnosis of septic arthritis and osteomyelitis of the symphysis pubis, especially early in the course of the disease[29]. The lack of experience in the evaluation of symphyses by ultrasound could be explained by the rarity, atypical course of the disease, and mimicry of other diseases.

SMI allows for clearer detection of synovial hypertrophy and active vascularity at an early stage of the disease than conventional PD. All possible ultrasound changes according to the literature[1,12,24-27], our own experience, and this case data are summarised in Table 1 (we recommend additional studies to determine the sensitivity and specificity of SMI in diagnosing septic arthritis). At the early stage of confirming a diagnosis, vascularity needs to be checked by an experienced musculoskeletal sonographer. MRI plays the most important role in excluding abscesses connected to the joint, especially when high inflammatory markers are found. As our case showed, MRI helps to exclude complications of arthritis and must be performed in cases with sepsis or high inflammatory markers.

Regarding management, in the early stages of the disease, empiric administration (mostly penicillins according to the literature[13] or a combination[12]) of intravenous antibiotics is the mainstay until the response of blood or synovial fluid cultures. Intravenous antibiotics with joint drainage are indicated for more than 60% of cases[30]. Synovial thickening, cellulitis, and bone edema may persist even after the eradication of the infection[30]. After three months we performed an ultrasound with MRI due to the risk of a persistent abscess. Both investigations confirmed late erosions in the joint margins and mild arthritis. However, if the MRI at the early stage did not detect an abscess, then ultrasound imaging in combination with a chest X-ray could be sufficient for the follow-up, therefore more studies are needed.

**Table 1** Ultrasound findings for septic arthritis of the manubriosternal joint according to the course of the disease

	Disease course		
	Early - acute	Subacute	Chronic residual
Effusion	+++	+++	-/+
Synovial thickening	+	+++	+ / ++
Active vascularity:			
PD	-/+	++	-/+
SMI	++	+++	+ / ++
Bone erosions	-/+	++ / +++	+++

+++ high; ++ medium; + mild; - not detected.

PD: Power Doppler; SMI: Superb microvascular imaging.

The case demonstrates the role of a wide spectrum of radiological tests in evaluating rare pathology - septic arthritis of the manubriosternal joint and the use of advanced ultrasound for follow-up persistent changes. Furthermore, ultrasound findings of septic arthritis of the manubriosternal joint are analyzed in detail in all stages of the disease. There is a lack of information in the literature about the management of septic arthritis of symphysis by ultrasound, the best choice of investigation in the differential diagnosis from early to late disease course and follow-up of these patients. Ultrasound provides the clinician with tools to promptly manage such a case, especially when more costly methods are not available. There is a task to accrue more data on ultrasound use for practical application in septic arthritis generally and purulent process in symphyses.

## CONCLUSION

SMI in comparison with other radiological tests demonstrates the diagnostic usefulness for the early diagnosis and follow-up monitoring of patients with septic arthritis of the MS joint, especially in the subclinical case at the beginning of the disease, and for screening in the late course. It provides objective findings that assist a clinician in making a time-sensitive diagnosis.

## ACKNOWLEDGEMENTS

Authors would like to thank the patient and Vilnius University Hospital Santaros Clinics for giving informed consent and providing the images for this article.

## FOOTNOTES

**Author contributions:** Seskute G performed ultrasound investigations; Seskute G, Kausaite D, and Chalkovskaja A analyzed images, reviewed the literature, and wrote the original manuscript; Bulotaite E prepared and commented on magnetic resonance imaging and computed tomography views, and drafted the article; Butrimiene I was responsible for conceiving and revising the manuscript for the important intellectual content; all authors approved the final version of the manuscript and agreed to be accountable for all aspects of the work if questions arise related to its accuracy or integrity.

**Informed consent statement:** Informed written consent was obtained from the patient for publication of this report and any accompanying images.

**Conflict-of-interest statement:** The authors declare that they have no conflict of interest to disclose.

**CARE Checklist (2016) statement:** The authors have read the CARE Checklist (2016), and the manuscript was prepared and revised according to the CARE Checklist (2016).

**Open-Access:** This article is an open-access article that was selected by an in-house editor and fully peer-reviewed by external reviewers. It is distributed in accordance with the Creative Commons Attribution NonCommercial (CC BY-NC 4.0) license, which permits others to distribute, remix, adapt, build upon this work non-commercially, and license their derivative works on different terms, provided the original work is properly cited and the use is non-



commercial. See: <https://creativecommons.org/licenses/by-nc/4.0/>

**Country/Territory of origin:** Lithuania

**ORCID number:** Goda Seskute 0000-0003-4830-1497; Dominyka Kausaite 0000-0002-4914-2419; Ana Chalkovskaja 0000-0003-4424-4456; Egle Bulotaite 0000-0001-7781-2865; Irena Butrimiene 0000-0002-3795-7741.

**Corresponding Author's Membership in Professional Societies:** EMEUNET; Lithuanian Rheumatologists Association.

**S-Editor:** Ma YJ

**L-Editor:** A

**P-Editor:** Ma YJ

## REFERENCES

- 1 **Gaigneux E**, Cormier G, Varin S, Mérot O, Maugars Y, Le Goff B. Ultrasound abnormalities in septic arthritis are associated with functional outcomes. *Joint Bone Spine* 2017; **84**: 599-604 [PMID: 28219656 DOI: 10.1016/j.jbspin.2017.02.002]
- 2 **Gruber BL**, Kaufman LD, Gorevic PD. Septic arthritis involving the manubriosternal joint. *J Rheumatol* 1985; **12**: 803-804 [PMID: 4057206]
- 3 **López-Longo FJ**, Monteagudo I, Vaquero FJ, Martínez Moreno JL, Carreño L. Primary septic arthritis of the manubriosternal joint in a heroin user. *Clin Orthop Relat Res* 1986; 230-231 [PMID: 3955954]
- 4 **Sinha S**, Sinha A, Nagarajah K, Oei EL, Critchley P, McNally MA. Chronic sternal osteomyelitis complicating primary manubriosternal septic arthritis. *Clin Rheumatol* 2006; **25**: 934-936 [PMID: 16328095 DOI: 10.1007/s10067-005-0101-5]
- 5 **Peng EW**, McKillop G, Prasad S, Walker WS. Septic arthritis of the manubriosternal joint. *Ann Thorac Surg* 2007; **83**: 1190-1194 [PMID: 17307494 DOI: 10.1016/j.athoracsur.2006.07.032]
- 6 **Nwaejike N**, Unsworth-White MJ. Manubriosternal subluxation/dislocation can lead to manubriosternal septic arthritis in patients with kyphoscoliosis. *Ann R Coll Surg Engl* 2010; **92**: W35-W37 [PMID: 20353634 DOI: 10.1308/147870810X476755]
- 7 **Van Linthoudt D**, De Torrente A, Humair L, Ott H. Septic manubriosternal arthritis in a patient with Reiter's disease. *Clin Rheumatol* 1987; **6**: 293-295 [PMID: 3621849 DOI: 10.1007/BF02201043]
- 8 **Kruper LL**, Low DW, Bucky LP. Immediate pectoralis flap closure following septic arthritis of the manubriosternal joint. *Plast Reconstr Surg* 2001; **107**: 997-999 [PMID: 11252094 DOI: 10.1097/00006534-200104010-00014]
- 9 **Patel P**, Gray RR. Tuberculous osteomyelitis/arthritis of the first costo-clavicular joint and sternum. *World J Radiol* 2014; **6**: 928-931 [PMID: 25550999 DOI: 10.4329/wjr.v6.i12.928]
- 10 **Zaheen A**, Siemieniuk RA, Gudgeon P. An atypical cause of atypical chest pain. *Can J Infect Dis Med Microbiol* 2014; **25**: 253-254 [PMID: 25371686 DOI: 10.1155/2014/515169]
- 11 **Gorospe L**, Ayala-Carbonero AM, Rodríguez-Díaz R, García Latorre R, Muñoz-Molina GM, Cabañero-Sánchez A. Tuberculosis of the manubriosternal joint and concurrent asymptomatic active pulmonary tuberculosis in a patient presenting with a chest wall mass. *Clin Imaging* 2015; **39**: 311-314 [PMID: 25457526 DOI: 10.1016/j.clinimag.2014.08.006]
- 12 **Carnevale A**, Righi R, Maniscalco P, Labaj O, Occhionorelli S, Benea G, Giganti M. Primary septic arthritis of the manubriosternal joint in an immunocompetent young patient: A case report. *Radiol Case Rep* 2017; **12**: 682-685 [PMID: 29484048 DOI: 10.1016/j.radcr.2017.08.006]
- 13 **O'Connor A**, Furtado S. Septic arthritis of the manubriosternal joint presenting as a chest-wall swelling in an immunocompetent patient. *J Surg Case Rep* 2019; **2019**: rjz261 [PMID: 31749956 DOI: 10.1093/jscr/rjz261]
- 14 **Honda H**, Yaita K. Suppurative Arthritis of the Manubriosternal Joint. *Intern Med* 2019; **58**: 2903 [PMID: 31178513 DOI: 10.2169/internalmedicine.2839-19]
- 15 **Park AY**, Seo BK. Up-to-date Doppler techniques for breast tumor vascularity: superb microvascular imaging and contrast-enhanced ultrasound. *Ultrasonography* 2018; **37**: 98-106 [PMID: 29025210 DOI: 10.14366/uscg.17043]
- 16 **Hata J**. Seeing the Unseen New Techniques in Vascular Imaging. *Med Rev* 2014; 1-8
- 17 **Fu Z**, Zhang J, Lu Y, Wang S, Mo X, He Y, Wang C, Chen H. Clinical Applications of Superb Microvascular Imaging in the Superficial Tissues and Organs: A Systematic Review. *Acad Radiol* 2021; **28**: 694-703 [PMID: 32418782 DOI: 10.1016/j.acra.2020.03.032]
- 18 **Ross JJ**, Shamsuddin H. Sternoclavicular septic arthritis: review of 180 cases. *Medicine (Baltimore)* 2004; **83**: 139-148 [PMID: 15118542 DOI: 10.1097/01.md.0000126761.83417.29]
- 19 **Monkhouse WS**. Last's Anatomy, Regional and Applied. 10th ed. Sinnatamby C, editor. Edinburgh: Churchill Livingstone. 1999: 539
- 20 **Gray Henry T**, Pickering P, Robert H. Anatomy, descriptive and surgical. 39th ed. New York: Bounty Books, 1977
- 21 **Long B**, Koefman A, Gottlieb M. Evaluation and Management of Septic Arthritis and its Mimics in the Emergency Department. *West J Emerg Med* 2019; **20**: 331-341 [PMID: 30881554 DOI: 10.5811/westjem.2018.10.40974]
- 22 **Carpenter CR**, Schuur JD, Everett WW, Pines JM. Evidence-based diagnostics: adult septic arthritis. *Acad Emerg Med* 2011; **18**: 781-796 [PMID: 21843213 DOI: 10.1111/j.1553-2712.2011.01121.x]
- 23 **Womack J**. Septic arthritis of the sternoclavicular joint. *J Am Board Fam Med* 2012; **25**: 908-912 [PMID: 23136331 DOI: 10.3122/jabfm.2012.06.110196]
- 24 **Kim S**, Baradia H, Sambasivan A. The Use of Ultrasonography in Expediting Septic Joint Identification and Treatment: A



- Case Report. *Am J Phys Med Rehabil* 2020; **99**: 449-451 [PMID: 31361617 DOI: 10.1097/PHM.0000000000001284]
- 25 **Manar AB**, Hanan AH, Wesam AM. Role of high resolution ultrasonography in diagnosing septic hip arthritis in premature neonates admitted to the neonatal intensive care unit. *Egypt J Radiology Nucl Med* 2017; **48**: 971-975 [DOI: 10.1016/j.ejrm.2017.06.003]
  - 26 **Mnif J**, Khannous M, Keskes H, Louati N, Damak J, Kechaou MS. [Ultrasonography in the diagnostic approach of septic arthritis]. *Rev Chir Orthop Reparatrice Appar Mot* 1997; **83**: 148-155 [PMID: 9231182]
  - 27 **Kawashiri SY**, Edo Y, Kawakami A. Early Detection of Inflammation and Joint Destruction Revealed by Ultrasound in a Patient with Sternoclavicular Septic Arthritis. *Intern Med* 2019; **58**: 865-869 [PMID: 30449803 DOI: 10.2169/internalmedicine.1782-18]
  - 28 **Becker I**, Stringer MD, Jeffery R, Woodley SJ. Sonographic anatomy of the pubic symphysis in healthy nulliparous women. *Clin Anat* 2014; **27**: 1058-1067 [PMID: 24904004 DOI: 10.1002/ca.22423]
  - 29 **Ross JJ**, Hu LT. Septic arthritis of the pubic symphysis: review of 100 cases. *Medicine (Baltimore)* 2003; **82**: 340-345 [PMID: 14530783 DOI: 10.1097/01.md.0000091180.93122.1c]
  - 30 **Bierry G**, Huang AJ, Chang CY, Torriani M, Bredella MA. MRI findings of treated bacterial septic arthritis. *Skeletal Radiol* 2012; **41**: 1509-1516 [PMID: 22430565 DOI: 10.1007/s00256-012-1397-2]



Published by **Baishideng Publishing Group Inc**  
7041 Koll Center Parkway, Suite 160, Pleasanton, CA 94566, USA

**Telephone:** +1-925-3991568

**E-mail:** [bpgoffice@wjgnet.com](mailto:bpgoffice@wjgnet.com)

**Help Desk:** <https://www.f6publishing.com/helpdesk>

<https://www.wjgnet.com>

