

# World Journal of *Clinical Cases*

*World J Clin Cases* 2021 October 16; 9(29): 8627-8952



## Contents

Thrice Monthly Volume 9 Number 29 October 16, 2021

## REVIEW

- 8627 Time to give up traditional methods for the management of gastrointestinal neuroendocrine tumours  
*Yozgat A, Kekilli M, Altay M*

## MINIREVIEWS

- 8647 Healthcare practice strategies for integrating personalized medicine: Management of COVID-19  
*Liu WY, Chien CW, Tung TH*
- 8658 Clinical application of repetitive transcranial magnetic stimulation for post-traumatic stress disorder: A literature review  
*Cheng P, Zhou Y, Xu LZ, Chen YF, Hu RL, Zou YL, Li ZX, Zhang L, Shun Q, Yu X, Li LJ, Li WH*
- 8666 Pros and cons of continuous glucose monitoring in the intensive care unit  
*Sun MT, Li IC, Lin WS, Lin GM*

## ORIGINAL ARTICLE

## Clinical and Translational Research

- 8671 Prognostic implications of ferroptosis-associated gene signature in colon adenocarcinoma  
*Miao YD, Kou ZY, Wang JT, Mi DH*

## Retrospective Study

- 8694 Cefoperazone sodium/sulbactam sodium *vs* piperacillin sodium/tazobactam sodium for treatment of respiratory tract infection in elderly patients  
*Wang XX, Ma CT, Jiang YX, Ge YJ, Liu FY, Xu WG*
- 8702 Modified Gant procedure for treatment of internal rectal prolapse in elderly women  
*Xu PP, Su YH, Zhang Y, Lu T*
- 8710 Clinical and imaging features of desmoid tumors of the extremities  
*Shi Z, Zhao XM, Jiang JM, Li M, Xie LZ*
- 8718 Retrospective analysis of surgically treated pT4b gastric cancer with pancreatic head invasion  
*Jin P, Liu H, Ma FH, Ma S, Li Y, Xiong JP, Kang WZ, Hu HT, Tian YT*
- 8729 Development of a random forest model for hypotension prediction after anesthesia induction for cardiac surgery  
*Li XF, Huang YZ, Tang JY, Li RC, Wang XQ*

**Clinical Trials Study**

- 8740** Effects of mindful breathing combined with sleep-inducing exercises in patients with insomnia  
*Su H, Xiao L, Ren Y, Xie H, Sun XH*

**Observational Study**

- 8749** Chronic hepatitis-C infection in COVID-19 patients is associated with in-hospital mortality  
*Ronderos D, Omar AMS, Abbas H, Makker J, Baiomi A, Sun H, Mantri N, Choi Y, Fortuzi K, Shin D, Patel H, Chilimuri S*
- 8763** Midazolam dose is associated with recurrence of paradoxical reactions during endoscopy  
*Jin EH, Song JH, Lee J, Bae JH, Chung SJ*

**CASE REPORT**

- 8773** Isolated mass-forming IgG4-related sclerosing cholangitis masquerading as extrahepatic cholangiocarcinoma: A case report  
*Song S, Jo S*
- 8782** *Salmonella typhi* infection-related appendicitis: A case report  
*Zheng BH, Hao WM, Lin HC, Shang GG, Liu H, Ni XJ*
- 8789** ACTA2 mutation is responsible for multisystemic smooth muscle dysfunction syndrome with seizures: A case report and review of literature  
*Yang WX, Zhang HH, Hu JN, Zhao L, Li YY, Shao XL*
- 8797** Whole-genome amplification/preimplantation genetic testing for propionic acidemia of successful pregnancy in an obligate carrier Mexican couple: A case report  
*Neumann A, Alcantara-Ortigoza MA, González-del Angel A, Zarate Díaz NA, Santana JS, Porchia LM, López-Bayghen E*
- 8804** Is mannitol combined with furosemide a new treatment for refractory lymphedema? A case report  
*Kim HS, Lee JY, Jung JW, Lee KH, Kim MJ, Park SB*
- 8812** Successful treatment of floating splenic volvulus: Two case reports and a literature review  
*Sun C, Li SL*
- 8820** Removal of "ruptured" pulmonary artery infusion port catheter by pigtail catheter combined with gooseneck trap: A case report  
*Chen GQ, Wu Y, Zhao KF, Shi RS*
- 8825** Isolated neutropenia caused by copper deficiency due to jejunal feeding and excessive zinc intake: A case report  
*Ohmori H, Kodama H, Takemoto M, Yamasaki M, Matsumoto T, Kumode M, Miyachi T, Sumimoto R*
- 8831** Diagnosis and treatment of eosinophilic fasciitis: Report of two cases  
*Song Y, Zhang N, Yu Y*
- 8839** Familial left cervical neurofibromatosis 1 with scoliosis: A case report  
*Mu X, Zhang HY, Shen YH, Yang HY*

- 8846** Successful treatment after toxic epidermal necrolysis induced by AZD-9291 in a patient with non-small cell lung cancer: A case report  
*Li W, He X, Liu H, Zhu J, Zhang HM*
- 8852** Anesthesia management in a pediatric patient with Becker muscular dystrophy undergoing laparoscopic surgery: A case report  
*Peng L, Wei W*
- 8858** Diagnosis of upper gastrointestinal perforation complicated with fistula formation and subphrenic abscess by contrast-enhanced ultrasound: A case report  
*Qiu TT, Fu R, Luo Y, Ling WW*
- 8864** Adenomyoepithelioma of the breast with malignant transformation and repeated local recurrence: A case report  
*Oda G, Nakagawa T, Mori M, Fujioka T, Onishi I*
- 8871** Primary intracranial synovial sarcoma with hemorrhage: A case report  
*Wang YY, Li ML, Zhang ZY, Ding JW, Xiao LF, Li WC, Wang L, Sun T*
- 8879** Lumbar infection caused by *Mycobacterium paragordoniae*: A case report  
*Tan YZ, Yuan T, Tan L, Tian YQ, Long YZ*
- 8888** Primary intratracheal neurilemmoma in a 10-year-old girl: A case report  
*Wu L, Sha MC, Wu XL, Bi J, Chen ZM, Wang YS*
- 8894** Ovarian pregnancy rupture following ovulation induction and intrauterine insemination: A case report  
*Wu B, Li K, Chen XF, Zhang J, Wang J, Xiang Y, Zhou HG*
- 8901** Delayed diagnosis of imperforate hymen with huge hematocolpometra: A case report  
*Jang E, So KA, Kim B, Lee AJ, Kim NR, Yang EJ, Shim SH, Lee SJ, Kim TJ*
- 8906** Acute pancreatitis with hypercalcemia caused by primary hyperparathyroidism associated with paraneoplastic syndrome: A case report and review of literature  
*Yang L, Lin Y, Zhang XQ, Liu B, Wang JY*
- 8915** Use of a modified tracheal tube in a child with traumatic bronchial rupture: A case report and review of literature  
*Fan QM, Yang WG*
- 8923** Isolated liver metastasis detected 11 years after the curative resection of rectal cancer: A case report  
*Yonenaga Y, Yokoyama S*
- 8932** Severe bleeding after operation of preauricular fistula: A case report  
*Tian CH, Chen XJ*
- 8938** Secondary aorto-esophageal fistula initially presented with empyema after thoracic aortic stent grafting: A case report  
*Wang DQ, Liu M, Fan WJ*

- 8946**    Disruption of sensation-dependent bladder emptying due to bladder overdistension in a complete spinal cord injury: A case report

*Yoon JY, Kim DS, Kim GW, Won YH, Park SH, Ko MH, Seo JH*

**ABOUT COVER**

Editorial Board Member of *World Journal of Clinical Cases*, Jjiang-Huei Jeng, DDS, PhD, Professor, School of Dentistry and Department of Dentistry, National Taiwan University Medical College and National Taiwan University Hospital, School of Dentistry, College of Dental Medicine, Kaohsiung Medical University, Taipei 100, Taiwan. [jhjeng@ntu.edu.tw](mailto:jhjeng@ntu.edu.tw)

**AIMS AND SCOPE**

The primary aim of *World Journal of Clinical Cases* (*WJCC*, *World J Clin Cases*) is to provide scholars and readers from various fields of clinical medicine with a platform to publish high-quality clinical research articles and communicate their research findings online.

*WJCC* mainly publishes articles reporting research results and findings obtained in the field of clinical medicine and covering a wide range of topics, including case control studies, retrospective cohort studies, retrospective studies, clinical trials studies, observational studies, prospective studies, randomized controlled trials, randomized clinical trials, systematic reviews, meta-analysis, and case reports.

**INDEXING/ABSTRACTING**

The *WJCC* is now indexed in Science Citation Index Expanded (also known as SciSearch®), Journal Citation Reports/Science Edition, Scopus, PubMed, and PubMed Central. The 2021 Edition of Journal Citation Reports® cites the 2020 impact factor (IF) for *WJCC* as 1.337; IF without journal self cites: 1.301; 5-year IF: 1.742; Journal Citation Indicator: 0.33; Ranking: 119 among 169 journals in medicine, general and internal; and Quartile category: Q3. The *WJCC*'s CiteScore for 2020 is 0.8 and Scopus CiteScore rank 2020: General Medicine is 493/793.

**RESPONSIBLE EDITORS FOR THIS ISSUE**

Production Editor: Jia-Hui Li; Production Department Director: Xiang Li; Editorial Office Director: Jin-Lei Wang.

**NAME OF JOURNAL**

*World Journal of Clinical Cases*

**ISSN**

ISSN 2307-8960 (online)

**LAUNCH DATE**

April 16, 2013

**FREQUENCY**

Thrice Monthly

**EDITORS-IN-CHIEF**

Dennis A Bloomfield, Sandro Vento, Bao-Gan Peng

**EDITORIAL BOARD MEMBERS**

<https://www.wjgnet.com/2307-8960/editorialboard.htm>

**PUBLICATION DATE**

October 16, 2021

**COPYRIGHT**

© 2021 Baishideng Publishing Group Inc

**INSTRUCTIONS TO AUTHORS**

<https://www.wjgnet.com/bpg/gerinfo/204>

**GUIDELINES FOR ETHICS DOCUMENTS**

<https://www.wjgnet.com/bpg/GerInfo/287>

**GUIDELINES FOR NON-NATIVE SPEAKERS OF ENGLISH**

<https://www.wjgnet.com/bpg/gerinfo/240>

**PUBLICATION ETHICS**

<https://www.wjgnet.com/bpg/GerInfo/288>

**PUBLICATION MISCONDUCT**

<https://www.wjgnet.com/bpg/gerinfo/208>

**ARTICLE PROCESSING CHARGE**

<https://www.wjgnet.com/bpg/gerinfo/242>

**STEPS FOR SUBMITTING MANUSCRIPTS**

<https://www.wjgnet.com/bpg/GerInfo/239>

**ONLINE SUBMISSION**

<https://www.f6publishing.com>





## Anesthesia management in a pediatric patient with Becker muscular dystrophy undergoing laparoscopic surgery: A case report

Ling Peng, Wei Wei

**ORCID number:** Ling Peng 0000-0002-1298-601X; Wei Wei 0000-0001-5452-8116.

**Author contributions:** Peng L drafted the manuscript; Wei W supervised the writing of the manuscript; both authors participated in the management of the patient in this case report, and read and approved the manuscript.

**Informed consent statement:** Informed written consent was obtained from the patient's father for publication of this report and any accompanying images.

**Conflict-of-interest statement:** The authors declare that have no conflicts of interest.

**CARE Checklist (2016) statement:** The authors have read the CARE Checklist (2016) statement, and the manuscript was prepared and revised according to the CARE Checklist (2016) statement.

**Open-Access:** This article is an open-access article that was selected by an in-house editor and fully peer-reviewed by external reviewers. It is distributed in accordance with the Creative Commons Attribution NonCommercial (CC BY-NC 4.0) license, which permits others to distribute, remix, adapt, build upon this work non-commercially,

**Ling Peng, Wei Wei,** Department of Anaesthesiology, West China Hospital of Sichuan University, Chengdu 610041, Sichuan Province, China

**Corresponding author:** Wei Wei, MD, Chief Doctor, Department of Anaesthesiology, West China Hospital of Sichuan University, No. 37 Guoxue Lane, Wuhou District, Chengdu 610041, Sichuan Province, China. [weiw@scu.edu.cn](mailto:weiw@scu.edu.cn)

### Abstract

#### BACKGROUND

Patients with Becker muscular dystrophy (BMD) have a high risk of developing hyperkalemia, rhabdomyolysis, and malignant hyperthermia when exposed to volatile anesthetics and depolarizing muscle relaxants. Patients with BMD are also prone to respiratory depression after general anesthesia. Thus, it is extremely challenging for anesthesiologists to manage anesthesia in BMD patients, particularly in pediatric BMD patients. Here, we present successful anesthesia management using transversus abdominis plane block (TAPB) combined with total intravenous anesthesia (TIVA) in a pediatric BMD patient undergoing laparoscopic inguinal hernia repair.

#### CASE SUMMARY

A 2-year-old boy, weighing 15 kg, with BMD, was scheduled for laparoscopic inguinal hernia repair. TIVA was used for induction, and continuous infusions of short-acting intravenous anesthetics combined with TAPB were performed for anesthesia maintenance. Moreover, TAPB provided good postoperative analgesia. The patient underwent uneventful surgery and anesthesia, and over the 17 mo follow-up period showed no anesthesia-induced complications.

#### CONCLUSION

TAPB combined with TIVA, using short-acting intravenous anesthetic agents, can provide safe and effective anesthesia management in pediatric BMD patients undergoing short-term abdominal surgery.

**Key Words:** Transversus abdominis plane block; Total intravenous anesthesia; Becker muscular dystrophy; Pediatric patient; Case report

©The Author(s) 2021. Published by Baishideng Publishing Group Inc. All rights reserved.

and license their derivative works on different terms, provided the original work is properly cited and the use is non-commercial. See: <http://creativecommons.org/licenses/by-nc/4.0/>

**Manuscript source:** Unsolicited manuscript

**Specialty type:** Medicine, research and experimental

**Country/Territory of origin:** China

**Peer-review report's scientific quality classification**

Grade A (Excellent): 0  
Grade B (Very good): 0  
Grade C (Good): C  
Grade D (Fair): 0  
Grade E (Poor): 0

**Received:** May 18, 2021

**Peer-review started:** May 18, 2021

**First decision:** June 15, 2021

**Revised:** June 22, 2021

**Accepted:** August 9, 2021

**Article in press:** August 9, 2021

**Published online:** October 16, 2021

**P-Reviewer:** Abubakar MS

**S-Editor:** Wang LL

**L-Editor:** Filipodia

**P-Editor:** Wu RR



**Core Tip:** Becker muscular dystrophy (BMD) is a rare disease induced by genetic mutations. Anesthesia management is extremely challenging in patients with BMD, as they are at high risk of developing hyperkalemia, rhabdomyolysis, or malignant hyperthermia. The mortality rate is very high in patients with these complications. In this report, we describe the use of total intravenous anesthesia combined with transversus abdominis plane block for laparoscopic inguinal hernia repair in a pediatric patient with BMD. This anesthesia technique is considered a safe and effective strategy for pediatric BMD patients. Our pediatric BMD patient achieved a good outcome.

**Citation:** Peng L, Wei W. Anesthesia management in a pediatric patient with Becker muscular dystrophy undergoing laparoscopic surgery: A case report. *World J Clin Cases* 2021; 9(29): 8852-8857

**URL:** <https://www.wjgnet.com/2307-8960/full/v9/i29/8852.htm>

**DOI:** <https://dx.doi.org/10.12998/wjcc.v9.i29.8852>

## INTRODUCTION

Becker muscular dystrophy (BMD) is an X-linked autosomal recessive disease resulting in partial absence or abnormality of dystrophin[1]. It is a rare disease with an incidence of approximately 1 in 18000 live male births[2]. Although the progression of BMD is slow, the disease eventually results in dilated cardiomyopathy or respiratory failure that may not be consistent with muscular weakness[3]. Patients with BMD have a high risk of hyperkalemia, rhabdomyolysis, and malignant hyperthermia when they are exposed to volatile anesthetics and depolarizing muscle relaxants[4]. Malignant hyperthermia is a severe anesthesia-related complication with a poor prognosis and high mortality rate. Therefore, it is highly challenging for anesthesiologists to manage anesthesia in BMD patients, particularly in pediatric patients. Herein, we present successful anesthesia management using transversus abdominis plane block (TAPB) combined with total intravenous anesthesia (TIVA) in a pediatric BMD patient undergoing laparoscopic inguinal hernia repair to provide experience regarding anesthesia management in BMD patients.

## CASE PRESENTATION

### Chief complaints

A 2-year-old boy, weighing 15 kg and 93 cm in height, was hospitalized due to a left inguinal hernia (Figure 1A).

### History of present illness

The patient developed a reducible mass in the left groin area after crying at the age of 1 year.

### History of past illness

The child was diagnosed with BMD at the age of 18 mo based on genetic testing, which showed a deletion of exon 45-47 in the Duchenne muscular dystrophy (DMD) gene.

### Personal and family history

No data were available.

### Physical examination

Physical examination revealed that the patient was in good general condition, except for congenital malformations of the fingers (Figure 1B) and toes (Figure 1C).

### Laboratory examinations

Laboratory tests showed elevated levels of creatine kinase (CK, 4891 IU/L), lactate dehydrogenase (LDH, 745 IU/L), and hydroxybutyrate dehydrogenase (HBDH, 668





**Figure 1 Physical examination.** A: The patient's left inguinal hernia; B: Congenital malformations of the fingers; C: Toes.

IU/L).

### **Imaging examinations**

Preoperative electrocardiogram, transthoracic echocardiography, and chest X-ray were normal. Electromyography suggested possible myogenic damage in bilateral musculus biceps brachii.

---

## **FINAL DIAGNOSIS**

---

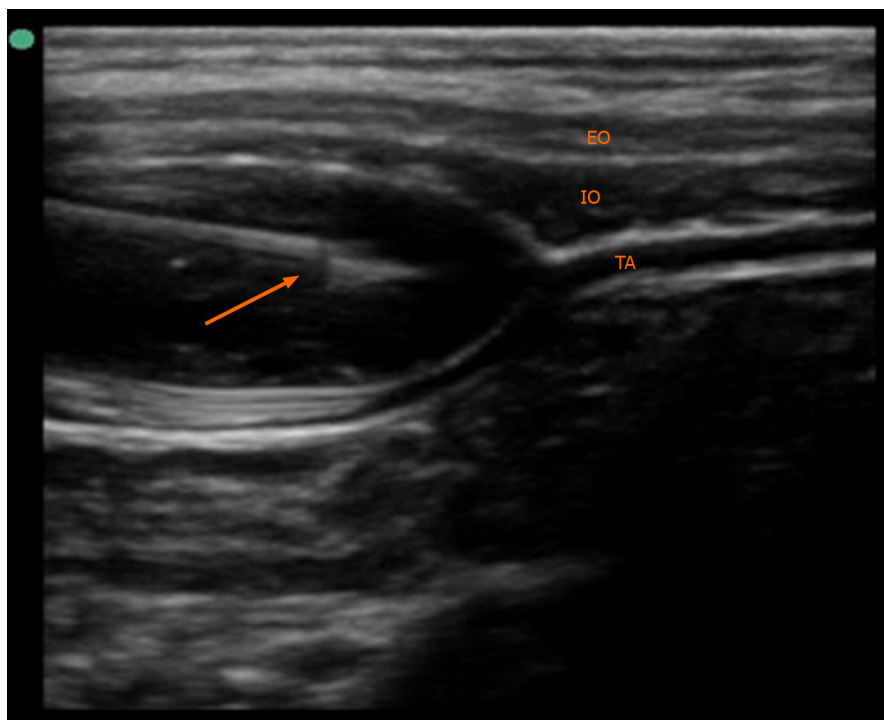
The patient was diagnosed with inguinal hernia combined with BMD.

---

## **TREATMENT**

---

The patient was scheduled for laparoscopic inguinal hernia repair. Before surgery, we prepared an anesthesia machine without recent use of volatile anesthetics. The machine was also flushed with fresh oxygen for approximately 30 min. Dantrolene was also prepared for emergency administration. Following admission to the operating room, the patient was monitored using non-invasive blood pressure measurement, electrocardiogram, and pulse oxygen saturation. Peripheral venous access was previously established in the ward. General anesthesia was induced with 0.15 mg atropine, 0.5 mg midazolam, 45 mg propofol, 30 µg fentanyl, and 1 mg cisatracurium besylate. A cuffed endotracheal tube 4.5 mm in size was inserted using a video laryngoscope for mechanical ventilation. At 13 cm H<sub>2</sub>O inspiratory pressure, 8-10 mL/kg of tidal volume could be achieved. End-tidal carbon dioxide (EtCO<sub>2</sub>) and nasopharynx temperature were continuously monitored. Ventilator parameters were adjusted to maintain EtCO<sub>2</sub> in the normal range. Bilateral TAPB with 0.25% ropivacaine 6 mL under ultrasound guidance was then performed (Figure 2). The TAPB can provide analgesia for iliac and inguinal regions for approximately 6 h. Anesthesia was maintained with 2-4 mg/kg/h propofol and 0.05-0.1 µg/kg/min remifentanyl with an oxygen-air mixture. During the operation, the patient's heart rate ranged between 100 and 130 bpm, while the mean blood pressure was between 60 and 80 mmHg. The EtCO<sub>2</sub> fluctuated between 35 and 45 mmHg, and the nasopharyngeal temperature was 36.4-36.6 °C. The operation lasted approximately 20 min. The patient recovered spontaneous breathing 10 min after cessation of anesthetics infusion, and then 0.2 mg neostigmine combined with 0.1 mg atropine was administered to reverse cisatracurium besylate-induced neuromuscular block. After 5 min of neostigmine administration, the patient's tidal volume increased to approximately 6-8 mL/kg, and he recovered consciousness. The endotracheal tube was immediately removed.



**Figure 2** Transversus abdominis plane block was performed under ultrasound guidance. The arrow indicates the nerve block needle, and the local anesthetics spread between the internal oblique (IO) and transversus abdominis (TA). EO: External oblique.

## OUTCOME AND FOLLOW-UP

The patient recovered from anesthesia uneventfully and was transferred to the postoperative care unit (PACU). There were no episodes of decreased oxygen saturation or nausea in the PACU, and he did not require additional analgesics during the postoperative period. He was discharged on postoperative day 1. The 17 mo follow-up period revealed no complications related to anesthesia.

## DISCUSSION

BMD is a congenital muscle disorder caused by genetic mutations[1]. The diagnosis usually depends on a muscle biopsy or genetic testing[4]. BMD differs from DMD in terms of slower progression and less severe muscle weakness. BMD patients rarely have clinical manifestations in early childhood but often have other deformities, such as scoliosis, tracheal stenosis, macroglossia, or inguinal hernia[3,5,6]. These deformities usually require surgical correction in childhood. Anesthesia management is extremely challenging for anesthesiologists, as patients with BMD have a high risk of developing hyperkalemia, rhabdomyolysis, or malignant hyperthermia, and the incidence of respiratory depression after anesthesia is also increased[4]. Cardiac arrest and malignant hyperthermia episodes have been reported in young BMD patients who inhaled isoflurane during anesthesia induction or maintenance[7-9]. Therefore, anesthesia management is more difficult in children with BMD, as the available anesthesia methods for children are limited.

Intraspinal anesthesia, such as spinal anesthesia, epidural anesthesia, caudal block, and saddle block, using local anesthetics is considered a good option for patients with BMD[6]. When intraspinal anesthesia was performed as the only anesthesia technique, BMD patients were less likely to have rhabdomyolysis or malignant hyperthermia. However, intraspinal anesthesia is limited in severe BMD patients with impaired respiratory or cardiac function, as it may further decrease the patient's breathing capacity or cardiac output.

Regional anesthesia is considered a safe approach in patients with muscular dystrophy[10]. Regional anesthesia has a reduced impact on hemodynamics and respiratory function. Therefore, it might have more advantages in high-risk patients with cardiac or respiratory dysfunction induced by muscular dystrophy. Moreover, regional anesthesia could provide effective postoperative analgesia without

respiratory depression, postoperative nausea, or vomiting. However, both intraspinal anesthesia and regional anesthesia are difficult to implement as the only anesthetic technique in a conscious pediatric patient because of non-cooperation.

Previous reports have shown that TIVA with or without a non-depolarizing muscle relaxant is a safe approach for anesthesia management in BMD patients[1,2,11]. It has been proven that propofol, etomidate, and opioids did not trigger hyperkalemia, rhabdomyolysis, or malignant hyperthermia[12,13]. Nevertheless, when TIVA was used as the only anesthetic technique, the occurrence of postoperative respiratory depression may increase in BMD patients due to high sensitivity to opioids and muscle relaxants. Moreover, propofol may lead to profound hypotension, reduced organ perfusion, and violent coughing[14]. Due to high sensitivity and prolonged duration of action of muscle relaxants in muscular dystrophy patients, it is even suggested that muscle relaxants should be avoided[2]. Another report revealed that muscle relaxant antagonists could effectively reverse muscle relaxation in progressive BMD patients, and the risk of respiratory depression induced by residual neuromuscular blockade after endotracheal extubation could be decreased[11]. Train-of-four (TOF) stimuli may be helpful in monitoring neuromuscular blockade when muscle relaxants are used. Thus, it is possible that non-depolarizing muscle relaxants can be used in patients with BMD. Cisatracurium besylate is a non-depolarizing muscle relaxant without the requirement of dose-dependent histamine release. In our patient, we used a small dose of cisatracurium besylate to provide muscle relaxation for endotracheal intubation and surgery. In addition, different to using TIVA as the only anesthetic technique, we performed TAPB after anesthesia induction to allow a reduction in the dose of the intravenously administered anesthetics and muscle relaxant during anesthesia maintenance. The respiratory depression induced by opioids and residual muscle relaxants might also decrease.

After surgery, particularly in the PACU, close attention should be paid to respiratory depression, analgesia, and mechanical muscle injury in BMD pediatric patients. Episodes of decreased oxygen saturation may occur due to postoperative respiratory depression. As opioids are considered to result in a high risk of respiratory depression, postoperative nausea, and vomiting, opioid-based patient-controlled intravenous analgesia should be avoided in BMD patients. Although non-steroidal anti-inflammatory drugs are used for postoperative pain management in adult BMD patients, their safety and effectiveness during analgesia are still uncertain[2,6,15]. Regional techniques, such as TAPB in our case, could provide an effective and safe postoperative analgesia for BMD patients[10]. The excellent analgesia provided by regional anesthesia could also decrease the restlessness of pediatric patients after surgery. To prevent mechanical muscle injury, the noninvasive blood pressure monitoring interval may need to be extended.

Although dantrolene is effective in treating anesthesia-induced rhabdomyolysis or malignant hyperthermia, prevention is still the most important factor in the anesthesia management of patients with BMD[3]. Volatile anesthetics and depolarizing muscle relaxants should be contraindicated in patients with BMD or with a positive family history. It is also necessary to flush the anesthetic machine with fresh oxygen before anesthesia. Comprehensive perioperative monitoring, including electrocardiogram, blood pressure, pulse oxygen saturation, EtCO<sub>2</sub>, and body temperature, are very important in BMD patients. Blood gas analysis should also be performed if necessary.

There were some limitations during the anesthesia management of our patient. First, TOF stimuli were not applied during anesthesia or in the PACU in our patient. However, we reduced the dose of intravenous anesthetic agents and muscle relaxant. In addition, a muscle relaxant antagonist was administered to reverse the neuromuscular block. Second, considering the duration of surgery was short, we did not perform invasive blood pressure monitoring and blood gas analysis. We extended noninvasive blood pressure monitoring to every 5 min to prevent mechanical muscle injury.

## CONCLUSION

TAPB combined with TIVA, using short-acting intravenous anesthetic agents, could provide safe and effective anesthesia management and postoperative analgesia for short-term abdominal operations in pediatric BMD patients. Comprehensive perioperative monitoring and care are crucial for muscular dystrophy patients undergoing general anesthesia.

## REFERENCES

- 1 **Parish M**, Farzin H. Adult patient with Becker dystrophy undergoing orthopedic surgery: an anesthesia challenge. *Int Med Case Rep J* 2018; **11**: 33-36 [PMID: [29497338](#) DOI: [10.2147/IMCRJ.S150037](#)]
- 2 **Iwata M**, Kuzumoto N, Akasaki Y, Morioka M, Nakayama K, Matsuzawa N, Kimoto K, Shimomura T. The ultrasound-guided nerve blocks of abdominal wall contributed to anesthetic management of cholecystectomy in a patient with Becker muscular dystrophy without using muscle relaxants. *JA Clin Rep* 2017; **3**: 64 [PMID: [29457107](#) DOI: [10.1186/s40981-017-0134-1](#)]
- 3 **Gurnaney H**, Brown A, Litman RS. Malignant hyperthermia and muscular dystrophies. *Anesth Analg* 2009; **109**: 1043-1048 [PMID: [19762730](#) DOI: [10.1213/ane.0b013e3181aa5cf6](#)]
- 4 **Segura LG**, Lorenz JD, Weingarten TN, Scavonetto F, Bojanić K, Selcen D, Sprung J. Anesthesia and Duchenne or Becker muscular dystrophy: review of 117 anesthetic exposures. *Paediatr Anaesth* 2013; **23**: 855-864 [PMID: [23919455](#) DOI: [10.1111/pan.12248](#)]
- 5 **Lee DK**, Lim BG, Lee IO, Oh HR, Lim SH, Lee MK. Unexpected tracheal narrowing during general anesthesia in the prone position of Duchenne muscular dystrophy patient -A report of two cases-. *Korean J Anesthesiol* 2013; **64**: 456-459 [PMID: [23741571](#) DOI: [10.4097/kjae.2013.64.5.456](#)]
- 6 **Tatulli F**, Caraglia A, Delcuratolo A, Cassano S, Chetta GS. Repair of an inguinoscrotal hernia in a patient with Becker muscular dystrophy. *G Chir* 2017; **37**: 216-219 [PMID: [28098058](#) DOI: [10.11138/gchir/2016.37.5.216](#)]
- 7 **Poole TC**, Lim TY, Buck J, Kong AS. Perioperative cardiac arrest in a patient with previously undiagnosed Becker's muscular dystrophy after isoflurane anaesthesia for elective surgery. *Br J Anaesth* 2010; **104**: 487-489 [PMID: [20190256](#) DOI: [10.1093/bja/aeq035](#)]
- 8 **Kleopa KA**, Rosenberg H, Heiman-Patterson T. Malignant hyperthermia-like episode in Becker muscular dystrophy. *Anesthesiology* 2000; **93**: 1535-1537 [PMID: [11149452](#) DOI: [10.1097/00000542-200012000-00030](#)]
- 9 **Ohkoshi N**, Yoshizawa T, Mizusawa H, Shoji S, Toyama M, Iida K, Sugishita Y, Hamano K, Takagi A, Goto K. Malignant hyperthermia in a patient with Becker muscular dystrophy: dystrophin analysis and caffeine contracture study. *Neuromuscul Disord* 1995; **5**: 53-58 [PMID: [7719142](#) DOI: [10.1016/0960-8966\(94\)e0026-5](#)]
- 10 **Bang SU**, Kim YS, Kwon WJ, Lee SM, Kim SH. Peripheral nerve blocks as the sole anesthetic technique in a patient with severe Duchenne muscular dystrophy. *J Anesth* 2016; **30**: 320-323 [PMID: [26721827](#) DOI: [10.1007/s00540-015-2127-4](#)]
- 11 **Shimauchi T**, Yamaura K, Sugibe S, Hoka S. Usefulness of sugammadex in a patient with Becker muscular dystrophy and dilated cardiomyopathy. *Acta Anaesthesiol Taiwan* 2014; **52**: 146-148 [PMID: [25199695](#) DOI: [10.1016/j.aat.2014.02.005](#)]
- 12 **Kawaai H**, Tanaka K, Yamazaki S. Continuous infusion propofol general anesthesia for dental treatment in patients with progressive muscular dystrophy. *Anesth Prog* 2005; **52**: 12-16 [PMID: [15859443](#) DOI: [10.2344/0003-3006\(2005\)52\[12:CIPGAF\]2.0.CO;2](#)]
- 13 **Kim TW**, Nemergut ME. Preparation of modern anesthesia workstations for malignant hyperthermia-susceptible patients: a review of past and present practice. *Anesthesiology* 2011; **114**: 205-212 [PMID: [21169802](#) DOI: [10.1097/ALN.0b013e3181ee2cb7](#)]
- 14 **Jain A**. Propofol-induced violent coughing in a patient with Becker's muscular dystrophy. *Indian J Pharmacol* 2011; **43**: 476-477 [PMID: [21845012](#) DOI: [10.4103/0253-7613.83134](#)]
- 15 **Zhou SY**, Wang D, Liu C, Zhang S, Shan BL, Ma HC. Laparoscopic gynecological surgery in an adult woman with Becker muscular dystrophy performed with sevoflurane with cisatracurium anesthesia: A case report. *Medicine (Baltimore)* 2020; **99**: e19733 [PMID: [32311965](#) DOI: [10.1097/MD.00000000000019733](#)]



Published by **Baishideng Publishing Group Inc**  
7041 Koll Center Parkway, Suite 160, Pleasanton, CA 94566, USA

**Telephone:** +1-925-3991568

**E-mail:** [bpgoffice@wjgnet.com](mailto:bpgoffice@wjgnet.com)

**Help Desk:** <https://www.f6publishing.com/helpdesk>

<https://www.wjgnet.com>

