

Combination therapy with daclatasvir and asunaprevir for dialysis patients infected with hepatitis C virus

Ken Sato, Yuichi Yamazaki, Tatsuya Ohyama, Takeshi Kobayashi, Norio Horiguchi, Satoru Kakizaki, Motoyasu Kusano, Masanobu Yamada

Ken Sato, Yuichi Yamazaki, Tatsuya Ohyama, Takeshi Kobayashi, Norio Horiguchi, Satoru Kakizaki, Masanobu Yamada, Department of Medicine and Molecular Science, Gunma University Graduate School of Medicine, Gunma 371-8511, Japan

Ken Sato, Yuichi Yamazaki, Norio Horiguchi, Satoru Kakizaki, Department of Gastroenterology, Heisei Hidaka Clinic, Gunma 371-0001, Japan

Motoyasu Kusano, Department of Endoscopy and Endoscopic Surgery, Gunma University Hospital, Gunma 371-8511, Japan

Author contributions: Sato K drafted the article and analyzed and interpreted the data; Yamazaki Y, Ohyama T, Kobayashi T, Horiguchi N, Kakizaki S and Kusano M analyzed the data; Yamada M approved the final version to be published.

Institutional review board statement: The institutional review board in our institute does not require more than obtaining written informed consent for the publication of case reports.

Informed consent statement: We obtained written informed consent.

Conflict-of-interest statement: The authors have declared no conflicts of interest.

Open-Access: This article is an open-access article which was selected by an in-house editor and fully peer-reviewed by external reviewers. It is distributed in accordance with the Creative Commons Attribution Non Commercial (CC BY-NC 4.0) license, which permits others to distribute, remix, adapt, build upon this work non-commercially, and license their derivative works on different terms, provided the original work is properly cited and the use is non-commercial. See: <http://creativecommons.org/licenses/by-nc/4.0/>

Correspondence to: Ken Sato, MD, PhD, Department of Medicine and Molecular Science, Gunma University Graduate School of Medicine, 3-39-22 Showa-machi, Maebashi, Gunma 371-8511, Japan. satoken@gunma-u.ac.jp
Telephone: +81-272-208127
Fax: +81-272-208136

Received: November 6, 2015
Peer-review started: November 9, 2015
First decision: December 18, 2015
Revised: January 12, 2016
Accepted: January 29, 2016
Article in press: January 31, 2016
Published online: March 16, 2016

Abstract

The standard antiviral therapy for dialysis patients infected with hepatitis C virus (HCV) is (pegylated) interferon monotherapy, but its efficacy is insufficient. Oral direct-acting antiviral agents (DAAs) have recently been developed for chronic hepatitis C patients. However, some DAAs have contraindications for chronic renal failure (CRF). Daclatasvir and asunaprevir are metabolized largely in the liver and are not contraindicated in CRF. Combination therapy with daclatasvir and asunaprevir was used for 4 dialysis patients infected with genotype 1b HCV. One patient had viral breakthrough, and the 3 others had sustained virological response 12. One patient was admitted for heart failure and percutaneous coronary intervention due to concomitant ischemic disease. Heart failure was unlikely to be caused by the combination therapy, as it was probably due to water overload. The patient continued to receive the combination therapy after the remission of the heart failure. The combination therapy was well tolerated in the other patients.

Key words: Hepatitis C; Oral drug; Daclatasvir; Asunaprevir; Dialysis

© The Author(s) 2016. Published by Baishideng Publishing Group Inc. All rights reserved.

Core tip: Oral combination therapy with the direct-acting antiviral agents daclatasvir and asunaprevir, which are

both metabolized largely in the liver, is a very useful strategy for dialysis patients infected with genotype 1b hepatitis C virus. Although there were only 4 dialysis patients, the combination therapy was effective and showed a relatively favorable safety profile. One patient was admitted for heart failure with or without pneumonitis and percutaneous coronary intervention, although the causal relationship between these adverse events and the combination therapy was interpreted as negative. Our case reports warrant further studies, although careful observation during the treatment is needed.

Sato K, Yamazaki Y, Ohya T, Kobayashi T, Horiguchi N, Kakizaki S, Kusano M, Yamada M. Combination therapy with daclatasvir and asunaprevir for dialysis patients infected with hepatitis C virus. *World J Clin Cases* 2016; 4(3): 88-93 Available from: URL: <http://www.wjgnet.com/2307-8960/full/v4/i3/88.htm> DOI: <http://dx.doi.org/10.12998/wjcc.v4.i3.88>

INTRODUCTION

Combination therapy with daclatasvir and asunaprevir has been reported to have a sustained virological response (SVR) rate of over 80% after 24 wk of therapy in chronic hepatitis C patients with genotype 1b^[1,2] and is available in Japan. These 2 direct-acting antiviral agents (DAAs) are recommended for patients with chronic hepatitis C with genotype 1b based on Japan Society of Hepatology guidelines for the management of hepatitis C virus (HCV) infection^[3] in Japan.

Currently, the Kidney Disease Improving Global Outcomes and the Japanese Society for Dialysis Therapy recommend antiviral therapy for dialysis patients infected with HCV^[4,5]. The standard antiviral therapy for dialysis patients infected with HCV has been (pegylated) interferon (IFN) monotherapy because of the contraindication of ribavirin due to potential renal toxicity. However, the efficacy of (pegylated) IFN monotherapy has been insufficient for patients infected with HCV.

Although some oral DAAs are contraindicated for chronic renal impairment, daclatasvir and asunaprevir are both metabolized largely in the liver and are not contraindicated in chronic renal failure. Thus, we treated dialysis patients infected with genotype 1b HCV. The resistance-associated variants (RAVs) were analyzed by the PCR-invader method^[6] or direct sequencing^[7].

We received written informed consent from all 4 patients. The submitted case reports comply with the Declaration of Helsinki. Here, we report 4 dialysis patients infected with genotype 1b HCV that were treated with the combination therapy of daclatasvir and asunaprevir as case reports. To our knowledge, our report is the first to show the effectiveness of oral DAAs for dialysis patients in Japan.

CASE REPORT

In all patients, the HCV genotype was 1b and the

severity of liver disease was judged as chronic hepatitis based on the laboratory data and imaging. After we started this combination therapy, we principally checked the laboratory data and adverse events on a weekly basis. The laboratory findings, treatments and outcomes of all cases are shown in Table 1.

Case 1

A 62-year-old female is receiving dialysis due to chronic renal failure caused by chronic glomerulonephritis at 26 years of age. Chronic hepatitis C was diagnosed at 39 years of age probably due to post-transfusion hepatitis after transfusion at 28 years of age. She received a liver biopsy approximately 10 years ago, and the histology showed fibrous portal expansion without bridging fibrosis. At that time, the platelet count was already several tens of thousands. Thus, she has had thrombocytopenia for unknown reasons since that time. The severity of liver disease was judged as chronic hepatitis based on other laboratory data and imaging. She received peginterferon α -2a monotherapy, but the virological response was partial. Regarding the RAVs, the L31 amino acid mutation was negative, but the D168E and Q80L amino acid mutations were positive and the Y93H mutation was slightly positive. We fully informed her using general information including the SVR rate of the combination therapy of daclatasvir and asunaprevir and provided her with some information about the effect and safety of this combination therapy for dialysis patients. However, she had a strong desire to receive this combination therapy. Thus, we began this combination therapy. The serum viral load disappeared at week 2 of therapy, but reappeared at week 4 of therapy. After we confirmed the positivity of the serum HCV RNA in weeks 7 and 8, we diagnosed a viral breakthrough, and the combination therapy was discontinued. The reason is that the most recent guidelines from the Study Group for the Standardization of Treatment of Viral Hepatitis Including Cirrhosis published by the Ministry of Health, Labor and Welfare recommends consideration for the discontinuation of antiviral therapy in the case of viral breakthrough referring to the reappearance of HCV RNA while still on therapy in patients who have a $> 1 \log_{10}$ IU/mL increase in HCV RNA above the nadir. The maintenance of combination therapy for the patient who had viral breakthrough may promote multiple drug resistance. The patient's adherence to both drugs was 100% until then. During the therapy, there were no adverse events, and the therapy was well tolerated. After the viral breakthrough, we checked the RAVs approximately 2 and 9 mo after the discontinuation of the combination therapy. The mutation profile of the RAVs was almost the same as that of the baseline, but the virus newly achieved a V170I amino acid mutation. She took 600 mg ursodeoxycholic acid before starting the combination therapy and continued to take it during the combination therapy and after the discontinuation of the combination therapy. We increased the dose up to 900 mg because

Table 1 Laboratory findings at baseline, treatments and outcomes of dialysis cases

Parameters	Case 1	Case 2	Case 3	Case 4
Age (yr)	62	61	72	70
Sex	Female	Male	Male	Male
BMI (kg/m ²)	17.9	20.9	19.4	22.3
HCV genotype	1b	1b	1b	1b
Cause of dialysis	CGN	CGN	CGN	DM
IFN-based therapy:	PEG-IFN- α 2a: partial response	Naive: NA	Naive: NA	Naive: NA
Outcome				
At the start of therapy				
HCV RNA (log ₁₀ IU/mL)	4.7	6	6.3	4.9
ALT (IU/L)	54	18	36	19
AST (IU/L)	36	20	31	13
WBC (cells/ μ L)	1660	3780	4330	5200
Hemoglobin (g/dL)	10.5	11.3	12.4	11.6
Platelets (cells/ μ L)	72000	204000	146000	218000
RAVs at baseline	D168E, Y93Y/H, Q80L	None	None	None
Severity of liver disease	Chronic hepatitis	Chronic hepatitis	Chronic hepatitis	Chronic hepatitis
Treatment and outcome				
Daclatasvir dosage (mg)	60	60	60	60
Asunaprevir dosage (mg)	200	200	200	200
Week of serum HCV RNA disappearance	2	3	3	2
Adherence to daclatasvir	100% ¹	100%	100%	100%
Adherence to asunaprevir	100% ¹	100%	100%	100%
Weeks of therapy	9	24	24	24
Response	Breakthrough	SVR12	SVR12	SVR12
Adverse events	None	None	None	Heart failure, Pneumonitis, Myocardial ischemia

¹The patient's adherence to both drugs was 100% until the date of the discontinuation of the combination therapy. BMI: Body mass index; CGN: Chronic glomerulonephritis; DM: Diabetes mellitus; NA: Not applicable; HCV: Hepatitis C virus; ALT: Alanine aminotransferase; AST: Aspartate aminotransferase; WBC: White blood cells; RAVs: Resistance-associated variants; SVR: Sustained virological response.

of the flare-up of serum alanine aminotransferase (ALT) after the discontinuation of the combination therapy, and the serum ALT then improved. The time course after the start of the combination therapy is shown in Figure 1.

Case 2

A 61-year-old male is receiving dialysis due to chronic renal failure probably caused by chronic glomerulonephritis at 28 years of age. The transmission source of hepatitis C may have been a blood transfusion when he received a cadaveric renal transplant at 30 years of

age. He did not receive interferon-based therapy. He had no RAVs that were associated with the combination therapy. We started this combination therapy, and the patient's adherence to both drugs was 100%. Serum HCV RNA became undetectable in week 3 of therapy, and then he achieved rapid virological response (RVR) and SVR12. During the therapy, there were no adverse events, and the therapy was well tolerated.

Case 3

A 72-year-old male is receiving dialysis due to chronic renal failure caused by chronic glomerulonephritis since 1977. The transmission source of hepatitis C may have been a blood transfusion. His medical history included prostate cancer at 64 years of age, radiation proctitis due to radiation therapy for the prostate cancer, and a cerebral lacunar infarction at 65 years of age. Moreover, he had arrhythmia, bronchial asthma, goiter, and secondary hyperparathyroidism. He did not take any concomitant-use forbidden or combined-use caution medications and did not receive interferon-based therapy. He had no RAVs that were associated with the combination therapy. We started this combination therapy and the patient's adherence to both drugs was 100%. The serum HCV RNA became undetectable on week 3 of therapy, and then he achieved RVR and SVR12. During the therapy, there were no adverse events, and the therapy was well tolerated.

Case 4

A 70-year-old male is receiving dialysis due to chronic renal failure arising from diabetic nephropathy in 2014. The transmission source of hepatitis C could not be identified. He had not received interferon-based therapy. He had no RAVs that were associated with the combination therapy. As he had taken nifedipine as a combined-use caution, nifedipine was discontinued after consultation with an attending cardiovascular specialist. Thus, we started this combination therapy. On day 60 of the therapy, he experienced difficulty breathing and admitted himself to the hospital where he was receiving dialysis. He was diagnosed with a heart failure that was unlikely to bear a causal relationship to the combination therapy, but rather was probably due to water overload, as postulated by an attending nephrologist in the hospital. The duration of hospitalization was 6 d. On day 1 after discharge, he experienced difficulty breathing and was hospitalized again. He was diagnosed as suffering from heart failure and pneumonitis and received antibiotics and volume control through dialysis. Then, he was discharged without symptoms. He could continue to receive the combination therapy with daclatasvir and asunaprevir after the remission of heart failure. As the attending nephrologist suspected that the deterioration of cardiac function might be a cause of heart failure in this episode, he asked the attending cardiovascular specialist to check the condition of the coronary arteries. Then, he admitted himself to our hospital to receive percutaneous coronary intervention

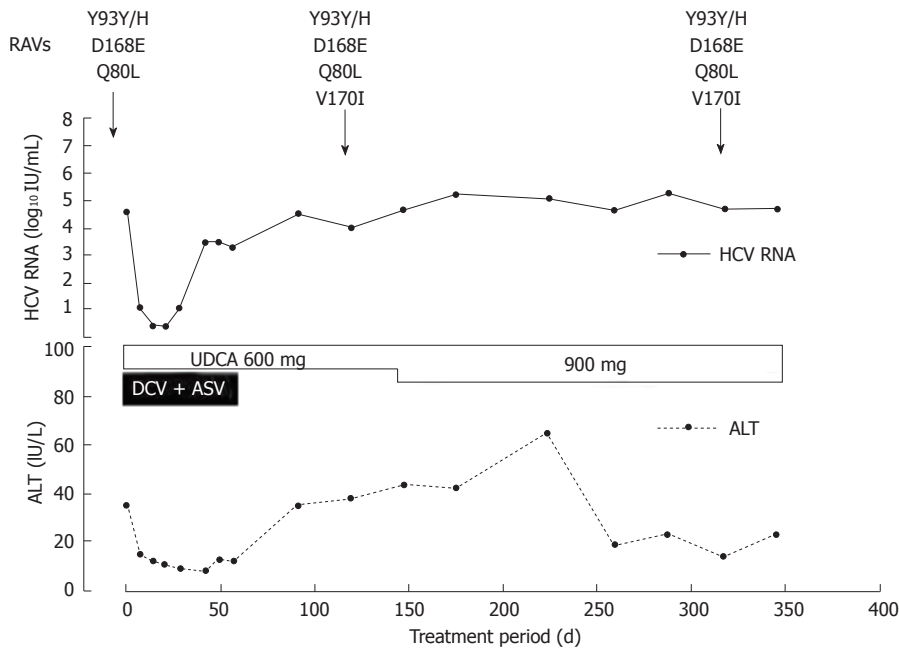


Figure 1 Clinical course of Case 1 of viral breakthrough during the combination treatment with daclatasvir and asunaprevir. RAVs: Resistance-associated variants; HCV: Hepatitis C virus; ALT: Alanine aminotransferase; UDCA: Ursodeoxycholic acid; DCV: Daclatasvir; ASV: Asunaprevir.

on day 101 of therapy, and ischemia was diagnosed and treated by a drug-eluting stent (XIENCE Alpine[®], Abbott Vascular Japan Co., Ltd., Minato-ku, Tokyo, Japan). After discharge from the hospital, he could continue to receive the combination therapy with daclatasvir and asunaprevir safely until the target completion date. Twenty-six days after the completion of the combination therapy, he was admitted to our hospital to recheck the condition of the coronary arteries, and ischemia was not diagnosed. The serum HCV RNA became undetectable in week 2 of therapy, and then he achieved RVR and SVR12. The patient's adherence to both drugs was 100%.

DISCUSSION

The major findings from these case reports are that the combination therapy with daclatasvir and asunaprevir was effective for dialysis patients and generally well tolerated. Sofosbuvir and ledipasvir have been recently approved and are available in Japan. The treatment period of this drug combination therapy is 12 wk, which is half the length of the 24-wk combination therapy with daclatasvir and asunaprevir. Moreover, there is little possibility of developing serious adverse events such as elevation of transaminase levels in the combination therapy of sofosbuvir and ledipasvir. However, this combination therapy has a flaw in that it is contraindicated in patients with chronic renal failure (eGFR < 30 mL/min per 1.73 m²) and dialysis. Thus, the combination therapy with daclatasvir and asunaprevir is quite useful for dialysis patients and superior to the combination therapy of sofosbuvir and ledipasvir in this regard. To our knowledge, this is the first report that shows the effectiveness of the oral

DAAs for dialysis patients in Japan.

The standard therapy for IFN therapy in dialysis patients includes pegylated IFN α -2a, natural IFN α , recombinant IFN α -2b, and natural IFN β . Only approximately one-third of hemodialysis patients with chronic hepatitis C achieve SVR with standard IFN monotherapy^[4]. The SVR rate is 14%-75% by pegylated IFN α -2a monotherapy^[5]. As these trials include patients with various genotypes, we have difficulty accurately evaluating the SVR rate in dialysis patients by (pegylated) IFN monotherapy. In our case reports, however, 3 dialysis patients without RAVs achieved SVR12. Regarding Case 1, perhaps we should not have treated her in light of RAVs at baseline, even though she had a strong desire to receive this combination therapy. By selecting the subjects to treat by examination of RAVs, a high SVR rate in dialysis patients with genotype 1b HCV would be expected.

The heart failure observed in Case 4 is unlikely to bear a causal relationship to the combination therapy, as mentioned previously. As dialysis patients are likely to develop heart failure based on the disease itself or iatrogenically, we should pay close attention to the development of heart failure during the combination therapy.

To treat dialysis patients, a better understanding of the metabolism of daclatasvir and asunaprevir is quite important. Daclatasvir is the substrate of CYP3A and metabolized mainly by CYP3A4, which is a member of the cytochrome P450 superfamily of enzymes and mainly found in the liver and the intestine. In the single oral administration of daclatasvir, it is eliminated 88% in fecal matter and 6.6% in urine. Asunaprevir is the substrate of OATP1B1 and OATP2B1 and metabolized mainly by CYP3A. In the single oral administration of

asunaprevir, it is eliminated 84% in fecal matter and less than 1% in urine. Thus, both drugs are mainly eliminated through the fecal route.

In end-stage renal disease (ESRD) foreign patients, the area under the curve (AUC) values for total and unbound daclatasvir were 26.9% and 20.1% higher than those with normal renal function by the single oral administration of 60 mg daclatasvir, respectively. The AUC and C_{max} values for asunaprevir were 10.1% lower and 28.6% higher than those with normal renal function in a twice a day for 7-d repeated dose study in ESRD foreign patients, respectively.

Generally, dialysis patients are likely to take various medicines due to their complications. Daclatasvir and especially asunaprevir have concomitant drugs that should be cautiously used. We should cease or change concomitant drugs that should be avoided or carefully used before the combination therapy. Calcium-channel blockers are one such concomitant drug class to be carefully used. In Case 4, we discontinued nifedipine for ischemic heart disease in advance and started the administration of the combination therapy after we verified that there was neither an increase in blood pressure nor an angina attack. Thus, the concomitant drugs and complications were completely checked in advance, and the application of this combination therapy was cautiously considered, as is also the case for patients not receiving dialysis. The administration of the combination therapy may be performed after the discontinuation or change of a combined-use caution situationally.

The combination therapy of daclatasvir and asunaprevir sometimes causes elevated transaminase levels, and this adverse event can develop at any time during the therapy. Thus, we should frequently check for liver dysfunction, regardless of dialysis. The 4 patients in our case reports did not experience an elevation in transaminase levels. As the dialysis patients are likely to have concomitant drugs and complications, we need to have more careful follow-up for them.

Our case reports have limitations. The sample size of our case reports is very small, and the serum concentrations of daclatasvir and asunaprevir during the therapy were not measured.

In summary, the combination therapy of daclatasvir and asunaprevir was a very useful strategy for dialysis patients infected with genotype 1b HCV. Large prospective studies of the combination therapy of daclatasvir and asunaprevir for dialysis patients are needed in the near future to confirm the results of our case reports.

COMMENTS

Case characteristics

Almost free of symptoms in all 4 cases.

Clinical diagnosis

Dialysis patients infected with hepatitis C virus (HCV).

Laboratory diagnosis

The blood draw showed hepatitis C viremia and chronic renal failure.

Imaging diagnosis

Abdominal computed tomography or echography revealed that all cases were considered chronic hepatitis according to the severity of liver disease.

Treatment

All cases were treated with daclatasvir and asunaprevir.

Term explanation

Direct-acting antiviral agents (DAAs): DAAs are molecules that target specific nonstructural proteins of the virus and disrupt viral replication and infection. Resistance-associated variants (RAVs): RAVs have been detected in the treatment-naïve HCV as well as after drug exposure and are thought to result from genetic variation inherent in the virus itself as well as selective pressure from drugs.

Experiences and lessons

The combination therapy of daclatasvir and asunaprevir is a very useful strategy for dialysis patients infected with genotype 1b HCV, but careful selection of subjects for treatment should be performed by examination of the RAVs.

Peer-review

The authors reported combination therapy with daclatasvir and asunaprevir for four dialysis patients infected with HCV genotype 1b. Except for one patient which was discontinued after viral breakthrough, this combination therapy was quite effective, however long term observation and monitoring of patients should be done. Overall, this combination therapy was well tolerated in patients. This case report will be useful as a base for further investigate the effectiveness of the combination therapy of daclatasvir and asunaprevir in dialysis patients.

REFERENCES

- 1 Kumada H, Suzuki Y, Ikeda K, Toyota J, Karino Y, Chayama K, Kawakami Y, Ido A, Yamamoto K, Takaguchi K, Izumi N, Koike K, Takehara T, Kawada N, Sata M, Miyagoshi H, Eley T, McPhee F, Damokosh A, Ishikawa H, Hughes E. Daclatasvir plus asunaprevir for chronic HCV genotype 1b infection. *Hepatology* 2014; **59**: 2083-2091 [PMID: 24604476 DOI: 10.1002/hep.27113]
- 2 Manns M, Pol S, Jacobson IM, Marcellin P, Gordon SC, Peng CY, Chang TT, Everson GT, Heo J, Gerken G, Yoffe B, Townner WJ, Bourliere M, Metivier S, Chu CJ, Sievert W, Bronowicki JP, Thabut D, Lee YJ, Kao JH, McPhee F, Kopit J, Mendez P, Linaberry M, Hughes E, Noviello S. All-oral daclatasvir plus asunaprevir for hepatitis C virus genotype 1b: a multinational, phase 3, multicohort study. *Lancet* 2014; **384**: 1597-1605 [PMID: 25078304 DOI: 10.1016/S0140-6736(14)61059-X]
- 3 Tanaka A. JSH guidelines for the management of hepatitis C virus infection (version 3). *Nihon Rinsho* 2015; **73**: 221-227 [PMID: 25764674]
- 4 Kidney Disease: Improving Global Outcomes (KDIGO). KDIGO clinical practice guidelines for the prevention, diagnosis, evaluation, and treatment of hepatitis C in chronic kidney disease. *Kidney Int Suppl* 2008; **(109)**: S1-99 [PMID: 18382440 DOI: 10.1038/ki.2008.81]
- 5 Akiba T, Hora K, Imawari M, Sato C, Tanaka E, Izumi N, Harada T, Ando R, Kikuchi K, Tomo T, Hirakata H, Akizawa T. 2011 Japanese Society for Dialysis Therapy guidelines for the treatment of hepatitis C virus infection in dialysis patients. *Ther Apher Dial* 2012; **16**: 289-310 [PMID: 22817117 DOI: 10.1111/j.1744-9987.2012.01078.x]
- 6 Suzuki F, Sezaki H, Akuta N, Suzuki Y, Seko Y, Kawamura Y, Hosaka T, Kobayashi M, Saito S, Arase Y, Ikeda K, Kobayashi M, Mineta R, Watahiki S, Miyakawa Y, Kumada H. Prevalence of hepatitis C virus variants resistant to NS3 protease inhibitors or the NS5A inhibitor (BMS-790052) in hepatitis patients with genotype 1b. *J Clin Virol* 2012; **54**: 352-354 [PMID: 22658798 DOI: 10.1016/j.jcv.2012.04.024]

- 7 **Miura M**, Maekawa S, Sato M, Komatsu N, Tatsumi A, Takano S, Amemiya F, Nakayama Y, Inoue T, Sakamoto M, Enomoto N. Deep sequencing analysis of variants resistant to the non-structural 5A

inhibitor daclatasvir in patients with genotype 1b hepatitis C virus infection. *Hepatol Res* 2014; **44**: E360-E367 [PMID: 24612030 DOI: 10.1111/hepr.12316]

P- Reviewer: Chuang WL, Utama A **S- Editor:** Qi Y **L- Editor:** A
E- Editor: Wu HL





Published by **Baishideng Publishing Group Inc**

8226 Regency Drive, Pleasanton, CA 94588, USA

Telephone: +1-925-223-8242

Fax: +1-925-223-8243

E-mail: bpgoffice@wjgnet.com

Help Desk: <http://www.wjgnet.com/esps/helpdesk.aspx>

<http://www.wjgnet.com>

