

Gastroenterology case report of mesalazine-induced cardiopulmonary hypersensitivity

José Ferrusquía, Isabel Pérez-Martínez, Ricardo Gómez de la Torre, María Luisa Fernández-Almira, Ruth de Francisco, Luis Rodrigo, Sabino Riestra

José Ferrusquía, Isabel Pérez-Martínez, Ruth de Francisco, Luis Rodrigo, Sabino Riestra, Department of Gastroenterology, Central University Hospital of Asturias, 33011 Oviedo, Asturias, Spain

Ricardo Gómez de la Torre, María Luisa Fernández-Almira, Department of Internal Medicine, Central University Hospital of Asturias, 33011 Oviedo, Asturias, Spain

Author contributions: Ferrusquía J and Pérez-Martínez I drafted the manuscript; Gómez de la Torre R, Fernández-Almira ML, de Francisco R and Riestra S critically reviewed the manuscript; all authors read and approved the final manuscript.

Ethics approval: The study was reviewed and approved by the Central University Hospital of Asturias research ethics committee.

Informed consent: All study participants, or their legal guardian, provided informed written consent prior to study enrollment.

Conflict-of-interest: Sabino Riestra has not received fees for serving as a speaker, a consultant or an advisory board member for any organizations.

Open-Access: This article is an open-access article which was selected by an in-house editor and fully peer-reviewed by external reviewers. It is distributed in accordance with the Creative Commons Attribution Non Commercial (CC BY-NC 4.0) license, which permits others to distribute, remix, adapt, build upon this work non-commercially, and license their derivative works on different terms, provided the original work is properly cited and the use is non-commercial. See: <http://creativecommons.org/licenses/by-nc/4.0/>

Correspondence to: Sabino Riestra, MD, Department of Gastroenterology, Central University Hospital of Asturias, Avenida de Roma s/n, 33011 Oviedo, Asturias, Spain. sriestram7@hotmail.com

Telephone: + 34-985-108000

Received: September 2, 2014

Peer-review started: September 3, 2014

First decision: October 29, 2014

Revised: November 27, 2014

Accepted: January 21, 2015

Article in press: January 21, 2015

Published online: April 7, 2015

been widely used to treat patients with inflammatory bowel disease. Accumulating evidence indicates that mesalazine has a very low rate of adverse drug reactions and is well tolerated by patients. However, a few cases of pulmonary and cardiac disease related to mesalazine have been reported in the past, though infrequently, preventing clinicians from diagnosing the conditions early. We describe the case of a 32-year-old man with ulcerative colitis who was admitted with a two-month history of persistent fever following mesalazine treatment initiated 14 mo earlier. At the time of admission, mesalazine dose was increased from 1.5 to 3.0 g/d, and antibiotic therapy was started with no improvement. Three weeks after admission, the patient developed dyspnea, non-productive cough, and chest pain. Severe eosinophilia was detected in laboratory tests, and a computed tomography scan revealed interstitial infiltrates in both lungs, as well as a large pericardial effusion. The bronchoalveolar lavage reported a CD4/CD8 ratio of 0.5, and an increased eosinophil count. Transbronchial biopsy examination showed a severe eosinophilic infiltrate of the lung tissue. Mesalazine-induced cardiopulmonary hypersensitivity was suspected after excluding other possible etiologies. Consequently, mesalazine treatment was suspended, and corticosteroid therapy was initiated, resulting in resolution of symptoms and radiologic abnormalities. We conclude that mesalazine-induced pulmonary and cardiac hypersensitivity should always be considered in the differential diagnosis of unexplained cardiopulmonary symptoms and radiographic abnormalities in patients with inflammatory bowel disease.

Key words: Eosinophilia; Mesalazine; Pericardial effusion; Lung hypersensitivity; Ulcerative colitis

© The Author(s) 2015. Published by Baishideng Publishing Group Inc. All rights reserved.

Abstract

Mesalazine is a 5-aminosalicylic acid derivative that has

Core tip: We report a case of lung and cardiac hypersensitivity caused by mesalazine therapy in a patient

with ulcerative colitis. Despite a few previously reported mesalazine-induced cardiac and pulmonary hypersensitivity cases, both entities are extremely infrequent making it difficult for the clinician to recognize these conditions during their early stages. An early diagnosis of these entities is extremely important, as the treatment consists of mesalazine suspension, usually resulting in a complete resolution of symptoms.

Ferrusquía J, Pérez-Martínez I, Gómez de la Torre R, Fernández-Almira ML, de Francisco R, Rodrigo L, Riestra S. Gastroenterology case report of mesalazine-induced cardiopulmonary hypersensitivity. *World J Gastroenterol* 2015; 21(13): 4069-4077 Available from: URL: <http://www.wjgnet.com/1007-9327/full/v21/i13/4069.htm> DOI: <http://dx.doi.org/10.3748/wjg.v21.i13.4069>

INTRODUCTION

Mesalazine, a 5-aminosalicylic acid derivative, is a medication widely used in the management of inflammatory bowel disease (IBD). The precise mechanism of mesalazine action remains poorly understood. However, it has been proposed that the drug acts locally on the colonic mucosa reducing inflammation through a variety of anti-inflammatory processes. These processes include the inhibition of proinflammatory cytokines (interleukin-1, -2, and -8 and tumor necrosis factor- α), the induction of the proliferator activated receptor- γ gene expression, or mesalazine acting as a potent antioxidant and free-radical scavenger^[1]. The use of sulfasalazine in the treatment of IBD has been limited by the side effects, most of them secondary to the sulfapyridine component^[2]. On the other hand, the use of mesalazine is usually well tolerated by patients, due to its favorable safety profile. Due to a limited number of cases of mesalazine-induced pulmonary disease and pericardial effusion, it has been difficult for clinicians to diagnose these diseases early. We describe the case of a patient with ulcerative colitis (UC) who, due to mesalazine treatment, simultaneously developed lung disease, pericardial effusion, and severe eosinophilia.

CASE REPORT

A 32-year-old non-smoking man with a 16-mo history of extensive UC treated with mesalazine (1.5 g/d) since the initial UC diagnosis and azathioprine (150 mg/d) for the last 13 mo was admitted to the hospital with a 2-mo history of asthenia, fever and night sweats. Prior to the appearance of the symptoms, UC was in clinical remission. Laboratory tests showed microcytic hypochromic anemia, a normal WBC count, and an increase in the erythrocyte sedimentation rate (91.0 mm/h) and the C-reactive protein level (10.3 mg/dL). Both chest radiograph and electrocardiogram

were normal. At the admission, mesalazine dose was increased to 3 g/d. Blood, urine and stool samples were collected for culture prior to a 10-d course of intravenous antibiotic treatment with ciprofloxacin and metronidazole. Nevertheless, the patient continued to be febrile resulting in termination of the antibiotic therapy. Cultures drawn at admission, as well as serologic testing for human immunodeficiency virus, were all negative. A rectosigmoidoscopy showed no evidence of disease activity. A computed tomography (CT) scan of the chest revealed the presence of centrilobular pulmonary nodules in the left lower lobe and lingula, as well as mediastinal and axillary lymphadenopathy.

After a few days of hospitalization, a progressive increase in the WBC and eosinophil counts were detected in peripheral blood. Three weeks after admission, a blood test showed a WBC count of $12.6 \times 10^9/L$ and a severe eosinophilia of $7.8 \times 10^9/L$ (62.3%). Immunoglobulins (IgA, IgG and IgM) and complement levels were normal. Rheumatoid factor, anti-citrullinated peptide antibodies, and anti-nuclear antibodies were all negative, while the anti-neutrophil cytoplasmic antibody exhibited a positive cytoplasmic staining pattern (titer, 1:160). During this time, our patient developed clinical symptoms of dyspnea, a non-productive cough, and thoracic pain. A second CT scan was performed, revealing the presence of a patchy ground glass opacification, centrilobular pulmonary nodules extending to both inferior lobes, and a 33.6-mm pericardial effusion not previously present (Figure 1A and B). An echocardiogram showed a large pericardial effusion with no signs of hemodynamic instability. Additionally, pulmonary function testing revealed a marked decrease of 66.8% in the diffusion capacity for carbon monoxide (DLCO). The tuberculin skin test revealed no induration, and the QuantiFERON TB-Gold test was also negative. Bronchoscopy findings reported an inflammatory stenosis of the left principal bronchia. The bronchoalveolar lavage (BAL) showed an eosinophilia of 72.0%, with CD4 and CD8 counts of 29.0 and 56.0%, respectively (CD4/CD8 ratio: 0.52). Transbronchial biopsy examination demonstrated the presence of a dense eosinophilic infiltrate throughout the interstitium, alveolar spaces, and capillaries, consistent with eosinophilic pneumonia, but no indication of necrosis or granulomas (Figure 2).

One month after admission, mesalazine-induced eosinophilic pneumonia, pericardial effusion and severe eosinophilia were suspected. Consequently, mesalazine was withdrawn, and therapy with prednisone was initiated. A few days after discontinuation of mesalazine, our patient had a quick and significant clinical improvement as indicated by normalization of the hemoglobin level and eosinophil count. In addition, a chest radiograph and a CT scan of the thorax revealed a complete resolution of the mediastinal and axillary lymphadenopathy, pericardial effusion,

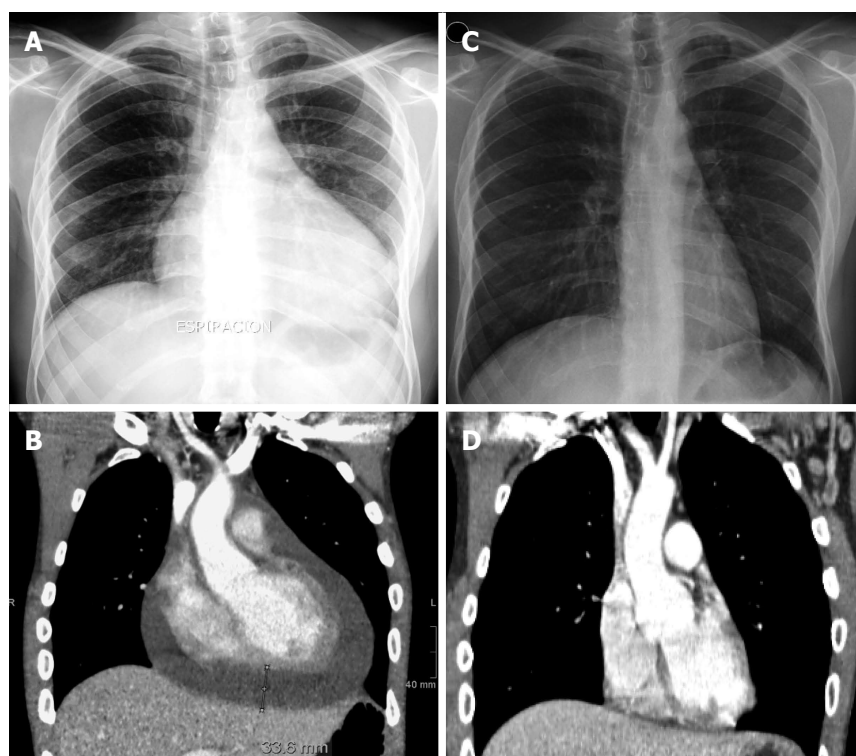


Figure 1 Radiograph of the chest and computed tomography scan before and after mesalazine suspension. A: Chest radiograph showing an enlarged cardiac silhouette due to a cardiac effusion during mesalazine treatment; B: Computed tomography (CT) scan of the chest revealing cardiomegaly due to a large pericardial effusion (maximum width of 33.6 mm) during mesalazine therapy; C: Normal chest radiograph after mesalazine withdrawal; D: CT scan of the chest showing a complete resolution of the pericardial effusion after suspension of mesalazine.

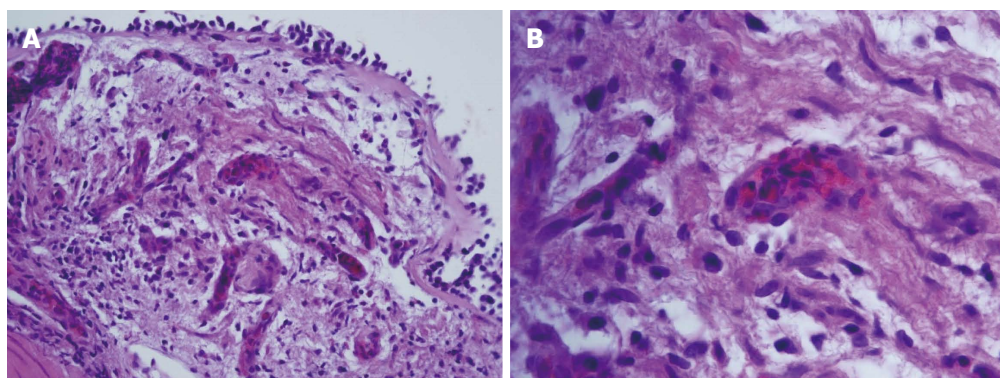


Figure 2 Transbronchial biopsy of the left inferior pulmonary lobe. A: An eosinophilic infiltrate throughout the alveolar septa, alveolar spaces and capillaries (HE stain, × 40); B: An eosinophilic infiltrate in the interior of capillaries (HE stain, × 100).

pulmonary nodules and infiltrates (Figure 1C and D). Despite continuous reduction in the DLCO (73.5%) 6 mo after discontinuation of mesalazine, our patient remained completely asymptomatic and capable of conducting a fully active life.

DISCUSSION

Clinicians treating patients with IBD exhibiting pulmonary symptoms face multiple causes for the onset of these symptoms. A respiratory involvement as an extraintestinal manifestation of UC (serositis, sarcoidosis, interstitial lung disease, or pulmonary

embolism) should be taken into consideration. Furthermore, lung infections, triggered or worsened by the immunosuppressive medication, as well as pulmonary adverse reactions induced by the drugs used to treat the underlying disease, should also be considered as the underlying cause of the pulmonary symptoms in IBD patients^[3].

The use of sulfasalazine has been related to multiple adverse drug reactions (ADRs), hence, mesalazine has become the first-line treatment for the induction and maintenance of remission of mildly to moderately active UC^[2]. Although mesalazine is usually well tolerated by patients, some serious ADRs like

hepatitis, blood dyscrasias, pancreatitis, and interstitial nephritis have been reported^[4]. Mesalazine-induced pulmonary side effects are rare, and its pathogenesis is not well understood. Nevertheless, it is thought that two mechanisms may be responsible for these side effects: (1) a toxicity mechanism that could be dose-dependent; and (2) an immunologic mechanism that might be dose-independent^[5,6].

Typical mesalazine-related side effects, which include fatigue, non-productive cough, fever, dyspnea and chest pain^[7], usually appear after 1-6 mo of treatment. In very rare cases, patients treated with mesalazine exhibited side effects as early as a few days or several years after the treatment^[6]. Laboratory tests may reveal peripheral eosinophilia while pulmonary nodules and an interstitial infiltrate with a ground glass pattern are usually seen in the chest radiograph or CT scan. If performed, the BAL frequently shows an elevated count of eosinophils or lymphocytes, and a reduction of the CD4/CD8 ratio. In addition, pulmonary function tests usually demonstrate a reduced DLCO. Histopathologic findings include interstitial lymphocytic infiltrates, alveolar eosinophilic infiltrates, alveolar fibrosis, and non-necrotizing granulomas^[5].

Differentiating mesalazine-induced lung disease from IBD-related pulmonary manifestation, as well as establishing a diagnosis, is challenging. It is known that mesalazine-induced lung disease usually affects the lung parenchyma^[8], whereas the IBD-related pulmonary manifestations typically involve the upper respiratory tract^[9]. If the diagnosis remains unclear, a lung biopsy should be considered in order to exclude other conditions. Preferably, the presence of eosinophilia in peripheral blood, BAL, or lung tissue should be used as indicators for diagnosing mesalazine-induced lung disease. Otherwise, diagnosis should be based on clinical presentation, exclusion of other causes of lung disease, and a trial of drug discontinuation. One case reported a complete resolution of the symptoms after the reduction of the mesalazine dose^[6]. In patients with severe respiratory symptoms or with a lack of improvement after mesalazine withdrawal, glucocorticoid therapy with prednisone (1 mg/kg per day) should be considered. Reintroduction of mesalazine is not usually recommended. Nonetheless, cases have been reported where rechallenge did not produce recurrence of pulmonary symptoms^[10-12].

Thirty-eight cases of mesalazine-induced pulmonary disease were found in the literature. The principal characteristics of those cases are summarized in Table 1. There were 18 men (46.2%) and 21 women (53.8%) with a mean age of 42 years (range: 10-72 years) at the onset of symptoms. Thirty-three of them were diagnosed with UC (84.6%) and six had Crohn's disease (15.4%). Mesalazine dose at the onset of symptoms varied from 750 mg to 4.8 g/d. The time between initiation of mesalazine treatment and the onset of pulmonary symptoms ranged from two days to 4-5 years. The most

common symptoms were non-productive cough, fever and dyspnea, which were present in 74.0%, 72.0% and 64.0% of the patients, respectively. Eosinophilia in peripheral blood was reported in 18 patients (46.0%), and pulmonary infiltrates with an interstitial pattern were the most frequent radiologic finding, appearing in 73.0% of patients. Similarly, eosinophilic pneumonia was the most common histologic finding, appearing in 41.0% of the biopsies. Mesalazine was suspended in 38 patients (97.4%), and 23 of them (60.5%) received systemic glucocorticoids as part of the treatment. Rechallenge was tried in seven patients, but recurrence was only seen in four of them (57.1%).

Cardiac disease as an extraintestinal manifestation of IBD is very rare. When it does occur, acute pericarditis is the most frequent form of presentation^[13], but myocarditis, pericardial effusion, and cardiac tamponade have also been described^[14,15]. Conversely, most cases of cardiac disease in patients with IBD are drug induced and, even when its pathogenesis is unclear, the consideration is that an idiosyncratic hypersensitivity reaction and a drug-induced lupus-like syndrome mechanism are related^[16]. Although most cases of mesalazine-induced cardiac hypersensitivity in IBD patients are not severe, life-threatening complications have been reported^[17]. The treatment for the condition consists of mesalazine suspension and administration of non-steroidal anti-inflammatory drugs or corticosteroids, taking into consideration that the former may exacerbate the underlying IBD in some patients^[18]. Table 2 summarizes the principal characteristics of previously published cases of mesalazine-induced cardiac hypersensitivity in patients with IBD.

The Naranjo algorithm scale^[19] was used to assess the probability of ADRs. The Naranjo algorithm scale is a questionnaire designed to determine the likelihood of whether ADRs are secondary to a drug rather than the result of other factors. ADRs of ≥ 9 points were considered to be definite, probable at 5-8 points, possible at 1-4 points, and doubtful at 0 points. Our patient scored 8 points, suggesting probable ADRs. However, due to the presence of eosinophilia in the peripheral blood, BAL and lung biopsy, the patient's deteriorating condition following mesalazine treatment followed by a significant improvement after discontinuation of mesalazine therapy, all strongly support our diagnosis, especially since other causes of cardiopulmonary disease were excluded. Azathioprine-induced pulmonary disease has also been described^[20], nevertheless, it is by far less frequent and in this case it did not seem to contribute to the patient's symptoms as he was receiving this medication at same dose for 13 mo prior to admission, throughout his entire hospitalization, and after being discharged. As clinical improvement was documented at the time mesalazine was stopped, we conclude this to be the cause.

Cardiopulmonary toxicity related to mesalazine is extremely infrequent making it difficult for clinicians to

Table 1 Summary of previously published cases of mesalazine-induced pulmonary hypersensitivity in patients with inflammatory bowel disease

Ref.	Age (yr)/sex	Disease	Daily dose	Duration of therapy ¹	Symptoms	EOS	RP	HF	CD4/CD8	BAL	DLCO	Steroid therapy	Rechallenge /recurrence
Le Gros <i>et al</i> ^[21]	54/F	UC	750 mg	5 d	T, R	ND	I	ND	Ratio: 0.95	Mo: 63% L: 35% E: 1.5%	53%	No	No
Welte <i>et al</i> ^[22]	67/M	UC	1 g IR	10 d	D, DC, R	ND	I	ND	ND	ND	ND	Yes	No
Reinoso <i>et al</i> ^[3]	64/F	UC	3.6 g	2 yr	T, D, DC	ND	I	ND	ND	ND	↓	No	No
Lagler <i>et al</i> ^[23]	66/M	UC	1.5 g	3.5 mo	D, DC	No	I	LP	ND	Mo: 30% L: 67%	54%	Yes	No
Honeybourne <i>et al</i> ^[24]	30/F	UC	1.6 g	7 mo	T, D, DC, CP	Yes 16%	ND	EP	ND	ND	ND	No	No
Declerck <i>et al</i> ^[25]	45/F	UC	3 g	3 mo	D	No	I	ND	ND	Mo: 45% L: 38% E: 11%	ND	No	No
Muzzi <i>et al</i> ^[10]	60/F	CD	2.4 g	ND	T, D, DC	No	I	ND	CD4: 56% CD8: 31% Ratio: 1.80	Mo: 40% L: 55% E: 3%	ND	No	Yes/No
Bitton <i>et al</i> ^[26]	32/F	UC	4 g	9 mo	T, D, DC	Yes 8.9%	ND	LP/IF	ND	ND	ND	Yes	No
Sviri <i>et al</i> ^[27]	49/M	CD	3 g	3.5 mo	T, D, DC	No	I	LP/IF	ND	L: 60% E: 10%	80%	Yes	Yes/Yes
Lázaro <i>et al</i> ^[28]	60/M	UC	ND	4 wk	T, D, DC	Yes	I	IP	ND	Mo: 80% L: 8% E: 10%	67%	No	No
Pascual-Lledó <i>et al</i> ^[29]	64/F	CD	3 g	2 mo	D, DC, CP	No	I	NL	ND	ND	ND	No ²	No
Sesin <i>et al</i> ^[30]	72/F	UC	1.6-2.4 g ³	2 mo	T, D, CP, PC	No	ND ⁴	ND	ND	ND	ND	No	No
Tanigawa <i>et al</i> ^[31]	35/F	UC	1.5 mg	40 d	T, DC	Yes	I	EP	CD4: 44% CD8: 34% Ratio: 1.3	Mo: 44% L: 49% E: 7%	ND	No	No
Guslandi <i>et al</i> ^[32]	29/F	UC	3 g	2 d	D, CP	No	ND	ND	ND	ND	ND	No	Yes/Yes
Facchini <i>et al</i> ^[33]	15/M	UC	2.8 g	4 mo	D, DC	No	A	ND	ND	ND	ND	Yes	No
Zamir <i>et al</i> ^[34]	23/F	UC	ND	6 wk	F, DC	Yes	ND	ND	ND	ND	ND	Yes	No
Saltzman <i>et al</i> ^[35]	53/F	UC	ND	4 mo	T, DC, R	Yes 27%	A	EP	ND	E: 79%	ND	Yes	No
Haralambou <i>et al</i> ^[36]	18/F	UC	1.6 g P.O. + 4 g (enema)	2 mo	T, D, DC, CP	Yes 88%	I	BO	ND	ND	ND	Yes	No
Sossai <i>et al</i> ^[6]	70/F	UC	2.4 g	3 mo	D, DC	No	I	IP	Ratio: 0.39	Mo: 40% L: 60%	ND	No	N/A ⁵
Pérez <i>et al</i> ^[37]	50/M	UC	4 g	2 mo	T, D, DC	ND	ND	EP	ND	ND	ND	Yes	No
Foster <i>et al</i> ^[5]	44/M 30/F	CD UC	2.4-4.8 g 4.8 g	15 mo 2 yr	T, D, DC T, D, DC, CP	No No	A A	IP/IF IP/IF	ND ND	N: 73% N: 43%	ND ND	Yes No	No No
Hakoda <i>et al</i> ^[38]	29/F 30/M	UC UC	3.6 g 2.25 g	8 mo 4 wk	T, D, DC T, DC	No Yes	A ND	IP EP	ND ND	ND ND	19% ND	Yes Yes	No No
Actis <i>et al</i> ^[39]	57/M	UC	ND	2 yr	T, D, DC, CP	No	A	ND	ND	ND	↓	Yes	No
Kohli <i>et al</i> ^[40]	10/F	UC	3.2 g	2 wk	T, D, DC	Yes 12%	I	IP	ND	ND	ND	Yes	Yes/Yes
Katsenos <i>et al</i> ^[41]	18/M	UC	ND	1 yr	T, PC	Yes	I	ND	ND	Mo: 15% L: 20% E: 60%	ND	Yes	No
Price <i>et al</i> ^[11]	28/F	UC	1.2 g	4-5 yr	T, PC	Yes	B	ND	ND	N: 95%	ND	Yes	Yes/No ⁶
Iannone <i>et al</i> ^[42]	32/F	UC	ND	4 mo	T, DC	No	I	ND	ND	ND	74%	Yes	No
Cilloniz <i>et al</i> ^[43]	14/M	CD	3 g	8 mo	CP	No	I	IP	ND	Mo: 68% L: 27%	93%	Yes	No

Park <i>et al</i> ^[44]	35/M	CD	4 g	3 mo	T, DC	Yes 32%	I	EP	CD4: 54% CD8: 41% Ratio: 1.3	L: 31% E: 41%	ND	No	No
Shimizu <i>et al</i> ^[45]	50/F	UC	ND	4 wk	T, DC	ND	ND	ND	ND	L: 58% E: 20%	ND	No	No
Sposato <i>et al</i> ^[46]	42/M	UC	3.2 g	8 d	T, CP	Yes 14%	I	ND	ND	Mo: 13% E: 47% N: 34%	ND	Yes ⁷	No
Lamsiah <i>et al</i> ^[47]	57/F	UC	ND (enemas)	3 mo	T, D, DC	Yes	I	ND	ND	ND	ND	Yes	Yes/Yes ⁸
Kevans <i>et al</i> ^[48]	17/M	UC	4 g	3 mo	D, DC, CP	Yes 23%	A	ND	ND	ND	ND	Yes	No
Abraham <i>et al</i> ^[49]	65/M	UC	4.8 g	2 wk	T, D, DC ⁹	No	I	LP/IF	ND	ND	ND	Yes	No
Kim <i>et al</i> ^[50]	30/F	UC	1 g IR	19 d	PC	Yes 24%	I	EP	ND	Mo: 73% N: 19%	ND	Yes	No
Michy <i>et al</i> ^[12]	72/M	UC	ND	4 mo	D	Yes	ND	EP	ND	L: 23% N: 28% E: 14%	ND	Yes	Yes/No ¹⁰
Current case	32/M	UC	1.5-3 g ³	14 mo	T, D, DC, CP	Yes 62%	I	EP	CD4: 29% CD8: 56% Ratio: 0.51	E: 72%	67%	Yes	No

¹Time under mesalazine treatment before symptoms appeared; ²Patient was on low-dose Deflazacort during all the course of the pulmonary disease; ³Mesalazine dose was increased after patient was admitted; ⁴Bilateral pleural effusion was also noted; ⁵Patient improved after reducing mesalazine dose; ⁶Rechallenge was intended with olsalazine 1.5 g/d, with no recurrence; ⁷Patient had no response to glucocorticoid therapy but showed improvement after mesalazine withdrawal; ⁸After mesalazine removal a second rechallenge with sulfasalazine was intended with no recurrence of symptoms; ⁹Patient required endotracheal intubation for severe respiratory insufficiency; ¹⁰No recurrence was noted after the reintroduction of mesalazine enemas. A: Alveolar pattern; B: Bronchiectasis; BAL: Bronchoalveolar lavage; BO: Bronchiolitis obliterans; CD: Crohn's disease; CP: Chest pain; CT: Corticoid therapy; D: Dyspnea; DC: Dry cough; DLCO: Diffusion capacity for carbon monoxide; E: Eosinophils; EOS: Eosinophilia; EP: Eosinophilic pneumonia; F: Female; HF: Histopathologic findings; I: Interstitial pattern; IF: Interstitial fibrosis; IP: Interstitial pneumonitis; IR: Intrarectal; L: Lymphocytes; LP: Lymphocytic pneumonitis; M: Male; Mo: Monocytes; N: Neutrophils; N/A: Not applicable; NC: No change; ND: No data available; NL: Normal; PC: Productive cough; PE: Pleural effusion; R: Rash; RP: Radiologic pattern; T: Fever; UC: Ulcerative colitis.

Table 2 Summary of previously published cases of mesalazine-induced cardiac hypersensitivity in patients with inflammatory bowel disease

Ref.	Age (yr)/sex	Disease	Daily dose	Duration of therapy	Symptoms	Cardiac disease	Pharmacologic treatment	Rechallenge/recurrence
Vayre <i>et al</i> ^[51]	53/M	CD	500 mg	8 yr	T, CP	AP, PE	Prednisolone	No
Ishikawa <i>et al</i> ^[16]	17/M	UC	1.5 g	2 wk	T, CP	AP, PE	Prednisolone	Yes/Yes
Doganay <i>et al</i> ^[52]	21/M	UC	2 g	10 d	T, D	AM	Budesonide	No
García-Morán <i>et al</i> ^[17]	39/M	UC	4 g P.O. + 2 g (enemas)	2 d	T, CP	AM, AMI	Methylprednisolone	No
Martín <i>et al</i> ^[53]	22/M	UC	3 g	ND	CP	AM	Corticosteroids	No
Cappell <i>et al</i> ^[15]	32/M	UC	ND	10 yr	T, CP, D	Chronic pericarditis, PT	Prednisone	No
Bernal-Sprekelsen <i>et al</i> ^[54]	54/M	UC	1.5 g	3 wk	T, CP	AP, PE	ASA	Yes/Yes ¹
Freeman <i>et al</i> ^[55]	26/M	UC	1.6 g	3 wk	T, CP	AM	Hydrocortisone	Yes/No ²
Sierra Ausín <i>et al</i> ^[56]	47/M	UC	3 g P.O. + 1 g (enemas)	3 wk	T, CP	AP	NSAIDs	No
Park <i>et al</i> ^[57]	26/M	UC	2.4 g	1 mo	T, CP	AM, PE	ASA, prednisolone	Yes/Yes
Calafat <i>et al</i> ^[13]	37/M	UC	1 g IR	1 mo	CP	AP, PE	ASA	No
	37/F	UC	3g	2 wk	CP	AP, PE	Analgesics	No
Sonu <i>et al</i> ^[58]	20/F	UC	Sulfasalazine 2 g + mesalazine (enemas) ³	3 wk	CP	AM, PT	Ibuprofen and colchicine	Yes/Yes ⁴
Current case	32/M	UC	1.5-3 g ³	14 mo	T, CP, D	AP, PE	Prednisone	No

¹After mesalazine suspension a rechallenge with mesalazine 500 mg IR was intended with recurrence of symptoms; ²After mesalazine suspension a rechallenge with sulfasalazine was intended without recurrence of symptoms; ³Mesalazine dose was not specified; ⁴After both sulfasalazine and mesalazine enemas were suspended, and low-dose balsalazide was initiated with recurrence of symptoms; ⁵Mesalazine dose was increased after patient was admitted. AP: Acute pericarditis; AM: Acute myopericarditis; AMI: Acute mitral insufficiency; ASA: Acetylsalicylic acid; CD: Crohn's disease; CP: Chest pain; D: Dyspnea; F: Female; IR: Intrarectal; M: Male; ND: No data available; NSAIDs: Nonsteroidal anti-inflammatory drugs; PE: Pericardial effusion; PT: Pericardial tamponade; T: Fever; UC: Ulcerative colitis.

recognize and diagnose it in the regular practice. The drug-induced pulmonary and cardiac hypersensitivity should be considered in any IBD patient who develops unexplained lung or cardiac disease while on mesalazine. Early recognition of these ADRs may lead to prompt cessation of the drug, most likely resulting in a complete resolution of the symptoms and radiologic abnormalities.

ACKNOWLEDGMENTS

The authors would like to thank Stacie Griffis, MD and Eleanor Boyce for her help with the translation of the manuscript.

COMMENTS

Case characteristics

A 32-year-old man with ulcerative colitis presented with fever, dyspnea, non-productive cough, and chest pain 14 mo from the initiation of mesalazine treatment.

Clinical diagnosis

Mesalazine-induced eosinophilic pneumonia and pericardial effusion.

Differential diagnosis

Cardiorespiratory involvement as an extra-intestinal manifestation of ulcerative colitis (serositis, sarcoidosis, interstitial lung disease or pulmonary embolism); lung infections; and drug-induced adverse reactions.

Laboratory diagnosis

Microcytic hypochromic anemia, WBC count of $12.6 \times 10^3/L$, eosinophilia of $7.8 \times 10^3/L$ (62.3%), diffusion capacity for carbon monoxide of 66.8%, and a bronchoalveolar lavage that reported an eosinophilia of 72.0%, with CD4 and CD8 counts of 29.0% and 56.0%, respectively (CD4/CD8 ratio: 0.51).

Imaging diagnosis

Computed tomography scan showed the presence of a patchy ground glass opacification, centrilobular pulmonary nodules that extended to both inferior lobes, and a large pericardial effusion of 33.6 mm. An echocardiogram confirmed the presence of a large pericardial effusion without evidence of hemodynamic instability.

Pathological diagnosis

A transbronchial biopsy examination showed the presence of a dense eosinophilic infiltrate throughout the interstitium, alveolar spaces, and capillaries, consistent with eosinophilic pneumonia.

Treatment

Mesalazine was suspended, and therapy with prednisone was initiated. Azathioprine therapy was continued at the same dose, before, during and after hospitalization.

Related reports

Mesalazine-induced pulmonary and cardiac hypersensitivity are extremely infrequent entities, making it difficult for clinicians to recognize them. This diagnosis was supported by the presence of eosinophilia in the peripheral blood, bronchoalveolar lavage, and lung biopsy, the deterioration of our patient after an increment of the mesalazine dose, as well as the improvement of the patient after discontinuation of mesalazine therapy. Nevertheless, elimination of other causes is required prior to establishing mesalazine-induced pulmonary and cardiac hypersensitivity diagnosis.

Experiences and lessons

An early recognition and an extensive diagnostic workup are essential in recognizing mesalazine-induced lung and cardiac hypersensitivity in inflammatory bowel disease patients as drug withdrawal may result in a favorable outcome for the patient.

Peer-review

The authors described an interesting case of a patient with ulcerative colitis who developed lung and cardiac hypersensitivity related to mesalazine therapy. This

article highlights the importance of considering drug-induced pulmonary and cardiac hypersensitivity in all inflammatory bowel disease patients who develop unexplained lung or cardiac disease while receiving mesalazine treatment.

REFERENCES

- 1 **Iacucci M**, de Silva S, Ghosh S. Mesalazine in inflammatory bowel disease: a trendy topic once again? *Can J Gastroenterol* 2010; **24**: 127-133 [PMID: 20151072]
- 2 **Bergman R**, Parkes M. Systematic review: the use of mesalazine in inflammatory bowel disease. *Aliment Pharmacol Ther* 2006; **23**: 841-855 [PMID: 16573787 DOI: 10.1111/j.1365-2036.2006.02846.x]
- 3 **Reinoso MA**, Schroeder KW, Pisani RJ. Lung disease associated with orally administered mesalamine for ulcerative colitis. *Chest* 1992; **101**: 1469-1471 [PMID: 1582327 DOI: 10.1378/chest.101.5.1469]
- 4 **Loftus EV**, Kane SV, Bjorkman D. Systematic review: short-term adverse effects of 5-aminosalicylic acid agents in the treatment of ulcerative colitis. *Aliment Pharmacol Ther* 2004; **19**: 179-189 [PMID: 14723609 DOI: 10.1111/j.0269-2813.2004.01827.x]
- 5 **Foster RA**, Zander DS, Mergo PJ, Valentine JF. Mesalamine-related lung disease: clinical, radiographic, and pathologic manifestations. *Inflamm Bowel Dis* 2003; **9**: 308-315 [PMID: 14555914 DOI: 10.1097/00054725-200309000-00004]
- 6 **Sossai P**, Cappellato MG, Stefani S. Can a drug-induced pulmonary hypersensitivity reaction be dose-dependent? A case with mesalamine. *Mt Sinai J Med* 2001; **68**: 389-395 [PMID: 11687867]
- 7 **Schleiermacher D**, Hoffmann JC. Pulmonary abnormalities in inflammatory bowel disease. *J Crohns Colitis* 2007; **1**: 61-69 [PMID: 21172186 DOI: 10.1016/j.crohns.2007.08.009]
- 8 **Camus P**, Piard F, Ashcroft T, Gal AA, Colby TV. The lung in inflammatory bowel disease. *Medicine* (Baltimore) 1993; **72**: 151-183 [PMID: 8502168 DOI: 10.1097/00005792-199372030-00003]
- 9 **Levine JS**, Burakoff R. Extraintestinal manifestations of inflammatory bowel disease. *Gastroenterol Hepatol* (N Y) 2011; **7**: 235-241 [PMID: 21857821]
- 10 **Muzzi A**, Ciani F, Bianchini D, Festini G, Volpe C. Adverse pulmonary effects of mesalamine. *Chest* 1995; **108**: 1181 [PMID: 7555145 DOI: 10.1378/chest.108.4.1181-a]
- 11 **Price LC**, Poullis A, Grubnic S, Kang JY, Rayner CF. Mesalazine-induced bronchiectasis and eosinophilia in a patient with ulcerative colitis: a case report. *J R Soc Med* 2007; **100**: 151-152 [PMID: 17339311 DOI: 10.1258/jrsm.100.3.151]
- 12 **Michy B**, Raymond S, Graffin B. [Organizing pneumonia during treatment with mesalazine]. *Rev Mal Respir* 2014; **31**: 70-77 [PMID: 24461446 DOI: 10.1016/j.rmr.2013.04.026]
- 13 **Calafat M**, Mañosa M, Cabré E, Domènech E. [Acute pericarditis associated with oral or topical mesalazine therapy in patients with ulcerative colitis]. *Gastroenterol Hepatol* 2014; **37**: 254-255 [PMID: 24333139 DOI: 10.1016/j.gastrohep.2013.09.004]
- 14 **Jose FA**, Heyman MB. Extraintestinal manifestations of inflammatory bowel disease. *J Pediatr Gastroenterol Nutr* 2008; **46**: 124-133 [PMID: 18223370 DOI: 10.1097/MPG.0b013e318093f4b0]
- 15 **Cappell MS**, Turkieh A. Chronic pericarditis and pericardial tamponade associated with ulcerative colitis. *Dig Dis Sci* 2008; **53**: 149-154 [PMID: 17574528 DOI: 10.1007/s10620-007-9836-y]
- 16 **Ishikawa N**, Imamura T, Nakajima K, Yamaga J, Yuchi H, Ootsuka M, Inatsu H, Aoki T, Eto T. Acute pericarditis associated with 5-aminosalicylic acid (5-ASA) treatment for severe active ulcerative colitis. *Intern Med* 2001; **40**: 901-904 [PMID: 11579953 DOI: 10.2169/internalmedicine.40.901]
- 17 **García-Morán S**, Sáez-Royuela F, Pérez-Alvarez JC, Gento E, Téllez J. Myopericarditis and mitral insufficiency associated with ulcerative colitis treated with mesalazine. *Inflamm Bowel Dis* 2006; **12**: 334-335 [PMID: 16633055 DOI: 10.1097/01.MIB.0000209788.19952.b7]
- 18 **Takeuchi K**, Smale S, Premchand P, Maiden L, Sherwood R, Thjodleifsson B, Bjornsson E, Bjarnason I. Prevalence and

- mechanism of nonsteroidal anti-inflammatory drug-induced clinical relapse in patients with inflammatory bowel disease. *Clin Gastroenterol Hepatol* 2006; **4**: 196-202 [PMID: 16469680 DOI: 10.1016/S1542-3565(05)00980-8]
- 19 **Naranjo CA**, Busto U, Sellers EM, Sandor P, Ruiz I, Roberts EA, Janecek E, Domecq C, Greenblatt DJ. A method for estimating the probability of adverse drug reactions. *Clin Pharmacol Ther* 1981; **30**: 239-245 [PMID: 7249508 DOI: 10.1038/clpt.1981.154]
 - 20 **Nagy F**, Molnar T, Makula E, Kiss I, Milassin P, Zollei E, Tiszlavicz L, Lonovics J. A case of interstitial pneumonitis in a patient with ulcerative colitis treated with azathioprine. *World J Gastroenterol* 2007; **13**: 316-319 [PMID: 17226917 DOI: 10.3748/wjg.v13.i2.316]
 - 21 **le Gros V**, Saveuse H, Lesur G, Brion N. Lung and skin hypersensitivity to 5-aminosalicylic acid. *BMJ* 1991; **302**: 970 [PMID: 1827746 DOI: 10.1136/bmj.302.6782.970-a]
 - 22 **Welte T**, Hamm H, Fabel H. Mesalazine alveolitis. *Lancet* 1991; **338**: 1273 [PMID: 1682668 DOI: 10.1016/0140-6736(91)92140-W]
 - 23 **Lagler U**, Schulthess HK, Kuhn M. [Acute alveolitis due to mesalazine]. *Schweiz Med Wochenschr* 1992; **122**: 1332-1334 [PMID: 1411390]
 - 24 **Honeybourne D**. Mesalazine toxicity. *BMJ* 1994; **308**: 533-534 [PMID: 8166873 DOI: 10.1136/bmj.308.6927.533b]
 - 25 **Declercq D**, Wallaert B, Demarcq-Delerue G, Tonnel AB. [Iatrogenic diffuse interstitial pneumonia linked to 5-aminosalicylate]. *Rev Mal Respir* 1994; **11**: 292-293 [PMID: 8041994]
 - 26 **Bitton A**, Peppercorn MA, Hanrahan JP, Upton MP. Mesalamine-induced lung toxicity. *Am J Gastroenterol* 1996; **91**: 1039-1040 [PMID: 8633548]
 - 27 **Sviri S**, Gafanovich I, Kramer MR, Tsvang E, Ben-Chetrit E. Mesalamine-induced hypersensitivity pneumonitis. A case report and review of the literature. *J Clin Gastroenterol* 1997; **24**: 34-36 [PMID: 9013348 DOI: 10.1097/00004836-199701000-00007]
 - 28 **Lázaro MT**, García-Tejedor MT, Díaz-Lobato S. Mesalamine-induced lung disease. *Arch Intern Med* 1997; **157**: 462 [PMID: 9046901 DOI: 10.1001/archinte.1997.00440250122018]
 - 29 **Pascual-Lledó JF**, Calvo-Bonachera J, Carrasco-Miras F, Sanchez-Martínez H. Interstitial pneumonitis due to mesalamine. *Ann Pharmacother* 1997; **31**: 499 [PMID: 9101017]
 - 30 **Sesin GP**, Mucciardi N, Almeida S. Mesalamine-associated pleural effusion with pulmonary infiltration. *Am J Health Syst Pharm* 1998; **55**: 2304-2305 [PMID: 9825882]
 - 31 **Tanigawa K**, Sugiyama K, Matsuyama H, Nakao H, Kohno K, Komuro Y, Iwanaga Y, Eguchi K, Kitaichi M, Takagi H. Mesalazine-induced eosinophilic pneumonia. *Respiration* 1999; **66**: 69-72 [PMID: 9973695 DOI: 10.1159/000029341]
 - 32 **Guslandi M**. Respiratory distress during mesalamine therapy. *Dig Dis Sci* 1999; **44**: 48-49 [PMID: 9952222 DOI: 10.1023/A:1026641830958]
 - 33 **Facchini S**, Candusso M, Zennaro F, Ventura A. Clinical quiz. 5-ASA hypersensitivity lung disease. *J Pediatr Gastroenterol Nutr* 1999; **29**: 349,357 [PMID: 10468004]
 - 34 **Zamir D**, Weizman J, Zamir C, Fireman Z, Weiner P. [Mesalamine-induced hypersensitivity pneumonitis]. *Harefuah* 1999; **137**: 28-30, 87, 86 [PMID: 10959271]
 - 35 **Saltzman K**, Rossoff LJ, Gouda H, Tongia S. Mesalamine-induced unilateral eosinophilic pneumonia. *AJR Am J Roentgenol* 2001; **177**: 257 [PMID: 11418451 DOI: 10.2214/ajr.177.1.1770257]
 - 36 **Haralambou G**, Teirstein AS, Gil J, Present DH. Bronchiolitis obliterans in a patient with ulcerative colitis receiving mesalamine. *Mt Sinai J Med* 2001; **68**: 384-388 [PMID: 11687866]
 - 37 **Pérez C**, Errázuriz I, Brockmann P, González S, Cofré C. [Eosinophilic pneumonia caused by mesalazine. Report of one case]. *Rev Med Chil* 2003; **131**: 81-84 [PMID: 12643224]
 - 38 **Hakoda Y**, Aoshima M, Kinoshita M, Sakurai M, Ohyashiki K. [A case of eosinophilic pneumonia possibly associated with 5-aminosalicylic acid (5-ASA)]. *Nihon Kokyuki Gakkai Zasshi* 2004; **42**: 404-409 [PMID: 15168457]
 - 39 **Actis GC**, Ottobrelli A, Baldi S, Scappaticci E, Modena V, Fusaro E, Mengozzi G, Rizzetto M. Mesalamine-induced lung injury in a patient with ulcerative colitis and a confounding autoimmune background: a case report. *Mt Sinai J Med* 2005; **72**: 136-140 [PMID: 15770345]
 - 40 **Kohli R**, Melin-Aldana H, Sentongo TA. Mesalamine-induced pneumonitis during therapy for chronic inflammatory bowel disease: a pediatric case report. *J Pediatr Gastroenterol Nutr* 2005; **41**: 479-482 [PMID: 16205520 DOI: 10.1097/01.mpg.0000173601.31647.84]
 - 41 **Katsenos S**, Psathakis K, Kokkonouzis I, Panagou P, Tsintiris K, Bouros D. Drug-induced pulmonary toxicity in a patient treated with mesalazine and azathioprine for ulcerative colitis. *Acta Gastroenterol Belg* 2007; **70**: 290-292 [PMID: 18074739]
 - 42 **Iannone P**, Lenzi T. An unusual case of pneumonia. *Intern Emerg Med* 2008; **3**: 391-393 [PMID: 18480972 DOI: 10.1007/s11739-008-0146-y]
 - 43 **Cilloniz R**, Chesrown SE, Gonzalez-Peralta RP. Asymptomatic presentation of mesalamine-induced lung injury in an adolescent with Crohn disease. *BMJ Case Rep* 2009; **2009**: [PMID: 21686567 DOI: 10.1136/bcr.09.2008.0908]
 - 44 **Park JE**, Hwangbo Y, Chang R, Chang YW, Jang JY, Kim BH, Dong SH, Kim HJ. [Mesalazine-induced eosinophilic pneumonia in a patient with Crohn's disease]. *Korean J Gastroenterol* 2009; **53**: 116-120 [PMID: 19237838]
 - 45 **Shimizu T**, Hayashi M, Shimizu N, Kinebuchi S, Toyama J. [A case of mesalazine-induced lung injury improved by only discontinuation of mesalazine]. *Nihon Kokyuki Gakkai Zasshi* 2009; **47**: 543-547 [PMID: 19601534]
 - 46 **Sposato B**, Allegri MP, Riccardi MP, Chigiotti S, Nencioni C, Ricciardi B, Carli T, Cresti A, Perari MG, Migliorini MG, Toti M. Mesalazine-induced multi-organ hypersensitivity. *Clin Drug Investig* 2010; **30**: 413-417 [PMID: 20441247 DOI: 10.2165/11535480-000000000-00000]
 - 47 **Lamsiah T**, Moudén K, Baaj M, Hadri L. [Interstitial pneumonia related to mesalamine]. *Gastroenterol Clin Biol* 2010; **34**: 224-226 [PMID: 20299168 DOI: 10.1016/j.gcb.2009.08.013]
 - 48 **Kevans D**, Greene J, Galvin L, Morgan R, Murray FE. Mesalazine-induced bronchiolitis obliterans organizing pneumonia (BOOP) in a patient with ulcerative colitis and primary sclerosing cholangitis. *Inflamm Bowel Dis* 2011; **17**: E137-E138 [PMID: 21761513 DOI: 10.1002/ibd.21819]
 - 49 **Abraham A**, Karakurum A. Acute respiratory failure secondary to mesalamine-induced interstitial pneumonitis. *BMJ Case Rep* 2013; **2013**: bcr2013009834 [PMID: 23964037 DOI: 10.1136/bcr-2013-009834]
 - 50 **Kim JH**, Lee JH, Koh ES, Park SW, Jang AS, Kim D, Park CS. Acute eosinophilic pneumonia related to a mesalazine suppository. *Asia Pac Allergy* 2013; **3**: 136-139 [PMID: 23667838 DOI: 10.5415/apallergy.2013.3.2.136]
 - 51 **Vayre F**, Vayre-Oundjian L, Monsuez JJ. Pericarditis associated with longstanding mesalazine administration in a patient. *Int J Cardiol* 1999; **68**: 243-245 [PMID: 10189017]
 - 52 **Doganay L**, Akinci B, Pekel N, Simsek I, Akpinar H. Mesalazine-induced myopericarditis in a patient with ulcerative colitis. *Int J Colorectal Dis* 2006; **21**: 199-200 [PMID: 15726390 DOI: 10.1007/s00384-004-0706-1]
 - 53 **Martín M**, Santamarta E, de la Iglesia JM, Saiz A. [Myopericarditis in a patient with ulcerative colitis treated with mesalazine]. *Med Clin (Barc)* 2010; **134**: 43-44 [PMID: 19423137 DOI: 10.1016/j.medcli.2009.02.028]
 - 54 **Bernal-Sprekelsen JC**, de las Marinas MD, Salvador A, Landete FJ, Morera FJ. Recurrent pericarditis in a patient with ulcerative proctitis due to mesalazine suppositories. *Int J Colorectal Dis* 2010; **25**: 1143-1144 [PMID: 20237787 DOI: 10.1007/s00384-010-0921-x]
 - 55 **Freeman HJ**, Salh B. Recurrent myopericarditis with extensive ulcerative colitis. *Can J Cardiol* 2010; **26**: 549-550 [PMID: 21165365 DOI: 10.1016/S0828-282X(10)70470-0]
 - 56 **Sierra Ausín M**, Rascarachi G, Díez Rodríguez R, Arias Rodríguez L, Del Pozo Maroto E, Muñoz Núñez F. [Mesalazine-induced acute pericarditis]. *Gastroenterol Hepatol* 2010; **33**: 338-339 [PMID: 20441247 DOI: 10.1136/bcr.09.2008.0908]

20005014 DOI: 10.1016/j.gastrohep.2009.10.006]

- 57 **Park EH**, Kim BJ, Huh JK, Jeong EH, Lee SH, Bang KB, Seol JS, Sung JW, Kim BS, Kang JH. Recurrent mesalazine-induced myopericarditis in a patient with ulcerative colitis. *J Cardiovasc Ultrasound* 2012; **20**: 154-156 [PMID: 23185660 DOI: 10.4250/

jcu.2012.20.3.154]

- 58 **Sonu I**, Wong R, Rothenberg ME. 5-ASA induced recurrent myopericarditis and cardiac tamponade in a patient with ulcerative colitis. *Dig Dis Sci* 2013; **58**: 2148-2150 [PMID: 23361575 DOI: 10.1007/s10620-013-2566-4]

P- Reviewer: Blonski W, Day AS, Shi RH, Tonelli F, Wittmann T
S- Editor: Ma YJ **L- Editor:** A **E- Editor:** Wang CH





Published by **Baishideng Publishing Group Inc**

8226 Regency Drive, Pleasanton, CA 94588, USA

Telephone: +1-925-223-8242

Fax: +1-925-223-8243

E-mail: bpgoffice@wjgnet.com

Help Desk: <http://www.wjgnet.com/esps/helpdesk.aspx>

<http://www.wjgnet.com>



ISSN 1007-9327



9 771007 932045