

World Journal of *Clinical Cases*

World J Clin Cases 2019 August 6; 7(15): 1908-2133



**REVIEW**

- 1908** Bone alterations in inflammatory bowel diseases
Sgambato D, Gimigliano F, De Musis C, Moretti A, Toro G, Ferrante E, Miranda A, De Mauro D, Romano L, Iolascon G, Romano M

MINIREVIEWS

- 1926** Extrahepatic hepcidin production: The intriguing outcomes of recent years
Daher R, Lefebvre T, Puy H, Karim Z
- 1937** Neoadjuvant endocrine therapy: A potential strategy for ER-positive breast cancer
Yao LT, Wang MZ, Wang MS, Yu XT, Guo JY, Sun T, Li XY, Xu YY

ORIGINAL ARTICLE**Basic Study**

- 1954** Vestigial like family member 3 is a novel prognostic biomarker for gastric cancer
Zhang LH, Wang Z, Li LH, Liu YK, Jin LF, Qi XW, Zhang C, Wang T, Hua D

Retrospective Study

- 1964** HER2 heterogeneity is a poor prognosticator for HER2-positive gastric cancer
Kaito A, Kuwata T, Tokunaga M, Shitara K, Sato R, Akimoto T, Kinoshita T

Case Control Study

- 1978** Changes in corneal endothelial cell density in patients with primary open-angle glaucoma
Yu ZY, Wu L, Qu B

Observational Study

- 1986** Myocardial bridge-related coronary heart disease: Independent influencing factors and their predicting value
Zhao DH, Fan Q, Ning JX, Wang X, Tian JY
- 1996** Clinical significance and role of up-regulation of SERPINA3 expression in endometrial cancer
Zhou ML, Chen FS, Mao H
- 2003** Evaluation of right ventricular volume and systolic function in normal fetuses using intelligent spatiotemporal image correlation
Sun JX, Cai AL, Xie LM

- 2013** Correlation between intracoronary thrombus components and coronary blood flow after percutaneous coronary intervention for acute myocardial infarction at different onset time
Zhang MJ, Liu X, Liu LH, Li N, Zhang N, Wang YQ, Sun XJ, Huang PH, Yin HM, Liu YH, Zheng H

META-ANALYSIS

- 2022** Performance of common imaging techniques *vs* serum biomarkers in assessing fibrosis in patients with chronic hepatitis B: A systematic review and meta-analysis
Xu XY, Wang WS, Zhang QM, Li JL, Sun JB, Qin TT, Liu HB

CASE REPORT

- 2038** Acute bleeding after argon plasma coagulation for weight regain after gastric bypass: A case report
Moura DTHD, Sachdev AH, Lu PW, Ribeiro IB, Thompson CC
- 2044** Left colonic metastasis from primary hepatocellular carcinoma: A case report
Tagliabue F, Burati M, Chiarelli M, Marando A, Simone MD, Cioffi U
- 2049** ALK-positive anaplastic large cell lymphoma presenting multiple lymphomatous polyposis: A case report and literature review
Saito M, Izumiyama K, Ogasawara R, Mori A, Kondo T, Tanaka M, Morioka M, Miyashita K, Tanino M
- 2058** Modified Tong Xie Yao Fang relieves solitary rectal ulcer syndrome: A case report
Zhang LL, Hao WS, Xu M, Li C, Shi YY
- 2065** Hydrogen gas therapy induced shrinkage of metastatic gallbladder cancer: A case report
Chen JB, Pan ZB, Du DM, Qian W, Ma YY, Mu F, Xu KC
- 2075** Giant nonfunctional ectopic adrenocortical carcinoma on the anterior abdominal wall: A case report
Zhou DK, Liu ZH, Gao BQ, Wang WL
- 2081** Oncogenic osteomalacia caused by a phosphaturic mesenchymal tumor of the femur: A case report
Tang D, Wang XM, Zhang YS, Mi XX
- 2087** Gastric duplication cyst mimicking large cystic lymphangioma in an adult: A rare case report and review of the literature
Xu FY, Sun A, Gan Y, Hu HJ
- 2094** Endometriosis of the duplex appendix: A case report and review of the literature
Zhu MY, Fei FM, Chen J, Zhou ZC, Wu B, Shen YY
- 2103** Fever and neck pain after pacemaker lead extraction: A case report
Wang SX, Bai J, Ma R, Lan RF, Zheng J, Xu W

- 2110** c.753_754delAG, a novel *CFTR* mutation found in a Chinese patient with cystic fibrosis: A case report and review of the literature
Wang YQ, Hao CL, Jiang WJ, Lu YH, Sun HQ, Gao CY, Wu M
- 2120** Common iliac artery occlusion with small intestinal transection caused by blunt abdominal trauma: A case report and review of the literature
Zhou YX, Ji Y, Chen J, Yang X, Zhou Q, Lv J
- 2128** Percutaneous coronary intervention for ostial lesions of the left main stem in a patient with congenital single left coronary artery: A case report
Wu Q, Li ZZ, Yue F, Wei F, Zhang CY

ABOUT COVER

Editorial Board Member of *World Journal of Clinical Cases*, Shu-Pin Huang, MD, Associate Professor, Attending Doctor, Director, Department of Urology, Kaohsiung Medical University, Kaohsiung 807, Taiwan

AIMS AND SCOPE

World Journal of Clinical Cases (*World J Clin Cases*, *WJCC*, online ISSN 2307-8960, DOI: 10.12998) is a peer-reviewed open access academic journal that aims to guide clinical practice and improve diagnostic and therapeutic skills of clinicians.

The primary task of *WJCC* is to rapidly publish high-quality Case Report, Clinical Management, Editorial, Field of Vision, Frontier, Medical Ethics, Original Articles, Meta-Analysis, Minireviews, and Review, in the fields of allergy, anesthesiology, cardiac medicine, clinical genetics, clinical neurology, critical care, dentistry, dermatology, emergency medicine, endocrinology, family medicine, gastroenterology and hepatology, etc.

INDEXING/ABSTRACTING

The *WJCC* is now indexed in PubMed, PubMed Central, Science Citation Index Expanded (also known as SciSearch®), and Journal Citation Reports/Science Edition. The 2019 Edition of Journal Citation Reports cites the 2018 impact factor for *WJCC* as 1.153 (5-year impact factor: N/A), ranking *WJCC* as 99 among 160 journals in Medicine, General and Internal (quartile in category Q3).

RESPONSIBLE EDITORS FOR THIS ISSUE

Responsible Electronic Editor: *Yan-Xia Xing*

Proofing Production Department Director: *Yun-Xiaojuan Wu*

NAME OF JOURNAL

World Journal of Clinical Cases

ISSN

ISSN 2307-8960 (online)

LAUNCH DATE

April 16, 2013

FREQUENCY

Semimonthly

EDITORS-IN-CHIEF

Dennis A Bloomfield, Sandro Vento

EDITORIAL BOARD MEMBERS

<https://www.wjnet.com/2307-8960/editorialboard.htm>

EDITORIAL OFFICE

Jin-Lei Wang, Director

PUBLICATION DATE

August 6, 2019

COPYRIGHT

© 2019 Baishideng Publishing Group Inc

INSTRUCTIONS TO AUTHORS

<https://www.wjnet.com/bpg/gerinfo/204>

GUIDELINES FOR ETHICS DOCUMENTS

<https://www.wjnet.com/bpg/GerInfo/287>

GUIDELINES FOR NON-NATIVE SPEAKERS OF ENGLISH

<https://www.wjnet.com/bpg/gerinfo/240>

PUBLICATION MISCONDUCT

<https://www.wjnet.com/bpg/gerinfo/208>

ARTICLE PROCESSING CHARGE

<https://www.wjnet.com/bpg/gerinfo/242>

STEPS FOR SUBMITTING MANUSCRIPTS

<https://www.wjnet.com/bpg/GerInfo/239>

ONLINE SUBMISSION

<https://www.f6publishing.com>



Observational Study

Evaluation of right ventricular volume and systolic function in normal fetuses using intelligent spatiotemporal image correlation

Jia-Xing Sun, Ai-Lu Cai, Li-Mei Xie

ORCID number: Jia-Xing Sun (0000-0002-7667-6686); Ai-Lu Cai (0000-0003-0390-8930); Li-Mei Xie (0000-0002-5308-1786).

Author contributions: Sun JX and Xie LM contributed equally to this work; Xie LM designed the research; Sun JX, Cai AL, Xie LM performed research; Sun JX analyzed the data and wrote the paper.

Institutional review board statement: The study was reviewed and approved by Shengjing Hospital of China Medical University.

Informed consent statement: Patients were not required to give informed consent to the study because the analysis used anonymous data.

Conflict-of-interest statement: There are no conflicts of interest to report.

Data sharing statement: No additional data are available.

STROBE statement: The manuscript was written and revised according to the STROBE Statement.

Open-Access: This article is an open-access article that was selected by an in-house editor and fully peer-reviewed by external reviewers. It is distributed in accordance with the Creative Commons Attribution Non Commercial (CC BY-NC 4.0) license, which permits others to distribute, remix, adapt, build upon this work non-commercially,

Jia-Xing Sun, Ai-Lu Cai, Li-Mei Xie, Ultrasound Department, Shengjing Hospital of China Medical University, Shenyang 110004, Liaoning Province, China

Li-Mei Xie, Ultrasound Department, Roicare Hospital and Clinics, Shenyang 110004, Liaoning Province, China

Corresponding author: Li-Mei Xie, MD, PhD, Professor, Ultrasound Department, Shengjing Hospital of China Medical University/Roicare Hospital and Clinics, No. 36 Sanhao Street, Shenyang 110004, Liaoning Province, China. xielm72@163.com

Telephone: +86-24-9661574194

Fax: +86-24-9661574194

Abstract

BACKGROUND

Heart defects are the most common congenital malformations in fetuses. Fetal cardiac structure and function abnormalities lead to changes in ventricular volume. As ventricular volume is an important index for evaluating fetal cardiovascular development, an effective and reliable method for measuring fetal ventricular volume and cardiac function is necessary for accurate ultrasonic diagnosis and effective clinical treatment. The new intelligent spatiotemporal image correlation (iSTIC) technology acquires high-resolution volumetric images. In this study, the iSTIC technique was used to measure right ventricular volume and to evaluate right ventricular systolic function to provide a more accurate and convenient evaluation of fetal heart function.

AIM

To investigate the value of iSTIC in evaluating right ventricular volume and systolic function in normal fetuses.

METHODS

Between October 2014 and September 2015, a total of 123 pregnant women received prenatal ultrasound examinations in our hospital. iSTIC technology was used to acquire the entire fetal cardiac volume with off-line analysis using QLAB software. Cardiac systolic and diastolic phases were defined by opening of the atrioventricular valve and the subsequent closure of the atrioventricular valve. The volumetric data of the two phases were measured by manual tracking and summation of multiple slices and recording of the right ventricular end-systolic volume and the right ventricular end-diastolic volume. The data were used to calculate the right stroke volume, the right cardiac output, and the right ejection fraction. The correlations of changes between the above-mentioned indices and

and license their derivative works on different terms, provided the original work is properly cited and the use is non-commercial. See: <http://creativecommons.org/licenses/by-nc/4.0/>

Manuscript source: Unsolicited manuscript

Received: March 27, 2019

Peer-review started: March 28, 2019

First decision: May 31, 2019

Revised: June 12, 2019

Accepted: July 3, 2019

Article in press: July 4, 2019

Published online: August 6, 2019

P-Reviewer: Dave M, Lowenberg M

S-Editor: Wang JL

L-Editor: Filipodia

E-Editor: Xing YX



gestational age were analyzed. The right ventricular volumes of 30 randomly selected cases were measured twice by the same sonographer, and the intra-observer agreement measurements were calculated.

RESULTS

Among the 123 normal fetuses, the mean right ventricular end-diastolic volume increased from 0.99 ± 0.34 mL at 22 wk gestation to 3.69 ± 0.36 mL at 35^{±6} wk gestation. The mean right ventricular end-systolic volume increased from 0.43 ± 0.18 mL at 22 wk gestation to 1.36 ± 0.22 mL at 35^{±6} wk gestation. The mean right stroke volume increased from 0.62 ± 0.29 mL at 22 wk gestation to 2.33 ± 0.18 mL at 35^{±6} wk gestation. The mean right cardiac output increased from 92.23 ± 40.67 mL/min at 22 wk gestation to 335.83 ± 32.75 mL/min at 35^{±6} wk gestation. Right ventricular end-diastolic volume, right ventricular end-systolic volume, right stroke volume, and right cardiac output all increased with gestational age and the correlations were linear ($P < 0.01$). Right ejection fraction had no apparent correlation with gestational age ($P > 0.05$).

CONCLUSION

Fetal right ventricular volume can be quantitatively measured using iSTIC technology with relative ease and high repeatability. iSTIC technology is expected to provide a new method for clinical evaluation of fetal cardiac function.

Key words: Ultrasonography; Fetus; Intelligent spatiotemporal image correlation; Right ventricular volume; Cardiac function

©The Author(s) 2019. Published by Baishideng Publishing Group Inc. All rights reserved.

Core tip: Heart defects are the most common congenital malformations in fetuses. Fetal cardiac structure and function abnormalities often lead to changes in ventricular volume. Numerous studies have focused on fetal heart functions, which have not been widely accepted. Between October 2014 and September 2015, the intelligent spatiotemporal image correlation technique was used to measure right ventricular volume in 123 normal fetuses and to evaluate right ventricular systolic function to provide a new method for more accurate and convenient evaluation of fetal heart function.

Citation: Sun JX, Cai AL, Xie LM. Evaluation of right ventricular volume and systolic function in normal fetuses using intelligent spatiotemporal image correlation. *World J Clin Cases* 2019; 7(15): 2003-2012

URL: <https://www.wjgnet.com/2307-8960/full/v7/i15/2003.htm>

DOI: <https://dx.doi.org/10.12998/wjcc.v7.i15.2003>

INTRODUCTION

Heart defects are the most common congenital malformations in fetuses with an incidence six times greater than chromosome abnormalities and four times greater than neural tube defects^[1,2]. The diagnosis of congenital heart disease is a challenge using prenatal ultrasound and is the focus of perinatal medical research. Congenital heart disease can be divided into structural and functional abnormalities. Indeed, fetal cardiac structure and function abnormalities often lead to changes in ventricular volume. As ventricular volume is an important index for evaluating fetal cardiovascular development, an effective and reliable method for measuring fetal ventricular volume and cardiac function is necessary for accurate ultrasonic diagnosis and effective clinical treatment of congenital heart disease.

Numerous studies have focused on fetal heart function in an effort to evaluate cardiac function in the healthy fetus and in those in states of cardiac decompensation^[3]. The accuracy of traditional two-dimensional (2D) ultrasound in the quantitative evaluation of fetal heart function has not been widely accepted^[4-15]. Spatiotemporal image correlation (STIC) technology overcomes many of the shortcomings of conventional 2D ultrasound in the measurement of fetal ventricular volume and evaluation of fetal cardiac function. Recently, a number of studies have used STIC technology in combination with organ computer-aided analysis software to

measure fetal ventricular volume and evaluate heart function with proven accuracy and feasibility^[4-7,16-27]. However, STIC still has some limitations and the imaging principle determines that STIC is not a real-time three-dimensional (3D) imaging technology. One-way scanning using the sensors during the scanning process execution is slow, which leads to relatively long image acquisition time. Therefore, STIC is vulnerable to the effects of fetal and maternal respiration, resulting in degradation of image quality^[21,23].

The new intelligent STIC (iSTIC) technology adopts an electronic matrix type of probe, which is composed of thousands of vibrating bits, thus generating real-time 3D images with acquired data. The new iSTIC technology acquires high-resolution volumetric images of one cardiac cycle in only 2 s, thus reducing the effects of fetal movement on the image. iSTIC realizes real-time 3D visualization of the fetal heart, which has been shown to have many advantages^[24,25,27-29]. In the present study, the iSTIC technique was used to measure right ventricular volume in normal fetuses and to evaluate right ventricular systolic function to provide a new method for more accurate and convenient evaluation of fetal heart function.

MATERIALS AND METHODS

General information

One hundred twenty-three healthy gravidas with singleton gestations who visited our hospital for prenatal ultrasonography between October 2014 and September 2015 were included in the study. The maternal age range was 22–36 years (average, 26.60 ± 3.54 years). The gestational age range was 22–35⁺6 wk (mean, 28 ± 3.79 wk), including 20 cases at 22–23⁺6 wk, 24 cases at 24–25⁺6 wk, 20 cases at 26–27⁺6 wk, 16 cases at 28–29⁺6 wk, 18 cases at 30–31⁺6 wk, 15 cases at 32–33⁺6 wk, and 10 cases at 34–35⁺6 wk. The inclusion criteria were as follows: (1) singleton pregnancy; (2) fetal biological measurement indicators consistent with the corresponding gestational age; (3) no obvious fetal anatomic abnormalities shown on 2D ultrasound examination; (4) pregnant women were informed of the purpose of the evaluation, and informed consent was obtained before image acquisition; and (5) fetal heart image acquired using real-time 3D iSTIC technology was free of artifacts.

Instruments

An IU22 3D color Doppler ultrasound diagnostic instrument from Philips Company (Bothell, WA, USA) was used with a 2–4 MHz electronic matrix probe. QLAB software was used for image analysis and post-processing.

Data acquisition

The information of the last menstrual period and the gestational age in the pregnant women was obtained and recorded. The women were asked to lie flat, and a fetal echo program was begun with transabdominal scanning using an X6-1 probe. They were advised to hold their breath during the acquisition process to avoid interference of motion artifacts. Using a 3D/4D iSTIC technology model for a 4-chamber view of the fetal heart, the 3D/4D sampling frame location was adjusted and the sampling range assured 3D/4D volume data acquisition. The sampling frame included the entire fetal heart. The fetal heart rate was measured and recorded after completion of data acquisition. All images were stored in a built-in hard disk in the machine for later offline analysis.

Data analysis

(1) Post-processing of 3D image. The image stored in the built-in hard disk in the machine was extracted for analysis using QLAB software. The atrioventricular valve opening and closing framing at end systole and diastole in the entire cardiac cycle were observed to measure the fetal right ventricular volume. End systole was defined as the moment before atrioventricular valve opening, and end diastole was defined as the moment immediately after the atrioventricular valve closed. The center point of the central position of the right ventricle was adjusted using stacked contours to draw a line along the endocardium of the right ventricular apex to the edge of the tricuspid valve, the software was then automatically stratified followed by manual outlining of the contour of each layer of the lining of the heart at the short axis view of the heart including the trabecular muscle and regulating bundle. Computer software automatically calculated the volume of the right ventricle (Figure 1). The right ventricular end-diastolic volume (REDV) and the right ventricular end-systolic volume (RESV) were measured by the same observer three times to obtain the average value.

(2) The heart function index was calculated as follows: The right stroke volume

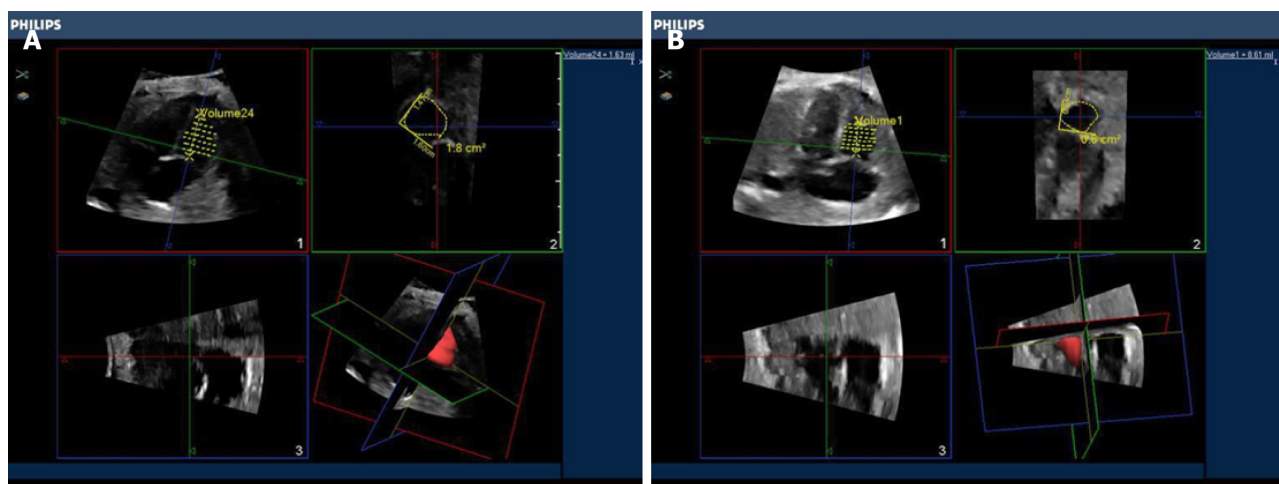


Figure 1 Fetal right ventricular end diastolic volume obtained by intelligent spatiotemporal image correlation technique.

(RSV) = REDV - RESV; the right cardiac output (RCO) = RSV \times fetal heart rate; the right ejection fraction = RSV/REDV.

(3) The paired Student's *t* test was performed by randomly retrieved images from 30 cases with the fetal right ventricular volume independently measured by two observers (twice for each observer or twice by the same observer) to evaluate the consistency of the measurement. The average value by each observer was compared.

Statistical analysis

Data input and processing were carried out using SPSS 23.0 statistical software. The quantitative data conforming to normal distribution were presented as $\bar{x} \pm s$. Spearman rank correlation analysis was used to determine the relationship between fetal right ventricular volume and cardiac function parameter changes with gestational age. In addition, the paired Student's *t* test was used to evaluate the consistency of the measurement by the same observer and between different observers. Differences with $P < 0.05$ were considered statistically significant.

RESULTS

Spearman rank correlation analysis

The changes in normal fetal REDV, RESV, RSV, and RCO with gestational age showed significant linear correlations, and the correlation coefficients were 0.903, 0.874, 0.866 and 0.865, respectively ($P < 0.01$, Figure 2, Table 1). Right ejection fraction did not change as gestational age increased, was relatively constant throughout the entire pregnancy, and was not significantly correlated with gestational age ($P > 0.05$, Table 1). Measurement of fetal right ventricular volume and cardiac function was carried out using the iSTIC technique (Table 2).

Paired Student's *t* test

The intraclass correlation coefficients (ICC) of REDV measured by the same observer was 0.989 with a 95% confidence interval (CI) of 0.978–0.995. The ICC of RESV was 0.978 with a 95%CI of 0.955–0.989. The ICC of REDV measured by different observers was 0.988 with a 95%CI of 0.975–0.994. The ICC of RESV was 0.988 with a 95%CI of 0.900–0.977. There was no statistical difference between the same observer and different observers when applying the iSTIC technique to measure RESV and REDV using the consistency test, and the correlation coefficients were 0.989, 0.951, 0.990, and 0.980, respectively. The results showed that there was particularly good consistency between the same observer and different observers ($P < 0.001$, Table 3).

DISCUSSION

Fetal cardiac function can be affected by a variety of conditions and prenatal interventions. Accurate assessment of fetal cardiac function could help to understand the process of fetal heart disease, improve the accuracy of diagnosis, and determine prenatal interventions^[2,5,6,16,19,20,22,23,26,30-39]. Two-dimensional ultrasound is still the

Table 1 The relationship between normal fetal right ventricular end-diastolic volume, right ventricular end-systolic volume, right stroke volume, right cardiac output, and right ejection fraction with gestational ages from 22 to 35⁺₆ wk

Gestational age	REDV	RESV	RSV	RCO	REF
<i>r</i>	0.903	0.874	0.866	0.865	0.120
<i>P</i>	< 0.001	< 0.001	< 0.001	< 0.001	0.187

REDV: Right ventricular end-diastolic volume; RESV: Right ventricular end-systolic volume; RSV: Right stroke volume; RCO: Right cardiac output; REF: Right ejection fraction.

traditional gold standard for diagnosis of fetal congenital heart diseases^[17,20,21] but has a number of limitations in the quantitative evaluation of fetal ventricular volume and cardiac function. When abnormal fetal heart structure causes significant cardiac geometric morphology changes, accurate quantitative assessment of fetal ventricular volume and cardiac function by 2D ultrasound is difficult^[3,34].

Application of the STIC imaging technique in fetal heart disorders has been studied extensively, which adds the time factor into the process of 3D data acquisition with continuous unidirectional scanning of the target area by the sensor to obtain the 3D volume data composed of each 2D slice. After completion of volume data acquisition, the software can automatically group 2D sections at the same time to reorganize the image of the entire fetal cardiac cycle, with end-systolic and end-diastolic phases of the cardiac cycle image defined according to opening and closing of the atrioventricular valve in post-processing^[3,16,17,20-23,29,36,38-42]. Such technology overcomes the imaginary heart geometry by 2D ultrasound along with a relatively simple image acquisition process and fewer requirements for operator experience. The imaging principle determines that STIC is not a real-time imaging technology but a delayed signal. Therefore, when an abnormality of the fetal heart leads to ventricular desynchrony, the maximum and minimum volume of the fetal ventricle cannot be accurately estimated using this method.

In contrast, iSTIC can generate real-time 3D images with an electronic matrix probe used vertically, and a horizontally-arranged 2D probe to conduct matrix volume imaging. The acoustic beam can automatically rotate for large-range scanning, which can significantly reduce the acquisition time of 3D image data and improve work efficiency. The acquisition time of one image by STIC is usually 8–12 s, but iSTIC only requires 2 s. With the imaging time significantly shortened, iSTIC has solved the contradiction between slow STIC imaging and a rapid fetal heart rate and reduced the effects of fetal and maternal respiration and other factors on the quality of the image. The image resolution is thus increased^[29,43,44]. In theory, accuracy of the iSTIC technique in the measurement of fetal ventricular volume is higher than STIC, which also reduces the exposure time of the fetus to ultrasound.

In this study, iSTIC technology was used to evaluate the heart function of 123 normal fetuses. The results showed that the fetal right ventricular volume, right ventricular stroke output, and RCO increased as gestational age increased, thus showing a good correlation with gestational age. Right ejection fraction did not change as the gestational age increased, which was relatively constant throughout the pregnancy and consistent with a previous report^[23]. During the entire process of fetal growth and development, the circulatory system plays a critical role. Unlike adults, the fetal right ventricle has the main circulating function. As the right ventricular volume continues to increase, the increased RCO with gestational age can meet the oxygen and nutrient demands for fetal development. In contrast, due to the anatomic and structural characteristics of the right ventricle, which has an irregular shape with the regulation bundle at the apex as well as a rougher endocardial surface compared with the left ventricle, it is particularly important to find an accurate and reliable method to measure fetal right ventricular volume and cardiac function indices.

This study had some shortcomings, such as small sample size and the manual delineation of the lining of the heart in post-processing, which requires clear endocardial imaging and multiple measurements to obtain an average value and reduce measurement errors as far as possible. Due to the rough endocardium surface of the right ventricle, measurement error is inevitable. In addition, there is currently no gold standard for the assessment of fetal heart function to compare the data obtained by iSTIC technology.

In summary, iSTIC technology can be used for the quantitative measurement of fetal right ventricular volume and the evaluation of right ventricular systolic function, which has shown a number of advantages, and the application of iSTIC technology in

Table 2 Measured normal fetal right ventricular end-diastolic volume, right ventricular end-systolic volume, right stroke volume, right cardiac output, and right ejection fraction values with gestational ages between 22 and 35⁺6 wk

Gestational age, wk	Case	REDV, mL	RESV, mL	RSV, mL	RCO, mL/min	REF
22–23 ⁺ 6	20	0.99 ± 0.34	0.43 ± 0.18	0.62 ± 0.29	92.23 ± 40.67	0.58 ± 0.12
24–25 ⁺ 6	24	1.43 ± 0.28	0.55 ± 0.15	0.90 ± 0.18	132.10 ± 26.61	0.62 ± 0.58
26–27 ⁺ 6	20	1.66 ± 0.39	0.69 ± 0.20	0.98 ± 0.22	149.25 ± 34.68	0.59 ± 0.06
28–29 ⁺ 6	16	2.06 ± 0.53	0.77 ± 0.15	1.29 ± 0.44	181.12 ± 57.03	0.61 ± 0.06
30–31 ⁺ 6	18	2.61 ± 0.33	1.00 ± 0.14	1.60 ± 0.26	232.58 ± 45.60	0.61 ± 0.05
32–33 ⁺ 6	15	2.98 ± 0.49	1.10 ± 0.17	1.88 ± 0.39	275.86 ± 55.43	0.63 ± 0.04
34–35 ⁺ 6	10	3.69 ± 0.36	1.36 ± 0.22	2.33 ± 0.18	335.83 ± 32.75	0.63 ± 0.03

REDV: Right ventricular end-diastolic volume; RESV: Right ventricular end-systolic volume; RSV: Right stroke volume; RCO: Right cardiac output; REF: Right ejection fraction. $RSV = REDV - RESV$; $RCO = RSV \times$ fetal heart rate; $REF = RSV / REDV$.

prenatal diagnosis is worthy of further study and discussion.

Table 3 Consistency between the same observer and different observers

	<i>n</i>	Observer A	Observer B	<i>t</i>	<i>P</i>	<i>r</i>	<i>P</i>	ICC	95%CI
REDV	30	1.54 ± 0.82	1.51 ± 0.79	1.417	0.167	0.989	< 0.001	0.988	0.975-0.994
RESV	30	0.62 ± 0.36	0.61 ± 0.37	0.384	0.704	0.951	< 0.001	0.951	0.900-0.977
		First measurement	Second measurement						
REDV	30	1.54 ± 0.81	1.54 ± 0.84	0.196	0.846	0.990	< 0.001	0.989	0.978-0.995
RESV	30	0.63 ± 0.36	0.61 ± 0.37	1.731	0.094	0.980	< 0.001	0.978	0.955-0.989

REDV: Right ventricular end-diastolic volume; RESV: Right ventricular end-systolic volume; ICC: Intraclass correlation coefficients.

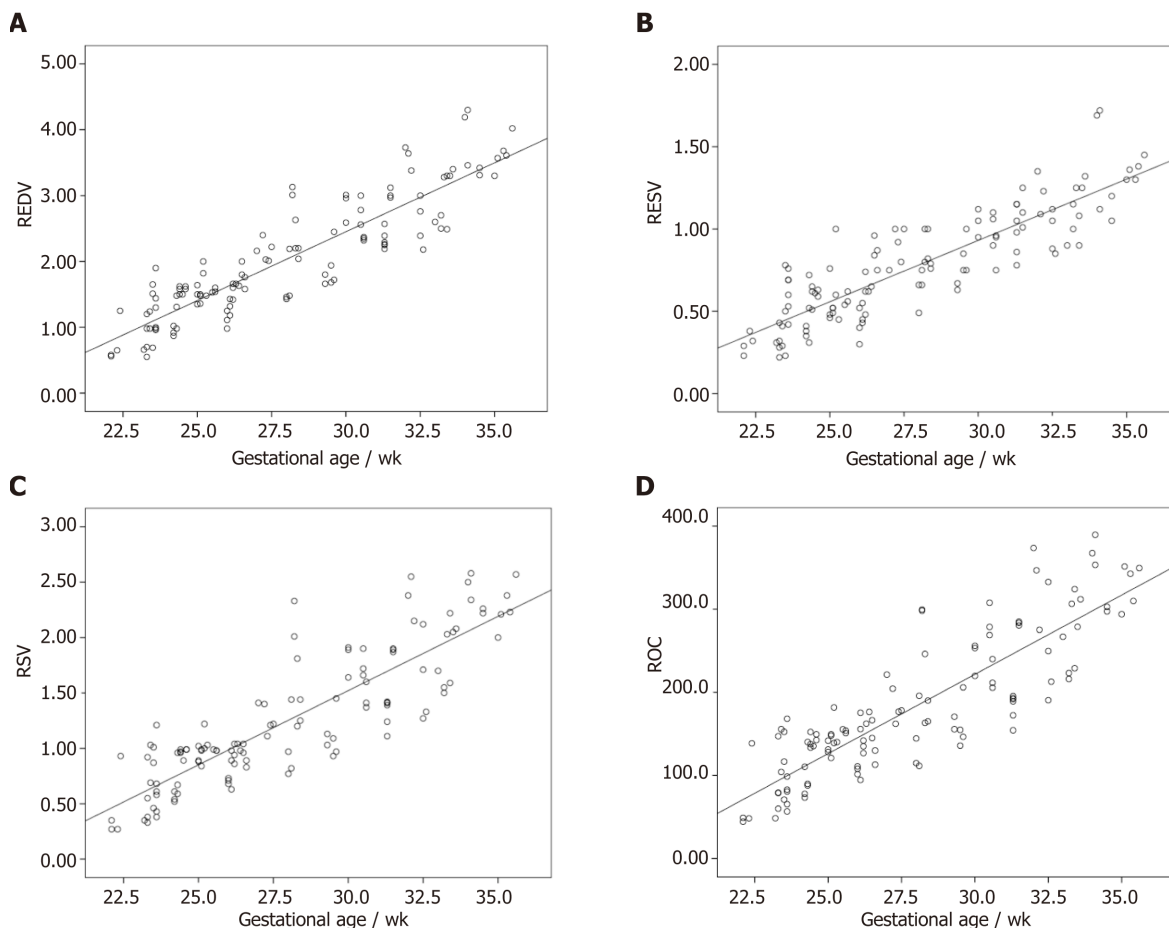


Figure 2 Correlations. A: Correlation between right ventricular end diastolic volume and gestational age (wk); B: Correlation between right ventricular end systolic volume and gestational age (wk); C: Correlation between right ventricular stroke volume and gestational age (wk); D: Correlation between right ventricular cardiac output and gestational age (wk). REDV: Right ventricular end-diastolic volume; RESV: Right ventricular end-systolic volume; RSV: Right stroke volume; RCO: Right cardiac output.

ARTICLE HIGHLIGHTS

Research background

Heart defects are the most common congenital malformations in fetuses. Fetal cardiac structure and function abnormalities lead to changes in ventricular volume. As ventricular volume is an important index for evaluating fetal cardiovascular development, an effective and reliable method for measuring fetal ventricular volume and cardiac function is necessary for accurate ultrasonic diagnosis and effective clinical treatment. The new intelligent spatiotemporal image correlation (iSTIC) technology acquires high-resolution volumetric images. Numerous studies have focused on fetal heart function which have not been widely accepted. The iSTIC technique was used to measure right ventricular volume in 123 normal fetuses, and to evaluate right ventricular systolic function to provide a new method for more accurate and convenient evaluation of fetal heart function.

Research motivation

The iSTIC technique was used to provide a new method for more accurate and convenient evaluation of fetal heart function.

Research objectives

One hundred twenty-three healthy gravidas with singleton gestations who visited our hospital for prenatal ultrasonography between October 2014 and September 2015 were included in the study.

Research methods

The women were asked to lie flat, and a fetal echo program was begun with transabdominal scanning using an X6-1 probe. Using a 3D/4D iSTIC technology model for a 4-chamber view of the fetal heart, the 3D/4D sampling frame location was adjusted and the sampling range assured 3D/4D volume data acquisition and the sampling frame included the entire fetal heart. The fetal heart rate was measured and recorded after completion of data acquisition.

Research results

The changes in normal fetal right ventricular end-diastolic volume, right ventricular end-systolic volume, right stroke volume, and right cardiac output with gestational age showed significant linear correlations. Right ejection fraction did not change as gestational age increased, was relatively constant throughout the entire pregnancy, and was not significantly correlated with gestational age.

Research conclusions

iSTIC technology can be used for the quantitative measurement of fetal right ventricular volume and the evaluation of right ventricular systolic function.

Research perspectives

iSTIC can generate real-time 3D images, only requires 2 s, and is the best method now. The direction of the future research is to improve the scanning time.

REFERENCES

- 1 **Carvalho JS**, Mavrides E, Shinebourne EA, Campbell S, Thilaganathan B. Improving the effectiveness of routine prenatal screening for major congenital heart defects. *Heart* 2002; **88**: 387-391 [PMID: 12231598 DOI: 10.1136/heart.88.4.387]
- 2 **Tedesco GD**, de Souza Bezerra M, Barros FS, Martins WP, Nardoza LM, Carrilho MC, Moron AF, Carvalho FH, Rolo LC, Araujo Júnior E. Reference Ranges of Fetal Cardiac Biometric Parameters Using Three-Dimensional Ultrasound with Spatiotemporal Image Correlation M Mode and Their Applicability in Congenital Heart Diseases. *Pediatr Cardiol* 2017; **38**: 271-279 [PMID: 27878625 DOI: 10.1007/s00246-016-1509-1]
- 3 **Godfrey ME**, Messing B, Cohen SM, Valsky DV, Yagel S. Functional assessment of the fetal heart: a review. *Ultrasound Obstet Gynecol* 2012; **39**: 131-144 [PMID: 21611999 DOI: 10.1002/uog.9064]
- 4 **Simioni C**, Nardoza LM, Araujo Júnior E, Rolo LC, Terasaka OA, Zamith MM, Moron AF. Fetal cardiac function assessed by spatio-temporal image correlation. *Arch Gynecol Obstet* 2011; **284**: 253-260 [PMID: 21188403 DOI: 10.1007/s00404-010-1813-6]
- 5 **Simioni C**, Araujo Júnior E, Martins WP, Rolo LC, Rocha LA, Nardoza LM, Moron AF. Fetal cardiac output and ejection fraction by spatio-temporal image correlation (STIC): comparison between male and female fetuses. *Rev Bras Cir Cardiovasc* 2012; **27**: 275-282 [PMID: 22996979 DOI: 10.5935/1678-9741.20120058]
- 6 **Simioni C**, Nardoza LM, Araujo Júnior E, Rolo LC, Zamith M, Caetano AC, Moron AF. Heart stroke volume, cardiac output, and ejection fraction in 265 normal fetus in the second half of gestation assessed by 4D ultrasound using spatio-temporal image correlation. *J Matern Fetal Neonatal Med* 2011; **24**: 1159-1167 [PMID: 21250911 DOI: 10.3109/14767058.2010.545921]
- 7 **Rolo LC**, Marcondes Machado Nardoza L, Araujo Júnior E, Simioni C, Maccagnano Zamith M, Fernandes Moron A. Reference curve of the fetal ventricular septum area by the STIC method: preliminary study. *Arq Bras Cardiol* 2011; **96**: 386-392 [PMID: 21468533 DOI: 10.1590/s0066-782x2011005000036]
- 8 **Araujo Júnior E**, Rolo LC, Rocha LA, Nardoza LM, Moron AF. The value of 3D and 4D assessments of the fetal heart. *Int J Womens Health* 2014; **6**: 501-507 [PMID: 24868174 DOI: 10.2147/IJWH.S47074]
- 9 **Adler DG**, Gabr M, Taylor LJ, Witt B, Pleskow D. Initial report of transesophageal EUS-guided intraparenchymal lung mass core biopsy: Findings and outcomes in two cases. *Endosc Ultrasound* 2018; **7**: 413-417 [PMID: 29786035 DOI: 10.4103/eus.eus_13_18]
- 10 **Sawada H**, Chen JZ, Wright BC, Sheppard MB, Lu HS, Daugherty A. Heterogeneity of Aortic Smooth Muscle Cells: A Determinant for Regional Characteristics of Thoracic Aortic Aneurysms? *J Transl Int Med* 2018; **6**: 93-96 [PMID: 30425944 DOI: 10.2478/jtim-2018-0023]
- 11 **Castro-Pocas FM**, Araújo TP, Ferreira ML, Saraiva MM. The role of endoscopic ultrasound in a case of lung cancer with jaundice. *Endosc Ultrasound* 2018; **7**: 279-281 [PMID: 27824020 DOI: 10.4103/2303-9027.193570]
- 12 **Das UN**. Is Aortic Aneurysm Preventable? *J Transl Int Med* 2017; **5**: 72-78 [PMID: 28721338 DOI: 10.1515/jtim-2017-0022]
- 13 **Qin C**, Wei B, Ma Z. Endobronchial ultrasound: Echoing in the field of pediatrics. *Endosc Ultrasound* 2018; **7**: 371-375 [PMID: 30289110 DOI: 10.4103/eus.eus_40_18]
- 14 **Wang J**, Ouyang N, Qu L, Lin T, Zhang X, Yu Y, Jiang C, Xie L, Wang L, Wang Z, Ren S, Chen S, Huang J, Liu F, Huang W, Qin X. Effect of MTHFR A1298C and MTRR A66G Genetic Mutations on Homocysteine Levels in the Chinese Population: A Systematic Review and Meta-analysis. *J Transl Int Med* 2017; **5**: 220-229 [PMID: 29340279 DOI: 10.1515/jtim-2017-0037]

- 15 **Sahai AV.** EUS is trending! *Endosc Ultrasound* 2018; **7**: 353-355 [PMID: [30168481](#) DOI: [10.4103/eus.eus_22_18](#)]
- 16 **Gómez O,** Soveral I, Bennasar M, Crispi F, Masoller N, Marimon E, Bartrons J, Gratacós E, Martínez JM. Accuracy of Fetal Echocardiography in the Differential Diagnosis between Truncus Arteriosus and Pulmonary Atresia with Ventricular Septal Defect. *Fetal Diagn Ther* 2016; **39**: 90-99 [PMID: [26113195](#) DOI: [10.1159/000433430](#)]
- 17 **Bravo-Valenzuela NJ,** Peixoto AB, Nardoza LM, Souza AS, Araujo Júnior E. Applicability and technical aspects of two-dimensional ultrasonography for assessment of fetal heart function. *Med Ultrason* 2017; **19**: 94-101 [PMID: [28180202](#) DOI: [10.11152/mu-934](#)]
- 18 **He Y,** Wang J, Gu X, Zhang Y, Han J, Liu X, Li Z. Application of spatio-temporal image correlation technology in the diagnosis of fetal cardiac abnormalities. *Exp Ther Med* 2013; **5**: 1637-1642 [PMID: [23837046](#) DOI: [10.3892/etm.2013.1060](#)]
- 19 **DeVore GR.** Assessing fetal cardiac ventricular function. *Semin Fetal Neonatal Med* 2005; **10**: 515-541 [PMID: [16257825](#) DOI: [10.1016/j.siny.2005.08.009](#)]
- 20 **Araujo Júnior E,** Tonni G, Bravo-Valenzuela NJ, Da Silva Costa F, Meagher S. Assessment of Fetal Congenital Heart Diseases by 4-Dimensional Ultrasound Using Spatiotemporal Image Correlation: Pictorial Review. *Ultrasound Q* 2018; **34**: 11-17 [PMID: [29112643](#) DOI: [10.1097/RUQ.0000000000000328](#)]
- 21 **Rocha LA,** Rolo LC, Barros FS, Nardoza LM, Moron AF, Araujo Júnior E. Assessment of Quality of Fetal Heart Views by 3D/4D Ultrasonography Using Spatio-Temporal Image Correlation in the Second and Third Trimesters of Pregnancy. *Echocardiography* 2015; **32**: 1015-1021 [PMID: [25231765](#) DOI: [10.1111/echo.12743](#)]
- 22 **Rolo LC,** Nardoza LM, Araujo Júnior E, Simioni C, Zamith MM, Moron AF. [Assessment of the fetal mitral and tricuspid valves areas development by three-dimensional ultrasonography]. *Rev Bras Ginecol Obstet* 2010; **32**: 426-432 [PMID: [21271147](#) DOI: [10.1590/S0100-72032010000900003](#)]
- 23 **Zhang J,** Zhou Q, Peng Q, Zhao Y, Gong Z. [Assessment of the right ventricle function of fetus by spatio-temporal image correlation]. *Zhong Nan Da Xue Xue Bao Yi Xue Ban* 2015; **40**: 486-494 [PMID: [26032069](#) DOI: [10.11817/j.issn.1672-7347.2015.05.005](#)]
- 24 **Xiong Y,** Liu T, Wu Y, Xu JF, Ting YH, Yeung Leung T, Lau TK. Comparison of real-time three-dimensional echocardiography and spatiotemporal image correlation in assessment of fetal interventricular septum. *J Matern Fetal Neonatal Med* 2012; **25**: 2333-2338 [PMID: [22642553](#) DOI: [10.3109/14767058.2012.695822](#)]
- 25 **Xiong Y,** Liu T, Gan HJ, Wu Y, Xu JF, Ting YH, Leung TY, Lau TK. Detection of the fetal conotruncal anomalies using real-time three-dimensional echocardiography with live xPlane imaging of the fetal ductal arch view. *Prenat Diagn* 2013; **33**: 462-466 [PMID: [23494925](#) DOI: [10.1002/pd.4088](#)]
- 26 **Zhang J,** Zhou Q, Zhao Y, Peng Q, Gong Z, Long X. Evaluation of right ventricular function in fetal hypoplastic left heart syndrome using spatio-temporal image correlation (STIC). *Cardiovasc Ultrasound* 2016; **14**: 12 [PMID: [27066831](#) DOI: [10.1186/s12947-016-0056-5](#)]
- 27 **Xiong Y,** Chen M, Chan LW, Ting YH, Fung TY, Leung TY, Lau TK. Scan the fetal heart by real-time three-dimensional echocardiography with live xPlane imaging. *J Matern Fetal Neonatal Med* 2012; **25**: 324-328 [PMID: [21574902](#) DOI: [10.3109/14767058.2011.575904](#)]
- 28 **Lu Y,** Yang T, Luo H, Deng F, Cai Q, Sun W, Song H. Visualization and quantitation of fetal movements by real-time three-dimensional ultrasound with live xPlane imaging in the first trimester of pregnancy. *Croat Med J* 2016; **57**: 474-481 [PMID: [27815938](#) DOI: [10.3325/cmj.2016.57.474](#)]
- 29 **Zhu M,** Ashraf M, Zhang Z, Streiff C, Shimada E, Kimura S, Schaller T, Song X, Sahn DJ. Real Time Three-Dimensional Echocardiographic Evaluations of Fetal Left Ventricular Stroke Volume, Mass, and Myocardial Strain: In Vitro and In Vivo Experimental Study. *Echocardiography* 2015; **32**: 1697-1706 [PMID: [25865121](#) DOI: [10.1111/echo.12939](#)]
- 30 **Meyer-Wittkopf M,** Cole A, Cooper SG, Schmidt S, Sholler GF. Three-dimensional quantitative echocardiographic assessment of ventricular volume in healthy human fetuses and in fetuses with congenital heart disease. *J Ultrasound Med* 2001; **20**: 317-327 [PMID: [11316309](#) DOI: [10.1046/j.1469-0705.2001.0180S1019.x](#)]
- 31 **Blessberger H,** Binder T. NON-invasive imaging: Two dimensional speckle tracking echocardiography: basic principles. *Heart* 2010; **96**: 716-722 [PMID: [20424157](#) DOI: [10.1136/hrt.2007.141002](#)]
- 32 **Blessberger H,** Binder T. Two dimensional speckle tracking echocardiography: clinical applications. *Heart* 2010; **96**: 2032-2040 [PMID: [21088126](#) DOI: [10.1136/hrt.2010.199885](#)]
- 33 **Zhao L,** Wu Y, Chen S, Ren Y, Chen P, Niu J, Li C, Sun K. Feasibility Study on Prenatal Cardiac Screening Using Four-Dimensional Ultrasound with Spatiotemporal Image Correlation: A Multicenter Study. *PLoS One* 2016; **11**: e0157477 [PMID: [27314236](#) DOI: [10.1371/journal.pone.0157477](#)]
- 34 **Rolo LC,** Santana EF, da Silva PH, Costa Fda S, Nardoza LM, Tonni G, Moron AF, Araujo Júnior E. Fetal cardiac interventricular septum: volume assessment by 3D/4D ultrasound using spatio-temporal image correlation (STIC) and virtual organ computer-aided analysis (VOCAL). *J Matern Fetal Neonatal Med* 2015; **28**: 1388-1393 [PMID: [25134922](#) DOI: [10.3109/14767058.2014.955005](#)]
- 35 **Hamill N,** Yeo L, Romero R, Hassan SS, Myers SA, Mittal P, Kusanovic JP, Balasubramaniam M, Chaiworapongsa T, Vaisbuch E, Espinoza J, Gotsch F, Goncalves LF, Lee W. Fetal cardiac ventricular volume, cardiac output, and ejection fraction determined with 4-dimensional ultrasound using spatiotemporal image correlation and virtual organ computer-aided analysis. *Am J Obstet Gynecol* 2011; **205**: 76.e1-76.10 [PMID: [21531373](#) DOI: [10.1016/j.ajog.2011.02.028](#)]
- 36 **Messing B,** Cohen SM, Valsky DV, Shen O, Rosenak D, Lipschuetz M, Yagel S. Fetal heart ventricular mass obtained by STIC acquisition combined with inversion mode and VOCAL. *Ultrasound Obstet Gynecol* 2011; **38**: 191-197 [PMID: [21370304](#) DOI: [10.1002/uog.8980](#)]
- 37 **Barros FS,** Moron AF, Rolo LC, Rocha LA, Martins WP, Tonni G, Nardoza LM, Araujo Júnior E. Fetal myocardial wall area: constructing a reference range by means of spatiotemporal image correlation in the rendering mode. *Fetal Diagn Ther* 2015; **37**: 44-50 [PMID: [25095802](#) DOI: [10.1159/000363653](#)]
- 38 **Turan S,** Turan OM, Desai A, Harman CR, Baschat AA. First-trimester fetal cardiac examination using spatiotemporal image correlation, tomographic ultrasound and color Doppler imaging for the diagnosis of complex congenital heart disease in high-risk patients. *Ultrasound Obstet Gynecol* 2014; **44**: 562-567 [PMID: [24585667](#) DOI: [10.1002/uog.13341](#)]
- 39 **Tanis JC,** Mohammed N, Bennasar M, Martinez JM, Bijns B, Crispi F, Gratacos E. Online versus offline spatiotemporal image correlation (STIC) M-mode for the evaluation of cardiac longitudinal annular displacement in fetal growth restriction. *J Matern Fetal Neonatal Med* 2018; **31**: 1845-1850 [PMID: [30168481](#) DOI: [10.4103/eus.eus_22_18](#)]

- 28508694 DOI: [10.1080/14767058.2017.1330408](https://doi.org/10.1080/14767058.2017.1330408)]
- 40 **Yagel S**, Cohen SM, Shapiro I, Valsky DV. 3D and 4D ultrasound in fetal cardiac scanning: a new look at the fetal heart. *Ultrasound Obstet Gynecol* 2007; **29**: 81-95 [PMID: [17200988](https://pubmed.ncbi.nlm.nih.gov/17200988/) DOI: [10.1002/uog.3912](https://doi.org/10.1002/uog.3912)]
- 41 **Tedesco GD**, de Souza Bezerra M, Barros FSB, Martins WP, Nardozza LMM, Mattar R, Moron AF, Rolo LC, Araujo Júnior E. Fetal Heart Function by Tricuspid Annular Plane Systolic Excursion and Ventricular Shortening Fraction Using STIC M-Mode: Reference Ranges and Validation. *Am J Perinatol* 2017; **34**: 1354-1361 [PMID: [28571079](https://pubmed.ncbi.nlm.nih.gov/28571079/) DOI: [10.1055/s-0037-1603652](https://doi.org/10.1055/s-0037-1603652)]
- 42 **Messing B**, Gilboa Y, Lipschuetz M, Valsky DV, Cohen SM, Yagel S. Fetal tricuspid annular plane systolic excursion (f-TAPSE): evaluation of fetal right heart systolic function with conventional M-mode ultrasound and spatiotemporal image correlation (STIC) M-mode. *Ultrasound Obstet Gynecol* 2013; **42**: 182-188 [PMID: [23288668](https://pubmed.ncbi.nlm.nih.gov/23288668/) DOI: [10.1002/uog.12375](https://doi.org/10.1002/uog.12375)]
- 43 **Acar P**, Battle L, Dulac Y, Peyre M, Dubourdieu H, Hascoet S, Groussolles M, Vayssière C. Real-time three-dimensional foetal echocardiography using a new transabdominal xMATRIX array transducer. *Arch Cardiovasc Dis* 2014; **107**: 4-9 [PMID: [24364911](https://pubmed.ncbi.nlm.nih.gov/24364911/) DOI: [10.1016/j.acvd.2013.10.003](https://doi.org/10.1016/j.acvd.2013.10.003)]
- 44 **Liu J**, Wang Y, Zhao H, Liu W. Spatio-temporal image correlation rendering mode visualizes the specific location and surrounding structure of ventricular septal defect. *Clin Anat* 2019; **32**: 408-420 [PMID: [30623992](https://pubmed.ncbi.nlm.nih.gov/30623992/) DOI: [10.1002/ca.23330](https://doi.org/10.1002/ca.23330)]



Published By Baishideng Publishing Group Inc
7041 Koll Center Parkway, Suite 160, Pleasanton, CA 94566, USA
Telephone: +1-925-2238242
Fax: +1-925-2238243
E-mail: bpgoffice@wjgnet.com
Help Desk: <https://www.f6publishing.com/helpdesk>
<https://www.wjgnet.com>

