

World Journal of *Gastroenterology*

World J Gastroenterol 2018 June 21; 24(23): 2413-2536





REVIEW

- 2413 Recent advances in non-invasive magnetic resonance imaging assessment of hepatocellular carcinoma
Ippolito D, Inchingolo R, Grazioli L, Drago SG, Nardella M, Gatti M, Faletti R
- 2427 Taking advantage of the potential of mesenchymal stromal cells in liver regeneration: Cells and extracellular vesicles as therapeutic strategies
Fiore EJ, Domínguez LM, Bayo J, García MG, Mazzolini GD
- 2441 Feasibility of using marginal liver grafts in living donor liver transplantation
Lan X, Zhang H, Li HY, Chen KF, Liu F, Wei YG, Li B

MINIREVIEWS

- 2457 Vedolizumab for inflammatory bowel disease: From randomized controlled trials to real-life evidence
Scribano ML

ORIGINAL ARTICLE

Basic Study

- 2468 Dynamic alterations in the gut microbiota and metabolome during the development of methionine-choline-deficient diet-induced nonalcoholic steatohepatitis
Ye JZ, Li YT, Wu WR, Shi D, Fang DQ, Yang LY, Bian XY, Wu JJ, Wang Q, Jiang XW, Peng CG, Ye WC, Xia PC, Li LJ

Case Control Study

- 2482 Association of twelve polymorphisms in three onco-lncRNA genes with hepatocellular cancer risk and prognosis: A case-control study
Wang BG, Xu Q, Lv Z, Fang XX, Ding HX, Wen J, Yuan Y

Retrospective Cohort Study

- 2491 Subtotal colonic bypass plus colostomy with antiperistaltic cecoproctostomy for the treatment of slow transit constipation in an aged population: A retrospective control study
Yang Y, Cao YL, Wang WH, Zhang YY, Zhao N, Wei D

Retrospective Study

- 2501 Transarterial embolization and low-dose continuous hepatic arterial infusion chemotherapy with oxaliplatin and raltitrexed for hepatocellular carcinoma with major portal vein tumor thrombus
Zhu LZ, Xu S, Qian HL

Clinical Trials Study

- 2508 Clinical and prognostic significance of Raf kinase inhibitory protein expression in gastrointestinal stromal tumors
Wang Y, Chen JJ, Wang XF, Wang Q

META-ANALYSIS

- 2518 Comparing outcomes for endoscopic submucosal dissection between Eastern and Western countries: A systematic review and meta-analysis
Daoud DC, Suter N, Durand M, Bouin M, Faulques B, von Renteln D

ABOUT COVER

Editorial board member of *World Journal of Gastroenterology*, Tatsuo Kanda, MD, PhD, Associate Professor, Division of Gastroenterology and Hepatology, Department of Internal Medicine, Nihon University School of Medicine, Tokyo 173-8610, Japan

AIMS AND SCOPE

World Journal of Gastroenterology (*World J Gastroenterol*, *WJG*, print ISSN 1007-9327, online ISSN 2219-2840, DOI: 10.3748) is a peer-reviewed open access journal. *WJG* was established on October 1, 1995. It is published weekly on the 7th, 14th, 21st, and 28th each month. The *WJG* Editorial Board consists of 642 experts in gastroenterology and hepatology from 59 countries.

The primary task of *WJG* is to rapidly publish high-quality original articles, reviews, and commentaries in the fields of gastroenterology, hepatology, gastrointestinal endoscopy, gastrointestinal surgery, hepatobiliary surgery, gastrointestinal oncology, gastrointestinal radiation oncology, gastrointestinal imaging, gastrointestinal interventional therapy, gastrointestinal infectious diseases, gastrointestinal pharmacology, gastrointestinal pathophysiology, gastrointestinal pathology, evidence-based medicine in gastroenterology, pancreatology, gastrointestinal laboratory medicine, gastrointestinal molecular biology, gastrointestinal immunology, gastrointestinal microbiology, gastrointestinal genetics, gastrointestinal translational medicine, gastrointestinal diagnostics, and gastrointestinal therapeutics. *WJG* is dedicated to become an influential and prestigious journal in gastroenterology and hepatology, to promote the development of above disciplines, and to improve the diagnostic and therapeutic skill and expertise of clinicians.

INDEXING/ABSTRACTING

World Journal of Gastroenterology (*WJG*) is now indexed in Current Contents[®]/Clinical Medicine, Science Citation Index Expanded (also known as SciSearch[®]), Journal Citation Reports[®], Index Medicus, MEDLINE, PubMed, PubMed Central and Directory of Open Access Journals. The 2017 edition of Journal Citation Reports[®] cites the 2016 impact factor for *WJG* as 3.365 (5-year impact factor: 3.176), ranking *WJG* as 29th among 79 journals in gastroenterology and hepatology (quartile in category Q2).

EDITORS FOR THIS ISSUE

Responsible Assistant Editor: *Xiang Li*
Responsible Electronic Editor: *Yan Huang*
Proofing Editor-in-Chief: *Lian-Sheng Ma*

Responsible Science Editor: *Xue-Jiao Wang*
Proofing Editorial Office Director: *Ze-Mao Gong*

NAME OF JOURNAL
World Journal of Gastroenterology

ISSN
ISSN 1007-9327 (print)
ISSN 2219-2840 (online)

LAUNCH DATE
October 1, 1995

FREQUENCY
Weekly

EDITORS-IN-CHIEF
Damian Garcia-Olmo, MD, PhD, Doctor, Professor, Surgeon, Department of Surgery, Universidad Autonoma de Madrid; Department of General Surgery, Fundacion Jimenez Diaz University Hospital, Madrid 28040, Spain

Stephen C Strom, PhD, Professor, Department of Laboratory Medicine, Division of Pathology, Karolinska Institutet, Stockholm 141-86, Sweden

Andrzej S Tarnawski, MD, PhD, DSc (Med), Professor of Medicine, Chief Gastroenterology, VA Long Beach Health Care System, University of California, Irvine, CA, 5901 E. Seventh Str., Long Beach,

CA 90822, United States

EDITORIAL BOARD MEMBERS
All editorial board members resources online at <http://www.wjgnet.com/1007-9327/editorialboard.htm>

EDITORIAL OFFICE
Ze-Mao Gong, Director
World Journal of Gastroenterology
Baishideng Publishing Group Inc
7901 Stoneridge Drive, Suite 501,
Pleasanton, CA 94588, USA
Telephone: +1-925-2238242
Fax: +1-925-2238243
E-mail: editorialoffice@wjgnet.com
Help Desk: <http://www.f6publishing.com/helpdesk>
<http://www.wjgnet.com>

PUBLISHER
Baishideng Publishing Group Inc
7901 Stoneridge Drive, Suite 501,
Pleasanton, CA 94588, USA
Telephone: +1-925-2238242
Fax: +1-925-2238243
E-mail: bpgoffice@wjgnet.com
Help Desk: <http://www.f6publishing.com/helpdesk>
<http://www.wjgnet.com>

PUBLICATION DATE
June 21, 2018

COPYRIGHT
© 2018 Baishideng Publishing Group Inc. Articles published by this Open-Access journal are distributed under the terms of the Creative Commons Attribution Non-commercial License, which permits use, distribution, and reproduction in any medium, provided the original work is properly cited, the use is non commercial and is otherwise in compliance with the license.

SPECIAL STATEMENT
All articles published in journals owned by the Baishideng Publishing Group (BPG) represent the views and opinions of their authors, and not the views, opinions or policies of the BPG, except where otherwise explicitly indicated.

INSTRUCTIONS TO AUTHORS
Full instructions are available online at <http://www.wjgnet.com/bpg/gerinfo/204>

ONLINE SUBMISSION
<http://www.f6publishing.com>

Feasibility of using marginal liver grafts in living donor liver transplantation

Xiang Lan, Hua Zhang, Hong-Yu Li, Ke-Fei Chen, Fei Liu, Yong-Gang Wei, Bo Li

Xiang Lan, Hua Zhang, Ke-Fei Chen, Fei Liu, Yong-Gang Wei, Bo Li, Department of Liver Surgery and Liver Transplantation Center, West China Hospital of Sichuan University, Chengdu 610041, Sichuan Province, China

Hong-Yu Li, Department of Pancreatic Surgery, West China Hospital of Sichuan University, Chengdu 610041, Sichuan Province, China

ORCID number: Xiang Lan (0000-0002-5626-0106); Hua Zhang (0000-0002-5776-8286); Hong-Yu Li (0000-0002-9614-5700); Ke-Fei Chen (0000-0003-1657-0094); Fei Liu (0000-0002-9650-1576); Yong-Gang Wei (0000-0001-8776-289X); Bo Li (0000-0002-1411-3722).

Author contributions: Lan X and Zhang H contributed equally to this study and participated in the research design and manuscript preparation; Li HY, Chen KF, and Liu F generated the tables and figures; and Li B and Wei YG revised the article.

Conflict-of-interest statement: All authors declare that there are no conflicts of interest in this article.

Open-Access: This article is an open-access article which was selected by an in-house editor and fully peer-reviewed by external reviewers. It is distributed in accordance with the Creative Commons Attribution Non Commercial (CC BY-NC 4.0) license, which permits others to distribute, remix, adapt, build upon this work non-commercially, and license their derivative works on different terms, provided the original work is properly cited and the use is non-commercial. See: <http://creativecommons.org/licenses/by-nc/4.0/>

Manuscript source: Invited manuscript

Correspondence to: Bo Li, MD, PhD, Professor, Department of Liver Surgery and Liver Transplantation Center, West China Hospital of Sichuan University, 37 Guoxue Road, Wuhou District, Chengdu 610041, Sichuan Province, China. hxcdlibo@126.com
Telephone: +86-18980601470

Received: March 25, 2018

Peer-review started: March 26, 2018

First decision: April 18, 2018

Revised: May 4, 2018

Accepted: May 18, 2018

Article in press: May 18, 2018

Published online: June 21, 2018

Abstract

Liver transplantation (LT) is one of the most effective treatments for end-stage liver disease caused by related risk factors when liver resection is contraindicated. Additionally, despite the decrease in the prevalence of hepatitis B virus (HBV) over the past two decades, the absolute number of HBsAg-positive people has increased, leading to an increase in HBV-related liver cirrhosis and hepatocellular carcinoma. Consequently, a large demand exists for LT. While the wait time for patients on the donor list is, to some degree, shorter due to the development of living donor liver transplantation (LDLT), there is still a shortage of liver grafts. Furthermore, recipients often suffer from emergent conditions, such as liver dysfunction or even hepatic encephalopathy, which can lead to a limited choice in grafts. To expand the pool of available liver grafts, one option is the use of organs that were previously considered "unusable" by many, which are often labeled "marginal" organs. Many previous studies have reported on the possibilities of using marginal grafts in orthotopic LT; however, there is still a lack of discussion on this topic, especially regarding the feasibility of using marginal grafts in LDLT. Therefore, the present review aimed to summarize the feasibility of using marginal liver grafts for LDLT and discuss the possibility of expanding the application of these grafts.

Key words: Marginal liver grafts; Living donor liver transplantation; Liver transplant waiting lists; Small-for-size grafts; Older donors; ABO-incompatible; Steatosis; Chronic hepatitis

© The Author(s) 2018. Published by Baishideng Publishing

Group Inc. All rights reserved.

Core tip: There are few reviews concerning the feasibility of using marginal liver grafts in living donor liver transplantation (LDLT). We reviewed more than 300 articles, summarized new findings, and confirmed that marginal grafts are a feasible option for expanding options for patients on liver transplant waiting lists in emergency situations in LDLT (*e.g.*, liver failure or hepatic encephalopathy). However, such grafts place the recipients at greater risk for adverse events. Although some indispensable treatments are needed to address the deficiencies of these grafts, recipients can receive a favorable prognosis, similar to that of patients who receive standard liver grafts, under these treatments.

Lan X, Zhang H, Li HY, Chen KF, Liu F, Wei YG, Li B. Feasibility of using marginal liver grafts in living donor liver transplantation. *World J Gastroenterol* 2018; 24(23): 2441-2456 Available from: URL: <http://www.wjgnet.com/1007-9327/full/v24/i23/2441.htm> DOI: <http://dx.doi.org/10.3748/wjg.v24.i23.2441>

INTRODUCTION

The high mortality of patients on waiting lists due to the shortage of cadaveric donors is a major challenge in liver transplantation (LT)^[1]. This challenge has led to the emergence of living donor liver transplantation (LDLT) after the first successful procedure in 1989^[2,3]. However, following a sharp increase in recipients who suffer from emergency situations, the wide gap between the demands of patients and suitable living donors is gradually increasing^[4,5]. Therefore, the transplantation community has focused on the search for strategies to increase the pool of available liver grafts, including the use of organs that were previously considered “unusable” by many and often labeled “marginal” organs^[6].

An accepted definition of marginal donors remains unclear in LDLT. These expanded-criteria grafts have the potential to increase the risk of poor graft function or primary nonfunction and are referred to as “marginal” organs^[7]. In this review, we define marginal liver grafts for LDLT as small-for-size grafts, older donors, moderate or severe steatosis of liver grafts, chronic hepatitis, and grafts with tumors. The survival of recipients with marginal organs can be the same as that of patients with high-quality liver grafts under proper treatment^[8].

Many previous studies have reported on the possibilities of using marginal grafts in orthotopic liver transplantation (OLT), but there is still a lack of discussion on this topic, especially regarding the feasibility of using marginal grafts in LDLT. Therefore, the present review aimed to summarize and discuss

the possibility of expanding the application of marginal grafts in LDLT.

SMALL-FOR-SIZE GRAFTS IN LDLT

Choosing to use a liver graft can be a remarkably complex decision. There is an increasing trend of patients dying while on waiting lists due to the everyday risk of death or serious complications while waiting; this risk must be balanced against the use of a marginal graft, which may not be feasible. Size mismatching between the graft and the recipient is a critical predictor of the so-called “marginal liver grafts” in LDLT recipients. A small-for-size graft has become the main reason for unsuitability for liver donation in some transplantation centers^[9]. The most common index with which to evaluate graft size matching is the graft-to-recipient weight ratio (GRWR) or graft volume (GV)/standard liver volume (SLV). The GRWR was first reported to require a safety range of above 1%; otherwise, the rate of graft survival could decrease^[10]. With the increased demand for LDLT and the improvement of surgical techniques, however, many expanded-criteria grafts are used. Accordingly, the accepted arbitrary requirement for GRWR was reduced to 0.8%, and the GV/SLV value was 40%^[11,12]. As many transplantation centers accumulated experience on small-for-size grafts for LDLT, grafts with a GRWR < 0.8% were used and reported to be as safe as those with a GRWR ≥ 0.8%^[13-17]. After challenging the boundary of GRWR = 0.8%, the acceptable minimum GRWR has been continuously lowered. Lee SD *et al.*^[18] reported that a GRWR as low as 0.7% is safe and that there is no need to modulate portal pressure in adult-to-adult LDLT using the right-lobe in favorable conditions, such as a low Model for End-Stage Liver Disease (MELD) score. Furthermore, Alim A *et al.*^[19] even suggested that a GRWR as low as 0.6% may be safe if the MELD score is < 20, donor age is < 45, and there is no evidence of liver steatosis in the donor graft during portal inflow modulation performed according to the portal flow. To date, the reported lowest GRWR of grafts that have been successfully used is between 0.40% and 0.46% (Table 1)^[20].

Small-for-size syndrome (SFSS), including small-for-size dysfunction (SFSD) and small-for-size nonfunction (SFSNF), is a concerning and life-threatening complication in patients receiving grafts with a GRWR < 0.8%^[21,22]. The incidence of SFSS varies from 4.7% to 27.5% in different LT centers^[23-30]. Specifically, the syndrome rate can be as high as 50%-75% in left-lobe LDLT or small-for-size grafts group and as low as 8.4% in right-lobe LDLT^[31,32]. Graft size is the only independent predictor of SFSS^[31]. However, other studies have described that SFSS can occur even in the presence of a normal GRWR^[16]. Regardless of the definition used for SFSS, it seems clear that other key factors should be considered in addition to a mismatched graft size. The

Table 1 Recommended minimum graft-to-recipient weight ratio in different studies

| Ref. | Recommended minimum GRWR | <i>n</i> (small <i>vs</i> large) | One-year survival (small <i>vs</i> large) | Five-year survival (small <i>vs</i> large) | Study type |
|---|--|----------------------------------|---|--|------------|
| Kiuchi <i>et al</i> ^[10] (1999) | 1% | 276 (49 <i>vs</i> 215) | 61.2% <i>vs</i> 92.6% | NS | RS |
| Lee <i>et al</i> ^[11] (2003) | 0.8% | 141 (10 <i>vs</i> 131) | Univariate and multiple analysis | NS | RS |
| Moon <i>et al</i> ^[13] (2010) | Less than 0.8% | 427 (35 <i>vs</i> 392) | 87.8% <i>vs</i> 90.7% | 74.1% <i>vs</i> 79.4% | RS |
| Lan <i>et al</i> ^[14] (2009) | Less than 0.8% | 89 (15 <i>vs</i> 74) | 73.3% <i>vs</i> 71.6% | NS | RS |
| Selzner <i>et al</i> ^[15] (2009) | Less than 0.8% | 271 (22 <i>vs</i> 249) | 91.0% <i>vs</i> 89.0% | 83.0% <i>vs</i> 87% | RS |
| Chen <i>et al</i> ^[16] (2014) | Less than 0.8% | 196 (45 <i>vs</i> 151) | 82.2% <i>vs</i> 81.4% | 71.1% <i>vs</i> 75.5% | RS |
| She <i>et al</i> ^[17] (2017) | Left lobe graft <i>vs</i> right lobe graft | 218 (19 <i>vs</i> 199) | 89.5% <i>vs</i> 95.9% | 89.5% <i>vs</i> 86.8% | RS |
| Lee <i>et al</i> ^[18] (2014) | Less than 0.7% | 317 (23 <i>vs</i> 294) | 100% <i>vs</i> 93.2% | NS | RS |
| Alim <i>et al</i> ^[19] (2016) | 0.6% | 649 | Seven patients had GRWR of 0.6%. If MELD score was below 20, donor age below 45, and no signs for any hepatosteatosi, GRWR of 0.6% was safe | | RS |
| Lee <i>et al</i> ^[20] (2015) | 0.40% | NS | Lowest GRWR of 0.40% had been successfully used | | RS |

PS: Prospective study; RS: Retrospective study; Ref.: Reference; GRWR: Graft-to-recipient weight ratio.

Table 2 Incidence of small-for-size syndrome when using small-for-size grafts *n* (%)

| Ref. | <i>n</i> | SFSS (Incidence) | Factors to SFSS | Study type |
|--|----------|------------------|---|------------|
| Goldaracena <i>et al</i> ^[21] (2017) | NS | NS | A graft GRWR < 0.8% of predisposes the graft to SFSS | RE |
| Graham <i>et al</i> ^[22] (2014) | NS | NS | GRWR of 0.8 to 1.0 was established as a lower limit to prevent SFSS | RE |
| Botha <i>et al</i> ^[23] (2010) | 21 | 1 (4.7) | Hemi-portocaval shunt can decrease SFSS incidence | RS |
| Goralczyk <i>et al</i> ^[24] (2011) | 22 | 5 (22.7) | Posterior cavoplasty can decrease SFSS incidence | RS |
| Soejima <i>et al</i> ^[25] (2003) | 36 | 8 (22.2) | Cirrhosis predisposes the graft to SFSS | RS |
| Ben-Haim <i>et al</i> ^[26] (2001) | 40 | 5 (8) | Child's class B or C with received grafts of GRWR < 0.85% predisposes the graft to SFSS | RS |
| Sudhindran <i>et al</i> ^[27] (2012) | NS | 10%-20% | Left lobe grafts predisposes the graft to SFSS | RE |
| Yi <i>et al</i> ^[28] (2008) | 29 | 8 (27.5) | Left lobe grafts predisposes the graft to SFSS | RS |
| Soejima <i>et al</i> ^[29] (2012) | 312 | 43 (15.3) | Left lobe grafts predisposes the graft to SFSS | RS |
| Gruttadauria <i>et al</i> ^[30] (2015) | 83 | 13 (15.7) | Non-surgical modulation of the portal inflow can decrease SFSS incidence | RS |
| Shoreem <i>et al</i> ^[31] (2017) | 174 | 20 (11.5) | Left lobe grafts predisposes the graft to SFSS | RS |
| Lauro <i>et al</i> ^[32] (2007) | 8 | 4 (50) | Surgical modulation of the portal inflow can decrease SFSS incidence | RS |

RE: Review; RS: Retrospective study; SFSS: Small-for-size syndrome; GRWR: Graft-to-recipient weight ratio.

incidence of SFSS is listed in Table 2.

Middle hepatic vein (MHV) or outflow reconstruction of the liver graft is associated with size mismatch. A small-for-size graft without MHV reconstruction can lead to various degrees of congestion of the anterior segment and a greater loss of hepatocellular function^[33]. In our early observational studies with small sample sizes, we recommended a GRWR > 1.0%^[34] or even 1.2%^[35] as a security threshold for patients without MHV reconstruction. Asakuma M *et al*^[36] established an algorithm known as the estimated congestion ratio (ECR, ECR = regional volume of v5 + v8 / right-lobe volume) to estimate whether MHV should be reconstructed for low-GRWR grafts. A liver with an ECR > 0.4 is an MHV-dominant liver, and higher GRWR grafts should be used. However, it is still unknown how far we can lower the GRWR following the improvement of postoperative management and surgical technique if there is no reconstruction of outflow. In addition to outflow reconstruction, the inflow of grafts, including portal hypertension following reperfusion and the

hyperdynamic splanchnic state, is reported as a major factor that can trigger SFSS^[37-39]; however, these views are controversial^[40]. Enhanced cholestasis, hepatocyte ballooning, disruption of the sinusoidal line, and transformation of activated Ito cells into fibroblasts are observed under the conditions of portal hypertension, or overperfusion^[41,42]. Recipients with a final portal vein pressure (PVP) ≤ 15 mmHg or a pressure gradient of PVP-central vein pressure (CVP) ≤ 5 mmHg have a better prognosis^[43]. In another study, liver-graft-to-spleen-volume ratio was used to predict early graft function in children and young adults undergoing LDLT, in which < 0.88 predicted portal hyperperfusion^[44]. Moreover, a MELD score > 20^[45], a decline in the platelet (PLT) count at post operation day (POD) 3 > 56%^[46] and donor age > 45 years are also risk factors for a poor prognosis in recipients of small-for-size grafts^[19].

To increase the safety of the expanded use of small-for-size grafts, some treatments are recommended. Graft inflow or PVP modulation is at the forefront of these treatments. Portosystemic shunting techniques

Table 3 Remedies when using small-for-size graft

| Ref. | n | Remedy for using small-for-size graft | Study type |
|--|-----|---|------------|
| Botha <i>et al</i> ^[23] (2010) | 21 | Hemi-portocaval shunt can decrease SFSS incidence | RS |
| Goralczyk <i>et al</i> ^[24] (2011) | 22 | Posterior cavoplasty can decrease SFSS incidence | RS |
| Kim <i>et al</i> ^[47] (2017) | 160 | Preserving collateral veins on small-for-size grafts | RS + PSM |
| Hessheimer <i>et al</i> ^[48] (2011) | NS | Portocaval shunt | AE |
| Xiao <i>et al</i> ^[49] (2012) | 1 | Transjugular intrahepatic portosystemic shunt | CR |
| Sato <i>et al</i> ^[50] (2008) | 4 | Portocaval shunt using ligamentum teres | CR |
| Nutu <i>et al</i> ^[51] (2018) | 2 | Complete splenic embolization | CR |
| Badawy <i>et al</i> ^[52] (2017) | 164 | Splenectomy | RS |
| Troisi <i>et al</i> ^[53] (2016) | NS | Splenic artery ligation, splenectomy, meso-caval shunt, spleno-renal shunt, portocaval shunt, and splenic artery embolization | SR |
| Xu <i>et al</i> ^[54] (2015) | NS | Dual grafts | RE |
| Gao <i>et al</i> ^[55] (2017) | NS | Adipose-derived mesenchymal stem cells transplantation | AE |
| Kobayashi <i>et al</i> ^[56] (2009) | 5 | Auxiliary partial liver transplantation | CR |

PSM: Propensity score matching; AE: Animal experiments; CR: Case report; SR: Systematic review; RE: Review; SFSS: Small-for-size syndrome.

or preservation of collateral veins^[19,47-50], as well as splenectomy or splenic artery ligation/embolization^[51-53], are effective ways to address post-transplantation portal hyperperfusion. In cases where the GRWR of grafts is very low, dual grafts can be considered^[54]. Moreover, autologous stem cell implantation^[55] and auxiliary partial LDLT (a second transplant) are also reported to treat SSFS^[56]. Remedies when using small-for-size grafts are listed in Table 3.

Generally, a GRWR < 0.8% is no longer a critical predictor for recipients and can even be lowered to 0.5%-0.6% if there are accompanying factors of PVP ≤ 15 mmHg, MHV reconstruction, or young donor age.

OLDER DONORS IN LDLT

Because LDLT allows more choices in the use of a suitable liver graft compared with OLT, elderly donors were rarely considered in the early years of transplantation. However, following the increasing demands for LDLT and the urgent need to save the lives of patients suffering from hepatic encephalopathy, the use of elderly liver grafts has been reported more frequently in recent years as a means to increase the donor pool and address high waiting list mortality^[57]. In Japan, the percentages of donors older than 50 and 60 years were 18.1% and 4%, respectively^[58]. It is expected that the number of older donors will increase in the future because of the continuing donor shortage^[59].

The definition of older donors is quite different in different transplantation centers. In the present review, we define older donors as donors older than 50 years. Controversy exists regarding the use of livers from older donors. The liver regeneration rate is impaired in older donors (donor age ≥ 50 years) compared with young donors (donor age < 30 years), according to computed tomography (CT) volumetric data after LDLT at POD 7^[60], and donor age (≥50 years) was independently correlated with impaired remnant liver regeneration at 3^[61] and 6 mo in right-

lobe LDLT^[58]. Kawano Y *et al*^[62] analyzed telomeres in the hepatocytes of 12 paired donor-recipients and found that donor age was a crucial factor affecting the sustainability of telomere length in hepatocytes after pediatric LDLT. Based on the conclusion that older donors were significantly associated with impaired liver regeneration, some researchers found that the recipients of grafts from donors older than 45-50 years old, along with a GW/SLV ratio < 35%-40%, had worse outcomes^[63,64]. Yoshizumi T *et al*^[65] established the following formula, called a predictive score, to evaluate the impact of donor age, graft size, and MELD score on prognosis: predictive score = 0.011 × graft weight (%) - 0.016 × donor age - 0.008 × MELD score - 0.15 × shunt (if present) - 1.757. Patients with a predictive score ≥ 1.3 had a lower incidence of postoperative complications and a better prognosis.

Additionally, more studies have shown that LDLT using older donors could induce more serious postoperative complications and higher mortality rates than transplants using younger donors^[66-70]; similarly, having a donor older than the recipient by > 20 years is problematic^[68]. Moreover, it has been reported that fibrosis progression in patients with recurrent hepatitis C tended to be faster after LDLT with grafts from older donors^[71]. Donor age is an independent, strong prognostic factor in LDLT. However, other researchers found that grafts from older donors can be used safely, even though the regenerative capacity of older grafts is impaired when the donor age is ≥ 50 years^[72-75] or even ≥ 55 years^[76]. The impact of older donors on the 1- and 5-year survival of recipients is shown in Table 4.

While donor age is a controversial topic, the impaired regenerative capacity of older grafts has been confirmed in some studies. According to these previous studies, older liver grafts can be prudent candidates but cannot be used in the presence of other marginal conditions (e.g., small-for-size grafts or moderate and severe steatosis). More high-quality and prospective studies are needed on this topic.

Table 4 Older donors for living donor liver transplantation

| Ref. | Definition of older donors | n (older vs young) | One-year survival (older vs young) | Five-year survival (older vs young) | Study type |
|---|-----------------------------------|--------------------|--|-------------------------------------|------------|
| Tanemura <i>et al</i> ^[58] (2012) | 50 yr old | 101 (24 vs 77) | Older donor livers might have impaired regenerative ability | | RS |
| Ono <i>et al</i> ^[60] (2011) | 50 yr old | 15 (6 vs 9) | Liver regeneration is impaired with age after donor hepatectomy | | RS |
| Akamatsu <i>et al</i> ^[61] (2007) | 50 yr old | 299 (62 vs 237) | 85.0% vs 93.0% | 72.0% vs 87.0% | RS |
| Kawano <i>et al</i> ^[62] (2014) | NS | 12 | Donor age is a crucial factor affecting telomere length sustainability in hepatocytes after pediatric LDLT | | PS |
| Imamura <i>et al</i> ^[63] (2017) | NS | 198 | A worse outcome might be associated with aging of the donor | | RS |
| Dayangac <i>et al</i> ^[64] (2011) | 50 yr old | 150 (28 vs 122) | 78.6% vs 83.4% | NS | RS |
| Yoshizumi <i>et al</i> ^[65] (2008) | NS | 28 | Graft size, donor age, and patient status are the indicators of early graft function | | RS |
| Han <i>et al</i> ^[66] (2014) | 55 yr old | 604 (26 vs 578) | Median OS (M): 31.2 ± 31.3 vs 50.6 ± 40.6 | | RS |
| Kamo <i>et al</i> ^[67] (2015) | 60 yr old | 1597 (69 vs 1528) | 69.5% vs 81.2% | 62.0% vs 79.3% | RS |
| Shin <i>et al</i> ^[68] (2013) | Donor-recipient age gradient > 20 | 821 | Worse graft survival was observed if the donor is older than the recipient by > 20 | | RS |
| Kubota <i>et al</i> ^[69] (2017) | 50 yr old | 315 (126 vs 189) | 73.0% vs 80.9% | 39.7% vs 47.1% | RS |
| Katsuragawa <i>et al</i> ^[70] | NS | 24 | G/SLV and donor age were independent factors that affected graft survival rates | | RS |
| Wang <i>et al</i> ^[72] (2015) | 50 yr old | 159 (10 vs 149) | 100% vs 93.0% | 90.0% vs 87.0% | RS |
| Ikegami <i>et al</i> ^[73] (2008) | 50 yr old | 232 (32 vs 200) | 80.0% vs 81.7% | 73.8% vs 76.7% | RS |
| Li <i>et al</i> ^[74] (2012) | 50 yr old | 129 (21 vs 108) | 90.0% vs 86.0% | 66.0% vs 75% | RS |
| Goldaracena <i>et al</i> ^[75] (2016) | 50 yr old | 469 (91 vs 378) | 92.0% vs 96.0% | 83.0% vs 79.0% | RS |
| Kim <i>et al</i> ^[76] (2017) | 55 yr old | 540 (42 vs 498) | 95.2% vs 94.6% | NS | RS |

LDLT: Living donor liver transplantation; CR: Case report; RS: Retrospective study.

ABO-INCOMPATIBLE LDLT

Although more high-quality liver grafts are available for patients in LDLT than in OLT, donors are restricted to family members or domestic relationships in many transplantation centers because of ethical norms. ABO-incompatible LTs are performed only in emergencies, when ABO-compatible grafts are unavailable. Therefore, breaking ABO blood group barriers becomes inevitable. ABO-incompatible LT was first performed and reported by Starzl *et al*^[77], and no acute rejections were observed after transplantation. Subsequently, ABO-incompatible LT gradually began to be performed in some LT centers, and hyperacute rejection was commonly reported^[78,79].

In addition to antibody-mediated rejection, ABO-incompatible LDLT can involve other complications. Thrombotic microangiopathy (TMA) is a rare complication following LT, but it is reported to have a slightly higher incidence in ABO-incompatible LDLT^[80-82]. ABO incompatibility, cyclophosphamide and recipient blood group (type O) are closely correlated with the occurrence of TMA^[80,82]. The incidence of TMA is 37.9% following ABO-incompatible LDLT and 0.0%-2.8% following ABO-compatible LDLT (OR = 44.7)^[80]. The elevation of fibrinolytic function markers, such as plasminogen activator inhibitor type 1, can be considered a predictor of TMA following LDLT. The incidence of biliary tract complications is more common than that of TMA. Biliary strictures are one of the most important complications associated with ABO incompatibility, with reported incidence rates between 15.8% and 20.7%^[83,84]. An isoagglutinin attack on the graft vascular endothelium can result in ischemic cholangiopathy, and isoagglutinin can even directly attack the endothelium of the graft

bile duct^[85,86]. CT scans can provide a clear indication of biliary strictures in ABO-incompatible LDLT^[87]. Yamada Y *et al*^[88] reported a case of idiopathic hypereosinophilic syndrome following ABO-incompatible LDLT. The patient suffered from portal vein thrombosis on postoperative day 10, and the histopathological findings of the thrombus revealed dense eosinophilic deposition. Studies on the impact of ABO incompatibility on LDLT are listed in Table 5.

Despite serious complications, ABO-incompatible LDLT can be a feasible option for patients if certain essential treatments are included^[89,90]. Rituximab, an anti-CD20 immunoglobulin (IgG)1 terminating B-lymphocytes with an affinity for IgG Fc receptor (FcγR), is a critical strategy in the regimens for desensitization for ABO-incompatible LDLT and yields outcomes for ABO-incompatible LDLT that are similar to those for ABO-compatible LDLT^[91,92]. Rituximab is given for 3 d^[93], 3 wk, or even as soon as a suitable donor that is ABO-compatible is selected^[94] at a dosage of 375 mg/m². In the early stage of transplantation, rituximab was usually given along with one or more other protocols, such as a splenectomy^[95,96], plasma exchanges^[97-102], intravenous IgG^[100,103], and intrahepatic arterial infusion of prostaglandin E1^[92,104,105]. In some recent studies, pre-transplant rituximab and/or basiliximab monotherapy, without additional treatments, also yielded outcomes that are comparable to those of procedures with additional treatments^[106]. The affinity between IgG Fcγ Receptor (FcγR) and rituximab, however, is influenced by the single-nucleotide polymorphisms (SNPs) of FcγR. SNPs of FCGR2A (131H/R) and FCGR3A (158F/V) are the alleles that encode FcγR. FCGR2A (131H/R) had a higher affinity for IgG1 than FCGR2A (131H/R

Table 5 Impact of ABO-incompatible on living donor liver transplantation

| Ref. | <i>n</i> | Complications | Incidence of related complication (%) | Risk factors | Study type |
|---|----------|------------------------------|---------------------------------------|--|------------|
| Miyata <i>et al</i> ^[80] (2007) | 57 | Thrombotic microangiopathy | 7.0 | ABO-incompatibility, CPA, and recipient blood group (type O) | RS |
| Oya <i>et al</i> ^[81] (2008) | 1 | Thrombotic microangiopathy | NS | ABO-incompatible LDLT (type B to O) | CR |
| Kishida <i>et al</i> ^[82] (2016) | 129 | Thrombotic microangiopathy | 10.1 | ABO-incompatible, tacrolimus | RS |
| Song <i>et al</i> ^[83] (2014) | 1102 | Biliary stricture | 15.8 | ABO-incompatible, acute cellular rejection | RS |
| Ikegami <i>et al</i> ^[84] (2016) | 408 | Biliary stricture | 20.4 | ABO-incompatible | RS |
| Yamada <i>et al</i> ^[88] (2010) | 1 | Idiopathic hypereosinophilic | NS | ABO-incompatible | CR |

LDLT: Living donor liver transplantation; CR: Case report; RS: Retrospective study.

or R/R). Accordingly, patients with FCGR2A (131H/H) have a better reaction to the effects of rituximab on B cells^[91]. The treatment results of ABO-compatible LDLT are summarized in Table 6.

These findings reveal that rituximab monotherapy in ABO-compatible LDLT is feasible, but it is better to test the SNPs of FCγR; otherwise, multiple treatments, such as plasma exchanges and intravenous IgG, must be performed in addition to rituximab if there is a lower affinity between IgG FCγR and rituximab. There is still a lack of more persuasive evidence to confirm the feasibility of splenectomy in conjunction with ABO-compatible LDLT treatments.

LIVER GRAFT STEATOSIS

Steatosis is a common feature used to identify marginal liver function, and reports on the utility of steatotic liver grafts in clinical practice have yielded controversial results. The use of steatotic liver grafts has been confirmed to have a significant relationship with increased complications and poorer outcomes^[107,108]. Traditionally, steatotic livers with > 60% fat must be discarded. Livers with < 30% fat are feasible and anticipated to have good function. Livers with 30%-60% fat have poor results, with decreased graft survival and decreased patient survival^[109]. Moreover, hepatic steatosis is reported to be a leading cause of donor rejection in LDLT^[110]. In some transplantation centers, approximately 40% of donor grafts are discarded because of severe liver steatosis^[9]. Because of the release of inflammatory cytokines and inhibition of the capacity to differentiate steatosis hepatocytes, the early regenerative capacity of the remnant liver is injured, and, as a result of impaired hepatocyte replication, compensatory expansion of hepatic progenitor cells occurs during steatotic liver regeneration after LDLT^[111]. Furthermore, Cho *et al*^[112] confirmed that hepatic steatosis is associated with intra-hepatic cholestasis and transient hyperbilirubinemia

during regeneration after LDLT. In this study, 67 LDLT recipients examined on POD 10 were scored based on the numbers of portal tracts per area of liver tissue and intrahepatic cholestasis, and the preoperative degree of macrovesicular steatosis was found to be independently associated with cholestasis after LDLT. However, these researchers also found that the long-term capacity of hepatocyte regeneration was not impaired after LDLT with mild macrovesicular steatosis grafts^[113]. Based on this finding, some recent studies have found that moderately steatotic liver grafts and donors with a BMI ≥ 30 kg/m² are not contraindications for LDLT, and complications and survival are not significantly different compared with those associated with non-steatosis grafts^[114,115]. Moreover, the risk of steatosis was determined by the presence of microsteatosis and macrosteatosis, rather than the total quantitative degree of steatosis. The grafts with high microsteatosis (30%) mixed with macrosteatosis showed no significant difference in postoperative biochemical liver function, 2-wk graft regeneration, postoperative complications, and 5-year survival^[116]. The studies on the impact of graft steatosis on LDLT outcomes are listed in Table 7.

To decrease the risk associated with fatty liver grafts, especially with severe steatosis, some treatments are suggested (Table 8). According to Oshita *et al*^[117], donors who are diagnosed with hepatic steatosis pre-transplantation should undergo a diet treatment consisting of an 800-1400 kcal/d diet and a 100-400 kcal/d exercise regimen without drug treatment with a target body mass index of 22 kg/m². After these strategies, the average BMI was reduced from 23.3 ± 0.6 to 21.9 ± 0.4 kg/m². The liver biopsy results of most of these donors showed stage 0/1 fibrosis and minimal/mild steatosis after the diet therapy. In addition, surgical outcomes and overall survival did not significantly differ between the recipients of grafts from non-steatosis and diet-treated donors (with steatosis). In another study, bezafibrate (400 mg/d) was used along with a protein-rich (1000 kcal/d) diet and exercise (600 kcal/d) for 2-8

Table 6 Remedies when using ABO- incompatible on living donor liver transplantation

| Ref. | n | Immunosuppression strategy | Remedies | Conclusion | Study type |
|--|-----|-----------------------------|--|--|------------|
| Kawagishi <i>et al</i> ^[89] (2009) | 105 | TAC + MP + AZ | Rituximab | ABO-incompatible LDLT can be feasible used if humoral rejection are overcome | RS |
| Yoon <i>et al</i> ^[90] (2018) | 918 | TAC + MP + steroids | Rituximab and PE | ABO-incompatible LDLT is a feasible option under remedies | RS |
| Sakai <i>et al</i> ^[91] (2017) | 20 | TAC+ MP | Rituximab and PE | FCGR SNPs influence the effect of rituximab on B-cells | PS |
| Egawa <i>et al</i> ^[92] (2017) | 33 | TAC | Rituximab, PE, local infusion, splenectomy and immunoglobulins | Only rituximab dose is a significantly favorable factor for AMR | RS |
| Ikegami <i>et al</i> ^[93] (2007) | 1 | TAC + MP + steroids | Rituximab and PE | Rituximab and plasma exchanges seemed ineffective | CR |
| Ikegami <i>et al</i> ^[94] (2009) | 7 | TAC + MP + steroids | Rituximab, IVIG, and PE | Rituximab, IVIG, and PE seems to be a safe treatment | RS |
| Usui <i>et al</i> ^[95] (2007) | 73 | TAC + MP + steroids | Rituximab, PE and splenectomy | Bone suppression is a big challenge when using rituximab | RS |
| Chen <i>et al</i> ^[96] (2017) | 2 | TAC + MP + steroids | Basiliximab combine with splenectomy | ABO-i LDLT with splenectomy is undoubtedly life-saving | CR |
| Uchiyama <i>et al</i> ^[97] (2011) | 15 | TAC + MP + steroids | Rituximab and PE | Isoagglutinin mediated-rejection should be more concerned | RS |
| Soin <i>et al</i> ^[98] (2014) | 3 | TAC + MP + steroids | Rituximab and PE | ABO-incompatible LDLT is a feasible option under remedies | CR |
| Rummler <i>et al</i> ^[99] (2017) | 10 | TAC + MP + steroids | PE | Immunosuppression only combining with PE is feasible | RS |
| Kim <i>et al</i> ^[100] (2016) | 182 | TAC + MP + steroids | Rituximab, IVIG, and PE | ABO-incompatible LDLT can be safely performed under remedies | RS |
| Kim <i>et al</i> ^[101] (2013) | 22 | TAC + MP + steroids | Rituximab and PE | ABO-incompatible LDLT can be safely performed under remedies | RS |
| Kawagishi <i>et al</i> ^[102] (2005) | 3 | TAC + MP + steroids | Rituximab and PE | ABO-incompatible LDLT can be safely performed under remedies | CR |
| Kim <i>et al</i> ^[103] (2017) | 43 | TAC + MP + steroids | Rituximab and IVIG | A simplified protocol using rituximab and IVIG for ABO-I LDLT is safe | RS |
| Yoshizawa <i>et al</i> ^[104] (2005) | 8 | TAC + MP + cyclophosphamide | Rituximab and PGE1 infusion | Rituximab prophylaxis and HA infusion therapy is feasible | RS |
| Egawa <i>et al</i> ^[105] (2008) | 118 | TAC + steroids | Methylprednisolone and PGE1 infusion | Recipients with preexisting high effector CD8 T- cells are unfavorable candidates for ABO-I LDLT | RS |
| Yamamoto <i>et al</i> ^[106] (2018) | 40 | TAC + MP + steroids | Rituximab monotherapy | Rituximab monotherapy is feasible | RS |

LDLT: Living donor liver transplantation; CR: Case report; RS: Retrospective study; SNPs: Single-nucleotide polymorphisms.

wk^[118]. Even severely steatotic livers could be used for LDLT grafting subsequent to this short-term treatment regimen. Furthermore, a 1200 kcal/d diet and a minimum of 60 min/d of moderate cardio training are also recommended to rapidly reverse liver steatosis in donors^[119]. In addition to lifestyle and dietary changes, dual-graft LDLT was reported when one donor had severe liver steatosis and another had a low GRWR^[120].

In conclusion, steatosis in the donor must be thoroughly evaluated before LDLT, either by biopsy or imaging diagnosis. The proportion of macrosteatosis is now considered a crucial predictor of the prognosis of recipients. If there are no further options, donors with hepatic steatosis can reach donation criteria through

lifestyle and dietary changes in a short time.

CHRONIC HEPATITIS OF GRAFTS

The use of liver grafts that test positive for chronic hepatitis or other blood disseminated diseases found in epidemic areas is usually inevitable in cases of organ shortages associated with OLT. However, because LDLT recipients, to some degree, have more choices regarding his/her donors, there are a few studies reporting on HBsAg or HBcAb(+) liver grafts, while no studies refer to HCV-positive living liver grafts.

HBsAg(-) LDLT patients who have received HBsAg or HBcAb(+) grafts have a high risk of *de novo* HBV

Table 7 Impact of graft steatosis on living donor liver transplantation

| Ref. | n | Conclusion | Study type |
|--|-----|---|------------|
| Dirican <i>et al</i> ^[9] (2015) | 161 | Approximately 40% of donor grafts are discarded because of severe liver steatosis | RS |
| Perkins <i>et al</i> ^[109] (2006) | NS | Typically steatotic livers with > 60% fat are not transplanted; with < 30% fat are usable and anticipated to have good function; with 30%-60% fat give poor results | Comments |
| Kotecha <i>et al</i> ^[110] (2013) | 340 | Hepatic steatosis is a leading cause of donor rejection in LDLT | PS |
| Cho <i>et al</i> ^[111] (2010) | 54 | Hepatocyte replication is impaired during steatotic liver regeneration after LDLT | PS |
| Cho <i>et al</i> ^[112] (2006) | 67 | Hepatic steatosis is associated with intrahepatic cholestasis and transient hyperbilirubinemia during regeneration | PS |
| Cho <i>et al</i> ^[113] (2005) | 55 | Mildly steatotic graft did not increase the risk of graft dysfunction or morbidity in LDLT | PS |
| Gao <i>et al</i> ^[114] (2009) | 24 | Moderately steatotic (30%-60%) liver grafts provide adequate function in the first phase after transplantation and can be used for transplantation | RS |
| Knaak <i>et al</i> ^[115] (2017) | 105 | Donors with BMI > 30, in the absence of graft steatosis, are not contraindicated for LDLT | RS |
| Han <i>et al</i> ^[116] (2015) | 211 | The risk of steatosis may be determined by the relative composition of MiS and MaS, rather than the total quantitative degree | RS |

LDLT: Living donor liver transplantation; RS: Retrospective study; PS: Prospective study.

Table 8 Treatments for fat donors

| Ref. | n | Treatments | Study type |
|--|-----|--|------------|
| Oshita <i>et al</i> ^[117] (2012) | 128 | Diet treatment consisting of an 800 to 1400 kcal/d diet and a 100 to 400 kcal/d exercise regimen without drug treatment, targeting body mass index of 22 kg/m ² | RS |
| Nakamuta <i>et al</i> ^[118] (2013) | 11 | Bezafibrate (400 mg/d) was used along with a protein-rich (1000 kcal/d) diet and exercise (600 kcal/d) for 2-8 wk | RS |
| Choudhary <i>et al</i> ^[119] (2015) | 16 | 1200 kcal/d and a minimum of 60 min/d of moderate cardio training are also recommended to rapidly reverse liver steatosis in donors | PS |
| Moon <i>et al</i> ^[120] (2006) | 2 | Dual-graft living donor liver transplantation for severe graft steatosis | CR |

RS: Retrospective study; PS: Prospective study; CR: Case report.

infection after transplantation (Table 9). However, these grafts are still considered to be safe and feasible with antiviral prophylaxis in both adult and pediatric LDLT^[121-126]. Patients were given HBV vaccinations to achieve anti-HBs > 1000 IU/L pre-transplantation and > 100 IU/L post-transplantation, with a standard post-transplantation treatment regimen of high-dose hepatitis B IgG, lamivudine and/or adefovir (in cases of lamivudine resistance)^[126]. Specifically, some studies have proposed a new strategy; specifically, patients with a pre-transplantation anti-HB titer > 1000 IU/L do not need post-transplantation prophylaxis; patients with a low pre-transplantation titer, < 1000 IU/L, should be given lamivudine post-transplantation (at a dose of 100 mg/d or 3 mg/kg/d for at least 2 years after transplantation) or adefovir prophylaxis (with lamivudine at a dose of 10 mg/d if a mutant strain for lamivudine is identified) and, hopefully, will respond appropriately to post-transplantation vaccinations by maintaining anti-HB titers > 100 IU/L; and low titer non-responders (anti-HB titer < 100 IU/L despite vaccination) should be given continuous lamivudine or adefovir indefinitely^[121]. In some transplantation centers, nucleotide analogs (lamivudine) are routinely used first if HBsAg(-) LDLT patients receive HBsAg or HBcAb(+) grafts, regardless of the anti-HB titer, for at least 2 years. Moreover,

patients who had a YMDD mutation were given adefovir combined with lamivudine^[123]. Hara Y *et al*^[127] reported one patient who experienced spontaneous eradication of *de novo* HBV after LDLT with an HBcAb(+) graft without any treatment. This 8-year-old female patient (HBsAg-negative) underwent LDLT, received an HBcAb(+) left-lobe graft, and was subsequently infected with HBV. Sixteen years after LDLT, her serological HBV status was as follows: HbsAg(-), HBsAb(+), HBeAb(-), HBeAb(+), HbcAb(+), and HBV DNA(-). In another study, recipients with HCV genotype 2 infections who had received an HBcAb(+) graft were given sofosbuvir and ribavirin, along with hepatitis B IgG to prevent recurrence of HCV and HBV^[128].

In HbsAg(+) LDLT patients who receive HBsAg or HBcAb(+) grafts, the antiviral protocol must be performed as for HBsAg(-) LDLT patients to maintain the HBV DNA at a low or negative level, despite the persistence of the HBV marker (HBsAg). High-dose HBV IgG, lamivudine, famciclovir, and interferon were recommended (Table 10)^[129-131].

Populations with HBsAg-negative/HBcAb-positive and undetectable serum HBV DNA have been gradually increasing over the past several decades. Most patients are now considered to have a covert HBV infection and have a high risk of HBV reactivation when treated with

Table 9 Impact of HBsAg or HBcAb(+) grafts on HBsAg(-) living donor liver transplantation patients

| Ref. | Donor | Incidence of <i>de novo</i> HBV infection (%) | Prevention of <i>de novo</i> HBV infection | Study type |
|--|----------|---|---|------------|
| Wang ^[122] (2017) | HBcAb(+) | 4.2 | HBV vaccinations with the aim of achieving anti-HBs > 1000 IU/L pre-transplant and > 100 IU/L post-transplant | RS |
| Xi <i>et al</i> ^[122] (2013) | HBcAb(+) | 23.9 | No prophylaxis, adefovir, and lamivudine are given to <i>de novo</i> patients | RS |
| Dong <i>et al</i> ^[123] (2017) | HBcAb(+) | 7.9 | HBIG 100 IU/kg during the operation and lamivudine 3 mg/kg per day after the surgery for at least 1 year until HBV vaccine reaction | RS |
| Loggi <i>et al</i> ^[124] (2016) | HBsAg(+) | NS | HBIG and lamivudine, adefovir or tenofovir | SR |
| Lei <i>et al</i> ^[125] (2013) | HBcAb(+) | 15.0 | No specific prophylaxis | RS |
| Lin <i>et al</i> ^[126] (2007) | HBcAb(+) | 3.3 | Lamivudine monoprophyllaxis, HBV vaccinations | RS |
| Hara <i>et al</i> ^[127] (2016) | HBcAb(+) | NS | Lamivudine first and adefovir dipivoxil were combined with lamivudine 2 yr later | CR |

HBV: Hepatitis B virus; RS: Retrospective study; SR: Systematic review; CR: Case report.

Table 10 Impact of HBsAg or HBcAb(+) grafts on HBsAg(+) living donor liver transplantation patients

| Ref. | Donor | Incidence of <i>de novo</i> HBV infection | Prevention of De Novo HBV infection | Study type |
|--|----------|---|---|------------|
| Hwang <i>et al</i> ^[129] (2006) | HBsAg(+) | NS | High-dose HBIG and lamivudine, famciclovir and interferon; a final regimen of lamivudine and adefovir | CR |
| Soejima <i>et al</i> ^[130] (2007) | HBsAg(+) | NS | lamivudine and adefovir dipivoxil | CR |
| Jeng <i>et al</i> ^[131] (2015) | HBsAg(+) | NS | Entecavir 0.5 mg once daily | RS |

HBV: Hepatitis B virus; CR: Case report; RS: Retrospective study.

Table 11 Graft with hepatic benign tumor

| Ref. | n | Type of tumors in grafts | Prognosis | Study type |
|--|----|--|--|------------|
| Li <i>et al</i> ^[133] (2017) | 15 | Cavernous hemangioma, perivascular epithelioid cell tumor, inflammatory pseudotumor, and focal nodular hyperplasia | One patient died from pulmonary embolism | OS |
| Fuchino <i>et al</i> ^[134] (2017) | 1 | HBsAg(+) and inflammatory pseudotumor | Tumor vanished after 3 yr | CR |

OS: Observational study; CR: Case report.

a robust immunosuppressive agent^[132]. Therefore, the use of HBsAg-negative/HBcAb-positive liver grafts has a high risk of *de novo* HBV for HBsAg(-) recipients. However, with active immunization and an antiviral protocol, the HBsAg-negative/HBcAb-positive liver grafts can be transplanted safely.

GRAFTS WITH A BENIGN HEPATIC TUMOR

Usually, there are rare recipients of LDLT or doctors who are willing to make an active choice to use a graft with an undetermined tumor. This is not only an ethical issue but also indicates a high risk for recipients to face rapid dysfunction of their liver grafts. However, if recipients are in an emergency situation and have no other proper donors, grafts with benign tumors may be a last choice. Li G *et al*^[133] recently reported on 15 consecutive recipients using an otherwise discarded, partial liver

resection graft with a benign hepatic tumor. These benign tumors are as follows: Cavernous hemangioma, perivascular epithelioid cell tumor, inflammatory pseudotumor, and focal nodular hyperplasia. One patient died from a pulmonary embolism, and the other 14 patients had a good prognosis. Additionally, a vanishing tumor in a liver graft from an HBV(+) donor was observed. Contrast-enhanced magnetic resonance imaging (MRI) showed hypervascularity in the arterial phase and in the hepatobiliary phase, the tumor showed a low intensity, findings similar to those in HCC. Regardless, the graft with suspected HCC was accepted by the recipient, and the tumor disappeared completely within several months after LDLT^[134].

For LDLT patients using grafts with a benign hepatic tumor, only two observational studies with a small sample size are present in the literature (Table 11). It seems that grafts with benign tumors are feasible in some conditions, but more studies with long-term follow-ups are needed to evaluate the safety of these

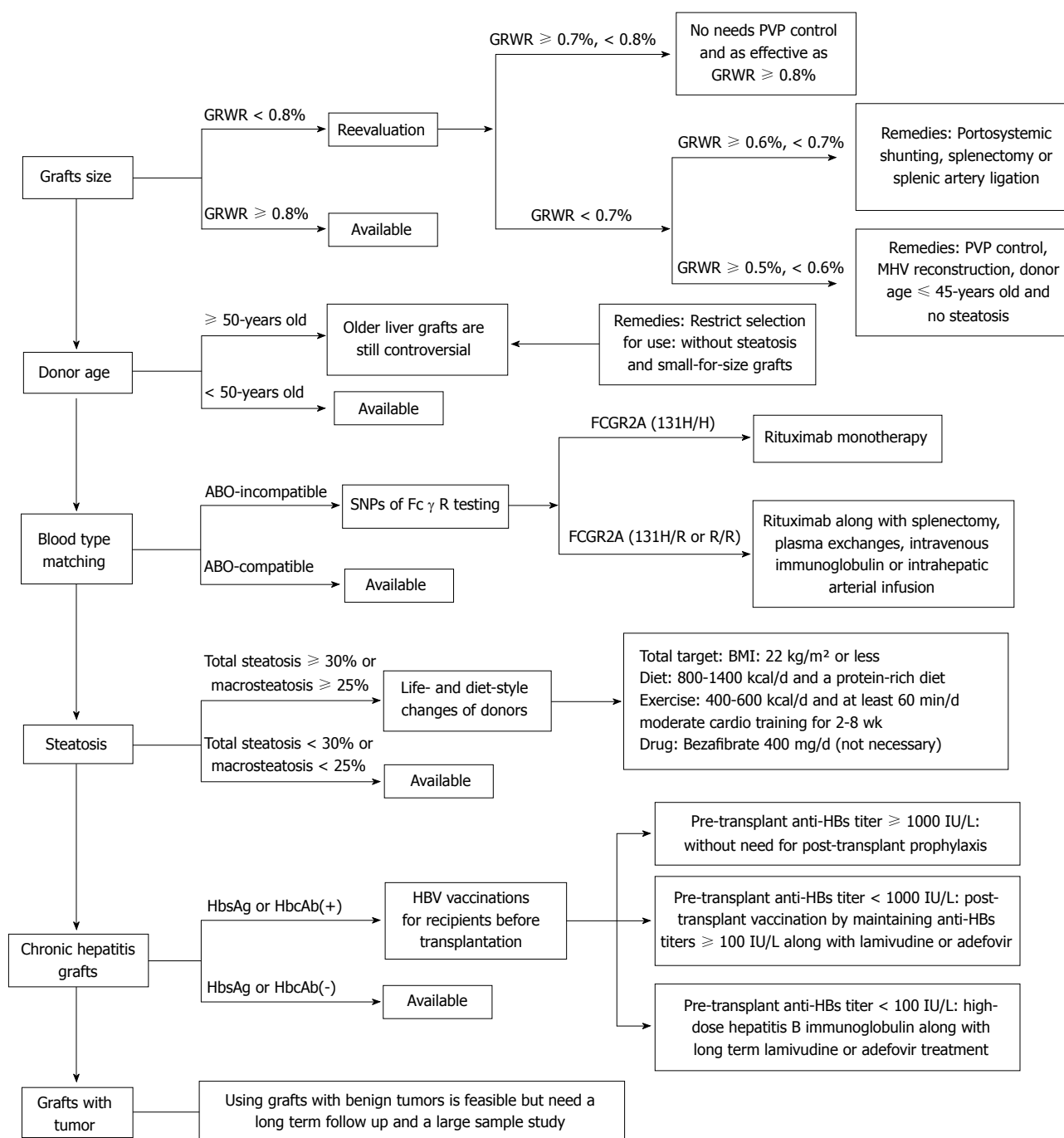


Figure 1 Selective strategies and remedies of using marginal donors in living donor liver transplantation.

marginal grafts.

CONCLUSION

To our knowledge, this is the first review on marginal donors specifically for LDLT. This review, which includes cohort studies, case-control studies, and case reports on marginal liver grafts in LDLT, demonstrated that marginal grafts are a feasible way to expand the options for patients on LT waiting lists in emergency situations (e.g., liver failure or hepatic encephalopathy); however, these grafts place the recipients at a greater risk of liver

dysfunction. Some indispensable treatments are needed to address the deficiencies of these grafts.

There are some new findings in this review: (1) It is permissible for the GRWR to be as low as 0.5%-0.6% (not 0.8%, as currently specified) if PVP is controlled under 15 mmHg; otherwise, outflow reconstruction is needed. (2) There is controversy surrounding older liver grafts. These grafts can be used prudently, but other marginal conditions must be absent (e.g., small-for-size grafts or moderate and severe steatosis). (3) Splenectomy is no longer necessary when an ABO-incompatible LDLT is performed. Rituximab monotherapy is even confirmed

to be an effective treatment if there is a high affinity between IgG FcγR and rituximab. (4) Total steatosis of liver grafts is not a proper predictor of prognosis. Instead, the presence of microsteatosis and macrosteatosis is a crucial factor. Donors with steatosis of the liver can meet the donation criteria through lifestyle and dietary changes before surgery. (5) HbsAg or HbcAb(+) grafts increase the risk of *de novo* HBV infection after transplantation in HbsAg(-) LDLT patients but can also be used safely with active immunotherapy. And (6) Grafts with benign tumors that have been discarded from other patients are feasible, but the long-term prognosis cannot be determined.

According to the new findings of this review listed above, we summarized a selection of strategies for different types of marginal liver grafts in LDLT and their related treatments (Figure 1). With this review, based on more than 100 references, we expect that the transplantation pool can be effectively and safely expanded in the situation of organ shortage.

ACKNOWLEDGMENTS

We thank Dr. Lunan Yan (Department of Liver Surgery and Liver Transplantation Center, West China Hospital of Sichuan University) for the assistance with data collection.

REFERENCES

- Fisher RA.** Living donor liver transplantation: eliminating the wait for death in end-stage liver disease? *Nat Rev Gastroenterol Hepatol* 2017; **14**: 373-382 [PMID: 28196987 DOI: 10.1038/nrgastro.2017.2]
- Makuuchi M,** Kawasaki S, Noguchi T, Hashikura Y, Matsunami H, Hayashi K, Harada H, Kakazu T, Takayama T, Kawarasaki H. Donor hepatectomy for living related partial liver transplantation. *Surgery* 1993; **113**: 395-402 [PMID: 8456395]
- Makuuchi M,** Kawarasaki H, Iwanaka T, Kamada N, Takayama T, Kumon M. Living related liver transplantation. *Surg Today* 1992; **22**: 297-300 [PMID: 1392338]
- Routh D,** Sharma S, Naidu CS, Rao PP, Sharma AK, Ranjan P. Comparison of outcomes in ideal donor and extended criteria donor in deceased donor liver transplant: a prospective study. *Int J Surg* 2014; **12**: 774-777 [PMID: 24947949 DOI: 10.1016/j.ijsu.2014.06.003]
- Nure E,** Liroi MC, Frongillo F, Bianco G, Silvestrini N, Fiorillo C, Sganga G, Agnes S. Overextended Criteria Donors: Experience of an Italian Transplantation Center. *Transplant Proc* 2015; **47**: 2102-2105 [PMID: 26361653 DOI: 10.1016/j.transproceed.2014.11.077]
- Laing RW,** Mergental H, Yap C, Kirkham A, Whilku M, Barton D, Curbishley S, Boteon YL, Neil DA, Hübscher SG, Perera MTPR, Muiesan P, Isaac J, Roberts KJ, Cilliers H, Afford SC, Mirza DF. Viability testing and transplantation of marginal livers (VITTAL) using normothermic machine perfusion: study protocol for an open-label, non-randomised, prospective, single-arm trial. *BMJ Open* 2017; **7**: e017733 [PMID: 29183928 DOI: 10.1136/bmjopen-2017-017733]
- Nemes B,** Gelley F, Zádori G, Piros L, Perneczky J, Kóbori L, Fehérvári I, Görög D. Outcome of liver transplantation based on donor graft quality and recipient status. *Transplant Proc* 2010; **42**: 2327-2330 [PMID: 20692473 DOI: 10.1016/j.transproceed.2010.05.018]
- Giretti G,** Barbier L, Bucur P, Marques F, Perarnau JM, Ferrandière M, Tellier AC, Kerouedan V, Altieri M, Causse X, Debette-Gratien M, Silvain C, Salamé E. Recipient Selection for Optimal Utilization of Discarded Grafts in Liver Transplantation. *Transplantation* 2018; **102**: 775-782 [PMID: 29298235 DOI: 10.1097/TP.0000000000002069]
- Dirican A,** Baskiran A, Dogan M, Ates M, Soyer V, Sarici B, Ozdemir F, Polat Y, Yilmaz S. Evaluation of Potential Donors in Living Donor Liver Transplantation. *Transplant Proc* 2015; **47**: 1315-1318 [PMID: 26093708 DOI: 10.1016/j.transproceed.2015.04.045]
- Kiuchi T,** Kasahara M, Uryuhara K, Inomata Y, Uemoto S, Asonuma K, Egawa H, Fujita S, Hayashi M, Tanaka K. Impact of graft size mismatching on graft prognosis in liver transplantation from living donors. *Transplantation* 1999; **67**: 321-327 [PMID: 10075602]
- Lee DS,** Gil WH, Lee HH, Lee KW, Lee SK, Kim SJ, Choi SH, Heo JS, Hyon WS, Kim GS, Paik SW, Koh KC, Joh JW. Factors affecting graft survival after living donor liver transplantation. *Transplant Proc* 2004; **36**: 2255-2256 [PMID: 15561210 DOI: 10.1016/j.transproceed.2004.08.073]
- Fan ST,** Lo CM, Liu CL, Yong BH, Wong J. Determinants of hospital mortality of adult recipients of right lobe live donor liver transplantation. *Ann Surg* 2003; **238**: 864-869; discussion 869-870 [PMID: 14631223 DOI: 10.1097/01.sla.0000098618.11382.77]
- Moon JI,** Kwon CH, Joh JW, Jung GO, Choi GS, Park JB, Kim JM, Shin M, Kim SJ, Lee SK. Safety of small-for-size grafts in adult-to-adult living donor liver transplantation using the right lobe. *Liver Transpl* 2010; **16**: 864-869 [PMID: 20583075 DOI: 10.1002/lt.22094]
- Lan X,** Li B, Wang XF, Peng CJ, Wei YG, Yan LN. [Feasibility of small size graft following living donor liver transplantation]. *Zhonghua Wei Ke Za Zhi* 2009; **47**: 1218-1220 [PMID: 19781165]
- Selzner M,** Kashfi A, Catral MS, Selzner N, Greig PD, Lilly L, McGilvray ID, Therapondos G, Adcock LE, Ghanekar A, Levy GA, Renner EL, Grant DR. A graft to body weight ratio less than 0.8 does not exclude adult-to-adult right-lobe living donor liver transplantation. *Liver Transpl* 2009; **15**: 1776-1782 [PMID: 19938139 DOI: 10.1002/lt.21955]
- Chen PX,** Yan LN, Wang WT. Outcome of patients undergoing right lobe living donor liver transplantation with small-for-size grafts. *World J Gastroenterol* 2014; **20**: 282-289 [PMID: 24415883 DOI: 10.3748/wjg.v20.i1.282]
- She WH,** Chok KS, Fung JY, Chan AC, Lo CM. Outcomes of right-lobe and left-lobe living-donor liver transplantations using small-for-size grafts. *World J Gastroenterol* 2017; **23**: 4270-4277 [PMID: 28694667 DOI: 10.3748/wjg.v23.i23.4270]
- Lee SD,** Kim SH, Kim YK, Lee SA, Park SJ. Graft-to-recipient weight ratio lower to 0.7% is safe without portal pressure modulation in right-lobe living donor liver transplantation with favorable conditions. *Hepatobiliary Pancreat Dis Int* 2014; **13**: 18-24 [PMID: 24463075]
- Alim A,** Erdogan Y, Yuzer Y, Tokat Y, Oezcelik A. Graft-to-recipient weight ratio threshold adjusted to the model for end-stage liver disease score for living donor liver transplantation. *Liver Transpl* 2016; **22**: 1643-1648 [PMID: 27509534 DOI: 10.1002/lt.24523]
- Lee SG.** A complete treatment of adult living donor liver transplantation: a review of surgical technique and current challenges to expand indication of patients. *Am J Transplant* 2015; **15**: 17-38 [PMID: 25358749 DOI: 10.1111/ajt.12907]
- Goldaracena N,** Echeverri J, Selzner M. Small-for-size syndrome in live donor liver transplantation-Pathways of injury and therapeutic strategies. *Clin Transplant* 2017; **31** [PMID: 27935645 DOI: 10.1111/ctr.12885]
- Graham JA,** Samstein B, Emond JC. Early Graft Dysfunction in Living Donor Liver Transplantation and the Small for Size Syndrome. *Curr Transplant Rep* 2014; **1**: 43-52 [PMID: 27280080 DOI: 10.1007/s40472-013-0006-1]

- 23 **Botha JF**, Langnas AN, Campos BD, Grant WJ, Freise CE, Ascher NL, Mercer DF, Roberts JP. Left lobe adult-to-adult living donor liver transplantation: small grafts and hemiportocaval shunts in the prevention of small-for-size syndrome. *Liver Transpl* 2010; **16**: 649-657 [PMID: 20440774 DOI: 10.1002/lt.22043]
- 24 **Goralczyk AD**, Obed A, Beham A, Tsui TY, Lorf T. Posterior cavoplasty: a new approach to avoid venous outflow obstruction and symptoms for small-for-size syndrome in right lobe living donor liver transplantation. *Langenbecks Arch Surg* 2011; **396**: 389-395 [PMID: 21207055 DOI: 10.1007/s00423-010-0736-9]
- 25 **Soejima Y**, Shimada M, Suehiro T, Hiroshige S, Ninomiya M, Shiotani S, Harada N, Hideki I, Yonemura Y, Maehara Y. Outcome analysis in adult-to-adult living donor liver transplantation using the left lobe. *Liver Transpl* 2003; **9**: 581-586 [PMID: 12783399 DOI: 10.1053/jlts.2003.50114]
- 26 **Ben-Haim M**, Emre S, Fishbein TM, Sheiner PA, Bodian CA, Kim-Schluger L, Schwartz ME, Miller CM. Critical graft size in adult-to-adult living donor liver transplantation: impact of the recipient's disease. *Liver Transpl* 2001; **7**: 948-953 [PMID: 11699030 DOI: 10.1053/jlts.2001.29033]
- 27 **Sudhindran S**, Menon RN, Balakrishnan D. Challenges and Outcome of Left-lobe Liver Transplants in Adult Living Donor Liver Transplants. *J Clin Exp Hepatol* 2012; **2**: 181-187 [PMID: 25755426 DOI: 10.1016/S0973-6883(12)60106-6]
- 28 **Yi NJ**, Suh KS, Cho YB, Lee HW, Cho EH, Cho JY, Shin WY, Kim J, Lee KU. The right small-for-size graft results in better outcomes than the left small-for-size graft in adult-to-adult living donor liver transplantation. *World J Surg* 2008; **32**: 1722-1730 [PMID: 18553047 DOI: 10.1007/s00268-008-9641-6]
- 29 **Soejima Y**, Shirabe K, Taketomi A, Yoshizumi T, Uchiyama H, Ikegami T, Ninomiya M, Harada N, Ijichi H, Maehara Y. Left lobe living donor liver transplantation in adults. *Am J Transplant* 2012; **12**: 1877-1885 [PMID: 22429497 DOI: 10.1111/j.1600-6143.2012.04022.x]
- 30 **Gruttadauria S**, Pagano D, Liotta R, Tropea A, Tuzzolino F, Marrone G, Mamone G, Marsh JW, Miraglia R, Luca A, Vizzini G, Gridelli BG. Liver Volume Restoration and Hepatic Microarchitecture in Small-for-Size Syndrome. *Ann Transplant* 2015; **381**: 381-389 [PMID: 26148966 DOI: 10.12659/AOT.894082]
- 31 **Shoreem H**, Gad EH, Soliman H, Hegazy O, Saleh S, Zakaria H, Ayoub E, Kamel Y, Abouelella K, Ibrahim T, Marawan I. Small for size syndrome difficult dilemma: Lessons from 10 years single centre experience in living donor liver transplantation. *World J Hepatol* 2017; **9**: 930-944 [PMID: 28824744 DOI: 10.4254/wjh.v9.i21.930]
- 32 **Lauro A**, Diago Uso T, Quintini C, Di Benedetto F, Dazzi A, De Ruvo N, Masetti M, Cautero N, Risaliti A, Zanfi C, Ramacciato G, Begliomini B, Siniscalchi A, Miller CM, Pinna AD. Adult-to-adult living donor liver transplantation using left lobes: the importance of surgical modulations on portal graft inflow. *Transplant Proc* 2007; **39**: 1874-1876 [PMID: 17692638 DOI: 10.1016/j.transproceed.2007.05.052]
- 33 **Kim DG**, Moon IS, Kim SJ, Lee YJ, Lee MD. Effect of middle hepatic vein reconstruction in living donor liver transplantation using right lobe. *Transplant Proc* 2006; **38**: 2099-2101 [PMID: 16980012 DOI: 10.1016/j.transproceed.2006.06.005]
- 34 **Peng CJ**, Wang XF, Li B, Wei YG, Yan LN, Wen TF, Yang JY, Wang WT, Zhao JC. Efficacy of middle hepatic vein reconstruction in adult right-lobe living donor liver transplantation. *Hepatobiliary Pancreat Dis Int* 2010; **9**: 135-138 [PMID: 20382582]
- 35 **Wu H**, Yan LN, Li B, Zeng Y, Wen TF, Zhao JC, Wang WT, Yang JY, Xu MQ, Chen ZY, Lu Q, Luo HZ, Li J. Hepatic venous outflow reconstruction in right lobe graft without middle hepatic vein. *Hepatol Res* 2007; **37**: 1044-1051 [PMID: 17645520 DOI: 10.1111/j.1872-034X.2007.00121.x]
- 36 **Asakuma M**, Fujimoto Y, Bourquain H, Uryuhara K, Hayashi M, Tanigawa N, Peitgen HO, Tanaka K. Graft selection algorithm based on congestion volume for adult living donor liver transplantation. *Am J Transplant* 2007; **7**: 1788-1796 [PMID: 17524079 DOI: 10.1111/j.1600-6143.2007.01849.x]
- 37 **Navasa M**, Feu F, García-Pagán JC, Jiménez W, Llach J, Rimola A, Bosch J, Rodés J. Hemodynamic and humoral changes after liver transplantation in patients with cirrhosis. *Hepatology* 1993; **17**: 355-360 [PMID: 8444409]
- 38 **Matsudaira S**, Ishizaki Y, Yoshimoto J, Fujiwara N, Kawasaki S. Risk Factors for Intractable Ascites After Adult-to-Adult Living Donor Liver Transplantation Using Left Lobe. *Transplant Direct* 2017; **3**: e138 [PMID: 28361122 DOI: 10.1097/TXD.0000000000000652]
- 39 **Mukhtar A**, Dabbous H. Modulation of splanchnic circulation: Role in perioperative management of liver transplant patients. *World J Gastroenterol* 2016; **22**: 1582-1592 [PMID: 26819524 DOI: 10.3748/wjg.v22.i4.1582]
- 40 **Kanetkar AV**, Balakrishnan D, Sudhindran S, Dhar P, Gopalakrishnan U, Menon R, Sudheer OV. Is Portal Venous Pressure or Porto-systemic Gradient Really A Harbinger of Poor Outcomes After Living Donor Liver Transplantation? *J Clin Exp Hepatol* 2017; **7**: 235-246 [PMID: 28970711 DOI: 10.1016/j.jceh.2017.01.114]
- 41 **Ikegami T**, Shirabe K, Yoshizumi T, Aishima S, Taketomi YA, Soejima Y, Uchiyama H, Kayashima H, Toshima T, Maehara Y. Primary graft dysfunction after living donor liver transplantation is characterized by delayed functional hyperbilirubinemia. *Am J Transplant* 2012; **12**: 1886-1897 [PMID: 22494784 DOI: 10.1111/j.1600-6143.2012.04052.x]
- 42 **Demetris AJ**, Kelly DM, Eghtesad B, Fontes P, Wallis Marsh J, Tom K, Tan HP, Shaw-Stiffel T, Boig L, Novelli P, Planinsic R, Fung JJ, Marcos A. Pathophysiologic observations and histopathologic recognition of the portal hyperperfusion or small-for-size syndrome. *Am J Surg Pathol* 2006; **30**: 986-993 [PMID: 16861970]
- 43 **Uemura T**, Wada S, Kaido T, Mori A, Ogura Y, Yagi S, Fujimoto Y, Ogawa K, Hata K, Yoshizawa A, Okajima H, Uemoto S. How far can we lower graft-to-recipient weight ratio for living donor liver transplantation under modulation of portal venous pressure? *Surgery* 2016; **159**: 1623-1630 [PMID: 26936527 DOI: 10.1016/j.surg.2016.01.009]
- 44 **Takahashi Y**, Matsuura T, Yoshimaru K, Yanagi Y, Hayashida M, Taguchi T. Liver graft-to-spleen volume ratio as a useful predictive factor of the early graft function in children and young adults transplanted for biliary atresia: a retrospective study. *Transpl Int* 2018; **31**: 620-628 [PMID: 29424478 DOI: 10.1111/tri.13131]
- 45 **Karademir S**, Astarcioglu H, Ozbilgin M, Ozkardesler S, Yilmaz T, Akarsu M, Akan M, Ozzeybek D, Obuz F, Astarcioglu I. Efficacy of right anterior sector drainage reconstruction in right-lobe live-donor transplantation. *Transplant Proc* 2006; **38**: 3582-3584 [PMID: 17175337 DOI: 10.1016/j.transproceed.2006.10.043]
- 46 **Mori S**, Park MS, Kim H, Choi Y, Hong G, Yi NJ, Lee KW, Suh KS. Dysfunction in Patients With Small-for-Size Grafts After Living Donor Liver Transplantation. *Int Surg* 2015; **100**: 524-530 [PMID: 25785339 DOI: 10.9738/INTSURG-D-14-00016.1]
- 47 **Kim SH**, Lee EC, Park SJ. Impact of preserved collateral veins on small-for-size grafts in living donor liver transplantation. *Hepatol Res* 2018; **48**: 295-302 [PMID: 29125895 DOI: 10.1111/hepr.13002]
- 48 **Hessheimer AJ**, Fondevila C, Taurá P, Muñoz J, Sánchez O, Fuster J, Rimola A, García-Valdecasas JC. Decompression of the portal bed and twice-baseline portal inflow are necessary for the functional recovery of a "small-for-size" graft. *Ann Surg* 2011; **253**: 1201-1210 [PMID: 21587116 DOI: 10.1097/SLA.0b013e3181ffb2d7]
- 49 **Xiao L**, Li F, Wei B, Li B, Tang CW. Small-for-size syndrome after living donor liver transplantation: successful treatment with a transjugular intrahepatic portosystemic shunt. *Liver Transpl* 2012; **18**: 1118-1120 [PMID: 22511462 DOI: 10.1002/lt.23457]
- 50 **Sato Y**, Oya H, Yamamoto S, Kobayashi T, Hara Y, Kokai H, Hatakeyama K. Method for spontaneous constriction and closure of portocaval shunt using a ligamentum teres hepatis in small-for-size

- graft liver transplantation. *Transplantation* 2010; **90**: 1200-1203 [PMID: 21088651 DOI: 10.1097/TP.0b013e3181fa93e0]
- 51 **Nutu OA**, Justo Alonso I, Marcacuzco Quinto AA, Calvo Pulido J, Jiménez Romero LC. Complete splenic embolization for the treatment of refractory ascites after liver transplantation. *Rev Esp Enferm Dig* 2018; **110**: 257-259 [PMID: 29411988 DOI: 10.17235/reed.2018.5338/2017]
 - 52 **Badawy A**, Hamaguchi Y, Satoru S, Kaido T, Okajima H, Uemoto S. Evaluation of safety of concomitant splenectomy in living donor liver transplantation: a retrospective study. *Transpl Int* 2017; **30**: 914-923 [PMID: 28512755 DOI: 10.1111/tri.12985]
 - 53 **Troisi RI**, Berardi G, Tomassini F, Sainz-Barriga M. Graft inflow modulation in adult-to-adult living donor liver transplantation: A systematic review. *Transplant Rev (Orlando)* 2017; **31**: 127-135 [PMID: 27989547 DOI: 10.1016/j.tre.2016.11.002]
 - 54 **Xu Y**, Chen H, Yeh H, Wang H, Leng J, Dong J. Living donor liver transplantation using dual grafts: Experience and lessons learned from cases worldwide. *Liver Transpl* 2015; **21**: 1438-1448 [PMID: 26336078 DOI: 10.1002/lt.24315]
 - 55 **Gao W**, Zhang L, Zhang Y, Sun C, Chen X, Wang Y. Adipose-derived mesenchymal stem cells promote liver regeneration and suppress rejection in small-for-size liver allograft. *Transpl Immunol* 2017; **45**: 1-7 [PMID: 28778713 DOI: 10.1016/j.trim.2017.07.005]
 - 56 **Kobayashi T**, Sato Y, Yamamoto S, Oya H, Hara Y, Watanabe T, Kokai H, Hatakeyama K. Feasibility of auxiliary partial living donor liver transplantation for fulminant hepatic failure as an aid for small-for-size graft: single center experience. *Transplant Proc* 2009; **41**: 262-264 [PMID: 19249530 DOI: 10.1016/j.transproceed.2008.10.025]
 - 57 **Dasari BVM**, Schlegel A, Mergental H, Perera MTPR. The use of old donors in liver transplantation. *Best Pract Res Clin Gastroenterol* 2017; **31**: 211-217 [PMID: 28624109 DOI: 10.1016/j.bpg.2017.03.002]
 - 58 **Tanemura A**, Mizuno S, Wada H, Yamada T, Nobori T, Isaji S. Donor age affects liver regeneration during early period in the graft liver and late period in the remnant liver after living donor liver transplantation. *World J Surg* 2012; **36**: 1102-1111 [PMID: 22374540 DOI: 10.1007/s00268-012-1496-1]
 - 59 **Abdelfattah MR**, Elsiehy H. Reappraisal of upper age limit for adult living-donor liver transplantation using right lobe grafts: an outcome analysis. *Eur J Gastroenterol Hepatol* 2015; **27**: 593-599 [PMID: 25822867 DOI: 10.1097/MEG.0000000000000322]
 - 60 **Ono Y**, Kawachi S, Hayashida T, Wakui M, Tanabe M, Itano O, Obara H, Shinoda M, Hibi T, Oshima G, Tani N, Mihara K, Kitagawa Y. The influence of donor age on liver regeneration and hepatic progenitor cell populations. *Surgery* 2011; **150**: 154-161 [PMID: 21719061 DOI: 10.1016/j.surg.2011.05.004]
 - 61 **Akamatsu N**, Sugawara Y, Tamura S, Kaneko J, Matsui Y, Togashi J, Makuuchi M. Impact of live donor age on liver transplantation. *Transplant Proc* 2007; **39**: 3189-3193 [PMID: 18089350 DOI: 10.1016/j.transproceed.2007.03.116]
 - 62 **Kawano Y**, Ishikawa N, Aida J, Sanada Y, Izumiyama-Shimomura N, Nakamura K, Poon SS, Matsumoto K, Mizuta K, Uchida E, Tajiri T, Kawarasaki H, Takubo K. Q-FISH measurement of hepatocyte telomere lengths in donor liver and graft after pediatric living-donor liver transplantation: donor age affects telomere length sustainability. *PLoS One* 2014; **9**: e93749 [PMID: 24727734 DOI: 10.1371/journal.pone.0093749]
 - 63 **Imamura H**, Hidaka M, Soyama A, Kitasato A, Adachi T, Ono S, Natsuda K, Hara T, Kugiyama T, Baimakhanov Z, Okada S, Fujita F, Kanetaka K, Takatsuki M, Kuroki T, Eguchi S. A Donor Age-Based and Graft Volume-Based Analysis for Living Donor Liver Transplantation in Elderly Recipients. *Transplant Direct* 2017; **3**: e168 [PMID: 28706971 DOI: 10.1097/TXD.0000000000000688]
 - 64 **Dayangac M**, Taner CB, Yaprak O, Demirbas T, Balci D, Duran C, Yuzer Y, Tokat Y. Utilization of elderly donors in living donor liver transplantation: when more is less? *Liver Transpl* 2011; **17**: 548-555 [PMID: 21506243 DOI: 10.1002/lt.22276]
 - 65 **Yoshizumi T**, Taketomi A, Uchiyama H, Harada N, Kayashima H, Yamashita Y, Soejima Y, Shimada M, Maehara Y. Graft size, donor age, and patient status are the indicators of early graft function after living donor liver transplantation. *Liver Transpl* 2008; **14**: 1007-1013 [PMID: 18581462 DOI: 10.1002/lt.21462]
 - 66 **Han JH**, You YK, Na GH, Kim EY, Lee SH, Hong TH, Kim DG. Outcomes of living donor liver transplantation using elderly donors. *Ann Surg Treat Res* 2014; **86**: 184-191 [PMID: 24783177 DOI: 10.4174/ast.2014.86.4.184]
 - 67 **Kamo N**, Kaido T, Hammad A, Ogawa K, Fujimoto Y, Uemura T, Mori A, Hatano E, Okajima H, Uemoto S. Impact of elderly donors for liver transplantation: A single-center experience. *Liver Transpl* 2015; **21**: 591-598 [PMID: 25641778 DOI: 10.1002/lt.24086]
 - 68 **Shin M**, Moon HH, Kim JM, Park JB, Kwon CH, Kim SJ, Joh JW. Importance of donor-recipient age gradient to the prediction of graft outcome after living donor liver transplantation. *Transplant Proc* 2013; **45**: 3005-3012 [PMID: 24157024 DOI: 10.1016/j.transproceed.2013.08.018]
 - 69 **Kubota T**, Hata K, Sozu T, Ueda Y, Hirao H, Okamura Y, Tamaki I, Yoshikawa J, Kusakabe J, Tanaka H, Gageyama S, Anazawa T, Yoshizawa A, Yagi S, Yamashiki N, Okajima H, Kaido T, Uemoto S. Impact of Donor Age on Recipient Survival in Adult-to-Adult Living-donor Liver Transplantation. *Ann Surg* 2018; **267**: 1126-1133 [PMID: 28288061 DOI: 10.1097/SLA.0000000000002194]
 - 70 **Katsuragawa H**, Yamamoto M, Katagiri S, Yoshitoshi K, Ariizumi S, Kotera Y, Takahashi Y, Takasaki K. Graft size and donor age are independent factors for graft loss in adult-to-adult living-donor liver transplantation using the left liver. *J Hepatobiliary Pancreat Surg* 2009; **16**: 178-183 [PMID: 19165414 DOI: 10.1007/s00534-008-0026-x]
 - 71 **Selzner N**, Girgrah N, Lilly L, Guindi M, Selzner M, Therapondos G, Adeyi O, McGilvray I, Catral M, Greig PD, Grant D, Levy G, Renner EL. The difference in the fibrosis progression of recurrent hepatitis C after live donor liver transplantation versus deceased donor liver transplantation is attributable to the difference in donor age. *Liver Transpl* 2008; **14**: 1778-1786 [PMID: 19025914 DOI: 10.1002/lt.21598]
 - 72 **Wang K**, Jiang WT, Deng YL, Pan C, Shen ZY. Effect of donor age on graft function and long-term survival of recipients undergoing living donor liver transplantation. *Hepatobiliary Pancreat Dis Int* 2015; **14**: 50-55 [PMID: 25655290]
 - 73 **Ikegami T**, Taketomi A, Ohta R, Soejima Y, Yoshizumi T, Shimada M, Maehara Y. Donor age in living donor liver transplantation. *Transplant Proc* 2008; **40**: 1471-1475 [PMID: 18589131 DOI: 10.1016/j.transproceed.2008.02.084]
 - 74 **Li C**, Wen TF, Yan LN, Li B, Yang JY, Xu MQ, Wang WT, Wei YG. Safety of living donor liver transplantation using older donors. *J Surg Res* 2012; **178**: 982-987 [PMID: 22835951 DOI: 10.1016/j.jss.2012.06.065]
 - 75 **Goldaracena N**, Sapisochin G, Spetzler V, Echeverri J, Kathis M, Catral MS, Greig PD, Lilly L, McGilvray ID, Levy GA, Ghanekar A, Renner EL, Grant DR, Selzner M, Selzner N. Live Donor Liver Transplantation With Older (≥ 50 Years) Versus Younger Donors: Does Age Matter? *Ann Surg* 2016; **263**: 979-985 [PMID: 26106842 DOI: 10.1097/SLA.0000000000001337]
 - 76 **Kim SH**, Lee EC, Shim JR, Park SJ. Right lobe living donors ages 55 years old and older in liver transplantation. *Liver Transpl* 2017; **23**: 1305-1311 [PMID: 28734130 DOI: 10.1002/lt.24823]
 - 77 **Starzl TE**, Koep LJ, Halgrimson CG, Hood J, Schroter GP, Porter KA, Weil R 3rd. Fifteen years of clinical liver transplantation. *Gastroenterology* 1979; **77**: 375-388 [PMID: 376395]
 - 78 **Sanchez-Urdazpal L**, Sterioff S, Janes C, Schwerman L, Rosen C, Krom RA. Increased bile duct complications in ABO incompatible liver transplant recipients. *Transplant Proc* 1991; **23**: 1440-1441 [PMID: 1989259]
 - 79 **Gugenheim J**, Samuel D, Fabiani B, Saliba F, Castaing D, Reynes M, Bismuth H. Rejection of ABO incompatible liver allografts in man. *Transplant Proc* 1989; **21**: 2223-2224 [PMID: 2652718]
 - 80 **Miyata R**, Shimazu M, Tanabe M, Kawachi S, Hoshino K,

- Wakabayashi G, Kawai Y, Kitajima M. Clinical characteristics of thrombotic microangiopathy following ABO incompatible living donor liver transplantation. *Liver Transpl* 2007; **13**: 1455-1462 [PMID: 17902122 DOI: 10.1002/lt.21253]
- 81 **Oya H**, Sato Y, Yamamoto S, Nakatsuka H, Kobayashi T, Watanabe T, Kokai H, Hatakeyama K. Thrombotic microangiopathy after ABO-incompatible living donor liver transplantation: a case report. *Transplant Proc* 2008; **40**: 2549-2551 [PMID: 18929797 DOI: 10.1016/j.transproceed.2008.07.117]
 - 82 **Kishida N**, Shinoda M, Itano O, Obara H, Kitago M, Hibi T, Yagi H, Abe Y, Matsubara K, Odaira M, Tanabe M, Shimazu M, Kitagawa Y. Increased Incidence of Thrombotic Microangiopathy After ABO-Incompatible Living Donor Liver Transplantation. *Ann Transplant* 2016; **21**: 755-764 [PMID: 27956735]
 - 83 **Song GW**, Lee SG, Hwang S, Kim KH, Ahn CS, Moon DB, Ha TY, Jung DH, Park GC, Kang SH, Jung BH, Yoon YI, Kim N. Biliary stricture is the only concern in ABO-incompatible adult living donor liver transplantation in the rituximab era. *J Hepatol* 2014; **61**: 575-582 [PMID: 24801413 DOI: 10.1016/j.jhep.2014.04.039]
 - 84 **Ikegami T**, Yoshizumi T, Soejima Y, Uchiyama H, Shirabe K, Maehara Y. Feasible usage of ABO incompatible grafts in living donor liver transplantation. *Hepatobiliary Surg Nutr* 2016; **5**: 91-97 [PMID: 27115002 DOI: 10.3978/j.issn.2304-3881.2015.06.02]
 - 85 **Sanchez-Urdazpal L**, Batts KP, Gores GJ, Moore SB, Sterioff S, Wiesner RH, Krom RA. Increased bile duct complications in liver transplantation across the ABO barrier. *Ann Surg* 1993; **218**: 152-158 [PMID: 8342994]
 - 86 **Demetris AJ**, Jaffe R, Tzakis A, Ramsey G, Todo S, Belle S, Esquivel C, Shapiro R, Markus B, Mroczek E. Antibody-mediated rejection of human orthotopic liver allografts. A study of liver transplantation across ABO blood group barriers. *Am J Pathol* 1988; **132**: 489-502 [PMID: 3046369]
 - 87 **Choi SH**, Kim KW, Kim SY, Kim JS, Kwon JH, Song GW, Lee SG. Computed tomography findings in ABO-incompatible living donor liver transplantation recipients with biliary strictures. *Eur Radiol* 2018; **28**: 2572-2581 [PMID: 29294154 DOI: 10.1007/s00330-017-5226-9]
 - 88 **Yamada Y**, Hoshino K, Shimojima N, Shinoda M, Obara H, Kawachi S, Fuchimoto Y, Tanabe M, Kitagawa Y, Morikawa Y. Idiopathic hypereosinophilic syndrome in a case with ABO-incompatible liver transplantation for biliary atresia complicated by portal vein thrombosis. *Pediatr Transplant* 2010; **14**: e49-e53 [PMID: 20042017 DOI: 10.1111/j.1399-3046.2009.01170.x]
 - 89 **Kawagishi N**, Takeda I, Miyagi S, Satoh K, Akamatsu Y, Sekiguchi S, Satomi S. Long-term outcome of ABO-incompatible living-donor liver transplantation: a single-center experience. *J Hepatobiliary Pancreat Surg* 2009; **16**: 468-472 [PMID: 19335338 DOI: 10.1007/s00534-009-0074-x]
 - 90 **Yoon YI**, Song GW, Lee SG, Hwang S, Kim KH, Kim SH, Kang WH, Cho HD, Jwa EK, Kwon JH, Tak EY, Kirchner VA. Outcome of ABO-incompatible adult living-donor liver transplantation for patients with hepatocellular carcinoma. *J Hepatol* 2018; **68**: 1153-1162 [PMID: 29452208 DOI: 10.1016/j.jhep.2018.02.002]
 - 91 **Sakai H**, Tanaka Y, Tazawa H, Shimizu S, Verma S, Ohira M, Tahara H, Ide K, Ishiyama K, Kobayashi T, Onoe T, Ohdan H. Effect of Fc-γ Receptor Polymorphism on Rituximab-Mediated B Cell Depletion in ABO-Incompatible Adult Living Donor Liver Transplantation. *Transplant Direct* 2017; **3**: e164 [PMID: 28620648 DOI: 10.1097/TXD.0000000000000683]
 - 92 **Egawa H**, Umeshita K, Uemoto S. Optimal dosage regimen for rituximab in ABO-incompatible living donor liver transplantation. *J Hepatobiliary Pancreat Sci* 2017; **24**: 89-94 [PMID: 28002655 DOI: 10.1002/jhpb.419]
 - 93 **Ikegami T**, Taketomi A, Soejima Y, Iguchi T, Sanefuji K, Kayashima H, Yoshizumi T, Harada N, Maehara Y. Successful ABO incompatible living donor liver transplantation in a patient with high isoagglutinin titer using high-dose intravenous immunoglobulin. *Transplant Proc* 2007; **39**: 3491-3494 [PMID: 18089417 DOI: 10.1016/j.transproceed.2007.09.028]
 - 94 **Ikegami T**, Taketomi A, Soejima Y, Yoshizumi T, Uchiyama H, Harada N, Iguchi T, Hashimoto N, Maehara Y. Rituximab, IVIG, and plasma exchange without graft local infusion treatment: a new protocol in ABO incompatible living donor liver transplantation. *Transplantation* 2009; **88**: 303-307 [PMID: 19667930 DOI: 10.1097/TP.0b013e3181adcae6]
 - 95 **Usui M**, Isaji S, Mizuno S, Sakurai H, Uemoto S. Experiences and problems pre-operative anti-CD20 monoclonal antibody infusion therapy with splenectomy and plasma exchange for ABO-incompatible living-donor liver transplantation. *Clin Transplant* 2007; **21**: 24-31 [PMID: 17302588 DOI: 10.1111/j.1399-0012.2006.00572.x]
 - 96 **Chen G**, Sun J, Wei S, Chen Y, Tang G, Xie Z, Xu H, Chen J, Zhao H, Yuan Z, Wang W, Liu G, Wang B, Niu B. Simultaneous ABO-incompatible living-donor liver transplantation and splenectomy without plasma exchange in China: Two case reports. *J Int Med Res* 2017; **45**: 2146-2152 [PMID: 28635356 DOI: 10.1177/0300060517110407]
 - 97 **Uchiyama H**, Mano Y, Taketomi A, Soejima Y, Yoshizumi T, Ikegami T, Shirabe K, Maehara Y. Kinetics of anti-blood type isoagglutinin titers and B lymphocytes in ABO-incompatible living donor liver transplantation with rituximab and plasma exchange. *Transplantation* 2011; **92**: 1134-1139 [PMID: 21946174 DOI: 10.1097/TP.0b013e318231e9f8]
 - 98 **Soin AS**, Raut V, Mohanka R, Rastogi A, Goja S, Balachandran M, Saigal S, Saraf N, Bhargui P, Sumana KR, Singla P, Srinivasan T, Choudhary N, Tiwari A, Raina V, Govil D, Mohan N, Vohra V. Use of ABO-incompatible grafts in living donor liver transplantation-first report from India. *Indian J Gastroenterol* 2014; **33**: 72-76 [PMID: 24369388 DOI: 10.1007/s12664-013-0424-0]
 - 99 **Rummler S**, Bauschke A, Baerthel E, Juette H, Maier K, Malessa C, Barz D, Settmacher U. ABO-Incompatible Living Donor Liver Transplantation in Focus of Antibody Rebound. *Transfus Med Hemother* 2017; **44**: 46-51 [PMID: 28275333 DOI: 10.1159/000450792]
 - 100 **Kim JD**, Choi DL, Kim SG, Lee AJ. Single-Center Experience of ABO-Incompatible Living-Donor Liver Transplantation With a New Simplified Intravenous Immunoglobulin Protocol: A Propensity Score-Matching Analysis. *Transplant Proc* 2016; **48**: 1134-1138 [PMID: 27320573 DOI: 10.1016/j.transproceed.2016.02.040]
 - 101 **Kim JM**, Kwon CH, Joh JW, Kang ES, Park JB, Lee JH, Kim SJ, Paik SW, Lee SK, Kim DW. ABO-incompatible living donor liver transplantation is suitable in patients without ABO-matched donor. *J Hepatol* 2013; **59**: 1215-1222 [PMID: 23928408 DOI: 10.1016/j.jhep.2013.07.035]
 - 102 **Kawagishi N**, Satoh K, Enomoto Y, Akamatsu Y, Sekiguchi S, Fukumori T, Fujimori K, Satomi S. New strategy for ABO-incompatible living donor liver transplantation with anti-CD20 antibody (rituximab) and plasma exchange. *Transplant Proc* 2005; **37**: 1205-1206 [PMID: 15848670 DOI: 10.1016/j.transproceed.2004.12.114]
 - 103 **Kim SH**, Lee EC, Shim JR, Park SJ. A simplified protocol using rituximab and immunoglobulin for ABO-incompatible low-titre living donor liver transplantation. *Liver Int* 2018; **38**: 932-939 [PMID: 29053910 DOI: 10.1111/liv.13614]
 - 104 **Yoshizawa A**, Sakamoto S, Ogawa K, Kasahara M, Uryuhara K, Oike F, Ueda M, Takada Y, Egawa H, Tanaka K. New protocol of immunosuppression for liver transplantation across ABO barrier: the use of Rituximab, hepatic arterial infusion, and preservation of spleen. *Transplant Proc* 2005; **37**: 1718-1719 [PMID: 15919443 DOI: 10.1016/j.transproceed.2005.03.148]
 - 105 **Egawa H**, Teramukai S, Haga H, Tanabe M, Fukushima M, Shimazu M. Present status of ABO-incompatible living donor liver transplantation in Japan. *Hepatology* 2008; **47**: 143-152 [PMID: 17929298 DOI: 10.1002/hep.21928]
 - 106 **Yamamoto H**, Uchida K, Kawabata S, Isono K, Miura K, Hayashida S, Oya Y, Sugawara Y, Inomata Y. Feasibility of

- Monotherapy by Rituximab Without Additional Desensitization in ABO-incompatible Living-Donor Liver Transplantation. *Transplantation* 2018; **102**: 97-104 [PMID: 28938311 DOI: 10.1097/TP.0000000000001956]
- 107 **Jiménez-Castro MB**, Negrete-Sánchez E, Casillas-Ramírez A, Gulfo J, Álvarez-Mercado AI, Cornide-Petronio ME, Gracia-Sancho J, Rodés J, Peralta C. The effect of cortisol in rat steatotic and non-steatotic liver transplantation from brain-dead donors. *Clin Sci (Lond)* 2017; **131**: 733-746 [PMID: 28246131 DOI: 10.1042/CS20160676]
 - 108 **Xue M**, Lv C, Chen X, Liang J, Zhao C, Zhang Y, Huang X, Sun Q, Wang T, Gao J, Zhou J, Yu M, Fan J, Gao X. Donor liver steatosis: A risk factor for early new-onset diabetes after liver transplantation. *J Diabetes Investig* 2017; **8**: 181-187 [PMID: 27511316 DOI: 10.1111/jdi.12560]
 - 109 **Perkins JD**. Saying “Yes” to obese living liver donors: short-term intensive treatment for donors with hepatic steatosis in living-donor liver transplantation. *Liver Transpl* 2006; **12**: 1012-1013 [PMID: 16721781 DOI: 10.1002/lt.20807]
 - 110 **Kotecha HL**, Saraf N, Saigal S, Choudhary NS, Yadav A, Mohanka R, Rastogi A, Menon PB, Goja S, Soin AS. NAFLD is the leading cause of donor rejection in living donor liver transplantation. *J Clin Exp Hepatol* 2013; **3**: S116 [DOI: 10.1016/j.jceh.2013.03.201]
 - 111 **Cho JY**, Suh KS, Shin WY, Lee HW, Yi NJ, Kim MA, Jang JJ, Lee KU. Expansion of hepatic progenitor cell in fatty liver graft after living donor liver transplantation. *Transpl Int* 2010; **23**: 530-537 [PMID: 20003044 DOI: 10.1111/j.1432-2277.2009.01020.x]
 - 112 **Cho JY**, Suh KS, Lee HW, Cho EH, Yang SH, Cho YB, Yi NJ, Kim MA, Jang JJ, Lee KU. Hepatic steatosis is associated with intrahepatic cholestasis and transient hyperbilirubinemia during regeneration after living donor liver transplantation. *Transpl Int* 2006; **19**: 807-813 [PMID: 16961772 DOI: 10.1111/j.1432-2277.2006.00355.x]
 - 113 **Cho JY**, Suh KS, Kwon CH, Yi NJ, Cho SY, Jang JJ, Kim SH, Lee KU. The hepatic regeneration power of mild steatotic grafts is not impaired in living-donor liver transplantation. *Liver Transpl* 2005; **11**: 210-217 [PMID: 15666394 DOI: 10.1002/lt.20340]
 - 114 **Gao F**, Xu X, Ling Q, Wu J, Zhou L, Xie HY, Wang HP, Zheng SS. Efficacy and safety of moderately steatotic donor liver in transplantation. *Hepatobiliary Pancreat Dis Int* 2009; **8**: 29-33 [PMID: 19208511]
 - 115 **Knaak M**, Goldaracena N, Doyle A, Cattral MS, Greig PD, Lilly L, McGilvray ID, Levy GA, Ghanekar A, Renner EL, Grant DR, Selzner N, Selzner N. Donor BMI; 30 Is Not a Contraindication for Live Liver Donation. *Am J Transplant* 2017; **17**: 754-760 [PMID: 27545327 DOI: 10.1111/ajt.14019]
 - 116 **Han S**, Ha SY, Park CK, Joh JW, Kwon CH, Kwon GY, Kim G, Gwak MS, Jeong WK, Ko JS. Microsteatosis may not interact with macrosteatosis in living donor liver transplantation. *J Hepatol* 2015; **62**: 556-562 [PMID: 25450710 DOI: 10.1016/j.jhep.2014.10.027]
 - 117 **Oshita A**, Tashiro H, Amano H, Kobayashi T, Onoe T, Ide K, Takaki S, Takahashi S, Arihiro K, Chayama K, Ohdan H. Safety and feasibility of diet-treated donors with steatotic livers at the initial consultation for living-donor liver transplantation. *Transplantation* 2012; **93**: 1024-1030 [PMID: 22495493 DOI: 10.1097/TP.0b013e31824c9e25]
 - 118 **Nakamuta M**, Morizono S, Soejima Y, Yoshizumi T, Aishima S, Takasugi S, Yoshimitsu K, Enjoji M, Kotoh K, Taketomi A, Uchiyama H, Shimada M, Nawata H, Maehara Y. Short-term intensive treatment for donors with hepatic steatosis in living-donor liver transplantation. *Transplantation* 2005; **80**: 608-612 [PMID: 16177634]
 - 119 **Choudhary NS**, Saraf N, Saigal S, Gautam D, Lipi L, Rastogi A, Goja S, Menon PB, Bhangui P, Ramchandra SK, Soin AS. Rapid Reversal of Liver Steatosis With Life Style Modification in Highly Motivated Liver Donors. *J Clin Exp Hepatol* 2015; **5**: 123-126 [PMID: 26155039 DOI: 10.1016/j.jceh.2015.04.002]
 - 120 **Moon D**, Lee S, Hwang S, Kim K, Ahn C, Park K, Ha T, Song G. Resolution of severe graft steatosis following dual-graft living donor liver transplantation. *Liver Transpl* 2006; **12**: 1156-1160 [PMID: 16799937 DOI: 10.1002/lt.20814]
 - 121 **Wang SH**, Loh PY, Lin TL, Lin LM, Li WF, Lin YH, Lin CC, Chen CL. Active immunization for prevention of De novo hepatitis B virus infection after adult living donor liver transplantation with a hepatitis B core antigen-positive graft. *Liver Transpl* 2017; **23**: 1266-1272 [PMID: 28691231 DOI: 10.1002/lt.24814]
 - 122 **Xi ZF**, Xia Q, Zhang JJ, Chen XS, Han LZ, Zhu JJ, Wang SY, Qiu DK. De novo hepatitis B virus infection from anti-HBc-positive donors in pediatric living donor liver transplantation. *J Dig Dis* 2013; **14**: 439-445 [PMID: 23638710 DOI: 10.1111/1751-2980.12066]
 - 123 **Dong C**, Gao W, Ma N, Sun C, Zheng WP, Wang K, Shen ZY. Risks and treatment strategies for de novo hepatitis B virus infection from anti-HBc-positive donors in pediatric living donor liver transplantation. *Pediatr Transplant* 2017; **21** [PMID: 27933716 DOI: 10.1111/petr.12854]
 - 124 **Loggi E**, Conti F, Cucchetti A, Ercolani G, Pinna AD, Andreone P. Liver grafts from hepatitis B surface antigen-positive donors: A review of the literature. *World J Gastroenterol* 2016; **22**: 8010-8016 [PMID: 27672295 DOI: 10.3748/wjg.v22.i35.8010]
 - 125 **Lei J**, Yan L, Wang W. A comprehensive study of the safety of using anti-hepatitis B core (Hbc) positive subjects in living donor liver transplants. *Hepatogastroenterology* 2013; **60**: 1426-1432 [PMID: 23933935 DOI: 10.5754/hge13062]
 - 126 **Lin CC**, Chen CL, Concejero A, Wang CC, Wang SH, Liu YW, Yang CH, Yong CC, Lin TS, Jawan B, Cheng YF, Eng HL. Active immunization to prevent de novo hepatitis B virus infection in pediatric live donor liver recipients. *Am J Transplant* 2007; **7**: 195-200 [PMID: 17227568 DOI: 10.1111/j.1600-6143.2006.01618.x]
 - 127 **Hara Y**, Tokodai K, Nakanishi C, Miyagi S, Kawagishi N. Spontaneous resolution of de novo hepatitis B after living donor liver transplantation with hepatitis B core antibody positive graft: a case report. *Surg Case Rep* 2016; **2**: 118 [PMID: 27797067 DOI: 10.1186/s40792-016-0246-2]
 - 128 **Sasaki R**, Kanda T, Ohtsuka M, Yasui S, Haga Y, Nakamura M, Yokoyama M, Wu S, Nakamoto S, Arai M, Maruyama H, Miyazaki M, Yokosuka O. Successful Management of Graft Reinfection of HCV Genotype 2 in Living Donor Liver Transplantation from a Hepatitis B Core Antibody-Positive Donor with Sofosbuvir and Ribavirin. *Case Rep Gastroenterol* 2016; **10**: 366-372 [PMID: 27721720 DOI: 10.1159/000447423]
 - 129 **Hwang S**, Lee SG, Park KM, Kim KH, Ahn CS, Oh HB, Moon DB, Ha TY, Lim YS, Jung DH. Five-year follow-up of a hepatitis B virus-positive recipient of hepatitis B surface antigen-positive living donor liver graft. *Liver Transpl* 2006; **12**: 993-997 [PMID: 16721765 DOI: 10.1002/lt.20799]
 - 130 **Soejima Y**, Shimada M, Taketomi A, Yoshizumi T, Uchiyama H, Ikegami T, Nakamuta M, Maehara Y. Successful living donor liver transplantation using a graft from a hepatitis B surface antigen-positive donor. *Liver Int* 2007; **27**: 1282-1286 [PMID: 17919241 DOI: 10.1111/j.1478-3231.2007.01528.x]
 - 131 **Jeng LB**, Thorat A, Yang HR, Yeh CC, Chen TH, Hsu CH, Hsu SC, Poon KS, Li PC, Lai HC, Su WP, Peng CY. Successful use of hepatitis B surface antigen-positive liver grafts - an effective source for donor organs in endemic areas: a single-center experience. *Ann Transplant* 2015; **20**: 103-111 [PMID: 25703063 DOI: 10.12659/AOT.893032]
 - 132 **Tang Z**, Li X, Wu S, Liu Y, Qiao Y, Xu D, Li J. Risk of hepatitis B reactivation in HBsAg-negative/HBcAb-positive patients with undetectable serum HBV DNA after treatment with rituximab for lymphoma: a meta-analysis. *Hepatol Int* 2017; **11**: 429-433 [PMID: 28856548 DOI: 10.1007/s12072-017-9817-y]
 - 133 **Li G**, Mu X, Huang X, Qian X, Qin J, Tan Z, Zhang W, Xu X, Tan S, Zhu Z, Li W, Wang X, Wang X, Sun B. Liver transplantation using the otherwise-discarded partial liver resection graft with hepatic benign tumor: Analysis of a preliminary experience on 15

consecutive cases. *Medicine* (Baltimore) 2017; **96**: e7295 [PMID: 28723742 DOI: 10.1097/MD.00000000000007295]

134 **Fuchino M**, Tajiri K, Minemura M, Sugiyama T. Vanishing

Tumor in a Liver Graft from a Hepatitis B Virus Surface Antigen-Positive Donor. *Case Rep Gastroenterol* 2017; **11**: 610-615 [PMID: 29118691 DOI: 10.1159/000481164]

P- Reviewer: Chiu KW, Kanda T, Qi XS **S- Editor:** Wang XJ
L- Editor: Filipodia **E- Editor:** Huang Y





Published by **Baishideng Publishing Group Inc**
7901 Stoneridge Drive, Suite 501, Pleasanton, CA 94588, USA
Telephone: +1-925-223-8242
Fax: +1-925-223-8243
E-mail: bpgoffice@wjgnet.com
Help Desk: <http://www.f6publishing.com/helpdesk>
<http://www.wjgnet.com>



ISSN 1007-9327

