

Retroileal trans-mesenteric colorectal anastomosis

Pierpaolo Sileri, Ilaria Capuano, Carolina Iliana Ciangola, Luana Franceschilli, Federica Giorgi, Achille Lucio Gaspari

Pierpaolo Sileri, Ilaria Capuano, Carolina Iliana Ciangola, Luana Franceschilli, Federica Giorgi, Achille Lucio Gaspari, Department of Surgical Sciences, University of Rome Tor Vergata, 00133 Rome, Italy

Author contributions: All authors contributed to substantial contributions to conception and design, acquisition of data; Sileri P, Capuano I and Franceschilli L contributed to drafting the article or revising it critically for important intellectual content; Sileri P, Capuano I and Gaspari AL gave final approval of the version to be published.

Correspondence to: Pierpaolo Sileri, MD, MS, PhD, Department of Surgical Sciences, University of Rome Tor Vergata, Cattedra Chirurgia Generale, Policlinico Tor Vergata, 6B, Viale Oxford 81, 00133 Rome, Italy. piersileri@yahoo.com
Telephone: +39-33-39137249 Fax: +39-6-20902927

Received: August 17, 2013 Revised: October 22, 2013

Accepted: November 7, 2013

Published online: November 28, 2013

Abstract

Colorectal anastomosis after extended left colectomies may result difficult, and, sometimes, impossible due to the shortness of the vascular pedicles and the distance between the two ends. Total colectomy with ileo-rectal or ileo-anal anastomosis with sacrifice of healthy colon and ileocaecal valve is usually preferred to overcome this problem. In this manuscript we describe the step-by-step surgical technique of retroileal transmesenteric colorectal anastomosis which can be used as a salvage technique for both open and laparoscopic surgeries. We also discuss the advantages and disadvantages of this approach compared to other techniques. We believe that the widespread of laparoscopic colorectal surgery as well as the raising volume of metachronous colorectal resections will revive this vintage overlooked approach.

© 2013 Baishideng Publishing Group Co., Limited. All rights reserved.

Key words: Colorectal anastomosis; Retroileal anasto-

mosis; Extended left colectomy

Core tip: Several approaches have been proposed as salvage techniques to avoid total colectomy with ileo-rectal or ileo-anal anastomosis after an extensive mobilization and left colon resection. However, as these techniques, which we are going to discuss hereafter, involve various technical difficulties, we present a valid alternative to ileo-rectal or ileo-anal anastomosis: a retro-ileal, trans-mesenteric colorectal anastomosis, first described by R. Turnbull in 1972, which allows a safe and tension free anastomosis after both open and laparoscopic extended left colon resections with inadequate residual length for standard colo-rectal anastomosis.

Sileri P, Capuano I, Ciangola CI, Franceschilli L, Giorgi F, Gaspari AL. Retroileal trans-mesenteric colorectal anastomosis. *World J Surg Proced* 2013; 3(3): 25-28 Available from: URL: <http://www.wjgnet.com/2219-2832/full/v3/i3/25.htm> DOI: <http://dx.doi.org/10.5412/wjsp.v3.i3.25>

INTRODUCTION

After extensive mobilization and left colon resection, the colorectal anastomosis may result impossible due to the distance between the two ends and the shortness of the middle and right colic pedicles. Several approaches have been proposed as salvage techniques to avoid total colectomy with ileo-rectal or ileo-anal anastomosis in these cases. It is well known that low colo-rectal anastomosis may have septic complications as high as 15%, while ileo-rectal anastomosis may have a risk of anastomotic leak between 3%-17%^[1,2]. It is obvious that the aim of surgery should be to preserve the function (*i.e.*, ileo-caecal valve and a portion of the colon) as well as reduce complications (*i.e.*, anastomotic leak or septic complications). In particular, when an ileo-rectal anastomosis is avoided, the terminal ileum and the ileo-caecal valve preservation reduces malabsorption, bacterial overgrowth, while improv-

ing diarrhoea, urgency or incontinence, usually occurring after extended colonic resection. Over the last decades few approaches have been described mainly in the open surgery era.

The Deloyers^[3] procedure, consisting in an anastomosis between the right or the transverse colon and the rectum or anus after mobilizing and rotating into a counter clockwise direction the right colon (including the caecum and the ascending colon, up to the hepatic flexure) with preservation of the ileo-colic junction and the ileocolic artery. After the initial Deloyers' report only 5 studies, including less than 100 patients have shown good functional results mainly after surgery for chronic constipation or Hirschsprung disease^[4-6]. Among these, only one paper considered this approach after Hartmann reversal, failed previous colorectal anastomosis, diverticular disease, left colon cancer and ischemic colitis. This retrospective study observed the largest population (48 patients), reporting early complications up to 23% (mainly intra-abdominal haemorrhage, wound infection, persistent ileus) and 23% of late complications (incisional hernias, colo-anal anastomosis stenosis)^[7].

Subtotal colectomy with caeco-rectal end-to-end anastomosis, when the right colon can not be preserved. This technique seems, however, to be comparable to the total colectomy with ileo-rectal anastomosis technique in terms of therapeutic effectiveness, postoperative morbidity and mortality and impact on the quality of life^[8].

Moreover, these two approaches may present several technical difficulties when a laparoscopic approach is needed. Obviously, the widespread of laparoscopic colorectal surgery demands for faster and easier techniques.

In 1972, Turnbull proposed a retro-ileal tunnel to anastomose the proximal transverse colon to the rectum. This technique consists in performing a passage through an avascular plane at the terminal ileum mesentery and the proximal transverse colon, anastomosed to the rectum. However, this old technique has been largely overlooked for decades, although it represents a valid alternative to ileo-rectal or ileo-anal anastomosis, allowing a safe and tension free anastomosis. Since it is very easy to perform, we believe that this is the technical solution for both open and laparoscopic extended left colon resections with inadequate residual length for standard colo-rectal anastomosis.

In the manuscript we present the surgical technique with a series of figures suitable either for open or laparoscopic approach.

SURGICAL TECHNIQUE DESCRIPTION

Ileal mesentery window creation

After extended left colectomy, the remnant colon is vascularized only by the tributaries of the superior mesenteric artery. The entire small intestine is retracted on the left side of the patient and cranially, in order to expose the root of the mesentery. At this point, the terminal

ileum is identified for a segment of 30-50 cm and the mesentery is inspected for the vascular arcades. This allows the respect of the terminal ileum and caecum vascularization when the window is created and tailored for the transverse colon passage. Usually, a 3 cm opening is necessary (Figure 1A). While in open surgery a trans-mesenteric lighting, in order to individualize the avascular plane, is possible, during laparoscopic surgery this is not doable, since the light is in the same direction of the scope. However, the window can be created immediately proximal to the take-off of the ileo-colic vessel, where an avascular plane is usually present.

Freeing the transverse colon

It is necessary to free the transverse colon from its attachments, particularly from the gastro-colic ligament as well as all the folds that may create tension thus creating tension through the mesenteric passage. The distance that needs to be covered can be measured above the mesentery. If a laparoscopic approach is used and a mechanical anastomosis is planned, the anvil is inserted after a standard purse-string is performed. After the colon has been passed through the avascular mesenteric window (Figure 1B), the anastomosis is performed. If an open technique is chosen an end-to-end or side-to-end anastomosis is performed. At this point the anvil is gently passed through the mesentery and the anastomosis performed to the rectal stump. Once these two elements have been connected, an anastomosis is performed and checked, to ensure that there is no tension or twisting (Figure 1C). Finally, the colon is fixed to the border of the mesenteric passage using interrupted absorbable 2-0 stitches and the posterior mesenteric window (or residual gap) is closed with interrupted stitches to avoid internal hernias.

Our experience

Since 2007 we have performed this procedure in 10 patients. All patients were male with a mean age of 65.1 years (range: 41-82 years). Indications for surgery were: left colon cancer ($n = 2$), left colon cancer associated with diverticular disease ($n = 2$), metachronous left colorectal cancer in previously resected patients ($n = 2$), synchronous cancer of the recto-sigmoid colon and the splenic flexure ($n = 2$), extensive diverticular disease ($n = 2$). Of these surgeries, 8 were open while 2 were laparoscopic. Median follow up was 40 mo. One patient had superficial Surgical Site Infection. One patient developed an incisional hernia on the site of 15 mm trocar insertion, repaired 6 mo after surgery. Three patients experienced longer term diarrhoea, and 2 of them required occasional Loperamide treatment. One patient died 2 mo after surgery due to sequelae of his Chronic Renal Failure. He had a previous failed renal transplant, secondary to acute rejection. Two patients died due to cancer recurrence, 2 and 4 years after surgery, respectively. No complications related to the surgical procedures were encountered, including anastomotic leaks, stenosis or small bowel obstruction secondary to internal hernia or adhesions.

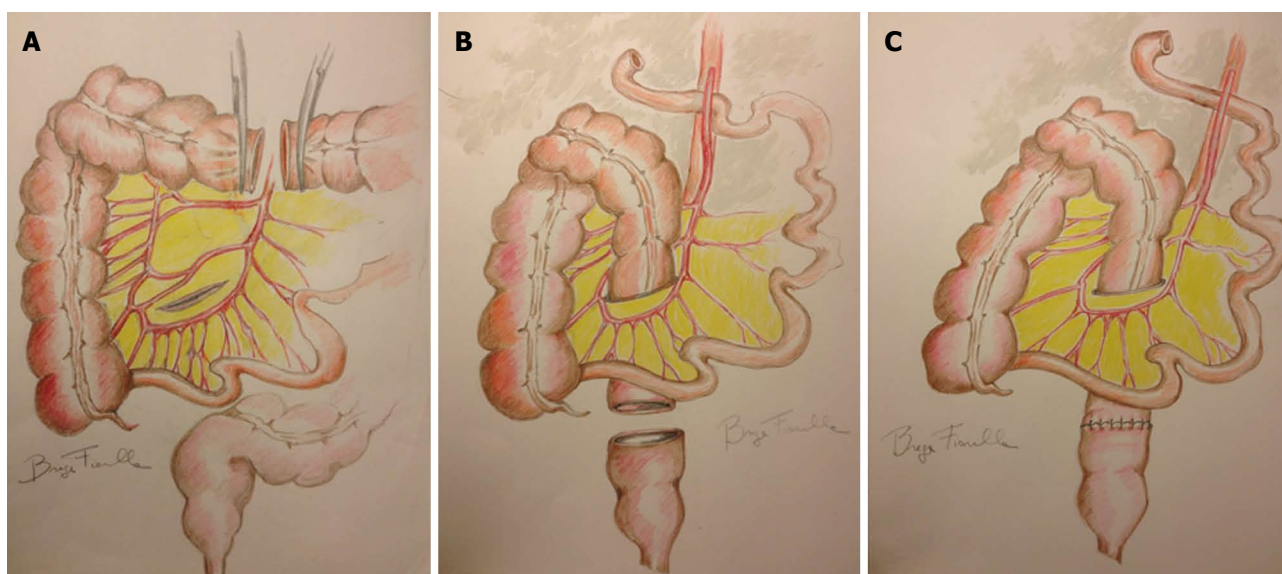


Figure 1 Ileal mesentery surgical technique description. A: After the proximal resection, an avascular mesenteric window is created; B: After an extended left colectomy has been performed, the remnant colon is passed through the avascular mesenteric window, behind the ileum; C: An end-to-end, trans-mesenteric, retroileal colo-rectal anastomosis is performed.

DISCUSSION

We believe that this “vintage” technique has been overlooked for decades and it may turn to be fashion again after the widespread of colorectal laparoscopy. Major drawbacks such as the need of proximal transverse colon taking down and risk of internal hernia through the mesenteric window or jejunum loop obstruction favoured the Deloyers procedure. However, literature on trans-mesenteric lowering is scant^[9-11]. The first Turnbull’s report presented 11 retroileal colo-rectal anastomosis with a total of 3 minor postoperative complications, including partial small bowel obstructions resolved medically, 1 small incisional hernia and minor wound infection. For more than 20 years the technique was not presented and reappeared in the literature in 1994 when Nafe *et al*^[10] reported a series of 28 cases with a single case of anastomotic leak (about 3%) comparable to conventional anastomosis. Overall, including sporadic case reports, a handful of reports are present in literature with a lack of surgical indications, specific surgical technique description as well as outcomes.

Supporters of the Deloyers procedure aimed that the retro-ileal anastomosis requires the preservation of the entire transverse colon. Obviously, the ligation of the left branch of the middle colic pedicle is often sufficient, but, if a more extended resection is required with a proximal transverse colon anastomosis, the middle colic pedicle ligation is possible at the origin but, in this case, the sole Drummond’s arcade will supply the right transverse colon. Regarding the risk of jejunum loop obstruction or the risk of internal hernia through the mesenteric window, it should be minimized by narrowing the mesenteric window and performing mesenteric-to-bowel sutures^[9]. Moreover, according to our experience, since the peritoneal window is performed 20-30 cm from the ileo-cecal

valve, proximal to the marginal arcade, this does not represent a limit, when a loop diverting ileostomy is needed.

On the other hand, the Deloyers procedure has the main disadvantage of creating torsion of the vascular pedicle increasing the risk of venous ischemia, despite few modifications have been proposed^[12-14].

Moreover, when a laparoscopic approach is chosen, the retroileal passage seems to be a valid option to overcome the distance between the two ends and to perform a safe, tension-free anastomosis. It is intuitive that a distance between the proximal transverse colon and the rectal stump is less when the intestine crosses the mesenteric route on the right side, through the peritoneal window. In fact, anatomically, the small bowel mesentery from its origin goes mainly from the middle to the left side, leaving the right part to the right colon mesentery. The passage of the colon above the small bowel may result impossible and may jeopardize the vascularization, creating tension. However, the retroileal window may result more difficult in laparoscopic surgery, especially in obese patients, thus a more careful identification of the ileo-colic vessels should be performed. In conclusion, we do believe that this technique can be always used, when an extended left colon resection is required.

REFERENCES

- 1 **Chambers WM**, Mortensen NJ. Postoperative leakage and abscess formation after colorectal surgery. *Best Pract Res Clin Gastroenterol* 2004; **18**: 865-880 [PMID: 15494283]
- 2 **Tang ST**, Yang Y, Wang GB, Tong QS, Mao YZ, Wang Y, Li SW, Ruan QL. Laparoscopic extensive colectomy with transanal Soave pull-through for intestinal neuronal dysplasia in 17 children. *World J Pediatr* 2010; **6**: 50-54 [PMID: 20143211 DOI: 10.1007/s12519-010-0006-5]
- 3 **Deloyers L**. [Suspension of the right colon permits without exception preservation of the anal sphincter after extensive

- colectomy of the transverse and left colon (including rectum). Technic -indications- immediate and late results]. *Lyon Chir* 1964; **60**: 404-413 [PMID: 14167748]
- 4 **Prévot J.** [Hirschsprung's disease: Deloyers' technic]. *Ann Chir Infant* 1970; **11**: 81-84 [PMID: 5526530]
- 5 **Costalat G,** Garrigues JM, Didelot JM, Yousfi A, Boccasanta P. [Subtotal colectomy with ceco-rectal anastomosis (Deloyers) for severe idiopathic constipation: an alternative to total colectomy reducing risks of digestive sequelae]. *Ann Chir* 1997; **51**: 248-255 [PMID: 9297887]
- 6 **Bonnard A,** de Lagausie P, Leclair MD, Marwan K, Languepin J, Bruneau B, Berribi D, Aigrain Y. Definitive treatment of extended Hirschsprung's disease or total colonic form. *Surg Endosc* 2001; **15**: 1301-1304 [PMID: 11727138 DOI: 10.1007/s004640090092]
- 7 **Manceau G,** Karoui M, Breton S, Blanchet AS, Rousseau G, Savier E, Siksik JM, Vaillant JC, Hannoun L. Right colon to rectal anastomosis (Deloyers procedure) as a salvage technique for low colorectal or coloanal anastomosis: postoperative and long-term outcomes. *Dis Colon Rectum* 2012; **55**: 363-368 [PMID: 22469806 DOI: 10.1097/DCR.0b013e3182423f83]
- 8 **Marchesi F,** Sarli L, Percalli L, Sansebastiano GE, Veronesi L, Di Mauro D, Porrini C, Ferro M, Roncoroni L. Subtotal colectomy with antiperistaltic cecorectal anastomosis in the treatment of slow-transit constipation: long-term impact on quality of life. *World J Surg* 2007; **31**: 1658-1664 [PMID: 17541684 DOI: 10.1007/s00268-007-9111-6]
- 9 **Rombeau JL,** Collins JP, Turnbull RB. Left-sided colectomy with retroileal colorectal anastomosis. *Arch Surg* 1978; **113**: 1004-1005 [PMID: 687079 DOI: 10.1001/archsurg.1978.01370200098020]
- 10 **Nafe M,** Athanasiadis S, Köhler A. [Indications and technique of retro-ileal colorectal anastomosis after expanded left-sided hemicolectomy]. *Chirurg* 1994; **65**: 804-806 [PMID: 7995091]
- 11 **Hogan NM,** Joyce MR. Retroileal colorectal anastomosis: an old technique, still relevant. *Tech Coloproctol* 2012; Epub ahead of print [PMID: 22398845 DOI: 10.1007/s10151-012-0814-9]
- 12 **Roncoroni L,** Sarli L, Costi R, Violi V. [Caecal-rectal antiperistaltic anastomosis without torsion of the vascular pedicle]. *Ann Chir* 2000; **125**: 871-873 [PMID: 11244595 DOI: 10.1016/S0003-3944(00)00010-9]
- 13 **Perrier G,** Peillon C, Testart J. [Modifications of the Deloyers procedure in order to perform a cecal-rectal anastomosis without torsion of the vascular pedicle]. *Ann Chir* 1999; **53**: 254 [PMID: 10339871]
- 14 **Zinzindohoué F.** [Difficult colo-colonic or colo-rectal anastomoses: trans-mesenteric anastomoses and anastomoses with right colonic inversion]. *Ann Chir* 1998; **52**: 571-573 [PMID: 9752509]

P- Reviewers: Cho A, Kin T, Lin JK, Piccinni G

S- Editor: Song XX **L- Editor:** A **E- Editor:** Zhang DN





百世登
Baishideng®

Published by **Baishideng Publishing Group Co., Limited**

Flat C, 23/F., Lucky Plaza, 315-321 Lockhart Road,

Wan Chai, Hong Kong, China

Fax: +852-65557188

Telephone: +852-31779906

E-mail: bpgoffice@wjgnet.com

<http://www.wjgnet.com>

