



Pathological diagnosis and immunohistochemical analysis of giant retrosternal goiter in the elderly: A case report

Yong-Chang Meng, Liu-Sheng Wu, Ning Li, Hong-Wei Li, Jing Zhao, Jun Yan, Xiao-Qiang Li, Peng Li, Jiang-Qi Wei

Specialty type: Medicine, general and internal

Provenance and peer review: Unsolicited article; Externally peer reviewed.

Peer-review model: Single blind

Peer-review report's scientific quality classification

Grade A (Excellent): 0
Grade B (Very good): B
Grade C (Good): C
Grade D (Fair): 0
Grade E (Poor): 0

P-Reviewer: Hasan A, Egypt

Received: November 9, 2023

Peer-review started: November 9, 2023

First decision: November 22, 2023

Revised: November 22, 2023

Accepted: January 3, 2024

Article in press: January 3, 2024

Published online: January 26, 2024



Yong-Chang Meng, Hong-Wei Li, Jiang-Qi Wei, Department of Cardiothoracic Surgery, Xinxiang First People's Hospital, Xinxiang 453000, Henan Province, China

Liu-Sheng Wu, Jun Yan, School of Clinical Medicine, Tsinghua University, Beijing 100084, China

Ning Li, Graduate School, Qinghai University, Xining 810016, Qinghai Province, China

Jing Zhao, Department of Pathology, Xinxiang First People's Hospital, Xinxiang 453000, Henan Province, China

Xiao-Qiang Li, Peng Li, Department of Thoracic Surgery, Peking University Shenzhen Hospital, Shenzhen 518036, Guangdong Province, China

Corresponding author: Jiang-Qi Wei, PhD, Doctor, Department of Cardiothoracic Surgery, Xinxiang First People's Hospital, No. 63 Yiheng Street, Weibin District, Xinxiang 453000, Henan Province, China. 2733514758@qq.com

Abstract

BACKGROUND

Elderly giant retrosternal thyroid goiter is a rare yet significant medical condition, often presenting clinical symptoms that can be confused with other diseases, posing diagnostic and therapeutic challenges. This study aims to delve into the characteristics and potential mechanisms of this ailment through pathological diagnosis and immunohistochemical analysis, providing clinicians with more precise diagnostic and treatment strategies.

CASE SUMMARY

A 77-year-old male, was admitted to hospital with the chief complaint of finding a goiter in the semilunar month during physical examination, accompanied by dyspnea. Locally protruding into the superior mediastinum, the adjacent structure was compressed, the trachea was compressed to the right, and the local lumen was slightly narrowed. The patient was diagnosed with giant retrosternal goiter. Considering dyspnea caused by trachea compression, our department planned to perform giant retrosternal thyroidectomy. Immunohistochemical results: Tg (+), TTF-1 (+), Calcitonin (CT) (I), Ki-67 (+, about 20%), CD34 (-). Retrosternal goiter means that more than 50% of the volume of the thyroid gland is below the upper margin of the sternum. As retrosternal goiter disease is a relatively rare disease,

once the disease is diagnosed, it should be timely surgical treatment, and the treatment is more difficult, the need for professional medical team for comprehensive treatment.

CONCLUSION

The imaging manifestations of giant retrosternal goiter are atypical, histomorphology and immunohistochemistry can assist in its diagnosis. This article reviews the relevant literature of giant retrosternal goiter immunohistochemistry and shows that giant retrosternal goiter is positive for Tg, TTF-1, and Ki-67.

Key Words: Giant retrosternal goiter; Pathology; Immunohistochemistry; Case report

©The Author(s) 2024. Published by Baishideng Publishing Group Inc. All rights reserved.

Core Tip: Elderly giant retrosternal thyroid goiter is a rare yet significant medical condition, often presenting clinical symptoms that can be confused with other diseases, posing diagnostic and therapeutic challenges. The diagnosis of elderly giant retrosternal thyroid goiter is difficult and often results in unnecessary or inappropriate treatment. Therefore, it is particularly important to correctly identify and diagnose the disease, and this article reports a 77-year-old male patient with giant retrosternal goiter.

Citation: Meng YC, Wu LS, Li N, Li HW, Zhao J, Yan J, Li XQ, Li P, Wei JQ. Pathological diagnosis and immunohistochemical analysis of giant retrosternal goiter in the elderly: A case report. *World J Clin Cases* 2024; 12(3): 643-649

URL: <https://www.wjgnet.com/2307-8960/full/v12/i3/643.htm>

DOI: <https://dx.doi.org/10.12998/wjcc.v12.i3.643>

INTRODUCTION

Elderly giant retrosternal thyroid goiter is an extremely rare and challenging thyroid disorder[1]. Its rarity lies in the fact that it typically afflicts elderly patients, with a relatively low incidence rate. Due to its often nonspecific symptoms such as difficulty breathing, swallowing, and the presence of a neck mass, it can easily be misdiagnosed as other conditions like cardiovascular diseases or esophageal cancer, posing significant clinical challenges[2-4]. The significance of this case report lies in providing the medical community with a detailed clinical case and pathological analysis of elderly giant retrosternal thyroid goiter, along with immunohistochemical research data[5]. Furthermore, this study contributes to improving the diagnosis and treatment methods for this condition, offering more accurate and personalized medical care [6-8].

We report this case with the aim of disseminating new information about elderly giant retrosternal thyroid goiter to the medical community, enhancing awareness of the disease, and providing valuable data for future research and treatment. By sharing this case, we hope to foster further investigation into this rare disorder and better support patients in terms of diagnosis and management.

CASE PRESENTATION

Chief complaints

Finding a goiter in the semilunar month during physical examination.

History of present illness

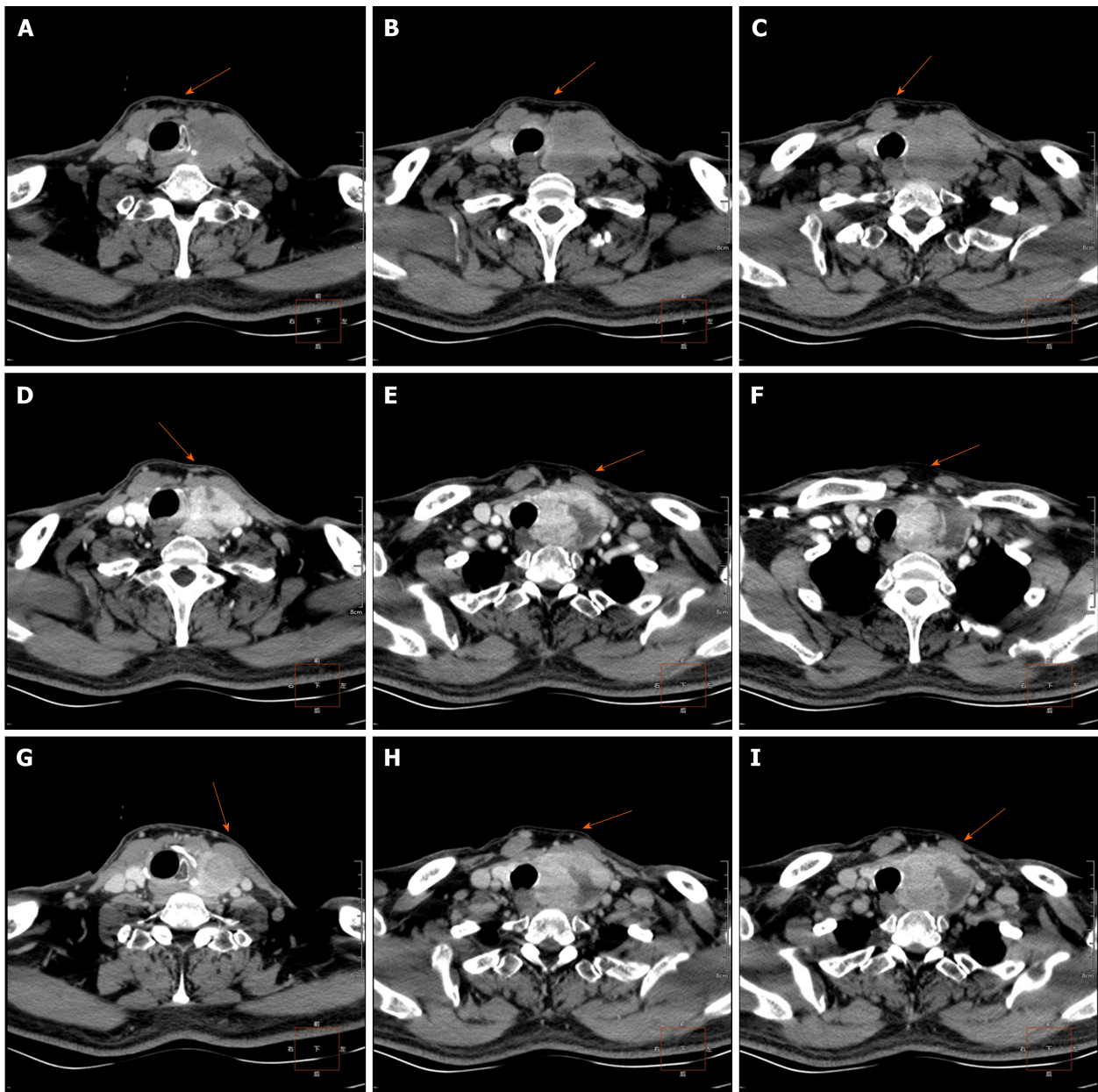
A 77-year-old male patient was admitted to hospital after a physical examination revealed a goiter. No other special clinical symptoms and signs. Before admission, chest enhanced computed tomography (CT) scan showed that the left lobe of the thyroid gland was enlarged and slightly low-density mass was seen, about 49 mm × 43 mm × 68 mm in size, the boundary was not clear, its internal density was uneven, the enhanced scan was significantly uneven and enhanced, local protrusion into the upper mediastinum, compression of adjacent structures, rightward compression of the trachea, and local lumen was slightly narrowed.

History of past illness

A history of hypertension, regular oral antihypertensive medication treatment, and well-controlled blood pressure.

Personal and family history

Nothing special.



DOI: 10.12998/wjcc.v12.i3.643 Copyright ©The Author(s) 2024.

Figure 1 Computed tomography examination before surgery. A-C: Preoperative computed tomography (CT) scan; D-F: Preoperative enhanced CT (arterial phase); G-I: Preoperative enhanced CT (venous phase).

Physical examination

Nothing special.

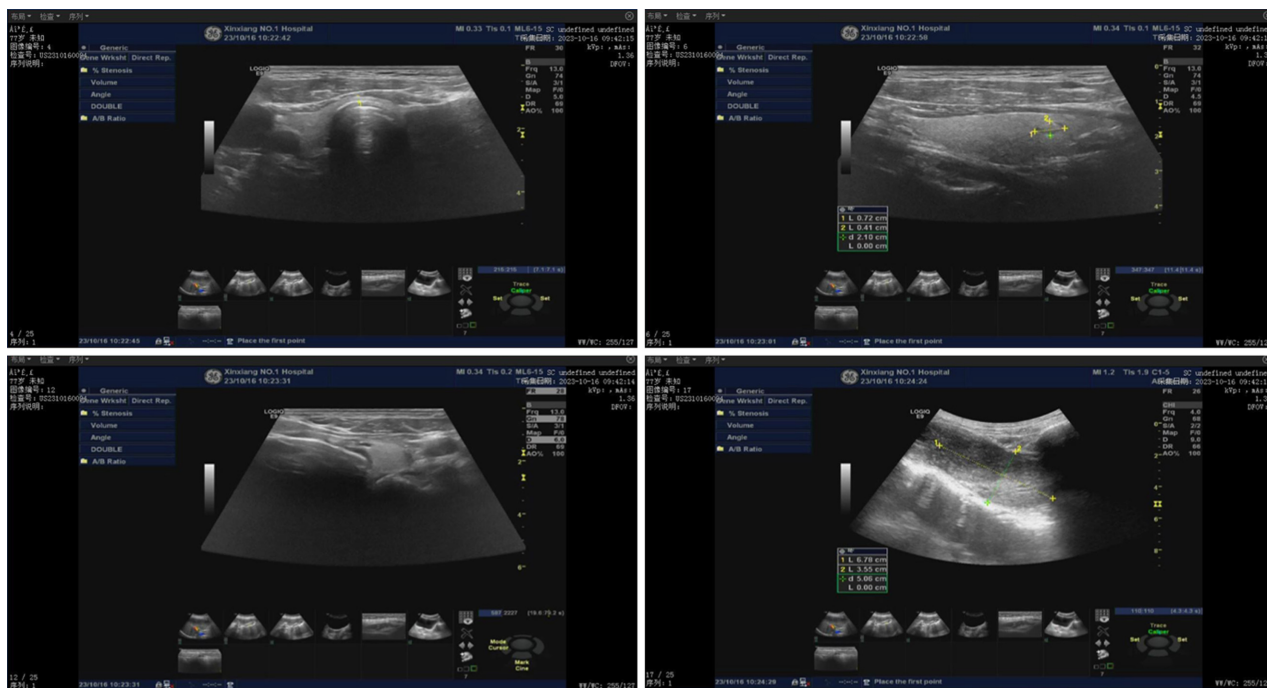
Laboratory examinations

Combined with subimmunohistochemical findings, consistent with follicular thyroid cancer (Left goiter ice stone). Immunohistochemical results: Tg (+), TTF-1 (+), Calcitonin (CT) (I), Ki-67 (+, about 20%), CD34 (-).

Imaging examinations

Thyroid plain CT scan plus enhanced imaging showed that the volume of the left lobe of the thyroid increased and slightly low-density mass was seen, the size was about 49mm×43mm×68mm, the boundary was not clear, the internal density was not uniform, and the enhanced scan was obviously uneven and enhanced, local protrusion into the upper mediastinum, compression of adjacent structures, rightward compression of the trachea, and local lumen was slightly narrowed. The size, shape and density of the right lobe of the thyroid gland were normal. There was no obvious lymph node shadow in the neck (Figure 1).

Real-time ultrasound examination of thyroid and elastic imaging showed that the right lobe of thyroid gland was 1.7 cm × 1.4 cm, the left lobe was 5.2 cm × 3.3 cm, and the isthmus was 0.2 cm thick. The thyroid gland tissue echo was uniform, and a solid cystic nodule was found in the right lobe of thyroid gland with a size of 0.7 cm × 0.4 cm, clear



DOI: 10.12998/wjcc.v12.i3.643 Copyright ©The Author(s) 2024.

Figure 2 Thyroid and elastic real-time imaging ultrasound.

boundary and regular shape. CDFI: Visible peripheral blood flow signal, and elasticity score: Multiple solid cystic nodules were observed in the left lobe of the thyroid gland, mainly solid components, with a size of 6.8 cm × 3.6 cm, clear boundary, regular shape, and peripheral blood flow signals (Figure 2).

FINAL DIAGNOSIS

The pathological diagnosis was micro-invasive follicular thyroid cancer (Figures 3 and 4).

TREATMENT

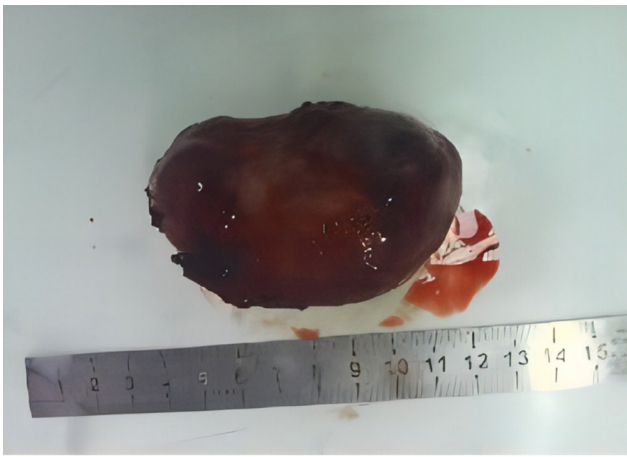
We recommend that patients continue to receive treatment after surgery and to do regular follow-up observations.

OUTCOME AND FOLLOW-UP

The patient recovered after operation, and no recurrence was found after 6 mo.

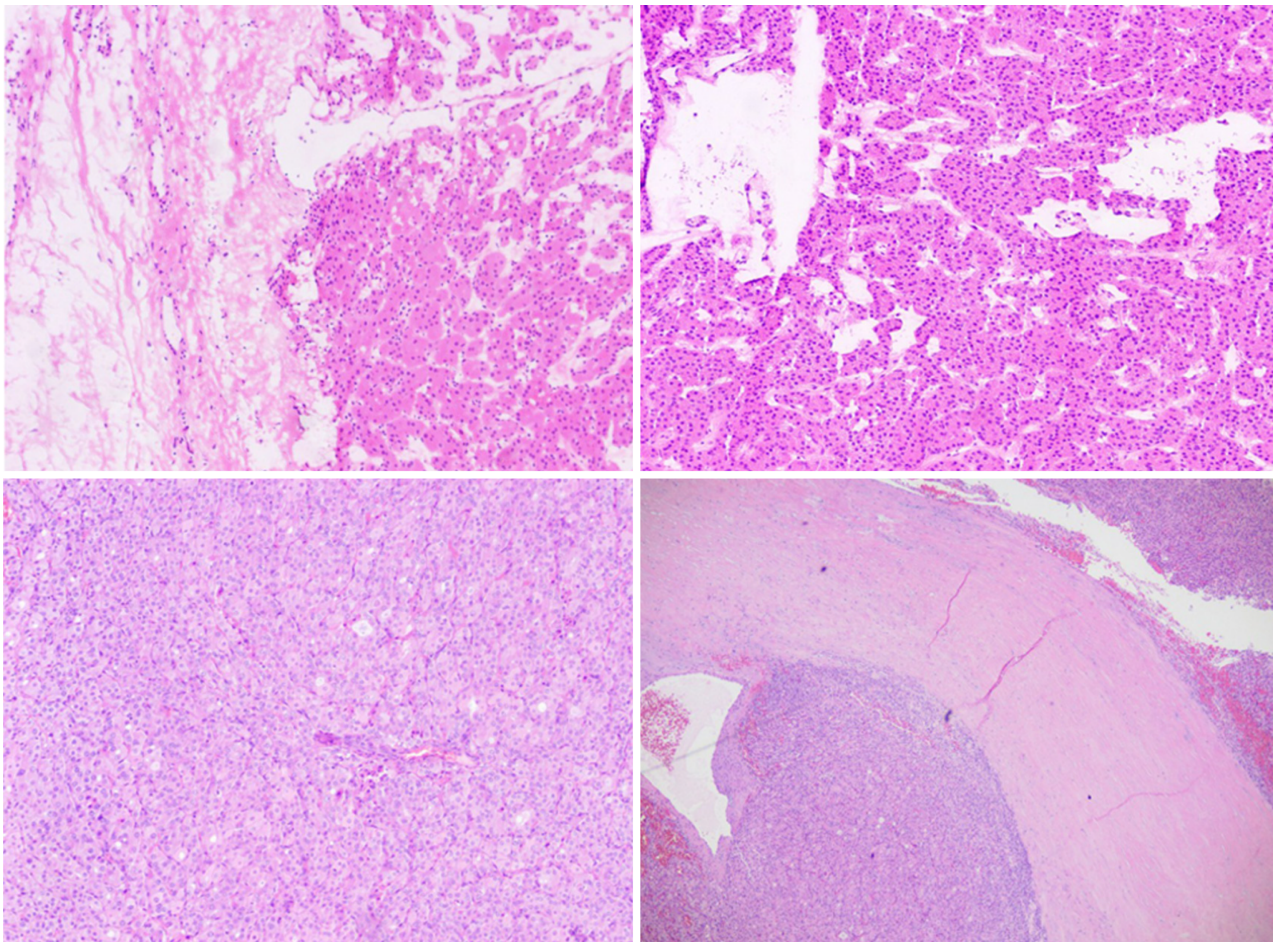
DISCUSSION

In this project, we studied a large retrosternal goiter in an elderly patient. Giant retrosternal goiter is a specific type of thyroid tumor characterized by the growth of a goiter to the back of the sternum[9-11]. According to the nature and growth rate of the tumor, it can be divided into two types: benign and malignant[12]. Benign giant retrosternal goiter usually grows slowly, but because of its location, it can cause difficulty breathing and swallowing, with a noticeable impact on the patient's quality of life[13]. Malignant giant retrosternal goiter is potentially malignant and requires a more aggressive treatment strategy. The clinical manifestations of giant retrosternal goiter in the elderly usually include dyspnea, dysphagia, hoarseness, and neck mass[14]. These symptoms are similar to other diseases and can easily lead to misdiagnosis or delayed diagnosis. Therefore, clinicians facing these symptoms in patients should be on high alert for the possibility of giant retrosternal goiter and conduct detailed physical examination and imaging evaluation to confirm the diagnosis and develop appropriate treatment[15-17]. The relatively low incidence of giant retrosternal goiter in old age makes the disease even rarer. Due to its rarity, the medical community has limited knowledge and awareness of the disease, which is easily overlooked or misdiagnosed[18]. However, it is precisely because of its potentially serious harm that we believe it is necessary to conduct in-depth research on this rare disease in order to improve diagnostic accuracy.



DOI: 10.12998/wjcc.v12.i3.643 Copyright ©The Author(s) 2024.

Figure 3 Photos were taken of the size of the left thyroid gland tumor after operation.



DOI: 10.12998/wjcc.v12.i3.643 Copyright ©The Author(s) 2024.

Figure 4 Results of HE staining of the left thyroid gland mass after surgery.

and treatment effectiveness[19]. For the treatment of giant retrosternal goiter in the elderly, surgical resection is usually the preferred method. The outcome of surgery depends largely on the nature of the tumor, preoperative preparation, and the overall health of the patient. For benign giant retrosternal goiter, surgery usually results in a significant improvement in the patient's symptoms and has a good long-term prognosis[20]. However, for malignant lesions, further treatment may be required after surgery, such as radiation therapy or chemoradiotherapy, and the prognosis is relatively poor.

The imaging features of giant retrosternal goiter are one of the important diagnostic bases for this disease. Typically, a CT or magnetic resonance imaging examination of the patient's neck will reveal the following features: A large retrosternal goiter is located behind the sternum and usually presents as a uniform mass that takes up space in the upper

rib cage and part of the neck[21]. The immunohistochemical features of thyroid follicular carcinoma include thyroid specific markers such as thyroglobulin and thyroid peroxidase, CK19, HMGA2, PAX8, Tg, TTF-1, Ki-67, *etc.* These markers are often significantly expressed in follicular carcinoma and help in diagnosis, treatment selection and prognosis assessment. Immunohistochemical analysis is very important for the diagnosis and treatment of follicular cancer and provides strong support and guidance. In terms of clinical manifestations, the symptoms of giant retrosternal goiter in the elderly can be diverse, including poor breathing, swallowing discomfort, sore throat, throat swelling, hoarseness and so on[22]. Patients often see a doctor for these symptoms, but because they are not specific, they are easily confused with other neck or chest diseases.

Therefore, a comprehensive consideration of clinical and radiological features is essential for correct diagnosis and treatment planning. For such patients, comprehensive clinical evaluation should be actively conducted to ensure early detection and treatment of giant retrosternal goiter in the elderly, thereby improving the quality of life and prognosis of patients.

CONCLUSION

Through comprehensive pathological diagnosis and immunohistochemical analysis of a giant retrosternal mass in an elderly patient, we discussed the characteristics of this rare disease. The results showed that the immunohistochemical markers of micro-invasive follicular thyroid cancer had a certain diversity. Among them, CK19, HMGA2, PAX8, Tg, TTF-1 and Ki-67 play a crucial role in pathological diagnosis.

FOOTNOTES

Co-first authors: Yong-Chang Meng, Liu-Sheng Wu and Ning Li.

Co-corresponding authors: Jiang-Qi Wei and Jun Yan.

Author contributions: Meng YC and Wu LS analyzed the data and wrote the paper; Li XQ and Wei JQ designed the research; Yan J and Li P guided the research; Zhao J, Li HW and Li N collected and downloaded the data of our research; All the authors revised it critically for important intellectual content, gave final approval of the version to be published and agreed to be accountable for all aspects of the work. The reasons for designating Wei JQ and Yan J as co-corresponding authors are threefold. First, the research was performed as a collaborative effort, and the designation of co-corresponding authorship accurately reflects the distribution of responsibilities and burdens associated with the time and effort required to complete the study and the resultant paper. This also ensures effective communication and management of post-submission matters, ultimately enhancing the paper's quality and reliability. Second, the overall research team encompassed authors with a variety of expertise and skills from different fields, and the designation of co-corresponding authors best reflects this diversity. This also promotes the most comprehensive and in-depth examination of the research topic, ultimately enriching readers' understanding by offering various expert perspectives. Third, Wei JQ and Yan J contributed efforts of equal substance throughout the research process. The choice of these researchers as co-corresponding authors acknowledges and respects this equal contribution, while recognizing the spirit of teamwork and collaboration of this study. In summary, we believe that designating Wei JQ and Yan J as co-corresponding authors of is fitting for our manuscript as it accurately reflects our team's collaborative spirit, equal contributions, and diversity.

Supported by the Scientific Research Foundation of Peking University Shenzhen Hospital, No. KYQD202100X; the National Natural Science Foundation of China, No. 81972829; and Precision Medicine Research Program of Tsinghua University, No. 2022ZLA006.

Informed consent statement: Informed written consent was obtained from the patient for publication of this report and any accompanying images.

Conflict-of-interest statement: All the authors declare no conflicts of interest.

CARE Checklist (2016) statement: The authors have read the CARE Checklist (2016), and the manuscript was prepared and revised according to the CARE Checklist (2016).

Open-Access: This article is an open-access article that was selected by an in-house editor and fully peer-reviewed by external reviewers. It is distributed in accordance with the Creative Commons Attribution NonCommercial (CC BY-NC 4.0) license, which permits others to distribute, remix, adapt, build upon this work non-commercially, and license their derivative works on different terms, provided the original work is properly cited and the use is non-commercial. See: <https://creativecommons.org/licenses/by-nc/4.0/>

Country/Territory of origin: China

ORCID number: Liu-Sheng Wu 0000-0001-9580-2257; Jiang-Qi Wei 0000-1214-0025-1455.

S-Editor: Yan JP

L-Editor: A

P-Editor: Zhang YL

REFERENCES

- 1 Nakamura R, Okuda K, Chiba K, Matsui T, Oda R, Tatematsu T, Yokota K, Nakanishi R. A large intrathoracic goiter with tracheal stenosis: Complete resection using a robot-assisted thoracoscopic approach. *Thorac Cancer* 2022; **13**: 1874-1877 [PMID: 35567330 DOI: 10.1111/1759-7714.14470]
- 2 Pan Y, Chen C, Yu L, Zhu S, Zheng Y. Airway Management of Retrosternal Goiters in 22 Cases in a Tertiary Referral Center. *Ther Clin Risk Manag* 2020; **16**: 1267-1273 [PMID: 33376336 DOI: 10.2147/TCRM.S281709]
- 3 Cankar Dal H. Difficult airway management and emergency tracheostomy in a patient with giant goiter presenting with respiratory arrest: A case report. *Exp Ther Med* 2022; **24**: 499 [PMID: 35837072 DOI: 10.3892/etm.2022.11426]
- 4 Figueiredo AA, Simões-Pereira J. Giant retrosternal goitre causing lung atelectasis. *Endokrynol Pol* 2022; **73**: 794-795 [PMID: 36059170 DOI: 10.5603/EP.a2022.0043]
- 5 Sun X, Chen C, Zhou R, Chen G, Jiang C, Zhu T. Anesthesia and airway management in a patient with acromegaly and tracheal compression caused by a giant retrosternal goiter: a case report. *J Int Med Res* 2021; **49**: 300060521999541 [PMID: 33878943 DOI: 10.1177/0300060521999541]
- 6 D'hulst L, Deroose C, Strybol D, Coolen J, Gheysens O. 18F-FDG PET/CT and MRI of a Mediastinal Malignant Granular Cell Tumor With Associated Recurrent Pericarditis. *Clin Nucl Med* 2018; **43**: 589-590 [PMID: 29847320 DOI: 10.1097/RLU.0000000000002137]
- 7 Khalid MA, Iqbal J, Memon HL, Hanif FM, Butt MOT, Luck NH, Majid Z. Dyspepsia Amongst End Stage Renal Disease Undergoing Hemodialysis: Views from a Large Tertiary Care Center. *J Transl Int Med* 2018; **6**: 78-81 [PMID: 29984202 DOI: 10.2478/jtim-2018-0013]
- 8 Lampridis S, Lau MC, Mhandu P, Parissis H. Concomitant off-pump coronary artery bypass grafting and total thyroidectomy for a large retrosternal goitre: a case report and review of the literature. *J Thorac Dis* 2016; **8**: E362-E368 [PMID: 27162701 DOI: 10.21037/jtd.2016.03.33]
- 9 Zuo T, Gao Z, Chen Z, Wen B, Chen B, Zhang Z. Surgical Management of 48 Patients with Retrosternal Goiter and Tracheal Stenosis: A Retrospective Clinical Study from a Single Surgical Center. *Med Sci Monit* 2022; **28**: e936637 [PMID: 35949114 DOI: 10.12659/MSM.936637]
- 10 Battistella E, Pomba L, Sidoti G, Vignotto C, Toniato A. Retrosternal Goitre: Anatomical Aspects and Technical Notes. *Medicina (Kaunas)* 2022; **58** [PMID: 35334525 DOI: 10.3390/medicina58030349]
- 11 Wu B, Xie X, Li X, Zhu Q, Zhou C. Large intramural hematoma of the esophagus after endoscopic injection sclerotherapy: A case report. *Medicine (Baltimore)* 2023; **102**: e32752 [PMID: 36705374 DOI: 10.1097/MD.00000000000032752]
- 12 Chen Q, Su A, Zou X, Liu F, Gong R, Zhu J, Li Z, Wei T. Clinicopathologic Characteristics and Outcomes of Massive Multinodular Goiter: A Retrospective Cohort Study. *Front Endocrinol (Lausanne)* 2022; **13**: 850235 [PMID: 35685217 DOI: 10.3389/fendo.2022.850235]
- 13 Simões AB, D'Avila LH, Silva CK, Valentini DF Jr. A very rare case of an intrathoracic pancreatic pseudocyst. *Rev Esp Enferm Dig* 2023 [PMID: 37539529 DOI: 10.17235/reed.2023.9819/2023]
- 14 Nesti C, Wohlfarth B, Borbély YM, Kaderli RM. Case Report: Modified Thoracoscopic-Assisted Cervical Resection for Retrosternal Goiter. *Front Surg* 2021; **8**: 695963 [PMID: 34179070 DOI: 10.3389/fsurg.2021.695963]
- 15 Moore E, Merali N, Abbassi-Ghadi N. Herpes simplex oesophagitis leading to perforation and mediastinal collection: a case report and review of literature. *Ann R Coll Surg Engl* 2023; **105**: 94-96 [PMID: 35639460 DOI: 10.1308/rcsann.2022.0044]
- 16 Palani P, Lokeshwaran S, Sunil Kumar K, Girish G, Vidya MN, Gupta N. A 33-Year-Old Woman With Breathing Difficulty, Inspiratory Wheeze, and Hemoptysis. *Chest* 2023; **163**: e141-e145 [PMID: 36894271 DOI: 10.1016/j.chest.2022.08.2220]
- 17 Cantinotti M, Giordano R, Marchese P, Franchi E, Viacava C, Pak V, Murzi B, Arcieri L, Poli V, Federici D, Koestenberger M, Assanta N. Retrosternal Clots After Fontan Surgery by Systematic Evaluation With Transthoracic Ultrasound. *J Cardiothorac Vasc Anesth* 2020; **34**: 951-955 [PMID: 31812566 DOI: 10.1053/j.jvca.2019.11.009]
- 18 Chen YH, Lin PC, Chen YL, Yiang GT, Wu MY. Point-of-Care Ultrasonography Helped to Rapidly Detect Pneumomediastinum in a Vomiting Female. *Medicina (Kaunas)* 2023; **59** [PMID: 36837595 DOI: 10.3390/medicina59020394]
- 19 Bernaldo-de-Quirós E, Cózar B, López-Esteban R, Clemente M, Gil-Jaurena JM, Pardo C, Pita A, Pérez-Caballero R, Camino M, Gil N, Fernández-Santos ME, Suarez S, Pion M, Martínez-Bonet M, Correa-Rocha R. A Novel GMP Protocol to Produce High-Quality Treg Cells From the Pediatric Thymic Tissue to Be Employed as Cellular Therapy. *Front Immunol* 2022; **13**: 893576 [PMID: 35651624 DOI: 10.3389/fimmu.2022.893576]
- 20 Knobel M. An overview of retrosternal goiter. *J Endocrinol Invest* 2021; **44**: 679-691 [PMID: 32780357 DOI: 10.1007/s40618-020-01391-6]
- 21 Nagaty M, Shehata MS, Elkady AS, Eid M, Nady M, Youssef A, Henish MIE, Monazea K, Noreldin RI, Nasr M, Fayad S, Abdelwahed MS, Hasan A. An assessment of the role of surgical loupe technique in prevention of postthyroidectomy complications: a comparative prospective study. *Ann Med Surg (Lond)* 2023; **85**: 446-452 [PMID: 37008171 DOI: 10.1097/MS9.0000000000000271]
- 22 Hauch A, Al-Qurayshi Z, Randolph G, Kandil E. Total thyroidectomy is associated with increased risk of complications for low- and high-volume surgeons. *Ann Surg Oncol* 2014; **21**: 3844-3852 [PMID: 24943236 DOI: 10.1245/s10434-014-3846-8]



Published by **Baishideng Publishing Group Inc**
7041 Koll Center Parkway, Suite 160, Pleasanton, CA 94566, USA

Telephone: +1-925-3991568

E-mail: office@baishideng.com

Help Desk: <https://www.f6publishing.com/helpdesk>

<https://www.wjgnet.com>

