



BRIEF ARTICLES

Effect of early propranolol administration on portal hypertensive gastropathy in cirrhotic rats

Savas Rafailidis, Charalampos Demertzidis, Konstantinos Ballas, Michail Alatsakis, Nikolaos Symeonidis, Theodoros Pavlidis, Kyriakos Psarras, Valentini Tzioufa-Asimakopoulou, Athanassios Sakadamis

Savas Rafailidis, Charalampos Demertzidis, Konstantinos Ballas, Michail Alatsakis, Nikolaos Symeonidis, Theodoros Pavlidis, Kyriakos Psarras, Athanassios Sakadamis, 2nd Propedeutical Department of Surgery, Aristotles University of Thessaloniki, Medical School, Hippokration General Hospital of Thessaloniki, 54630 Thessaloniki, Greece

Valentini Tzioufa-Asimakopoulou, Department of Pathology, Aristotles University of Thessaloniki, Medical School, Hippokration General Hospital of Thessaloniki, 54630 Thessaloniki, Greece

Author contributions: Rafailidis S, Demertzidis C and Alatsakis M contributed equally to this work; Ballas K, Demertzidis C and Alatsakis M designed the study; Rafailidis S, Demertzidis C, Alatsakis M, Symeonidis N, Psarras K performed the experimental studies; Ballas K, Pavlidis T, Rafailidis S analyzed the data; Tzioufa-Asimakopoulou V performed the pathological analysis; Sakadamis A supervised the whole experimental study; Rafailidis S wrote the paper.

Correspondence to: Dr. Savas Rafailidis, 2nd Propedeutical Department of Surgery, Hippokration General Hospital, Buiding A, 5th Floor, Konstantinoupoleos 49, 54630 Thessaloniki, Greece. svrafail@otenet.gr

Telephone: +30-2310-992933 Fax: +30-2310-992932

Received: May 28, 2009 Revised: August 12, 2009

Accepted: August 19, 2009

Published online: September 14, 2009

Abstract

AIM: To investigate any protective effect of early propranolol administration in the development of portal hypertensive gastropathy in cirrhotic rats.

METHODS: For the development of liver cirrhosis and portal hypertensive gastropathy, 60 rats underwent ligation of the left adrenal vein and complete devascularization of the left renal vein, followed by phenobarbital and carbon tetrachloride (CCl₄) administration. After two weeks of CCl₄ administration, the rats were randomly separated into two groups. In group A, propranolol was continuously administered intragastrically throughout the study, whereas in group B normal saline (placebo) was administered instead. Hemodynamic studies and vascular morphometric analysis of gastric sections were performed after complete induction of cirrhosis.

RESULTS: Vascular morphometric studies showed higher numbers of vessels in all mucosal layers in

the control group. Statistical analysis revealed a significantly higher total vascular surface in the control group compared to the propranolol group, but with no statistically significant difference between the mean vascular surfaces between the groups. Our study clearly shows that the increased mucosal blood flow is manifested by a marked increase of vessel count.

CONCLUSION: Early propranolol's administration in portal hypertensive cirrhotic rats seems to prevent intense gastric vascular congestion that characterizes portal hypertensive gastropathy.

© 2009 The WJG Press and Baishideng. All rights reserved.

Key words: Portal hypertension; Portal hypertensive gastropathy; Hepatic cirrhosis; Carbon tetrachloride; Gastric mucosal lesion

Peer reviewers: Ned Snyder, MD, FACP, AGAF, Professor of Medicine, Chief of Clinical Gastroenterology and Hepatology, Department of Internal Medicine, The University of Texas Medical Branch, 301 University Blvd., Galveston, Texas 77555-0764, United States; Osman C Ozdogan, Associate Professor, Department of Gastroenterology, Liver Unit, Marmara University School of Medicine, Istanbul 34662, Turkey; Sun-Lung Tsai, MD, PhD, Professor, Director, Hepatogastroenterology Section, Department of Internal Medicine and Liver Research Unit, Department of Medical Research, Chi Mei Medical Center, 901 Chung Hwa Road, Young-Kang City, Tainan County 710, Taiwan, China

Rafailidis S, Demertzidis C, Ballas K, Alatsakis M, Symeonidis N, Pavlidis T, Psarras K, Tzioufa-Asimakopoulou V, Sakadamis A. Effect of early propranolol administration on portal hypertensive gastropathy in cirrhotic rats. *World J Gastroenterol* 2009; 15(34): 4284-4289 Available from: URL: <http://www.wjgnet.com/1007-9327/15/4284.asp> DOI: <http://dx.doi.org/10.3748/wjg.15.4284>

INTRODUCTION

Portal hypertension is a clinical syndrome characterized by elevation of portal pressure and accompanies most cases of hepatic cirrhosis. Most liver cirrhosis complications are attributable to concomitant portal hypertension and the consequent development of portosystemic collaterals and hyperdynamic circulation^[1-4]. Portal hypertensive

gastropathy (PHG) represents a clinical entity in portal hypertension and is endoscopically characterized by a mosaic-like or snake skin pattern of the gastric mucosa, mainly in the body and fundus of the stomach and more rarely in the gastric antrum^[5,6]. These gastric mucosal lesions represent another frequent cause of upper gastrointestinal bleeding, even though esophagogastric varices remain the major source of bleeding in patients with portal hypertension^[5,7].

Non-selective β -blockers have largely been used for primary prophylaxis of bleeding from gastroesophageal varices^[8-12]. Their effect though, as well as of many other agents, on the development of varices has yet to be clarified because there are conflicting results from several studies, both clinical and experimental^[13-17]. On the other hand, development of PHG seems to follow a different pathophysiological pathway and there are relatively few studies investigating drugs' effect on PHG. Propranolol, for example, has been shown to reduce bleeding related to PHG in small studies^[11,12] and these observations were confirmed in a randomized controlled trial of 56 patients with PHG^[18]. We therefore decided to investigate propranolol's effect on PHG and to clarify more precisely if early propranolol administration has any preventive effect on the development of PHG in rats with carbon-tetrachloride (CCl₄)-induced cirrhosis.

MATERIALS AND METHODS

Animals

Sixty four-month-old-male Wistar rats, weighting 280-350 g, were used. They were housed one per cage, kept on an artificial 12-h light-dark cycle and at stable room temperature of 20-22°C. They had free access to tap water and standard laboratory pulverized rat chow throughout the study.

For all animal experiments the "Principles of laboratory animal care" (NIH publication No. 86-23, revised 1985) were followed. The study was approved by the Ethical Committee of the Aristotle University of Thessaloniki.

Experimental model

Liver cirrhosis, portal hypertension and esophagogastric varices were induced using a model, originally developed in our department, which has been proved to be very effective for the induction of cirrhotic portal hypertension as well as of esophageal and gastric varices^[19].

Briefly, all animals underwent ligation of the left adrenal vein and complete devascularization of the left renal vein. Two weeks later, induction of liver cirrhosis started according to the model of weekly intragastric administration of CCl₄ in the phenobarbitone-induced rat^[20,21].

Animal groups and drug administration

Two weeks after the beginning of carbon tetrachloride administration, the rats were randomly separated into two groups. In Group A, comprising 30 rats, propranolol was continuously administered throughout the study, whereas in Group B (30 rats), normal saline (placebo)

was continuously administered instead of propranolol. This early commencement of drug administration, before the full development of liver cirrhosis, aimed to simulate clinical practice, where any kind of preventive treatment should begin soon after initiation of the effect of a hepatotoxic agent. Propranolol (Inderal®, Wyeth Pharmaceuticals Inc., USA), dissolved in normal saline, was administered intragastrically, at a dose of 30 mg/kg per day.

Experimental period - animal sacrifice

CCl₄ was administered weekly until stable ascites developed (8-10 wk) as previously described^[16,17,19,22]. Ascites development was easily recognized by an abrupt increase in body weight and confirmed by the abdominal distention observed in the anesthetized rat in the prone position. Once stable ascites developed, CCl₄ administration was discontinued; one week later, rats were re-operated, portal pressure was measured and then the animals were sacrificed with an *iv* bolus administration of 0.5 mL of potassium chloride. The liver, stomach, and esophagus were carefully dissected and removed.

Portal pressure measurement

Portal pressure measurements were performed before animal sacrifice under light ether anesthesia; the rats were kept fasting for 12 h, with free access only to water. The peritoneal cavity of the animal was carefully accessed through the old midline incision, the presence of ascites was confirmed and ascitic fluid was carefully collected and measured. Portal pressure measurement was conducted by catheterization of a mesenteric vein with a PE-50 catheter, which was advanced until its tip reached the origin of the portal vein, while its other end was connected to a Space Labs, Inc. (Model 90308-11-14) pressure recorder. The external zero reference point was placed at the mid portion of the rat.

Histopathological study

The liver, stomach, and esophagus were fixed in 10% buffered formalin solution and embedded in paraffin soon after their removal.

Two sections of the stomach, the first at the cardioesophageal junction and the second at the body of the stomach, were stained with hematoxylin-eosin and initially examined on a light microscope (magnification $\times 4$ and $\times 10$). A liver section was also examined to confirm development of liver cirrhosis.

Morphometric analysis

Following light microscopy, all sections to be studied were scanned by a high resolution frame capture camera (JVC TK-F7300U), processed with computer software (Tema v1.00) and reproduced on a high-contrast, high-resolution PC monitor.

By use of the above mentioned software, delineating the outlines of vessels led to an easy calculation of the following parameters per optical field: (1) Total number of veins counted in gastric submucosa; (2) Total submucosal area occupied by vessels; (3) Mean

cross sectional vessel area (this variable was calculated by dividing total submucosal vessel area by the number of submucosal vessels); (4) Total number of superficial vessels in the gastric mucosa; (5) Total area of superficial vessels in the gastric mucosa; (6) Mean cross sectional vessel area of superficial gastric mucosal vessels; (7) Total number of deep gastric mucosal vessels; (8) Total area of deep gastric mucosal vessels; and (9) Mean cross sectional area of deep gastric mucosal vessels

All calculations were performed blindly by an experienced pathologist who was not informed as to the origin of the preparations.

Statistical analysis

Statistical version 6.0 (Stat Soft Inc.) was used for statistical analysis. First, the distribution of each parameter was determined according to its histograms and normal plots and was confirmed by application of the Shapiro-Wilk W test. Results were expressed as mean \pm SD for variables with normal distribution and as median - interquartile range for skewed distribution. Comparison between groups was performed using Student's t -test for unpaired data to evaluate differences in portal pressure and total submucosal area occupied by vessels; values of these variables followed a normal distribution. For all other variables, the non-parametric Mann Whitney U -test was applied. $P < 0.05$ were considered statistically significant.

RESULTS

Mortality

Forty-eight rats survived the study. There were no significant differences in body weight of rats among the two groups. There were seven deaths in group A and five in group B. As shown in Table 1, one of the propranolol group rats and two of the control group died from variceal bleeding before the end of the study (large amounts of blood were found in the stomach and upper jejunum). Two rats of group A and three rats of group B died from improper manipulation (administration of carbon tetrachloride into the tracheal-bronchial tree), while the deaths of four group A rats were attributed to CCl_4 toxicity.

Ascites

No significant difference in the amount of ascitic fluid was observed between the two groups ($P > 0.05$).

Portal pressure

Portal pressure values followed a normal distribution in both groups. Mean portal pressure was lower in the propranolol group (11.6 ± 1.36) compared to mean portal pressure of control group (14.61 ± 1.84) (Table 2). Comparison between groups revealed a portal pressure decrease of 21.5% in the propranolol group, which was proved to be statistically significant ($P < 0.05$).

Liver cirrhosis

All rats developed micronodular cirrhosis within 8-10 wk.

Table 1 Number of rats and causes of death

	Total number of deaths <i>n</i> (%)	Cause of death		
		Variceal bleeding	CCl_4 toxicity	Improper manipulation
Group A (<i>n</i> = 30)	7 (23.3)	1	4	2
Group B (<i>n</i> = 30)	5 (16.67)	2	-	3

Table 2 Portal pressure in group A and B

	Portal pressure (mmHg)			
	Mean	Minimum	Maximum	SD
Group A (<i>n</i> = 23)	11.60	9.20	14.3	1.36
Group B (<i>n</i> = 25)	14.61	11.3	18.2	1.84

Propranolol causes significant decrease ($P < 0.05$) in portal pressure.

Regenerating nodules surrounded by thickened septa of connective tissue with obvious architectural distortion were present on all hepatic sections. There was no obvious difference in the degree of hepatic fibrosis between the groups.

Gastric sections on light microscopy

Microscopic examination of the stomach revealed excessive mucosal and submucosal vascular congestion. Besides congestion, animals of group B (placebo treated groups) were found with more mucosal and submucosal vessels, while in some of them the development of smooth muscle cells in the mucosa was noticed.

Morphometric analysis of gastric mucosa and submucosa

Measurements and calculations were performed by image analysis in both groups. From the variables studied, only total and mean cross sectional area of superficial gastric mucosal vessels followed a normal distribution in both groups, while all other variables studied presented skewed distributions in either group or were non-continuous scale variables. Comparison between groups was performed using Student's t -test for unpaired data for the variables "total area of gastric superficial mucosal vessels" and "mean cross sectional area of gastric superficial mucosal vessels", and the non-parametric Mann Whitney U -test for all other variables. The summarized analysis and comparison of data are shown in Table 3. Statistically significant differences ($P < 0.05$) between groups were revealed for the variables "total area occupied by vessels" and "total number of counted veins" in the submucosa, the deep and superficial layers of gastric mucosa. On the other hand, the variable "mean cross sectional area" of gastric submucosal vessels as well as of deep and superficial gastric mucosal vessels did not differ significantly between the groups.

DISCUSSION

Esophageal varices have long been considered the major cause of upper gastrointestinal hemorrhage in patients

Table 3 Results of morphometric analysis and comparison between groups

	Group A	Group B	P
Total area of submucosal vessels (μm^2)	47 441.37 \pm 24 299.48	47 539.12 (33 295.84, 55 931.07)	0.0037
Mean cross sectional area of submucosal vessels (μm^2)	4682.70 (3571.92, 6350.68)	5911.17 \pm 1963.34	0.09
Number of submucosal vessels	5 (4, 7)	8 (7, 9)	0.01
Total area of superficial gastric mucosal vessels (μm^2)	7004.03 \pm 2438.37	10 994.49 \pm 3746.56	0.0001
Mean cross sectional area of superficial mucosal vessels (μm^2)	642.78 \pm 432.59	573.70 (475.08, 623.39)	0.25
Number of superficial gastric mucosal vessels	12 (9, 14)	20 (17, 24)	0.00001
Total area of deep gastric mucosal vessels (μm^2)	6916.76 (3694.98, 8016.40)	19 367.84 \pm 7034.08	0.0008
Mean cross sectional area of deep gastric mucosal vessels (μm^2)	834.88 (554.05, 953.04)	982.90 (697.11, 1249.35)	0.1
Number of deep gastric mucosal vessels	9 (7, 11)	20 (16, 22)	0.00001

Values are mean \pm SD or median (lower, upper quartiles).

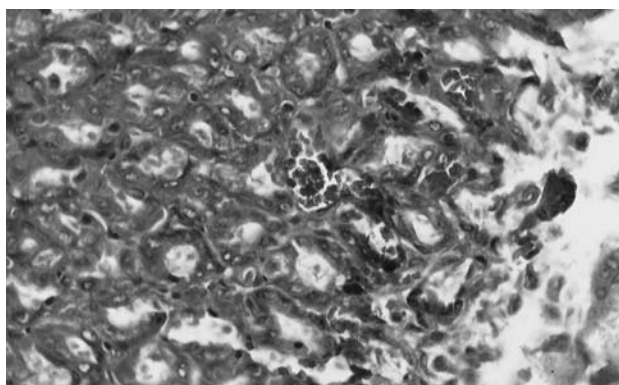


Figure 1 Vascular ectasia and congestion of gastric submucosa in group B (HE, \times 400).

with portal hypertension. However, gastric mucosal lesions have lately been considered as another frequent cause of upper gastrointestinal bleeding in these patients, accounting for 20% to 40% of all cases^[23,24]. Dilated precapillaries, capillaries and submucosal veins, extensive submucosal edema, thickening of the submucosal arteriolar walls and submucosal veins showing features of arterIALIZATION, are all observed in patients with portal hypertension^[5,25-28], while morphometric analyses have shown an increase of mean mucosal capillary cross-sectional area^[29-32]. Clinically significant bleeding is seen in association with severe portal hypertensive gastropathy (PHG) and non-selective beta-blockers, such as propranolol and nadolol, have been shown to reduce portal pressure and gastric mucosal blood flow. Previous experimental studies using propranolol^[13,14,33,34] and clonidine^[35] early in the process of portal hypertension induction have been proven effective in prevention of complications.

However, these studies, mainly based on hemodynamic measurements, are very sensitive and easily affected by a number of imponderable and in many cases unknown factors^[36-38]. This might explain why similar studies from various research centers often resulted in completely different conclusions^[39-43].

To avoid these problems, we decided to directly investigate the effects of early propranolol administration on gastric mucosal and submucosal pathology. The gastric mucosal and submucosal vein plexus (Figure 1) was meticulously studied and measurements of vessels'

and submucosa's areas were carefully performed with the aid of an image analysis system. Portal pressure was the only hemodynamic parameter studied. Measurements revealed a 21.5% decrease of portal pressure in propranolol treated rats; these results are fully compatible with literature data^[13,14,33,34]. On the other hand, careful analysis of morphometric data revealed that early propranolol administration significantly affects the total area of gastric submucosal and mucosal vessels as well as the number of gastric submucosal and mucosal vessels of cirrhotic rats, while the mean cross sectional area does not seem to be significantly affected.

In clinical practice, cirrhosis represents the major cause of portal hypertension. Induction of cirrhotic portal hypertension by carbon tetrachloride administration was therefore considered to be an appropriate experimental model for our study. In this model, portal hypertensive syndrome is fully developed after a reasonable time, permitting the study of chronic and early propranolol administration. All similar studies presented in the literature^[13,14,33-35], were carried out either in prehepatic portal hypertension or in cases of schistosomiasis, probably due to lack of reliable models capable of developing esophagogastric varices in cirrhotic rats. This is mainly due to the development of extended collaterals from the portal vein to the left renal vein via the left adrenal vein. These collaterals, which are non-functional in normal rats, prevent portosystemic shunt through the gastric and lower esophageal veins in case of portal hypertension. We overcame this problem by using a modification of the well-known model of carbon tetrachloride induced cirrhosis. This included the induction of cirrhosis in rats that had previously undergone ligation of the left adrenal vein and complete devascularization of the left renal vein. The effectiveness of this model has already been demonstrated in previous studies^[15-17,19].

Gastric submucosal vessels, as well as superficial and deep gastric mucosal vessels, were meticulously studied, and various measurements were carefully performed using an image analysis system, which permitted objective determination of numerous parameters. All gastric submucosal, as well as deep and superficial gastric mucosal vessels per optical field, were counted, and their borders were carefully delineated, to calculate the total and mean cross sectional area of submucosal gastric

veins, and deep and superficial gastric mucosal vessels. An accurate method of measuring vessel cross-sectional areas and comparing them would be to perfuse fix the vessels with a controlled perfusion pressure; however, the significant in vivo differences in portal pressure between the groups, and their effect on gastric vessels, would be masked. We also thought to perfuse fix vessels with pressures comparative to portal pressures; however, this was technically difficult. Thus, the final choice was to use no perfusion fixation and compare simple sections, by measuring several parameters, including vessel numbers. Several factors, besides portal pressure, affect vein development and gastric mucosal and submucosal congestion in cirrhotic animals. It is a general belief that portal pressure increase is the main causative factor for the development of portosystemic collaterals^[1-3], which are considered to be the result of widening, distension, and hypertrophy of pre-existing vessels. Additionally, active angiogenesis can also participate in their formation. Propranolol, by reducing the hepatic venous pressure gradient and azygos blood flow, seems to contribute to the reducing opening of pre-existing blood vessels. On the other hand, neoangiogenesis seems to be prevented by abolishing the norepinephrine inducing effect on vascular endothelial growth factor (VEGF) expression^[44-46]. Morphometric analysis in our study revealed a statistically significant difference ($P < 0.05$) between groups in the number of mucosal and submucosal vessels, as well as in the total area occupied by vessels, which was significantly greater ($P < 0.05$) in the placebo group compared to the propranolol treated group. On the other hand, there was no difference in mean cross sectional area of submucosal and mucosal vessels between the groups.

We can therefore claim, based on the results of this experimental study, that early propranolol administration in portal hypertensive cirrhotic rats could be useful in prevention of portal hypertensive gastropathy and its complications.

COMMENTS

Background

Patients with portal hypertension are at substantial risk of bleeding from small gastric mucosal lesions that have been largely described as portal hypertensive gastropathy.

Research frontiers

Propranolol is a well-known and extensively used beta-blocker that has been shown to reduce bleeding related to portal hypertensive gastropathy in small studies. In the area of prevention of portal hypertensive gastropathy, previous experimental studies have shown that early continuous administration of non-selective β -blockers, such as propranolol, could ameliorate portosystemic hemodynamics and therefore reduce complications. The sensitive and easily affected hemodynamic measurements used in previous studies have resulted in different conclusions and led to an effort to directly investigate the effects of early propranolol administration on gastric mucosal and submucosal pathology.

Innovations and breakthroughs

The concept that early continuous administration of drugs is capable of reducing portal pressure and could prevent the development of extended portosystemic collaterals and consequently esophagogastric varices or portal hypertensive gastropathy, has led to a series of experimental and clinical studies. Many agents with a known lowering effect on portal pressure (including propranolol, nadolol, clonidine, octreotide, isosorbite mononitrate and, more recently, endothelin

receptor antagonists) have already been tested for their effect on portosystemic shunting and development of esophageal varices, when administered early, that is before the full development of portal hypertension syndrome. Several studies have been published, both clinical and experimental, with controversial results on the protective role of non-selective beta-blockers. To avoid complicated and easily affected hemodynamic measurements the authors decided to directly investigate the effects of early propranolol administration on gastric mucosal and submucosal pathology. The gastric mucosal and submucosal vein plexus was meticulously studied and measurements of vessels' and submucosa's area were carefully performed with the aid of an image analysis system. Portal pressure was the only hemodynamic parameter studied in order to confirm the already known propranolol's effect on it.

Applications

The study results suggest that early propranolol administration in portal hypertensive cirrhotic rats could prevent intense gastric vascular congestion, which characterizes portal hypertensive gastropathy and could therefore be useful in preventing its complications.

Peer review

This is a well designed study to look at the effects of a non selective β blocker in the prevention of portal hypertensive gastropathy in a rat model for cirrhosis and portal hypertension.

REFERENCES

- Gupta TK, Chen L, Groszmann RJ. Pathophysiology of portal hypertension. *Baillieres Clin Gastroenterol* 1997; **11**: 203-219
- Paquet KJ. Causes and pathomechanisms of oesophageal varices development. *Med Sci Monit* 2000; **6**: 915-928
- Groszmann RJ, Abraldes JG. Portal hypertension: from bedside to bench. *J Clin Gastroenterol* 2005; **39**: S125-S130
- Bosch J, Pizcueta P, Feu F, Fernández M, García-Pagán JC. Pathophysiology of portal hypertension. *Gastroenterol Clin North Am* 1992; **21**: 1-14
- McCormack TT, Sims J, Eyre-Brook I, Kennedy H, Goepel J, Johnson AG, Triger DR. Gastric lesions in portal hypertension: inflammatory gastritis or congestive gastropathy? *Gut* 1985; **26**: 1226-1232
- Thuluvath PJ, Yoo HY. Portal Hypertensive gastropathy. *Am J Gastroenterol* 2002; **97**: 2973-2978
- Sarfeh IJ, Tarnawski A. Gastric mucosal vasculopathy in portal hypertension. *Gastroenterology* 1987; **93**: 1129-1131
- Groszmann RJ, Bosch J, Grace ND, Conn HO, Garcia-Tsao G, Navasa M, Alberts J, Rodes J, Fischer R, Bermann M. Hemodynamic events in a prospective randomized trial of propranolol versus placebo in the prevention of a first variceal hemorrhage. *Gastroenterology* 1990; **99**: 1401-1407
- Poynard T, Calès P, Pasta L, Ideo G, Pascal JP, Pagliaro L, Lebrech D. Beta-adrenergic-antagonist drugs in the prevention of gastrointestinal bleeding in patients with cirrhosis and esophageal varices. An analysis of data and prognostic factors in 589 patients from four randomized clinical trials. Franco-Italian Multicenter Study Group. *N Engl J Med* 1991; **324**: 1532-1538
- Groszmann RJ, Garcia-Tsao G, Bosch J, Grace ND, Burroughs AK, Planas R, Escorsell A, Garcia-Pagan JC, Patch D, Matloff DS, Gao H, Makuch R. Beta-blockers to prevent gastroesophageal varices in patients with cirrhosis. *N Engl J Med* 2005; **353**: 2254-2261
- Lebrech D, Poynard T, Hillon P, Benhamou JP. Propranolol for prevention of recurrent gastrointestinal bleeding in patients with cirrhosis: A controlled study. *N Engl J Med* 1981; **305**: 1371-1374
- Hosking SW, Kennedy HJ, Seddon I, Triger DR. The role of propranolol in congestive gastropathy of portal hypertension. *Hepatology* 1987; **7**: 437-441
- Lin HC, Soubrane O, Cailmail S, Lebrech D. Early chronic administration of propranolol reduces the severity of portal hypertension and portal-systemic shunts in conscious portal vein stenosed rats. *J Hepatol* 1991; **13**: 213-219
- Sarin SK, Groszmann RJ, Mosca PG, Rojkind M, Stadelcker

- MJ, Bhatnagar R, Reuben A, Dayal Y. Propranolol ameliorates the development of portal-systemic shunting in a chronic murine schistosomiasis model of portal hypertension. *J Clin Invest* 1991; **87**: 1032-1036
- 15 **Ballas KD**, Tzioufa-Asimakopoulou V, Marakis G, Alatsakis MB, Papavasiliou AV, Rafailidis S, Sakadamis AK. Effect of early octreotide administration on the development of esophageal varices in cirrhotic rats. *Hepatol Res* 2004; **29**: 104-112
 - 16 **Rafailidis S**, Ballas K, Psarras K, Pavlidis T, Emoniotou E, Papamichali R, Kalodimos G, Marakis G, Sakadamis A, Koukoulis G. Effect of early bosentan administration on the development of esophageal varices in cirrhotic rats: experimental study in Wistar rats. *J Gastroenterol* 2008; **43**: 897-904
 - 17 **Alatsakis M**, Ballas KD, Pavlidis TE, Psarras K, Rafailidis S, Tzioufa-Asimakopoulou V, Marakis GN, Sakantamis AK. Early propranolol administration does not prevent development of esophageal varices in cirrhotic rats. *Eur Surg Res* 2009; **42**: 11-16
 - 18 **Pérez-Ayuso RM**, Piqué JM, Bosch J, Panés J, González A, Pérez R, Rigau J, Quintero E, Valderrama R, Viver J. Propranolol in prevention of recurrent bleeding from severe portal hypertensive gastropathy in cirrhosis. *Lancet* 1991; **337**: 1431-1434
 - 19 **Sakadamis AK**, Ballas KD, Tzioufa-Asimakopoulou V, Alatsakis MB. A rat model of liver cirrhosis and esophageal varices. *Res Exp Med (Berl)* 2001; **200**: 137-154
 - 20 **Proctor E**, Chatamra K. High yield micronodular cirrhosis in the rat. *Gastroenterology* 1982; **83**: 1183-1190
 - 21 **Proctor E**, Chatamra K. Standardized micronodular cirrhosis in the rat. *Eur Surg Res* 1984; **16**: 182-186
 - 22 **Karalis M**, Pavlidis TE, Psarras K, Ballas K, Zaraboukas T, Rafailidis S, Symeonidis N, Marakis GN, Sakantamis AK. Effect of experimentally induced liver cirrhosis on wound healing of the post-extraction tooth socket in rats. *Eur Surg Res* 2008; **40**: 190-196
 - 23 **Terés J**, Bordas JM, Bru C, Diaz F, Bruguera M, Rodes J. Upper gastrointestinal bleeding in cirrhosis: clinical and endoscopic correlations. *Gut* 1976; **17**: 37-40
 - 24 **Ohta M**, Yamaguchi S, Gotoh N, Tomikawa M. Pathogenesis of portal hypertensive gastropathy: a clinical and experimental review. *Surgery* 2002; **131**: S165-S170
 - 25 **Hashizume M**, Tanaka K, Inokuchi K. Morphology of gastric microcirculation in cirrhosis. *Hepatology* 1983; **3**: 1008-1012
 - 26 **Foster PN**, Wyatt JL, Bullimore DW, Losowsky MS. Gastric mucosa in patients with portal hypertension: prevalence of capillary dilatation and *Campylobacter pylori*. *J Clin Pathol* 1989; **42**: 919-921
 - 27 **Payen JL**, Calès P, Voigt JJ, Barbe S, Pilette C, Dubuisson L, Desmorat H, Vinel JP, Kervran A, Chayvialle JA. Severe portal hypertensive gastropathy and antral vascular ectasia are distinct entities in patients with cirrhosis. *Gastroenterology* 1995; **108**: 138-44
 - 28 **Toyonaga A**, Iwao T. Portal-hypertensive gastropathy. *J Gastroenterol Hepatol* 1998; **13**: 865-877
 - 29 **Quintero E**, Pique JM, Bombi JA, Bordas JM, Sentis J, Elena M, Bosch J, Rodes J. Gastric mucosal vascular ectasias causing bleeding in cirrhosis. A distinct entity associated with hypergastrinemia and low serum levels of pepsinogen I. *Gastroenterology* 1987; **93**: 1054-1061
 - 30 **Iwao T**, Toyonaga A, Tanikawa K. Gastric red spots in patients with cirrhosis: subclinical condition of gastric mucosal hemorrhage? *Gastroenterol Jpn* 1990; **25**: 685-692
 - 31 **McCormick PA**, Sankey EA, Cardin F, Dhillon AP, McIntyre N, Burroughs AK. Congestive gastropathy and *Helicobacter pylori*: an endoscopic and morphometric study. *Gut* 1991; **32**: 351-354
 - 32 **Parikh SS**, Desai SB, Prabhu SR, Trivedi MH, Shankaran K, Bhukhanwala FA, Kalro RH, Desai HG. Congestive gastropathy: factors influencing development, endoscopic features, *Helicobacter pylori* infection, and microvessel changes. *Am J Gastroenterol* 1994; **89**: 1036-1042
 - 33 **Sarin SK**, Stadeker M, Groszmann RJ. Propranolol prevents the development of portal systemic shunting in chronic murine schistosomiasis. *Gastroenterology* 1989; **96**: A654
 - 34 **Ruthardt FW**, Stauber RE, Kuhlen R, Ban Thiel DH. Chronic beta blockade reduces portal systemic shunting in portal hypertensive rats. *Gastroenterology* 1990; **98**: A199
 - 35 **Lin HC**, Soubrane O, Lebrech D. Prevention of portal hypertension and portosystemic shunts by early chronic administration of clonidine in conscious portal vein-stenosed rats. *Hepatology* 1991; **14**: 325-330
 - 36 **Debaene B**, Goldfarb G, Braillon A, Jolis P, Lebrech D. Effects of ketamine, halothane, enflurane, and isoflurane on systemic and splanchnic hemodynamics in normovolemic and hypovolemic cirrhotic rats. *Anesthesiology* 1990; **73**: 118-124
 - 37 **Zimpfer M**, Manders WT, Barger AC, Vatner SF. Pentobarbital alters compensatory neural and humoral mechanisms in response to hemorrhage. *Am J Physiol* 1982; **243**: H713-H721
 - 38 **Lee SS**, Hadengue A, Girod C, Lebrech D. Discrepant responses to betaxolol in conscious and anaesthetized portal hypertensive rats. *Hepatology* 1986; **3**: S139
 - 39 **Jenkins SA**, Baxter JN, Corbett WA, Shields R. The effects of a somatostatin analogue SMS 201-995 on hepatic haemodynamics in the cirrhotic rat. *Br J Surg* 1985; **72**: 864-867
 - 40 **Jenkins SA**, Baxter JN, Corbett WA, Shields R. Effects of a somatostatin analogue SMS 201-995 on hepatic haemodynamics in the pig and on intravariceal pressure in man. *Br J Surg* 1985; **72**: 1009-1012
 - 41 **Jenkins SA**, Baxter JN, Corbett W, Devitt P, Ware J, Shields R. A prospective randomised controlled clinical trial comparing somatostatin and vasopressin in controlling acute variceal haemorrhage. *Br Med J (Clin Res Ed)* 1985; **290**: 275-278
 - 42 **Sonnenberg GE**, Keller U, Perruchoud A, Burckhardt D, Gyr K. Effect of somatostatin on splanchnic hemodynamics in patients with cirrhosis of the liver and in normal subjects. *Gastroenterology* 1981; **80**: 526-532
 - 43 **Merkel C**, Gatta A, Zuin R, Finucci GF, Nosadini R, Ruol A. Effect of somatostatin on splanchnic hemodynamics in patients with liver cirrhosis and portal hypertension. *Digestion* 1985; **32**: 92-98
 - 44 **Fredriksson JM**, Lindquist JM, Bronnikov GE, Nedergaard J. Norepinephrine induces vascular endothelial growth factor gene expression in brown adipocytes through a beta-adrenoreceptor/cAMP/protein kinase A pathway involving Src but independently of Erk1/2. *J Biol Chem* 2000; **275**: 13802-13811
 - 45 **Weil J**, Benndorf R, Fredersdorf S, Griese DP, Eschenhagen T. Norepinephrine upregulates vascular endothelial growth factor in rat cardiac myocytes by a paracrine mechanism. *Angiogenesis* 2003; **6**: 303-309
 - 46 **Annabi B**, Lachambre MP, Plouffe K, Moumdjian R, Béliveau R. Propranolol adrenergic blockade inhibits human brain endothelial cells tubulogenesis and matrix metalloproteinase-9 secretion. *Pharmacol Res* 2009; Epub ahead of print

S- Editor Tian L L- Editor Stewart GJ E- Editor Yin DH