



Red wine and green tea reduce *H pylori*- or VacA-induced gastritis in a mouse model

Paolo Ruggiero, Giacomo Rossi, Francesco Tombola, Laura Pancotto, Laura Lauretti, Giuseppe Del Giudice, Mario Zoratti

Paolo Ruggiero, Laura Pancotto, Laura Lauretti, Giuseppe Del Giudice, Novartis Vaccines & Diagnostics s.r.l., Research Center, Siena, Italy

Giacomo Rossi, Department of Veterinary Science, University of Camerino, Matelica, Italy

Francesco Tombola, Department of Biomedical Sciences, University of Padova, Italy

Francesco Tombola, Mario Zoratti, CNR Institute of Neuroscience, Section for Biomembranes, Padova, Italy

Supported partly by a CNR Target Project Biotechnology grant and a University of Padova Young Investigator grant

Correspondence to: Paolo Ruggiero, Novartis Vaccines & Diagnostics s.r.l., Research Center, Via Fiorentina 1, Siena I-53100, Italy. paolo.ruggiero@novartis.com

Telephone: +39-577-243111 Fax: +39-577-243564

Received: 2006-10-09 Accepted: 2006-12-01

Ruggiero P, Rossi G, Tombola F, Pancotto L, Lauretti L, Del Giudice G, Zoratti M. Red wine and green tea reduce *H pylori*- or VacA-induced gastritis in a mouse model. *World J Gastroenterol* 2007; 13(3): 349-354

<http://www.wjgnet.com/1007-9327/13/349.asp>

Abstract

AIM: To investigate whether red wine and green tea could exert anti-*H pylori* or anti-VacA activity *in vivo* in a mouse model of experimental infection.

METHODS: Ethanol-free red wine and green tea concentrates were administered orally as a mixture of the two beverages to *H pylori* infected mice, or separately to VacA-treated mice. Gastric colonization and gastric inflammation were quantified by microbiological, histopathological, and immunohistochemical analyses.

RESULTS: In *H pylori*-infected mice, the red wine and green tea mixture significantly prevented gastritis and limited the localization of bacteria and VacA to the surface of the gastric epithelium. Similarly, both beverages significantly prevented gastric epithelium damage in VacA-treated mice; green tea, but not red wine, also altered the VacA localization in the gastric epithelium.

CONCLUSION: Red wine and green tea are able to prevent *H pylori*-induced gastric epithelium damage, possibly involving VacA inhibition. This observation supports the possible relevance of diet on the pathological outcome of *H pylori* infection.

© 2007 The WJG Press. All rights reserved.

Key words: VacA; *H pylori*; Gastritis; Wine; Tea; Polyphenols

INTRODUCTION

H pylori chronically infects human stomach, causing atrophic gastritis. The majority of infections are asymptomatic; nevertheless, infected individuals can incur severe gastroduodenal diseases such as peptic ulcer^[1] and gastric mucosa-associated lymphoid tissue (MALT) lymphoma^[2]. *H pylori* infection plays a relevant role in gastric carcinogenesis, which was also shown in animals^[3]. The current antibiotic-based therapies against *H pylori* are generally effective, but can fail due to antibiotic resistance or lack of patient compliance. To colonize the host stomach, *H pylori* expresses several factors that can play a role in pathogenesis. One that is most characterized is the vacuolating cytotoxin VacA, which induces cell vacuolation and rearrangements of late endosomes and lysosomes *in vitro*^[4]. VacA forms anion-selective, urea-permeable channels in artificial and plasma membranes^[5]. It promotes diffusion across the epithelium of urea^[6], which is hydrolysed by *H pylori* urease, leading neutralisation of acidic gastric juice and thus favouring bacterial survival. *In vitro*, VacA exhibits several properties that suggest its role in disturbing the host immune system, although *in vivo* experimental proof of similar activity remains to be provided^[7]. The most evident *in vivo* activity of VacA is to cause damage of gastric epithelium, as shown in murine models^[8,9]. Plant-derived substances have been reported to limit *H pylori* gastric colonization in Mongolian gerbils^[10,11]. We have previously found that polyphenols and polyphenol-rich beverages, such as tea and wine, inhibit VacA activity *in vitro*^[12], and that some polyphenols can limit both *H pylori*- and VacA-induced gastric damage *in vivo*^[13]. Also, it has been recently reported that hop bract extract exerts anti-VacA activity *in vitro* and *in vivo*^[14]. In the present paper we investigated whether red wine and green tea concentrates could influence gastric colonization or gastric pathology in *H pylori*-infected or VacA-treated mice.

MATERIALS AND METHODS

Bacteria

SPM 326, a Type I *H. pylori* strain expressing s1/m1 VacA isoform, was used^[15]. Bacteria were grown at 37°C in Columbia Agar (Oxoid, Basingstoke, UK) plates containing 5% fresh defibrinated horse serum and Dent's supplement (Oxoid), under microaerophylic conditions, using CampyGen (Oxoid), and harvested in saline immediately before challenge.

Toxin

Native s1/m1-type VacA was produced and tested for vacuolating activity on HeLa cells as previously described^[16,17]. Prior to use, it was activated at pH 2.0 for 10 min at R.T., then neutralized and diluted in saline.

Red wine and green tea concentrates

Red wine (RW) was produced on a local (Sarmede, Italy) family vineyard by the traditional spontaneous fermentation process, without additives. Green tea (GT) infusion was obtained by boiling 2 g of lyophilised and otherwise untreated leaves from Morocco in 1 L of distilled water for 5 min. GT and alcohol-free RW concentrates were obtained by vacuum distillation at 30°C, then stored in aliquots at -20°C. Prior to administration concentrates were thawed, diluted in water to reach 3-fold (RW) or 1.5-fold (GT) concentration in comparison with the original volume, and filtered at 0.2 µm. RW + GT mixture was prepared at the same final concentrations.

Mice and study design

Specific-pathogen-free mice (Charles River, Calco, Italy) were housed and treated in compliance with the current law. The schedule of the treatments is summarized in Table 1. Overnight starved 6-wk old CD1 mice (average body weight 22 g) were infected intragastrically by two administrations each other day of 10⁸ CFU/mouse^[15]. Alternatively, starved 6-wk old BALB/c mice (average body weight 18 g) received two intragastric administrations each other day of either 10 µg or 50 µg of VacA^[8]. Controls received saline only. Starting 24 h before infection or VacA administration, the animals had free access to drinking water containing 1% glucose and RW + GT in the case of *H. pylori* infection, RW or GT in the case of VacA administration. Controls drank a 1% glucose solution. The beverages were changed daily; their intake was about 5 mL/d per mouse, without appreciable differences among the different groups. Two weeks after infection, or 4 d after the first VacA treatment, the animals were euthanized, and each stomach immediately removed and cut along the greater and lesser curvature, obtaining two equivalent parts. One part was formalin fixed and paraffin embedded for further histopathological analysis. Gastric mucosa was scraped from the remaining half stomach and cultured on selective plates, prepared as described above with the addition of 0.2 mg/mL bacitracin (Sigma-Aldrich), to quantify *H. pylori* colony forming units (CFU).

Histopathology

From paraffin-embedded stomachs 4 µm-thick sections

Table 1 Schedule of treatments

Group	n	D -1 to the D of sacrifice	D 0	D 2	D 4	D 14
RW + GT	6	RW + GT	Infection	Infection	-	Sacrifice
Infected	6	1% glucose	Infection	Infection	-	Sacrifice
Non infected	6	1% glucose	Saline	Saline	-	Sacrifice
RW	5	RW	VacA 10 µg	VacA 10 µg	Sacrifice	-
	5	RW	VacA 50 µg	VacA 50 µg	Sacrifice	-
GT	5	GT	VacA 10 µg	VacA 10 µg	Sacrifice	-
	5	GT	VacA 50 µg	VacA 50 µg	Sacrifice	-
VacA control	5	1% glucose	VacA 10 µg	VacA 10 µg	Sacrifice	-
	5	1% glucose	VacA 50 µg	VacA 50 µg	Sacrifice	-
Saline	5	1% glucose	Saline	Saline	Sacrifice	-

were cut, dewaxed, and stained with haematoxylin-eosin (HE), then blindly examined. Gastritis was graded in antrum, corpus and fundus of each stomach according to the updated Sydney System^[18], and scored from 0 to 3 corresponding to normal, mild, moderate and severe, respectively. Gastric sections were also subjected to immunohistochemical (IHC) staining using either an anti-*H. pylori* polyclonal antibody (HistoLine) or an anti-VacA monoclonal antibody as already described^[13,19].

Statistical analysis

Data were evaluated by one-tailed Mann-Whitney *U* test. Probability values less than 5% ($P < 0.05$) were considered and referred to as statistically significant.

RESULTS

Red wine and green tea alter the *H. pylori* localization in gastric mucosa

H. pylori SPM 326 colonized stomachs of both control and RW + GT-treated mice, giving geometric means of 1.6×10^3 and 2.6×10^3 CFU/stomach respectively, lacking significant difference ($P = 0.22$). While in RW + GT-treated animals *H. pylori* was detectable by IHC mainly on the surface of the gastric mucosa (Figure 1A), in the infected control both superficial and deep staining was observed (Figure 1C). In adjacent sections, VacA localization by IHC resulted very similar to that of *H. pylori*, with the difference that VacA staining appeared slightly weaker in RW + GT-treated animals (Figure 1B) and slightly stronger in the infected controls (Figure 1D) as compared with the corresponding *H. pylori* staining.

Red wine and green tea prevent *H. pylori*-induced gastritis

The observation of HE-stained sections of gastric mucosa of *H. pylori*-infected controls revealed gastric inflammation of normal/mild grade in antrum, and mild/moderate in corpus and fundus. Gastritis scores were assigned to antrum, corpus and fundus of each mouse stomach and the mean of the three gastric sites was calculated. RW + GT-treated mice showed gastritis scores significantly lower than those of the corresponding infected, untreated controls ($P < 0.05$) (Figure 2A).

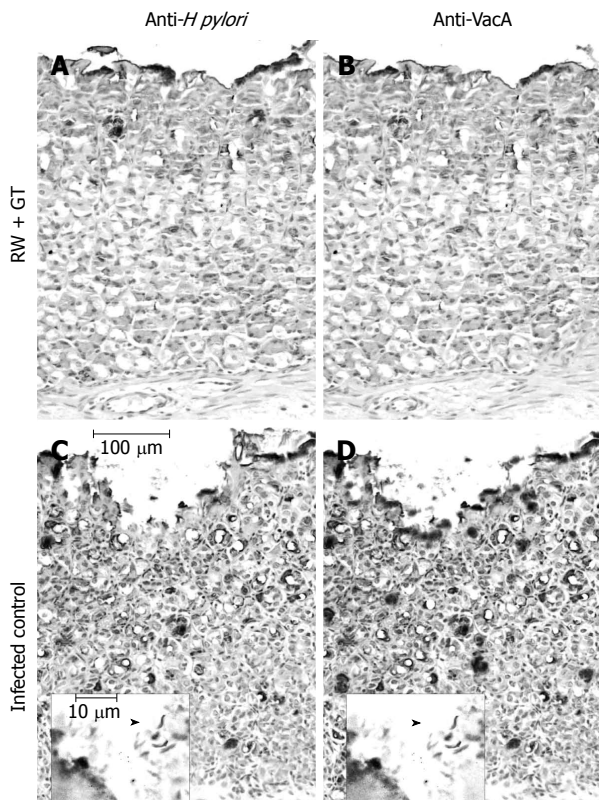


Figure 1 Representative images of IHC detection of *H pylori* (A and C) or VacA (B and D) in gastric mucosa sections from *H pylori*-infected mice in the presence (A and B) or in the absence (C and D) of RW + GT treatment. In the gastric epithelium of infected controls (C and D, adjacent sections) *H pylori* and VacA are detectable with a similar pattern, both superficially and deeply, while upon RW + GT treatment (A and B, adjacent sections) the immunostaining is mainly confined to the surface of the epithelium. Inserts at larger magnification show typical *H pylori* morphology (arrowheads).

Red wine and green tea prevent VacA-induced gastritis

Administration of 10 µg of VacA induced significant gastritis as compared with saline treatment ($P < 0.05$), although epithelial damage was little or absent in the antrum, and very mild in corpus and fundus. With this dose of VacA, reduction of gastritis scores was significant upon administration of GT ($P < 0.05$), but not of RW. Treatment with 50 µg of VacA induced significant ($P < 0.01$) and more evident gastritis (Figure 2B). The mucosal alterations were significantly milder in mice receiving RW or GT (Figures 2B, 3A and C) than those observed in VacA controls (Figures 2B and 3E). VacA controls presented mild epithelial damage in the antrum, and moderate/severe in corpus and fundus, where alteration of mucosal architecture was observed, with epithelial vacuolisation, diffuse mucosal erosion, and some ulcerations (Figure 3E). Gastric mucosa from saline controls did not show appreciable alterations as expected (Figures 2B and 3G).

Green tea alters VacA localization in gastric mucosa

The presence and distribution of VacA was examined by IHC in RW- and GT-treated gastric mucosa (Figure 3B and D), in comparison with VacA and saline controls (Figure 3F and H). VacA was detected both superficially and deeply in the gastric mucosa of mice that received either 10 µg (data not shown) or 50 µg of VacA (Figure

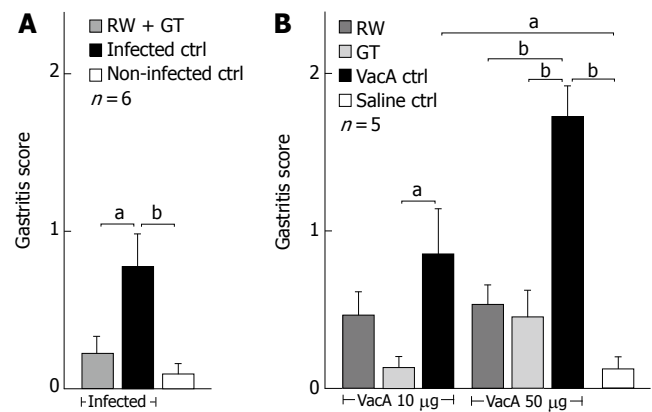


Figure 2 Gastritis score of *H pylori*-infected (A) or VacA-treated (B) mice in the presence or in the absence of RW and/or GT as indicated. Mean of antrum, corpus and fundus scores of each group. Bars = SE. ^a $P < 0.05$, ^b $P < 0.01$ comparison between the indicated groups.

3F), the higher VacA dose producing a qualitatively similar but more intense staining than the lower dose. RW-treated mice showed similar staining as compared with VacA-treated controls (Figure 3B and F, respectively). In contrast, gastric mucosa of GT-treated mice showed only superficial staining of VacA, which was undetectable in the gland crypts (Figure 3D). Saline controls were completely negative as expected (Figure 3H).

DISCUSSION

Upon experimental infection, CD1 mice are stably colonized by *H pylori* and develop gastric inflammation reproducing several of the aspects of the gastric pathology observed in infected humans^[15]. We chose to test in this model RW and GT on the basis of their previously demonstrated anti-VacA activity^[12], and also because they are very common beverages, whose activity against *H pylori* has been already proposed in other models^[20,21]. In our model, upon *H pylori* infection, RW + GT did not induce significant variation of gastric colonization levels in terms of CFU count, although qualitatively altering the distribution of bacteria that were localized more superficially in the gastric epithelium. We cannot exclude that such a difference of bacterial localization could have affected the quantification of colonization. However, if on one hand the action of RW + GT on *H pylori* infection level was difficult to quantify, on the other hand we observed a measurable and significant reduction of gastric inflammation. This result could be due to the observed restriction of the infection to the surface of gastric epithelium, but also to the possible inhibition of VacA exerted by RW + GT *in vivo*. In fact, VacA-deficient strains are able to infect mice, even though VacA can confer an advantage at early stages of the infection^[22]. Thus, *in vivo* inhibition of VacA could be reasonably expected to limit gastric damage, but not necessarily to produce a significant and stable decrease of *H pylori* colonization. Therefore, we evaluated the ability of GT and RW to prevent gastric epithelium damage induced by administration of purified native VacA to BALB/c mice. This mouse strain does not allow stable colonization by SPM326^[23], whereas it

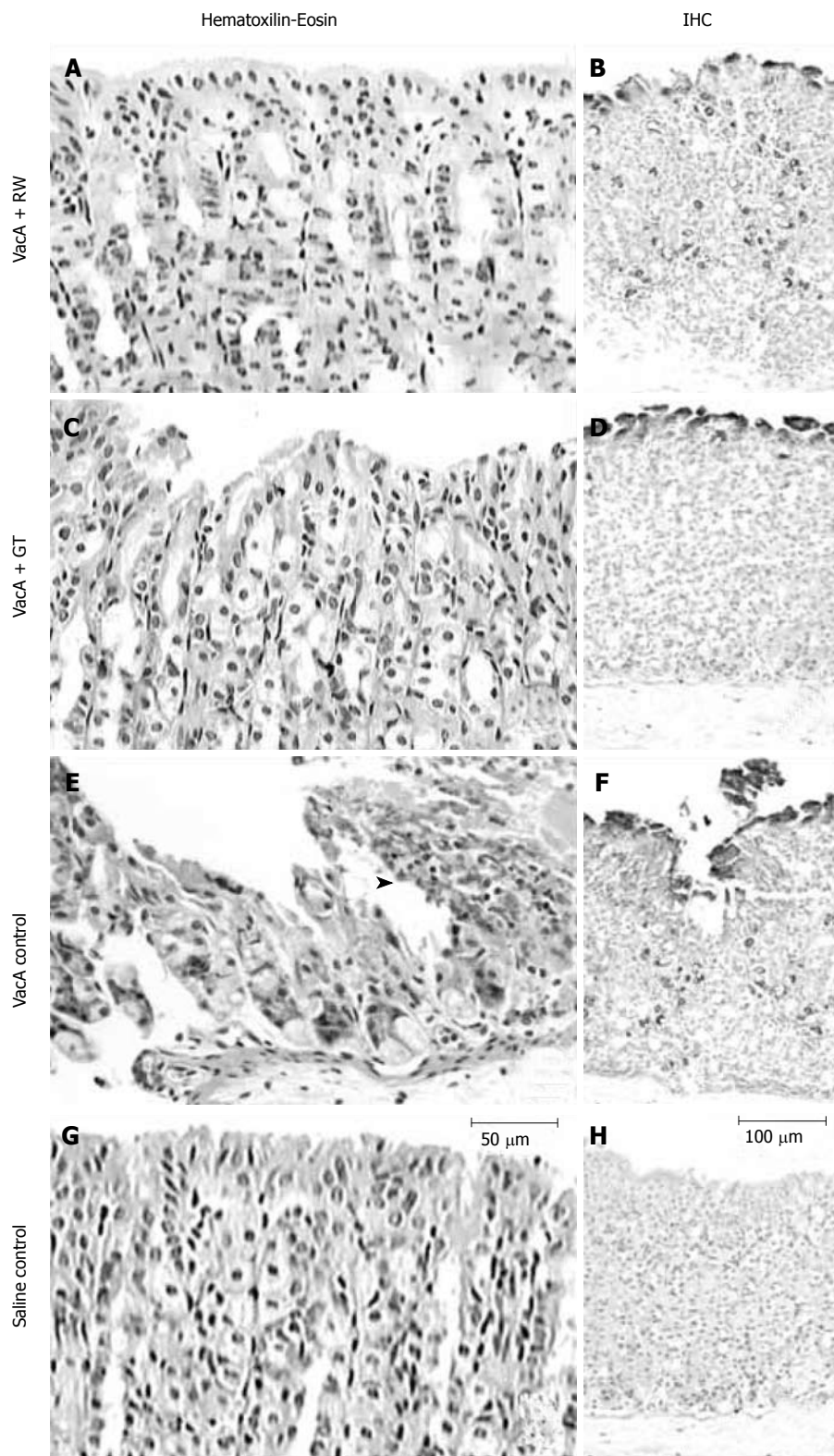


Figure 3 Representative images of sections of gastric corpus mucosa of mice treated with 50 µg of VacA in the presence (A-D) or in the absence (E and F) of RW or GT as indicated, in comparison with saline-treated control (G and H). HE staining (A, C, E and G): VacA control (E) shows a typical loss of mucosal architecture, with areas of cellular debris and inflammatory cells admixture (arrowhead), almost undetectable in the presence of RW (A) or GT (C). IHC detection of VacA (B, D, F and H): distribution of VacA upon RW treatment (B) is both superficial and deep, similarly to that of VacA-treated control (F), while upon GT treatment (D) VacA is detectable only on the surface of gastric epithelium.

is sensitive to VacA^[8]. In this model both GT and RW were able to significantly prevent VacA-induced gastric inflammation. Moreover, GT treatment resulted in VacA to be localized only on the surface of the gastric epithelium, and not in the gland crypts, similarly to the results observed in *H. pylori*-infected mice subjected to RW + GT treatment, and also similarly to that reported for hop bracts extract administration to VacA-treated mice^[14]. Thus, under our experimental conditions, different actions on VacA appear

to be exerted by RW and GT, the former preventing gastric epithelium damage without altering the toxin localization, the latter also limiting its penetration in the gastric epithelium. It must be remarked that VacA is not the only actor on the scene of the pathological outcome of *H. pylori* infection, whose mechanisms are only partially known, and that the identification of *H. pylori* virulence factors still requires investigation^[24]. Both in humans and animals, the disease outcome depends on the virulence of the infecting

strain and on the host's genetic background and immune response^[25-27]. Also, the development of gastric pathology in humans can be influenced by lifestyle^[28,29], and more generally by environmental factors. However, due to the evidence of the direct role of VacA in determining gastric damage^[8,30,31], its inhibition can be reasonably considered relevant to limit *H pylori*-induced gastric pathology. In conclusion, we have shown that green tea and red wine can prevent the deterioration of gastric mucosa induced by *H pylori* infection or VacA administration in mice, possibly involving inhibition of VacA toxin. The potential relevance in humans of this protective activity deserves further investigation.

ACKNOWLEDGMENTS

We are indebted with G Matteucci and R Sabato for managing animal resources, and with S Torricelli and M Tortoli for animal handling.

COMMENTS

Background

H pylori infection of human stomach causes atrophic gastritis, peptic ulcer and gastric mucosa-associated lymphoid tissue (MALT) lymphoma, and plays a relevant role in gastric carcinogenesis. The current antibiotic-based therapy faces problems of antibiotic resistance or lack of patient compliance. No vaccines are presently licensed. Current research focuses on both antimicrobials and vaccines.

Research frontiers

Several plant extracts or plant-derived substances, including polyphenols, have been reported to exert anti-*H pylori* activity *in vitro* and/or, more importantly, *in vivo*. This research field could lead not only to discover new antimicrobials, but also to clarify the possible relevance of diet in the complex mechanism of host-pathogen interaction and in the pathological outcome of *H pylori* infection.

Innovations and breakthroughs

We report for the first time the ability of the mixture of red wine (RW) and green tea (GT) to restrict to the mucosal surface the *H pylori* gastric colonization, which otherwise was both superficial and deep. The altered colonization in RW + GT-treated mice was accompanied by the prevention of gastritis, similarly to that reported by Matsubara *et al* with GT extracts in Mongolian gerbils. In mice administered with VacA toxin, GT treatment both prevented gastric inflammation and limited VacA penetration into the gastric mucosa, while RW was able to prevent gastric inflammation only; the effect of both substances can be at least in part related to VacA inhibition, which we have previously observed *in vitro* with these substances. The results obtained with GT in VacA-treated mice are similar to those reported by Yahiro *et al* with hop bracts extract.

Peer review

The authors described the effects of red wine and green tea against gastritis by infection of *H pylori* or VacA in mice. It was interesting that the combination red wine and green tea prevented induction of damage of gastric mucosa in the animal model. However, it is not clear whether red wine and green tea could prevent the damage, respectively.

Because the authors treated the animals before administration of the microorganism (or VacA), it was not clear if the combined treatment could inhibit the established gastritis either. Further work could better clarify this point.

REFERENCES

- Sontag SJ. Guilty as charged: bugs and drugs in gastric ulcer. *Am J Gastroenterol* 1997; **92**: 1255-1261
- Du MQ, Isaccson PG. Gastric MALT lymphoma: from aetiology to treatment. *Lancet Oncol* 2002; **3**: 97-104
- Sepulveda AR, Graham DY. Role of *Helicobacter pylori* in gastric carcinogenesis. *Gastroenterol Clin North Am* 2002; **31**: 517-535, x
- Reyrat JM, Pelicic V, Papini E, Montecucco C, Rappuoli R, Telford JL. Towards deciphering the *Helicobacter pylori* cytotoxin. *Mol Microbiol* 1999; **34**: 197-204
- Montecucco C, de Bernard M. Molecular and cellular mechanisms of action of the vacuolating cytotoxin (VacA) and neutrophil-activating protein (HP-NAP) virulence factors of *Helicobacter pylori*. *Microbes Infect* 2003; **5**: 715-721
- Tombola F, Morbiato L, Del Giudice G, Rappuoli R, Zoratti M, Papini E. The *Helicobacter pylori* VacA toxin is a urea permease that promotes urea diffusion across epithelia. *J Clin Invest* 2001; **108**: 929-937
- Schmees C, Gerhard M, Treptau T, Voland P, Schwendy S, Rad R, Prinz C. VacA-associated inhibition of T-cell function: reviewed and reconsidered. *Helicobacter* 2006; **11**: 144-146
- Telford JL, Ghiara P, Dell'Orco M, Comanducci M, Burrone D, Bugnoli M, Tecce MF, Censini S, Covacci A, Xiang Z. Gene structure of the *Helicobacter pylori* cytotoxin and evidence of its key role in gastric disease. *J Exp Med* 1994; **179**: 1653-1658
- Fujikawa A, Shirasaka D, Yamamoto S, Ota H, Yahiro K, Fukada M, Shintani T, Wada A, Aoyama N, Hirayama T, Fukamachi H, Noda M. Mice deficient in protein tyrosine phosphatase receptor type Z are resistant to gastric ulcer induction by VacA of *Helicobacter pylori*. *Nat Genet* 2003; **33**: 375-381
- Kataoka M, Hirata K, Kunikata T, Ushio S, Iwaki K, Ohashi K, Ikeda M, Kurimoto M. Antibacterial action of tryptanthrin and kaempferol, isolated from the indigo plant (*Polygonum tinctorium* Lour.), against *Helicobacter pylori*-infected Mongolian gerbils. *J Gastroenterol* 2001; **36**: 5-9
- Takabayashi F, Harada N, Yamada M, Murohisa B, Oguni I. Inhibitory effect of green tea catechins in combination with sucralose on *Helicobacter pylori* infection in Mongolian gerbils. *J Gastroenterol* 2004; **39**: 61-63
- Tombola F, Campello S, De Luca L, Ruggiero P, Del Giudice G, Papini E, Zoratti M. Plant polyphenols inhibit VacA, a toxin secreted by the gastric pathogen *Helicobacter pylori*. *FEBS Lett* 2003; **543**: 184-189
- Ruggiero P, Tombola F, Rossi G, Pancotto L, Lauretti L, Del Giudice G, Zoratti M. Polyphenols reduce gastritis induced by *Helicobacter pylori* infection or VacA toxin administration in mice. *Antimicrob Agents Chemother* 2006; **50**: 2550-2552
- Yahiro K, Shirasaka D, Tagashira M, Wada A, Morinaga N, Kuroda F, Choi O, Inoue M, Aoyama N, Ikeda M, Hirayama T, Moss J, Noda M. Inhibitory effects of polyphenols on gastric injury by *Helicobacter pylori* VacA toxin. *Helicobacter* 2005; **10**: 231-239
- Marchetti M, Aricò B, Burrone D, Figura N, Rappuoli R, Ghiara P. Development of a mouse model of *Helicobacter pylori* infection that mimics human disease. *Science* 1995; **267**: 1655-1658
- Manetti R, Massari P, Burrone D, de Bernard M, Marchini A, Olivieri R, Papini E, Montecucco C, Rappuoli R, Telford JL. *Helicobacter pylori* cytotoxin: importance of native conformation for induction of neutralizing antibodies. *Infect Immun* 1995; **63**: 4476-4480
- Papini E, de Bernard M, Milia E, Bugnoli M, Zerial M, Rappuoli R, Montecucco C. Cellular vacuoles induced by *Helicobacter pylori* originate from late endosomal compartments. *Proc Natl Acad Sci USA* 1994; **91**: 9720-9724
- Dixon MF, Genta RM, Yardley JH, Correa P. Classification and grading of gastritis. The updated Sydney System. International Workshop on the Histopathology of Gastritis, Houston 1994. *Am J Surg Pathol* 1996; **20**: 1161-1181
- Rossi G, Ruggiero P, Peppoloni S, Pancotto L, Fortuna D, Lauretti L, Volpini G, Mancianti S, Corazza M, Taccini E, Di Pisa F, Rappuoli R, Del Giudice G. Therapeutic vaccination against *Helicobacter pylori* in the beagle dog experimental model: safety, immunogenicity, and efficacy. *Infect Immun* 2004; **72**: 3252-3259
- Mahady GB, Pendland SL, Chadwick LR. Resveratrol and red wine extracts inhibit the growth of CagA+ strains of *Helicobacter pylori* *in vitro*. *Am J Gastroenterol* 2003; **98**: 1440-1441
- Matsubara S, Shibata H, Ishikawa F, Yokokura T, Takahashi M, Sugimura T, Wakabayashi K. Suppression of *Helicobacter*

- pylori*-induced gastritis by green tea extract in Mongolian gerbils. *Biochem Biophys Res Commun* 2003; **310**: 715-719
- 22 **Salama NR**, Otto G, Tompkins L, Falkow S. Vacuolating cytotoxin of *Helicobacter pylori* plays a role during colonization in a mouse model of infection. *Infect Immun* 2001; **69**: 730-736
- 23 **van Doorn NE**, Namavar F, Sparrius M, Stoof J, van Rees EP, van Doorn LJ, Vandenbroucke-Grauls CM. *Helicobacter pylori*-associated gastritis in mice is host and strain specific. *Infect Immun* 1999; **67**: 3040-3046
- 24 **Lu H**, Yamaoka Y, Graham DY. *Helicobacter pylori* virulence factors: facts and fantasies. *Curr Opin Gastroenterol* 2005; **21**: 653-659
- 25 **Del Giudice G**, Covacci A, Telford JL, Montecucco C, Rappuoli R. The design of vaccines against *Helicobacter pylori* and their development. *Annu Rev Immunol* 2001; **19**: 523-563
- 26 **Rad R**, Dossumbekova A, Neu B, Lang R, Bauer S, Saur D, Gerhard M, Prinz C. Cytokine gene polymorphisms influence mucosal cytokine expression, gastric inflammation, and host specific colonisation during *Helicobacter pylori* infection. *Gut* 2004; **53**: 1082-1089
- 27 **Hwang IR**, Kodama T, Kikuchi S, Sakai K, Peterson LE, Graham DY, Yamaoka Y. Effect of interleukin 1 polymorphisms on gastric mucosal interleukin 1beta production in *Helicobacter pylori* infection. *Gastroenterology* 2002; **123**: 1793-1803
- 28 **Kelley JR**, Duggan JM. Gastric cancer epidemiology and risk factors. *J Clin Epidemiol* 2003; **56**: 1-9
- 29 **Simán JH**, Forsgren A, Berglund G, Florén CH. Tobacco smoking increases the risk for gastric adenocarcinoma among *Helicobacter pylori*-infected individuals. *Scand J Gastroenterol* 2001; **36**: 208-213
- 30 **de Bernard M**, Cappon A, Del Giudice G, Rappuoli R, Montecucco C. The multiple cellular activities of the VacA cytotoxin of *Helicobacter pylori*. *Int J Med Microbiol* 2004; **293**: 589-597
- 31 **Wada A**, Yamasaki E, Hirayama T. *Helicobacter pylori* vacuolating cytotoxin, VacA, is responsible for gastric ulceration. *J Biochem* 2004; **136**: 741-746

S- Editor Wang GP L- Editor Luzte M E- Editor Bi L