



Low interleukin-10 level indicates a good prognosis in *Salmonella enterica* serovar typhimurium-induced pediatric hemophagocytic lymphohistiocytosis: A case report

Yuan-Yuan Chen, Xiang-Zhi Xu, Xiao-Jun Xu

Specialty type: Medicine, research and experimental

Provenance and peer review: Unsolicited article; Externally peer reviewed.

Peer-review model: Single blind

Peer-review report's scientific quality classification

Grade A (Excellent): 0
Grade B (Very good): 0
Grade C (Good): C
Grade D (Fair): 0
Grade E (Poor): 0

P-Reviewer: Polat SE, Turkey

Received: October 30, 2023

Peer-review started: October 30, 2023

First decision: December 29, 2023

Revised: January 10, 2024

Accepted: March 5, 2024

Article in press: March 5, 2024

Published online: March 26, 2024



Yuan-Yuan Chen, Xiao-Jun Xu, Division/Center of Pediatric Hematology Oncology, Children's Hospital, Zhejiang University School of Medicine, Hangzhou 310003, Zhejiang Province, China

Xiang-Zhi Xu, Pediatric Intensive Care Unit, Children's Hospital of Zhejiang University School of Medicine, Hangzhou 310003, Zhejiang Province, China

Corresponding author: Xiao-Jun Xu, MD, Chief Doctor, Division/Center of Pediatric Hematology Oncology, Children's Hospital of Zhejiang University School of Medicine, No. 57 Zhugan Road, Hangzhou 310003, Zhejiang Province, China. xuxiaojun@zju.edu.cn

Abstract

BACKGROUND

Secondary hemophagocytic lymphohistiocytosis (sHLH) triggered by *Salmonella enterica* serovar Typhimurium is rare in pediatric patients. There is no consensus on how to treat *S. typhimurium*-triggered sHLH.

CASE SUMMARY

A 9-year-old boy with intermittent fever for 3 d presented to our hospital with positive results for *S. typhimurium*, human rhinovirus, and *Mycoplasma pneumoniae* infections. At the time of admission to our institution, the patient's T helper 1/T helper 2 cytokine levels were 326 pg/mL for interleukin 6 (IL-6), 9.1 pg/mL for IL-10, and 246.7 pg/mL for interferon-gamma (IFN- γ), for which the ratio of IL-10 to IFN- γ was 0.04. In this study, the patient received meropenem, linezolid, and cefoperazone/sulbactam in combination with high-dose methylprednisolone therapy (10 mg/kg/d for 3 d) and antishock supportive treatment twice. After careful evaluation, this patient did not receive HLH chemotherapy and recovered well.

CONCLUSION

S. Typhimurium infection-triggered sHLH patient had a ratio of IL-10 to IFN- γ \leq 1.33, an IL-10 concentration \leq 10.0 pg/mL, and/or an IFN- γ concentration \leq 225 pg/mL at admission. Early antimicrobial and supportive treatment was sufficient, and the HLH-94/2004 protocol was not necessary under these conditions.

Key Words: Hemophagocytic lymphohistiocytosis; Cytokine pattern; Interferon gamma;

Interleukin-10; *Salmonella enterica* serovar Typhimurium; Case report

©The Author(s) 2024. Published by Baishideng Publishing Group Inc. All rights reserved.

Core Tip: *Salmonella enterica* serovar Typhimurium is one kind of pathogen that can trigger secondary hemophagocytic lymphohistiocytosis (sHLH). There is no consensus on how to treat *S. Typhimurium*-triggered sHLH. Compared to controls, an *S. Typhimurium*-triggered sHLH patient showed a ratio of interleukin-10 (IL-10) to interferon-gamma (IFN- γ) ≤ 1.33 , an IL-10 concentration ≤ 10.0 pg/mL, and/or IFN- γ concentration ≤ 225 pg/mL on admission. The HLH-94/2004 protocol was not necessary, and early antimicrobial and supportive treatment was sufficient.

Citation: Chen YY, Xu XZ, Xu XJ. Low interleukin-10 level indicates a good prognosis in *Salmonella enterica* serovar typhimurium-induced pediatric hemophagocytic lymphohistiocytosis: A case report. *World J Clin Cases* 2024; 12(9): 1660-1668

URL: <https://www.wjgnet.com/2307-8960/full/v12/i9/1660.htm>

DOI: <https://dx.doi.org/10.12998/wjcc.v12.i9.1660>

INTRODUCTION

Hemophagocytic lymphohistiocytosis (HLH) is a syndrome composed of clinical findings such as fever, hepatosplenomegaly, cytopenias, hypertriglyceridemia, hypofibrinogenemia, hemophagocytosis in the bone marrow or spleen or lymph nodes, low or absent natural killer cell activity, and elevated levels of serum ferritin (SF) and soluble cluster of differentiation 25 (CD25)[1]. HLH comprises two conditions: primary HLH (pHLH) and secondary HLH (sHLH). pHLH occurs in the presence of an underlying predisposing genetic defect in the cytolytic pathway, whereas sHLH is acquired in the setting of an infectious, malignant, or autoimmune cause without genetic defects[2].

sHLH can be triggered by the Epstein-Barr virus (EBV)[3], cytomegalovirus[4], and *Salmonella enterica* serovar typhimurium[5,6], etc. *S. typhimurium* is a Gram-negative bacterium that depends on an essential inflammatory response to colonize the intestinal tract, causing self-limiting gastroenteritis in humans[7,8]. *S. typhimurium* alone, in some animal models, could be an independent trigger of sHLH[9]. Some pediatric patients infected with *S. typhimurium* progress to sHLH[10]. Cytokine storm syndrome is a life-threatening systemic inflammatory state characterized by elevated levels of circulating cytokines and immune cell hyperactivation[11]. In our previous study, we reported a specific cytokine pattern for HLH: interleukin 10 (IL-10) > 60 pg/mL, interferon gamma (IFN- γ) > 75 pg/mL, and IL-6 > 51.1 pg/mL[12]. Patients with a ratio of IL-10 to IFN- γ > 1.33 combined with IFN- γ ≤ 225 pg/mL were considered to have pHLH, whereas sHLH patients usually had a ratio of IL-10 to IFN- γ ≤ 1.33 [13]. Moreover, an IL-10 concentration ≥ 456 pg/mL was an independent prognostic factor for early death[14].

In this study, a patient who developed HLH due to *S. typhimurium* infection is described. His IL-10 concentration was 9.1 pg/mL, and the ratio of IL-10 to IFN- γ was 0.04 at admission. Seven patients infected with *S. typhimurium* and three EBV-HLH patients were included as controls. The HLH patient did not receive chemotherapy, and after anti-infection therapy and supportive treatments, he recovered very well.

CASE PRESENTATION

Chief complaints

A 9-year-old Chinese boy was admitted to the hospital due to an intermittent fever for 3 d.

History of present illness

Approximately 3 d before admission, the patient presented with a fever of 39.3 °C without any inductive or provocative factors, and his complete blood count (CBC) showed pancytopenia. His white blood cell count was 2.33×10^9 /L, his hemoglobin level was 96 g/L, and his platelet was 25×10^9 /L. He did not have any symptoms of cough, vomiting, or diarrhea.

History of past illness

The patient had no relevant medical history.

Personal and family history

There were no special features in the patient's background or family history, and there was no consanguinity.

Physical examination

At the time of admission, the patient had an intermittent fever for 3 d. His abdomen was distended, and there was no

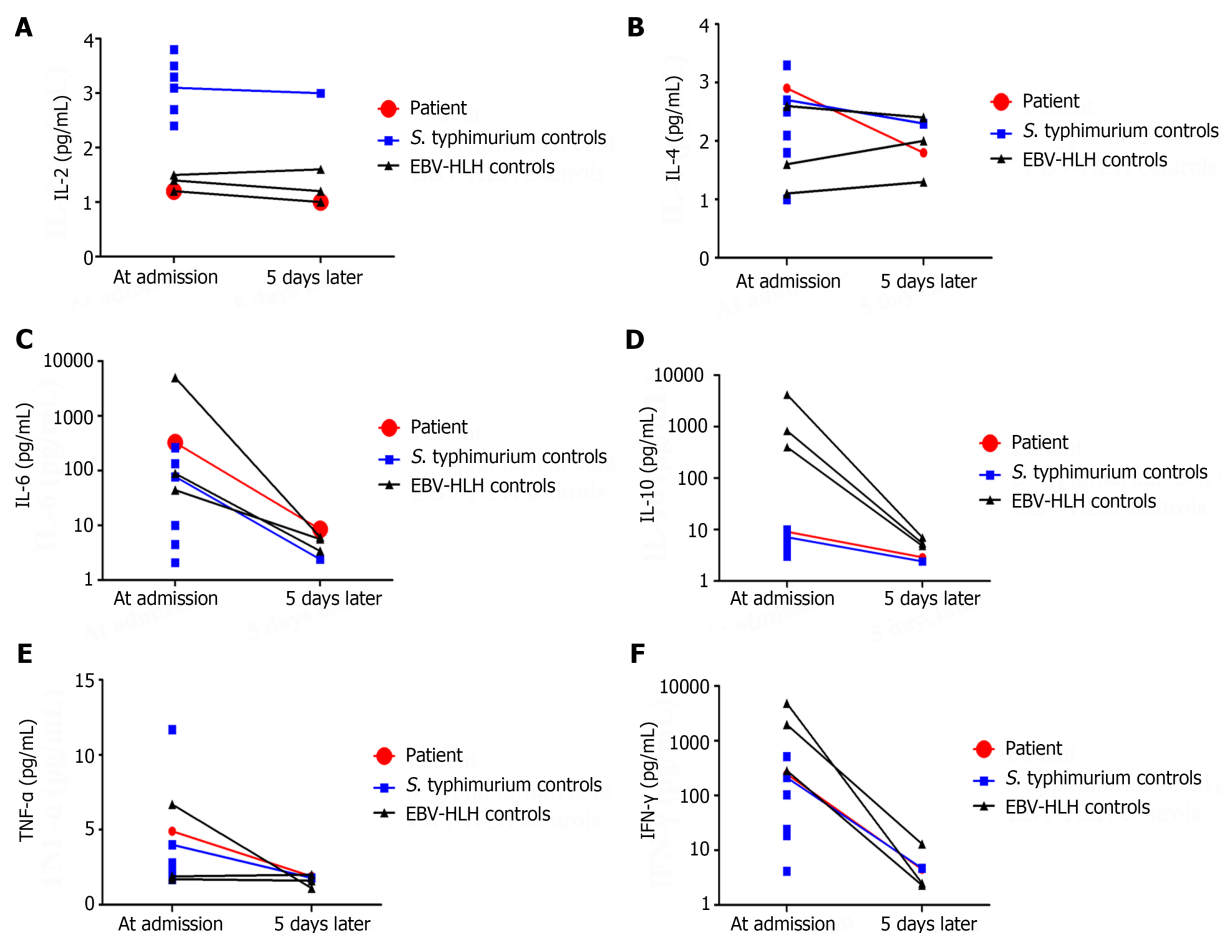


Figure 1 T helper 1/T helper 2 cytokine levels at admission and 5 d later. A: Interleukin 2 (IL-2) is shown for this patient, 7 *Salmonella enterica* serovar *typhimurium* (*S. typhimurium*)-infected controls, and 3 Epstein-Barr virus-hemophagocytic lymphohistiocytosis (EBV-HLH) controls; B: IL-4 is shown for the patient and controls; C: IL-6 is shown for the patient and controls; D: IL-10 is shown for the patient and controls; E: Tumor necrosis factor- α (TNF- α) is shown for the patient and controls; F: Interferon- γ (IFN- γ) is shown for the patient and controls.

enlargement of the spleen or liver below his costal margins. No palpable lymphadenopathy was observed. Physiological reflexes were normal. The Bacillus Calmette-Guerin vaccination scar was normal, and no rashes were observed on his skin. The vital signs of the patient during hospitalization are shown in Table 1.

Laboratory examinations

His soluble CD25 concentration was 2646.9 pg/mL. Bone marrow biopsy revealed some hemophagocytic histiocytes and a decreased number of megakaryocytes. T helper 1/T helper 2 (Th1/Th2) cytokine levels, including those of IL-2, IL-4, IL-6, IL-10, tumor necrosis factor- α (TNF- α), and IFN- γ , were quantitatively determined with a human Th1/Th2 Cytokine Kit II (BD Biosciences, San Jose, CA, United States) during the course of the disease (Figures 1 and 2). The results of the CBC comparison (Figure 3), C-reactive protein, procalcitonin, fibrinogen, triglyceride, and SF levels are shown in Table 1. The other laboratory findings are shown in Table 2.

Imaging examinations

B-ultrasound of the abdomen and chest computed tomography showed no abnormalities.

FINAL DIAGNOSIS

The final diagnosis was sHLH due to *S. typhimurium* infection. The diagnosis of HLH was established on the basis of fever, cytopenia, hypofibrinogenemia, and hemophagocytosis in the bone marrow; elevated levels of SF; and increased soluble CD25, which fulfilled more than five criteria. The diagnosis of *S. typhimurium* infection was confirmed by blood culture.

Table 1 Clinical indexes from admission to discharge

| Testing date | WBC as × 10 ⁹ /L | ALC as × 10 ⁹ /L | ANC as × 10 ⁹ /L | Hb in g/L | PLT as × 10 ⁹ /L | CRP in mg/L | PCT in ng/mL | Fib in g/L | TG in mmol/L | SF in mg/L | T in C | HR, times/min | RR, times/min | BP in mmHg | SpO ₂ , % |
|--------------------|-----------------------------|-----------------------------|-----------------------------|-----------|-----------------------------|-------------|--------------|------------|--------------|------------|--------|---------------|---------------|------------|----------------------|
| September 25, 2022 | 2.33 | 0.57 | 1.63 | 96 | 25 | 10.88 | 2.32 | 2.23 | 1.03 | > 1500 | 39.4 | 128 | 20 | 78/40 | > 95% |
| September 26, 2022 | 2.74 | 0.83 | 1.8 | 109 | 36 | 11.52 | 2.8 | 1.93 | 1.39 | > 1500 | 35.6 | 16 | 30 | 91/70 | > 95% |
| September 27, 2022 | 2.75 | 0.76 | 1.91 | 98 | 26 | 6.2 | 2.6 | NT | NT | NT | 35.5 | 78 | 20 | 103/67 | > 95% |
| September 28, 2022 | 2.14 | 0.82 | 1.2 | 87 | 76 | 2.69 | NT | NT | NT | 1835.0 | 35.8 | 74 | 18 | 105/73 | > 95% |
| September 29, 2022 | 2.51 | 1.08 | 1.23 | 89 | 70 | 1.01 | NT | 1.26 | NT | NT | 36.0 | 77 | 19 | 100/75 | > 95% |
| September 30, 2022 | 2.81 | 0.97 | 1.71 | 92 | 58 | 0.48 | NT | 1.12 | 1.7 | NT | 36.0 | 102 | 18 | 83/54 | > 95% |
| October 2, 2022 | 4.82 | 3.03 | 1.58 | 87 | 37 | 0.64 | NT | 1.59 | NT | 725.2 | 37.3 | 86 | 20 | 86/60 | > 95% |
| October 3, 2022 | 3.93 | 2.23 | 1.63 | 81 | 38 | 0.38 | 0.291 | NT | NT | NT | 37.1 | 72 | 22 | 72/44 | > 95% |
| October 4, 2022 | 6.31 | 4.73 | 1.35 | 84 | 29 | 0.5 | NT | NT | NT | NT | 38.4 | 123 | 23 | 90/58 | > 95% |
| October 5, 2022 | 4.11 | 2.72 | 1.19 | 77 | 31 | 0.87 | NT | NT | NT | NT | 37.9 | 112 | 22 | 82/57 | > 95% |
| October 6, 2022 | 4.04 | 2.94 | 0.94 | 74 | 50 | 1.1 | 0.118 | NT | NT | NT | 38.6 | 154 | 28 | 87/56 | > 95% |
| October 7, 2022 | 3.67 | 2.78 | 0.68 | 77 | 50 | 1.79 | NT | NT | NT | NT | 37.8 | 120 | 16 | 97/69 | > 95% |
| October 8, 2022 | 3.73 | 2.99 | 0.55 | 75 | 50 | 1.37 | NT | 3.44 | NT | 384.5 | 37.6 | 136 | 22 | 75/51 | > 95% |
| October 9, 2022 | 3.53 | 2.36 | 0.92 | 105 | 50 | 0.92 | NT | NT | NT | NT | 37.6 | 105 | 23 | 108/76 | > 95% |
| October 10, 2022 | 3.98 | 3.05 | 0.69 | 93 | 48 | 0.9 | NT | NT | NT | 332.5 | 37.6 | 95 | 24 | 111/77 | > 95% |
| October 11, 2022 | 4.78 | 3.64 | 0.88 | 99 | 56 | 1.3 | 0.096 | NT | NT | NT | 37.3 | 131 | 20 | 128/84 | > 95% |
| October 12, 2022 | 5.89 | 4.78 | 0.73 | 98 | 54 | 1.08 | NT | NT | 1.11 | NT | 37.2 | 104 | 26 | 84/59 | > 95% |

| | | | | | | | | | | | | | | | |
|------------------|------|------|------|-----|----|------|----|----|----|-----|------|-----|----|-------|-------|
| October 14, 2022 | 5.1 | 4.05 | 0.66 | 97 | 56 | 1.14 | NT | NT | NT | NT | 37.2 | 117 | 22 | 97/60 | > 95% |
| October 15, 2022 | 6.06 | 4.82 | 0.77 | 99 | 63 | 0.41 | NT | NT | NT | NT | 36.3 | 105 | 20 | 90/62 | > 95% |
| October 16, 2022 | 7.05 | 5.69 | 0.88 | 101 | 74 | 0.41 | NT | NT | NT | 346 | 36.5 | 120 | 23 | 97/67 | > 95% |

ALC: Absolute lymphocyte count; ANC: Absolute neutrophil count; BP: Blood pressure; CRP: C-reactive protein; Fib: Fibrinogen; Hb: Hemoglobin; HR: Heart rate; NT: Not tested; PCT: Procalcitonin; PLT: Platelet count; RR: Respiratory rate; SF: Serum ferritin; SpO₂: Pulse oxygen saturation; T: Temperature; TG: Triglyceride; WBC: White blood cell count.

TREATMENT

From September 25, 2022 to September 26, 2022, this patient received meropenem and linezolid anti-infection therapy. From September 26, 2022 to September 28, 2022, the patient received meropenem and high-dose methylprednisolone therapy (180 mg/d, body weight of 18.8 kg). From September 28, 2022 to October 11, 2022, the patient received cefoperazone/sulbactam as anti-infection therapy, and *S. typhimurium* was sensitive to the treatment. During the inpatient period, this boy experienced two episodes of shock, one on September 25, 2022 and one on October 3, 2022, during which time his blood pressure decreased to 78/40 mmHg and 72/44 mmHg, respectively. Both episodes of shock occurred after the patient developed a fever, and his body temperature eventually returned to normal. After antishock therapy, his vital signs stabilized. From October 11, 2022 to October 17, 2022, this patient received meropenem therapy again.

OUTCOME AND FOLLOW-UP

After careful evaluation, the patient did not receive HLH chemotherapy during the whole disease course and was discharged on October 17, 2022. During the nonhospitalization period, he was followed up by telephone for more than 1 year and recovered very well.

DISCUSSION

Currently, dexamethasone, etoposide, cyclosporine A, and ruxolitinib are the main choices for HLH treatment[15]. Reliable laboratory markers that can differentiate subtypes of HLH at an early stage would provide tremendous help for treatment. Several researchers have shown that elevated IL-10 levels are associated with a poor prognosis in HLH[16,17]. In this study, we examined 8 children infected with *S. typhimurium*, and only 1 of them fulfilled the diagnostic criteria for HLH. The IL-10 levels in this *S. typhimurium*-HLH patient and the 7 controls with *S. typhimurium* infection were lower than 10.0 pg/mL, while the levels of IL-10 in the 3 EBV-HLH patients were all greater than 10.0 pg/mL. In our clinical practice, different cytokine patterns for differentiating various HLH subtypes can be obtained within 5 h, and 88 patients with IFN- γ levels \leq 225 pg/mL and a ratio of IL-10 to IFN- γ \leq 1.33 have the best outcome, showing that this subtype has

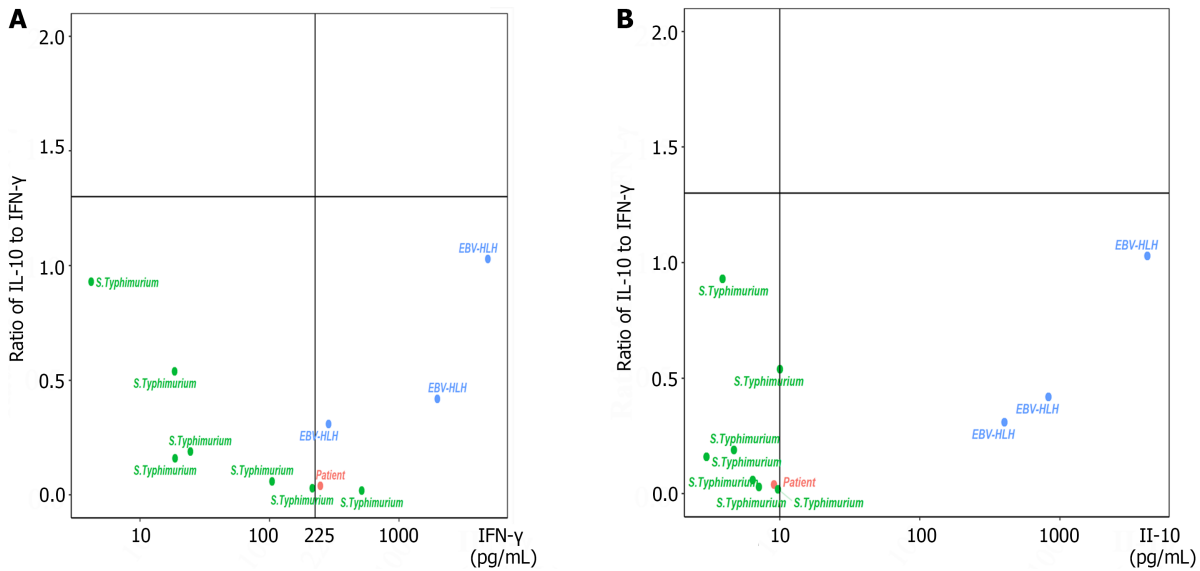


Figure 2 Four-quadrant models for differentiating secondary hemophagocytic lymphohistiocytosis patients with different features. A: Distribution of the patients, 7 controls infected with *Salmonella enteric* serovar *typhimurium* (*S. typhimurium*), and 3 Epstein-Barr virus-hemophagocytic lymphohistiocytosis (EBV-HLH) patients according to a four-quadrant diagram based on the ratio of interleukin-10 (IL-10) to interferon gamma (IFN-γ) > 1.33 or ≤ 1.33 and IFN-γ level > 225 pg/mL or ≤ 225 pg/mL; B: Distribution of the patients, 7 controls infected with *S. typhimurium*, and 3 EBV-HLH patients according to a four-quadrant diagram based on the ratio of IL-10 to IFN-γ > 1.33 or ≤ 1.33 and IL-10 level > 10 pg/mL or ≤ 10 pg/mL.

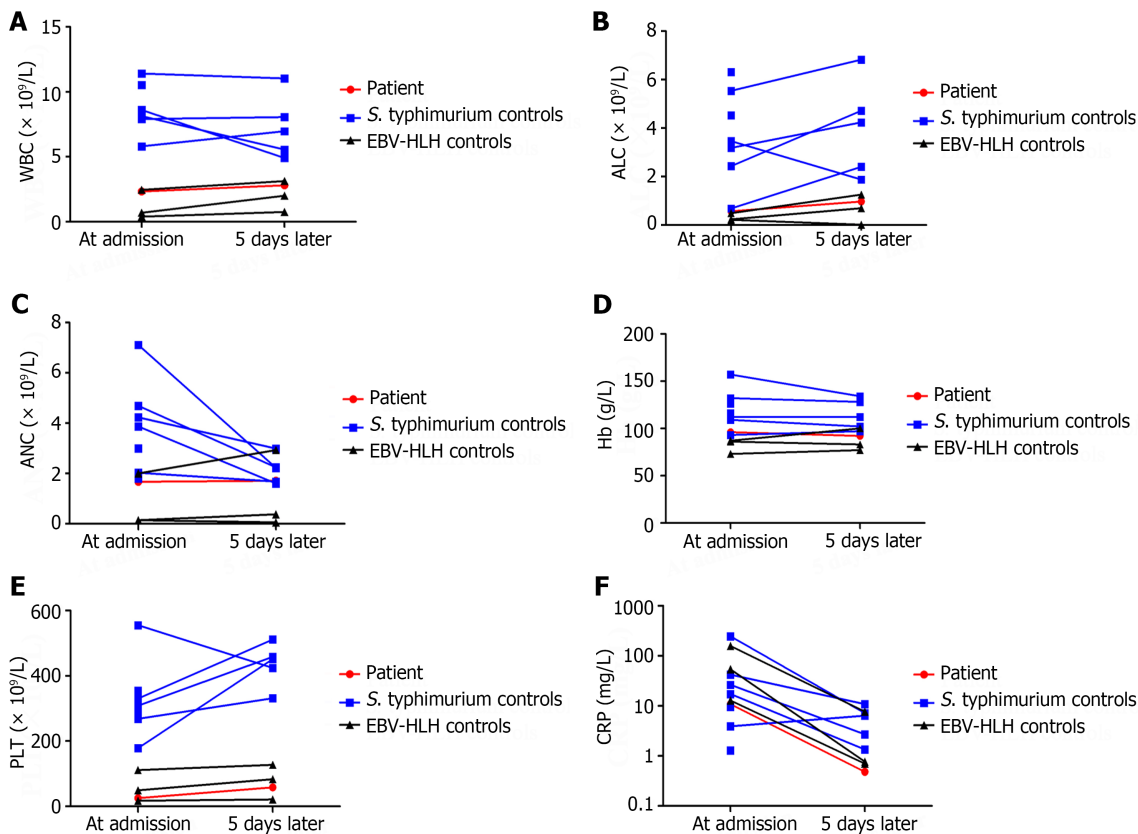


Figure 3 Complete blood count at admission and 5 d later. A: White blood cell (WBC) count of the patient, 7 *Salmonella enteric* serovar *typhimurium* (*S. typhimurium*)-infected controls, and 3 Epstein-Barr virus-hemophagocytic lymphohistiocytosis (EBV-HLH) controls; B: Absolute lymphocyte count (ALC) of the patient and controls; C: Absolute neutrophil count (ANC) of the patient and controls; D: Hemoglobin (Hb) of the patient and controls; E: Platelet (PLT) count of the patient and controls; F: C-reactive protein (CRP) of the patient and controls.

Table 2 Results of laboratory examinations after admission

| Testing date | Laboratory examination items | Results |
|--------------------|---|---|
| September 26, 2022 | Nucleic acid detection of 13 pathogens from nasopharyngeal swab | Human Rhino Virus and Mycoplasma Pneumoniae were positive, and others were all negative |
| September 26, 2022 | T-cell spot of tuberculosis assay | Negative |
| September 26, 2022 | EBV antibodies | EBVCA-IgM was 1.26 U/mL, EBVCA-IgG was 10.9 U/mL, EBNA-IgG was more than 600 U/mL, EBEA-IgG was negative, and EBEA-IgM was 0.06 COI |
| September 26, 2022 | EBV-DNA | 0 copies/mL |
| September 28, 2022 | Blood culture | <i>S. typhimurium</i> was positive |
| September 30, 2022 | Widal test | FDSO, FDSH, FDSC, FDSB, and FDSC were all less than 1:40 |
| October 1, 2022 | Stool culture | Negative |
| October 1, 2022 | Cerebrospinal fluid culture | Negative |
| October 4, 2022 | Blood culture for the second time | Negative |
| October 7, 2022 | Urine culture | Negative |
| October 7, 2022 | Sputum culture | Negative |
| October 11, 2022 | Bone marrow culture | Negative |
| October 17, 2022 | Widal test for the second time | FDSO and FDSH were both 1:40, while FDSC, FDSB, and FDSC were less than 1:40 |

COI: Cut-off index; EBEA: EBV early antigen; EBNA: EBV nuclear antigen; EBV: Epstein-Barr virus; EBVCA: EBV viral capsid antigen; FDSB: Antigen of *Salmonella paratyphi* B; FDSC: Antigen of *Salmonella paratyphi* C; FDSO: O-antigen of *S. typhimurium*; FDSH: H-antigen of *S. typhimurium*; FDSC: Antigen of *Salmonella paratyphi* A; IgG: Immunoglobulin G; IgM: Immunoglobulin M.

the best outcome of all HLH subtypes[13], which was verified by this study.

There is no consensus on how to treat *S. typhimurium*-triggered sHLH, and early intervention is needed to improve outcomes in patients with HLH[18]. Most of the current research is empirical, and the decision-making process is relevant to the time point at which positive culture results are obtained and based on the clinician's experience. Several researchers have shown that antimicrobial and supportive treatment alone are effective[5,19-23]. However, many researchers have used both antimicrobial treatment and the HLH protocol to treat sHLH triggered by *Salmonella* infections[6,10,24]. In this study, after careful evaluation, our patient did not receive HLH chemotherapy during the whole disease course. After receiving meropenem, linezolid, and cefoperazone/sulbactam for anti-infection therapy combined with high-dose methylprednisolone therapy, the patient recovered very well.

This study had several limitations. First, it was impossible to precisely distinguish pHLH from sHLH, as this patient did not undergo pHLH-related gene examinations during the study period. Second, the 7 controls infected with *S. typhimurium* recovered well, and only some agreed to undergo a second recheck of their cytokines and CBC, which led to missing data. Finally, only 1 patient infected with *S. typhimurium* progressed to sHLH, and we could not perform a cohort analysis of specific cytokine patterns.

CONCLUSION

In summary, if a *Salmonella*-triggered sHLH patient has a ratio of IL-10 to IFN- γ ≤ 1.33 , an IL-10 concentration ≤ 10.0 pg/mL, and/or an IFN- γ concentration ≤ 225 pg/mL at admission, early antimicrobial and supportive treatment may be sufficient. Eight weeks of dexamethasone treatment and the HLH-94/2004 protocol are not necessary under these conditions.

FOOTNOTES

Author contributions: Xu XJ was the principal investigator and takes primary responsibility for the manuscript; Chen YY and Xu XZ acquired and analyzed the data; Chen YY drafted the manuscript; Xu XJ and Chen YY revised the manuscript; All authors approved the final version to be published.

Supported by Zhejiang Province Health and Wellness Science and Technology Program in 2022, China, No. 2022RC202.

Informed consent statement: Written informed consent was obtained from the patient's guardian for publication of this case report and

accompanying images.

Conflict-of-interest statement: The authors have no conflicts of interest to declare.

CARE Checklist (2016) statement: The authors have read the CARE Checklist (2016), and the manuscript was prepared and revised according to the CARE Checklist (2016).

Open-Access: This article is an open-access article that was selected by an in-house editor and fully peer-reviewed by external reviewers. It is distributed in accordance with the Creative Commons Attribution NonCommercial (CC BY-NC 4.0) license, which permits others to distribute, remix, adapt, build upon this work non-commercially, and license their derivative works on different terms, provided the original work is properly cited and the use is non-commercial. See: <https://creativecommons.org/licenses/by-nc/4.0/>

Country/Territory of origin: China

ORCID number: Yuan-Yuan Chen 0000-0002-8206-1979; Xiang-Zhi Xu 0009-0004-1727-9068; Xiao-Jun Xu 0000-0003-1388-2535.

S-Editor: Liu H

L-Editor: Filipodia

P-Editor: Cai YX

REFERENCES

- Henter JI, Horne A, Aricó M, Egeler RM, Filipovich AH, Imashuku S, Ladisch S, McClain K, Webb D, Winiarski J, Janka G. HLH-2004: Diagnostic and therapeutic guidelines for hemophagocytic lymphohistiocytosis. *Pediatr Blood Cancer* 2007; **48**: 124-131 [PMID: 16937360 DOI: 10.1002/pbc.21039]
- Kanegane H, Noguchi A, Yamada Y, Yasumi T. Rare diseases presenting with hemophagocytic lymphohistiocytosis. *Pediatr Int* 2023; **65**: e15516 [PMID: 36843347 DOI: 10.1111/ped.15516]
- Konishi S, Ono R, Tanaka M, Imadome KI, Nakazawa Y, Kanegane H, Hasegawa D. Cytokine-based disease monitoring in refractory HLH with primary EBV infection. *Pediatr Int* 2023; **65**: e15590 [PMID: 37615380 DOI: 10.1111/ped.15590]
- Chevalier K, Schmidt J, Coppo P, Galicier L, Noël N, Lambotte O. Hemophagocytic Lymphohistiocytosis Associated With Cytomegalovirus Infection: 5 Cases and a Systematic Review of the Literature. *Clin Infect Dis* 2023; **76**: 351-358 [PMID: 35974465 DOI: 10.1093/cid/ciac649]
- Arora N, Singla N, Jain A, Sharma P, Sharma N. Secondary haemophagocytic lymphohistiocytosis (HLH) triggered by Salmonella typhi. *Postgrad Med J* 2022; **98**: e29 [PMID: 37066570 DOI: 10.1136/postgradmedj-2021-139999]
- Şahin Yaşar A, Karaman K, Geylan H, Çetin M, Güven B, Öner AF. Typhoid Fever Accompanied With Hematopoietic Lymphohistiocytosis and Rhabdomyolysis in a Refugee Child. *J Pediatr Hematol Oncol* 2019; **41**: e233-e234 [PMID: 30608489 DOI: 10.1097/MPH.0000000000001400]
- Badie F, Ghandali M, Tabatabaei SA, Safari M, Khorshidi A, Shayestehpour M, Mahjoubin-Tehran M, Morshedi K, Jalili A, Tajiknia V, Hamblin MR, Mirzaei H. Use of Salmonella Bacteria in Cancer Therapy: Direct, Drug Delivery and Combination Approaches. *Front Oncol* 2021; **11**: 624759 [PMID: 33738260 DOI: 10.3389/fonc.2021.624759]
- Galán JE. Salmonella Typhimurium and inflammation: a pathogen-centric affair. *Nat Rev Microbiol* 2021; **19**: 716-725 [PMID: 34012042 DOI: 10.1038/s41579-021-00561-4]
- Brown DE, McCoy MW, Pilonieta MC, Nix RN, Detweiler CS. Chronic murine typhoid fever is a natural model of secondary hemophagocytic lymphohistiocytosis. *PLoS One* 2010; **5**: e9441 [PMID: 20195482 DOI: 10.1371/journal.pone.0009441]
- Iwasaki T, Hara H, Takahashi-Igari M, Matsuda Y, Imai H. Probable hemophagocytic lymphohistiocytosis by extensively drug-resistant Salmonella Typhi. *Pediatr Int* 2022; **64**: e14695 [PMID: 34582121 DOI: 10.1111/ped.14695]
- Cron RQ, Goyal G, Chatham WW. Cytokine Storm Syndrome. *Annu Rev Med* 2023; **74**: 321-337 [PMID: 36228171 DOI: 10.1146/annurev-med-042921-112837]
- Xu XJ, Tang YM, Song H, Yang SL, Xu WQ, Zhao N, Shi SW, Shen HP, Mao JQ, Zhang LY, Pan BH. Diagnostic accuracy of a specific cytokine pattern in hemophagocytic lymphohistiocytosis in children. *J Pediatr* 2012; **160**: 984-90.e1 [PMID: 22226576 DOI: 10.1016/j.jpeds.2011.11.046]
- Xu XJ, Luo ZB, Song H, Xu WQ, Henter JI, Zhao N, Wu MH, Tang YM. Simple Evaluation of Clinical Situation and Subtypes of Pediatric Hemophagocytic Lymphohistiocytosis by Cytokine Patterns. *Front Immunol* 2022; **13**: 850443 [PMID: 35296096 DOI: 10.3389/fimmu.2022.850443]
- Luo ZB, Chen YY, Xu XJ, Zhao N, Tang YM. Prognostic factors of early death in children with hemophagocytic lymphohistiocytosis. *Cytokine* 2017; **97**: 80-85 [PMID: 28582648 DOI: 10.1016/j.cyto.2017.03.013]
- Yan WL, Yang SL, Zhao FY, Xu XJ. Ruxolitinib is an alternative to etoposide for patient with hemophagocytic lymphohistiocytosis complicated by acute renal injury: A case report. *J Oncol Pharm Pract* 2022; **28**: 222-227 [PMID: 34074166 DOI: 10.1177/10781552211020821]
- Hao L, Ren J, Zhu Y, Ma Y, Pan J, Yang L. Elevated Interleukin-10 Levels Are Associated with Low Platelet Count and Poor Prognosis in 90 Adult Patients with Hemophagocytic Lymphohistiocytosis. *Int Arch Allergy Immunol* 2023; **184**: 400-408 [PMID: 36634629 DOI: 10.1159/000528349]
- Zhou Y, Kong F, Wang S, Yu M, Xu Y, Kang J, Tu S, Li F. Increased levels of serum interleukin-10 are associated with poor outcome in adult hemophagocytic lymphohistiocytosis patients. *Orphanet J Rare Dis* 2021; **16**: 347 [PMID: 34348761 DOI: 10.1186/s13023-021-01973-4]
- Rubio-Perez J, Rodríguez-Pérez ÁR, Díaz-Blázquez M, Moreno-García V, Dómine-Gómez M. Treatment-related hemophagocytic lymphohistiocytosis due to atezolizumab: a case report and review of the literature. *J Med Case Rep* 2022; **16**: 365 [PMID: 36195892 DOI: 10.1186/s13256-022-03585-3]

- 19 **Uribe-Londono J**, Castano-Jaramillo LM, Penagos-Tascon L, Restrepo-Gouzy A, Escobar-Gonzalez AF. Hemophagocytic Lymphohistiocytosis Associated with Salmonella typhi Infection in a Child: A Case Report with Review of Literature. *Case Rep Pediatr* 2018; **2018**: 6236270 [PMID: 30595935 DOI: 10.1155/2018/6236270]
- 20 **Çamlar SA**, Kır M, Aydoğan C, Bengo ŞY, Türkmen MA, Soylu A, Kavukçu S. Salmonella glomerulonephritis and haemophagocytic lymphohistiocytosis in an adolescent. *Türk Pediatri Ars* 2016; **51**: 173-175 [PMID: 27738405 DOI: 10.5152/TurkPediatriArs.2016.3956]
- 21 **Caksen H**, Akbayram S, Oner AF, Kösem M, Tuncer O, Atas B, Odabaş D. A case of typhoid fever associated with hemophagocytic syndrome. *J Emerg Med* 2003; **25**: 321-322 [PMID: 14585463 DOI: 10.1016/s0736-4679(03)00212-9]
- 22 **Abbas A**, Raza M, Majid A, Khalid Y, Bin Waqar SH. Infection-associated Hemophagocytic Lymphohistiocytosis: An Unusual Clinical Masquerader. *Cureus* 2018; **10**: e2472 [PMID: 29900092 DOI: 10.7759/cureus.2472]
- 23 **Non LR**, Patel R, Esmaeeli A, Despotovic V. Typhoid Fever Complicated by Hemophagocytic Lymphohistiocytosis and Rhabdomyolysis. *Am J Trop Med Hyg* 2015; **93**: 1068-1069 [PMID: 26324725 DOI: 10.4269/ajtmh.15-0385]
- 24 **Dange NS**, Sawant V, Dash L, Kondekar AS. A Rare Case of Salmonella meningitis and Hemophagocytic Lymphohistiocytosis. *J Glob Infect Dis* 2021; **13**: 100-102 [PMID: 34194179 DOI: 10.4103/jgid.jgid_224_20]



Published by **Baishideng Publishing Group Inc**
7041 Koll Center Parkway, Suite 160, Pleasanton, CA 94566, USA

Telephone: +1-925-3991568

E-mail: office@baishideng.com

Help Desk: <https://www.f6publishing.com/helpdesk>

<https://www.wjgnet.com>

