

Unique case of oligoastrocytoma with recurrence and grade progression: Exhibiting differential expression of high mobility group-A1 and human telomerase reverse transcriptase

Puneet Gandhi, Richa Khare, Kavita Niraj, Nitin Garg, Sandeep K Sorte, Hanni Gulwani

Puneet Gandhi, Richa Khare, Kavita Niraj, Department of Research, Bhopal Memorial Hospital and Research Centre, Bhopal 462038, India

Nitin Garg, Sandeep K Sorte, Department of Neurosurgery, Bhopal Memorial Hospital and Research Centre and Bansal Hospital, Bhopal 462038, India

Hanni Gulwani, Department of Pathology, Bhopal Memorial Hospital and Research Centre, Bhopal 462038, India

Author contributions: Gandhi P and Niraj K designed the report; Khare R performed the IF-IHC; Khare R, Garg N and Sorte SK collected and analyzed clinical data; Gulwani H analyzed conventional pathological parameters; Gandhi P, Khare R and Niraj K performed immune-marker analysis, statistics and wrote the manuscript.

Supported by M.P. Biotech Council, M.P. for financial assistance; and BMHRC for infrastructural facilities, No. 249.

Institutional review board statement: The present case report is a part of project IEC/21/Res/11, which was reviewed and approved by BMHRC institutional review board.

Informed consent statement: Written informed consent as per institutional ethics committee (IEC/21/Res/11) was obtained from the legal authorised representative prior to study inclusion.

Conflict-of-interest statement: All authors state that they have no financial or any other conflict of interest to declare.

Open-Access: This article is an open-access article which was selected by an in-house editor and fully peer-reviewed by external reviewers. It is distributed in accordance with the Creative Commons Attribution Non Commercial (CC BY-NC 4.0) license, which permits others to distribute, remix, adapt, build upon this work non-commercially, and license their derivative works on different terms, provided the original work is properly cited and the use is non-commercial. See: <http://creativecommons.org/licenses/by-nc/4.0/>

Manuscript source: Invited manuscript

Correspondence to: Dr. Puneet Gandhi, Professor, Head, Department of Research, Bhopal Memorial Hospital and Research Centre, Raisen Bypass Road, Bhopal 462038, India. puneetgandhi67@yahoo.com
Telephone: +91-755-2742152

Received: April 26, 2016

Peer-review started: April 28, 2016

First decision: May 17, 2016

Revised: May 29, 2016

Accepted: June 27, 2016

Article in press: June 29, 2016

Published online: September 16, 2016

Abstract

Mixed gliomas, primarily oligoastrocytomas, account for about 5%-10% of all gliomas. Distinguishing oligo-astrocytoma based on histological features alone has limitations in predicting the exact biological behavior, necessitating ancillary markers for greater specificity. In this case report, human telomerase reverse transcriptase (hTERT) and high mobility group-A1 (HMGA1); markers of proliferation and stemness, have been quantitatively analyzed in formalin-fixed paraffin-embedded tissue samples of a 34 years old patient with oligoastrocytoma. Customized florescence-based immunohistochemistry protocol with enhanced sensitivity and specificity is used in the study. The patient presented with a history of generalized seizures and his magnetic resonance imaging scans revealed infiltrative ill-defined mass lesion with calcified foci within the left frontal white matter, suggestive of glioma. He was surgically treated at our center for four consecutive clinical events. Histopathologically, the tumor was identified as oligoastrocytoma-grade II followed by

two recurrence events and final progression to grade III. Overall survival of the patient without adjuvant therapy was more than 9 years. Glial fibrillary acidic protein, p53, Ki-67, nuclear atypia index, pre-operative neutrophil-lymphocyte ratio, are the other parameters assessed. Findings suggest that hTERT and HMGA1 are linked to tumor recurrence and progression. Established markers can assist in defining precise histopathological grade in conjunction with conventional markers in clinical setup.

Key words: Human telomerase reverse transcriptase; High mobility group-A1; Oligoastrocytoma; Recurrence; Tumor grade

© **The Author(s) 2016.** Published by Baishideng Publishing Group Inc. All rights reserved.

Core tip: The clinical relevance of defining precise histological grade II and III in glioma subtypes is crucial for intervention. This case report presents two new prospective markers high mobility group-A1 and human telomerase reverse transcriptase which can be used to assess stemness and proliferation, with greater sensitivity and specificity, through fluorescence based immunohistochemistry; and demarcate malignancy grade in oligoastrocytoma.

Gandhi P, Khare R, Niraj K, Garg N, Sorte SK, Gulwani H. Unique case of oligoastrocytoma with recurrence and grade progression: Exhibiting differential expression of high mobility group-A1 and human telomerase reverse transcriptase. *World J Clin Cases* 2016; 4(9): 296-301 Available from: URL: <http://www.wjgnet.com/2307-8960/full/v4/i9/296.htm> DOI: <http://dx.doi.org/10.12998/wjcc.v4.i9.296>

INTRODUCTION

Mixed gliomas, primarily oligoastrocytomas (OA) account for about 5%-10% of all gliomas^[1], are an aggressive type and their usual fate is to recur. Criteria for the reappearance of tumors include radiological features like tumor location, extent of surgical resection^[2] and proliferation indices^[3] with median survival being 3 to > 10 years in oligoastrocytoma^[4].

Ki-67 and CD133 are taken as standard tissue based molecular markers in clinical set-up, for proliferation index and cancer stemness, respectively. However, Skjulsvik *et al*^[5], stated that although Ki-67/MIB-1 proliferation indices correlate well with histological malignancy grade in all glioma subtypes, a considerable overlap is observed between these subtypes. Consequently, Ki-67/MIB-1 immunostaining alone is not sufficient to adequately determine the grade accurately. Similarly, CD133 is considered as a putative marker for stem cells, but because of varying expression in mixed gliomas, it needs to be interpreted with caution^[6]. This scenario necessitates identification of new molecular markers of clinical relevance, which can help delineate grade progression as well as recurrence related to stemness

in glial tumor sub-types.

In situ hybridization based study, suggested a correlation of human telomerase reverse transcriptase (hTERT) expression with malignant transformation of gliocytes and degree of malignancy^[7]. Similarly, expression of high mobility group-A1 (HMGA1) protein, an architectural transcription factor, has been shown to closely relate to malignant proliferation, invasion and differentiation of tumor from the perspective of tumor stem cells^[8].

In this case report, immunofluorescence (IF) based expression of HMGA1 and hTERT in formalin-fixed-paraffin-embedded (FFPE) tissue samples of a patient with oligoastrocytoma, has been evaluated quantitatively in reference to tumor recurrence as well as grade progression.

CASE REPORT

A 34 years old male was referred to the Neurosurgery Department with a history of generalized seizures and 4 recurrent episodes, in three months. The patient had no neurological deficit. Magnetic resonance imaging (MRI) scans revealed infiltrative ill-defined mass lesion within the left frontal white matter, suggestive of glioma (Figure 1A). Left fronto-temporal awake craniotomy and near total excision of the tumor was done. In regular follow-up, patient was observed to be symptom free. After 43 mo, he had recurrent seizures and computed tomography (CT) scan showed an increase in size of the residual tumor with mass effect and calcified foci (Figure 1B). Re-exploration and decompression of the tumor was done, but a part of the tumor near the motor strip and deep eloquent areas was left behind. CT scans during follow ups revealed residual tumor without any significant mass effect. Patient led a neurologically asymptomatic life on regular antiepileptics for the next 48 mo. When presented again with recurrence of seizures, unconsciousness and multiple episodes of vomiting, MRI showed large fronto-temporal lesion causing significant mass effect and midline shift (Figure 1C). The patient was effectively mobilized, improved neurologically and became conscious and obeying. He was advised adjuvant therapy considering the residual tumor, with no histological change in the grade of tumor. However, patient deferred adjuvant therapy and again presented after 11 mo in altered sensorium. This time CT exam revealed an increase in size of the left temporal-parietal lesion with large cystic component and intrasubcortical hemorrhage with transtentorial herniation, also involving the brain stem (Figure 1D). Life saving re-exploration craniotomy with decompression and left temporal-parietal lobectomy was done. After a month long stay in the hospital, patient was discharged with strong advice for adjuvant therapy along with other medications and supportive care, making his overall survival at 9 years and 3 mo at the time of the study.

Written informed consent as per institutional ethics committee (IEC/21/Res/11) was obtained. Reported histopathological grades for all resections were noted from medical records and re-analyzed. The first resection was

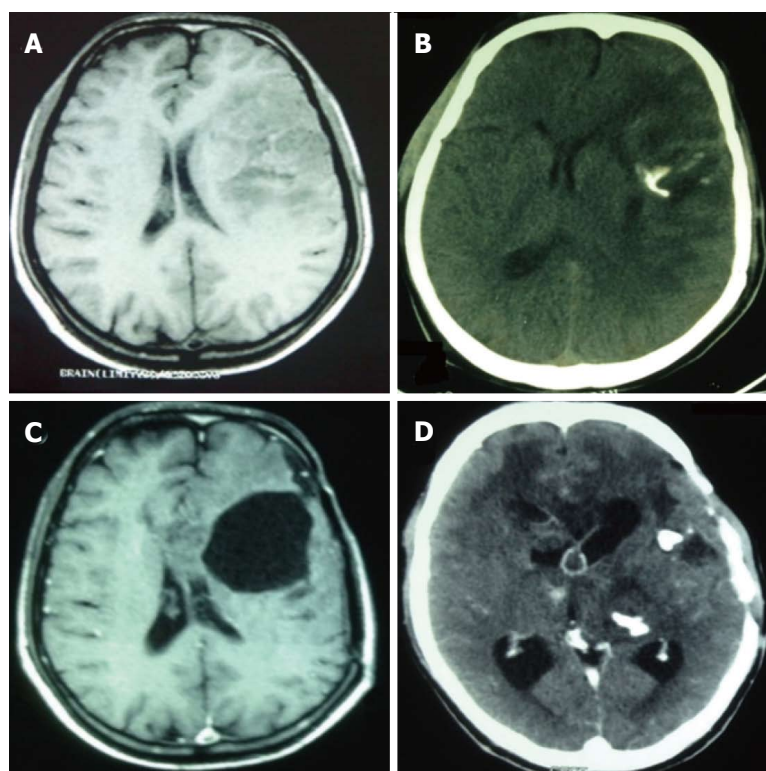


Figure 1 Radiological scans and findings before each surgical resection. A: MRI scans at initial diagnosis suggestive of glioma; B: CT scans at first recurrence showing calcification indicative of oligo-component presence; C: MRI scans just before third surgical intervention; D: CT scans before last resection confirming increased calcification. MRI: Magnetic resonance imaging; CT: Computed tomography.

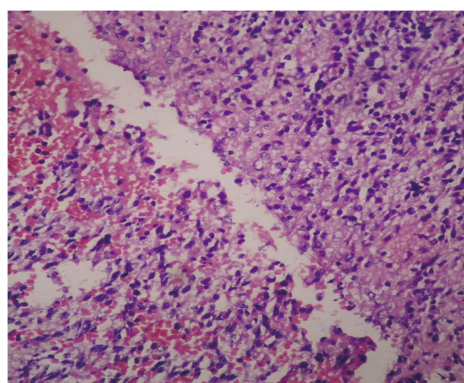


Figure 2 Perinuclear halo and honeycomb appearance in oligodendroglial component.

oligo-astrocytoma (grade- II). Histological examination showed diffused infiltrating glioma composed of sheets of atypical astrocytic and oligodendroglial cells arranged against a fibrillary background. Cells had scant light eosinophilic cytoplasm with condensed, pleomorphic, vesicular nucleus. Characteristic perinuclear halo (honeycomb appearance) (Figure 2) and regions of small laminated calcification; were seen in oligodendroglial component. Large areas of hemorrhage, microcystic changes, arborizing thin capillaries (chicken wire pattern) were also noted. Immunohistochemical analysis of this patient's tumor revealed approximately 45% oligodendroglial and 55% astrocytic cells, with tumor cell expression of p53 and GFAP, indicating that the patient had an OA. On first and second recurrence the resected sample persisted as oligoastrocytoma-grade II . Histo-pathologically last resection was reported as

anaplastic oligo-astrocytoma (grade III) indicative of grade progression and intense invasiveness in terms of increased Ki-67 index.

IF based expression of HMGA1 and hTERT in FFPE tissue was assessed in the areas with the highest degree of malignancy, while glial fibrillary acidic protein (GFAP), p53, neutrophil-lymphocyte ratio (NLR), nuclear atypia index (NAI) and Ki-67 proliferation index were the other parameters evaluated.

hTERT and HMGA1 by IF

The expression of HMGA1 and hTERT molecules in FFPE glioma tissue by florescence based immunohistochemistry (IF-IHC) was carried out as per protocol described here. In brief, sequential deparaffinization and hydration of slides was followed by treatment with 0.1% sodium borohydride and 0.05% crystal violet consecutively. Antigen retrieval was performed in sodium citrate buffer (pH 6.0) followed by permeabilization with 0.2% Triton X-100. Sections were blocked for 60 min, and incubated with primary antibody hTERT (Abcam 1:750) or HMGA1 (Abcam 1:1000) overnight at 4 °C . Slides were then treated with host specific secondary antibodies (FITC labelled, 1:300 dilution), counterstained with 4', 6-diamidino-2-phenylindol (DAPI). Sections were then slaked with 0.1% Sudan black B, washed and mounted using antifade. Images were captured at 40X and digitalized using Zeiss AxioPlan 2 epifluorescent microscope and ASI imaging system (Case Data Manager Expo 4.5 software). At least 1000 cells/section were enumerated for each marker, using Image J-derivate "Fiji" software.

Evaluation of results showed that the expression of

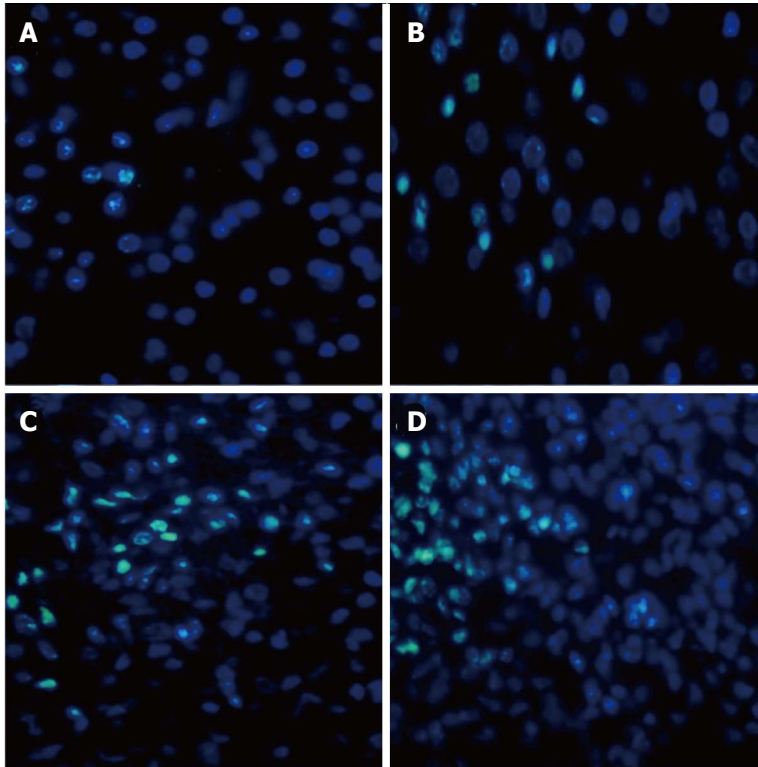


Figure 3 Florescence based immunohistochemistry for analysis and interpretation of human telomerase reverse transcriptase expression. A: Expression of marker in the first resected sample (grade II); B: Signal intensity of the marker at first recurrence (grade II); C: Increased hTERT expression at second recurrence (grade II); D: Intense immune-reactivity at confined foci in last surgical sample resected classified as histopathological grade III. hTERT: Human telomerase reverse transcriptase.

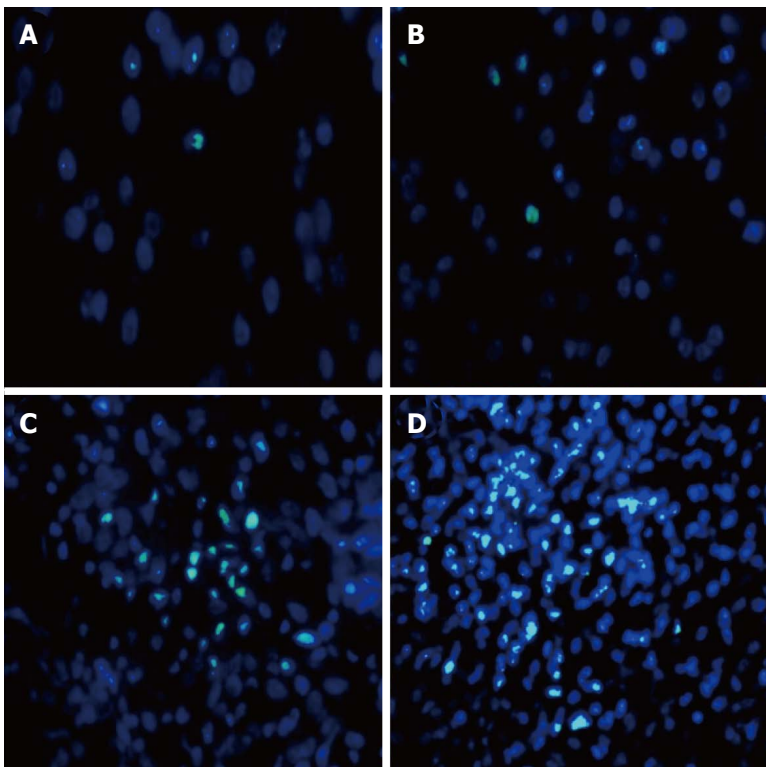


Figure 4 The figure depicts differential high mobility group-A1 immunostaining. A: Minimal immune-expression in initial sample (grade II); B: At first recurrence (grade II); C: Increased signal intensity of the marker in sample from second recurrence (grade II); D: HMGA1 expression highly up-regulated with progression to histopathological grade III. HMGA1: High mobility group-A1.

proliferative marker hTERT (Figure 3) and stemness marker HMGA1 (Figure 4) increased with each resection I, II, III and IV; concurrent with tumor recurrence and grade progression (Table 1).

Ki-67

Ki-67 proliferation index, GFAP and p53 were evaluated

using peroxidase-IHC based routine lab protocol. Ki-67 labelling indices were found to be concomitant with an expression of both our tissue markers (Table 1).

NAI

Nuclear atypia, evaluated in DAPI stained cells, was recorded in 500 cells per section. NAI increased with

Table 1 Evaluated tissue markers

S. No.	Markers	I resection	II resection	III resection	IV resection
1	hTERT	1.23%	2.05%	2.71%	4.50%
2	HMGA1	0.50%	0.87%	1.09%	2.62%
3	Ki-67 INDEX	1.00%	4.00%	7.00%	8.50%
4	NAI	6.30%	12.94%	16.06%	31.01%

hTERT: Human telomerase reverse transcriptase; HMGA1: High mobility group-A1; NAI: Nuclear atypia index.

recurrence; highest value being at 4th resection when tumor grade progressed (Table 1).

NLR

Value of NLR was calculated from pre-surgery full blood count using Leishman stain. The patient had been on steroids for 24 h prior to surgery and did not present clinical signs of sepsis at the time of blood sampling for NLR. The pre-operative NLR value in the therapy naive sample was 2.17 which increased to 7.81 in resection IV with change in histological grade from low to high.

DISCUSSION

Although tissue based molecular markers like mitotic count, Ki67/MIB1, PCNA, CD133 are being used for enumeration of proliferation index and stemness in glioma sub-types, the clinical outcome based on these markers singularly, still remains controversial. This variable functionality led us to investigate two tissue based molecular markers: hTERT and HMGA1, to enumerate proliferation and stemness in OA.

Cellular and molecular basis of cell proliferation is vital to diagnostics, in dealing with this malignancy. Our results revealed that expression of hTERT in each resection increased because of proliferation in residual tumor, leading to recurrence (Table 1). A study by Shervington *et al*^[9] in glioma patients, showed a significant difference in telomerase protein levels between cancerous and normal tissues. Also, in line with our finding, IHC based hTERT expression pattern has been reported on low and high grade glioma samples, indicating higher expression to be linked with grade progression^[10]. The analysis of our marker indicates that measurement of precise proliferative activity is crucial to delineate the transition from low to high grade OA.

Cancer stem cells are known to be responsible for tumor recurrence. As can be deduced from clinical history of the patient, recurrence of tumor was initiated because of the presence of stem cell(s) in the tumor mass left behind since gross total resection could not be clinically achieved in any of the surgical interventions. Increase in expression of stemness marker HMGA1 relates to tumor recurrence with a marked difference in expression when grade progressed, as evident from IF based quantitative analysis (Table 1) and our further work validates these markers in a bigger cohort (data under publication).

Results are concomitant with earlier studies, one which revealed that expression of HMGA1 significantly correlates with malignancy, proliferation, invasion and angiogenesis in 60 glioma samples^[11]; and also with another study that showed a differential IHC expression of HMGA1 in patients with primary and recurrent GBM^[12]. Our study technique was IF based, with greater sensitivity, specificity for the epitopes in question and the evaluation was quantitative. Although our patient deferred adjuvant therapy; a positive prognosis in terms of 112 mo of overall survival is recorded. This is augmented by Ki67, hTERT and HMGA1 indices; values of which are less than our in-house established thresholds for low and high grade. In the present case of OA, the percentage expression of our markers HMGA1 and hTERT is concomitant with Ki67 index making these two newly established markers prospective candidates in assisting precise grading of cases such as OA.

COMMENTS

Case characteristics

A 34 years old male was referred to the Neurosurgery department with a history of general seizures and 4 recurrent episodes of seizures in three months.

Clinical diagnosis

History of 4 episodes of recurrent seizures with normal neurological examination.

Differential diagnosis

The cause of seizures could not be ascertained clinically and required further evaluation by imaging. Seizures were not characteristic of a particular location and patient had a normal neurological examination.

Laboratory diagnosis

All labs were within normal limits.

Imaging diagnosis

Magnetic resonance imaging (MRI) scans revealed infiltrative ill-defined mass lesion within the left frontal white matter, suggestive of glioma. Follow-up computed tomography scan/MRI, showed increase in size of the residual tumor with mass effect and calcified foci. Imaging indicated increasing invasiveness as the disease progressed.

Pathological diagnosis

Haematoxylin and eosin staining showed diffused infiltrating glioma composed of sheets of atypical astrocytic and oligodendroglial cells arranged against a fibrillary background, indicative of oligo-astrocytoma (grade-II). Peroxidase-immunohistochemistry (IHC) was used to assess Ki-67, glial fibrillary acidic protein, p53 and immunofluorescence (IF) based IHC was used to evaluate human telomerase reverse transcriptase (hTERT) and high mobility group-A1 (HMGA1).

Treatment

Near/sub total excision of the tumor was done at first resection and also when increase in size of the residual tumor with mass effect was observed; however, patient deferred suggested adjuvant therapy.

Related reports

Oligoastrocytoma (mixed glioma) is an aggressive, highly infiltrating glioma type. Distinguishing oligoastrocytomas (OA) based on histological features alone has limitations in predicting the exact biological behavior, necessitating ancillary markers for greater specificity.

Term explanation

Nuclear atypia index (NAI) is a count of abnormal cell nuclei, in most cases indicative of malignancy. Nuclear lymphocyte ratio (NLR) is a marker of subclinical inflammation and a factor of poor prognosis in various cancers. hTERT and HMGA1 are markers of proliferation and stemness, respectively.

Experiences and lessons

The study technique was IF based, with greater sensitivity and specificity for the epitopes in question and the evaluation was quantitative. In the present case of OA, the percentage expression of our markers HMGA1 and hTERT is concomitant with Ki67 index making these two newly established markers prospective candidates in assisting precise grading of cases such as OA.

Peer-review

An interesting case presentation.

REFERENCES

- 1 **American Brain Tumor Association.** Oligodendroglioma and Oligoastrocytoma. [retrieved 2015 Dec 7]. Available from: URL: <http://www.abta.org>
- 2 **Nestler U,** Lutz K, Pichlmeier U, Stummer W, Franz K, Reulen HJ, Bink A. Anatomic features of glioblastoma and their potential impact on survival. *Acta Neurochir (Wien)* 2015; **157**: 179-186 [PMID: 25391974 DOI: 10.1007/s00701-014-2271-x]
- 3 **Louis DN,** Ohgaki H, Wiestler OD, Cavenee WK, Burger PC, Jouvet A, Scheithauer BW, Kleihues P. The 2007 WHO classification of tumours of the central nervous system. *Acta Neuropathol* 2007; **114**: 97-109 [PMID: 17618441 DOI: 10.1007/s00401-007-0278-6]
- 4 **Vigneswaran K,** Neill S, Hadjipanayis CG. Beyond the World Health Organization grading of infiltrating gliomas: advances in the molecular genetics of glioma classification. *Ann Transl Med* 2015; **3**: 95 [PMID: 26015937 DOI: 10.3978/j.issn.2305-5839.2015.03.57]
- 5 **Skjulsvik AJ,** Mørk JN, Torp MO, Torp SH. Ki-67/MIB-1 immunostaining in a cohort of human gliomas. *Int J Clin Exp Pathol* 2014; **7**: 8905-8910 [PMID: 25674263]
- 6 **Beier D,** Wischhusen J, Dietmaier W, Hau P, Proescholdt M, Brawanski A, Bogdahn U, Beier CP. CD133 expression and cancer stem cells predict prognosis in high-grade oligodendroglial tumors. *Brain Pathol* 2008; **18**: 370-377 [PMID: 18371181 DOI: 10.1111/j.1750-3639.2008.00130.x]
- 7 **Wang DL,** Wang YF, Shi GS, Huang H. [Correlation of hTERT expression to maspin and bFGF expression and their significance in glioma]. *Ai Zheng* 2007; **26**: 601-606 [PMID: 17562265]
- 8 **Fan H,** Guo H, Zhang IY, Liu B, Luan L, Xu S, Hou X, Liu W, Zhang R, Wang X, Pang Q. The different HMGA1 expression of total population of glioblastoma cell line U251 and glioma stem cells isolated from U251. *Brain Res* 2011; **1384**: 9-14 [PMID: 21300033 DOI: 10.1016/j.brainres.2011.01.105]
- 9 **Shervington A,** Patel R. Differential hTERT mRNA processing between young and older glioma patients. *FEBS Lett* 2008; **582**: 1707-1710 [PMID: 18435920 DOI: 10.1016/j.febslet.2008.04.027]
- 10 **Yang K,** Liu Y, Liu Z, Liu J, Liu X, Chen X, Li C, Zeng Y. p38γ overexpression in gliomas and its role in proliferation and apoptosis. *Sci Rep* 2013; **3**: 2089 [PMID: 23807566 DOI: 10.1038/srep02089]
- 11 **Pang B,** Fan H, Zhang IY, Liu B, Feng B, Meng L, Zhang R, Sadeghi S, Guo H, Pang Q. HMGA1 expression in human gliomas and its correlation with tumor proliferation, invasion and angiogenesis. *J Neurooncol* 2012; **106**: 543-549 [PMID: 21984063 DOI: 10.1007/s11060-011-0710-6]
- 12 **Liang Z.** The Expression and Significance of HMGA1, TROP2 in Malignant Gliomas. *J Shandong Univ Health Sci* 2013; **51**: 59-61

P- Reviewer: Lakatos PL, Tsikouras PPT, Yao D **S- Editor:** Ji FF
L- Editor: A **E- Editor:** Lu YJ





Published by **Baishideng Publishing Group Inc**

8226 Regency Drive, Pleasanton, CA 94588, USA

Telephone: +1-925-223-8242

Fax: +1-925-223-8243

E-mail: bpgoffice@wjgnet.com

Help Desk: <http://www.wjgnet.com/esps/helpdesk.aspx>

<http://www.wjgnet.com>

