

# World Journal of *Gastroenterology*

*World J Gastroenterol* 2024 March 14; 30(10): 1261-1469



## EDITORIAL

- 1261 Bridging the gap: Unveiling the crisis of physical inactivity in inflammatory bowel diseases  
*Stafie R, Singeap AM, Rotaru A, Stanciu C, Trifan A*
- 1266 Double role of depression in gastric cancer: As a causative factor and as consequence  
*Christodoulidis G, Konstantinos-Elleftherios K, Marina-Nektaria K*
- 1270 Capsule endoscopy and panendoscopy: A journey to the future of gastrointestinal endoscopy  
*Rosa B, Cotter J*
- 1280 Vonoprazan-amoxicillin dual regimen with *Saccharomyces boulardii* as a rescue therapy for *Helicobacter pylori*: Current perspectives and implications  
*Dirjayanto VJ, Audrey J, Simadibrata DM*
- 1287 Women health and microbiota: Different aspects of well-being  
*Nannini G, Amedei A*
- 1291 Nomograms and prognosis for superficial esophageal squamous cell carcinoma  
*Lin HT, Abdelbaki A, Krishna SG*

## REVIEW

- 1295 Overview of the immunological mechanisms in hepatitis B virus reactivation: Implications for disease progression and management strategies  
*Ma H, Yan QZ, Ma JR, Li DF, Yang JL*
- 1313 Optimizing nutrition in hepatic cirrhosis: A comprehensive assessment and care approach  
*Mendez-Guerrero O, Carranza-Carrasco A, Chi-Cervera LA, Torre A, Navarro-Alvarez N*
- 1329 Optimizing prediction models for pancreatic fistula after pancreatectomy: Current status and future perspectives  
*Yang F, Windsor JA, Fu DL*

## ORIGINAL ARTICLE

## Retrospective Cohort Study

- 1346 Cumulative effects of excess high-normal alanine aminotransferase levels in relation to new-onset metabolic dysfunction-associated fatty liver disease in China  
*Chen JF, Wu ZQ, Liu HS, Yan S, Wang YX, Xing M, Song XQ, Ding SY*
- 1358 Time trends and outcomes of gastrostomy placement in a Swedish national cohort over two decades  
*Skogar ML, Sundbom M*

**Retrospective Study**

- 1368** Stage at diagnosis of colorectal cancer through diagnostic route: Who should be screened?

*Agatsuma N, Utsumi T, Nishikawa Y, Horimatsu T, Seta T, Yamashita Y, Tanaka Y, Inoue T, Nakanishi Y, Shimizu T, Ohno M, Fukushima A, Nakayama T, Seno H*

**Observational Study**

- 1377** Differential diagnosis of Crohn's disease and intestinal tuberculosis based on ATR-FTIR spectroscopy combined with machine learning

*Li YP, Lu TY, Huang FR, Zhang WM, Chen ZQ, Guang PW, Deng LY, Yang XH*

**Prospective Study**

- 1393** Establishment and validation of an adherence prediction system for lifestyle interventions in non-alcoholic fatty liver disease

*Zeng MH, Shi QY, Xu L, Mi YQ*

**Basic Study**

- 1405** Alkaline sphingomyelinase deficiency impairs intestinal mucosal barrier integrity and reduces antioxidant capacity in dextran sulfate sodium-induced colitis

*Tian Y, Li X, Wang X, Pei ST, Pan HX, Cheng YQ, Li YC, Cao WT, Petersen JDD, Zhang P*

- 1420** Preliminary exploration of animal models of congenital choledochal cysts

*Zhang SH, Zhang YB, Cai DT, Pan T, Chen K, Jin Y, Luo WJ, Huang ZW, Chen QJ, Gao ZG*

- 1431** Serotonin receptor 2B induces visceral hyperalgesia in rat model and patients with diarrhea-predominant irritable bowel syndrome

*Li ZY, Mao YQ, Hua Q, Sun YH, Wang HY, Ye XG, Hu JX, Wang YJ, Jiang M*

**META-ANALYSIS**

- 1450** Shear-wave elastography to predict hepatocellular carcinoma after hepatitis C virus eradication: A systematic review and meta-analysis

*Esposito G, Santini P, Galasso L, Mignini I, Ainora ME, Gasbarrini A, Zocco MA*

**LETTER TO THE EDITOR**

- 1461** Current considerations on intraductal papillary neoplasms of the bile duct and pancreatic duct

*Pavlidis ET, Galanis IN, Pavlidis TE*

- 1466** Are we ready to use new endoscopic scores for ulcerative colitis?

*Quera R, Núñez F P*

**ABOUT COVER**

Editorial Board Member of *World Journal of Gastroenterology*, Toru Mizuguchi, MD, PhD, Professor, Surgeon, Department of Nursing, Division of Surgical Science, Sapporo Medical University Postgraduate School of Health Science, Sapporo, Hokkaido 0608556, Japan. [tmizu@sapmed.ac.jp](mailto:tmizu@sapmed.ac.jp)

**AIMS AND SCOPE**

The primary aim of *World Journal of Gastroenterology* (WJG, *World J Gastroenterol*) is to provide scholars and readers from various fields of gastroenterology and hepatology with a platform to publish high-quality basic and clinical research articles and communicate their research findings online. WJG mainly publishes articles reporting research results and findings obtained in the field of gastroenterology and hepatology and covering a wide range of topics including gastroenterology, hepatology, gastrointestinal endoscopy, gastrointestinal surgery, gastrointestinal oncology, and pediatric gastroenterology.

**INDEXING/ABSTRACTING**

The WJG is now abstracted and indexed in Science Citation Index Expanded (SCIE), MEDLINE, PubMed, PubMed Central, Scopus, Reference Citation Analysis, China Science and Technology Journal Database, and Superstar Journals Database. The 2023 edition of Journal Citation Reports® cites the 2022 impact factor (IF) for WJG as 4.3; Quartile category: Q2. The WJG's CiteScore for 2021 is 8.3.

**RESPONSIBLE EDITORS FOR THIS ISSUE**

Production Editor: *Ying-Yi Yuan*; Production Department Director: *Xiang Li*; Cover Editor: *Jia-Ru Fan*.

**NAME OF JOURNAL**

*World Journal of Gastroenterology*

**ISSN**

ISSN 1007-9327 (print) ISSN 2219-2840 (online)

**LAUNCH DATE**

October 1, 1995

**FREQUENCY**

Weekly

**EDITORS-IN-CHIEF**

Andrzej S Tarnawski

**EXECUTIVE ASSOCIATE EDITORS-IN-CHIEF**

Xian-Jun Yu (Pancreatic Oncology), Jian-Gao Fan (Chronic Liver Disease), Hou-Bao Liu (Biliary Tract Disease)

**EDITORIAL BOARD MEMBERS**

<http://www.wjgnet.com/1007-9327/editorialboard.htm>

**PUBLICATION DATE**

March 14, 2024

**COPYRIGHT**

© 2024 Baishideng Publishing Group Inc

**PUBLISHING PARTNER**

Shanghai Pancreatic Cancer Institute and Pancreatic Cancer Institute, Fudan University  
Biliary Tract Disease Institute, Fudan University

**INSTRUCTIONS TO AUTHORS**

<https://www.wjgnet.com/bpg/gerinfo/204>

**GUIDELINES FOR ETHICS DOCUMENTS**

<https://www.wjgnet.com/bpg/GerInfo/287>

**GUIDELINES FOR NON-NATIVE SPEAKERS OF ENGLISH**

<https://www.wjgnet.com/bpg/gerinfo/240>

**PUBLICATION ETHICS**

<https://www.wjgnet.com/bpg/GerInfo/288>

**PUBLICATION MISCONDUCT**

<https://www.wjgnet.com/bpg/gerinfo/208>

**POLICY OF CO-AUTHORS**

<https://www.wjgnet.com/bpg/GerInfo/310>

**ARTICLE PROCESSING CHARGE**

<https://www.wjgnet.com/bpg/gerinfo/242>

**STEPS FOR SUBMITTING MANUSCRIPTS**

<https://www.wjgnet.com/bpg/GerInfo/239>

**ONLINE SUBMISSION**

<https://www.f6publishing.com>

**PUBLISHING PARTNER's OFFICIAL WEBSITE**

<https://www.shca.org.cn>  
<https://www.zs-hospital.sh.cn>





## Basic Study

# Preliminary exploration of animal models of congenital choledochal cysts

Shu-Hao Zhang, Yue-Bin Zhang, Duo-Te Cai, Tao Pan, Ken Chen, Yi Jin, Wen-Juan Luo, Zong-Wei Huang, Qing-Jiang Chen, Zhi-Gang Gao

**Specialty type:** Gastroenterology and hepatology

### Provenance and peer review:

Unsolicited article; Externally peer reviewed.

**Peer-review model:** Single blind

### Peer-review report's scientific quality classification

Grade A (Excellent): 0  
Grade B (Very good): B, B  
Grade C (Good): 0  
Grade D (Fair): 0  
Grade E (Poor): 0

**P-Reviewer:** Kordzaia D, Georgia; Mijwil MM, Iraq

**Received:** October 17, 2023

**Peer-review started:** October 17, 2023

**First decision:** January 15, 2024

**Revised:** January 17, 2024

**Accepted:** February 21, 2024

**Article in press:** February 21, 2024

**Published online:** March 14, 2024



Shu-Hao Zhang, Yue-Bin Zhang, Duo-Te Cai, Tao Pan, Ken Chen, Yi Jin, Wen-Juan Luo, Zong-Wei Huang, Qing-Jiang Chen, Zhi-Gang Gao, Department of General Surgery, Children's Hospital, Zhejiang University School of Medicine, Hangzhou 310000, Zhejiang Province, China

**Corresponding author:** Zhi-Gang Gao, PhD, Chief Doctor, Department of General Surgery, Children's Hospital, Zhejiang University School of Medicine, No. 3333 Binsheng Road, Binjiang District, Hangzhou 310000, Zhejiang Province, China. [ebwk@zju.edu.cn](mailto:ebwk@zju.edu.cn)

## Abstract

### BACKGROUND

Various animal models have been used to explore the pathogenesis of choledochal cysts (CCs), but with little convincing results. Current surgical techniques can achieve satisfactory outcomes for treatment of CCs. Consequently, recent studies have focused more on clinical issues rather than basic research. Therefore, we need appropriate animal models to further basic research.

### AIM

To establish an appropriate animal model that may contribute to the investigation of the pathogenesis of CCs.

### METHODS

Eighty-four specific pathogen-free female Sprague-Dawley rats were randomly allocated to a surgical group, sham surgical group, or control group. A rat model of CC was established by partial ligation of the bile duct. The reliability of the model was confirmed by measurements of serum biochemical indices, morphology of common bile ducts of the rats as well as molecular biology experiments in rat and human tissues.

### RESULTS

Dilation classified as mild (diameter,  $\geq 1$  mm to  $< 3$  mm), moderate ( $\geq 3$  mm to  $< 10$  mm), and severe ( $\geq 10$  mm) was observed in 17, 17, and 2 rats in the surgical group, respectively, while no dilation was observed in the control and sham surgical groups. Serum levels of alanine aminotransferase, aspartate aminotransferase, total bilirubin, direct bilirubin, and total bile acids were significantly elevated in the surgical group as compared to the control group 7 d after surgery, while direct bilirubin, total bilirubin, and gamma-glutamyltransferase were

further increased 14 d after surgery. Most of the biochemical indices gradually decreased to normal ranges 28 d after surgery. The protein expression trend of signal transducer and activator of transcription 3 in rat model was consistent with the human CC tissues.

## CONCLUSION

The model of partial ligation of the bile duct of juvenile rats could morphologically simulate the cystic or fusiform CC, which may contribute to investigating the pathogenesis of CC.

**Key Words:** Choledochal cyst; Animal model; Partial ligation; Cystic and fusiform dilation; Juvenile rats

©The Author(s) 2024. Published by Baishideng Publishing Group Inc. All rights reserved.

**Core Tip:** Recent studies have focused more on clinical issues rather than etiology and pathogenesis of choledochal cyst (CC). In this study, our partial ligation of the bile duct of juvenile rats successfully simulated the pathological processes of recanalization after incomplete obstruction of the distal bile duct. The postoperative disease progression of this model was more consistent with the natural course of CC formation which may assist in further basic research on the pathogenesis of CC.

**Citation:** Zhang SH, Zhang YB, Cai DT, Pan T, Chen K, Jin Y, Luo WJ, Huang ZW, Chen QJ, Gao ZG. Preliminary exploration of animal models of congenital choledochal cysts. *World J Gastroenterol* 2024; 30(10): 1420-1430

**URL:** <https://www.wjgnet.com/1007-9327/full/v30/i10/1420.htm>

**DOI:** <https://dx.doi.org/10.3748/wjg.v30.i10.1420>

## INTRODUCTION

Choledochal cyst (CC) is a congenital hepatic malformation characterized by cystic or fusiform dilation of the common bile duct either with or without dilation of the intrahepatic bile duct. The hypothesis of pancreaticobiliary maljunction (PBM) proposed by Babbitt[1] in 1969 is the most likely cause of CC, emphasizing that pancreatic juice could cause segmental stricture, fibrosis, and thinning of the common bile duct. However, with the increased proportion of prenatal diagnosis of CCs, researchers have found that pancreatic acini are just beginning to appear, enzymes are immature during that time period, and there is no evidence of pancreatic secretion observed by electron microscopy[2]. Therefore, the role of fetal pancreatic juice in the formation of CCs remains controversial because the pancreas of newborns does not yet produce functional enzymes[3]. Accumulating evidence from clinical cases suggests that PBM cannot fully explain the pathogenesis of CCs.

Various animal models to simulate the disease process in humans have been used to investigate the pathogenesis of cystic and fusiform CCs. However, anastomosis of the pancreatic and biliary ducts, which allow pancreatic juice to enter the bile duct, only resulted in mild dilation of the common bile duct without cystic dilatation[4]. Moreover, even in large animal models, such as minipigs, no one was observed to have dilatation of the bile ducts[5]. In contrast, complete ligation of the lower segment of the common bile duct in neonatal lambs[6] and infant rats[7] can successfully create a model of cystic dilation, while in mature sheep, rats, dogs or rabbits, no cystic dilation was observed through the ligation of the lower segment of the common bile duct. However, it is not recognized as a conventional CC animal model because it does not conform to the mainstream hypothesis of PBM. Some researchers also constructed an animal model by combining anastomosis of the pancreatic and biliary ducts with ligation of the lower segment of the common bile duct. However, it is still unclear whether dilation of the common bile duct is caused solely by ligation of the lower segment or by the combination of both factors. Satisfactory outcomes achieved with current surgical techniques for CCs have led to a pause in basic research on the etiology of CCs, and recent studies have primarily focused on reporting large clinical series, improvements of surgical techniques and the management of postoperative complications[8]. Hence, appropriate animal models should be established to further basic research. In our study, our partial ligation of the bile duct of juvenile rats successfully simulated the pathological processes of recanalization after incomplete obstruction of the distal bile duct. The postoperative changing trends of biochemical indexes in rat model was similar to those observed in CCs, and the changing trend of signal transducer and activator of transcription 3 (STAT3) in the rat model was consistent with that observed in human CC tissues. Therefore, our study has established an animal model that may contribute to the investigation of the pathogenesis of CCs.

## MATERIALS AND METHODS

### Experimental animals and grouping

Specific pathogen-free female SD rats ( $n = 84$ ; mean body weight, 200 g  $\pm$  10 g) were purchased from Sibeifu Biotech-

nology Co., Ltd. (Beijing, China) and housed in an animal care facility operated by Zhejiang Yingyang Pharmaceutical Co., Ltd., (Hangzhou, China) at a constant temperature of 22 °C ± 2 °C and humidity of 50%-60% under a 12-h light-dark cycle with total air exchange at 15-20 times/h.

The 84 rats were randomly allocated to one of 7 groups of 12 rats each. Rats in groups A, B, and C were dissected on days 7, 14, and 28 after partial ligation of the bile duct, respectively. Rats in group D were dissected on day 28 after sham surgery without bile duct ligation. Rats in groups E, F, and G were dissected after 7 d, 14 d, and 28 d of feeding, respectively.

### **Partial ligation surgery of the bile duct of infant rats**

(1) Anesthesia: 2.5% pentobarbital sodium (0.25 mL/100 g) was injected into the abdominal cavity; (2) Positioning: After anesthesia, the rats were fixed with a supine position on the surgical table; (3) Skin preparation: The hair below the xiphoid process in the middle of the abdomen was removed with an electric shaver, exposing about 5 cm × 3 cm of skin, followed by iodine disinfection; (4) Skin incision: A midline longitudinal incision was made on the abdomen with surgical scissors, about 2 cm in length; (5) Bile duct isolation: Wet cotton swabs were used to separate the organs and locate the duodenum and pancreas, and then the bile duct was located with forceps; (6) Partial ligation: Place a 1 mL needle parallel to the bile duct and use 6-0 absorbable suture to ligate the bile duct and needle together at the lower segment of the bile duct. Then the needle was removed carefully after tightening the absorbable suture; and (7) Closure of the incision: After ligation, and the incision was intermittently sutured with 5-0 silk thread. Penicillin was administered intraperitoneally to prevent infection (0.3 mL, 400000 units/mL). Detailed surgical procedures were shown in [Figure 1](#).

### **lncRNA sequencing analysis**

An adequate amounts of human bile duct tissues were sent for lncRNA sequencing analysis. The pretreatment of tissue specimens, filtration of sequencing data, obtainment of clean reads, calculation of gene expression levels and differential expression analysis were performed by BGI Genomics CO., Ltd (seen in previous reported study[9]). To gain insights into the phenotypic changes, GO (<http://www.geneontology.org/>) and KEGG (<https://www.kegg.jp/>) enrichment analysis of annotated differentially expressed genes was performed using Phyper ([https://en.wikipedia.org/wiki/Hypergeometric\\_distribution](https://en.wikipedia.org/wiki/Hypergeometric_distribution)) based on the Hypergeometric test. The significant levels of terms and pathways were rigorously corrected using a Q value threshold of ≤ 0.05 by Bonferroni[10].

### **Biochemical indices in rat plasma**

The rat blood samples were centrifuged at 3000-4000 rpm for 10 min at 4 °C and the plasma was frozen for further analysis of biochemical parameters, which included alanine aminotransferase (ALT), aspartate aminotransferase (AST), total bilirubin (TBIL), direct bilirubin (DBIL), gamma-glutamyltransferase (GGT), and total bile acids (TBA). Reagent kits from Ningbo Puruibo company were shown as follows: ALT kit (Lot: ALT01), AST kit (Lot: AST01), TBA kit (Lot: TBA01S), DBIL kit (Lot: DBI01), TBIL kit (Lot: TBI01), and GGT kit (Lot: GGT01).

### **Molecular biology detection of human and rat common bile duct tissues**

**RNA Isolation and quantitative reverse transcription-polymerase chain reaction:** Total cellular RNA was extracted from CC patients' common bile ducts and rats' common bile ducts with TRIzol reagent (Invitrogen, cat. 15596026/15596018) and subjected to reverse transcription with PrimeScript RT reagent Kit (Takara, cat. RR037A) according to the manufacturers' instructions. The expressions of IL-6 and STAT3 were analyzed *via* quantitative reverse transcription-polymerase chain reaction (RT-qPCR) with a SYBR Premix EX Taq (Tli RNaseH plus, Takara, cat. RR420A) with primers listed in [Table 1](#). For analysis, expression levels of the genes were normalized to the values of GAPDH. Analysis of relative gene expression data using real-time quantitative PCR was calculated with the 2-11Ct method[11].

**Western blot:** Tissue samples (50 mg) were washed with Tris-buffered saline to remove residual blood and ground into small fragments, which were lysed with radioimmunoprecipitation assay on ice for 30 min. After addition of protein inhibitors, the mixture was centrifuged at 13000 rpm for 10-15 min and the supernatant was collected. Then, 5 × loading buffer was added and the mixture was heated in a metal bath at 95 °C for 5 min to fully denature the proteins. Protein levels were determined against standards. Protein expression levels of STAT3 and phosphorylated (p)-STAT3 and were normalized to expression of glyceraldehyde 3-phosphate dehydrogenase.

**Immunofluorescence histochemistry:** The common bile duct sections were deparaffinized in three changes of xylene and two changes of 100% ethanol and subsequent gradation of 95%, 80%, and 70% alcohol for 3 min each. After being heat-induced epitope retrieval with a preheated epitope retrieval solution (pH 8.0, Enzo Life Sciences, Inc. United States), endogenous peroxidase was inactivated by incubation in 3% H<sub>2</sub>O<sub>2</sub> for 20 min. Next, the sections were pre-incubated with 10% normal goat serum and then incubated overnight with primary antibodies: p-STAT3 (Abcam, ab76315). The next day, after washing, sections were incubated with Alexa Fluoro 488 Goat Anti-Rabbit IgG (Jackson, 111-545-144). At last, sections were counterstained with DAPI (Sigma-Aldrich). Slides were imaged using the Carl Zeiss Scope.A1.

### **Statistical analysis**

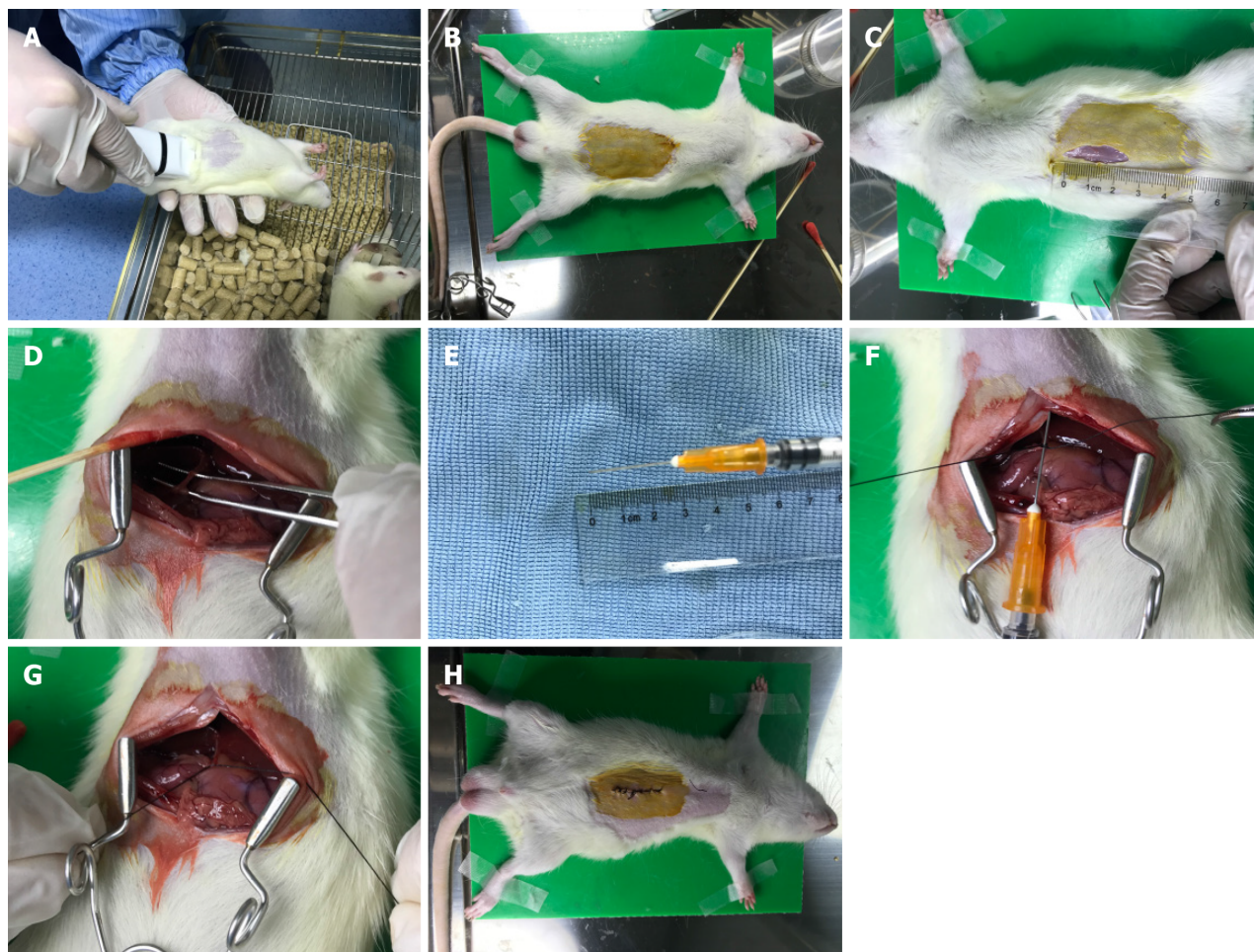
Data were shown as the medians ± IQRs or mean ± SEM depending on data characteristics. Statistical analysis was performed with SPSS18.0 and Graphpad Prism 6. Statistical P values were analyzed by a two-tailed Student's *t*-test. P values < 0.05 were considered statistically significant.



**Table 1 Primers of interleukin-6, signal transducer and activator of transcription 3, and GAPDH**

Gene	Gene ID	Forward primers	Reverse primers
IL-6	3569	GGTGGGTGTGTCCTCATTC	GGCATTGCATCCCTGAGTTG
STAT3	6774	GTGGGAAGAATCACGCCCTTC	AGATCCTGCACTCTCTTCCG
GAPDH	2597	GAACGGGAAGCTCACTGG	GCCTGCTTCACCACCTTCT

IL: Interleukin; STAT3: Signal transducer and activator of transcription 3.



**Figure 1 Surgical procedures of partial ligation of the bile duct of juvenile rats.** A: Anesthesia: 2.5% pentobarbital sodium (0.25 mL/100 g) was injected into the abdominal cavity; B: Positioning: After anesthesia, the rats were fixed with a supine position; C: Skin preparation: The hair was removed to expose about 5 cm × 3 cm of skin, followed by iodine disinfection; D: Bile duct isolation: The bile duct was located with forceps; E and F: Partial ligation: Place a 1 mL needle parallel to the bile duct and use 6-0 absorbable suture to ligate the bile duct and needle; G: Remove: The needle was removed after partial ligation; H: Closure of the incision: After ligation, and the incision was intermittently sutured.

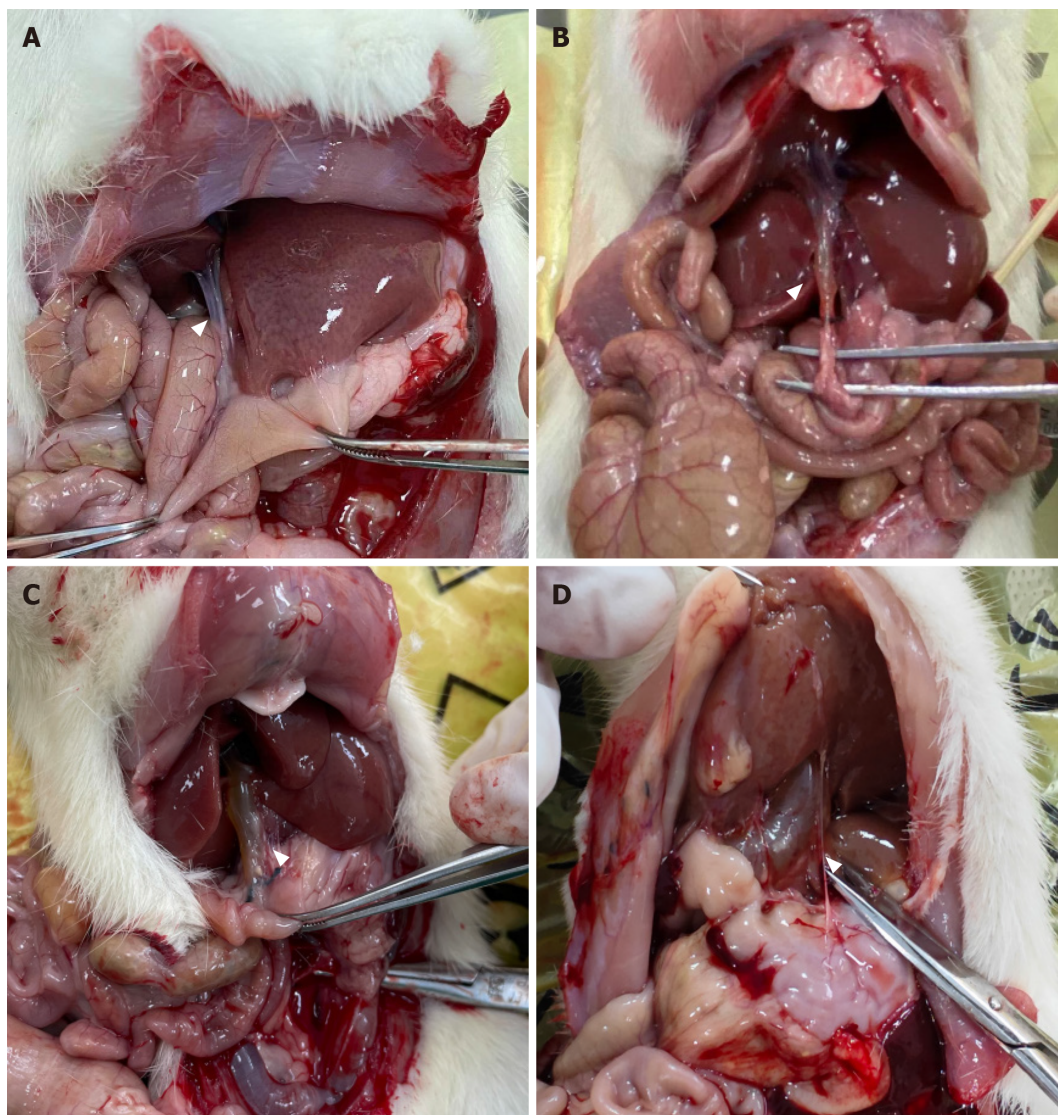
## RESULTS

### Rat models of CC

All 84 rats survived to the time of dissection. Rats in groups A-C showed varying degrees of dilation of the common bile ducts with slight damage to the liver, but no significant cholestasis or cirrhosis. Rats in group D developed slight adhesions around the surgical site and those in groups D-G showed no dilation of the common bile ducts. For normal rats, the diameter of the common bile duct is less than 1 mm. Based on measurements taken during dissection, dilation of the common bile duct was classified as none (< 1 mm), mild ( $\geq 1$  mm to < 3 mm), moderate ( $\geq 3$  mm to < 10 mm), and severe ( $\geq 10$  mm). Mild to moderate dilation resembled fusiform CC, while severe dilation resembled cystic CC11 (Figure 2). Bile duct dilation for each group is summarized in Table 2.

Table 2 Numbers of various degrees of bile duct dilation in each group				
Group	No dilation	Mild dilation	Moderate dilation	Severe dilation
	( $\varphi < 1\text{ mm}$ )	( $1\text{ mm} \leq \varphi < 3\text{ mm}$ )	( $3\text{ mm} \leq \varphi < 10\text{ mm}$ )	( $\varphi \geq 10\text{ mm}$ )
A	0	10	2	0
B	0	5	7	0
C	0	2	8	2
D	11	1	0	0
E-G	36	0	0	0

$\varphi$ : The maximum diameter of rat bile duct.

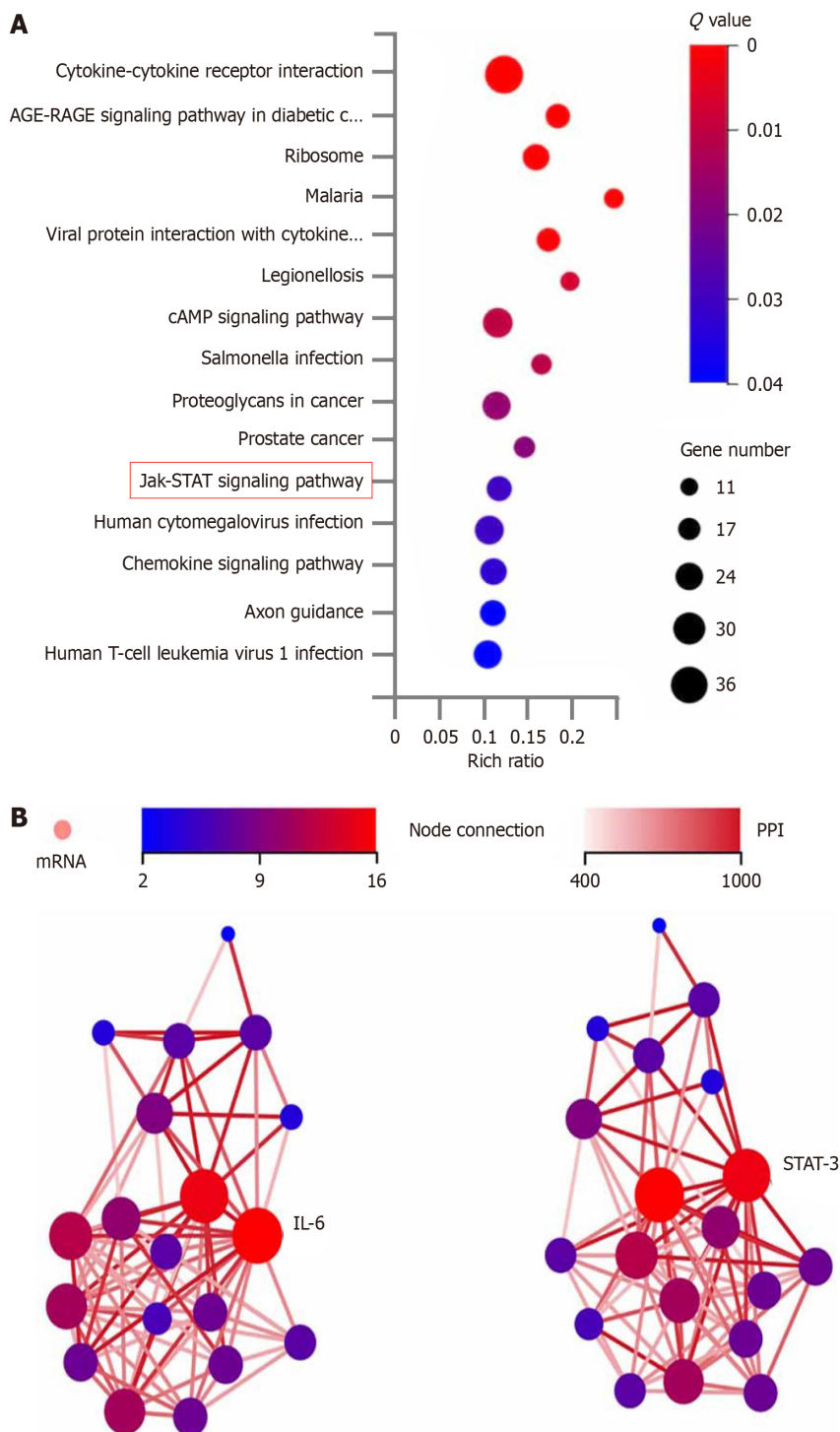


**Figure 2 Representative pictures of dilated bile ducts.** A: No dilation of the bile duct; B: Mild dilation of the bile duct; C: Moderate dilation of the bile duct; D: Severe dilation of the bile duct.

**Identification of differentially expressed genes in human tissues**

Of 103116 genes detected in the bile duct tissues between cystic and fusiform CCs, 993 were identified as differentially expressed genes (DEGs). Reference to the Kyoto Encyclopedia of Genes and Genomes (<https://www.genome.jp/kegg/>) revealed that 19 of the DEGs were enriched in the JAK-STAT signaling pathway (Figure 3). A protein-protein interaction network of the 19 DEGs in the JAK-STAT signaling pathway demonstrated that interleukin (IL)-6 had the highest node connectivity in the network, followed by the key factor STAT3 (Figure 3).

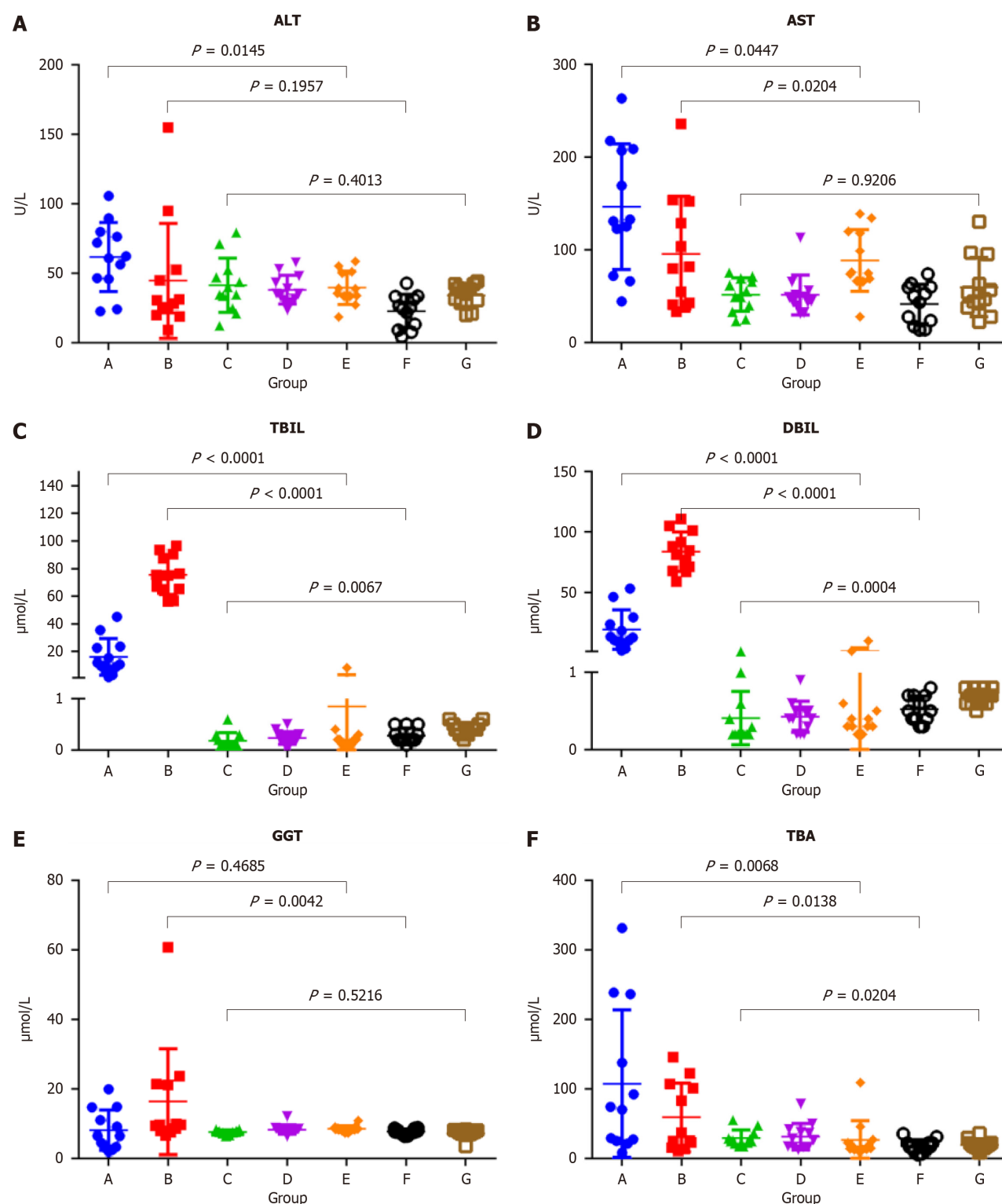




**Figure 3 Analysis of differentially expressed genes in human tissues.** A: Enrichment analysis of the differentially expressed genes (DEGs) by KEGG pathway; B: Protein interaction network analysis of the 19 DEGs in the JAK-STAT signaling pathway. IL: Interleukin; PPI: Protein interaction; STAT3: Signal transducer and activator of transcription 3.

### Levels of biochemical indices in rats

The mean normal serum concentrations (ranges) of ALT, AST, TBIL, DBIL, GGT, and TBA for female SD rats (groups E-G) were 33.55 (24.50-39.10) U/L, 59.60 (38.95-75.35) U/L, 0.60 (0.40-0.70)  $\mu\text{mol/L}$ , 0.30 (0.20-0.40)  $\mu\text{mol/L}$ , 7.95 (7.30-8.40)  $\mu\text{mol/L}$ , and 17.45 (13.55-22.27)  $\mu\text{mol/L}$ , respectively. Serum ALT levels were significantly higher in group A than group E ( $P = 0.0145$ ) and decreased to the normal range in group C. Serum AST levels were significantly higher in groups A and B than groups E and F ( $P = 0.0447$  and  $0.0204$ , respectively), and decreased to the normal range in group C. Serum TBIL levels were significantly higher in groups A and B than groups E and F (both,  $P < 0.0001$ ), significantly higher in group B than group A ( $P < 0.0001$ ), and decreased to the normal range in group C. Serum DBIL levels were significantly higher in groups A and B than groups E and F (both,  $P < 0.0001$ ), significantly higher in group B than group A ( $P < 0.0001$ ), and decreased to the normal range in group C. Serum GGT levels were significantly higher in group B than group F ( $P =$



**Figure 4 Comparison of biochemical indices levels in each group.** A: Alanine aminotransferase; B: Aspartate aminotransferase; C: Total bilirubin; D: Direct bilirubin; E: Gamma-glutamyltransferase; F: Total bile acids. ALT: Alanine aminotransferase; AST: Aspartate aminotransferase; TBIL: Total bilirubin; DBIL: Direct bilirubin; GGT: Gamma-glutamyltransferase; TBA: Total bile acids.

0.0042) and decreased to the normal range in group C. Serum TBA levels gradually decreased in group A-C, but were slightly higher than the normal range ( $P < 0.0204$ ) (Figure 4 and Table 3).

#### Western blot and immunofluorescence histochemical analyses for human and rats' tissues

The Western blot results of human bile duct tissues confirmed significant differences in the expression levels of p-STAT3 between cystic and fusiform CCs (Figure 4). Meanwhile, the Western blot results of the rat bile duct tissue (Figure 5A) showed upregulated expression of p-STAT3 on day 7 after partial ligation surgery, which further increased on day 14. However, p-STAT3 expression was significantly decreased on day 28. The expression level of p-STAT3 protein in group

**Table 3 Biochemical indices of rats in each group**

Biochemical indices	Group A	Group B	Group C	Group D	Group E	Group F	Group G
ALT (U/L)	61.55 (45.95-78.90)	29.30 (20.85-50.68)	37.40 (27.13-51.25)	35.20 (30.65-46.60)	37.15 (33.53-50.68)	24.80 (10.13-32.70)	35.90 (29.03-41.27)
AST (U/L)	131.80 (85.50-208.15)	80.60 (41.23-146.28)	52.30 (35.05-68.48)	46.60 (40.50-54.75)	75.20 (66.93-119.18)	46.75 (18.90-59.75)	50.20 (38.95-87.25)
TBIL (μmol/L)	12.90 (9.48-27.85)	82.90 (68.45-98.70)	0.20 (0.20-0.55)	0.40 (0.23-0.50)	0.35 (0.30-0.58)	0.50 (0.40-0.70)	0.70 (0.60-0.80)
DBIL (μmol/L)	11.25 (7.68-23.35)	75.20 (64.95-89.65)	0.10 (0.10-0.28)	0.20 (0.13-0.30)	0.20 (0.10-0.28)	0.20 (0.20-0.45)	0.40 (0.33-0.50)
GGT (μmol/L)	6.45 (3.15-13.78)	9.65 (8.08-21.33)	7.75 (7.38-7.90)	8.15 (7.83-8.45)	8.35 (8.05-8.90)	7.65 (7.18-8.48)	7.50 (7.00-8.08)
TBA (μmol/L)	72.05 (25.60-211.53)	31.25 (17.33-105.60)	25.55 (21.93-34.93)	27.45 (16.40-40.65)	16.45 (13.03-25.70)	17.05 (11.45-22.28)	18.10 (14.90-22.30)

ALT: Alanine aminotransferase; AST: Aspartate aminotransferase; TBIL: Total bilirubin; DBIL: Direct bilirubin; GGT: Gamma-glutamyltransferase; TBA: Total bile acids.

D-G were extremely low. And the expression level of STAT3 was significantly higher in groups A-D than groups E-G. Representative images of immunofluorescence staining of p-STAT3 in the bile duct tissues of groups B and F are shown in [Figure 5B](#). Notably, p-STAT3 expression was significantly greater in the epithelial cells of group B as compared to group F, indicating potential involvement of the JAK-STAT signaling pathway in bile duct dilation after partial ligation.

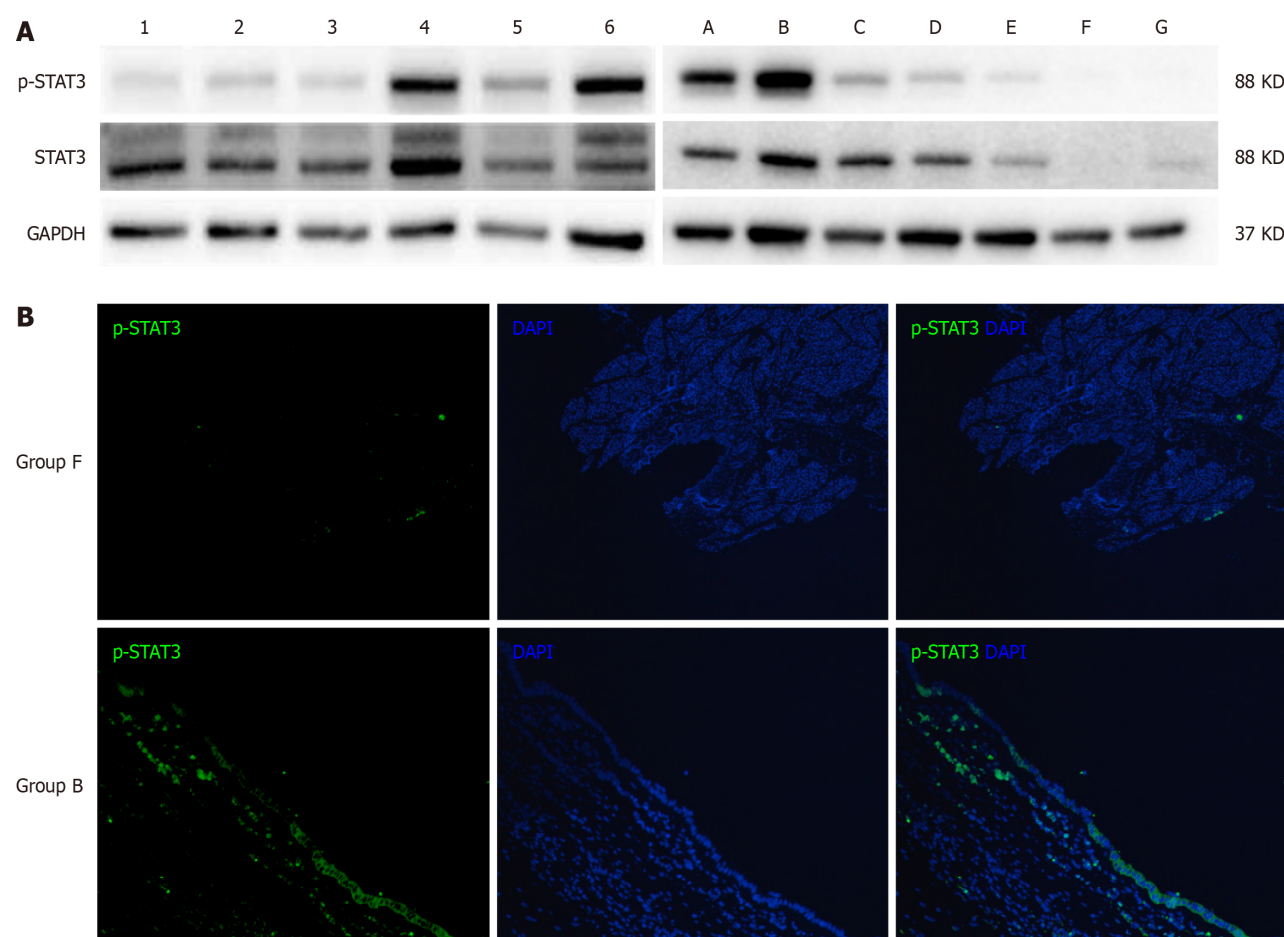
## DISCUSSION

Although the etiology of CC has been investigated for over a century, there is still a lack of appropriate animal models. In 1977, Spitz[6] reported an animal model of CC which involved distal ligation of the common bile duct in 2-d-old lambs. Subsequently, in 1979, Miyano *et al*[7] performed distal ligation of the common bile duct in 2-wk-old rats, thereby successfully establishing an animal model with dilated extrahepatic bile duct, while maintaining the normal intrahepatic bile duct. However, after the PBM hypothesis gained widespread recognition, subsequent animal models were mostly based on the anatomical structure of PBM. A dog model of PBM was initially constructed because of the similarity to the anatomical structures of the human pancreatic and bile ducts. Although anastomosis of the pancreatic and bile ducts causes abnormal anatomical structure and reflux of pancreatic juice, the refluxed pancreatic juice did not result in stenosis or typical cystic dilatation of the bile duct[12,13]. Improvements to the dog model have been attempted, such as partial ligation of the distal end of the common bile duct after pancreaticobiliary anastomosis[14]. However, it remains unclear whether dilation of the bile duct was caused by reflux of pancreatic juice, distal ligation, or both. In addition, most previous studies failed to provide an image of the model.

In our center, over 95% of CCs diagnosed prenatally are the cystic type and over 90% of cystic CCs were diagnosed in infants aged < 1 year. And several previous studies of CCs had reported the existence of distal stenosis of the bile duct[2, 15]. Babbitt[1], who proposed the hypothesis of PBM, also claimed that distal stenosis played a key role in the pathogenesis of bile duct dilation. Based on previous animal models, we conclude that morphological mimicry of CCs requires the use of an infant animal and stenosis of the distal bile duct. Therefore, we established a juvenile rat model by partial ligation of the distal bile duct. In the present study, all 36 rats in groups A-C and all 12 in group D survived to the day of dissection. The bile ducts of rats in groups A-C exhibited various degrees of dilation, but not those of the rats in group D. Notably, all rats with severe bile duct dilation were in group C. Therefore, this model is relatively stable and repeatable.

In this study, the cystic and fusiform dilations of the bile duct in the partially ligated rat model were morphologically similar to the cystic or fusiform CCs. Further analysis of biochemical indices showed that the serum levels of ALT, AST, DBIL, TBIL, and TBA were significantly elevated at 7 d after surgery, indicating that partial ligation of the bile duct simulated the pathological process of bile stasis caused by biliary obstruction. Meanwhile, serum levels of DBIL, TBIL, and GGT increased to higher levels at 14 d after surgery, and most indices, with the exception of TBA, gradually decreased to normal ranges at 28 d after surgery. These findings indicate that partial ligation of the bile duct results in increasing intra-cystic pressure and dilation of the bile ducts until bile production and outflow reached a dynamic equilibrium. Then, the indices returned to normal or near-normal levels. During this process, the bile duct continued to dilate and eventually formed cystic or fusiform CCs. Hence, partial ligation was more consistent with the natural course of CC formation than complete ligation. Meanwhile, the reliability of the partial ligation rat model was further validated





**Figure 5** Western blot and immunofluorescence histochemical analyses for human and rats' tissues. A: The western blot results for human bile duct tissues were on the left, numbers 1, 2, and 3 represent fusiform choledochal cysts (CCs), while numbers 4, 5, and 6 represent cystic CCs. The western blot results for rat bile duct tissues were on the right, representative picture of each group (group A-group G) was shown; B: The representative picture of the expression of phosphorylated signal transducer and activator of transcription 3 protein in group B and group F. STAT3: Signal transducer and activator of transcription 3.

by comparison to the characteristics of the human bile duct. Notably, activation of the IL-6/JAK/STAT3 signaling pathway, which is involved in cell proliferation and differentiation[16], was significantly elevated in cystic CCs. Also, immunofluorescence staining showed that expression of p-STAT3 was significantly elevated in the subepithelial layer of the bile duct, which may cause accelerated cell proliferation in the bile duct and make it easier for the formation of cystic dilation. In the rat model, p-STAT3 expression was also increased after partial ligation and gradually decreased at 28 days after surgery but was still higher than normal rats, which was consistent with the results of biochemical indices.

## CONCLUSION

In summary, our partial ligation of the bile duct in juvenile rats successfully morphologically simulated the cystic or fusiform human CCs. The postoperative disease progression was more consistent with the natural disease course of CC formation compared to complete ligation. Therefore, this stable and repeatable model can be utilized to investigate the pathogenesis of CC and further explore the causes of cystic and fusiform bile duct dilatations.

## ARTICLE HIGHLIGHTS

### Research background

Pancreaticobiliary maljunction (PBM) is the main hypothesis of choledochal cyst (CC). However, accumulating clinical evidence suggests that PBM cannot fully explain the pathogenesis of CC. Previously reported animal models, including models of anastomosis of the pancreatic and biliary ducts, models of complete ligation of the lower segment of the common bile duct, have been unable to adequately support basic researches on CCs.

### Research motivation

Satisfactory outcomes achieved with current surgical techniques for CCs have led to a pause in basic research on the pathogenesis of CCs. Thus, we need appropriate animal models of CCs to further basic researches.

### Research objectives

To establish a stable and repeatable animal model of CC based on partial ligation of the bile duct to investigate the pathogenesis of CCs.

### Research methods

Specific pathogen-free female SD rats were randomly allocated to a surgical group (partial ligation of the bile duct), sham surgical group, or control group. The partial ligation of the bile duct was performed by ligating a 1 mL needle and the bile duct together, followed by the careful removal of the needle after tightening the absorbable suture. The reliability of the model was confirmed through measurements of serum biochemical indices, the morphology of common bile duct and molecular biology experiments in rat and human tissues.

### Research results

All 84 rats survived to the time of dissection. Rats in the surgical group (groups A-C) showed varying degrees of dilation of the common bile ducts with slight damage to the liver and those in the sham surgical and control groups (groups D-G) showed no dilation of the common bile ducts. The changing trends of biochemical indexes indicated that the partially ligated bile ducts experienced a pathological process of recanalization after incomplete obstruction of the distal bile duct. And the reliability of the model was also confirmed by molecular biology experiments in rat and human tissues.

### Research conclusions

The model of partial ligation of the bile duct of juvenile rats could morphologically simulate the cystic or fusiform CCs. This stable and repeatable model was more consistent with the natural disease course of CC formation than complete ligation which may assist in the basic researches of CCs.

### Research perspectives

We hope our partial ligation of the bile duct of juvenile rats can promote the basic research of CCs and provide a reliable animal model for further research on the formation of cystic CCs or fusiform CCs.

---

## FOOTNOTES

**Author contributions:** Zhang SH designed and performed the research and wrote the paper; Gao ZG, Zhang YB, and Cai DT designed the research and supervised the report; Chen K, Jin Y, Luo WJ, and Huang ZW designed the research and contributed to the analysis; Chen QJ and Pan T provided clinical advice and supervised the report.

**Supported by** the Key R&D Program of Zhejiang, No. 2023C03029; Health Science and Technology Plan of Zhejiang Province, No. 2022RC201; and Zhejiang Provincial Natural Science Foundation Project, No. LY20H030007.

**Institutional review board statement:** The study was reviewed and approved by the Ethics Committee of The Children's Hospital, Zhejiang University School of Medicine (approval No. 2022-IRB-108). Prior to inclusion in this study, written informed consent was obtained from all subjects.

**Institutional animal care and use committee statement:** The protocol of the animal study was approved by the Institutional Animal Care and Use Committee of Laboratory Animal Center of Zhejiang University (approval No. ZJU20230273).

**Conflict-of-interest statement:** The authors declare that they have no conflict of interest.

**Data sharing statement:** No additional data are available.

**ARRIVE guidelines statement:** The authors have read the ARRIVE guidelines, and the manuscript was prepared and revised according to the ARRIVE guidelines.

**Open-Access:** This article is an open-access article that was selected by an in-house editor and fully peer-reviewed by external reviewers. It is distributed in accordance with the Creative Commons Attribution NonCommercial (CC BY-NC 4.0) license, which permits others to distribute, remix, adapt, build upon this work non-commercially, and license their derivative works on different terms, provided the original work is properly cited and the use is non-commercial. See: <https://creativecommons.org/licenses/by-nc/4.0/>

**Country/Territory of origin:** China

**ORCID number:** Shu-Hao Zhang 0000-0002-3124-9867; Zhi-Gang Gao 0009-0009-4020-7528.

**S-Editor:** Chen YL

L-Editor: A

P-Editor: Zheng XM

## REFERENCES

- 1 Babbitt DP. [Congenital choledochal cysts: new etiological concept based on anomalous relationships of the common bile duct and pancreatic bulb]. *Ann Radiol (Paris)* 1969; **12**: 231-240 [PMID: 5401505]
- 2 Greenholz SK. Antenatal diagnosis of choledochal cyst at 15 weeks' gestation: etiologic implications and management. *J Pediatr Surg* 1990; **25**: 584 [PMID: 2352098 DOI: 10.1016/0022-3468(90)90672-v]
- 3 Kolacek S, Puntis JW, Lloyd DR, Brown GA, Booth IW. Ontogeny of pancreatic exocrine function. *Arch Dis Child* 1990; **65**: 178-181 [PMID: 2317062 DOI: 10.1136/adc.65.2.178]
- 4 Ohkawa H, Sawaguchi S, Yamazaki Y, Sakaniwa M, Ishikawa A. The production of anomalous pancreaticobiliary ductal union in canine models. *Z Kinderchir* 1981; **32**: 328-336 [PMID: 7282070 DOI: 10.1055/s-2008-1063280]
- 5 Benhidjeb T, Said S, Rudolph B, Siegmund E. Anomalous pancreatobiliary junction--report of a new experimental model and review of the literature. *J Pediatr Surg* 1996; **31**: 1670-1674 [PMID: 8986984 DOI: 10.1016/s0022-3468(96)90045-7]
- 6 Spitz L. Experimental production of cystic dilatation of the common bile duct in neonatal lambs. *J Pediatr Surg* 1977; **12**: 39-42 [PMID: 833713 DOI: 10.1016/0022-3468(77)90293-7]
- 7 Miyano T, Suruga K, Suda K. Abnormal choledochopancreatic ductal junction related to the etiology of infantile obstructive jaundice diseases. *J Pediatr Surg* 1979; **14**: 16-26 [PMID: 423059 DOI: 10.1016/s0022-3468(79)80570-9]
- 8 Friedmacher F, Ford KE, Davenport M. Choledochal malformations: global research, scientific advances and key controversies. *Pediatr Surg Int* 2019; **35**: 273-282 [PMID: 30406431 DOI: 10.1007/s00383-018-4392-4]
- 9 Huang J, Qiu ZY, He J, Xu HS, Wang K, Du HY, Gao D, Zhao WN, Sun QG, Wang YS, Wen PZ, Li Q, Dong XO, Xie XZ, Jiang L, Wang HY, Liu YQ, Wan JM. Phytochrome B mediates dim-light-reduced insect resistance by promoting the ethylene pathway in rice. *Plant Physiol* 2023; **191**: 1272-1287 [PMID: 36437699 DOI: 10.1093/plphys/kiac518]
- 10 Abdi H. The Bonferroni and Šidák Corrections for Multiple Comparisons. encyclopedia of measurement & statistics. 2006. [cited 12 January 2023]. Available from: <https://www.semanticscholar.org/paper/The-Bonferroni-and-%C5%A0id%C3%A1k-Corrections-for-Multiple-Abdi/8b4300f253644d49c778c037ee614b9cf42a908c>
- 11 Livak KJ, Schmittgen TD. Analysis of relative gene expression data using real-time quantitative PCR and the 2<sup>-</sup>(Delta Delta C(T)) Method. *Methods* 2001; **25**: 402-408 [PMID: 11846609 DOI: 10.1006/meth.2001.1262]
- 12 Diao M, Li L, Cheng W. Congenital biliary dilatation may consist of 2 disease entities. *J Pediatr Surg* 2011; **46**: 1503-1509 [PMID: 21843715 DOI: 10.1016/j.jpedsurg.2010.12.022]
- 13 Oguchi Y. [Histopathological studies on congenital dilatation of the bile duct--with special reference to the regurgitation of pancreatic juice into the bile duct]. *Nihon Geka Gakkai Zasshi* 1986; **87**: 547-557 [PMID: 3713700]
- 14 Qian D, Jin BX. Experimental Study on the Etiology of Congenital Biliary Dilatation. *Chin J Pediatr Surg* 1990; **11**: 257-259 [DOI: 10.5223/pghn.2020.23.6.531]
- 15 Tsang TM, Tam PK, Chamberlain P. Obliteration of the distal bile duct in the development of congenital choledochal cyst. *J Pediatr Surg* 1994; **29**: 1582-1583 [PMID: 7877036 DOI: 10.1016/0022-3468(94)90224-0]
- 16 Huang B, Lang X, Li X. The role of IL-6/JAK2/STAT3 signaling pathway in cancers. *Front Oncol* 2022; **12**: 1023177 [PMID: 36591515 DOI: 10.3389/fonc.2022.1023177]



Published by **Baishideng Publishing Group Inc**  
7041 Koll Center Parkway, Suite 160, Pleasanton, CA 94566, USA

**Telephone:** +1-925-3991568

**E-mail:** [office@baishideng.com](mailto:office@baishideng.com)

**Help Desk:** <https://www.f6publishing.com/helpdesk>

<https://www.wjgnet.com>

