

# World Journal of *Diabetes*

*World J Diabetes* 2022 July 15; 13(7): 471-586



## EDITORIAL

- 471 Renin-angiotensin system blockers-SGLT2 inhibitors-mineralocorticoid receptor antagonists in diabetic kidney disease: A tale of the past two decades!  
*Singh AK, Singh R*

## REVIEW

- 482 Fetal programming of obesity and type 2 diabetes  
*Seneviratne SN, Rajindrajith S*
- 498 Biochemical composition of the glomerular extracellular matrix in patients with diabetic kidney disease  
*Adeva-Andany MM, Carneiro-Freire N*

## ORIGINAL ARTICLE

## Retrospective Cohort Study

- 521 Association between urinary concentrations of bisphenol A substitutes and diabetes in adults  
*Moreno-Gómez-Toledano R, Vélez-Vélez E, Arenas MI, Saura M, Bosch RJ*

## Retrospective Study

- 532 Efficacy and mechanism of anti-vascular endothelial growth factor drugs for diabetic macular edema patients  
*Li YF, Ren Q, Sun CH, Li L, Lian HD, Sun RX, Su X, Yu H*

## Observational Study

- 543 Elevated levels of fructosamine are independently associated with SARS-CoV-2 reinfection: A 12-mo follow-up study  
*Huang XY, Yang LJ, Hu X, Zhang XX, Gu X, Du LJ, He ZY, Gu XJ*

- 553 Factors associated with trabecular bone score in postmenopausal women with type 2 diabetes and normal bone mineral density  
*Fazullina ON, Korbut AI, Klimontov VV*

## Prospective Study

- 566 Relationship between quality of life and adolescent glycolipid metabolism disorder: A cohort study  
*Liang XH, Ren YL, Liang XY, Chen JY, Qu P, Tang X*

## LETTER TO THE EDITOR

- 581 More studies are necessary to establish the effectiveness of Jinhuang powder in the treatment of diabetic foot  
*Ye YW, Yan ZY, He LP, Li CP*

- 584**    Epidemiology for public health practice: The application of spatial epidemiology

*Liu L, Nagar G, Diarra O, Shosanya S, Sharma G, Afesumeh D, Krishna A*

**ABOUT COVER**

Editorial Board Member of *World Journal of Diabetes*, Agostino Di Ciaula, MD, Academic Fellow, Academic Research, Doctor, Medical Assistant, Clinica Medica "A. Murri", Department of Biomedical Sciences & Human Oncology, University of Bari Medical School, Bari 70124, Italy. agodiciaula@gmail.com

**AIMS AND SCOPE**

The primary aim of *World Journal of Diabetes* (WJD, *World J Diabetes*) is to provide scholars and readers from various fields of diabetes with a platform to publish high-quality basic and clinical research articles and communicate their research findings online.

WJD mainly publishes articles reporting research results and findings obtained in the field of diabetes and covering a wide range of topics including risk factors for diabetes, diabetes complications, experimental diabetes mellitus, type 1 diabetes mellitus, type 2 diabetes mellitus, gestational diabetes, diabetic angiopathies, diabetic cardiomyopathies, diabetic coma, diabetic ketoacidosis, diabetic nephropathies, diabetic neuropathies, Donohue syndrome, fetal macrosomia, and prediabetic state.

**INDEXING/ABSTRACTING**

The WJD is now abstracted and indexed in Science Citation Index Expanded (SCIE, also known as SciSearch®), Current Contents/Clinical Medicine, Journal Citation Reports/Science Edition, PubMed, PubMed Central, Reference Citation Analysis, China National Knowledge Infrastructure, China Science and Technology Journal Database, and Superstar Journals Database. The 2022 Edition of Journal Citation Reports® cites the 2021 impact factor (IF) for WJD as 4.560; IF without journal self cites: 4.450; 5-year IF: 5.370; Journal Citation Indicator: 0.62; Ranking: 62 among 146 journals in endocrinology and metabolism; and Quartile category: Q2.

**RESPONSIBLE EDITORS FOR THIS ISSUE**

Production Editor: *Yu-Xi Chen*; Production Department Director: *Xu Guo*; Editorial Office Director: *Jia-Ping Yan*.

**NAME OF JOURNAL**

*World Journal of Diabetes*

**ISSN**

ISSN 1948-9358 (online)

**LAUNCH DATE**

June 15, 2010

**FREQUENCY**

Monthly

**EDITORS-IN-CHIEF**

Lu Cai, Md. Shahidul Islam, Jian-Bo Xiao, Michael Horowitz

**EDITORIAL BOARD MEMBERS**

<https://www.wjnet.com/1948-9358/editorialboard.htm>

**PUBLICATION DATE**

July 15, 2022

**COPYRIGHT**

© 2022 Baishideng Publishing Group Inc

**INSTRUCTIONS TO AUTHORS**

<https://www.wjnet.com/bpg/gerinfo/204>

**GUIDELINES FOR ETHICS DOCUMENTS**

<https://www.wjnet.com/bpg/GerInfo/287>

**GUIDELINES FOR NON-NATIVE SPEAKERS OF ENGLISH**

<https://www.wjnet.com/bpg/gerinfo/240>

**PUBLICATION ETHICS**

<https://www.wjnet.com/bpg/GerInfo/288>

**PUBLICATION MISCONDUCT**

<https://www.wjnet.com/bpg/gerinfo/208>

**ARTICLE PROCESSING CHARGE**

<https://www.wjnet.com/bpg/gerinfo/242>

**STEPS FOR SUBMITTING MANUSCRIPTS**

<https://www.wjnet.com/bpg/GerInfo/239>

**ONLINE SUBMISSION**

<https://www.f6publishing.com>

## Biochemical composition of the glomerular extracellular matrix in patients with diabetic kidney disease

María M Adeva-Andany, Natalia Carneiro-Freire

**Specialty type:** Medicine, general and internal

**Provenance and peer review:** Invited article; Externally peer reviewed.

**Peer-review model:** Single blind

**Peer-review report's scientific quality classification**

Grade A (Excellent): 0  
Grade B (Very good): B  
Grade C (Good): C  
Grade D (Fair): 0  
Grade E (Poor): 0

**P-Reviewer:** Bayoumi RAL, United Arab Emirates; Javor E, Croatia

**Received:** February 1, 2022

**Peer-review started:** February 1, 2022

**First decision:** April 18, 2022

**Revised:** April 19, 2022

**Accepted:** June 24, 2022

**Article in press:** June 24, 2022

**Published online:** July 15, 2022



**María M Adeva-Andany, Natalia Carneiro-Freire**, Nephrology, Hospital Juan Cardona, Ferrol 15406, Spain

**Corresponding author:** María M Adeva-Andany, MD, PhD, Consultant Physician-Scientist, Nephrology, Hospital Juan Cardona, Pardo Bazán x/n, Ferrol 15406, Spain.  
[madevaa@yahoo.com](mailto:madevaa@yahoo.com)

### Abstract

In the glomeruli, mesangial cells produce mesangial matrix while podocytes wrap glomerular capillaries with cellular extensions named foot processes and tether the glomerular basement membrane (GBM). The turnover of the mature GBM and the ability of adult podocytes to repair injured GBM are unclear. The actin cytoskeleton is a major cytoplasmic component of podocyte foot processes and links the cell to the GBM. Predominant components of the normal glomerular extracellular matrix (ECM) include glycosaminoglycans, proteoglycans, laminins, fibronectin-1, and several types of collagen. In patients with diabetes, multiorgan composition of extracellular tissues is anomalous, including the kidney, so that the constitution and arrangement of glomerular ECM is profoundly altered. In patients with diabetic kidney disease (DKD), the global quantity of glomerular ECM is increased. The level of sulfated proteoglycans is reduced while hyaluronic acid is augmented, compared to control subjects. The concentration of mesangial fibronectin-1 varies depending on the stage of DKD. Mesangial type III collagen is abundant in patients with DKD, unlike normal kidneys. The amount of type V and type VI collagens is higher in DKD and increases with the progression of the disease. The GBM contains lower amount of type IV collagen in DKD compared to normal tissue. Further, genetic variants in the  $\alpha 3$  chain of type IV collagen may modulate susceptibility to DKD and end-stage kidney disease. Human cellular models of glomerular cells, analyses of human glomerular proteome, and improved microscopy procedures have been developed to investigate the molecular composition and organization of the human glomerular ECM.

**Key Words:** Diabetes; Kidney disease; Glycosaminoglycans; Factor H; Sialic acid; Laminin; Collagen; Fibronectin-1; Extracellular matrix

©The Author(s) 2022. Published by Baishideng Publishing Group Inc. All rights reserved.

**Core Tip:** Diabetic kidney disease is associated with profound disturbance in glomerular extracellular matrix (ECM). Understanding the mechanisms that regulate glomerular ECM synthesis and repair may contribute to design therapeutic strategies that improve clinical outcomes. The cytoskeleton inside the foot processes of podocytes is connected to the glomerular basement membrane (GBM) *via* associated proteins. There is a reciprocal interaction between the cellular cytoskeleton and the extracellular tissue that contribute to regulate ECM composition. Loss of anchor points in the GBM may lead to podocyte detachment. Likewise, alterations in the podocyte cytoskeleton may unfasten the cell and impair the filtration barrier.

**Citation:** Adeva-Andany MM, Carneiro-Freire N. Biochemical composition of the glomerular extracellular matrix in patients with diabetic kidney disease. *World J Diabetes* 2022; 13(7): 498-520

**URL:** <https://www.wjgnet.com/1948-9358/full/v13/i7/498.htm>

**DOI:** <https://dx.doi.org/10.4239/wjd.v13.i7.498>

## INTRODUCTION

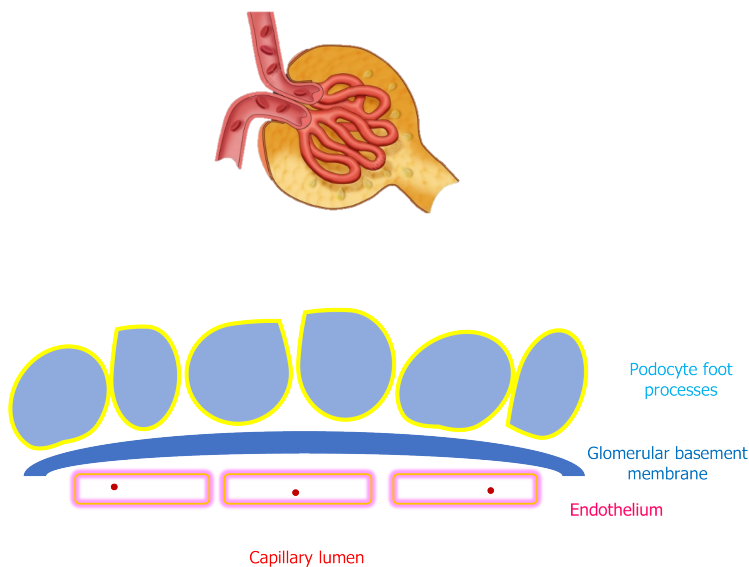
In human glomeruli, mesangial cells (which are thought to be akin to vascular smooth muscle cells) produce mesangial matrix while podocytes wrap glomerular capillaries with cellular extensions named foot processes and tether underneath glomerular basement membrane (GBM) (Figure 1). The turnover of the GBM present at birth and the ability of adult podocytes to restore damaged GBM are unclear. These cells have limited proliferation capacity, but they can undergo hypertrophy to compensate for the detachment and loss of contiguous podocytes, thus avoiding uncovered GBM areas to preserve the filtration barrier. Podocyte detachment may be caused by an altered composition of the GBM with deficiency of anchor points or by anomalies in the connection apparatus that links the foot processes to the GBM. The actin cytoskeleton is a major cytoplasmic component of the podocyte foot processes and connects the cell to the GBM. Actin-associated proteins such as  $\alpha$ -actinin-4 and inverted formin-2 attach the actin cytoskeleton to plasma membrane components (such as integrins, syndecans and dystroglycans), which in turn bind to their ligands in the GBM, including laminin and fibronectin-1[1-4]. The integrity of the GBM is crucial to maintain the filtration barrier, as highlighted by the clinical consequences of disorders that alter GBM components, such as laminin or collagen. Diabetes and other conditions associated with insulin resistance (such as Alström syndrome) are associated with a systemic and pronounced alteration in the composition of extracellular matrix (ECM), including the kidney and the blood vessels, that leads to multi-organ interstitial fibrosis[5]. Pathogenic mechanisms underlying this disturbance are unclear. Understanding the pathways of ECM assembly and remodeling and the cell-ECM interactions is crucial for designing therapeutic strategies and tissue engineering. A growing number of procedures have been improved and developed to investigate the biochemical composition and architecture of the ECM and its mutual interaction with the contiguous cells. Among them are biochemical assays to identify and quantify ECM components, genetic methods to investigate gene expression, imaging procedures, human cell cultures, and *in vitro* pharmacological evaluations to assess metabolic pathways.

Nuclear magnetic resonance spectroscopy and soft-ionization mass spectrometry represent complementary techniques for ECM research. Mass spectrometry techniques (such as matrix-assisted laser desorption and ionization) are useful for compositional analysis whereas nuclear magnetic resonance spectroscopy evaluates the molecular architecture of the ECM and its dynamics[6]. Raman spectroscopy is a label-free vibrational technique that contributes to characterize the molecular ECM structure and composition[7,8].

Histological methods for ECM analysis with conventional microscopy include immunohistochemistry and zymography. The former can be utilized to determine the localization of various ECM proteins while the latter may be used to evaluate proteinase activity in the ECM. In addition, imaging methods have been designed to characterize the human ECM and the adjacent cells at the molecular and cellular level. Scanning electron microscopy and multi-harmonic generation microscopy can be used to visualize ECM components and assess their structural properties[9]. Multiphoton imaging has been described to analyze the human structural organization of elastin and collagen during mechanical loading[10].

The construction of flat and tubular collagen gel-based scaffolds cellularized with vascular smooth muscle cells have enriched vascular tissue engineering[11]. Microgel assembly, a macroscopic aggregate formed by assembly of microgels, can be applied to tissue engineering and cell cultures[12].

A variety of genetic techniques are useful on ECM research. MicroRNAs are noncoding RNAs that regulate gene expression and participate in ECM pathophysiology. Microarrays can be used to determine microRNA profiles[13]. Weighted gene co-expression network analysis enables the identification of clusters of related genes that can be associated with specific clinical phenotypes. This technique has been used to assess differentially expressed ECM genes in patients with diabetic kidney



DOI: 10.4239/wjd.v13.i7.498 Copyright ©The Author(s) 2022.

**Figure 1** Glomerular capillaries and glomerular basement membrane.

disease (DKD) and other glomerular diseases[14,15]. The Matrisome Project has been developed to characterize genes encoding structural and associated ECM proteins (<http://matrisomeproject.mit.edu>).

Human cell culture technology and pharmacological investigations on cultured cells are instrumental tools on ECM research. Human pluripotent stem cells in culture have been used to generate models of various tissues. The presence of ECM in the cultures provides cues to the cells that modify their behavior and improves similarity to the native human tissue, including the kidney[16]. Stem cells reside in “niches” within the ECM and the composition of the ECM contributes to define the degree of quiescence and turnover of these cells[17]. Manufacture of a suitable ECM is crucial to alter growth, differentiation, and proliferation of stem cells and use them for tissue engineering[18]. Three-dimensional decellularized ECM derived from mesenchymal stem cell cultures has been attained by application of macromolecular crowding[19]. Three-dimensional tissue constructs that recapitulate human fibrous connective tissue have been achieved by using cultures of primary human fibroblasts, enabling the quantification of cell-derived changes in ECM synthesis in response to several stimuli, such as nutrient composition or pharmacological compounds[20]. Treatment of human bone marrow-derived mesenchymal cells with high molecular weight hyaluronic acid increases fibronectin production and ECM deposition, suggesting that hyaluronic acid-based biomaterials may be useful to promote ECM formation[21]. A pulsatile perfusion culture of progenitor cells has been developed as an *in vitro* system to construct vascular tissue[22]. Cell-matrix interactions may be investigated by micro-electro-mechanical systems and Organ-on-a-Chip technology[23].

In the kidney, human cellular models of glomerular epithelial cells have been developed that can be used to evaluate podocyte pathophysiology and investigate therapeutic strategies[24]. Investigations of the glomerular proteome have provided information on the proteins expressed in the glomerular ECM of adult normal human kidney. A database has been created that may be used for clinical research on the pathophysiology of kidney diseases[25-27]. Proteomic analysis of human glomerular ECM may be conducted from sections retrieved by kidney biopsy samples[28]. The sub-diffraction resolution stochastic optical reconstruction microscopy (STORM) facilitates the investigation of the molecular organization within the human GBM[29].

## NORMAL COMPOSITION OF THE HUMAN GBM AND MESANGIAL MATRIX

The analysis of the specific composition of the GBM and mesangial matrix is hindered by the technical obstacle of adequately separate these two compartments of glomerular ECM, as procedures that isolate glomerular ECM achieve samples that contain both GBM and mesangial matrix. However, immunohistochemical analyses contribute to determine the differential constitution of the two structures (Table 1) [27,30-32]. Major components of the normal glomerular ECM are laminin and collagen. In addition, glycosaminoglycans, proteoglycans, sialic acid, and fibronectin-1 are important constituents of the kidney ECM in humans.



**Table 1 Major components of the glomerular basement membrane and the mesangial matrix in normal human glomeruli**

	Glomerular basement membrane	Mesangial matrix
Heparan sulfate proteoglycan	Abundant	Abundant
Laminin	Major component	Minor component
Fibronectin	Minor component	Major component
Type I collagen	Absent in most studies	Absent in most studies
Type III collagen	Absent in most studies	Absent in most studies
Type IV collagen	Major component	Present (inconsistent amounts)
Type V collagen	Present	Present
Type VI collagen	Present	Present
Type XVII collagen	Present	Unknown
Type XVIII collagen	Present	Present
Tubulointerstitial nephritis antigen-like-1	Low abundance	High abundance
Nidogen / Entactin	Present	Low abundance
Fibulin-1	Present	Present
Fibrillin-1	Present	Present
Nephronectin	Present	Present
Vitronectin	Absent	Present
Microfibril-associated proteins	Absent	Present

### ***Glycosaminoglycans, proteoglycans, and sialic acid in the normal glomerulus***

Proteoglycans consist of a core protein attached to one or more glycosaminoglycan chains, which are formed by linear polysaccharides. Sulfate groups are usually bound to the unbranched polysaccharide chains, creating a high negative charge[33,34].

In kidney specimens from healthy humans, heparan sulfate is the predominant glycosaminoglycan present in the glomerular ECM, followed by hyaluronate, dermatan sulfate, and chondroitin sulfate isomers 4-sulfate and 6-sulfate[35-37].

Immunohistochemical studies show that both GBM and mesangial matrix contain heparan sulfate proteoglycans[33,38-40]. Among them, mass spectrometry-based analyses of normal human kidney samples reveal that agrin and perlecan are present in the glomerular proteome[27]. Agrin is a major heparan sulfate proteoglycan present in human GBM. Immunoelectron microscopy shows a linear distribution of agrin throughout the width of the normal GBM. In addition to the GBM, agrin mRNA and protein are detected in normal lungs[34,41]. Localization of agrin to the human GBM has been confirmed by STORM. Using this procedure, agrin is predominantly detected at the epithelial surface compared to the endothelial aspect of the GBM[29]. The precise function of agrin in the human kidney has not been defined, but it may contribute to the adhesion of the GBM to the podocyte by tethering laminins to cell surface receptors such as integrins or  $\alpha$ -dystroglycan[34,41]. In normal human kidney specimens, perlecan stained the GBM only slightly, in contrast to the strong staining of the mesangium, the Bowman's capsule, and the tubular basement membrane. The function of this heparan sulfate proteoglycan in the normal kidney remains to be clarified[34,42,43]. Unlike agrin, immunoelectron microscopy shows that perlecan is distributed only on the endothelial side of the GBM[34].

Sialic acid (neuraminic acid) is a nine-carbon carbohydrate that may exist as several derivatives. In humans, the most common sialic acid byproduct is the acetylated compound N-acetyl-neuraminic acid. Sialic acid typically occupies the terminal domain of oligosaccharide chains of some glycolipids and glycoproteins and usually protrudes from the cell surface. Sialidases (neuraminidases) are enzymes that remove sialic acid residues from glycosaminoglycans attached to proteins or lipids on the cell surface (desialylation). Sialyltransferases catalyze the addition of sialic acid residues to glycosaminoglycans (sialylation). Sialylated conjugates are identified by specific binding to lectins or by cationic dyes such as alcian blue[44,45]. In normal human kidney specimens, sialic acid stains strongly the podocytes, unlike glomerular capillaries and Bowman's capsule[44].

Both sulfated glycosaminoglycans and sialic acid are polyanions that have an essential role in the identification of "self" structures to avoid complement activation and subsequent complement-mediated injury in host tissues[46-49]. Sulfation can occur at various positions within the glycosaminoglycan structure creating the potential for high molecular variability. The unique position of sulfate groups in the glycosaminoglycan molecule is named sulfation code and defines functional character-



istics of the sulfated glycosaminoglycan, such as its interaction with proteins. Hyaluronic acid is a glycosaminoglycan that lacks sulfate groups and is not attached to a protein core to form proteoglycans [50]. Factor H is a glycoprotein that inhibits the alternative pathway of complement in “self” structures (as opposed to foreign elements such as pathogens), by recognizing sialic acid or sulfated glycosaminoglycans present on “self” biological surfaces. The interaction between factor H and sulfated glycosaminoglycans is highly specific and depends upon the sulfation code. Little or no binding occurs with hyaluronic acid. The binding of factor H to sialic acid or sulfated glycosaminoglycans on biological surfaces protects the host from autolytic complement attack (Figure 2). Deficit of binding sites for factor H due to loss of sulfated glycosaminoglycans or sialic acid (or alteration of the sulfation code or the sialylation pattern) impairs factor H binding to “self” structures and may result in complement-mediated damage due to unrestrained activation of the alternative pathway of complement [46,48,49,51-54].

### **Laminin in the normal glomerulus**

Protein quantification of the glomerular ECM proteome by mass spectrometry reveals that laminin isoforms and type IV collagen are the most abundant proteins in the glomerular ECM [27]. Laminins are heterotrimeric proteins composed of  $\alpha$ ,  $\beta$ , and  $\gamma$  glycoprotein chains. Different  $\alpha$ ,  $\beta$ , and  $\gamma$  chains create diverse isoforms of laminin heterotrimers, such as laminin  $\alpha 5/\beta 2/\gamma 1$  (laminin 521). Laminin heterotrimers polymerize in the extracellular space to form a network. Laminin polymerization is required for initiation of basement membrane formation. The actin cytoskeleton plays an important role in extracellular laminin polymerization. *In vitro* studies using myotubes reveal that the organization of extracellular laminin into networks is abnormal when the actin cytoskeleton is disrupted with cytochalasin (an agent that prevents actin polymerization) compared to control myotubes free of this compound. Cytochalasin-treated myotubes show no arrangement of surface laminin into complex networks, unlike control myotubes that show normal laminin array. However, no detrimental effect on laminin network formation was observed with wortmannin, an inhibitor of phosphatidylinositol 3-kinase [55].

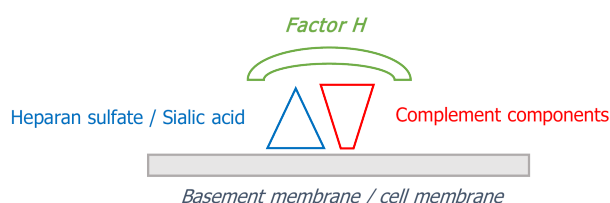
Laminin isoforms has been identified in the mesangial matrix of normal human kidneys, although this protein is predominantly detected in the GBM. Immunohistochemical studies show a continuous staining for laminin in the normal GBM. Immunogold electron microscopy reveals that laminin is distributed throughout the entire thickness of the GBM [37-40,56]. The organization of laminin 521 in normal human GBM has been investigated with STORM. Laminin 521 (and agrin) have their N-terminal domains facing the interior of the GBM while their C-terminal domains are oriented towards the surface of endothelial cells and podocytes [29].

The important functional role of laminin in the glomeruli is underlined by the clinical consequences of genetic mutations that alter the protein. Mutations in the gene that codes the  $\beta 2$  chain of laminin cause an autosomal recessive clinical spectrum of disorders that ranges from isolated congenital nephrotic syndrome (type 5) to Pierson syndrome, which consists of a combination of ocular abnormalities, neurological manifestations due to defects of the neuromuscular junction, and congenital nephrotic syndrome with diffuse mesangial sclerosis progressing rapidly to end-stage kidney disease (ESKD) [57,58].

### **Fibronectin-1 in the normal glomerulus**

Fibronectin-1 is a dimeric glycoprotein circulating in normal plasma and present in the healthy human kidney. Immunohistochemical studies show that fibronectin-1 is mainly present in the mesangium and to a far less degree in the GBM. Staining for fibronectin-1 also occurs in the Bowman's capsule and the peritubular interstitium [27,37,39,40,59,60]. The function of fibronectin-1 in the kidney is largely unknown. *In vitro* studies using cultured fibronectin-null cell lines find that fibronectin-1 polymerization in the ECM is involved in the deposition of other ECM components, such as fibulin, type III collagen, and type I collagen [61]. Fibronectin-1 possesses several domains that may function as binding sites for other molecules, including collagen and cell surface proteins such as integrins. Fibronectin-1 may connect to plasma membrane proteins which in turn are linked to the intracellular actin cytoskeleton. There is a reciprocal relationship between fibronectin-1 and the actin cytoskeleton. Agents that disrupt actin polymerization block the extracellular organization of fibronectin-1 into a network. In turn, inhibition of fibronectin-1 polymerization in the ECM induces changes in the actin cytoskeleton [62]. *In vitro* studies using cultured human podocytes show that fibronectin-1 is essential for the attachment of podocytes to the GBM during mechanical stress. Mechanical stretch induces a marked upregulation of fibronectin-1 in normal podocytes. Accordingly, in podocyte cell lines lacking fibronectin-1, a loss of podocytes greater than 80% is observed following mechanical stress [4].

An abnormal glomerular accumulation of fibronectin-1 may occur in acquired disorders, such as DKD and other diseases that feature mesangial expansion, such as lupus nephritis, IgA nephropathy, and membranoproliferative glomerulonephritis [62-65]. In addition, glomerulopathy with fibronectin-1 deposits (fibronectin nephropathy) is an autosomal dominant disease characterized by deposits of fibronectin-1 in the mesangial matrix and subendothelial space. Mutations in the *FN1* locus (that encodes fibronectin-1) at 2q32 have been identified as the genetic cause of the disease [63]. Clinical manifestations include proteinuria, hematuria, hypertension, and kidney failure that may progress to



DOI: 10.4239/wjd.v13.i7.498 Copyright ©The Author(s) 2022.

**Figure 2 Binding of complement factor H to components of the alternative pathway of complement (C3b) and heparan sulfate/sialic acid on “self” structures (cell membranes or basement membranes).**

ESKD. Asymptomatic patients harboring *FN1* mutations have been documented. Light microscopy reveals enlarged glomeruli with deposits of eosinophilic material in the mesangium and subendothelial space that shows reactivity with periodic acid Schiff (PAS) and trichrome stains while methenamine silver and Congo red stain negative. No immunoglobulin or complement factors are detectable by immunofluorescence studies. Electron microscopy reveals a normal GBM and large electron-dense deposits in the mesangium extending to the subendothelial space. Diagnosis can be established by specific immunohistochemical analysis, as the glomerular deposits stain intensely with anti-fibronectin-1 antibodies (Table 2)[62-65].

### Collagen in the normal glomerulus

Initial studies suggested the presence of collagen in normal human glomerular ECM by the high amount of glycine, hydroxyproline, and hydroxylysine in glomerular extracts[30,66-68]. Relative protein quantification confirms an abundant amount of type I, type IV, and type VI collagen in human glomerular ECM. As mentioned, type IV collagen and laminin are the most abundant proteins in the normal glomerular ECM[27].

**Type I collagen in the normal glomerulus:** Some studies fail to find type I collagen in normal human glomerular ECM, either the GBM or the mesangium[39,40,69]. However, mass spectrometry performed in adult kidney samples identifies abundant type I collagen in the glomerular ECM, although its localization to a specific glomerular ECM sector (GBM, mesangial matrix, or other) is undefined[27].

**Type III collagen in the normal glomerulus:** Type III collagen mRNA or protein have not been detected in healthy human glomeruli. Neither the mesangial matrix nor the GBM normally possess type III collagen[33,38-40,69-71]. However, type III collagen has been observed in sclerotic glomeruli, suggesting that production of this collagen type is linked to the progression of glomerular sclerosis[69]. In addition, glomerular type III collagen has been demonstrated in human kidney diseases, such as DKD, LIM homeodomain transcription factor-1 $\beta$  (LMX1 $\beta$ )-associated nephropathy (LAN) and type III collagen glomerulopathy.

Heterozygous loss of function mutations in the *LMX1 $\beta$*  gene (located on chromosome 9q34) cause LAN. Patients with LAN may present with isolated nephropathy or may exhibit additional extrarenal clinical manifestations composing the nail-patella syndrome[72,73]. The LMX1 $\beta$  protein is a transcription factor that possesses two LIM domains (cysteine rich sequences that usually mediate protein-protein interactions) and a homeodomain that regulates target gene transcription. The precise role of the LIM-homeodomain protein LMX1 $\beta$  in humans remains unknown[74,75]. Nail-patella syndrome or onychosteodysplasia is characterized by the association of nail hypoplasia or dysplasia, bone abnormalities that affect the knees, elbows, and pelvis, glaucoma, sensorineural hearing impairment, and nephropathy. Renal manifestations include hematuria, proteinuria, and kidney failure that may evolve to ESKD. *LMX1 $\beta$*  mutations may also cause isolated autosomal dominant kidney involvement with no extrarenal manifestations[72,73,75-78]. LAN is characterized by deposition of type III collagen within the GBM on electron microscopy examination. Fibrillar type III collagen bundles may be seen occasionally in the mesangial matrix as well. The GBM may demonstrate focal irregular thickening, thinning, splitting, or wrinkling and may contain patchy electron-lucent (“moth-eaten”) areas. Hyperplasia and effacement of podocyte foot processes is usually observed. The basement membrane of kidney tubules appears markedly thickened and demonstrates type III collagen deposition[78,79]. Light microscopy examination may reveal focal segmental glomerulosclerosis (FSGS) or unremarkable findings, such as mild interstitial fibrosis or mesangial proliferation. Immunofluorescence microscopy yields negative or non-specific findings, such as slight granular deposits of C3 in the mesangium. Specific immunohistochemical analyses show that the fibrillar material present within the GBM (and occasionally the mesangial matrix) is type III collagen[78-82]. The histological phenotype of LAN is expanding, as heterozygous mutations in the *LMX1 $\beta$*  gene have been reported in patients with autosomal dominant FSGS without ultrastructural abnormalities of the GBM and in families with FSGS and myelin figures and zebra bodies (electron-dense multilamellar inclusions) in podocytes, mesangial

**Table 2 Staining characteristics of the mesangial deposits in diabetic kidney diseases, fibronectin-1 nephropathy, and type III collagen glomerulopathy**

	Periodic acid Schiff	Methenamine silver	Congo red	Specific analysis
Diabetic kidney disease	Positive	Positive	Negative	Unknown material
Fibronectin-1 nephropathy	Positive	Negative	Negative	Fibronectin-1
Type III collagen nephropathy	Negative	Negative	Negative	Type III collagen

cells, and tubular epithelium. Patients affected with LAN and myelin figures and zebra bodies are free of Fabry's disease, which is the typical cause of these inclusions. Therefore, *LMX1 $\beta$*  pathogenic variants should be ruled out as a potential cause of autosomal dominant kidney disease, sporadic and hereditary forms of FSGS, and steroid-resistant nephrotic syndrome, regardless of extrarenal manifestations. In addition, the presence of myelin figures or zebra bodies may hint toward LAN diagnosis in patients free of lysosomal storage disorders or drug-induced phospholipidosis, although the mechanism underlying the appearance of these structures in LAN is unclear[80,82,83].

Type III collagen glomerulopathy (collagenofibrotic glomerulopathy) is characterized by deposition of type III collagen fibrils within the mesangial matrix and along the subendothelial aspect of a normal GBM. The cause of the excessive production and deposition of type III collagen in the glomeruli is unknown. The diagnosis of the disease is confirmed by electron microscopy and specific immunohistochemistry demonstrating the presence of mesangial type III collagen. Light microscopy reveals diffuse mesangial expansion that cause glomerular enlargement. In the advanced stage, the expanded mesangium shows a lobular appearance reminiscent of Kimmelstiel-Wilson nodules of DKD. In addition, the subendothelial accumulation of this material causes double contour or "reduplication" of the GBM. Unlike DKD, the amorphous material present in the mesangium stains negative with PAS. Masson's trichrome stain identifies the blue-colored collagen within the mesangium. Immunofluorescence microscopy studies are negative for immunoglobulins and complement components. Immunohistochemistry reveals strong staining for antibodies to type III collagen in the widened mesangial and subendothelial areas. Electron microscopy reveals a normal GBM and confirms the accumulation of electron-dense fibrillar material consistent with dense collagen bundles in mesangial and subendothelial zones. The fibrils exhibit a transverse band structure with distinctive periodicity suggesting type III collagen fibers. The mesangium and subendothelium acquire a mottled appearance due to the presence of collagen fibrils[84-86]. Accumulation of mesangial type III collagen has been reported in one patient with inherited factor H deficiency[87].

**Type IV collagen in the normal glomerulus:** Type IV collagen is an abundant protein of the glomerular ECM and may be observed in the GBM and the mesangium. In the normal GBM, a distinct continuous staining for type IV collagen indicates that this collagen type is a predominant component[27,31,37,39,71,88].

The molecule of type IV collagen consists of three  $\alpha$  chains. Six genes (*COL4A1-6*) encode six different  $\alpha$  chains that create several isoforms of type IV collagen. The  $\alpha 3$ ,  $\alpha 4$ , and  $\alpha 5$  chains of type IV collagen contain more cysteine than the chains  $\alpha 1$  and  $\alpha 2$ . Therefore,  $\alpha 1\alpha 1\alpha 2$  ( $\alpha 112$ ) trimers possess fewer disulfide bonds than  $\alpha 3\alpha 4\alpha 5$  ( $\alpha 345$ ) heterotrimers. The relative protein abundance of the  $\alpha 1$  and  $\alpha 2$  chains in normal adult glomerular ECM has been reported higher compared to the richness of the  $\alpha 3$ ,  $\alpha 4$ , and  $\alpha 5$  chains[27].

Ultrastructural examination with immunogold technique reveals that type IV collagen is concentrated in the endothelial zone and decreases towards the epithelial third of the GBM in normal human glomeruli. In addition, the  $\alpha 1$  chain is distributed primarily along the endothelial side of GBM whereas the  $\alpha 3$  and  $\alpha 4$  chains are seen throughout the thickness of the GBM[56,89]. Kidney assessment with STORM reveals that type IV collagen  $\alpha 345$  trimers are localized at the center of the GBM while type IV collagen  $\alpha 112$  trimers are located to the endothelial side. Co-labeling for both trimers of type IV collagen ( $\alpha 345$  and  $\alpha 112$ ) suggest the  $\alpha 112$  network occupies the space between the central  $\alpha 345$  Layer and the endothelial surface of the GBM[29].

In addition to the GBM, type IV collagen is detectable in the mesangial matrix of normal human glomeruli[38-40,43,71]. Investigations using quantitative immunogold electron microscopy show that mesangial type IV collagen labeling appears uniform throughout the mesangial matrix and extends to the subendothelial side of the GBM[56,89]. Electron microscopy examination with immunogold technique shows that the  $\alpha 1$  chain of type IV collagen is distributed primarily along the mesangial matrix and the endothelial side of GBM whereas the  $\alpha 3$  chain of type IV collagen is not detected in normal human mesangial matrix[32].

The relevance of type IV collagen to kidney structure and function is highlighted by the clinical consequences of mutations in genes that code the  $\alpha$  chains of this collagen type. Mutations in the *COL4A3-5* genes cause type IV collagen-related kidney disease (Table 3). The *COL4A5* gene encodes the  $\alpha 5$  chain and maps to the X chromosome. Mutations in this gene account for X-linked Alport syndrome.

**Table 3 Type IV collagen-related kidney disease**

	Gene/location	Protein	Mutation	Risk of progression to end-stage kidney disease
X-linked Alport syndrome	<i>COL4A5</i> /X chromosome	$\alpha 5$ chain of type IV collagen	Hemizygous (males) or heterozygous (females) mutations	Hemizygous: 100%; Heterozygous: 25%
Autosomal recessive Alport syndrome	<i>COL4A4</i> or <i>COL4A3</i> /2q36-37	$\alpha 4$ and $\alpha 3$ chains of type IV collagen	Biallelic (homozygous or compound heterozygous) mutations	100%
Autosomal dominant Alport syndrome	<i>COL4A4</i> or <i>COL4A3</i> 2q36-37	$\alpha 4$ and $\alpha 3$ chains of type IV collagen	Heterozygous mutations in the $\alpha 4$ or $\alpha 3$ chains	20% in patients with risk factors for progression
Digenic Alport syndrome	Two of the <i>COL4A3-5</i> genes	Two of the $\alpha 3-5$ chains		

Males harbor hemizygous mutations whereas females carry heterozygous mutations. The *COL4A4* and *COL4A3* genes encode respectively the  $\alpha 4$  and  $\alpha 3$  chains of type IV collagen and are located on chromosome locus 2q36-37. Mutations in these genes cause autosomal Alport syndrome. Biallelic (homozygous or compound heterozygous) mutations in either one of them result in autosomal recessive Alport syndrome whereas autosomal dominant Alport syndrome is due to heterozygous mutations in either the *COL4A4* or *COL4A3* genes. Mutations in two of the *COL4A5*, *COL4A4*, or *COL4A3* genes cause digenic Alport syndrome[90-94].

Mutations in type IV collagen are highly prevalent. Genome-wide association studies show that 1 in 600 subjects from the Icelandic population carry a variant in the *COL4A3* gene associated with hematuria and albuminuria. In the UK population, the *COL4A4* variant rs35138315 (Ser969X) has a carrier frequency of 0.13% and is also associated with hematuria and albuminuria[95]. Among 24 Greek families with familial microscopic hematuria, next generation sequencing identifies pathogenic mutations in the *COL4A3-5* genes in 17 (71%) of them[96]. Mutations in the *COL4A3-5* genes are also frequently found in patients with sporadic and familial FSGS[94,95,97-99]. Pathogenic variants in any of the *COL4A3-5* genes are found in up to 10% of patients with renal failure of unknown cause and in some families with IgA nephropathy[94]. Therefore, indications for screening for pathogenic variants in the *COL4A5*, *COL4A4*, or *COL4A3* genes have been extended beyond the classical Alport syndrome phenotype (hematuria, renal failure, family history of hematuria or renal failure) to include FSGS, persistent proteinuria, steroid-resistant nephrotic syndrome, familial IgA nephropathy, and ESKD without an obvious cause[94].

The phenotypical expression of mutations in type IV collagen (*COL4A3-5* genes) is heterogeneous. Patients with type IV collagen-related nephropathy may exhibit isolated microscopic hematuria, proteinuria, or kidney failure that evolves to ESKD. In addition, patients with type IV collagen mutations may experience extrarenal manifestations such as sensorineural hearing loss, lenticonus, and retinopathy[90-93,97]. In patients with mutations in the *COL4A5* gene (X-linked Alport syndrome), hemizygous males have a 100% risk of progression to ESKD while heterozygous females (formerly called carriers) have substantial risk associated with proteinuria, progressive renal disease, and sensorineural hearing loss. Their lifetime risk of progression to ESKD is approximately 25%. Patients with autosomal recessive Alport syndrome (due to biallelic mutations in *COL4A4* or *COL4A3* genes) have a 100% risk of ESKD. Patients with heterozygous mutations in *COL4A4* or *COL4A3* genes (autosomal dominant Alport syndrome) may be asymptomatic or may exhibit hematuria or proteinuria and include patients previously diagnosed with thin basement membrane nephropathy. Risk factors for progression to ESKD in these subjects include proteinuria, sensorineural deafness, family history of progression to ESKD and renal biopsy findings of FSGS or GBM thickening and disarray. The risk of ESKD is up to 20% among those with risk factors. Patients with heterozygous mutations in *COL4A4* or *COL4A3* genes without kidney manifestations (hematuria or proteinuria) generally have a good prognosis but should be screened in a yearly basis[93].

The kidney histological phenotype of mutations in type IV collagen is characterized by GBM alterations, effacement of podocyte foot processes, and FSGS. Light microscopy examination of kidney samples from patients with Alport syndrome may reveal normal glomeruli or only minor mesangial widening. Immunofluorescent staining generally renders negative or nonspecific results. Electron microscopy usually provides the diagnosis, revealing changes in the GBM that may include areas of thinning, thickening, lamellation, and splitting. Initially, the GBM exhibits segmental thinning followed by progressive thickening and disorganization. In addition, diffuse podocyte foot process effacement occurs very frequently[74,97,99-101]. Patients with pathogenic variants affecting the  $\alpha$  chains of type IV collagen may display FSGS with or without GBM changes[91,97-99,102,103].

**Type V collagen in the normal glomerulus:** In normal human glomeruli, type V collagen shows a distribution similar to type IV, being detectable in the GBM and the mesangium[38-40].



**Type VI collagen in the normal glomerulus:** In human adult glomerular tissue, mass spectrometry quantitative analyses show that type VI collagen is highly abundant[27]. In normal kidney samples, immunogold electron microscopy and immunohistochemical analyses show that the glomerular distribution of type VI collagen is comparable to that of the  $\alpha 1$  chain of type IV collagen, namely along the mesangial matrix and the endothelial aspect of the GBM mainly[27,31,32,38,40].

**Other types of collagen (type XV, type XVII and type XVIII collagen) in the normal glomerulus:** Type XV collagen ( $\alpha 1$  chain) has been found among ECM proteins in the glomerular proteome although its biological significance is uncertain[27].

Type XVII collagen is a transmembrane molecule involved in epithelial adhesion that has been identified as an autoantigen in bullous pemphigoid, a blistering skin disease of autoimmune origin. The association of bullous pemphigoid and a glomerular disease with characteristics of anti-GBM disease and membranous nephropathy has been reported in a 75-year-old man that also had circulating IgG against BP180, the 180-kDa bullous pemphigoid antigen (type XVII collagen). The kidney biopsy exhibited endocapillary inflammation without crescents. Direct immunofluorescence showed strong IgG and C3 staining in a combined granular and linear pattern along the GBM. Electron microscopy revealed subepithelial deposits[104]. In a kidney biopsy sample collected from a 4-year-old girl with hematuria, immunoelectron microscopy reveals that type XVII collagen is expressed in the foot processes of podocytes. In addition, type XVII collagen can be seen in the adjacent lamina rara externa of the GBM[105].

Type XVIII collagen has been identified among the ECM proteins in the glomerular proteome, being present in the GBM and the mesangium. Its expression pattern is similar to that of the  $\alpha 1$  and  $\alpha 2$  chains of type IV collagen[27,106].

#### **Other components and factors that may modulate the normal composition of the glomerular ECM**

The tubulointerstitial nephritis antigen-like-1 (TINAGL1) is highly abundant in normal glomerular ECM, being predominantly localized to the mesangial matrix. TINAGL1 is a glycoprotein structurally related to the tubulointerstitial nephritis antigen, a protein of the tubular basement membrane that is the antigenic target in autoimmune anti-tubular basement membrane disease. Nephronectin, vitronectin, fibulin-1, and fibrillin-1 have been identified as components of glomerular proteome using mass spectrometry. Nephronectin is present both in the GBM and mesangial matrix while vitronectin is localized in the mesangial matrix alone[27].

**Matrix metalloproteinases and their inhibitors:** Matrix metalloproteinases (MMPs) and their inhibitors are present in the ECM, but the particular isoforms distributed to the human kidney and their specific pathophysiologic role remain largely unknown. Disruption of the balance between MMPs and their inhibitors in the extracellular space has been implicated in the development of kidney fibrosis. Plasma concentration of MMPs and their inhibitors have been correlated with insulin resistance and kidney disease in clinical studies, suggesting that the composition of the ECM is altered in these conditions[107-109]. In the Renal Iohexol Clearance Survey, higher MMP-7 Levels were independently associated with increased risk of accelerated glomerular filtration rate (GFR) decline and incident chronic kidney disease among 1324 adults from the general population free of baseline diabetes, kidney disease or cardiovascular disease, over a median observation period of 5.6 years. In contrast, MMP2 and tissue inhibitor of metalloproteinase-1 (TIMP-1) showed no association with kidney disease[107]. Patients with insulin resistance display increased plasma TIMP-1 Level compared with healthy subjects. Accordingly, elevated plasma TIMP-1 concentration may be a marker of interstitial fibrosis due to excessive collagen deposition[108,109].

*In vitro* studies show that the expression of MMPs in the kidney ECM may be regulated at least in part by growth factors and ECM components[110,111]. In human kidney tubular cells, transforming growth factor- $\beta 1$  (TGF- $\beta 1$ ) induces MMP-2 expression *via* up-regulation of integrin-linked kinase[110], while elevated glucose concentration decreases MMP-9 and MMP-2 expression and increases TIMP-1 expression[112]. In cultured human glomerular epithelial cells, the expression of MMP-2 and MMP-9 is down-regulated by the presence of the  $\alpha 3$  chain of type IV collagen[111], while high glucose concentration reduces MMP-2 expression and up-regulates TIMP-2[113].

**Growth factors:** The ECM composition is modulated by growth factors such as TGF- $\beta 1$ , platelet-derived growth factor (PDGF), and vascular endothelial growth factor (VEGF). TGF- $\beta 1$  and PDGFs may promote ECM fibrosis in the kidney at least in part *via* integrins and integrin-associated proteins[114,115]. *In vitro* investigations using human mesangial cells show that TGF- $\beta 1$  induces mesangial matrix expansion[116]. Accordingly, up-regulation of TGF- $\beta 1$  is observed in the areas of interstitial and fibrosis in human fibrotic kidneys, compared with control kidneys[117]. Likewise, the expression of TGF- $\beta 1$  and type IV collagen is increased in kidney allografts with interstitial fibrosis compared to normal kidney tissue[118]. VEGF and its receptors are expressed in normal human kidney, particularly in podocytes and mesangial cells. In normal podocytes, transmission electron microscopy examination reveals that VEGF may be detected in the intracellular compartment (36%) and associated with the cell membrane (63%)[119]. *In vitro* studies show that VEGF induces a proliferative effect on human mesangial cells[120,121].

The role of VEGF in glomerular pathophysiology is largely unknown, but neutralizing VEGF activity may increase the risk of kidney disease, as bevacizumab (a monoclonal antibody against human VEGF-A) therapy has been associated with elevated risk of proteinuria and hypertension among cancer patients in a systematic review and meta-analysis of clinical trials[122]. Rapamycin therapy has been associated with reduced VEGF expression in the human kidney that might contribute to explain the renal side-effects of this drug[123].

**Integrins and integrin-associated proteins:** Growth factors may interact with integrins to initiate signaling cascades. Integrins are plasma membrane proteins that link structurally and functionally the cell cytoskeleton with the extracellular space (Figure 3). Inside the cell, the cytoplasmic domain of integrins connects with the cytoskeleton *via* integrin-associated proteins, including integrin-linked kinase, particularly interesting new cysteine-histidine-rich protein (PINCH1), parvin proteins, and calponin homology domain-containing integrin-linked kinase-binding protein (CH-ILKBP)[114,124-128]. PINCH1 is an adaptor protein that comprises five LIM domains and interacts with integrin-linked kinase[129]. The parvins are partner proteins to integrin-linked kinase and PINCH1[130]. CH-ILKBP interacts with integrin-linked kinase, PINCH1, and the cytoskeleton. The interaction with integrin-linked kinase mediates the plasma membrane localization of CH-ILKBP. Northern blot analyses show widespread CH-ILKBP expression in human tissues, particularly in the heart, skeletal muscle, and kidney[131]. *In vitro* studies using human cell lines (HeLa cells) show that depletion of CH-ILKBP prevents the membrane translocation and the phosphorylation of protein kinase B (AKT), suggesting that CH-ILKBP facilitates the activation of this kinase in response to extracellular signals[132]. Integrins and integrin-associated proteins convey cues from growth factors and ECM components to intracellular pathways, although specific signaling cascades are not fully elucidated in humans[110,117,118]. Integrin signaling *via* integrin-associated proteins has been implicated in the regulation of ECM deposition and may be involved in the development of kidney fibrosis, both in native kidneys and kidney allografts, although underlying mechanisms remain largely unsolved[118]. An up-regulation of  $\beta 1$  integrin and integrin-linked kinase has been observed in areas of interstitial fibrosis in human fibrotic kidneys, compared with control kidneys[117]. *In vitro* experiments using cultured human proximal tubular cells reveal that overexpression of integrin-linked kinase and PINCH1 increases fibronectin-1 expression and its extracellular assembly, whereas PINCH1 knockdown reduces TGF $\beta 1$ -mediated fibronectin-1 expression[110,124]. *In vitro* studies show that  $\alpha 3\beta 1$  integrin largely mediates the adhesion of human glomerular epithelial cells to type IV collagen[133]. Glucose concentration in the medium may alter integrin expression and the binding to type IV collagen in human glomerular epithelial cells[113], and human proximal tubular epithelial cells[112].

## COMPOSITION OF THE GLOMERULAR ECM IN DKD

Diabetes is associated with a profound alteration in the composition of extracellular tissues throughout the body, including the kidney and the blood vessels. Patients with diabetes demonstrate increased interstitial collagen production and deposition that leads to fibrosis. Alström syndrome is an autosomal recessive disease due to mutations in the ALMS1 protein, characterized by the presence of early childhood insulin resistance. Like diabetes, patients with Alström syndrome typically show systemic fibrosis of extracellular tissues[5,36,134-136]. In patients with DKD, the amount and biochemical composition of the GBM and mesangial matrix are markedly anomalous. The global amount of glomerular ECM is increased, the level of heparan sulfate proteoglycans is reduced, and the collagen content is augmented compared to normal kidneys (Table 4)[36,134]. Furthermore, the abnormal composition of the glomerular ECM becomes more pronounced with the progression of DKD. Advanced sclerotic lesions show increased type III collagen and reduced amount of heparan sulfate proteoglycan and fibronectin-1 compared to earlier stages of DKD (Figure 4)[39,137,138].

### Glomerular glycosaminoglycans, proteoglycans, and sialic acid in DKD

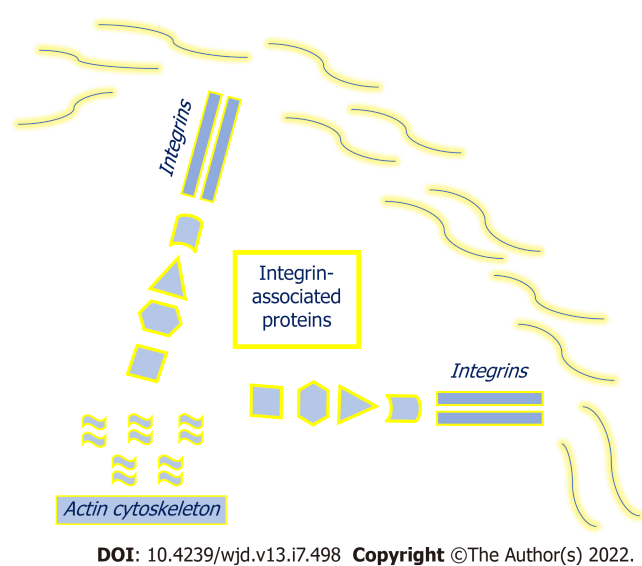
In patients with diabetes, the content of heparan sulfate in the glomerular ECM is prominently reduced while the global amount of extracellular tissue is increased. A quantitative assessment conducted by immunochemical procedures reveals that the abundance of heparan sulfate proteoglycan in the GBM of patients with diabetes is 30% lower than that of control subjects. The decrease in glomerular heparan sulfate has been also observed in other diseases, such as C3 glomerulopathy, membranous nephropathy, minimal change disease, and lupus nephritis[33,36,37,139].

The reduction in glomerular heparan sulfate proteoglycan associated with DKD starts to occur early and becomes more severe with the advance of the disorder. In patients with mild diffuse glomerulosclerosis, the staining pattern of heparan sulfate proteoglycan is reduced in the thickened mesangial matrix while in more pronounced diffuse glomerulosclerosis and mesangial nodules the enlarged matrix lacks heparan sulfate proteoglycan completely[33,39]. In contrast, the amount of hyaluronic acid is increased in the glomerular ECM of patients with DKD compared to control subjects[140]. As mentioned, heparan sulfate is a major ligand for factor H, an inhibitor of the alternative pathway of

**Table 4** Different composition of glomerular extracellular matrix (glomerular basement membrane and mesangial matrix) in normal subjects and patients with diabetes

	Normal glomeruli	Diabetic kidney disease
Heparan sulfate proteoglycans	GBM and mesangial matrix	Decreased amount
Laminin	Predominantly in the GBM	Inconsistent
Fibronectin-1	Mainly in the mesangial matrix	It varies according to DKD stage
Type I collagen	Inconsistent	No detectable
Type III collagen	Absent	Abundant
Type IV collagen	Abundant in the GBM	Reduced GBM amount
Type V collagen	Similar to type IV collagen	Increased mesangial amount
Type VI collagen	GBM and mesangial matrix	Increased mesangial amount

GBM: Glomerular basement membrane; DKD: Diabetic kidney disease.

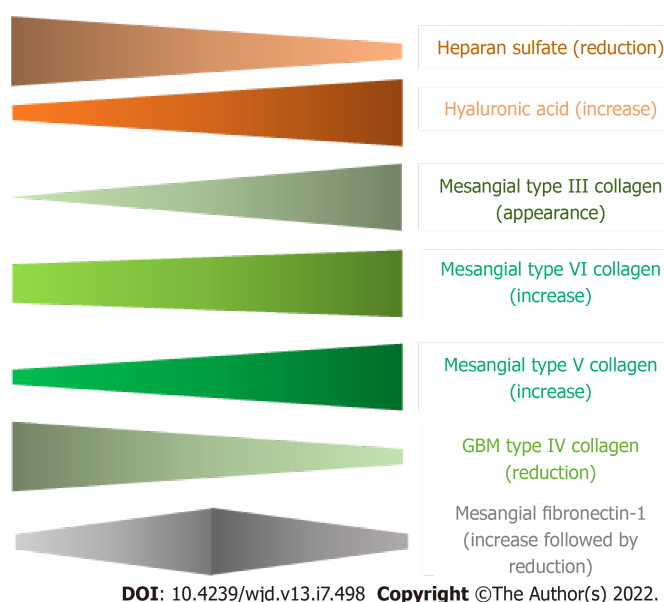


**Figure 3** Integrins and integrin-associated proteins.

complement on “self” biological surfaces. Loss of heparan sulfate (or altered sulfation pattern) may result in reduced factor H attachment to “self” structures, subsequent activation of the alternative pathway and complement-mediated injury, like occurs in the presence of mutated factor H (C3 glomerulopathy). Complement activation *via* the alternative pathway may contribute to the progression of renal and vascular complications in human diabetes. In patients with biopsy-proven DKD, a higher level of factor H in the urine has been independently associated with worse kidney outcomes, including onset of ESKD and faster kidney function decline, compared to control subjects[141]. Further, clinical studies have shown an association between single nucleotide polymorphisms in factor H and adverse clinical outcomes in different population groups of non-diabetic and diabetic patients[142,143]. In African American patients, genetic changes in factor H gene, such as the intronic variant rs379489, have been associated with ESKD in both non-diabetic and type 2 diabetes (T2D), compared to controls[142]. In 1158 T2D patients prospectively followed in the randomized controlled trial Bergamo Nephrologic Complications of T2D (BENEDICT), the single nucleotide polymorphism in the factor H gene c.2808G>T (p.Glu936Asp) is independently associated with increased risk of microalbuminuria and cardiovascular complications (Asp/Asp homozygotes, recessive model). T2D patients Asp/Asp homozygotes are at increased risk of microalbuminuria and cardiovascular events compared to carriers of one or two wild type Glu alleles[143].

Among patients with diabetes, the reported amount of glomerular sialic acid has been inconsistent. A decline in the content of sialic acid has been detected in the glomerular ECM of patients with diabetes, compared to normal kidney samples[68,144]. However, an increased expression of sialic acid on podocytes has been observed in patients with DKD and other kidney diseases without differences among them[44].





**Figure 4** Schematic variation in some components of the glomerular extracellular matrix according to the progression of diabetic kidney disease. GBM: Glomerular basement membrane.

A study that applied weighted gene co-expression network analysis to 179 human glomeruli reveals that two small leucine-rich proteoglycans (lumican and fibromodulin) are more abundant in the ECM of patients with DKD compared to controls and other glomerular diseases, such as IgA nephropathy or membranous nephropathy. Further, the expression level of lumican and fibromodulin is negatively correlated with kidney function. The specificity of lumican and fibromodulin in kidney samples from patients with DKD in comparison to normal specimens and patients with other glomerular diseases suggests that these ECM components may become potential diagnostic biomarkers for DKD[14].

#### **Glomerular laminin in DKD**

The laminin content of the glomerular ECM in patients with diabetes has been barely reported and the values are variable[37,39]. In human kidneys obtained at autopsy, there is a marked reduction in laminin content in the diabetic GBM compared to non-diabetic control subjects. Radioimmunoassays indicated that GBM from patients with diabetes contains average values of laminin that were 60% of control subjects[37]. However, immunohistochemical studies show an increased glomerular deposition of laminin in kidney biopsy samples from type 1 diabetes (T1D) and T2D patients with diffuse and nodular glomerulosclerosis[39].

#### **Glomerular fibronectin-1 in DKD**

Immunohistochemical studies reveal that the amount of mesangial fibronectin-1 is abnormal in patients with diabetes and varies with the advance of DKD. Antibodies to fibronectin-1 normally stain the mesangium and the subendothelial aspect of the GBM. Early lesions of mesangial expansion are associated with increased staining for fibronectin-1. However, a marked diminution in fluorescent intensity for fibronectin-1 is documented in more advanced mesangial enlargement (nodular lesions). Compared with normal tissues and early lesions of DKD, the progression of the disease is associated with a noticeable reduction in the amount of glomerular fibronectin-1[39,40,137]. The increase in mesangial fibronectin-1 that occurs in the early stage of DKD also takes place in other glomerular diseases characterized by mesangial expansion, such as mesangiocapillary glomerulonephritis[59,60]. An up-regulation of fibronectin-1 expression in the glomeruli has been also observed in patients with hypertension compared to normal kidneys[4]. Likewise, the amount of fibronectin-1 in vascular tissue is increased in patients with diabetes before the development of atherosclerosis lesions[59,145]. The content of fibronectin-1 in the intima-media of normal aorta specimens is more elevated in patients with diabetes (T1D and T2D) compared to control subjects, suggesting that diabetic patients develop structural alterations in the connective tissue of their arteries before the appearance of vascular disease [145]. In patients with DKD, the thickened capillary walls also contain a markedly elevated amount of fibronectin-1[59].

#### **Glomerular collagen in DKD**

Earlier studies found elevated glomerular ECM levels of glycine, hydroxyproline, hydroxylysine, and hexoses in patients with diabetes compared to normal kidney samples, suggesting an increase in the amount of collagen in the glomerular ECM from diabetic patients[30,36,66-68]. Radioimmunoassays

confirmed collagen enrichment in the glomerular ECM of patients with diabetes[37]. Accordingly, electron microscopy examination shows accumulation of collagen fibrils in the mesangium of patients with DKD[146].

**Glomerular type I collagen in DKD:** No glomerular type I collagen has been detected in DKD at any stage of the disorder[33,39,40,137,147].

**Glomerular type III collagen in DKD:** Unlike normal glomeruli, type III collagen is identified in the mesangium of patients with DKD and its amount increases gradually with the progression of the disease. Early DKD lesions (diffuse glomerulosclerosis) show positive staining for type III collagen that increases in more advanced mesangial nodular lesions. In the late stage of global sclerosis, type III collagen is diffusely present in the sclerotic mesangial matrix. Therefore, *de novo* synthesis of type III collagen in glomeruli occurs in patients with DKD[33,39,40,70,71]. A patient with T1D and collagen-*o*fibrotic glomerulopathy has been reported[148].

**Glomerular type IV collagen in DKD:** In patients with diabetes, immunohistochemical estimates of type IV collagen in the GBM reveal reduced staining compared to normal tissue. Accordingly, the density of gold particles for type IV collagen is decreased in the GBM of T1D patients on quantitative immunogold electron microscopy examination. Like in normal subjects, the labeling of antibody against type IV collagen in the GBM is concentrated in the endothelial zone and decreases towards the epithelial aspect of the GBM in diabetic patients[33,89].

In the mesangial matrix, immunohistochemical studies show that the amount of type IV collagen changes according to the stage of DKD. In earlier lesions of diffuse glomerulosclerosis, mesangial staining for type IV collagen is increased while more advanced nodular glomerulosclerosis showed marked reduction in the mesangial staining for type IV collagen, suggesting that type IV collagen is progressively substituted for other collagen types such as type VI and type III during the transition from diffuse to nodular glomerulosclerosis[39,40,89]. However, an elevated mesangial staining for type IV collagen has been observed in specific nodular lesions, called non-mesangiolytic nodules, compared to normal kidney[33,71]. The amount of type IV collagen in nodular lesions may depend on the type of the lesion, mesangiolytic or non-mesangiolytic. In a study aimed to investigate collagen staining of mesangial nodules from 67 patients with DKD, type IV collagen staining was only robust in nodular lesions with strong PAS/periodic acid methenamine silver (PAMS) staining (non-mesangiolytic nodular lesions). In contrast, nodular lesions with faint PAS/PAMS staining (mesangiolytic nodular lesions) did not show type IV collagen. The amount of type IV collagen correlates with the PAS and PAMS staining pattern. Non-mesangiolytic nodules (with prominent PAS/PAMS staining) are strongly positive for type IV collagen whereas mesangiolytic nodules (with weak or negative PAS/PAMS staining) show weak or negative staining for type IV collagen[147]. Immunofluorescence studies performed in 918 kidney biopsy samples from patients with diabetes (T1D and T2D) show accumulation of  $\alpha 3$  and  $\alpha 5$  chains of type IV collagen in diffuse mesangial sclerosis while minimal amounts of these  $\alpha 3$  and  $\alpha 5$  chains were seen within the mesangium of control subjects[43].

In patients with diabetes, two large clinical investigations with different population groups (African American and European descent subjects) have shown that genetic variants in the gene that codes the  $\alpha 3$  chain of type IV collagen (*COL4A3*) may modulate susceptibility to DKD and ESKD[149]. In 4885 African American patients with T2D, an association between the genetic variant R408H (rs34505188) in *COL4A3* and ESKD has been observed, suggesting that genetic changes in the *COL4A3* locus may contribute to ESKD susceptibility in patients with diabetes[149]. In 19406 T1D patients of European descent from 17 cohorts, a genome-wide association meta-analysis reveals that a single nucleotide polymorphism in the *COL4A3* gene is associated with protection from DKD (proteinuria and ESKD) [150].

**Glomerular type V collagen in DKD:** Immunohistochemical studies have documented an enrichment in mesangial type V collagen in diffuse glomerulosclerosis and nodular lesions in patients with DKD compared to control subjects. Increased staining for type V collagen is observed in advanced mesangial disease, compared to normal tissues and early mesangial disease.

Staining for type V collagen was strongly positive in all nodular lesions, mesangiolytic and non-mesangiolytic[39,40,137,147].

**Glomerular type VI collagen in DKD:** In patients with DKD, the amount of mesangial type VI collagen is elevated. Quantitation by radioimmunoassay reveals that the level of type VI collagen is 2.8-fold higher in the diabetic preparations compared to control subjects. Furthermore, the amount of mesangial type VI collagen increases with the progression of DKD. In earlier lesions of diffuse glomerulosclerosis, the contribution of type VI collagen deposition to the overall matrix expansion is minor. However, type VI collagen is a major component in the expanded mesangial matrix of nodular glomerulosclerosis. A marked increase in type VI collagen deposition is observed in nodular lesions where the strong positivity for type VI collagen is evenly distributed throughout the entire nodules[31,39,40,147].

### **Other factors that contribute to modulate the composition of kidney ECM in DKD**

As kidney ECM remodeling is profoundly altered in patients with DKD, the expression of MMPs, TIMPs, integrins, integrin-associated proteins, and signaling pathways from growth factors have been reported abnormal among these patients. In addition, the nuclear factor-kappa-B (NF- $\kappa$ B) family of transcription factors and advanced glycation end-products (AGEs) have been proposed as potential contributors to the ECM disturbance present in patients with DKD.

**MMPs and their inhibitors in patients with DKD:** The expression of MMPs and their inhibitors is altered in patients with DKD. Clinical studies have suggested that these ECM components might be useful to evaluate the risk for cardiovascular disease, kidney disease, and all-cause mortality among patients with diabetes. In a cross-sectional study, T1D patients with cardiovascular disease showed higher levels of TIMP-1 compared to T1D patients without cardiovascular disease[151]. In a prospective study that followed 337 T1D patients for a median period of 12.3 years, elevated MMP-2 plasma levels were associated with higher incidence of cardiovascular events, but this relationship was attenuated after adjustment for estimated GFR, suggesting that kidney function may mediate the association[152]. In a cross-sectional pooled analysis of three groups of T1D patients, circulating MMP-1, MMP-2, and MMP-3 Levels were associated with arterial stiffening independent of confounding factors while no association with TIMPs was observed[153]. In a case-control study that evaluated 120 control women and 120 women with a history of gestational diabetes 3.7 years after delivery, both serum TIMP-1 Levels and arterial stiffness were higher in subjects with previous gestational diabetes compared to control individuals[154]. In T1D patients, MMPs and their inhibitors have been associated with albuminuria in a cross-sectional study[151], and with kidney function decline in a prospective study[152]. In a prospective observational cohort study, urinary excretion of MMP-7 was independently associated with higher mortality rate over a median follow-up period of 3.0 years, in T2D patients with DKD. In contrast, no association between serum MMP-7 Level and mortality was observed[155]. In T1D patients, the association of MMP-1, MMP-2 and MMP-3 with all-cause mortality was attenuated after adjustment for estimated GFR, suggesting that the known association between kidney function and mortality may mediate the relation between MMPs and death[152].

However, MMPs expression in glomeruli may be altered in other glomerular diseases, such as IgA nephropathy, which is associated with extensive changes of the glomerular ECM proteome, including higher abundance of MMP-9, MMP-2,  $\alpha$ 1 chain of type IV collagen, fibronectin, and  $\beta$ 1-laminin[156].

**Growth factors (TGF- $\beta$ , PDGF, and VEGF) in patients with DKD:** In T2D patients with albuminuria, serum TGF- $\beta$ 1 Level is higher compared to healthy controls and T2D patients with normal urinary albumin excretion rate, suggesting that serum TGF- $\beta$ 1 might be used to evaluate progression of DKD [157,158]. Several meta-analyses indicate a potential value of serum TGF- $\beta$ 1 Levels to evaluate the risk of DKD and the advance of the disease[159-161]. However, the administration of a neutralizing monoclonal antibody against TGF- $\beta$ 1 to T1D and T2D patients with DKD failed to slow progression of the disease compared to placebo in a randomized controlled clinical trial, suggesting that TGF- $\beta$ 1 is not a major determinant of kidney function decline in patients with diabetes[162].

The glomerular expression of PDGF-B and its receptor (PDGFR- $\beta$ ) is higher in T2D patients with DKD compared to normal kidneys, particularly in samples with mild mesangial expansion. In contrast, the expression of PDGF-A and its receptor (PDGFR- $\alpha$ ) is comparable in normal kidneys and patients with DKD[163].

In patients with DKD, VEGF-A expression is lower compared to normal kidney tissue[164]. VEGF signaling has been reported to be differentially regulated in patients with DKD in a study that examined gene-expression changes in human DKD[165]. However, in a prospective study that recruited 155 T1D patients with proteinuria, plasma VEGF failed to predict kidney function decline over 3-year follow-up [166].

**Integrins and integrin-associated proteins in patients with DKD:** Glomerular integrin and integrin-linked kinase signaling pathways have been found differentially regulated in patients with DKD[165]. In addition, the expression of integrin-linked kinase in the mesangium is increased in kidney specimens from patients with diabetes and diffuse mesangial expansion, compared to control samples. In contrast, integrin-linked kinase level is reduced in glomeruli with advanced nodular sclerosis and global sclerosis, suggesting that integrin-linked kinase expression increases during early stages of DKD[114].

**NF- $\kappa$ B in patients with DKD:** NF- $\kappa$ B is a transcription factor that regulates the expression of several genes. NF- $\kappa$ B-inducing kinase activates the NF- $\kappa$ B signaling pathway. Dysregulation of NF- $\kappa$ B signaling has been implicated in DKD, but its role remains uncertain. In vitro studies using human proximal tubular epithelial cells (HK-2 cells) suggest a role for NF- $\kappa$ B pathway in modulating diabetes-induced disease in renal tubular epithelium[167,168].

**Advanced glycation products in patients with DKD:** AGEs are molecules that result from nonenzymatic glycation of proteins and lipids. They may bind to cell surface receptors (RAGEs). AGEs have been hypothesized to be involved in the development of human DKD, but their participation remain undefined. In kidney biopsies from patients with DKD, AGEs are detected in the expanded

mesangial matrix while they are not identified in control samples[169,170]. In addition, AGEs are identified in areas of glomerulosclerosis and arteriosclerosis in other diseases, such as FSGS, hypertensive nephrosclerosis, and lupus nephritis[169]. RAGE expression was detected in mesangial cells and glomerular epithelial cells, in both patients with DKD and control subjects[170]. In a cross-sectional study, the level of AGEs was positively associated with serum concentration of MMP-2, MMP3, and TIMP-1 while an inverse association with MMP-9 was observed in T1D patients[171].

## CONCLUSION

Understanding mechanisms that regulate glomerular ECM injury and repair may contribute to develop therapeutic strategies for DKD and other kidney diseases. During adult life, mesangial cells produce mesangial matrix. The turnover of the GBM present at birth is unknown. Podocyte foot processes surround and attach entirely the GBM. Adult podocytes may sustain hypertrophy following the loss of adjacent cells to prevent bared GBM areas that compromise the filtration barrier. Glycosaminoglycans, such as heparan sulfate and hyaluronic acid, are major constituents of the glomerular ECM. The specific pattern of sulfation of glycosaminoglycans allows the identification of these molecules as “self” by complement components and avoid complement-mediated self-damage. Sialic acid is also present in glomerular ECM and may serve to a similar function. Fibronectin-1 is important for the normal deposition of other ECM components, such as collagen. Type IV, V, and VI collagens are predominant types of collagen normally present in the glomerular ECM while type III collagen appears in diseased states, such as diabetes and glomerulosclerosis. The composition and arrangement of the glomerular ECM is profoundly altered in patients with diabetes. The global quantity of glomerular ECM is increased while the amount of sulfated proteoglycans is reduced and hyaluronic acid is augmented, compared to control tissue. Fibronectin-1 is increased in early lesions of mesangial expansion. Likewise, the amount of fibronectin-1 in capillary walls and aorta is increased before the development of vascular disease in patients with diabetes. Mesangial type III, type V, and type VI collagen amount is elevated in patients with DKD and increases progressively with the advance of the disease. Genetic variants in the gene that codes the  $\alpha 3$  chain of type IV collagen (*COL4A3*) may modulate susceptibility to DKD and ESKD.

## ACKNOWLEDGEMENTS

We are very grateful to Ms. Gema Souto, MHS for her help and support during the writing of this manuscript.

## FOOTNOTES

**Author contributions:** Adeva-Andany MM conceived and designed the review, performed the literature search and wrote the original draft of the manuscript; Carneiro-Freire N contributed to the writing and revision of intellectual content; both authors participated in the final version of the manuscript.

**Conflict-of-interest statement:** The authors declare that there is no conflict of interest.

**Open-Access:** This article is an open-access article that was selected by an in-house editor and fully peer-reviewed by external reviewers. It is distributed in accordance with the Creative Commons Attribution NonCommercial (CC BY-NC 4.0) license, which permits others to distribute, remix, adapt, build upon this work non-commercially, and license their derivative works on different terms, provided the original work is properly cited and the use is non-commercial. See: <https://creativecommons.org/licenses/by-nc/4.0/>

**Country/Territory of origin:** Suriname

**ORCID number:** María M Adeva-Andany 0000-0002-9997-2568; Natalia Carneiro-Freire 0000-0003-4404-0541.

**S-Editor:** Chang KL

**L-Editor:** A

**P-Editor:** Chang KL



## REFERENCES

- 1 **Saleem MA**, O'Hare MJ, Reiser J, Coward RJ, Inward CD, Farren T, Xing CY, Ni L, Mathieson PW, Mundel P. A conditionally immortalized human podocyte cell line demonstrating nephrin and podocin expression. *J Am Soc Nephrol* 2002; **13**: 630-638 [PMID: [11856766](#) DOI: [10.1681/ASN.V133630](#)]
- 2 **Faul C**, Asanuma K, Yanagida-Asanuma E, Kim K, Mundel P. Actin up: regulation of podocyte structure and function by components of the actin cytoskeleton. *Trends Cell Biol* 2007; **17**: 428-437 [PMID: [17804239](#) DOI: [10.1016/j.tcb.2007.06.006](#)]
- 3 **Pollak MR**. Familial FSGS. *Adv Chronic Kidney Dis* 2014; **21**: 422-425 [PMID: [25168831](#) DOI: [10.1053/j.ackd.2014.06.001](#)]
- 4 **Kliewe F**, Kaling S, Löttsch H, Artelt N, Schindler M, Rogge H, Schröder S, Scharf C, Amann K, Daniel C, Lindenmeyer MT, Cohen CD, Endlich K, Endlich N. Fibronectin is up-regulated in podocytes by mechanical stress. *FASEB J* 2019; **33**: 14450-14460 [PMID: [31675484](#) DOI: [10.1096/fj.201900978RR](#)]
- 5 **Baig S**, Paisey R, Dawson C, Barrett T, Maffei P, Hodson J, Rambhatla SB, Chauhan P, Bolton S, Dassie F, Francomano C, Marshall RP, Belal M, Skordilis K, Hayer M, Price AM, Cramb R, Edwards N, Steeds RP, Geberhiwot T. Defining renal phenotype in Alström syndrome. *Nephrol Dial Transplant* 2020; **35**: 994-1001 [PMID: [30307515](#) DOI: [10.1093/ndt/gfy293](#)]
- 6 **Riemer T**, Nimptsch A, Nimptsch K, Schiller J. Determination of the glycosaminoglycan and collagen contents in tissue samples by high-resolution <sup>1</sup>H NMR spectroscopy after DCl-induced hydrolysis. *Biomacromolecules* 2012; **13**: 2110-2117 [PMID: [22713080](#) DOI: [10.1021/bm300485j](#)]
- 7 **Bergholt MS**, Serio A, Albro MB. Raman Spectroscopy: Guiding Light for the Extracellular Matrix. *Front Bioeng Biotechnol* 2019; **7**: 303 [PMID: [31737621](#) DOI: [10.3389/fbioe.2019.00303](#)]
- 8 **Sherlock BE**, Chen J, Mansfield JC, Green E, Winlove CP. Biophotonic tools for probing extracellular matrix mechanics. *Matrix Biol Plus* 2021; **12**: 100093 [PMID: [34934939](#) DOI: [10.1016/j.mbplus.2021.100093](#)]
- 9 **Reimann C**, Brangsch J, Colletini F, Walter T, Hamm B, Botnar RM, Makowski MR. Molecular imaging of the extracellular matrix in the context of atherosclerosis. *Adv Drug Deliv Rev* 2017; **113**: 49-60 [PMID: [27639968](#) DOI: [10.1016/j.addr.2016.09.005](#)]
- 10 **Chow MJ**, Turcotte R, Lin CP, Zhang Y. Arterial extracellular matrix: a mechanobiological study of the contributions and interactions of elastin and collagen. *Biophys J* 2014; **106**: 2684-2692 [PMID: [24940786](#) DOI: [10.1016/j.bpj.2014.05.014](#)]
- 11 **Pezzoli D**, Di Paolo J, Kumra H, Fois G, Candiani G, Reinhardt DP, Mantovani D. Fibronectin promotes elastin deposition, elasticity and mechanical strength in cellularised collagen-based scaffolds. *Biomaterials* 2018; **180**: 130-142 [PMID: [30036726](#) DOI: [10.1016/j.biomaterials.2018.07.013](#)]
- 12 **Feng Q**, Li D, Li Q, Cao X, Dong H. Microgel assembly: Fabrication, characteristics and application in tissue engineering and regenerative medicine. *Bioact Mater* 2022; **9**: 105-119 [PMID: [34820559](#) DOI: [10.1016/j.bioactmat.2021.07.020](#)]
- 13 **Suh EJ**, Remillard MY, Legesse-Miller A, Johnson EL, Lemons JM, Chapman TR, Forman JJ, Kojima M, Silberman ES, Collier HA. A microRNA network regulates proliferative timing and extracellular matrix synthesis during cellular quiescence in fibroblasts. *Genome Biol* 2012; **13**: R121 [PMID: [23259597](#) DOI: [10.1186/gb-2012-13-12-r121](#)]
- 14 **Feng S**, Gao Y, Yin D, Lv L, Wen Y, Li Z, Wang B, Wu M, Liu B. Identification of Lumican and Fibromodulin as Hub Genes Associated with Accumulation of Extracellular Matrix in Diabetic Nephropathy. *Kidney Blood Press Res* 2021; **46**: 275-285 [PMID: [33887734](#) DOI: [10.1159/000514013](#)]
- 15 **Wang Z**, Chen X, Li C, Tang W. Application of weighted gene co-expression network analysis to identify novel key genes in diabetic nephropathy. *J Diabetes Investig* 2022; **13**: 112-124 [PMID: [34245661](#) DOI: [10.1111/jdi.13628](#)]
- 16 **Chen FM**, Liu X. Advancing biomaterials of human origin for tissue engineering. *Prog Polym Sci* 2016; **53**: 86-168 [PMID: [27022202](#) DOI: [10.1016/j.progpolymsci.2015.02.004](#)]
- 17 **Daley WP**, Peters SB, Larsen M. Extracellular matrix dynamics in development and regenerative medicine. *J Cell Sci* 2008; **121**: 255-264 [PMID: [18216330](#) DOI: [10.1242/jcs.006064](#)]
- 18 **Karamanos NK**, Theocharis AD, Piperigkou Z, Manou D, Passi A, Skandalis SS, Vynios DH, Orian-Rousseau V, Ricard-Blum S, Schmelzer CEH, Duca L, Durbeej M, Afratis NA, Troeberg L, Franchi M, Masola V, Onisto M. A guide to the composition and functions of the extracellular matrix. *FEBS J* 2021; **288**: 6850-6912 [PMID: [33605520](#) DOI: [10.1111/febs.15776](#)]
- 19 **Chiang CE**, Fang YQ, Ho CT, Assunção M, Lin SJ, Wang YC, Blocki A, Huang CC. Bioactive Decellularized Extracellular Matrix Derived from 3D Stem Cell Spheroids under Macromolecular Crowding Serves as a Scaffold for Tissue Engineering. *Adv Healthc Mater* 2021; **10**: e2100024 [PMID: [33890420](#) DOI: [10.1002/adhm.202100024](#)]
- 20 **Wilks BT**, Evans EB, Howes A, Hopkins CM, Nakhla MN, Williams G, Morgan JR. Quantifying Cell-Derived Changes in Collagen Synthesis, Alignment, and Mechanics in a 3D Connective Tissue Model. *Adv Sci (Weinh)* 2022; **9**: e2103939 [PMID: [35102708](#) DOI: [10.1002/advs.202103939](#)]
- 21 **Assunção M**, Yiu CHK, Wan HY, Wang D, Ker DFE, Tuan RS, Blocki A. Hyaluronic acid drives mesenchymal stromal cell-derived extracellular matrix assembly by promoting fibronectin fibrillogenesis. *J Mater Chem B* 2021; **9**: 7205-7215 [PMID: [33710248](#) DOI: [10.1039/d1tb00268f](#)]
- 22 **Lin S**, Mequanint K. Bioreactor-induced mesenchymal progenitor cell differentiation and elastic fiber assembly in engineered vascular tissues. *Acta Biomater* 2017; **59**: 200-209 [PMID: [28690007](#) DOI: [10.1016/j.actbio.2017.07.012](#)]
- 23 **Urbanczyk M**, Layland SL, Schenke-Layland K. The role of extracellular matrix in biomechanics and its impact on bioengineering of cells and 3D tissues. *Matrix Biol* 2020; **85-86**: 1-14 [PMID: [31805360](#) DOI: [10.1016/j.matbio.2019.11.005](#)]
- 24 **Abraham VC**, Miller LN, Pratt SD, Putman B, Kim L, Gopalakrishnan SM, King A. Implementation of a human podocyte injury model of chronic kidney disease for profiling of renoprotective compounds. *Eur J Pharmacol* 2017; **815**: 219-232 [PMID: [28899697](#) DOI: [10.1016/j.ejphar.2017.09.006](#)]
- 25 **Yoshida Y**, Miyazaki K, Kamiie J, Sato M, Okuizumi S, Kenmochi A, Kamijo K, Nabetani T, Tsugita A, Xu B, Zhang Y, Yaoita E, Osawa T, Yamamoto T. Two-dimensional electrophoretic profiling of normal human kidney glomerulus

- proteome and construction of an extensible markup language (XML)-based database. *Proteomics* 2005; **5**: 1083-1096 [PMID: [15668994](#) DOI: [10.1002/pmic.200401075](#)]
- 26 **Miyamoto M**, Yoshida Y, Taguchi I, Nagasaka Y, Tasaki M, Zhang Y, Xu B, Nameta M, Sezaki H, Cuellar LM, Osawa T, Morishita H, Sekiyama S, Yaoita E, Kimura K, Yamamoto T. In-depth proteomic profiling of the normal human kidney glomerulus using two-dimensional protein prefractionation in combination with liquid chromatography-tandem mass spectrometry. *J Proteome Res* 2007; **6**: 3680-3690 [PMID: [17711322](#) DOI: [10.1021/pr070203n](#)]
  - 27 **Lennon R**, Byron A, Humphries JD, Randles MJ, Carisey A, Murphy S, Knight D, Brenchley PE, Zent R, Humphries MJ. Global analysis reveals the complexity of the human glomerular extracellular matrix. *J Am Soc Nephrol* 2014; **25**: 939-951 [PMID: [24436468](#) DOI: [10.1681/ASN.2013030233](#)]
  - 28 **Hobeika L**, Barati MT, Caster DJ, McLeish KR, Merchant ML. Characterization of glomerular extracellular matrix by proteomic analysis of laser-captured microdissected glomeruli. *Kidney Int* 2017; **91**: 501-511 [PMID: [27988214](#) DOI: [10.1016/j.kint.2016.09.044](#)]
  - 29 **Suleiman H**, Zhang L, Roth R, Heuser JE, Miner JH, Shaw AS, Dani A. Nanoscale protein architecture of the kidney glomerular basement membrane. *Elife* 2013; **2**: e01149 [PMID: [24137544](#) DOI: [10.7554/eLife.01149](#)]
  - 30 **Beisswenger PJ**, Spiro RG. Studies on the human glomerular basement membrane. Composition, nature of the carbohydrate units and chemical changes in diabetes mellitus. *Diabetes* 1973; **22**: 180-193 [PMID: [4347583](#) DOI: [10.2337/diab.22.3.180](#)]
  - 31 **Mohan PS**, Carter WG, Spiro RG. Occurrence of type VI collagen in extracellular matrix of renal glomeruli and its increase in diabetes. *Diabetes* 1990; **39**: 31-37 [PMID: [2210058](#) DOI: [10.2337/diacare.39.1.31](#)]
  - 32 **Zhu D**, Kim Y, Steffes MW, Groppoli TJ, Butkowski RJ, Mauer SM. Application of electron microscopic immunocytochemistry to the human kidney: distribution of type IV and type VI collagen in normal human kidney. *J Histochem Cytochem* 1994; **42**: 577-584 [PMID: [8157929](#) DOI: [10.1177/42.5.8157929](#)]
  - 33 **Tamsma JT**, van den Born J, Bruijn JA, Assmann KJ, Weening JJ, Berden JH, Wieslander J, Schrama E, Hermans J, Veerkamp JH. Expression of glomerular extracellular matrix components in human diabetic nephropathy: decrease of heparan sulphate in the glomerular basement membrane. *Diabetologia* 1994; **37**: 313-320 [PMID: [8174847](#) DOI: [10.1007/bf00398060](#)]
  - 34 **Groffen AJ**, Ruegg MA, Dijkman H, van de Velden TJ, Buskens CA, van den Born J, Assmann KJ, Monnens LA, Veerkamp JH, van den Heuvel LP. Agrin is a major heparan sulfate proteoglycan in the human glomerular basement membrane. *J Histochem Cytochem* 1998; **46**: 19-27 [PMID: [9405491](#) DOI: [10.1177/002215549804600104](#)]
  - 35 **Murata K**. Acidic glycosaminoglycans in human kidney tissue. *Clin Chim Acta* 1975; **63**: 157-169 [PMID: [126123](#) DOI: [10.1016/0009-8981\(75\)90158-8](#)]
  - 36 **Parthasarathy N**, Spiro RG. Effect of diabetes on the glycosaminoglycan component of the human glomerular basement membrane. *Diabetes* 1982; **31**: 738-741 [PMID: [6219021](#) DOI: [10.2337/diab.31.8.738](#)]
  - 37 **Shimomura H**, Spiro RG. Studies on macromolecular components of human glomerular basement membrane and alterations in diabetes. Decreased levels of heparan sulfate proteoglycan and laminin. *Diabetes* 1987; **36**: 374-381 [PMID: [2948855](#) DOI: [10.2337/diab.36.3.374](#)]
  - 38 **Oomura A**, Nakamura T, Arakawa M, Ooshima A, Isemura M. Alterations in the extracellular matrix components in human glomerular diseases. *Virchows Arch A Pathol Anat Histopathol* 1989; **415**: 151-159 [PMID: [2500770](#) DOI: [10.1007/bf00784353](#)]
  - 39 **Nerlich A**, Schleicher E. Immunohistochemical localization of extracellular matrix components in human diabetic glomerular lesions. *Am J Pathol* 1991; **139**: 889-899 [PMID: [1928305](#)]
  - 40 **Nerlich AG**, Schleicher ED, Wiest I, Specks U, Timpl R. Immunohistochemical localization of collagen VI in diabetic glomeruli. *Kidney Int* 1994; **45**: 1648-1656 [PMID: [7933812](#) DOI: [10.1038/ki.1994.216](#)]
  - 41 **Groffen AJ**, Buskens CA, van Kuppevelt TH, Veerkamp JH, Monnens LA, van den Heuvel LP. Primary structure and high expression of human agrin in basement membranes of adult lung and kidney. *Eur J Biochem* 1998; **254**: 123-128 [PMID: [9652404](#) DOI: [10.1046/j.1432-1327.1998.2540123.x](#)]
  - 42 **Groffen AJ**, Hop FW, Tryggvason K, Dijkman H, Assmann KJ, Veerkamp JH, Monnens LA, Van den Heuvel LP. Evidence for the existence of multiple heparan sulfate proteoglycans in the human glomerular basement membrane and mesangial matrix. *Eur J Biochem* 1997; **247**: 175-182 [PMID: [9249024](#) DOI: [10.1111/j.1432-1033.1997.00175.x](#)]
  - 43 **Kriz W**, Löwen J, Federico G, van den Born J, Gröne E, Gröne HJ. Accumulation of worn-out GBM material substantially contributes to mesangial matrix expansion in diabetic nephropathy. *Am J Physiol Renal Physiol* 2017; **312**: F1101-F1111 [PMID: [28228399](#) DOI: [10.1152/ajprenal.00020.2017](#)]
  - 44 **Babal P**, Slugen I, Danis D, Zaviacic M, Gardner WA Jr. Sialic acid expression in normal and diseased human kidney. *Acta Histochem* 1996; **98**: 71-77 [PMID: [9054191](#)]
  - 45 **Bowles WHD**, Gloster TM. Sialidase and Sialyltransferase Inhibitors: Targeting Pathogenicity and Disease. *Front Mol Biosci* 2021; **8**: 705133 [PMID: [34395532](#) DOI: [10.3389/fmolb.2021.705133](#)]
  - 46 **Fearon DT**. Regulation by membrane sialic acid of beta1H-dependent decay-dissociation of amplification C3 convertase of the alternative complement pathway. *Proc Natl Acad Sci U S A* 1978; **75**: 1971-1975 [PMID: [273923](#) DOI: [10.1073/pnas.75.4.1971](#)]
  - 47 **Blackmore TK**, Sadlon TA, Ward HM, Lublin DM, Gordon DL. Identification of a heparin binding domain in the seventh short consensus repeat of complement factor H. *J Immunol* 1996; **157**: 5422-5427 [PMID: [8955190](#)]
  - 48 **Ram S**, Sharma AK, Simpson SD, Gulati S, McQuillen DP, Pangburn MK, Rice PA. A novel sialic acid binding site on factor H mediates serum resistance of sialylated *Neisseria gonorrhoeae*. *J Exp Med* 1998; **187**: 743-752 [PMID: [9480984](#) DOI: [10.1084/jem.187.5.743](#)]
  - 49 **Hellwage J**, Jokiranta TS, Friese MA, Wolk TU, Kampen E, Zipfel PF, Meri S. Complement C3b/C3d and cell surface polyanions are recognized by overlapping binding sites on the most carboxyl-terminal domain of complement factor H. *J Immunol* 2002; **169**: 6935-6944 [PMID: [12471127](#) DOI: [10.4049/jimmunol.169.12.6935](#)]
  - 50 **Feyzi E**, Saldeen T, Larsson E, Lindahl U, Salmivirta M. Age-dependent modulation of heparan sulfate structure and function. *J Biol Chem* 1998; **273**: 13395-13398 [PMID: [9593669](#) DOI: [10.1074/jbc.273.22.13395](#)]

- 51 **Pangburn MK**, Müller-Eberhard HJ. Complement C3 convertase: cell surface restriction of beta1H control and generation of restriction on neuraminidase-treated cells. *Proc Natl Acad Sci U S A* 1978; **75**: 2416-2420 [PMID: [276881](#) DOI: [10.1073/pnas.75.5.2416](#)]
- 52 **Meri S**, Pangburn MK. Discrimination between activators and nonactivators of the alternative pathway of complement: regulation via a sialic acid/polyanion binding site on factor H. *Proc Natl Acad Sci U S A* 1990; **87**: 3982-3986 [PMID: [1692629](#) DOI: [10.1073/pnas.87.10.3982](#)]
- 53 **Blackmore TK**, Hellwage J, Sadlon TA, Higgs N, Zipfel PF, Ward HM, Gordon DL. Identification of the second heparin-binding domain in human complement factor H. *J Immunol* 1998; **160**: 3342-3348 [PMID: [9531293](#)]
- 54 **Loeven MA**, Rops AL, Berden JH, Daha MR, Rabelink TJ, van der Vlag J. The role of heparan sulfate as determining pathogenic factor in complement factor H-associated diseases. *Mol Immunol* 2015; **63**: 203-208 [PMID: [25246018](#) DOI: [10.1016/j.molimm.2014.08.005](#)]
- 55 **Colognato H**, Winkelmann DA, Yurchenco PD. Laminin polymerization induces a receptor-cytoskeleton network. *J Cell Biol* 1999; **145**: 619-631 [PMID: [10225961](#) DOI: [10.1083/jcb.145.3.619](#)]
- 56 **Smith PS**, Fanning JC, Aarons I. The structure of the normal human glomerular basement membrane. Ultrastructural localization of type IV collagen and laminin. *Pathology* 1989; **21**: 254-258 [PMID: [2633114](#) DOI: [10.3109/00313028909061069](#)]
- 57 **Zenker M**, Aigner T, Wendler O, Tralau T, Müntefering H, Fenski R, Pitz S, Schumacher V, Royer-Pokora B, Wühl E, Cochat P, Bouvier R, Kraus C, Mark K, Madlon H, Dötsch J, Rascher W, Maruniak-Chudek I, Lennert T, Neumann LM, Reis A. Human laminin beta2 deficiency causes congenital nephrosis with mesangial sclerosis and distinct eye abnormalities. *Hum Mol Genet* 2004; **13**: 2625-2632 [PMID: [15367484](#) DOI: [10.1093/hmg/ddh284](#)]
- 58 **Hasselbacher K**, Wiggins RC, Matejas V, Hinkes BG, Mucha B, Hoskins BE, Ozaltin F, Nürnberg G, Becker C, Hangan D, Pohl M, Kuwertz-Bröking E, Griebel M, Schumacher V, Royer-Pokora B, Bakaloglu A, Nürnberg P, Zenker M, Hildebrandt F. Recessive missense mutations in LAMB2 expand the clinical spectrum of LAMB2-associated disorders. *Kidney Int* 2006; **70**: 1008-1012 [PMID: [16912710](#) DOI: [10.1038/sj.ki.5001679](#)]
- 59 **Weiss MA**, Ooi BS, Ooi YM, Engvall E, Ruoslahti E. Immunofluorescent localization of fibronectin in the human kidney. *Lab Invest* 1979; **41**: 340-347 [PMID: [385978](#)]
- 60 **Dixon AJ**, Burns J, Dunnill MS, McGee JO. Distribution of fibronectin in normal and diseased human kidneys. *J Clin Pathol* 1980; **33**: 1021-1028 [PMID: [7002956](#) DOI: [10.1136/jcp.33.11.1021](#)]
- 61 **Sottile J**, Hocking DC. Fibronectin polymerization regulates the composition and stability of extracellular matrix fibrils and cell-matrix adhesions. *Mol Biol Cell* 2002; **13**: 3546-3559 [PMID: [12388756](#) DOI: [10.1091/mbc.e02-01-0048](#)]
- 62 **Assmann KJ**, Koene RA, Wetzels JF. Familial glomerulonephritis characterized by massive deposits of fibronectin. *Am J Kidney Dis* 1995; **25**: 781-791 [PMID: [7747733](#) DOI: [10.1016/0272-6386\(95\)90555-3](#)]
- 63 **Castelletti F**, Donadelli R, Banterla F, Hildebrandt F, Zipfel PF, Bresin E, Otto E, Skerka C, Renieri A, Todeschini M, Caprioli J, Caruso RM, Artuso R, Remuzzi G, Noris M. Mutations in FN1 cause glomerulopathy with fibronectin deposits. *Proc Natl Acad Sci U S A* 2008; **105**: 2538-2543 [PMID: [18268355](#) DOI: [10.1073/pnas.0707730105](#)]
- 64 **Ertoý Baydar D**, Kutlugun AA, Bresin E, Piras R. A case of familial glomerulopathy with fibronectin deposits caused by the Y973C mutation in fibronectin. *Am J Kidney Dis* 2013; **61**: 514-518 [PMID: [23219110](#) DOI: [10.1053/j.ajkd.2012.08.050](#)]
- 65 **Ohtsubo H**, Okada T, Nozu K, Takaoka Y, Shono A, Asanuma K, Zhang L, Nakanishi K, Taniguchi-Ikeda M, Kaito H, Iijima K, Nakamura S. Identification of mutations in FN1 leading to glomerulopathy with fibronectin deposits. *Pediatr Nephrol* 2016; **31**: 1459-1467 [PMID: [27056061](#) DOI: [10.1007/s00467-016-3368-7](#)]
- 66 **Bonting SL**, De Bruin H, Pollak VE. QUANTITATIVE HISTOCHEMISTRY OF THE NEPHRON. VI. HYDROXYPROLINE IN THE HUMAN GLOMERULUS. *J Clin Invest* 1961; **40**: 177-180 [PMID: [16695847](#) DOI: [10.1172/jci104242](#)]
- 67 **Beisswenger PG**, Spiro RG. Human glomerular basement membrane: chemical alteration in diabetes mellitus. *Science* 1970; **168**: 596-598 [PMID: [5436594](#) DOI: [10.1126/science.168.3931.596](#)]
- 68 **Kefalides NA**. Biochemical properties of human glomerular basement membrane in normal and diabetic kidneys. *J Clin Invest* 1974; **53**: 403-407 [PMID: [11344553](#) DOI: [10.1172/jci107573](#)]
- 69 **Funabiki K**, Horikoshi S, Tomino Y, Nagai Y, Koide H. Immunohistochemical analysis of extracellular components in the glomerular sclerosis of patients with glomerulonephritis. *Clin Nephrol* 1990; **34**: 239-246 [PMID: [2073766](#)]
- 70 **Yoshioka K**, Takemura T, Tohda M, Akano N, Miyamoto H, Ooshima A, Maki S. Glomerular localization of type III collagen in human kidney disease. *Kidney Int* 1989; **35**: 1203-1211 [PMID: [2671464](#) DOI: [10.1038/ki.1989.111](#)]
- 71 **Razzaque MS**, Koji T, Taguchi T, Harada T, Nakane PK. In situ localization of type III and type IV collagen-expressing cells in human diabetic nephropathy. *J Pathol* 1994; **174**: 131-138 [PMID: [7965408](#) DOI: [10.1002/path.1711740209](#)]
- 72 **Bongers EM**, Huysmans FT, Levchenko E, de Rooy JW, Blickman JG, Admiraal RJ, Huygen PL, Cruysberg JR, Toolens PA, Prins JB, Krabbe PF, Borm GF, Schoots J, van Bokhoven H, van Remortele AM, Hoefsloot LH, van Kampen A, Knoers NV. Genotype-phenotype studies in nail-patella syndrome show that LMX1B mutation location is involved in the risk of developing nephropathy. *Eur J Hum Genet* 2005; **13**: 935-946 [PMID: [15928687](#) DOI: [10.1038/sj.ejhg.5201446](#)]
- 73 **Oe Y**, Mishima E, Mori T, Okamoto K, Honkura Y, Nagasawa T, Yoshida M, Sato H, Suzuki J, Ikeda R, Sohara E, Uchida S, Katori Y, Miyazaki M. A Novel Mutation in LMX1B (p.Pro219Ala) Causes Focal Segmental Glomerulosclerosis with Alport Syndrome-like Phenotype. *Intern Med* 2021; **60**: 2991-2996 [PMID: [33814499](#) DOI: [10.2169/internalmedicine.6987-20](#)]
- 74 **Hudson BG**, Tryggvason K, Sundaramoorthy M, Neilson EG. Alport's syndrome, Goodpasture's syndrome, and type IV collagen. *N Engl J Med* 2003; **348**: 2543-2556 [PMID: [12815141](#) DOI: [10.1056/NEJMra022296](#)]
- 75 **Edwards N**, Rice SJ, Raman S, Hynes AM, Srivastava S, Moore I, Al-Hamed M, Xu Y, Santibanez-Koref M, Thwaites DT, Gale DP, Sayer JA. A novel LMX1B mutation in a family with end-stage renal disease of 'unknown cause'. *Clin Kidney J* 2015; **8**: 113-119 [PMID: [25713721](#) DOI: [10.1093/ckj/sfu129](#)]
- 76 **Isojima T**, Harita Y, Furuyama M, Sugawara N, Ishizuka K, Horita S, Kajiho Y, Miura K, Igarashi T, Hattori M, Kitanaka S. LMX1B mutation with residual transcriptional activity as a cause of isolated glomerulopathy. *Nephrol Dial Transplant*



- 2014; **29**: 81-88 [PMID: [24042019](#) DOI: [10.1093/ndt/gft359](#)]
- 77 **Konomoto T**, Imamura H, Orita M, Tanaka E, Moritake H, Sato Y, Fujimoto S, Harita Y, Hisano S, Yoshiura K, Nunoi H. Clinical and histological findings of autosomal dominant renal-limited disease with LMX1B mutation. *Nephrology (Carlton)* 2016; **21**: 765-773 [PMID: [26560070](#) DOI: [10.1111/nep.12666](#)]
  - 78 **Andeen NK**, Schleit J, Blosser CD, Dorschner MO, Hisama FM, Smith KD. LMX1B-Associated Nephropathy With Type III Collagen Deposition in the Glomerular and Tubular Basement Membranes. *Am J Kidney Dis* 2018; **72**: 296-301 [PMID: [29246420](#) DOI: [10.1053/j.ajkd.2017.09.023](#)]
  - 79 **Silverman ME**, Goodman RM, Cuppage FE. The Nail-Patella syndrome. Clinical findings and ultrastructural observations in the kidney. *Arch Intern Med* 1967; **120**: 68-74 [PMID: [6028699](#) DOI: [10.1001/archinte.120.1.68](#)]
  - 80 **Boyer O**, Woerner S, Yang F, Oakeley EJ, Linghu B, Gribouval O, Tête MJ, Duca JS, Klickstein L, Damask AJ, Szustakowski JD, Heibel F, Matignon M, Baudouin V, Chantrel F, Champigneulle J, Martin L, Nitschké P, Gubler MC, Johnson KJ, Chibout SD, Antignac C. LMX1B mutations cause hereditary FSGS without extrarenal involvement. *J Am Soc Nephrol* 2013; **24**: 1216-1222 [PMID: [23687361](#) DOI: [10.1681/ASN.2013020171](#)]
  - 81 **Ghoumid J**, Petit F, Holder-Espinasse M, Jourdain AS, Guerra J, Dieux-Coeslier A, Figeac M, Porchet N, Manouvrier-Hanu S, Escande F. Nail-Patella Syndrome: clinical and molecular data in 55 families raising the hypothesis of a genetic heterogeneity. *Eur J Hum Genet* 2016; **24**: 44-50 [PMID: [25898926](#) DOI: [10.1038/ejhg.2015.77](#)]
  - 82 **Shimohata H**, Miyake Y, Yoshida Y, Usui J, Mori T, Sohara E, Uchida S, Hirayama K, Kobayashi M. LMX1B-associated nephropathy that showed myelin figures on electron microscopy. *CEN Case Rep* 2021; **10**: 588-591 [PMID: [34076843](#) DOI: [10.1007/s13730-021-00612-y](#)]
  - 83 **Lei L**, Oh G, Sutherland S, Abra G, Higgins J, Sibley R, Troxell M, Kambham N. Myelin bodies in LMX1B-associated nephropathy: potential for misdiagnosis. *Pediatr Nephrol* 2020; **35**: 1647-1657 [PMID: [32356190](#) DOI: [10.1007/s00467-020-04564-w](#)]
  - 84 **Duggal R**, Nada R, Rayat CS, Rane SU, Sakhuja V, Joshi K. Collagenofibrotic glomerulopathy-a review. *Clin Kidney J* 2012; **5**: 7-12 [PMID: [26069739](#) DOI: [10.1093/ndtplus/sfr144](#)]
  - 85 **Kurien AA**, Larsen CP, Cossey LN. Collagenofibrotic glomerulopathy. *Clin Kidney J* 2015; **8**: 543-547 [PMID: [26413279](#) DOI: [10.1093/ckj/sfv061](#)]
  - 86 **Aoki T**, Hayashi K, Morinaga T, Tomida H, Hishida M, Yamamoto S, Kajiwarra N, Tamai H. Two brothers with collagenofibrotic glomerulopathy. *CEN Case Rep* 2015; **4**: 85-89 [PMID: [28509277](#) DOI: [10.1007/s13730-014-0145-y](#)]
  - 87 **Vogt BA**, Wyatt RJ, Burke BA, Simonton SC, Kashtan CE. Inherited factor H deficiency and collagen type III glomerulopathy. *Pediatr Nephrol* 1995; **9**: 11-15 [PMID: [7742208](#) DOI: [10.1007/bf00858956](#)]
  - 88 **Kleppel MM**, Santi PA, Cameron JD, Wieslander J, Michael AF. Human tissue distribution of novel basement membrane collagen. *Am J Pathol* 1989; **134**: 813-825 [PMID: [2650557](#)]
  - 89 **Zhu D**, Kim Y, Steffes MW, Groppoli TJ, Butkowski RJ, Mauer SM. Glomerular distribution of type IV collagen in diabetes by high resolution quantitative immunochemistry. *Kidney Int* 1994; **45**: 425-433 [PMID: [8164429](#) DOI: [10.1038/ki.1994.55](#)]
  - 90 **Barker DF**, Hostikka SL, Zhou J, Chow LT, Oliphant AR, Gerken SC, Gregory MC, Skolnick MH, Atkin CL, Tryggvason K. Identification of mutations in the COL4A5 collagen gene in Alport syndrome. *Science* 1990; **248**: 1224-1227 [PMID: [2349482](#) DOI: [10.1126/science.2349482](#)]
  - 91 **Voskarides K**, Damianou L, Neocleous V, Zouvani I, Christodoulidou S, Hadjiconstantinou V, Ioannou K, Athanasiou Y, Patsias C, Alexopoulos E, Pierides A, Kyriacou K, Deltas C. COL4A3/COL4A4 mutations producing focal segmental glomerulosclerosis and renal failure in thin basement membrane nephropathy. *J Am Soc Nephrol* 2007; **18**: 3004-3016 [PMID: [17942953](#) DOI: [10.1681/asn.2007040444](#)]
  - 92 **Parkin JD**, San Antonio JD, Pedchenko V, Hudson B, Jensen ST, Savage J. Mapping structural landmarks, ligand binding sites, and missense mutations to the collagen IV heterotrimers predicts major functional domains, novel interactions, and variation in phenotypes in inherited diseases affecting basement membranes. *Hum Mutat* 2011; **32**: 127-143 [PMID: [21280145](#) DOI: [10.1002/humu.21401](#)]
  - 93 **Kashtan CE**, Ding J, Garosi G, Heidet L, Massella L, Nakanishi K, Nozu K, Renieri A, Rheault M, Wang F, Gross O. Alport syndrome: a unified classification of genetic disorders of collagen IV  $\alpha$ 345: a position paper of the Alport Syndrome Classification Working Group. *Kidney Int* 2018; **93**: 1045-1051 [PMID: [29551517](#) DOI: [10.1016/j.kint.2017.12.018](#)]
  - 94 **Savage J**, Storey H, Watson E, Hertz JM, Deltas C, Renieri A, Mari F, Hilbert P, Plevova P, Byers P, Cerkauskaite A, Gregory M, Cerkauskiene R, Ljubanovic DG, Becherucci F, Errichiello C, Massella L, Aiello V, Lennon R, Hopkinson L, Koziell A, Lungu A, Rothe HM, Hoefele J, Zacchia M, Martic TN, Gupta A, van Eerde A, Gear S, Landini S, Palazzo V, Al-Rabadi L, Claes K, Corveleyn A, Van Hoof E, van Geel M, Williams M, Ashton E, Belge H, Ars E, Bierzynska A, Gangemi C, Lipska-Ziętkiewicz BS. Consensus statement on standards and guidelines for the molecular diagnostics of Alport syndrome: refining the ACMG criteria. *Eur J Hum Genet* 2021; **29**: 1186-1197 [PMID: [33854215](#) DOI: [10.1038/s41431-021-00858-1](#)]
  - 95 **Barua M**, Paterson AD. Population-based studies reveal an additive role of type IV collagen variants in hematuria and albuminuria. *Pediatr Nephrol* 2022; **37**: 253-262 [PMID: [33635378](#) DOI: [10.1007/s00467-021-04934-y](#)]
  - 96 **Papazachariou L**, Papagregoriou G, Hadjipanagi D, Demosthenous P, Voskarides K, Koutsofti C, Stylianou K, Ioannou P, Xydakis D, Tzanakis I, Papadaki A, Kallivretakis N, Nikolakakis N, Perysinaki G, Gale DP, Diamantopoulos A, Goudas P, Goumenos D, Soloukides A, Boletis I, Melexopoulou C, Georgaki E, Frysira E, Komianou F, Grekas D, Paliouras C, Alivanis P, Vergoulas G, Pierides A, Daphnis E, Deltas C. Frequent COL4 mutations in familial microhematuria accompanied by later-onset Alport nephropathy due to focal segmental glomerulosclerosis. *Clin Genet* 2017; **92**: 517-527 [PMID: [28632965](#) DOI: [10.1111/cge.13077](#)]
  - 97 **Malone AF**, Phelan PJ, Hall G, Cetincelik U, Homstad A, Alonso AS, Jiang R, Lindsey TB, Wu G, Sparks MA, Smith SR, Webb NJ, Kalra PA, Adeyemo AA, Shaw AS, Conlon PJ, Jennette JC, Howell DN, Winn MP, Gbadegesin RA. Rare hereditary COL4A3/COL4A4 variants may be mistaken for familial focal segmental glomerulosclerosis. *Kidney Int* 2014; **86**: 1253-1259 [PMID: [25229338](#) DOI: [10.1038/ki.2014.305](#)]

- 98 **Xie J**, Wu X, Ren H, Wang W, Wang Z, Pan X, Hao X, Tong J, Ma J, Ye Z, Meng G, Zhu Y, Kiryluk K, Kong X, Hu L, Chen N. COL4A3 mutations cause focal segmental glomerulosclerosis. *J Mol Cell Biol* 2014; **6**: 498-505 [PMID: 25596306 DOI: 10.1093/jmcb/mju040]
- 99 **Yao T**, Udwan K, John R, Rana A, Haghighi A, Xu L, Hack S, Reich HN, Hladunewich MA, Cattran DC, Paterson AD, Pei Y, Barua M. Integration of Genetic Testing and Pathology for the Diagnosis of Adults with FSGS. *Clin J Am Soc Nephrol* 2019; **14**: 213-223 [PMID: 30647093 DOI: 10.2215/CJN.08750718]
- 100 **Dische FE**. Measurement of glomerular basement membrane thickness and its application to the diagnosis of thin-membrane nephropathy. *Arch Pathol Lab Med* 1992; **116**: 43-49 [PMID: 1734832]
- 101 **Kashtan CE**, Segal Y. Genetic disorders of glomerular basement membranes. *Nephron Clin Pract* 2011; **118**: c9-c18 [PMID: 21071975 DOI: 10.1159/000320876]
- 102 **Nogueira M**, Cartwright J Jr, Horn K, Doe N, Shappell S, Barrios R, Coroneos E, Truong LD. Thin basement membrane disease with heavy proteinuria or nephrotic syndrome at presentation. *Am J Kidney Dis* 2000; **35**: E15 [PMID: 10739808 DOI: 10.1016/s0272-6386(00)70033-3]
- 103 **Quinlan C**, Rheault MN. Genetic Basis of Type IV Collagen Disorders of the Kidney. *Clin J Am Soc Nephrol* 2021; **16**: 1101-1109 [PMID: 33849932 DOI: 10.2215/CJN.19171220]
- 104 **Hoorn EJ**, Taams NE, Hurskainen T, Salih M, Weening JJ, Jonkman MF, Pas HH, Schreurs MW. Bullous Pemphigoid With a Dual Pattern of Glomerular Immune Complex Disease. *Am J Kidney Dis* 2016; **67**: 302-306 [PMID: 26616334 DOI: 10.1053/j.ajkd.2015.10.015]
- 105 **Hurskainen T**, Moilanen J, Sormunen R, Franzke CW, Soininen R, Loeffek S, Huilaja L, Nuutinen M, Bruckner-Tuderman L, Autio-Harmainen H, Tasanen K. Transmembrane collagen XVII is a novel component of the glomerular filtration barrier. *Cell Tissue Res* 2012; **348**: 579-588 [PMID: 22457199 DOI: 10.1007/s00441-012-1368-x]
- 106 **Saarela J**, Rehn M, Oikarinen A, Autio-Harmainen H, Pihlajaniemi T. The short and long forms of type XVIII collagen show clear tissue specificities in their expression and location in basement membrane zones in humans. *Am J Pathol* 1998; **153**: 611-626 [PMID: 9708820 DOI: 10.1016/S0002-9440(10)65603-9]
- 107 **Enoksen ITT**, Svistounov D, Norvik JV, Stefansson VTN, Solbu MD, Eriksen BO, Melsom T. Serum Matrix Metalloproteinase 7 and accelerated GFR decline in a general non-diabetic population. *Nephrol Dial Transplant* 2021 [PMID: 34436577 DOI: 10.1093/ndt/gfab251]
- 108 **Głowińska-Olszewska B**, Urban M. Elevated matrix metalloproteinase 9 and tissue inhibitor of metalloproteinase 1 in obese children and adolescents. *Metabolism* 2007; **56**: 799-805 [PMID: 17512313 DOI: 10.1016/j.metabol.2007.01.011]
- 109 **Ishikawa J**, Hoshida S, Eguchi K, Ishikawa S, Pickering TG, Shimada K, Kario K. Plasma tissue inhibitor of matrix metalloproteinase-1 level is increased in normotensive non-dippers in association with impaired glucose metabolism. *Hypertens Res* 2008; **31**: 2045-2051 [PMID: 19098376 DOI: 10.1291/hypres.31.2045]
- 110 **Li Y**, Yang J, Dai C, Wu C, Liu Y. Role for integrin-linked kinase in mediating tubular epithelial to mesenchymal transition and renal interstitial fibrogenesis. *J Clin Invest* 2003; **112**: 503-516 [PMID: 12925691 DOI: 10.1172/jci17913]
- 111 **Aggeli AS**, Kitsiou PV, Tzinia AK, Boutaud A, Hudson BG, Tsilibary EC. Selective binding of integrins from different renal cell types to the NC1 domain of alpha3 and alpha1 chains of type IV collagen. *J Nephrol* 2009; **22**: 130-136 [PMID: 19229828]
- 112 **Karamessinis PM**, Tzinia AK, Kitsiou PV, Stetler-Stevenson WG, Michael AF, Fan WW, Zhou B, Margaritis LH, Tsilibary EC. Proximal tubular epithelial cell integrins respond to high glucose by altered cell-matrix interactions and differentially regulate matrixin expression. *Lab Invest* 2002; **82**: 1081-1093 [PMID: 12177247 DOI: 10.1097/01.lab.0000022224.86237.31]
- 113 **Kitsiou PV**, Tzinia AK, Stetler-Stevenson WG, Michael AF, Fan WW, Zhou B, Tsilibary EC. Glucose-induced changes in integrins and matrix-related functions in cultured human glomerular epithelial cells. *Am J Physiol Renal Physiol* 2003; **284**: F671-F679 [PMID: 12620921 DOI: 10.1152/ajprenal.00266.2002]
- 114 **Guo L**, Sanders PW, Woods A, Wu C. The distribution and regulation of integrin-linked kinase in normal and diabetic kidneys. *Am J Pathol* 2001; **159**: 1735-1742 [PMID: 11696434 DOI: 10.1016/s0002-9440(10)63020-9]
- 115 **van Roeyen CR**, Ostendorf T, Denecke B, Bokemeyer D, Behrmann I, Strutz F, Lichenstein HS, LaRochelle WJ, Pena CE, Chaudhuri A, Floege J. Biological responses to PDGF-BB vs PDGF-DD in human mesangial cells. *Kidney Int* 2006; **69**: 1393-1402 [PMID: 16557224 DOI: 10.1038/sj.ki.5000332]
- 116 **Dey N**, Ghosh-Choudhury N, Kasinath BS, Choudhury GG. TGFβ-stimulated microRNA-21 utilizes PTEN to orchestrate AKT/mTORC1 signaling for mesangial cell hypertrophy and matrix expansion. *PLoS One* 2012; **7**: e42316 [PMID: 22879939 DOI: 10.1371/journal.pone.0042316]
- 117 **Kim MK**, Maeng YI, Sung WJ, Oh HK, Park JB, Yoon GS, Cho CH, Park KK. The differential expression of TGF-β1, ILK and wnt signaling inducing epithelial to mesenchymal transition in human renal fibrogenesis: an immunohistochemical study. *Int J Clin Exp Pathol* 2013; **6**: 1747-1758 [PMID: 24040439]
- 118 **Yan Q**, Sui W, Xie S, Chen H, Zou G, Guo J, Zou H. Expression and role of integrin-linked kinase and collagen IV in human renal allografts with interstitial fibrosis and tubular atrophy. *Transpl Immunol* 2010; **23**: 1-5 [PMID: 20398767 DOI: 10.1016/j.trim.2010.04.001]
- 119 **Foster RR**, Hole R, Anderson K, Satchell SC, Coward RJ, Mathieson PW, Gillatt DA, Saleem MA, Bates DO, Harper SJ. Functional evidence that vascular endothelial growth factor may act as an autocrine factor on human podocytes. *Am J Physiol Renal Physiol* 2003; **284**: F1263-F1273 [PMID: 12620928 DOI: 10.1152/ajprenal.00276.2002]
- 120 **Simon M**, Gröne HJ, Jöhren O, Kullmer J, Plate KH, Risau W, Fuchs E. Expression of vascular endothelial growth factor and its receptors in human renal ontogenesis and in adult kidney. *Am J Physiol* 1995; **268**: F240-F250 [PMID: 7864162 DOI: 10.1152/ajprenal.1995.268.2.F240]
- 121 **Thomas S**, Vanuystel J, Gruden G, Rodríguez V, Burt D, Gnudi L, Hartley B, Viberti G. Vascular endothelial growth factor receptors in human mesangium in vitro and in glomerular disease. *J Am Soc Nephrol* 2000; **11**: 1236-1243 [PMID: 10864579 DOI: 10.1681/ASN.V1171236]
- 122 **Zhu X**, Wu S, Dahut WL, Parikh CR. Risks of proteinuria and hypertension with bevacizumab, an antibody against

- vascular endothelial growth factor: systematic review and meta-analysis. *Am J Kidney Dis* 2007; **49**: 186-193 [PMID: 17261421 DOI: 10.1053/j.ajkd.2006.11.039]
- 123 **Sartelet H**, Toupance O, Lorenzato M, Fadel F, Noel LH, Lagonotte E, Birembaut P, Chanard J, Rieu P. Sirolimus-induced thrombotic microangiopathy is associated with decreased expression of vascular endothelial growth factor in kidneys. *Am J Transplant* 2005; **5**: 2441-2447 [PMID: 16162193 DOI: 10.1111/j.1600-6143.2005.01047.x]
  - 124 **Kovalevich J**, Tracy B, Langford D. PINCH: More than just an adaptor protein in cellular response. *J Cell Physiol* 2011; **226**: 940-947 [PMID: 20945343 DOI: 10.1002/jcp.22437]
  - 125 **Ghatak S**, Morgner J, Wickström SA. ILK: a pseudokinase with a unique function in the integrin-actin linkage. *Biochem Soc Trans* 2013; **41**: 995-1001 [PMID: 23863169 DOI: 10.1042/BST20130062]
  - 126 **Kim YC**, Gonzalez-Nieves R, Cutler ML. Rsl1 contributes to cell adhesion and spreading in MCF10A cells via effects on P38 map kinase signaling. *Cell Adh Migr* 2015; **9**: 227-232 [PMID: 25482629 DOI: 10.4161/19336918.2014.972775]
  - 127 **Yang H**, Lin L, Sun K, Zhang T, Chen W, Li L, Xie Y, Wu C, Wei Z, Yu C. Complex structures of Rsl1 and PINCH1 reveal a regulatory mechanism of the ILK/PINCH/Parvin complex for F-actin dynamics. *Elife* 2021; **10** [PMID: 33587032 DOI: 10.7554/eLife.64395]
  - 128 **Górska A**, Mazur AJ. Integrin-linked kinase (ILK): the known vs. the unknown and perspectives. *Cell Mol Life Sci* 2022; **79**: 100 [PMID: 35089438 DOI: 10.1007/s00018-021-04104-1]
  - 129 **Velyvis A**, Yang Y, Wu C, Qin J. Solution structure of the focal adhesion adaptor PINCH LIM1 domain and characterization of its interaction with the integrin-linked kinase ankyrin repeat domain. *J Biol Chem* 2001; **276**: 4932-4939 [PMID: 11078733 DOI: 10.1074/jbc.M007632200]
  - 130 **Sepulveda JL**, Wu C. The parvins. *Cell Mol Life Sci* 2006; **63**: 25-35 [PMID: 16314921 DOI: 10.1007/s00018-005-5355-1]
  - 131 **Tu Y**, Huang Y, Zhang Y, Hua Y, Wu C. A new focal adhesion protein that interacts with integrin-linked kinase and regulates cell adhesion and spreading. *J Cell Biol* 2001; **153**: 585-598 [PMID: 11331308 DOI: 10.1083/jcb.153.3.585]
  - 132 **Fukuda T**, Guo L, Shi X, Wu C. CH-ILKBP regulates cell survival by facilitating the membrane translocation of protein kinase B/Akt. *J Cell Biol* 2003; **160**: 1001-1008 [PMID: 12654898 DOI: 10.1083/jcb.200212113]
  - 133 **Krishnamurti U**, Chen Y, Michael A, Kim Y, Fan WW, Wieslander J, Brunmark C, Rondeau E, Sraer JD, Delarue F, Tsilibary EC. Integrin-mediated interactions between primary/T-sv40 immortalized human glomerular epithelial cells and type IV collagen. *Lab Invest* 1996; **74**: 650-657 [PMID: 8600316]
  - 134 **Spiro RG**. Biochemistry of the renal glomerular basement membrane and its alterations in diabetes mellitus. *N Engl J Med* 1973; **288**: 1337-1342 [PMID: 4574722 DOI: 10.1056/nejm197306212882506]
  - 135 **Goldstein JL**, Fialkow PJ. The Alström syndrome. Report of three cases with further delineation of the clinical, pathophysiological, and genetic aspects of the disorder. *Medicine (Baltimore)* 1973; **52**: 53-71 [PMID: 4689172 DOI: 10.1097/00005792-197301000-00003]
  - 136 **Marshall JD**, Bronson RT, Collin GB, Nordstrom AD, Maffei P, Paisey RB, Carey C, Macdermott S, Russell-Eggitt I, Shea SE, Davis J, Beck S, Shatirishvili G, Mihai CM, Hoeltzenbein M, Pozzan GB, Hopkinson I, Siculo N, Naggert JK, Nishina PM. New Alström syndrome phenotypes based on the evaluation of 182 cases. *Arch Intern Med* 2005; **165**: 675-683 [PMID: 15795345 DOI: 10.1001/archinte.165.6.675]
  - 137 **Falk RJ**, Scheinman JI, Mauer SM, Michael AF. Polyantigenic expansion of basement membrane constituents in diabetic nephropathy. *Diabetes* 1983; **32** Suppl 2: 34-39 [PMID: 6400667 DOI: 10.2337/diab.32.2.s34]
  - 138 **Tervaert TW**, Mooyaart AL, Amann K, Cohen AH, Cook HT, Drachenberg CB, Ferrario F, Fogo AB, Haas M, de Heer E, Joh K, Noël LH, Radhakrishnan J, Seshan SV, Bajema IM, Bruijn JA; Renal Pathology Society. Pathologic classification of diabetic nephropathy. *J Am Soc Nephrol* 2010; **21**: 556-563 [PMID: 20167701 DOI: 10.1681/ASN.2010010010]
  - 139 **Schleicher E**, Wieland OH. Changes of human glomerular basement membrane in diabetes mellitus. *J Clin Chem Clin Biochem* 1984; **22**: 223-227 [PMID: 6726120 DOI: 10.1515/cclm.1984.22.3.223]
  - 140 **Berenson GS**, Ruiz H, Dalferes ER Jr, Dugan FA, Radhakrishnamurthy B. Acid mucopolysaccharide changes in diabetic kidneys. *Diabetes* 1970; **19**: 161-170 [PMID: 4245198 DOI: 10.2337/diab.19.3.161]
  - 141 **Zhao L**, Zhang Y, Liu F, Yang H, Zhong Y, Wang Y, Li S, Su Q, Tang L, Bai L, Ren H, Zou Y, Wang S, Zheng S, Xu H, Li L, Zhang J, Chai Z, Cooper ME, Tong N. Urinary complement proteins and risk of end-stage renal disease: quantitative urinary proteomics in patients with type 2 diabetes and biopsy-proven diabetic nephropathy. *J Endocrinol Invest* 2021; **44**: 2709-2723 [PMID: 34043214 DOI: 10.1007/s40618-021-01596-3]
  - 142 **Bonomo JA**, Palmer ND, Hicks PJ, Lea JP, Okusa MD, Langefeld CD, Bowden DW, Freedman BI. Complement factor H gene associations with end-stage kidney disease in African Americans. *Nephrol Dial Transplant* 2014; **29**: 1409-1414 [PMID: 24586071 DOI: 10.1093/ndt/gfu036]
  - 143 **Valoti E**, Noris M, Perna A, Rurali E, Gherardi G, Breno M, Parvanova Ilieva A, Petrov Iliev I, Bossi A, Trevisan R, Dodesini AR, Ferrari S, Stucchi N, Benigni A, Remuzzi G, Ruggenenti P. Impact of a Complement Factor H Gene Variant on Renal Dysfunction, Cardiovascular Events, and Response to ACE Inhibitor Therapy in Type 2 Diabetes. *Front Genet* 2019; **10**: 681 [PMID: 31428128 DOI: 10.3389/fgene.2019.00681]
  - 144 **Westberg NG**, Michael AF. Human glomerular basement membrane: chemical composition in diabetes mellitus. *Acta Med Scand* 1973; **1-2**: 39-47 [PMID: 4727247 DOI: 10.1111/j.0954-6820.1973.tb19411.x]
  - 145 **Rasmussen LM**, Heickendorff L. Accumulation of fibronectin in aortas from diabetic patients. A quantitative immunohistochemical and biochemical study. *Lab Invest* 1989; **61**: 440-446 [PMID: 2796291]
  - 146 **Kimmelstiel P**, Kim OJ, Beres J. Studies on renal biopsy specimens, with the aid of the electron microscope. I. Glomeruli in diabetes. *Am J Clin Pathol* 1962; **38**: 270-279 [PMID: 14456010 DOI: 10.1093/ajcp/38.3.270]
  - 147 **Mise K**, Ueno T, Hoshino J, Hazue R, Sumida K, Yamanouchi M, Hayami N, Suwabe T, Hiramatsu R, Hasegawa E, Sawa N, Fujii T, Hara S, Wada J, Makino H, Takaichi K, Ohashi K, Ubara Y. Nodular lesions in diabetic nephropathy: Collagen staining and renal prognosis. *Diabetes Res Clin Pract* 2017; **127**: 187-197 [PMID: 28388509 DOI: 10.1016/j.diabres.2017.03.006]
  - 148 **Alsaad KO**, Edrees B, Rahim KA, Alanazi A, Ahmad M, Aloudah N. Collagenofibrotic (Collagen Type III)

- glomerulopathy in association with diabetic nephropathy. *Saudi J Kidney Dis Transpl* 2017; **28**: 898-905 [PMID: 28748894]
- 149 **Guan M**, Ma J, Keaton JM, Dimitrov L, Mudgal P, Stromberg M, Bonomo JA, Hicks PJ, Freedman BI, Bowden DW, Ng MC. Association of kidney structure-related gene variants with type 2 diabetes-attributed end-stage kidney disease in African Americans. *Hum Genet* 2016; **135**: 1251-1262 [PMID: 27461219 DOI: 10.1007/s00439-016-1714-2]
  - 150 **Salem RM**, Todd JN, Sandholm N, Cole JB, Chen WM, Andrews D, Pezzolesi MG, McKeigue PM, Hiraki LT, Qiu C, Nair V, Di Liao C, Cao JJ, Valo E, Onengut-Gumuscu S, Smiles AM, McGurnaghan SJ, Haukka JK, Harjutsalo V, Brennan EP, van Zuydam N, Ahlqvist E, Doyle R, Ahluwalia TS, Lajer M, Hughes MF, Park J, Skupien J, Spiliopoulou A, Liu A, Menon R, Boustany-Kari CM, Kang HM, Nelson RG, Klein R, Klein BE, Lee KE, Gao X, Mauer M, Maestroni S, Caramori ML, de Boer IH, Miller RG, Guo J, Boright AP, Tregouet D, Gyorgy B, Snell-Bergeon JK, Maahs DM, Bull SB, Canty AJ, Palmer CNA, Stechemesser L, Paulweber B, Weitgasser R, Sokolovska J, Rovite V, Pīrāgs V, Prakapiene E, Radzeviciene L, Verkauskienė R, Panduru NM, Groop LC, McCarthy MI, Gu HF, Möllsten A, Falhammar H, Brismar K, Martin F, Rossing P, Costacou T, Zerbini G, Marre M, Hadjadj S, McKnight AJ, Forsblom C, McKay G, Godson C, Maxwell AP, Kretzler M, Susztak K, Colhoun HM, Krolewski A, Paterson AD, Groop PH, Rich SS, Hirschhorn JN, Florez JC; SUMMIT Consortium, DCCT/EDIC Research Group, GENIE Consortium. Genome-Wide Association Study of Diabetic Kidney Disease Highlights Biology Involved in Glomerular Basement Membrane Collagen. *J Am Soc Nephrol* 2019; **30**: 2000-2016 [PMID: 31537649 DOI: 10.1681/ASN.2019030218]
  - 151 **Peeters SA**, Engelen L, Buijs J, Chaturvedi N, Fuller JH, Schalkwijk CG, Stehouwer CD; EURODIAB Prospective Complications Study Group. Plasma levels of matrix metalloproteinase-2, -3, -10, and tissue inhibitor of metalloproteinase-1 are associated with vascular complications in patients with type 1 diabetes: the EURODIAB Prospective Complications Study. *Cardiovasc Diabetol* 2015; **14**: 31 [PMID: 25848912 DOI: 10.1186/s12933-015-0195-2]
  - 152 **Peeters SA**, Engelen L, Buijs J, Jorsal A, Parving HH, Tarnow L, Rossing P, Schalkwijk CG, Stehouwer CDA. Plasma matrix metalloproteinases are associated with incident cardiovascular disease and all-cause mortality in patients with type 1 diabetes: a 12-year follow-up study. *Cardiovasc Diabetol* 2017; **16**: 55 [PMID: 28446168 DOI: 10.1186/s12933-017-0539-1]
  - 153 **Peeters SA**, Engelen L, Buijs J, Chaturvedi N, Fuller JH, Jorsal A, Parving HH, Tarnow L, Theilade S, Rossing P, Schalkwijk CG, Stehouwer CDA. Circulating matrix metalloproteinases are associated with arterial stiffness in patients with type 1 diabetes: pooled analysis of three cohort studies. *Cardiovasc Diabetol* 2017; **16**: 139 [PMID: 29070037 DOI: 10.1186/s12933-017-0620-9]
  - 154 **Vilmi-Kerälä T**, Lauhio A, Tervahartiala T, Palomäki O, Uotila J, Sorsa T, Palomäki A. Subclinical inflammation associated with prolonged TIMP-1 upregulation and arterial stiffness after gestational diabetes mellitus: a hospital-based cohort study. *Cardiovasc Diabetol* 2017; **16**: 49 [PMID: 28407807 DOI: 10.1186/s12933-017-0530-x]
  - 155 **Afkarian M**, Zelnick LR, Ruzinski J, Kestenbaum B, Himmelfarb J, de Boer IH, Mehrotra R. Urine matrix metalloproteinase-7 and risk of kidney disease progression and mortality in type 2 diabetes. *J Diabetes Complications* 2015; **29**: 1024-1031 [PMID: 26412030 DOI: 10.1016/j.jdiacomp.2015.08.024]
  - 156 **Paunas FTI**, Finne K, Leh S, Osman TA, Marti HP, Berven F, Vikse BE. Characterization of glomerular extracellular matrix in IgA nephropathy by proteomic analysis of laser-captured microdissected glomeruli. *BMC Nephrol* 2019; **20**: 410 [PMID: 31726998 DOI: 10.1186/s12882-019-1598-1]
  - 157 **Ibrahim S**, Rashed L. Estimation of transforming growth factor-beta 1 as a marker of renal injury in type II diabetes mellitus. *Saudi Med J* 2007; **28**: 519-523 [PMID: 17457470]
  - 158 **Shaker OG**, Sadik NA. Transforming growth factor beta 1 and monocyte chemoattractant protein-1 as prognostic markers of diabetic nephropathy. *Hum Exp Toxicol* 2013; **32**: 1089-1096 [PMID: 23515495 DOI: 10.1177/0960327112470274]
  - 159 **Mou X**, Zhou DY, Ma JR, Liu YH, Chen HP, Hu YB, Shou CM, Chen JW, Liu WH, Ma GL. Serum TGF-β1 as a Biomarker for Type 2 Diabetic Nephropathy: A Meta-Analysis of Randomized Controlled Trials. *PLoS One* 2016; **11**: e0149513 [PMID: 26901047 DOI: 10.1371/journal.pone.0149513]
  - 160 **Qiao YC**, Chen YL, Pan YH, Ling W, Tian F, Zhang XX, Zhao HL. Changes of transforming growth factor beta 1 in patients with type 2 diabetes and diabetic nephropathy: A PRISMA-compliant systematic review and meta-analysis. *Medicine (Baltimore)* 2017; **96**: e6583 [PMID: 28403088 DOI: 10.1097/MD.0000000000006583]
  - 161 **Zhou T**, Li HY, Zhong H, Zhong Z. Relationship between transforming growth factor-β1 and type 2 diabetic nephropathy risk in Chinese population. *BMC Med Genet* 2018; **19**: 201 [PMID: 30458730 DOI: 10.1186/s12881-018-0717-3]
  - 162 **Voelker J**, Berg PH, Sheetz M, Duffin K, Shen T, Moser B, Greene T, Blumenthal SS, Rychlik I, Yagil Y, Zaoui P, Lewis JB. Anti-TGF-β1 Antibody Therapy in Patients with Diabetic Nephropathy. *J Am Soc Nephrol* 2017; **28**: 953-962 [PMID: 27647855 DOI: 10.1681/ASN.2015111230]
  - 163 **Uehara G**, Suzuki D, Toyoda M, Umezono T, Sakai H. Glomerular expression of platelet-derived growth factor (PDGF)-A, -B chain and PDGF receptor-α, -β in human diabetic nephropathy. *Clin Exp Nephrol* 2004; **8**: 36-42 [PMID: 15067514 DOI: 10.1007/s10157-003-0265-8]
  - 164 **Baelde HJ**, Eikmans M, Lappin DW, Doran PP, Hohenadel D, Brinkkoetter PT, van der Woude FJ, Waldherr R, Rabelink TJ, de Heer E, Bruijn JA. Reduction of VEGF-A and CTGF expression in diabetic nephropathy is associated with podocyte loss. *Kidney Int* 2007; **71**: 637-645 [PMID: 17264876 DOI: 10.1038/sj.ki.5002101]
  - 165 **Woroniecka KI**, Park AS, Mohtat D, Thomas DB, Pullman JM, Susztak K. Transcriptome analysis of human diabetic kidney disease. *Diabetes* 2011; **60**: 2354-2369 [PMID: 21752957 DOI: 10.2337/db10-1181]
  - 166 **Hovind P**, Tarnow L, Oestergaard PB, Parving HH. Elevated vascular endothelial growth factor in type 1 diabetic patients with diabetic nephropathy. *Kidney Int Suppl* 2000; **75**: S56-S61 [PMID: 10828763]
  - 167 **Zhao Y**, Banerjee S, LeJeune WS, Choudhary S, Tilton RG. NF-κB-inducing kinase increases renal tubule epithelial inflammation associated with diabetes. *Exp Diabetes Res* 2011; **2011**: 192564 [PMID: 21869881 DOI: 10.1155/2011/192564]
  - 168 **Bae EH**, Cho S, Joo SY, Ma SK, Kim SH, Lee J, Kim SW. 4-Hydroxy-2-hexenal-induced apoptosis in human renal proximal tubular epithelial cells. *Nephrol Dial Transplant* 2011; **26**: 3866-3873 [PMID: 21771752 DOI: 10.1093/ndt/gfr386]



- 10.1093/ndt/gfr386]
- 169 **Tanji N**, Markowitz GS, Fu C, Kislinger T, Taguchi A, Pischetsrieder M, Stern D, Schmidt AM, D'Agati VD. Expression of advanced glycation end products and their cellular receptor RAGE in diabetic nephropathy and nondiabetic renal disease. *J Am Soc Nephrol* 2000; **11**: 1656-1666 [PMID: [10966490](#) DOI: [10.1681/ASN.V1191656](#)]
- 170 **Suzuki D**, Toyoda M, Yamamoto N, Miyauchi M, Katoh M, Kimura M, Maruyama M, Honma M, Umezono T, Yagame M. Relationship between the expression of advanced glycation end-products (AGE) and the receptor for AGE (RAGE) mRNA in diabetic nephropathy. *Intern Med* 2006; **45**: 435-441 [PMID: [16679697](#) DOI: [10.2169/internalmedicine.45.1557](#)]
- 171 **Peeters SA**, Engelen L, Buijs J, Theilade S, Rossing P, Schalkwijk CG, Stehouwer CDA. Associations between advanced glycation endproducts and matrix metalloproteinases and its inhibitor in individuals with type 1 diabetes. *J Diabetes Complications* 2018; **32**: 325-329 [PMID: [29395841](#) DOI: [10.1016/j.jdiacomp.2017.12.011](#)]



Published by **Baishideng Publishing Group Inc**  
7041 Koll Center Parkway, Suite 160, Pleasanton, CA 94566, USA

**Telephone:** +1-925-3991568

**E-mail:** [bpgoffice@wjgnet.com](mailto:bpgoffice@wjgnet.com)

**Help Desk:** <https://www.f6publishing.com/helpdesk>

<https://www.wjgnet.com>

