



Efficacy and safety of local candida immunotherapy in recalcitrant warts in pediatric kidney transplantation: A case report

Ratna Acharya, Rachel Bush, Felicia Johns, Kiran Upadhyay

Specialty type: Transplantation

Provenance and peer review:

Unsolicited article; Externally peer reviewed.

Peer-review model: Single blind

Peer-review report's scientific quality classification

Grade A (Excellent): 0
Grade B (Very good): B, B
Grade C (Good): 0
Grade D (Fair): 0
Grade E (Poor): 0

P-Reviewer: Bellini MI, Italy; Sarier M, Turkey

Received: February 25, 2023

Peer-review started: February 25, 2023

First decision: March 15, 2023

Revised: March 21, 2023

Accepted: April 4, 2023

Article in press: April 4, 2023

Published online: June 18, 2023



Ratna Acharya, Department of Pediatrics, University of Florida, Gainesville, FL 32610, United States

Rachel Bush, Felicia Johns, Kiran Upadhyay, Department of Pediatric Nephrology, University of Florida, Gainesville, FL 32610, United States

Corresponding author: Kiran Upadhyay, MD, Associate Professor, Doctor, Department of Pediatric Nephrology, University of Florida, 1600 SW Archer Road, Gainesville, FL 32610, United States. kupadhyay@ufl.edu

Abstract

BACKGROUND

Warts are common in recipients of kidney transplantation (KT). Resistant warts which are not amenable to conventional therapies may lead to significant morbidity. Limited data exists on safety and efficacy of local immunotherapy among immunocompromised KT recipients.

CASE SUMMARY

We report a seven-year-old child who presented with recalcitrant plantar periungual warts in the early KT period. Immunosuppression consisted of tacrolimus, mycophenolate and steroid. Due to failure of conventional anti-wart therapies, he was treated with two sessions of intralesional (IL) candida immunotherapy along with liquid nitrogen cryotherapy leading to complete resolution of the warts. Interestingly, de novo BK viremia was seen about three weeks following the last candida immunotherapy. This required reduction of immunosuppression and other anti-BK viral therapies. Allograft function remained stable but there were donor specific antibodies detected. There also was elevated level of plasma donor derived cell-free DNA. A *pneumocystis jirovecii* pneumonia occurred ten months following completion of immunotherapy that was successfully treated with trimethoprim-sulfamethoxazole. During this ten-month follow-up period, there have been no recurrence of warts, and transplant kidney function has remained stable.

CONCLUSION

Stimulation of cell-mediated immunity against the human papilloma virus induced by the IL candida immunotherapy is thought to be a cause for wart resolution. With this therapy, whether it is necessary to augment the immunosuppression to prevent rejection is unclear as that may come with a risk of infectious complications. Larger, prospective studies in pediatric KT recipients are needed to

explore these important issues.

Key Words: Warts; Kidney transplantation; Candida; Immunotherapy; Pediatric; Case report

©The Author(s) 2023. Published by Baishideng Publishing Group Inc. All rights reserved.

Core Tip: Warts are common after pediatric kidney transplantation. Given immunosuppressed status, most children are unable to clear the warts with conventional anti-wart therapies. Local immunotherapy has emerged as an excellent treatment modality for treatment of resistant warts following kidney transplantation. However, the safety of such agents needs careful consideration with longitudinal studies. Here, we studied the efficacy and safety of local candida immunotherapy in an immunocompromised child with kidney transplantation and recalcitrant plantar warts.

Citation: Acharya R, Bush R, Johns F, Upadhyay K. Efficacy and safety of local candida immunotherapy in recalcitrant warts in pediatric kidney transplantation: A case report. *World J Transplant* 2023; 13(4): 201-207

URL: <https://www.wjgnet.com/2220-3230/full/v13/i4/201.htm>

DOI: <https://dx.doi.org/10.5500/wjt.v13.i4.201>

INTRODUCTION

Cutaneous common warts (verruca vulgaris) are commonly seen after kidney transplantation (KT)[1-3]. In one study of 60 children and adolescents with KT, the incidence of warts was 28% with increased prevalence with time since KT. Plantar warts are the most common warts following KT[4]. The most common immunosuppressive regimen in these patients was tacrolimus and prednisone, in combination with either azathioprine or mycophenolate mofetil (MMF). The most commonly seen human papillomavirus (HPV) strains responsible for common warts are HPV-2, 27, 29, 34 and 57[5]. Painful warts can impair the quality of life and cause significant morbidity[6]. Unlike in non-immunocompromised individuals, warts in KT recipients may not undergo spontaneous resolution. Although the risk of cancerous conversion is primarily seen with genital warts, multiple verrucae (> 10 verrucae) may be associated with the development of actinic keratoses, invasive squamous cell carcinoma and basal cell carcinoma[7]. Some of the treatment options are topical keratolytics such as salicylate, cryotherapy with liquid nitrogen, electrofulguration or radiofrequency ablation, duct tape, pulsed dye or CO₂ laser, intralesional (IL) bleomycin, surgical removal with curettage or cautery, and IL immunotherapy[8]. Here we describe a seven-year-old KT recipient with recalcitrant plantar warts who had an excellent response to the IL candida immunotherapy with no recurrence in the short-term follow-up of ten months.

CASE PRESENTATION

Chief complaints

A seven-year-old Caucasian male presented with multiple wart-like lesions in the plantar aspect of both foot after KT.

History of present illness

The patient had received a pre-emptive first living unrelated donor KT with bilateral native nephrectomies one month prior to the onset of the skin warts. He sustained early loss of renal allograft secondary to transplant renal artery thrombosis. Transplant kidney biopsy showed coagulative necrosis and he was transitioned to chronic hemodialysis until receiving a second deceased donor KT two months later with excellent allograft function. Induction immunosuppression (IS) for both first and second KT consisted of three doses of 1.5 mg/kg/dose Thymoglobulin[®] with steroid. Low dose tacrolimus and MMF were continued after the first failed KT. The first allograft was removed during the second KT. Maintenance IS for second KT consisted of tacrolimus, MMF and steroid. Serum trough tacrolimus level was maintained at the goal range.

History of past illness

The past medical history consisted of end stage renal disease secondary to posterior urethral valve. He however did not require dialysis given stable electrolytes and normal urine output. He had been immunized fully as per the routine childhood immunization schedule.

Personal and family history

The patient's personal and family history was otherwise unremarkable.

Physical examination

Physical examination of the patient showed normal vital signs and examination except for the abdomen with scar marks from prior surgeries and positive skin findings. Skin examination showed multiple verrucous papules and plaques on the anterior aspect of the plantar surface of foot bilaterally (Figures 1A and B), and some papular lesions in the left thumb. There were no warts seen in the genital region or the oropharynx region. The warts were extremely painful and would wake him throughout the night. The patient had difficulty ambulating and had to be carried to the clinic visits.

Laboratory examinations

Complete blood count was normal. Renal allograft function remained stable after second KT with serum creatinine of 0.5-0.6 mg/dL. C-reactive protein was normal. Serum trough tacrolimus level was at the goal of 9-11 ng/mL in the first month post KT, then 8-10 ng/mL in the second month, followed by 6-8 ng/mL from three to six months post KT. Urinalysis showed no proteinuria, hematuria or urinary tract infections. Given cytomegalovirus (CMV) mismatch, he received oral valganciclovir for six months post-KT. CMV, Epstein-Barr virus and BK virus polymerase chain reaction (PCR)s were all negative until six months post KT. HPV genotyping of the warts was not done.

Imaging examinations

Chest X-ray was negative for pneumonia or other viral processes. Renal allograft sonogram was normal.

FINAL DIAGNOSIS

Plantar warts in a child with kidney transplantation.

TREATMENT

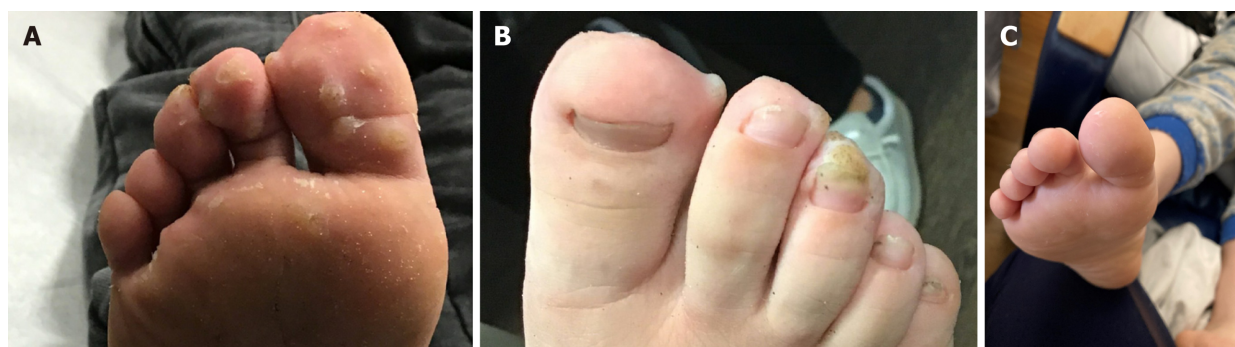
He was evaluated by dermatologist and was treated with lidocaine ointment, WartPEEL (17% salicylic acid and 2% 5-fluorouracil), WartSTICK (40% salicylic acid), and Differin (0.3% Adapalene gel) under occlusion for several weeks without any clinical improvement of the signs and symptoms. Six months after the first KT, he was treated with a first dose of Candin[®] (IL *Candida albicans* antigen) to the largest wart paired with liquid nitrogen cryotherapy. Second dose of IL Candin[®] and liquid nitrogen was administered four weeks later.

OUTCOME AND FOLLOW-UP

The patient had a significant improvement with almost complete resolution of the warts after two Candin[®] paired with liquid nitrogen cryotherapy. Complete resolution was indicated by complete disappearance of the hyperkeratosis and thickening of the skin. Due to the presence of few scattered lesions only, a third dose of liquid nitrogen cryotherapy was administered two months later without IL Candin[®]. There were no side effects observed such as blister, infection, post-inflammatory altered pigmentation, scarring or anaphylaxis. During a ten-month follow-up period since the second and last Candin[®] therapy, there have been no recurrences of the warts (Figure 1C).

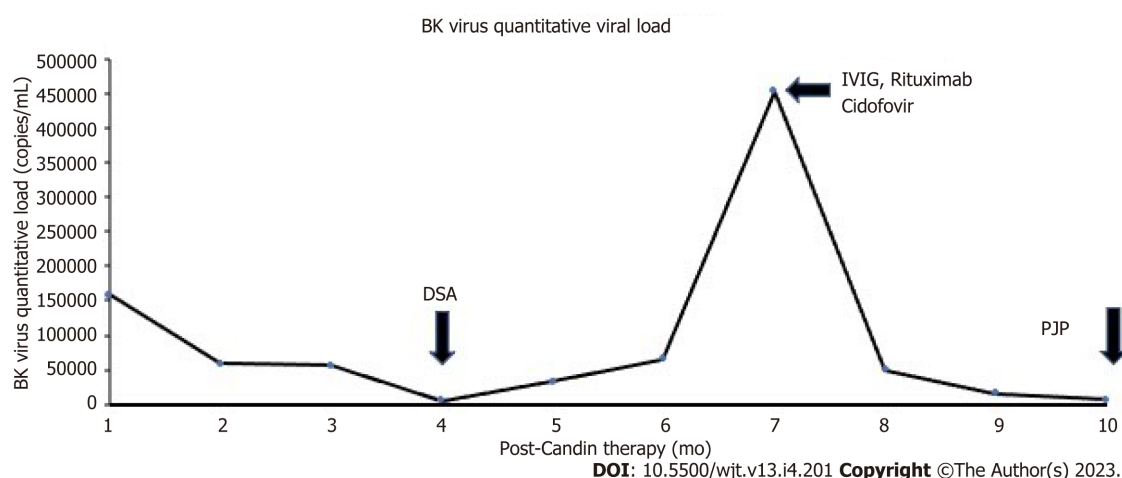
Three weeks after the first Candin[®] injection, a follow-up whole blood BK virus deoxyribonuclease (DNA) PCR showed BK viral load of 159000 copies/mL (ARUP laboratories, Salt Lake City, UT, United States). His immunosuppression regimen had been same as before and his allograft function was stable. Following this, his tacrolimus dose was reduced with a lower trough goal level of 3-5 ng/mL, mycophenolate was discontinued and leflunomide was started. Over the next one year, his BK virus DNA PCR showed persistent positivity with a peak viral load of 453000 copies/mL seven months post last Candin[®] therapy. He then received two monthly intravenous (IV) immunoglobulin therapies and a course of IV cidofovir with the most recent BK virus load of 6280 copies/mL ten months after the last Candin[®] therapy (Figure 2). The most recent immunosuppression regimen consists of tacrolimus 2 mg twice daily, prednisone 10 mg daily and leflunomide 20 mg daily.

Donor specific antibodies (DSA) were obtained monthly as a part of the transplant center's protocol. Four months after the last Candin[®] injection, weak DSA to class I antigens [B58, C12; 2500 mean fluorescent intensity (MFI) for both] were observed. Subsequently, strong DSAs against class II antigen (DQ6, 10000 MFI) also started appearing a month later. However, the serum creatinine remained stable around 0.6-0.7 mg/dL. He was treated with intravenous immunoglobulin and a dose of Rituximab 375



DOI: 10.5500/wjt.v13.i4.201 Copyright ©The Author(s) 2023.

Figure 1 Response to Candin[®] treatment. A: Plantar warts before Candin[®] treatment; B: Periungual plantar warts before Candin[®] treatment; C: Resolution of plantar warts after Candin[®] treatment.



DOI: 10.5500/wjt.v13.i4.201 Copyright ©The Author(s) 2023.

Figure 2 Association of Candin[®] treatment with BK viremia, donor specific antibodies and *pneumocystic carinii* pneumonia. DSA: Donor specific antibodies; IVIG: Intravenous immunoglobulin; PJP: *Pneumocystic carinii* pneumonia.

mg/m². A kidney transplant biopsy could not be obtained due to parental hesitation. However, a plasma donor-derived cell-free DNA (dd-cfDNA) test showed elevated value of 1.21% (reference range: < 0.7% dd-cfDNA, Viracor TRAC kidney dd-cfDNA, Eurofins Transplant Genomics, Framingham, MA, United States). A decision was made to serially follow the dd-cfDNA and DSA closely given stable serum creatinine.

Ten months after the last Candin[®] therapy, he presented with hypoxia and respiratory distress with chest X-ray showing ground-glass opacities in the lungs. He underwent bronchoscopy; the PCR of the bronchoalveolar lavage was positive for *pneumocystis jirovecii* and diagnosed with *pneumocystis jirovecii* pneumonia (PJP). He was treated with trimethoprim-sulfamethoxazole with complete resolution of respiratory symptoms. Immunosuppression was kept the same with a goal trough tacrolimus level of 3-5 ng/mL.

DISCUSSION

In patients with cutaneous warts with suboptimal or no response to conventional anti-wart therapies, IL immunotherapy may be useful[9,10]. Various IL immunotherapy regimen have been described such as candida antigen, mumps antigen, measles mumps rubella vaccine, purified protein derivative and bacilli calmette-guerin vaccine[10]. One systematic review showed 68% cure-rate of local immunotherapy in plantar warts, as opposed to low cure rate with topical salicylic acid and cryotherapy[11]. A randomized placebo-controlled trial by Horn *et al*[12] showed excellent efficacy of IL candida, mumps or trichophyton skin test antigens. The possible mechanism of action of immunotherapy is the proliferation of HPV-specific peripheral blood mononuclear cells that possibly mediate an immunologic attack against the wart tissue[13].

Data on efficacy of IL candida in children is scarce[14]. Alikhan *et al*[15] reported a retrospective study of 100 adults and children with verruca vulgaris who were treated with IL purified candida antigen therapy with 39% complete response and 41% partial response rate. In their study, six out of seven patients who were immunocompromised demonstrated partial or complete response rate. The proposed mechanism is *via* stimulation of a cell-mediated immune response. Phillips *et al*[13] retrospectively reviewed adults and children who received monthly IL candida antigen with 72% complete resolution rate. Another retrospective study of 220 children with multiple and recalcitrant warts who received IL candida injections showed 71% and 17% complete and partial response rates respectively. There were no side effects reported except for some discomfort at the time of injection[16]. IL *Candida* immunotherapy has also been shown to be efficacious in treating the distant non-injected warts[17]. Whether the similar results are expected in immunocompromised individuals needs to be studied on a larger scale.

With regards to immunosuppressed patients, the prevalence of warts corresponds with the duration of immunosuppressive therapy, increasing to 50%-92% in patients who are more than 4-5 years after transplantation[3]. Our report is unique in that the onset of warts was fairly rapid following KT. In most HPV infections in immunocompetent individuals, the cellular and cytotoxic immunity provided by T cells and natural killer cells are sufficient to control the warts[18]; however, in immunocompromised patients, due to lack of cell-mediated immunity, the proliferation of virus occurs causing warts, sometimes in unusual locations such as bladder[19,20]. Indeed, a few studies have reported clearance of the warts with reduction or cessation of immunosuppression only in KT recipients[21,22]. Conversion to another anti-rejection agent may be useful as well. Nguyen *et al*[23] reported 4 children with warts and molluscum contagiosum who benefited from conversion from tacrolimus/mycophenolate to tacrolimus/Leflunomide. Conversion to sirolimus has been shown to be effective for recalcitrant cutaneous viral warts in liver transplant recipients[24,25]. There is not much data on the efficacy of the IL immunotherapy. In patients who do undergo local immunotherapy, it is not known whether immunosuppression decreases the efficacy of local immunotherapy such as IL candida. Immunosuppression usually is at the maximal level during the first few months of KT and it will be interesting to study the efficacy of these immunotherapies during this period of maximal immunosuppression. On the other hand, there are also potential safety concerns with stimulating cell-mediated immunity with IL *Candida* therapy leading to rejection[26]. Few studies done in the children on warts have not looked at these longitudinal issues[4]. In our patient, there was a temporal relationship between the onset of BK viremia and Candin[®] therapy along with observation of DSA, elevated dd-cfDNA, and PJP a few months following the completion of Candin[®]. However, we could not establish a direct cause and relationship between IL candida and these findings. Since dd-cfDNA has been shown to diagnose subclinical rejection even in the absence of deranged renal function, this test may be important in children who have underwent IL candida therapy for establishing an early diagnosis of rejection and possibly close monitoring and treatment[27]. In those with concurrent viral infections and elevated dd-cfDNA, it is challenging to decide the amount of immunosuppression, as in our case. Also, since children with current BK viremia have been shown to have significantly higher median plasma dd-cfDNA, the importance of elevated dd-cfDNA in this subset of children is uncertain[28]. Also, as seen in this report, there may be an association between BK virus and HPV as both belong to the human papovavirus family. These are important topics of discussion that will need to be studied in further larger studies.

CONCLUSION

A decision of whether to treat with immunotherapy such as IL candida in immunocompromised transplant recipients is challenging due to concerns with efficacy and the possibility of rejection, and perhaps infections. Well-designed prospective studies are needed in the future to determine the efficacy and safety of this potentially curative treatment for the recalcitrant warts.

FOOTNOTES

Author contributions: All authors contributed to the study conception and design, writing; Acharya R, Bush R, and Johns F were involved in the acquisition of the clinical data, analysis, and interpretation; Upadhyay K was involved in the critical revision.

Informed consent statement: Informed consent was obtained from the parent of the patient for publication of the information.

Conflict-of-interest statement: All the authors report no relevant conflicts of interest for this article.

CARE Checklist (2016) statement: The authors have read the CARE checklist, and the manuscript was prepared and

revised according to the CARE checklist.

Open-Access: This article is an open-access article that was selected by an in-house editor and fully peer-reviewed by external reviewers. It is distributed in accordance with the Creative Commons Attribution NonCommercial (CC BY-NC 4.0) license, which permits others to distribute, remix, adapt, build upon this work non-commercially, and license their derivative works on different terms, provided the original work is properly cited and the use is non-commercial. See: <https://creativecommons.org/licenses/by-nc/4.0/>

Country/Territory of origin: United States

ORCID number: Ratna Acharya 0000-0001-5260-0057; Kiran Upadhyay 0000-0002-8441-0220.

S-Editor: Liu JH

L-Editor: A

P-Editor: Zhang YL

REFERENCES

- Oliveira WRP, Tirico MCCP, Souza AAV, Codarin FR, Silva LLC, Festa Neto C. Skin lesions in organ transplant recipients: a study of 177 consecutive Brazilian patients. *Int J Dermatol* 2019; **58**: 440-448 [PMID: 30565651 DOI: 10.1111/jid.14285]
- Oh CC, Lee HY, Tan BK, Assam PN, Kee TYS, Pang SM. Dermatological conditions seen in renal transplant recipients in a Singapore tertiary hospital. *Singapore Med J* 2018; **59**: 519-523 [PMID: 30386860 DOI: 10.11622/smedj.2018126]
- Dyall-Smith D, Trowell H, Dyall-Smith ML. Benign human papillomavirus infection in renal transplant recipients. *Int J Dermatol* 1991; **30**: 785-789 [PMID: 1661712 DOI: 10.1111/j.1365-4362.1991.tb04787.x]
- Lunn A, Ravenscroft J, Watson AR. Cutaneous warts in children before and after renal transplantation. *Pediatr Nephrol* 2010; **25**: 941-946 [PMID: 20024587 DOI: 10.1007/s00467-009-1390-8]
- Martelli-Marzagão F, Yamashiro AS, Ogawa MM, Santos GF Jr, Tomimori J, Porro AM. Clinical and histopathological characterization and typing of the human papillomavirus in common warts of kidney transplant recipients. *An Bras Dermatol* 2010; **85**: 743-746 [PMID: 21152808 DOI: 10.1590/s0365-05962010000500027]
- Moloney FJ, Keane S, O'Kelly P, Conlon PJ, Murphy GM. The impact of skin disease following renal transplantation on quality of life. *Br J Dermatol* 2005; **153**: 574-578 [PMID: 16120145 DOI: 10.1111/j.1365-2133.2005.06699.x]
- Cho CY, Lo YC, Hung MC, Lai CC, Chen CJ, Wu KG. Risk of cancer in patients with genital warts: A nationwide, population-based cohort study in Taiwan. *PLoS One* 2017; **12**: e0183183 [PMID: 28806741 DOI: 10.1371/journal.pone.0183183]
- Gibbs S, Harvey I. Topical treatments for cutaneous warts. *Cochrane Database Syst Rev* 2006; CD001781 [PMID: 16855978 DOI: 10.1002/14651858.CD001781.pub2]
- Bhalala KB, Poojary S, Shah KS. Comparative Study of Efficacy of Intralesional Purified Protein Derivative (PPD) Versus Intralesional Measles, Mumps, and Rubella (MMR) Vaccine in Management of Multiple Viral Warts. *J Cutan Aesthet Surg* 2021; **14**: 397-403 [PMID: 35283602 DOI: 10.4103/JCAS.JCAS_166_19]
- Fields JR, Saikaly SK, Schoch JJ. Intralesional immunotherapy for pediatric warts: A review. *Pediatr Dermatol* 2020; **37**: 265-271 [PMID: 31930595 DOI: 10.1111/pde.14094]
- García-Oreja S, Álvaro-Afonso FJ, García-Álvarez Y, García-Morales E, Sanz-Corbalán I, Lázaro Martínez JL. Topical treatment for plantar warts: A systematic review. *Dermatol Ther* 2021; **34**: e14621 [PMID: 33263934 DOI: 10.1111/dth.14621]
- Horn TD, Johnson SM, Helm RM, Roberson PK. Intralesional immunotherapy of warts with mumps, Candida, and Trichophyton skin test antigens: a single-blinded, randomized, and controlled trial. *Arch Dermatol* 2005; **141**: 589-594 [PMID: 15897380 DOI: 10.1001/archderm.141.5.589]
- Phillips RC, Ruhl TS, Pfenninger JL, Garber MR. Treatment of warts with Candida antigen injection. *Arch Dermatol* 2000; **136**: 1274-1275 [PMID: 11030787 DOI: 10.1001/archderm.136.10.1274-a]
- Majid I, Imran S. Immunotherapy with intralesional Candida albicans antigen in resistant or recurrent warts: a study. *Indian J Dermatol* 2013; **58**: 360-365 [PMID: 24082180 DOI: 10.4103/0019-5154.117301]
- Alikhan A, Griffin JR, Newman CC. Use of Candida antigen injections for the treatment of verruca vulgaris: A two-year mayo clinic experience. *J Dermatolog Treat* 2016; **27**: 355-358 [PMID: 26558635 DOI: 10.3109/09546634.2015.1106436]
- Muñoz Garza FZ, Roé Crespo E, Torres Pradilla M, Aguilera Peiró P, Baltà Cruz S, Hernández Ruiz ME, Baselga Torres E. Intralesional Candida Antigen Immunotherapy for the Treatment of Recalcitrant and Multiple Warts in Children. *Pediatr Dermatol* 2015; **32**: 797-801 [PMID: 26584692 DOI: 10.1111/pde.12667]
- Maronn M, Salm C, Lyon V, Galbraith S. One-year experience with candida antigen immunotherapy for warts and molluscum. *Pediatr Dermatol* 2008; **25**: 189-192 [PMID: 18429776 DOI: 10.1111/j.1525-1470.2008.00630.x]
- McBride AA. Human papillomaviruses: diversity, infection and host interactions. *Nat Rev Microbiol* 2022; **20**: 95-108 [PMID: 34522050 DOI: 10.1038/s41579-021-00617-5]
- Leiding JW, Holland SM. Warts and all: human papillomavirus in primary immunodeficiencies. *J Allergy Clin Immunol* 2012; **130**: 1030-1048 [PMID: 23036745 DOI: 10.1016/j.jaci.2012.07.049]
- Sarier M, Ozel E, Duman I, Yuksel Y, Demirbas A. HPV type 45-positive condyloma acuminata of the bladder in a renal

- transplant recipient. *Transpl Infect Dis* 2017; **19** [PMID: 28100036 DOI: 10.1111/tid.12667]
- 21 **Maor D**, Brennand S, Goh MSY, Chong AH. Recalcitrant hyperkeratotic verrucae in a renal transplant recipient clearing with cessation of immunosuppression. *JAAD Case Rep* 2018; **4**: 471-473 [PMID: 29984286 DOI: 10.1016/j.jidcr.2017.09.025]
- 22 **Ash MM**, Jolly PS. A Case Report of the Resolution of Multiple Recalcitrant Verrucae in a Renal Transplant Recipient After a Mycophenolate Mofetil Dose Reduction. *Transplant Proc* 2017; **49**: 213-215 [PMID: 28104140 DOI: 10.1016/j.transproceed.2016.11.030]
- 23 **Nguyen L**, McClellan RB, Chaudhuri A, Alexander SR, Chen SF, Concepcion W, Grimm P. Conversion from tacrolimus/mycophenolic acid to tacrolimus/Leflunomide to treat cutaneous warts in a series of four pediatric renal allograft recipients. *Transplantation* 2012; **94**: 450-455 [PMID: 22960763 DOI: 10.1097/TP.0b013e318264351e]
- 24 **Dharancy S**, Catteau B, Mortier L, Boleslawski E, Declerck N, Canva V, Piette F, Mathurin P, Pruvot FR. Conversion to sirolimus: a useful strategy for recalcitrant cutaneous viral warts in liver transplant recipient. *Liver Transpl* 2006; **12**: 1883-1887 [PMID: 17133572 DOI: 10.1002/Lt.20927]
- 25 **Shahidi S**, Moeinzadeh F, Mohammadi M, Gholamrezaei A. Sirolimus-based immunosuppression for treatment of cutaneous warts in kidney transplant recipients. *Iran J Kidney Dis* 2011; **5**: 351-353 [PMID: 21876315]
- 26 **Kawashima S**, Joachim K, Abdelrahim M, Abudayyeh A, Jhaveri KD, Murakami N. Immune checkpoint inhibitors for solid organ transplant recipients: clinical updates. *Korean J Transplant* 2022; **36**: 82-98 [PMID: 35919193 DOI: 10.4285/kjt.22.0013]
- 27 **Park S**, Guo K, Heilman RL, Poggio ED, Taber DJ, Marsh CL, Kurian SM, Kleiboeker S, Weems J, Holman J, Zhao L, Sinha R, Brietigam S, Rebello C, Abecassis MM, Friedewald JJ. Combining Blood Gene Expression and Cellfree DNA to Diagnose Subclinical Rejection in Kidney Transplant Recipients. *Clin J Am Soc Nephrol* 2021; **16**: 1539-1551 [PMID: 34620649 DOI: 10.2215/CJN.05530421]
- 28 **Dandamudi R**, Gu H, Goss CW, Walther L, Dharnidharka VR. Longitudinal Evaluation of Donor-Derived Cellfree DNA in Pediatric Kidney Transplantation. *Clin J Am Soc Nephrol* 2022; **17**: 1646-1655 [PMID: 36302566 DOI: 10.2215/CJN.03840322]



Published by **Baishideng Publishing Group Inc**
7041 Koll Center Parkway, Suite 160, Pleasanton, CA 94566, USA

Telephone: +1-925-3991568

E-mail: bpgoffice@wjgnet.com

Help Desk: <https://www.f6publishing.com/helpdesk>

<https://www.wjgnet.com>

