

## Gastrointestinal stromal tumor of the ampulla of Vater: A case report

Masayoshi Kobayashi, Nobuto Hirata, So Nakaji, Toshiyasu Shiratori, Hiroyuki Fujii, Eiji Ishii

Masayoshi Kobayashi, Nobuto Hirata, So Nakaji, Toshiyasu Shiratori, Hiroyuki Fujii, Eiji Ishii, Department of Gastroenterology, Kameda Medical Center, Chiba 296-0041, Japan

Author contributions: Kobayashi M designed the study and wrote the manuscript; Hirata N and Nakaji S contributed to the manuscript revision; Shiratori T, Fujii H and Ishii E contributed to the literature review and manuscript editing.

Correspondence to: Masayoshi Kobayashi, MD, Department of Gastroenterology, Kameda Medical Center, 929 Higashi-cho, Kamogawa City, Chiba 296-0041, Japan. k-masayoshi@hotmail.co.jp

Telephone: +81-4-70922211 Fax: +81-4-70991131

Received: December 1, 2013 Revised: February 9, 2014

Accepted: March 4, 2014

Published online: April 28, 2014

### Abstract

Gastrointestinal stromal tumors (GISTs) usually develop in the stomach and small intestine and only rarely occur at the ampulla of Vater, with only 11 cases reported in the literature. We report a case of a GIST of the ampulla of Vater. A 36-year-old, previously healthy man presented with a loss of consciousness lasting a few minutes. A gastroduodenal endoscopy revealed a submucosal tumor with central ulceration at the ampulla of Vater. The enhanced computed tomography scan revealed a smooth-outlined hypervascular solid mass (24 mm × 30 mm) in the second part of the duodenum. Neither lymphadenopathy nor metastasis was observed. Magnetic resonance cholangiopancreatography and endoscopic retrograde cholangiopancreatography showed normal bile and pancreatic ducts. Biopsies were collected from the ulcerative lesion, and the tumor was diagnosed as a GIST. A submucosal tumor with central ulceration may be a characteristic form of GISTs of the ampulla of Vater, and biopsy studies are useful for the diagnosing such tumors. The patient underwent pancreatoduodenectomy, and the operative specimen revealed a 2.2-cm GIST with 1 mitosis per 50 high-power fields. The gold standard for treatment of GISTs

is surgical resection without rupture of a capsule. If technically possible, local resection may be considered. However, when the location of the lesion presents challenges, a pancreatoduodenectomy should be performed for GIST of the ampulla of Vater.

© 2014 Baishideng Publishing Group Co., Limited. All rights reserved.

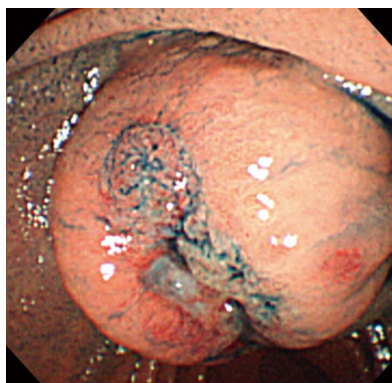**Key words:** Gastrointestinal stromal tumor; Ampulla of Vater; Submucosal tumor; Bleeding; Biopsy; Pancreatoduodenectomy

**Core tip:** Gastrointestinal stromal tumor (GIST) usually develops in the stomach and small intestine, and GIST of the ampulla of Vater is extremely rare, with only 11 cases reported in the literature. We report a case of GIST of the ampulla of Vater in a 36-year-old, previously healthy man who presented with a brief loss of consciousness. A gastroduodenal endoscopy revealed a submucosal tumor with central ulceration at the ampulla of Vater. Biopsies were collected from the ulcerative lesion, and the tumor was diagnosed as a GIST. The patient underwent pancreatoduodenectomy. The operative specimen revealed a 2.2-cm GIST with 1 mitosis per 50 high-power fields.

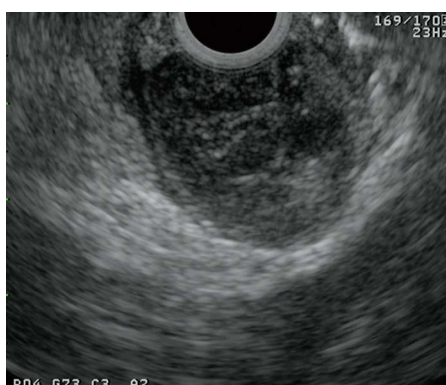Kobayashi M, Hirata N, Nakaji S, Shiratori T, Fujii H, Ishii E. Gastrointestinal stromal tumor of the ampulla of Vater: A case report. *World J Gastroenterol* 2014; 20(16): 4817-4821 Available from: URL: <http://www.wjgnet.com/1007-9327/full/v20/i16/4817.htm> DOI: <http://dx.doi.org/10.3748/wjg.v20.i16.4817>

### INTRODUCTION

The ampulla of Vater can exhibit a variety of neoplasms, such as carcinoma, adenoma, neuroendocrine tumor, gangliocytic paraganglioma and gastrointestinal



**Figure 1** A submucosal tumor with central ulceration at the ampulla of Vater.



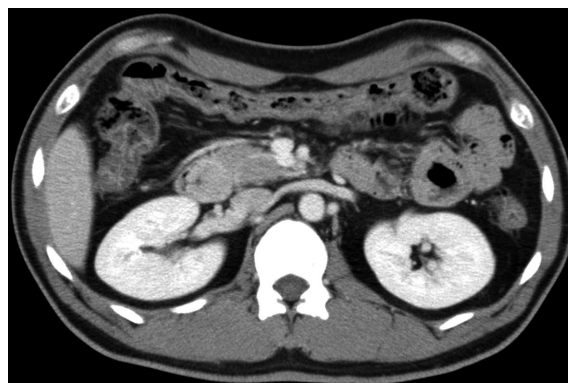
**Figure 2** Endoscopic ultrasonography revealed a round, low-echoic mass.

stromal tumor (GIST). GISTs are mesenchymal tumors of the gastrointestinal tract that express the tyrosine kinase receptor and originate from the interstitial cells of Cajal. The majority of GISTs are located in the stomach (60%-70%) and the small intestine (20%-25%), with only 4% occurring in the duodenum<sup>[1,2]</sup>. Cases of GIST affecting the ampulla of Vater are extremely rare, with only eleven cases described in the literature<sup>[1-11]</sup>. We report a case of GIST of the ampulla of Vater that was discovered because of loss of consciousness.

## CASE REPORT

A 36-year-old, previously healthy man presented with loss of consciousness lasting a few minutes. On admission, his blood pressure was 116/59 mmHg, heart rate was 85 beats/min, and temperature was 36.5 °C. A physical examination revealed mild anemia of the palpebral conjunctivae. The peripheral blood cell count indicated anemia with a hematocrit of 24.5%. The liver and renal function tests were normal. The levels of serum tumor markers, including carcinoembryonic antigen and carbohydrate antigen 19-9, were within normal limits.

A gastroduodenal endoscopy showed a submucosal tumor with central ulceration at the ampulla of Vater (Figure 1). Because there were small amounts of blood around the tumor, we considered that the patient had lost



**Figure 3** Enhanced computed tomography scan revealed a smooth-outlined hypervascular solid mass.

consciousness because of the bleeding from the tumor, which had already ceased spontaneously.

Endoscopic ultrasonography demonstrated a round, low-echoic mass originating from the muscularis propria (Figure 2). The enhanced computed tomography (CT) scan revealed a smooth-outlined hypervascular solid mass (24 mm × 30 mm) in the second part of the duodenum. Neither lymphadenopathy nor metastasis was observed (Figure 3). We additionally performed magnetic resonance imaging (MRI) and endoscopic retrograde cholangiopancreatography (ERCP) to obtain more information about the tumor, especially the relative position of the mass and the biliopancreatic duct because the tumor was located at the ampulla of Vater. On MRI, the mass showed low signal intensity on T1-weighted images and high signal intensity on T2-weighted images (Figure 4). Magnetic resonance cholangiopancreatography and ERCP showed normal bile and pancreatic ducts.

Biopsies were collected from the ulcerating lesion. The microscopic examination revealed a spindle-cell neoplasm, with the tumor cells positive for c-kit and CD34 (Figure 5). Thus, the tumor was diagnosed as a GIST.

The patient then underwent pancreatoduodenectomy. The operative specimen revealed a 2.2-cm GIST with 1 mitosis per 50 high-power fields, which classified the patient in the low-risk group, according to the National Institutes of Health (NIH) consensus criteria for risk stratification of GISTs. There was no lymph node metastasis. The patient was discharged 18 days after an uneventful postoperative course and has been doing well, with no recurrence, during the one-and-a-half years since the operation.

## DISCUSSION

GISTs are mesenchymal tumors of the gastrointestinal tract that express the tyrosine kinase receptor and originate from the interstitial cells of Cajal. The majority of GISTs are located in the stomach (60%-70%) and the small intestine (20%-25%), and only 4% of GISTs occur in the duodenum<sup>[1,2]</sup>. GIST of the ampulla of Vater is extremely rare. There are only eleven cases described

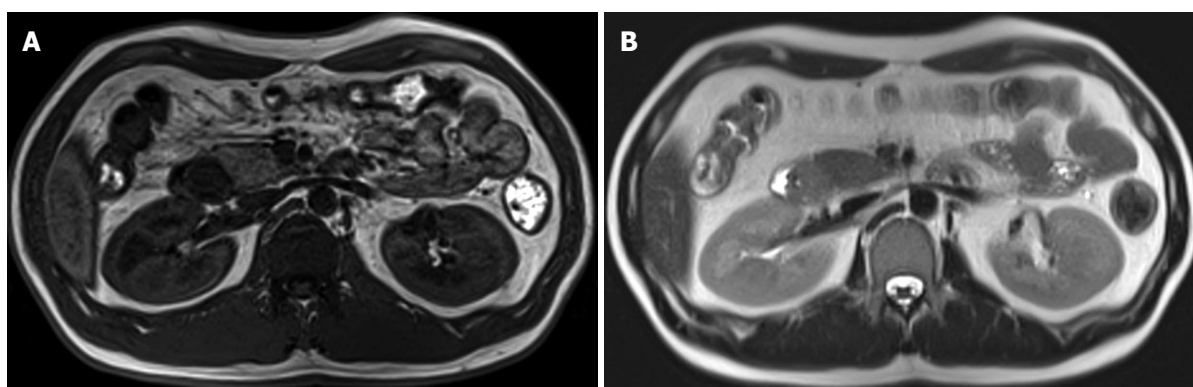


Figure 4 Mass showed low signal intensity on T1-weighted images (A) and high signal intensity on T2-weighted images (B).

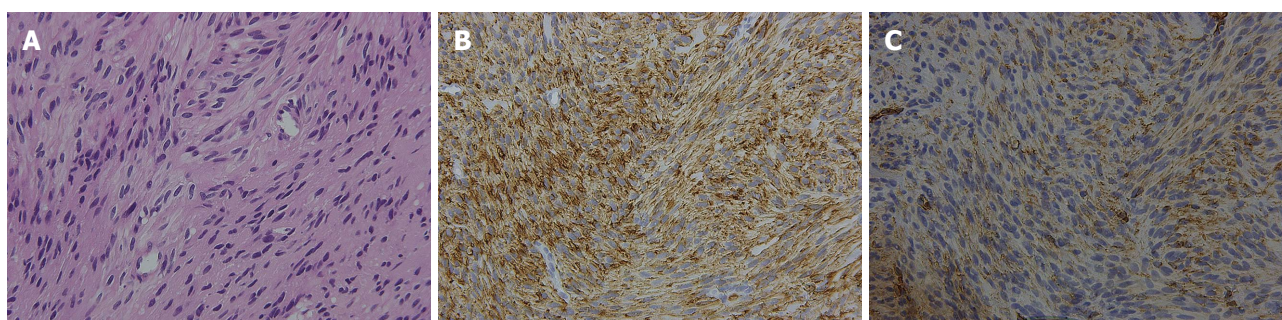


Figure 5 Microscopic examination revealed a spindle-cell neoplasm (A, hematoxylin and eosin,  $\times 200$ ), and the tumor cells were positive for c-kit (B,  $\times 200$ ) and CD34 (C,  $\times 200$ ).

Table 1 Reported cases of gastrointestinal stromal tumor of the ampulla of Vater

Age (yr)	Gender	Symptoms	Size (cm)	Biopsy	Surgery	Ref.	Year
83	Female	-	3.2	-	PD	[11]	2012
59	Male	Jaundice	7.6	GIST	PD	[10]	2010
55	Female	Epigastric pain	4.5	-	PD	[9]	2009
57	Male	Melena	2.6	GIST	Local resection	[8]	2007
69	Male	Melena	3.0	Negative	PD	[7]	2007
44	Male	Weight loss	9.0	GIST	PD	[6]	2007
65	Female	Jaundice	6.0	GIST	Local resection	[5]	2006
44	Male	Jaundice	8.0	Mesenchymal tumor	-	[2]	2005
68	Female	Weight loss	4.5	-	PD	[4]	2004
37	Female	Melena	5.5	GIST	PD	[1]	2004
77	Male	Pallor	4.0	GIST	PD	[3]	2001

GIST: Gastrointestinal stromal tumor.

in the literature according to a Medline search (Table 1) using the key words “ampulla of Vater” and “gastrointestinal stromal tumor”. The patients in the published reports were seven men and four women between 37 and 83 years of age. Our case was the youngest among these. Almost all cases exhibited certain symptoms, such as abdominal pain, jaundice, and melena. The tumor size ranged from 2.6-9 cm. Eight of the eleven cases showed a submucosal tumor with central ulceration, which may be a characteristic form of GISTs of the ampulla of Vater. In six cases, the diagnosis of GIST was made by the study of biopsies collected endoscopically from the ulcerating lesions. Although GISTs are submucosal tu-

mors, biopsy studies are useful for GIST of the ampulla of Vater because the tumor cells are exposed at the ulcerating lesions.

The differential diagnosis may include neuroendocrine tumor, gangliocytic paraganglioma, and intra-ampullary-type carcinoma, and there are also a few case reports of leiomyoma and leiomyosarcoma. In cases of neuroendocrine tumor, gastroduodenal endoscopy typically reveals a yellowish submucosal tumor with dilated vessels and erosion on the surface. Endoscopic ultrasonography demonstrates a low-echoic mass originating from the second/third layer. The diagnostic rate of biopsy is as low as 14%<sup>[12]</sup>, and some reported cases were diagnosed



by endoscopic ultrasonography fine needle aspiration<sup>[13]</sup>. In cases of gangliocytic paraganglioma, gastroduodenal endoscopy reveals a submucosal tumor with erosion and ulceration on the surface, located near the ampulla of Vater. By endoscopic ultrasonography, the tumor can typically be visualized as well circumscribed, located in the submucosal layer, and involving the muscularis propria. In cases of intra-ampullary-type carcinoma, gastroduodenal endoscopy reveals an enlarged papilla, and endoscopic ultrasonography shows an irregularly shaped low-echoic mass. Given these characteristics, a diagnosis can be reached by performing gastroduodenal endoscopy and endoscopic ultrasonography.

We cite this case as GIST of the ampulla of Vater because the GIST was macroscopically located at the ampulla of Vater. By definition, the ampulla of Vater is a field that is anatomically surrounded by the sphincter of Oddi. Therefore, GISTs of the ampulla of Vater should arise from the sphincter of Oddi based on the anatomical definition. In the case presented in this report, the GIST pathologically arose from the duodenal muscularis; of the reported ten cases, none of the reports mentioned the sphincter of Oddi. It is noteworthy to consider whether GISTs arising from the sphincter of Oddi actually exist. When GISTs of the ampulla of Vater are encountered, the relationship between the GISTs and the sphincter of Oddi is important to assess.

Among the ten patients who underwent surgery, eight cases involved pancreatoduodenectomy, and two were local resections. GISTs rarely metastasize to regional lymph nodes. There is only one reported GIST case with lymph nodes metastasis, and this particular patient also had liver metastasis<sup>[2]</sup>. The gold standard for GIST treatment is surgical resection without rupture of the tumor capsule. If technically feasible, local resection may be considered. However, when the location of the lesion presents associated difficulties, a pancreatoduodenectomy should be performed for GIST of the ampulla of Vater.

In general, adjuvant therapy with a tyrosine kinase inhibitor is recommended for patients with high-risk tumors, i.e., a tumor size > 10 cm, mitotic count > 10/50 HPF, and tumor rupture. However, no clear consensus exists regarding the cutoff that should be used to select patients for adjuvant therapy. In our case, the patient underwent no adjuvant therapy because he was in the low-risk group according to the NIH consensus criteria for risk stratification of GISTs. However, GISTs located at nongastric sites are associated with less favorable outcomes than are stomach GISTs. The patient in this case report has been doing well without recurrence during the one-and-a-half years since surgery, and we will continue to monitor him with a strict follow-up schedule.

## COMMENTS

### Case characteristics

A 36-year-old, previously healthy man presented with a loss of consciousness lasting a few minutes.

### Clinical diagnosis

Physical examination showed mild anemia of the palpebral conjunctivae.

### Differential diagnosis

Gastrointestinal bleeding.

### Laboratory diagnosis

The peripheral blood cell count showed anemia with a hematocrit of 24.5%; the liver and renal function tests were normal.

### Imaging diagnosis

Gastroduodenal endoscopy showed a submucosal tumor with central ulceration at the ampulla of Vater.

### Pathological diagnosis

Biopsies collected from the ulcerating lesion revealed a spindle-cell neoplasm and tumor cell positivity for c-kit and CD34.

### Treatment

The patient underwent pancreatoduodenectomy.

### Related reports

Gastrointestinal stromal tumor (GIST) of the ampulla of Vater is extremely rare, with only 11 cases reported in the literature.

### Experiences and lessons

This case report illustrates one of the rare causes of gastrointestinal bleeding; moreover, GIST of the ampulla of Vater can cause certain symptoms, such as abdominal pain, jaundice, and melena.

### Peer review

This article reports a rare case of a GIST of the ampulla of Vater.

## REFERENCES

- 1 Kim SH, Kim JH, Baik GH, Baek I, Hahn T, Oh SO, Kim JB, Park SH, Chang WK, Kim DJ, Park CK, Park HR. Malignant gastrointestinal stromal tumor of the ampulla of Vater: a case report. *Korean J Gastroenterol* 2004; **43**: 66-70 [PMID: 14745256]
- 2 Matsushita M, Kobayashi Y, Kobayashi H, Nagasawa M, Sato Y, Nakamura H. A case of gastrointestinal stromal tumour of the ampulla of Vater. *Dig Liver Dis* 2005; **37**: 275-277 [PMID: 15788212 DOI: 10.1016/j.dld.2004.06.019]
- 3 Takahashi Y, Noguchi T, Takeno S, Uchida Y, Shimoda H, Yokoyama S. Gastrointestinal stromal tumor of the duodenal ampulla: report of a case. *Surg Today* 2001; **31**: 722-726 [PMID: 11510612 DOI: 10.1007/s005950170079]
- 4 Wellmann K, Gohla G, Wenk H. [Malignant gastrointestinal stromal tumor (GIST) of the papilla vateri. A rare tumor entity]. *Chirurg* 2004; **75**: 196-199 [PMID: 14991183 DOI: 10.1007/s00104-003-0737-0]
- 5 Filippou DK, Pashalidis N, Skandalakis P, Rizos S. Malignant gastrointestinal stromal tumor of the ampulla of Vater presenting with obstructive jaundice. *J Postgrad Med* 2006; **52**: 204-206 [PMID: 16855323]
- 6 Koçer NE, Kayaselçuk F, Calışkan K, Ulasan S. Synchronous GIST with osteoclast-like giant cells and a well-differentiated neuroendocrine tumor in Ampulla Vateri: coexistence of two extremely rare entities. *Pathol Res Pract* 2007; **203**: 667-670 [PMID: 17656040 DOI: 10.1016/j.prp.2007.04.012]
- 7 Moss AC, Callery MP, Falchuk KR. Gastrointestinal [corrected] stromal tumor of the ampulla of vater mimicking a duodenal ulcer. *Clin Gastroenterol Hepatol* 2007; **5**: A26 [PMID: 17916534 DOI: 10.1016/j.cgh.2007.07.023]
- 8 Singhal D, Kumar M, Sud R, Chaudhary A. Image of the month. Gastrointestinal Stromal Tumor of the Ampulla of Vater. *Arch Surg* 2007; **142**: 899-900 [PMID: 17875846 DOI: 10.1001/archsurg.142.9.899]
- 9 Jerraya H, Bel Haj Salah R, Ben Mena K, Haouet K, Zaouche A. Stromal tumor of the ampulla of vater: report of a case and systematic review of reported cases. *Tunis Med* 2009 **87**: 556-559 [PMID: 20180372]
- 10 Park JE, Dong SH, Cho KH, Jang JY, Kim HJ, Kim BH, Chang YW, Chang R. [Successful resection of locally advanced gastrointestinal stromal tumor of the ampulla of Vater after

- treatment with imatinib]. *Korean J Gastroenterol* 2010; **56**: 39-44 [PMID: 20695129 DOI: 10.4166/kjg.2010.56.1.39]
- 11 **Brauner E**, Kuten J, Ben-Ishay O, HersHKovitz D, Kluger Y. Gastrointestinal stromal tumor of the ampulla of Vater. *Isr Med Assoc J* 2012; **14**: 588-589 [PMID: 23101427]
  - 12 **Hartel M**, Wente MN, Sido B, Friess H, Büchler MW. Carcinoid of the ampulla of Vater. *J Gastroenterol Hepatol* 2005; **20**: 676-681 [PMID: 15853978 DOI: 10.1111/j.1400-1746.2005.03744.x]
  - 13 **El Hajj II**, El Chafic AH, Cramer H, Al-Haddad M. Ampullary carcinoid tumors diagnosed by endoscopic ultrasound-guided fine needle aspiration in two patients with biliary and pancreatic duct obstruction. *Endoscopy* 2011; **43** Suppl 2 UCTN: E422-E423 [PMID: 22275034 DOI: 10.1055/s-0030-1257031]

**P- Reviewers:** Le Bian AZ, Wornni M    **S- Editor:** Wen LL  
**L- Editor:** A    **E- Editor:** Wu HL





Published by **Baishideng Publishing Group Co., Limited**

Flat C, 23/F., Lucky Plaza,  
315-321 Lockhart Road, Wan Chai, Hong Kong, China

Fax: +852-65557188

Telephone: +852-31779906

E-mail: [bpgoffice@wjgnet.com](mailto:bpgoffice@wjgnet.com)

<http://www.wjgnet.com>



ISSN 1007-9327



9 771007 932045