

Pedunculated Brunner's gland hamartoma of the duodenum causing upper gastrointestinal hemorrhage

Shoji Hirasaki, Motoharu Kubo, Atsushi Inoue, Yasuyuki Miyake, Hisako Oshiro

Shoji Hirasaki, Motoharu Kubo, Atsushi Inoue, Yasuyuki Miyake, Hisako Oshiro, Department of Internal Medicine, Kubo Hospital, Imabari 7992116, Japan

Author contributions: Hirasaki S and Kubo M contributed equally to this work; Hirasaki S, Kubo M, Inoue A, Miyake Y and Oshiro H were involved in the care of the patient; Kubo M performed the endoscopic resection; Hirasaki S wrote the paper. Correspondence to: Shoji Hirasaki, Department of Internal Medicine, Kubo Hospital, 1-1-19 Uchibori, Imabari 7992116, Japan. hirasaki@icknet.ne.jp

Telephone: +81-898-413233 Fax: +81-898-415841

Received: November 25, 2008 Revised: December 15, 2008

Accepted: December 22, 2008

Published online: January 21, 2009

Abstract

A case of pedunculated Brunner's gland hamartoma (BGH) of the duodenum causing upper gastrointestinal (GI) hemorrhage is reported. The patient was a 47-year-old man who visited our hospital for further evaluation of tarry stools and shortness of breath. Endoscopic examination of the upper digestive tract revealed a large peduncular polyp with bleeding, about 30 mm in diameter, arising from the wall of the second portion of the duodenum. GI bleeding occurred from the base of the stalk of the polyp. Endoscopic polypectomy was performed. Histological examination of the specimen revealed that the main body of the polyp contained several lobules of mature Brunner's gland with areas of cystic dilatation. The surface epithelium consisted of normal duodenal mucosa with areas of focal ulceration. This polyp was diagnosed as a BGH. The symptom of tarry stools resolved after endoscopic resection. Our case shows that treatment is necessary for duodenal BGH if GI bleeding occurs.

© 2009 The WJG Press and Baishideng. All rights reserved.

Key words: Brunner's gland; Hyperplasia; Duodenal polyp; Endoscopic polypectomy; Gastrointestinal bleeding

Peer reviewer: Chee Hooi Lim, MD, MBChB, MRCP, CCST, Department of Gastroenterology, Good Hope Hospital, Sutton Coldfield, W Midlands B75 7RR, United Kingdom

Hirasaki S, Kubo M, Inoue A, Miyake Y, Oshiro H. Pedunculated Brunner's gland hamartoma of the duodenum

causing upper gastrointestinal hemorrhage. *World J Gastroenterol* 2009; 15(3): 373-375 Available from: URL: <http://www.wjgnet.com/1007-9327/15/373.asp> DOI: <http://dx.doi.org/10.3748/wjg.15.373>

INTRODUCTION

Brunner's gland hyperplasia and hamartoma are infrequently encountered polypoid nodules and masses in the proximal duodenum^[1]. Brunner's gland hamartoma (BGH) is a very rare cause of upper gastrointestinal (GI) hemorrhage. Clinically, patients may present with symptoms of duodenal obstruction or upper GI hemorrhage and require endoscopic or surgical excision^[2]. Herein, we describe a relatively rare case of pedunculated BGH of the duodenum causing upper GI hemorrhage.

CASE REPORT

A 47-year-old man presented with the symptoms of tarry stools and shortness of breath. He was in good health with no specific family or past medical history. His body temperature was 36.5°C, blood pressure was 148/82 mmHg, and radial pulse rate was 70 beats/min and regular. He had anemia, but no jaundice. Neurological examination revealed no abnormal findings. Laboratory tests showed a red blood cell count of $318 \times 10^4/\mu\text{L}$ [normal range (NR), 430×10^4 - $570 \times 10^4/\mu\text{L}$], a white blood cell count of $7600/\mu\text{L}$, a platelet count of $30.8 \times 10^4/\mu\text{L}$, and a hemoglobin concentration of 8.9 g/dL (NR, 14-18 g/dL). Endoscopic examination of the upper digestive tract revealed a large peduncular polyp, about 30 mm in diameter, arising from the wall of the second portion of the duodenum (Figure 1A). The polyp head was lobulated. GI bleeding occurred from the base of stalk of the polyp (Figure 1B and C). It was suspected to be a BGH, from the endoscopic findings. An air-contrast barium meal also revealed a pedunculated polyp in the second portion of the duodenum (Figure 2). There was no lesion in the esophagus and stomach. Endoscopic polypectomy was performed (Figure 3). The cut surface of the resected specimen showed an approximately 3-cm whitish mass (Figure 4). Histological examination of the specimen revealed that the main body of the polyp contained several lobules of mature Brunner's gland with areas of cystic dilatation (Figure 5). The surface

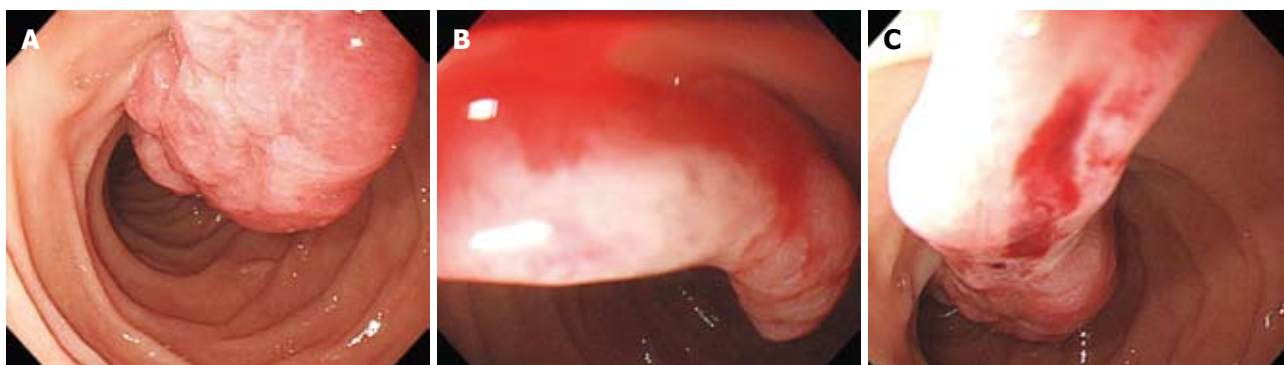

Figure 1 Endoscopy images. A large lobulated peduncular polyp, about 30 mm in diameter, in the second portion of the duodenum (A and B) and bleeding from the base of the stalk of the polyp (C).

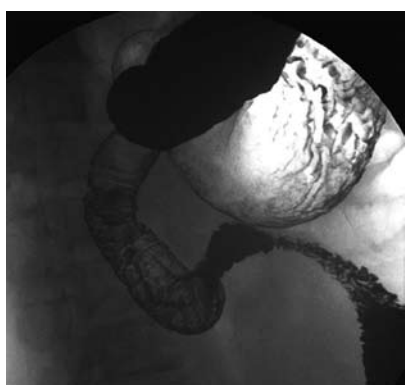


Figure 2 Double contrast radiograph of the duodenum showing an approximately 3-cm peduncular polyp.

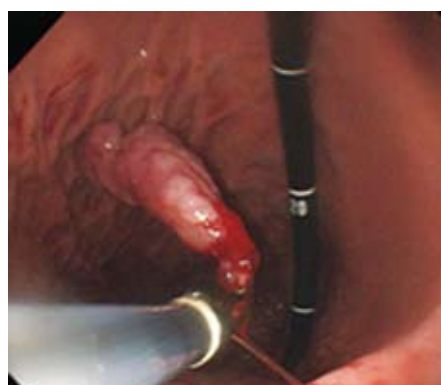


Figure 3 Endoscopic polypectomy was performed and the resected specimen was moved into the stomach.

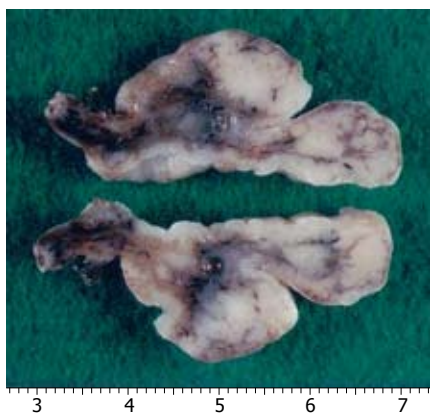

Figure 4 Macroscopic findings of the polypectomy specimen. The cut surface showed an approximately 3-cm whitish mass.

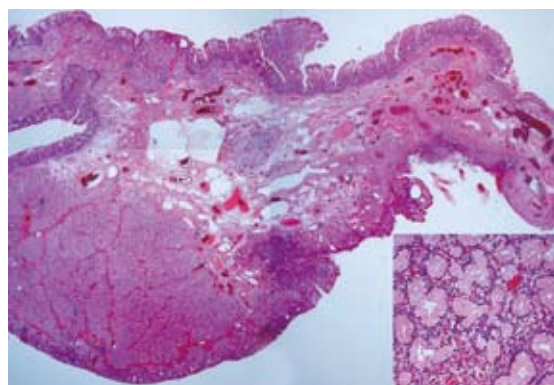


Figure 5 Microscopic findings of the polypectomy specimen. Low-power view of a cross section showing submucosal proliferation of Brunner's gland below the duodenal mucosa (HE x 10, x 100).

epithelium consisted of normal duodenal mucosa with areas of focal ulceration. The base of the stalk was ulcerated. There was no evidence of malignancy. The lesion was diagnosed as a pedunculated BGH of the duodenum. After endoscopic polypectomy, the symptom of tarry stools resolved.

DISCUSSION

The etiology of BGH remains obscure. BGH is present mostly in middle age without any gender

predominance^[3]; however, cases have been described from early infancy to even 80 years of age. BGHs have a broad range of sizes (0.5-12 cm)^[1,4-6]. The most common location is the posterior wall of the duodenum near the junction of the first and second portions. BGHs were found in the duodenal bulb in 70% of cases, in the second portion of the duodenum in 26%, and in the third portion in 4% in one series of 27 patients by Levine *et al*^[3]. In the present case, it was located in the second portion of the duodenum.

BGHs are usually asymptomatic and often detected

incidentally on barium meal or endoscopy^[1,6]. Another review of the literature has revealed that the main clinical feature of BGH is GI bleeding or bowel obstruction^[1,2,4,6,7]. The diagnosis of BGH is usually made by a combination of radiographic and endoscopic findings. The radiographic finding of large localized BGHs is a sessile or pedunculated polypoid filling defect^[1,6,8]. Endoscopic characteristic findings, like radiographic findings, are as follows: (1) pedunculated polyp, although 11% can be sessile^[3,9,10]; (2) polypoid or lobulated mass; and (3) covered with normal mucosa^[3,11,12]. BGH should be distinguished from other duodenal lesions such as leiomyoma, polypoid adenoma of the superficial mucosal glands, aberrant pancreatic tissue and malignant tumors^[1,4,13,14]. Diagnosis is rarely conclusive on endoscopic biopsies because the lesion locates mainly in the submucosal layer, and the biopsy is often not deep enough to reach the submucosal tumor tissue^[1,6,13]. The final diagnosis of BGH depends on the pathological findings of resected specimens obtained by endoscopic mucosal resection, polypectomy or surgical treatment.

As to therapy, BGH of the duodenum can best be removed endoscopically, because it is thought to be clinically and histologically benign. However, endoscopists should be aware that there have been rare case reports of malignancy arising from Brunner's gland^[1,4,15,16]. Endoscopic or surgical treatment is necessary if GI bleeding occurs^[4,7,11-14], as in the present case. GI bleeding, typically manifested by hematemesis or melena, from ulceration or erosion of the mucosa stretched over the submucosal lesion, may occur and can occasionally be massive and rarely fatal^[3,10,13]. In the present case, bleeding was caused by ulceration of the stalk. The mechanism underlying GI bleeding in the present case was atypical.

In conclusion, we report a case of pedunculated BGH of the duodenum causing upper GI hemorrhage. BGH should be generally taken into consideration as a differential diagnosis of duodenal masses. BGH is not fatal and patients remain asymptomatic in their daily lives, except for GI bleeding or bowel obstruction. Endoscopists should be aware that BGH may exhibit the aforementioned endoscopic characteristics and may cause GI bleeding.

REFERENCES

- 1 **Patel ND**, Levy AD, Mehrotra AK, Sobin LH. Brunner's gland hyperplasia and hamartoma: imaging features with clinicopathologic correlation. *AJR Am J Roentgenol* 2006; **187**: 715-722
- 2 **Matsumoto T**, Iida M, Matsui T, Yao T, Fujishima M. A large Brunner's gland adenoma removed by endoscopic polypectomy. *Endoscopy* 1990; **22**: 192-193
- 3 **Levine JA**, Burgart LJ, Batts KP, Wang KK. Brunner's gland hamartomas: clinical presentation and pathological features of 27 cases. *Am J Gastroenterol* 1995; **90**: 290-294
- 4 **Chattopadhyay P**, Kundu AK, Bhattacharyya S, Bandyopadhyay A. Diffuse nodular hyperplasia of Brunner's gland presenting as upper gastrointestinal haemorrhage. *Singapore Med J* 2008; **49**: 81-83
- 5 **Nakanishi T**, Takeuchi T, Hara K, Sugimoto A. A great Brunner's gland adenoma of the duodenal bulb. *Dig Dis Sci* 1984; **29**: 81-85
- 6 **Gao YP**, Zhu JS, Zheng WJ. Brunner's gland adenoma of duodenum: a case report and literature review. *World J Gastroenterol* 2004; **10**: 2616-2617
- 7 **de Nes LC**, Ouwehand F, Peters SH, Boom MJ. A large Brunner's gland hamartoma causing gastrointestinal bleeding and obstruction. *Dig Surg* 2007; **24**: 450-452
- 8 **Peetz ME**, Moseley HS. Brunner's gland hyperplasia. *Am Surg* 1989; **55**: 474-477
- 9 **Brookes MJ**, Manjunatha S, Allen CA, Cox M. Malignant potential in a Brunner's gland hamartoma. *Postgrad Med J* 2003; **79**: 416-417
- 10 **Zangara J**, Kushner H, Drachenberg C, Daly B, Flowers J, Fantry G. Iron deficiency anemia due to a Brunner's gland hamartoma. *J Clin Gastroenterol* 1998; **27**: 353-356
- 11 **Kehl O**, Buhler H, Stamm B, Amman RW. Endoscopic removal of a large, obstructing and bleeding duodenal Brunner's gland adenoma. *Endoscopy* 1985; **17**: 231-232
- 12 **Block KP**, Frick TJ, Warner TF. Gastrointestinal bleeding from a Brunner's gland hamartoma: characterization by endoscopy, computed tomography, and endoscopic ultrasound. *Am J Gastroenterol* 2000; **95**: 1581-1583
- 13 **Schluger LK**, Rotterdam H, Lebwohl O. Gastrointestinal hemorrhage from a Brunner's gland hamartoma. *Am J Gastroenterol* 1994; **89**: 2088-2089
- 14 **Walden DT**, Marcon NE. Endoscopic injection and polypectomy for bleeding Brunner's gland hamartoma: case report and expanded literature review. *Gastrointest Endosc* 1998; **47**: 403-407
- 15 **Christie AC**. Duodenal carcinoma with neoplastic transformation of the underlying Brunner's glands. *Br J Cancer* 1953; **7**: 65-67
- 16 **Fujimaki E**, Nakamura S, Sugai T, Takeda Y. Brunner's gland adenoma with a focus of p53-positive atypical glands. *J Gastroenterol* 2000; **35**: 155-158

S- Editor Tian L L- Editor Kerr C E- Editor Lin YP