

Is breast conservative surgery a reasonable option in multifocal or multicentric tumors?

Gilles Houvenaeghel, Agnès Tallet, Aurélie Jalaguier-Coudray, Monique Cohen, Marie Bannier, Camille Jauffret-Fara, Eric Lambaudie

Gilles Houvenaeghel, Agnès Tallet, Aurélie Jalaguier-Coudray, Monique Cohen, Marie Bannier, Camille Jauffret-Fara, Eric Lambaudie, Institut Paoli Calmettes and CRCM, Aix Marseille Université, 13009 Marseille, France

Author contributions: All the authors contributed equally to this work.

Conflict-of-interest statement: There is no conflict of interest associated with any of senior author, coauthors, contributed their efforts in this manuscript.

Open-Access: This article is an open-access article which was selected by an in-house editor and fully peer-reviewed by external reviewers. It is distributed in accordance with the Creative Commons Attribution Non Commercial (CC BY-NC 4.0) license, which permits others to distribute, remix, adapt, build upon this work non-commercially, and license their derivative works on different terms, provided the original work is properly cited and the use is non-commercial. See: <http://creativecommons.org/licenses/by-nc/4.0/>

Correspondence to: Gilles Houvenaeghel, MD, Institut Paoli Calmettes and CRCM, Aix Marseille Université, 232 Bd de Sainte Marguerite, 13009 Marseille, France. houvenaeghel@ipc.unicancer.fr
Telephone: +33-4-91223532
Fax: +33-4-91223613

Received: June 11, 2015
Peer-review started: June 15, 2015
First decision: September 17, 2015
Revised: October 29, 2015
Accepted: November 24, 2015
Article in press: November 25, 2015
Published online: April 10, 2016

Abstract

The incidence of multifocal (MF) and multicentric (MC) carcinomas varies widely among clinical studies, depend-

ing on definitions and methods for pathological sampling. Magnetic resonance imaging is increasingly used because it can help identify additional and conventionally occult tumors with high sensitivity. However, false positive lesions might incorrectly influence treatment decisions. Therefore, preoperative biopsies must be performed to avoid unnecessary surgery. Most studies have shown higher lymph node involvement rates in MF/MC tumors than in unifocal tumors. However, the rate of local recurrences is usually low after breast conservative treatment (BCT) of MC/MF tumors. It has been suggested that BCT is a reasonable option for MC/MF tumors in women aged 50-69 years, with small tumors and absence of extensive ductal carcinoma *in situ*. A meta-analysis showed an apparent decreased overall survival in MC/MF tumors but data are controversial. Surgery should achieve both acceptable cosmetic results and negative margins, which requires thorough preoperative radiological workup and localization of lesions. Boost radiotherapy techniques must be evaluated since double boosts might result in increased toxicity, namely fibrosis. In conclusion, BCT is feasible in selected patients with MC/MF but the choice of surgery must be discussed in a multidisciplinary team comprising at least radiologists, surgeons and radiotherapists.

Key words: Mastectomy; Breast conservative surgery; Multifocal tumors; Multicentric tumors; Radiotherapy; Local recurrence; Breast cancer; Survival

© **The Author(s) 2016.** Published by Baishideng Publishing Group Inc. All rights reserved.

Core tip: Multicentric and multifocal breast tumors should be identified preoperatively in order to adapt surgical treatment. They might be associated with more frequent lymph node involvement and worse prognosis but in most studies, the rates of local recurrence are low and similar to those of unifocal tumors. Breast conservative treatment is a reasonable option in selected patients

(age 50-69 years, small tumors and absence of extensive ductal carcinoma *in situ*). Postoperative radiotherapy, and especially boost radiotherapy must be discussed and evaluated due to the risk of increased toxicity in case of double boost.

Houvenaeghel G, Tallet A, Jalaguier-Coudray A, Cohen M, Bannier M, Jauffret-Fara C, Lambaudie E. Is breast conservative surgery a reasonable option in multifocal or multicentric tumors? *World J Clin Oncol* 2016; 7(2): 234-242 Available from: URL: <http://www.wjgnet.com/2218-4333/full/v7/i2/234.htm> DOI: <http://dx.doi.org/10.5306/wjco.v7.i2.234>

INTRODUCTION

Multicentric (MC: At least 2 invasive tumors in 2 different quadrants) or multifocal (MF: At least 2 invasive tumors in the same quadrant) carcinoma can be diagnosed preoperatively or in resected specimens^[1,2]. The frequency of these tumors ranges from 4% to 75%^[3-10]. This large variability results from differences in the definitions used and the methods of pathologic sampling^[11,12]. With continuous advances in preoperative imaging, the rate of MF and MC tumors is increasing^[13-15].

Conservative surgery with radiotherapy has been widely accepted as an alternative to mastectomy in the management of early stage breast cancer^[16,17], with a long-term local recurrence rate of approximately 15%-20%^[16-28]. The diagnosis of multifocality may influence breast cancer management, particularly with regard to the choice of surgery. Conservative treatment as an alternative to mastectomy in patients with synchronous ipsilateral breast cancer is controversial and no consensus exists. MF/MC breast cancer is generally considered as a contraindication for conservative surgery because of concerns about an increased risk of local recurrence^[29-32]. According to some reports, the local recurrence rate in MF/MC breast cancer after breast conservative therapy (BCT) is higher than that of unifocal tumors^[31,33]. This is the main reason for excluding BCT for MF/MC breast cancer^[34]. Moreover, poor cosmetic results, due to large resections, are also evoked. Therefore, many surgeons continue to perform mastectomy in patients with MF/MC breast cancer.

In contrast, extensive data have confirmed an excellent local control after BCT for unifocal breast cancer^[16,17,35-43]. At the 12-year follow-up of the National Surgical Adjuvant Breast and Bowel Project B-06 trial, the cumulative incidence of ipsilateral breast recurrence was only 10% in the group treated by lumpectomy and breast irradiation^[36].

The effectiveness of boost radiation treatment to decrease local recurrence has been established in a randomized trial by Bartelink *et al*^[44]. However, in MF/MC breast cancer, the influence of boost radiation has been poorly reported. From a surgical point of view, BCT with negative margins and acceptable aesthetic outcome

can be achieved if tumour foci are close enough to be resected as a single specimen^[45].

One study has shown a significant association between positive surgical margins and failure of attempted BCT in the case of MF tumors^[46].

This review will focus on the issue of conservative surgery with radiotherapy in the management of patients with MF/MC breast cancer.

DEFINITION OF MF AND MC TUMORS

MC carcinomas are defined by the presence of at least two invasive tumors in two different quadrants of the breast or in the same quadrant but at least 5 cm apart^[1]. MF carcinomas are defined by the presence of several invasive tumors in the same quadrant of the breast or in different quadrants if the distance between foci is below 5 cm.

Multiple tumors are defined by the presence of synchronous, distinct, invasive tumors in the same breast, and comprise MC and MF carcinomas. They can be discovered in two different settings: (1) Preoperative diagnosis of at least 2 different invasive tumors, based on clinical and/or radiological findings; and (2) Histological diagnosis when pathological examination of surgical specimens shows several foci, while the tumor was considered as unifocal based on preoperative workup.

However, various situations must be considered according to the localization of multiple tumors in the different quadrants of the breast and to the distance from the nipple-areola complex^[47].

FREQUENCY OF MC AND MF TUMORS

In the meta-analysis published by Vera-Badillo *et al*^[3], including 67557 patients, the rate of MC/MF tumors was 9.5% (6434 patients). In the EORTC 10981-22023 AMAROS trial, MF tumors of the same quadrant were included after 2008 and represented 33% of cases (342/1026)^[4].

However, the prevalence of MC/MF tumors varies from 5% to 44% in published series^[4-8], depending on the definition used, the method of histological examination of mastectomy specimens and the type of imaging used for diagnosis (Table 1).

Imaging

Mammography and ultrasound are the standard imaging tests for the diagnosis of breast cancer, and are also used to determine the extent of the disease within the affected breast. Because of its high sensitivity in breast cancer diagnosis and screening, magnetic resonance imaging (MRI) is being increasingly evaluated and used for preoperative local staging of breast cancer. Several multicenter trials showed that, in women with newly diagnosed breast cancer, MRI helped identify additional, conventionally occult lesions in 15%-27% of cases^[48-51]. In addition, MR helped identify unsuspected synchronous cancer in the opposite breast in 3%-6%

Table 1 Incidence of multifocal/multicentric tumors in the literature

Ref.	Yr	MF/MC (n)	MF/MC (%)
NIH <i>et al</i> ^[81]	1986	342	9
Vlastos <i>et al</i> ^[82]	2000	60	21
¹ Katz <i>et al</i> ^[83]	2001	149	14
Andea <i>et al</i> ^[62]	2002	101	18
¹ Pedersen <i>et al</i> ^[84]	2004	158	17
EBCTCG ^[85]	2005	1187	6
Coombs <i>et al</i> ^[8]	2005	94	11
¹ Litton <i>et al</i> ^[86]	2007	58	19
¹ Joergensen <i>et al</i> ^[87]	2008	945	13
¹ Cabioglu <i>et al</i> ^[88]	2009	147	11
¹ Yerushalmi <i>et al</i> ^[11]	2009	1554	6.1
¹ Weissenbacher <i>et al</i> ^[65]	2010	288	5
¹ Tot <i>et al</i> ^[89]	2011	148	30
Tot <i>et al</i> ^[90]	2011	225	44
Rezo <i>et al</i> ^[91]	2011	141	17
¹ Ustaalioglu <i>et al</i> ^[2]	2012	107	15.4
¹ Lynch <i>et al</i> ^[63]	2012	942	24
¹ Yerushalmi <i>et al</i> ^[5]	2012	1187	6
¹ Chung <i>et al</i> ^[66]	2012	164	14
Meretoja <i>et al</i> ^[92]	2012	206	20.6
¹ Pekar <i>et al</i> ^[93]	2013	153	34
Wolters <i>et al</i> ^[64]	2013	1862	20.8
Lynch <i>et al</i> ^[63]	2013	906	24
Hilton <i>et al</i> ^[94]	2013	202	15
van der Heiden-van der Loo <i>et al</i> ^[95]	2013	1729	13.1
Vera-Badillo <i>et al</i> ^[3]	2014	6565	9.7

¹Included in the meta-analysis of Vera-Badillo *et al*^[3]. MF/MC: Multifocal/multicentric.

of women with a recent diagnosis of unilateral breast cancer^[51]. However, the impact of breast MRI on breast cancer management is debated, due to a large number of additional benign lesions that could be detected and incorrectly influence clinical decisions^[52,53]. Indeed, one of the major limitations of breast MRI is that false-positive enhancement may appear in benign lesions, resulting in a relatively low specificity^[49]. If additional suspicious findings are identified, preoperative biopsies must be performed to limit the number of unnecessary wider excisions or mastectomies^[54].

INCIDENCE OF LYMPH NODE INVOLVEMENT IN MC/MF TUMORS

Although the meta-analysis of Vera-Badillo *et al*^[3] did not show differences in the rate of lymph node involvement, all the other studies demonstrated a higher rate in MC/MF tumors compared to unifocal tumors, with a mean difference of 10% to 20%.

The studies that reported lymph node detection showed the positivity of sentinel nodes in 42% to 59% of cases^[4,55-62]. The main hypothesis to explain this higher rate is that the global tumor volume, that includes all MC/MF tumors, is usually more important than that of unifocal tumors. However, in MC/MF carcinomas, tumor size is determined by the largest index lesion regardless of the number and size of other lesions, which does not take into account the cumulative tumor volume.

In the EORTC 10981-22023 AMAROS trial, sentinel node involvement for MF and unifocal tumors respectively was the following: Macrometastases 61% (105/171) and 57% (109/192) (NS), micrometastases 30% (52/171) and 29% (55/192) (NS), isolated tumor cells 8% (13/171) and 14% (27/192) ($P = 0.05$)^[4].

LOCAL RECURRENCE RATE OF MC/MF TUMORS COMPARED WITH UNIFOCAL TUMORS

The rate of local recurrences for MC/MF tumors in case of conservative treatment is low, except in the 3 oldest studies (Table 2), and similar to that observed after conservative treatment of unifocal tumors. As for unifocal tumors, this rate depends on selection criteria, particularly resection in negative margins, age over 35 or 40 years and tumor phenotype (hormone receptors and HER2 status).

LOCAL RECURRENCE RATES AND SURVIVAL IN MC/MF TUMORS COMPARED TO UNIFOCAL TUMORS BY TREATMENT STRATEGY (CONSERVATIVE OR NOT)

In the study by Lynch *et al*^[63], published in 2013, the rate of local recurrences was determined for unifocal tumors ($n = 2816$) and for MC ($n = 233$) or MF ($n = 673$) tumors according to treatment, namely 256 BCT, 466 mastectomies without radiotherapy and 184 mastectomies followed by radiotherapy (PMRT). After a median follow-up of 52 mo, the rate of locoregional control was 99%, 96% and 98% for MF, MC and unifocal tumors respectively ($P = 0.44$). Subgroup analyses showed similar results for the three treatment strategies (BCT, mastectomy without radiotherapy or PMRT). In multivariate analysis, multicentricity/multifocality was not associated with decreased locoregional control. The authors concluded that BCT was a valid option for MC/MF carcinomas of the breast and that the presence of MC/MF alone is not an indication of PMRT.

In the study by Yerushalmi *et al*^[5], local recurrence rate was determined after a median follow-up of 7.9 years and the authors compared the outcome of 11983 BCT (11683 unifocal tumors and 300 MC/MF tumors), and 7771 mastectomies (6884 unifocal tumors and 887 MC/MF tumors)^[5]. One fourth of MC/MF patients had BCT (300/1187). MC/MF patients who benefited from BCT were aged 50 to 69 years, they had no extensive ductal carcinoma *in situ* (DCIS) and they had smaller tumors. Cumulative local recurrence rate at 10 years was 1) for BCT 4.6% (95%CI: 4.1, 5) in unifocal tumors vs 5.5% (95%CI: 2.6, 9.9) in MC/MF tumors, $P = 0.76$, 2) for mastectomies 5.8% (95%CI: 5.2, 6.5) for unifocal tumors vs 6.5% (95%CI: 4.7, 8.7) in MC/MF tumors,

Table 2 Rates of local recurrence in multifocal/multicentric breast cancer^[5,31-33,63,66,68-73,93-96]

Ref.	Yr	Patients	MF or MC	Median follow-up (mo)	Local recurrences, %
Leopold <i>et al</i> ^[32]	1989	10	MF/MC	64	40
Kurtz <i>et al</i> ^[31]	1990	61	MF/MC	71	25
Wilson <i>et al</i> ^[33]	1993	13	MF	72	25
Hartsell <i>et al</i> ^[71]	1994	27	MC	53	3.7
Nos <i>et al</i> ^[72]	1999	56	MF	60	11
Cho <i>et al</i> ^[73]	2002	15	MF/MC	76	0
Kaplan <i>et al</i> ^[74]	2003	36	MF/MC	45	3
Okumura <i>et al</i> ^[75]	2004	34	MF/MC	58	0
Oh <i>et al</i> ^[96]	2006	97	MF/MC	66	6
Gentilini <i>et al</i> ^[76]	2008	476	MF/MC	73	5
Lim <i>et al</i> ^[97]	2009	147	MF	59	2
Bauman <i>et al</i> ^[98]	2010	22	MF/MC	42	4.5
Chung <i>et al</i> ^[66]	2012	164	MF	112	6.1
Yerushalmi <i>et al</i> ^[5]	2012	300	MF/MC	95	5.51
Lynch <i>et al</i> ^[63]	2013	256	MF	52	1.95
Kadioğlu <i>et al</i> ^[99]	2014	237	MF	46	5.2
Kadioğlu <i>et al</i> ^[99]	2014	36	MC	46	2

MF/MC: Multifocal/multicentric.

$P = 0.77$. In multivariate analysis, MC/MF was not significantly associated with recurrence or poor survival. In an additional matched analysis, recurrence rates were similar for MC/MF and unifocal tumors ($P = 0.6$). The authors concluded that BCT is a reasonable option in selected cases of MC/MF tumors, in particular in women aged 50-69 years, with small size tumors (< 1 cm) without extensive DCIS.

Wolters *et al*^[64] compared recurrence free survival and overall survival in 8935 patients with 7073 unifocal tumors (79.2%), 1398 MF tumors (15.6%) and 464 MC tumors (5.2%). They did not show any difference in RFS (1) in MF tumors (T1/T2 treated according to guidelines) for BCT ($n = 623$) vs mastectomy ($n = 319$): HR = 1.25, (95%CI: 0.83-1.88), $P = 0.284$, and (2) in MC tumors after adjustment on tumor size in case of negative margins, for BCT ($n = 60$) vs mastectomy ($n = 217$): HR = 1.19, (95%CI: 0.48-2.97), $P = 0.7$ and vs mastectomy + PMRT, HR = 1.23, (95%CI: 0.51-3.00), $P = 0.64$.

IMPACT OF MC/MF TUMORS ON SURVIVAL AND SYSTEMIC RISK COMPARED TO UNIFOCAL TUMORS, REGARDLESS OF TREATMENT (BCT OR MASTECTOMY)

In a study on 288 unifocal tumors matched with 288 MC/MF tumors the presence of MC/MF was significantly associated with decreased OS ($P = 0.016$), increased local recurrences ($P = 0.001$) and development of metastases ($P = 0.038$)^[65].

In the study by Wolters *et al*^[64], after adjustment on age, tumor size, grade and nodal status, no difference was shown in RFS or OS in patients who received adjuvant therapy according to guidelines in MC or MF tumors compared to unifocal tumors: (1) For MC carcinomas, no

difference in RFS [HR = 0.88, (95%CI: 0.67-1.16), $P = 0.35$] and in OS [HR = 1.08, (95%CI: 0.85-1.36), $P = 0.54$]; and (2) for MF carcinomas, no difference in RFS [HR = 1.05, (95%CI: 0.89-1.24), $P = 0.597$] and in OS [HR = 0.92, (95%CI: 0.78-1.08), $P = 0.28$].

In the meta-analysis of Vera-Badillo *et al*^[3], the impact on survival of MF/MC tumors was compared to that of unifocal tumors from 22 studies and 67557 patients (6565 MF/MC et 62326 unifocal tumors). In multivariate analysis, MC/MF tumors were associated with decreased OS (HR = 1.65, 95%CI: 1.07-2.52; $P = 0.02$), but the difference was not statistically significant in RFS (HR = 1.96, 95%CI: 0.94-4.12; $P = 0.07$). The authors concluded that MC/MF tumors seem to be associated with worse prognosis; however, the heterogeneity between studies did not allow an accurate determination of the real risk (one study alone, that differs from other studies, determined the shorter OS^[66]).

SURGICAL PROCEDURES AND COSMETIC RESULTS

In MC/MF carcinomas, the localization of tumors is of utmost importance to determine the type of resection allowing both favorable cosmetic results and negative margins. Types of incision and resections are determined according to the localization of tumors, the breast size, the degree of ptosis, the areola size and the distance from areola. In the last decade with the introduction of oncoplastic techniques, the surgical approach of MC tumors have changed. Oncoplastic techniques are therefore particularly adapted and valuable in this situation, achieving negative margins and a good cosmetic results better than conventional BCS; a schematic cartography of various possible situations and resection techniques^[47] and a classification quadrant per quadrant atlas for many oncoplastic surgical procedures were proposed^[67]. This strategy was applied to a consecutive series of 175

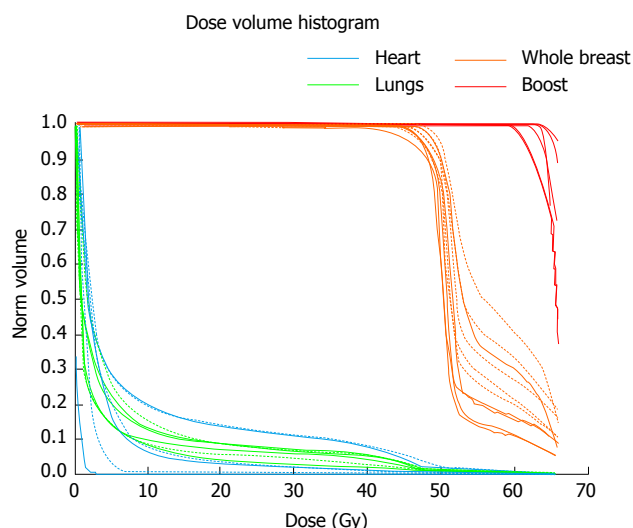


Figure 1 Dose-volume histograms for patients treated with a single boost (continuous lines) and with a double boost (dashed lines). The percentage of breast receiving 60 Gy or more with a single boost varies from 10% to 29% (median 15%, mean 16%) and with a double boost from 19% to 39% (median 25%, mean 27%).

women with breast cancer who required mastoplastic, including 27 patients (15.4%) with MF tumors^[68]. This study has confirmed that oncoplastic surgery techniques for breast cancer are associated with a low reoperation rate, a low risk of delay to adjuvant therapy and good cosmetic results. In an another study, Clough *et al*^[69] reported 17.2% (10/58) of positive margins after oncoplastic surgery for MF breast cancer, without significant difference with positive margins rate after oncoplastic surgery for unifocal tumor (10.6%: 23/217).

Radiological workup and preoperative tracking are essential to perform appropriate resection with negative margins. The orientation and the identification of resection margins on surgical specimens, that sometimes have complex shapes and localizations, must be accurate and requires the collaboration of surgeons and pathologists. A completion resection might be necessary.

BOOST RADIOTHERAPY IN MF/MC TUMORS

The benefits of a boost to the tumor bed have been demonstrated for invasive breast cancer treated with conservative surgery. However, extended boost, and more specifically boost fields for two locations in the breast, should be thoroughly evaluated because of possible toxicity and side effects, particularly fibrosis^[70]. A preoperative consultation with radiotherapists should be proposed, if not recommended, when different boost fields are considered.

Fifteen studies have reported the outcomes of patients with multiple ipsilateral synchronous breast cancer treated with BCT followed by whole-breast irradiation (WBI)^[11,31-33,66,71-79]. Most of these studies included patients treated for MF disease rather than MC disease

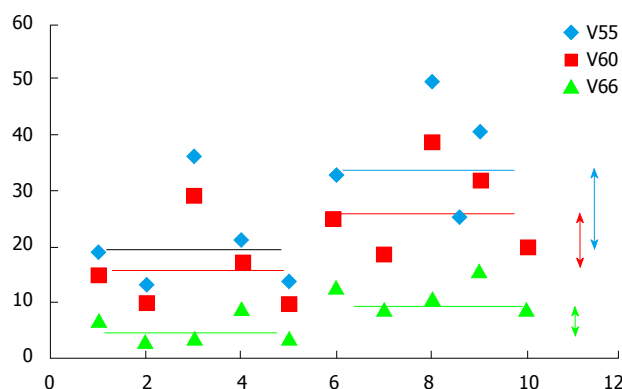


Figure 2 Volume of whole breast receiving an increased dose according to the dose-level. On the left side of the figure are reported the amount of breast receiving 66 Gy (green), 60 Gy (red) or 55 Gy (blue), in patients treated with a single boost (first 5 patients); on the right side of the figure are reported the amount of breast receiving 66 Gy, 60 Gy or 55 Gy, in patients treated with a double boost. The double arrows show the magnitude of increasing dose from single to double boost, according to dose level.

and the patients were mostly operated with a single incision and therefore a single field designed for the boost^[31-33,71,72]. BCT through double lumpectomy for MC disease raises the question of the safety of a double boost, regarding particularly the cosmetic result. Adding a boost after 50 Gy WBI increases the 10-year rate of severe fibrosis from 1.6% to 4.4% and of moderate fibrosis from 13% to 26%^[80]. Increasing the volume of the boost may increase this risk resulting in a poor cosmetic outcome, which is however the goal of BCT. This is the reason why we conducted a dosimetric study to assess the volume of breast receiving an increased dose, in patients treated in a classical manner (50 Gy-whole-breast + 16 Gy-single boost) and in patients treated with a double boost. The dose levels investigated were 110% and 120% of the prescribed dose (V55 and V60), and V66 as 66 Gy was the dose prescribed to each boost volume. Adding a second boost resulted in a 14%-increase of the volume of breast receiving more than 55 Gy, (from 19% to 33%), a 10%-increase of the volume of breast receiving more than 60 Gy, (from 15% to 25%) and a 2 Gy-increase in the mean dose received by the ipsilateral whole breast (Figures 1 and 2). The clinical significance of this increased dose is unknown but is expected to be real and deserves evaluation. An alternative could be an intraoperative boost, which would allow the preservation of the surrounding structures (normal tissues).

CONCLUSION

Conservative treatment is a reasonable option in selected cases of MF or MC tumors. Radiological workup and preoperative evaluation of all tumor sites are essential. A multidisciplinary discussion should be mandatory, especially for distant localizations, involving above all surgeons, radiologists and radiotherapists.

The selection of patients with low risk of recurrence

might be determined on the following criteria^[11,47,76]: (1) Technical feasibility, acceptable planned cosmetic result; (2) patient's choice after information about the risk of a new resection or mastectomy in cases of positive margins; (3) age > 40 years or > 50 years, absence of DCIS; (4) size of the largest lesion < 20 mm; and (5) feasibility of radiotherapy, including boost.

REFERENCES

- 1 **van la Parra RF**, de Roos WK, Contant CM, Bavelaar-Croon CD, Barneveld PC, Bosscha K. A prospective validation study of sentinel lymph node biopsy in multicentric breast cancer: SMMaC trial. *Eur J Surg Oncol* 2014; **40**: 1250-1255 [PMID: 24685336 DOI: 10.1016/j.ejso.2013.11.004]
- 2 **Ustaalioglu BO**, Bilici A, Kefeli U, Şeker M, Oncel M, Gezen C, Gumus M, Demirelli F. The importance of multifocal/multicentric tumor on the disease-free survival of breast cancer patients: single center experience. *Am J Clin Oncol* 2012; **35**: 580-586 [PMID: 21926901 DOI: 10.1097/COC.0b013e31822d9cd6]
- 3 **Vera-Badillo FE**, Napoleone M, Ocana A, Templeton AJ, Seruga B, Al-Mubarak M, AlHashem H, Tannock IF, Amir E. Effect of multifocality and multicentricity on outcome in early stage breast cancer: a systematic review and meta-analysis. *Breast Cancer Res Treat* 2014; **146**: 235-244 [PMID: 24928527 DOI: 10.1007/s10549-014-3018-3]
- 4 **Donker M**, Straver ME, van Tienhoven G, van de Velde CJ, Mansel RE, Litière S, Werutsky G, Duez NJ, Orzalesi L, Bouma WH, van der Mijle H, Nieuwenhuijzen GA, Velkamp SC, Helen Westenberg A, Rutgers EJ. Comparison of the sentinel node procedure between patients with multifocal and unifocal breast cancer in the EORTC 10981-22023 AMAROS Trial: identification rate and nodal outcome. *Eur J Cancer* 2013; **49**: 2093-2100 [PMID: 23522754 DOI: 10.1016/j.ejca.2013.02.017]
- 5 **Yerushalmi R**, Tyldesley S, Woods R, Kennecke HF, Speers C, Gelmon KA. Is breast-conserving therapy a safe option for patients with tumor multicentricity and multifocality? *Ann Oncol* 2012; **23**: 876-881 [PMID: 21810730 DOI: 10.1093/annonc/mdr326]
- 6 **Gallager HS**, Martin JE. The study of mammary carcinoma by mammography and whole organ sectioning. Early observations. *Cancer* 1969; **23**: 855-873 [PMID: 5775976]
- 7 **Holland R**, Veling SH, Mravunac M, Hendriks JH. Histologic multifocality of Tis, T1-2 breast carcinomas. Implications for clinical trials of breast-conserving surgery. *Cancer* 1985; **56**: 979-990 [PMID: 2990668]
- 8 **Coombs NJ**, Boyages J. Multifocal and multicentric breast cancer: does each focus matter? *J Clin Oncol* 2005; **23**: 7497-7502 [PMID: 16234516]
- 9 **Fowble B**, Yeh IT, Schultz DJ, Solin LJ, Rosato EF, Jardines L, Hoffman J, Eisenberg B, Weiss MC, Hanks G. The role of mastectomy in patients with stage I-II breast cancer presenting with gross multifocal or multicentric disease or diffuse microcalcifications. *Int J Radiat Oncol Biol Phys* 1993; **27**: 567-573 [PMID: 8226150]
- 10 **Eeles R**, Knee G, Jhavar S, Mangion J, Ebbs S, Gui G, Thomas S, Coppen M, A'hern R, Gray S, Cooper C, Bartek J, Yarnold J. Multicentric breast cancer: clonality and prognostic studies. *Breast Cancer Res Treat* 2011; **129**: 703-716 [PMID: 21080063 DOI: 10.1007/s10549-010-1230-3]
- 11 **Yerushalmi R**, Kennecke H, Woods R, Olivetto IA, Speers C, Gelmon KA. Does multicentric/multifocal breast cancer differ from unifocal breast cancer? An analysis of survival and contralateral breast cancer incidence. *Breast Cancer Res Treat* 2009; **117**: 365-370 [PMID: 19082705 DOI: 10.1007/s10549-008-0265-1]
- 12 **Egan RL**. Multicentric breast carcinomas: clinical-radiographic-pathologic whole organ studies and 10-year survival. *Cancer* 1982; **49**: 1123-1130 [PMID: 6277457]
- 13 **Wilkinson LS**, Given-Wilson R, Hall T, Potts H, Sharma AK, Smith E. Increasing the diagnosis of multifocal primary breast cancer by the use of bilateral whole-breast ultrasound. *Clin Radiol* 2005; **60**: 573-578 [PMID: 15851045]
- 14 **Sardanelli F**, Giuseppetti GM, Panizza P, Bazzocchi M, Fausto A, Simonetti G, Lattanzio V, Del Maschio A. Sensitivity of MRI versus mammography for detecting foci of multifocal, multicentric breast cancer in Fatty and dense breasts using the whole-breast pathologic examination as a gold standard. *AJR Am J Roentgenol* 2004; **183**: 1149-1157 [PMID: 15385322]
- 15 **Houssami N**, Ciatto S, Macaskill P, Lord SJ, Warren RM, Dixon JM, Irwig L. Accuracy and surgical impact of magnetic resonance imaging in breast cancer staging: systematic review and meta-analysis in detection of multifocal and multicentric cancer. *J Clin Oncol* 2008; **26**: 3248-3258 [PMID: 18474876 DOI: 10.1200/JCO.2007.15.2108]
- 16 **Fisher B**, Redmond C, Poisson R, Margolese R, Wolmark N, Wickerham L, Fisher E, Deutsch M, Caplan R, Pilch Y. Eight-year results of a randomized clinical trial comparing total mastectomy and lumpectomy with or without irradiation in the treatment of breast cancer. *N Engl J Med* 1989; **320**: 822-828 [PMID: 2927449]
- 17 **Veronesi U**, Saccozzi R, Del Vecchio M, Banfi A, Clemente C, De Lena M, Gallus G, Greco M, Luini A, Marubini E, Muscolino G, Rilke F, Salvadori B, Zecchini A, Zucali R. Comparing radical mastectomy with quadrantectomy, axillary dissection, and radiotherapy in patients with small cancers of the breast. *N Engl J Med* 1981; **305**: 6-11 [PMID: 7015141]
- 18 **Haffty BG**, Goldberg NB, Fischer D, McKhann C, Beinfeld M, Weissberg JB, Carter D, Gerald W. Conservative surgery and radiation therapy in breast carcinoma: local recurrence and prognostic implications. *Int J Radiat Oncol Biol Phys* 1989; **17**: 727-732 [PMID: 2777662]
- 19 **Solin LJ**, Fowble B, Martz KL, Goodman RL. Definitive irradiation for early stage breast cancer: The University of Pennsylvania experience. *Int J Radiat Oncol Biol Phys* 1988; **14**: 235-242 [PMID: 3276652]
- 20 **Stotter AT**, McNeese MD, Ames FC, Oswald MJ, Ellerbroek NA. Predicting the rate and extent of locoregional failure after breast conservation therapy for early breast cancer. *Cancer* 1989; **64**: 2217-2225 [PMID: 2553241]
- 21 **Recht A**, Silen W, Schnitt SJ, Connolly JL, Gelman RS, Rose MA, Silver B, Harris JR. Time-course of local recurrence following conservative surgery and radiotherapy for early stage breast cancer. *Int J Radiat Oncol Biol Phys* 1988; **15**: 255-261 [PMID: 2841261]
- 22 **Kurtz JM**, Amalric R, Brandone H, Ayme Y, Jacquemier J, Pietra JC, Hans D, Pollet JF, Bressac C, Spitalier JM. Local recurrence after breast-conserving surgery and radiotherapy. Frequency, time course, and prognosis. *Cancer* 1989; **63**: 1912-1917 [PMID: 2702564]
- 23 **Fourquet A**, Campana F, Zafrani B, Mosseri V, Vielh P, Durand JC, Vilcoq JR. Prognostic factors of breast recurrence in the conservative management of early breast cancer: a 25-year follow-up. *Int J Radiat Oncol Biol Phys* 1989; **17**: 719-725 [PMID: 2777661]
- 24 **Harris JR**, Recht A, Schnitt S, Connolly J, Silver B, Come S, Henderson IC. Current status of conservative surgery and radiotherapy as primary local treatment for early carcinoma of the breast. *Breast Cancer Res Treat* 1985; **5**: 245-255 [PMID: 3928002]
- 25 **Harris JR**, Recht A, Amalric R, Calle R, Clark RM, Reid JG, Spitalier JM, Vilcoq JR, Hellman S. Time course and prognosis of local recurrence following primary radiation therapy for early breast cancer. *J Clin Oncol* 1984; **2**: 37-41 [PMID: 6699656]
- 26 **Haffty BG**, Fischer D, Rose M, Beinfeld M, McKhann C. Prognostic factors for local recurrence in the conservatively treated breast cancer patient: a cautious interpretation of the data. *J Clin Oncol* 1991; **9**: 997-1003 [PMID: 2033434]
- 27 **Clark RM**, Wilkinson RH, Mahoney LJ, Reid JG, MacDonald WD. Breast cancer: a 21 year experience with conservative surgery and radiation. *Int J Radiat Oncol Biol Phys* 1982; **8**: 967-979 [PMID: 7107438]
- 28 **Mate TP**, Carter D, Fischer DB, Hartman PV, McKhann C, Merino M, Prosnitz LR, Weissberg JB. A clinical and histopathologic

- analysis of the results of conservation surgery and radiation therapy in stage I and II breast carcinoma. *Cancer* 1986; **58**: 1995-2002 [PMID: 3019514]
- 29 **Danoff BF**, Haller DG, Glick JH, Goodman RL. Conservative surgery and irradiation in the treatment of early breast cancer. *Ann Intern Med* 1985; **102**: 634-642 [PMID: 3885817]
- 30 **Winchester DP**, Cox JD. Standards for diagnosis and management of invasive breast carcinoma. American College of Radiology. American College of Surgeons. College of American Pathologists. Society of Surgical Oncology. *CA Cancer J Clin* 1998; **48**: 83-107 [PMID: 9522824]
- 31 **Kurtz JM**, Jacquemier J, Amalric R, Brandone H, Ayme Y, Hans D, Bressac C, Spitalier JM. Breast-conserving therapy for macroscopically multiple cancers. *Ann Surg* 1990; **212**: 38-44 [PMID: 2363602]
- 32 **Leopold KA**, Recht A, Schnitt SJ, Connolly JL, Rose MA, Silver B, Harris JR. Results of conservative surgery and radiation therapy for multiple synchronous cancers of one breast. *Int J Radiat Oncol Biol Phys* 1989; **16**: 11-16 [PMID: 2536361]
- 33 **Wilson LD**, Beinfeld M, McKhann CF, Haffty BG. Conservative surgery and radiation in the treatment of synchronous ipsilateral breast cancers. *Cancer* 1993; **72**: 137-142 [PMID: 8389664]
- 34 **Veronesi U**. NIH consensus meeting on early breast cancer. *Eur J Cancer* 1990; **26**: 843-844 [PMID: 2145909]
- 35 **Fisher B**, Anderson S. Conservative surgery for the management of invasive and noninvasive carcinoma of the breast: NSABP trials. National Surgical Adjuvant Breast and Bowel Project. *World J Surg* 1994; **18**: 63-69 [PMID: 8197778]
- 36 **Fisher B**, Anderson S, Redmond CK, Wolmark N, Wickerham DL, Cronin WM. Reanalysis and results after 12 years of follow-up in a randomized clinical trial comparing total mastectomy with lumpectomy with or without irradiation in the treatment of breast cancer. *N Engl J Med* 1995; **333**: 1456-1461 [PMID: 7477145]
- 37 **Clark RM**, McCulloch PB, Levine MN, Lipa M, Wilkinson RH, Mahoney LJ, Basrur VR, Nair BD, McDermot RS, Wong CS. Randomized clinical trial to assess the effectiveness of breast irradiation following lumpectomy and axillary dissection for node-negative breast cancer. *J Natl Cancer Inst* 1992; **84**: 683-689 [PMID: 1314910]
- 38 **Haffty BG**, Goldberg NB, Rose M, Heil B, Fischer D, Beinfeld M, McKhann C, Weissberg JB. Conservative surgery with radiation therapy in clinical stage I and II breast cancer. Results of a 20-year experience. *Arch Surg* 1989; **124**: 1266-1270 [PMID: 2818177]
- 39 **Jacobson JA**, Danforth DN, Cowan KH, d'Angelo T, Steinberg SM, Pierce L, Lippman ME, Lichter AS, Glatstein E, Okunieff P. Ten-year results of a comparison of conservation with mastectomy in the treatment of stage I and II breast cancer. *N Engl J Med* 1995; **332**: 907-911 [PMID: 7877647]
- 40 **Mansfield CM**, Komarnicky LT, Schwartz GF, Rosenberg AL, Krishnan L, Jewell WR, Rosato FE, Moses ML, Hagbin M, Taylor J. Ten-year results in 1070 patients with stages I and II breast cancer treated by conservative surgery and radiation therapy. *Cancer* 1995; **75**: 2328-2336 [PMID: 7712444]
- 41 **Sarrazin D**, Lê M, Rouëssé J, Contesso G, Petit JY, Lacour J, Viguier J, Hill C. Conservative treatment versus mastectomy in breast cancer tumors with macroscopic diameter of 20 millimeters or less. The experience of the Institut Gustave-Roussy. *Cancer* 1984; **53**: 1209-1213 [PMID: 6362840]
- 42 **Stehlin JS**, de Ipolyi PD, Greeff PJ, Gutierrez AE, Hardy RJ, Dahiya SL. A ten year study of partial mastectomy for carcinoma of the breast. *Surg Gynecol Obstet* 1987; **165**: 191-198 [PMID: 3629435]
- 43 **Recht A**. Selection of patients with early stage invasive breast cancer for treatment with conservative surgery and radiation therapy. *Semin Oncol* 1996; **23**: 19-30 [PMID: 8614842]
- 44 **Bartelink H**, Horiot JC, Poortmans P, Struikmans H, Van den Bogaert W, Barillot I, Fourquet A, Borger J, Jager J, Hoogenraad W, Collette L, Pierart M. Recurrence rates after treatment of breast cancer with standard radiotherapy with or without additional radiation. *N Engl J Med* 2001; **345**: 1378-1387 [PMID: 11794170]
- 45 **Schwartz GF**, Veronesi U, Clough KB, Dixon JM, Fentiman IS, Heywang-Köbrunner SH, Holland R, Hughes KS, Margolese R, Olivetto IA, Palazzo JP, Solin LJ. Proceedings of the Consensus Conference on Breast Conservation, April 28 to May 1, 2005, Milan, Italy. *Cancer* 2006; **107**: 242-250 [PMID: 16770785]
- 46 **Kurniawan ED**, Wong MH, Windle I, Rose A, Mou A, Buchanan M, Collins JP, Miller JA, Gruen RL, Mann GB. Predictors of surgical margin status in breast-conserving surgery within a breast screening program. *Ann Surg Oncol* 2008; **15**: 2542-2549 [PMID: 18618180 DOI: 10.1245/s10434-008-0054-4]
- 47 **Patani N**, Carpenter R. Oncological and aesthetic considerations of conservational surgery for multifocal/multicentric breast cancer. *Breast J* 2008; **16**: 222-232 [PMID: 20565467 DOI: 10.1111/j.1524-4741.2010.00917.x]
- 48 **Liberman L**, Morris EA, Kim CM, Kaplan JB, Abramson AF, Menell JH, Van Zee KJ, Dershaw DD. MR imaging findings in the contralateral breast of women with recently diagnosed breast cancer. *AJR Am J Roentgenol* 2003; **180**: 333-341 [PMID: 12540428]
- 49 **Liberman L**, Morris EA, Dershaw DD, Abramson AF, Tan LK. MR imaging of the ipsilateral breast in women with percutaneously proven breast cancer. *AJR Am J Roentgenol* 2003; **180**: 901-910 [PMID: 12646427]
- 50 **Houssami N**, Turner R, Morrow M. Preoperative magnetic resonance imaging in breast cancer: meta-analysis of surgical outcomes. *Ann Surg* 2013; **257**: 249-255 [PMID: 23187751 DOI: 10.1097/SLA.0b013e31827a8d17]
- 51 **Kuhl CK**. Current status of breast MR imaging. Part 2. Clinical applications. *Radiology* 2007; **244**: 672-691 [PMID: 17709824]
- 52 **Turnbull L**, Brown S, Harvey I, Olivier C, Drew P, Napp V, Hanby A, Brown J. Comparative effectiveness of MRI in breast cancer (COMICE) trial: a randomised controlled trial. *Lancet* 2010; **375**: 563-571 [PMID: 20159292 DOI: 10.1016/S0140-6736(09)62070-5]
- 53 **Peters NH**, van Esser S, van den Bosch MA, Storm RK, Plaisier PW, van Dalen T, Diepstraten SC, Weits T, Westenend PJ, Stapper G, Fernandez-Gallardo MA, Borel Rinkes IH, van Hillegersberg R, Mali WP, Peeters PH. Preoperative MRI and surgical management in patients with nonpalpable breast cancer: the MONET - randomised controlled trial. *Eur J Cancer* 2011; **47**: 879-886 [PMID: 21195605 DOI: 10.1016/j.ejca.2010.11.035]
- 54 **Sardanelli F**, Boetes C, Borisch B, Decker T, Federico M, Gilbert FJ, Helbich T, Heywang-Köbrunner SH, Kaiser WA, Kerin MJ, Mansel RE, Marotti L, Martincich L, Mauriac L, Meijers-Heijboer H, Orecchia R, Panizza P, Ponti A, Purushotham AD, Regitnig P, Del Turco MR, Thibault F, Wilson R. Magnetic resonance imaging of the breast: recommendations from the EUSOMA working group. *Eur J Cancer* 2010; **46**: 1296-1316 [PMID: 20304629 DOI: 10.1016/j.ejca.2010.02.015]
- 55 **Goyal A**, Newcombe RG, Mansel RE, Chetty U, Ell P, Fallowfield L, Kissin M, Sibbering M. Sentinel lymph node biopsy in patients with multifocal breast cancer. *Eur J Surg Oncol* 2004; **30**: 475-479 [PMID: 15135472]
- 56 **Ozmen V**, Muslumanoglu M, Cabioglu N, Tuzlali S, Ilhan R, Igci A, Kecer M, Bozfakioglu Y, Dagoglu T. Increased false negative rates in sentinel lymph node biopsies in patients with multi-focal breast cancer. *Breast Cancer Res Treat* 2002; **76**: 237-244 [PMID: 12462384]
- 57 **Meretoja TJ**, Leidenius MH, Heikkilä PS, Joensuu H. Sentinel node biopsy in breast cancer patients with large or multifocal tumors. *Ann Surg Oncol* 2009; **16**: 1148-1155 [PMID: 19242761 DOI: 10.1245/s10434-009-0397-5]
- 58 **Bergkvist L**, Frisell J, Liljegren G, Celebioglu F, Damm S, Thörn M. Multicentre study of detection and false-negative rates in sentinel node biopsy for breast cancer. *Br J Surg* 2001; **88**: 1644-1648 [PMID: 11736980]
- 59 **Kumar R**, Jana S, Heiba SI, Dakhel M, Axelrod D, Siegel B, Bernik S, Mills C, Wallack M, Abdel-Dayem HM. Retrospective analysis of sentinel node localization in multifocal, multicentric, palpable, or nonpalpable breast cancer. *J Nucl Med* 2003; **44**: 7-10 [PMID: 12515869]

- 60 **Tousimis E**, Van Zee KJ, Fey JV, Hoque LW, Tan LK, Cody HS, Borgen PI, Montgomery LL. The accuracy of sentinel lymph node biopsy in multicentric and multifocal invasive breast cancers. *J Am Coll Surg* 2003; **197**: 529-535 [PMID: 14522317]
- 61 **Spillane AJ**, Brennan ME. Accuracy of sentinel lymph node biopsy in large and multifocal/multicentric breast carcinoma--a systematic review. *Eur J Surg Oncol* 2011; **37**: 371-385 [PMID: 21292433 DOI: 10.1016/j.ejso.2011.01.011]
- 62 **Andea AA**, Wallis T, Newman LA, Bouwman D, Dey J, Visscher DW. Pathologic analysis of tumor size and lymph node status in multifocal/multicentric breast carcinoma. *Cancer* 2002; **94**: 1383-1390 [PMID: 11920492]
- 63 **Lynch SP**, Lei X, Hsu L, Meric-Bernstam F, Buchholz TA, Zhang H, Hortobágyi GN, Gonzalez-Angulo AM, Valero V. Breast cancer multifocality and multicentricity and locoregional recurrence. *Oncologist* 2013; **18**: 1167-1173 [PMID: 24136008 DOI: 10.1634/theoncologist.2013-0167]
- 64 **Wolters R**, Wöckel A, Janni W, Novopashenny I, Ebner F, Kreienberg R, Wischnewsky M, Schwentner L. Comparing the outcome between multicentric and multifocal breast cancer: what is the impact on survival, and is there a role for guideline-adherent adjuvant therapy? A retrospective multicenter cohort study of 8,935 patients. *Breast Cancer Res Treat* 2013; **142**: 579-590 [PMID: 24258258 DOI: 10.1007/s10549-013-2772-y]
- 65 **Weissenbacher TM**, Zschage M, Janni W, Jeschke U, Dimpfl T, Mayr D, Rack B, Schindlbeck C, Friese K, Dian D. Multicentric and multifocal versus unifocal breast cancer: is the tumor-node-metastasis classification justified? *Breast Cancer Res Treat* 2010; **122**: 27-34 [PMID: 20454925 DOI: 10.1007/s10549-010-0917-9]
- 66 **Chung AP**, Huynh K, Kidner T, Mirzadehgan P, Sim MS, Giuliano AE. Comparison of outcomes of breast conserving therapy in multifocal and unifocal invasive breast cancer. *J Am Coll Surg* 2012; **215**: 137-146; discussion 146-147 [PMID: 22608402 DOI: 10.1016/j.jamcollsurg.2012.05.006]
- 67 **Clough KB**, Kaufman GJ, Nos C, Buccimazza I, Sarfati IM. Improving breast cancer surgery: a classification and quadrant per quadrant atlas for oncoplastic surgery. *Ann Surg Oncol* 2010; **17**: 1375-1391 [PMID: 20140531 DOI: 10.1245/s10434-009-0792-y]
- 68 **Clough KB**, Ihrat T, Oden S, Kaufman G, Massey E, Nos C. Oncoplastic surgery for breast cancer based on tumour location and a quadrant-per-quadrant atlas. *Br J Surg* 2012; **99**: 1389-1395 [PMID: 22961518 DOI: 10.1002/bjs.8877]
- 69 **Clough KB**, Gouveia PF, Benyahi D, Massey EJ, Russ E, Sarfati I, Nos C. Positive Margins After Oncoplastic Surgery for Breast Cancer. *Ann Surg Oncol* 2015; **22**: 4247-4253 [PMID: 25893409 DOI: 10.1245/s10434-015-4514-3]
- 70 **Khan SA**. The many questions that surround multicentric and multifocal breast cancer. *Breast J* 2010; **16**: 219-221 [PMID: 20565466 DOI: 10.1111/j.1524-4741.2010.00929.x]
- 71 **Hartsell WF**, Recine DC, Griem KL, Cobleigh MA, Witt TR, Murthy AK. Should multicentric disease be an absolute contraindication to the use of breast-conserving therapy? *Int J Radiat Oncol Biol Phys* 1994; **30**: 49-53 [PMID: 8083128]
- 72 **Nos C**, Bourgeois D, Darles C, Asselain B, Campana F, Zafrani B, Durand JC, Clough K. [Conservative treatment of multifocal breast cancer: a comparative study]. *Bull Cancer* 1999; **86**: 184-188 [PMID: 10066949]
- 73 **Cho LC**, Senzer N, Peters GN. Conservative surgery and radiation therapy for macroscopically multiple ipsilateral invasive breast cancers. *Am J Surg* 2002; **183**: 650-654 [PMID: 12095594]
- 74 **Kaplan J**, Giron G, Tartter PI, Bleiweiss JJ, Estabrook A, Smith SR. Breast conservation in patients with multiple ipsilateral synchronous cancers. *J Am Coll Surg* 2003; **197**: 726-729 [PMID: 14585405]
- 75 **Okumura S**, Mitsumori M, Yamauchi C, Kawamura S, Oya N, Nagata Y, Hiraoka M, Kokubo M, Mise K, Kodama H. Feasibility of breast-conserving therapy for macroscopically multiple ipsilateral breast cancer. *Int J Radiat Oncol Biol Phys* 2004; **59**: 146-151 [PMID: 15093910]
- 76 **Gentilini O**, Botteri E, Rotmensz N, Da Lima L, Caliskan M, Garcia-Etienne CA, Sosnovskikh I, Intra M, Mazzarol G, Musmeci S, Veronesi P, Galimberti V, Luini A, Viale G, Goldhirsch A, Veronesi U. Conservative surgery in patients with multifocal/multicentric breast cancer. *Breast Cancer Res Treat* 2009; **113**: 577-583 [PMID: 18330695 DOI: 10.1007/s10549-008-9959-7]
- 77 **Kapoor NS**, Chung A, Huynh K, Giuliano AE. Preliminary results: double lumpectomies for multicentric breast carcinoma. *Am Surg* 2012; **78**: 1345-1348 [PMID: 23265123]
- 78 **Zervoudis S**, Iatrakis G, Mares P, Boileau L, Grammatikakis I, Evangelinakis N, Daures JP, Leteuff I, Avgouleas A, Stefanos T, Navrozoglou I. Breast conserving surgery in multicentric breast cancer, preliminary data of our experience. *Eur J Gynaecol Oncol* 2014; **35**: 530-534 [PMID: 25507421]
- 79 **Neri A**, Marrelli D, Megha T, Bettarini F, Tacchini D, De Franco L, Roviello F. "Clinical significance of multifocal and multicentric breast cancers and choice of surgical treatment: a retrospective study on a series of 1158 cases". *BMC Surg* 2015; **15**: 1 [PMID: 25586679 DOI: 10.1186/1471-2482-15-1]
- 80 **Bartelink H**, Horiot JC, Poortmans PM, Struikmans H, Van den Bogaert W, Fourquet A, Jager JJ, Hoogenraad WJ, Oei SB, Wárlám-Rodenhuis CC, Pierart M, Collette L. Impact of a higher radiation dose on local control and survival in breast-conserving therapy of early breast cancer: 10-year results of the randomized boost versus no boost EORTC 22881-10882 trial. *J Clin Oncol* 2007; **25**: 3259-3265 [PMID: 17577015]
- 81 National Institutes of Health Consensus Development Conference Statement: Adjuvant Chemotherapy for Breast Cancer. September 9-11, 1985. *CA Cancer J Clin* 1985; **36**: 42-47 [PMID: 3080207]
- 82 **Vlastos G**, Rubio IT, Mirza NQ, Newman LA, Aurora R, Alderfer J, Buzdar AU, Singletary SE. Impact of multicentricity on clinical outcome in patients with T1-2, N0-1, M0 breast cancer. *Ann Surg Oncol* 2000; **7**: 581-587 [PMID: 11005556]
- 83 **Katz A**, Strom EA, Buchholz TA, Theriault R, Singletary SE, McNeese MD. The influence of pathologic tumor characteristics on locoregional recurrence rates following mastectomy. *Int J Radiat Oncol Biol Phys* 2001; **50**: 735-742 [PMID: 11395242]
- 84 **Pedersen L**, Gunnarsdottir KA, Rasmussen BB, Moeller S, Lanng C. The prognostic influence of multifocality in breast cancer patients. *Breast* 2004; **13**: 188-193 [PMID: 15177420]
- 85 **Early Breast Cancer Trialists' Collaborative G**. Effects of chemotherapy and hormonal therapy for early breast cancer on recurrence and 15-year survival: an overview of the randomised trials. *Lancet* 2005; **365**: 1687-1717 [PMID: 15894097]
- 86 **Litton JK**, Eralp Y, Gonzalez-Angulo AM, Broglio K, Uyei A, Hortobágyi GN, Arun B. Multifocal breast cancer in women < 35 years old. *Cancer* 2007; **110**: 1445-1450 [PMID: 17676585]
- 87 **Joergensen LE**, Gunnarsdottir KA, Lanng C, Moeller S, Rasmussen BB. Multifocality as a prognostic factor in breast cancer patients registered in Danish Breast Cancer Cooperative Group (DBCG) 1996-2001. *Breast* 2008; **17**: 587-591 [PMID: 18691887 DOI: 10.1016/j.breast.2008.06.004]
- 88 **Cabioglu N**, Ozmen V, Kaya H, Tuzlali S, Igci A, Muslumanoglu M, Keer M, Dagoglu T. Increased lymph node positivity in multifocal and multicentric breast cancer. *J Am Coll Surg* 2009; **208**: 67-74 [PMID: 19228505 DOI: 10.1016/j.jamcollsurg.2008.09.001]
- 89 **Tot T**, Gere M, Pekár G, Tarján M, Hofmeyer S, Hellberg D, Lindquist D, Chen TH, Yen AM, Chiu SY, Tabár L. Breast cancer multifocality, disease extent, and survival. *Hum Pathol* 2011; **42**: 1761-1769 [PMID: 21663941 DOI: 10.1016/j.humphath.2011.02.002]
- 90 **Tot T**, Pekár G. Multifocality in "basal-like" breast carcinomas and its influence on lymph node status. *Ann Surg Oncol* 2011; **18**: 1671-1677 [PMID: 21161724 DOI: 10.1245/s10434-010-1480-7]
- 91 **Rezo A**, Dahlstrom J, Shadbolot B, Rodins K, Zhang Y, Davis AJ. Tumor size and survival in multicentric and multifocal breast cancer. *Breast* 2011; **20**: 259-263 [PMID: 21324695 DOI: 10.1016/j.breast.2011.01.005]
- 92 **Meretoja TJ**, Leidenius MH, Heikkilä PS, Boross G, Seiben I, Regitnig P, Luschin-Ebengreuth G, Žgajnar J, Perhavec A, Gazic B, Lázár G, Takács T, Vörös A, Saidan ZA, Nadeem RM, Castellano I, Sapino A, Bianchi S, Vezzosi V, Barranger E, Lousquy R, Arisio

- R, Foschini MP, Imoto S, Kamma H, Tvedskov TF, Kroman N, Jensen MB, Audisio RA, Cserni G. International multicenter tool to predict the risk of nonsentinel node metastases in breast cancer. *J Natl Cancer Inst* 2012; **104**: 1888-1896 [PMID: 23117131 DOI: 10.1093/jnci/djs455]
- 93 **Pekar G**, Hofmeyer S, Tabár L, Tarján M, Chen TH, Yen AM, Chiu SY, Hellberg D, Gere M, Tot T. Multifocal breast cancer documented in large-format histology sections: long-term follow-up results by molecular phenotypes. *Cancer* 2013; **119**: 1132-1139 [PMID: 23279980 DOI: 10.1002/cncr.27877]
- 94 **Hilton JF**, Bouganim N, Dong B, Chapman JW, Arnaout A, O' Malley F, Gelmon KA, Yerushalmi R, Levine MN, Bramwell VH, Whelan TJ, Pritchard KI, Shepherd LE, Clemons M. Do alternative methods of measuring tumor size, including consideration of multicentric/multifocal disease, enhance prognostic information beyond TNM staging in women with early stage breast cancer: an analysis of the NCIC CTG MA.5 and MA.12 clinical trials. *Breast Cancer Res Treat* 2013; **142**: 143-151 [PMID: 24113743 DOI: 10.1007/s10549-013-2714-8]
- 95 **van der Heiden-van der Loo M**, Schaapveld M, Ho VK, Siesling S, Rutgers EJ, Peeters PH. Outcomes of a population-based series of early breast cancer patients with micrometastases and isolated tumour cells in axillary lymph nodes. *Ann Oncol* 2013; **24**: 2794-2801 [PMID: 23864096 DOI: 10.1093/annonc/mdt243]
- 96 **Oh JL**, Dryden MJ, Woodward WA, Yu TK, Tereffe W, Strom EA, Perkins GH, Middleton L, Hunt KK, Giordano SH, Oswald MJ, Domain D, Buchholz TA. Locoregional control of clinically diagnosed multifocal or multicentric breast cancer after neoadjuvant chemotherapy and locoregional therapy. *J Clin Oncol* 2006; **24**: 4971-4975 [PMID: 17075114]
- 97 **Lim W**, Park EH, Choi SL, Seo JY, Kim HJ, Chang MA, Ku BK, Son B, Ahn SH. Breast conserving surgery for multifocal breast cancer. *Ann Surg* 2009; **249**: 87-90 [PMID: 19106681 DOI: 10.1097/SLA.0b013e31818e41c0]
- 98 **Bauman L**, Barth RJ, Rosenkranz KM. Breast conservation in women with multifocal-multicentric breast cancer: is it feasible? *Ann Surg Oncol* 2010; **17** Suppl 3: 325-329 [PMID: 20853054 DOI: 10.1245/s10434-010-1247-1]
- 99 **Kadioğlu H**, Yücel S, Yildiz S, Bozkurt S, Ersoy YE, Sağlam E, Müslümanoğlu M. Feasibility of breast conserving surgery in multifocal breast cancers. *Am J Surg* 2014; **208**: 457-464 [PMID: 24112680 DOI: 10.1016/j.amjsurg.2013.08.008]

P- Reviewer: Johnson N, Rubio IT

S- Editor: Ji FF **L- Editor:** A **E- Editor:** Li D





Published by **Baishideng Publishing Group Inc**

8226 Regency Drive, Pleasanton, CA 94588, USA

Telephone: +1-925-223-8242

Fax: +1-925-223-8243

E-mail: bpgoffice@wjgnet.com

Help Desk: <http://www.wjgnet.com/esps/helpdesk.aspx>

<http://www.wjgnet.com>

