

# World Journal of *Clinical Cases*

*World J Clin Cases* 2022 January 7; 10(1): 1-396



## Contents

Weekly Volume 10 Number 1 January 7, 2022

## MINIREVIEWS

- 1      Omicron variant (B.1.1.529) of SARS-CoV-2: Mutation, infectivity, transmission, and vaccine resistance  
*Ren SY, Wang WB, Gao RD, Zhou AM*
- 12     Hepatitis B virus reactivation in rheumatoid arthritis  
*Wu YL, Ke J, Zhang BY, Zhao D*
- 23     Paradoxical role of interleukin-33/suppressor of tumorigenicity 2 in colorectal carcinogenesis: Progress and therapeutic potential  
*Huang F, Chen WY, Ma J, He XL, Wang JW*

## ORIGINAL ARTICLE

## Case Control Study

- 35      Changes in rheumatoid arthritis under ultrasound before and after sinomenine injection  
*Huang YM, Zhuang Y, Tan ZM*
- 43      Benefits of multidisciplinary collaborative care team-based nursing services in treating pressure injury wounds in cerebral infarction patients  
*Gu YH, Wang X, Sun SS*

## Retrospective Study

- 51      Outcomes and complications of open, laparoscopic, and hybrid giant ventral hernia repair  
*Yang S, Wang MG, Nie YS, Zhao XF, Liu J*
- 62      Surgical resection of intradural extramedullary tumors in the atlantoaxial spine *via* a posterior approach  
*Meng DH, Wang JQ, Yang KX, Chen WY, Pan C, Jiang H*
- 71      Vancomycin lavage for the incidence of acute surgical site infection following primary total hip arthroplasty and total knee arthroplasty  
*Duan MY, Zhang HZ*
- 79      Distribution of transient receptor potential vanilloid-1 channels in gastrointestinal tract of patients with morbid obesity  
*Atas U, Erin N, Tazegul G, Elpek GO, Yıldırım B*
- 91      Value of neutrophil-lymphocyte ratio in evaluating response to percutaneous catheter drainage in patients with acute pancreatitis  
*Gupta P, Das GC, Bansal A, Samanta J, Mandavdhare HS, Sharma V, Naseem S, Gupta V, Yadav TD, Dutta U, Varma N, Sandhu MS, Kochhar R*

- 104** Influence of overweight and obesity on the mortality of hospitalized patients with community-acquired pneumonia  
*Wang N, Liu BW, Ma CM, Yan Y, Su QW, Yin FZ*
- 117** Minimally invasive open reduction of greater tuberosity fractures by a modified suture bridge procedure  
*Kong LP, Yang JJ, Wang F, Liu FX, Yang YL*
- 128** Increased levels of lactate dehydrogenase and hypertension are associated with severe illness of COVID-19  
*Jin ZM, Shi JC, Zheng M, Chen QL, Zhou YY, Cheng F, Cai J, Jiang XG*
- 136** Age, alcohol, sex, and metabolic factors as risk factors for colonic diverticulosis  
*Yan Y, Wu JS, Pan S*
- 143** Evaluation of right-to-left shunt on contrast-enhanced transcranial Doppler in patent foramen ovale-related cryptogenic stroke: Research based on imaging  
*Xiao L, Yan YH, Ding YF, Liu M, Kong LJ, Hu CH, Hui PJ*
- 155** Characterization of focal hypermetabolic thyroid incidentaloma: An analysis with F-18 fluorodeoxyglucose positron emission tomography/computed tomography parameters  
*Lee H, Chung YS, Lee JH, Lee KY, Hwang KH*

### Clinical Trials Study

- 166** Low-dose intralesional injection of 5-fluorouracil and triamcinolone reduces tissue resident memory T cells in chronic eczema  
*Wu Y, Wang GJ, He HQ, Qin HH, Shen WT, Yu Y, Zhang X, Zhou ML, Fei JB*

### Observational Study

- 177** Alterations in blink and masseter reflex latencies in older adults with neurocognitive disorder and/or diabetes mellitus  
*Bricio-Barrios JA, Rios-Bracamontes E, Rios-Silva M, Huerta M, Serrano-Moreno W, Barrios-Navarro JE, Ortiz GG, Huerta-Trujillo M, Guzmán-Esquivel J, Trujillo X*
- 189** Predicting adolescent perfectionism: The role of socio-demographic traits, personal relationships, and media  
*Livazović G, Kuzmanović K*
- 205** Novel m.4268T>C mutation in the mitochondrial tRNA<sup>Leu</sup> gene is associated with hearing loss in two Chinese families  
*Zhao LJ, Zhang ZL, Fu Y*
- 217** Superior mesenteric venous thrombosis: Endovascular management and outcomes  
*Alnahhal K, Toskich BB, Nussbaum S, Li Z, Erben Y, Hakaim AG, Farres H*

### Randomized Controlled Trial

- 227** Zinc carnosine-based modified bismuth quadruple therapy *vs* standard triple therapy for *Helicobacter pylori* eradication: A randomized controlled study  
*Ibrahim N, El Said H, Choukair A*

## CASE REPORT

- 236** Acquired coagulation dysfunction resulting from vitamin K-dependent coagulation factor deficiency associated with rheumatoid arthritis: A case report  
*Huang YJ, Han L, Li J, Chen C*
- 242** Intraoperative thromboelastography-guided transfusion in a patient with factor XI deficiency: A case report  
*Guo WJ, Chen WY, Yu XR, Shen L, Huang YG*
- 249** Positron emission tomography and magnetic resonance imaging combined with computed tomography in tumor volume delineation: A case report  
*Zhou QP, Zhao YH, Gao L*
- 254** Successful response to camrelizumab in metastatic bladder cancer: A case report  
*Xie C, Yuan X, Chen SH, Liu ZY, Lu DL, Xu F, Chen ZQ, Zhong XM*
- 260** HER2 changes to positive after neoadjuvant chemotherapy in breast cancer: A case report and literature review  
*Wang L, Jiang Q, He MY, Shen P*
- 268** Hyper-accuracy three-dimensional reconstruction as a tool for better planning of retroperitoneal liposarcoma resection: A case report  
*Ye MS, Wu HK, Qin XZ, Luo F, Li Z*
- 275** Recurrent postmenopausal bleeding - just endometrial disease or ovarian sex cord-stromal tumor? A case report  
*Wang J, Yang Q, Zhang NN, Wang DD*
- 283** Complex proximal femoral fracture in a young patient followed up for 3 years: A case report  
*Li ZY, Cheng WD, Qi L, Yu SS, Jing JH*
- 289** Bilateral Hypertrophic Olivary Degeneration after Pontine Hemorrhage: A Case Report  
*Zheng B, Wang J, Huang XQ, Chen Z, Gu GF, Luo XJ*
- 296** Clinical characteristics and outcomes of primary intracranial alveolar soft-part sarcoma: A case report  
*Chen JY, Cen B, Hu F, Qiu Y, Xiao GM, Zhou JG, Zhang FC*
- 304** Removal of laparoscopic cerclage stitches *via* laparotomy and rivanol-induced labour: A case report and literature review  
*Na XN, Cai BS*
- 309** Cerebral venous sinus thrombosis in pregnancy: A case report  
*Zhou B, Huang SS, Huang C, Liu SY*
- 316** Eustachian tube teratoma: A case report  
*Li JY, Sun LX, Hu N, Song GS, Dou WQ, Gong RZ, Li CT*

- 323** Protein-losing enteropathy caused by a jejunal ulcer after an internal hernia in Petersen's space: A case report  
*Yasuda T, Sakurazawa N, Kuge K, Omori J, Arai H, Kakinuma D, Watanabe M, Suzuki H, Iwakiri K, Yoshida H*
- 331** Lunate dislocation with avulsed triquetral fracture: A case report  
*Li LY, Lin CJ, Ko CY*
- 338** Clinical manifestations and prenatal diagnosis of Ullrich congenital muscular dystrophy: A case report  
*Hu J, Chen YH, Fang X, Zhou Y, Chen F*
- 345** Diagnosis and guidance of treatment of breast cancer cutaneous metastases by multiple needle biopsy: A case report  
*Li ZH, Wang F, Zhang P, Xue P, Zhu SJ*
- 353** Test of incremental respiratory endurance as home-based, stand-alone therapy in chronic obstructive pulmonary disease: A case report  
*Dosbaba F, Hartman M, Batalik L, Brat K, Plutinsky M, Hnatiak J, Formiga MF, Cahalin LP*
- 361** Diagnostic and surgical challenges of progressive neck and upper back painless masses in Madelung's disease: A case report and review of literature  
*Yan YJ, Zhou SQ, Li CQ, Ruan Y*
- 371** Suspected cerebrovascular air embolism during endoscopic esophageal varices ligation under sedation with fatal outcome: A case report  
*Zhang CMJ, Wang X*
- 381** An atypical primary malignant melanoma arising from the cervical nerve root: A case report and review of literature  
*Shi YF, Chen YQ, Chen HF, Hu X*
- 388** Epidural blood patch for spontaneous intracranial hypotension with subdural hematoma: A case report and review of literature  
*Choi SH, Lee YY, Kim WJ*

**ABOUT COVER**

Editorial Board Member of *World Journal of Clinical Cases*, Ravi Kant, MD, Associate Professor, Division of Endocrinology, Diabetes and Metabolism, Medical University of South Carolina/Anmed Campus, Anderson, SC 29621, United States. rkant82@hotmail.com

**AIMS AND SCOPE**

The primary aim of *World Journal of Clinical Cases* (WJCC, *World J Clin Cases*) is to provide scholars and readers from various fields of clinical medicine with a platform to publish high-quality clinical research articles and communicate their research findings online.

WJCC mainly publishes articles reporting research results and findings obtained in the field of clinical medicine and covering a wide range of topics, including case control studies, retrospective cohort studies, retrospective studies, clinical trials studies, observational studies, prospective studies, randomized controlled trials, randomized clinical trials, systematic reviews, meta-analysis, and case reports.

**INDEXING/ABSTRACTING**

The WJCC is now indexed in Science Citation Index Expanded (also known as SciSearch®), Journal Citation Reports/Science Edition, Scopus, PubMed, and PubMed Central. The 2021 Edition of Journal Citation Reports® cites the 2020 impact factor (IF) for WJCC as 1.337; IF without journal self cites: 1.301; 5-year IF: 1.742; Journal Citation Indicator: 0.33; Ranking: 119 among 169 journals in medicine, general and internal; and Quartile category: Q3. The WJCC's CiteScore for 2020 is 0.8 and Scopus CiteScore rank 2020: General Medicine is 493/793.

**RESPONSIBLE EDITORS FOR THIS ISSUE**

Production Editor: Lin-YuTong Wang; Production Department Director: Xiang Li; Editorial Office Director: Jin-Lai Wang.

**NAME OF JOURNAL**

*World Journal of Clinical Cases*

**ISSN**

ISSN 2307-8960 (online)

**LAUNCH DATE**

April 16, 2013

**FREQUENCY**

Weekly

**EDITORS-IN-CHIEF**

Bao-Gan Peng

**EDITORIAL BOARD MEMBERS**

<https://www.wjgnet.com/2307-8960/editorialboard.htm>

**PUBLICATION DATE**

January 7, 2022

**COPYRIGHT**

© 2022 Baishideng Publishing Group Inc

**INSTRUCTIONS TO AUTHORS**

<https://www.wjgnet.com/bpg/gerinfo/204>

**GUIDELINES FOR ETHICS DOCUMENTS**

<https://www.wjgnet.com/bpg/GerInfo/287>

**GUIDELINES FOR NON-NATIVE SPEAKERS OF ENGLISH**

<https://www.wjgnet.com/bpg/gerinfo/240>

**PUBLICATION ETHICS**

<https://www.wjgnet.com/bpg/GerInfo/288>

**PUBLICATION MISCONDUCT**

<https://www.wjgnet.com/bpg/gerinfo/208>

**ARTICLE PROCESSING CHARGE**

<https://www.wjgnet.com/bpg/gerinfo/242>

**STEPS FOR SUBMITTING MANUSCRIPTS**

<https://www.wjgnet.com/bpg/GerInfo/239>

**ONLINE SUBMISSION**

<https://www.f6publishing.com>

## Observational Study

## Superior mesenteric venous thrombosis: Endovascular management and outcomes

Khaled Alnahhal, Beau B Toskich, Samuel Nussbaum, Zhuo Li, Young Erben, Albert G Hakaim, Houssam Farres

**ORCID number:** Khaled Alnahhal 0000-0002-6387-0180; Beau B Toskich 0000-0002-3193-9737; Samuel Nussbaum 0000-0003-0664-5224; Zhuo Li 0000-0003-0839-7236; Young Erben 0000-0002-1571-6955; Albert G Hakaim 0000-0001-7805-8323; Houssam Farres 0000-0002-5740-1601.

**Author contributions:** Alnahhal K, Nussbaum S, and Farres H designed the study; Alnahhal K, Nussbaum S, and Li Z participated in the acquisition, analysis, and interpretation of the data, and drafted the initial manuscript; Toskich BB, Erben YM, Hakaim AG, and Farres H revised the article critically for important intellectual content.

**Institutional review board statement:** The study was reviewed and approved by the Mayo Clinic Institutional Review Board (Approval No. 19-005202).

**Informed consent statement:** Patients were not required to give informed consent to the study because the analysis used anonymous clinical data that were obtained after each patient agreed to treatment by written consent.

**Conflict-of-interest statement:** All authors declare that there are no

**Khaled Alnahhal, Samuel Nussbaum, Young Erben, Albert G Hakaim, Houssam Farres,** Department of Surgery, Division of Vascular Surgery, Mayo Clinic Florida, Jacksonville, FL 32224, United States

**Beau B Toskich,** Department of Radiology, Mayo Clinic Florida, Jacksonville, FL 32224, United States

**Zhuo Li,** Department of Biostatistics, Mayo Clinic Florida, Jacksonville, FL 32224, United States

**Corresponding author:** Houssam Farres, MD, Doctor, Surgeon, Department of Surgery, Division of Vascular Surgery, Mayo Clinic Florida, 4500 San Pablo Road South, Jacksonville, FL 32224, United States. [farres.houssam@mayo.edu](mailto:farres.houssam@mayo.edu)

## Abstract

## BACKGROUND

Superior mesenteric venous thrombosis (SMVT) is a rare but fatal condition that is typically treated initially with anticoagulation therapy, and if this fails, with endovascular interventions. However, due to its rarity, there are not many studies that have explored the effectiveness of anticoagulation and endovascular therapies in treating SMVT.

## AIM

To evaluate patients diagnosed with SMVT who received endovascular therapy in addition to anticoagulation and report technical and clinical outcomes.

## METHODS

A retrospective analysis of the patients who underwent endovascular treatment for SMVT at Mayo Clinic from 2000-2019 was performed. Technical success was defined as angiographic improvement in SMV flow after intervention. Primary patency was defined as the interval from reestablishing mesenteric venous flow until the first repeat thrombotic event or need for additional intervention. Secondary patency was defined as successful restoration of flow after repeat intervention until rethrombosis or last follow-up. The adverse events were reported through Clavien-Dindo classification.

## RESULTS

potential conflicts of interest with respect to the research, authorship, and/or publication of this article.

**Data sharing statement:** No additional data are available.

**STROBE statement:** The authors have read the STROBE Statement—checklist of items, and the manuscript was prepared and revised according to the STROBE Statement—checklist of items.

**Country/Territory of origin:** United States

**Specialty type:** Radiology, nuclear medicine and medical imaging

**Provenance and peer review:** Unsolicited article; Externally peer reviewed.

**Peer-review model:** Single blind

**Peer-review report's scientific quality classification**

Grade A (Excellent): 0  
Grade B (Very good): B, B  
Grade C (Good): C  
Grade D (Fair): D  
Grade E (Poor): 0

**Open-Access:** This article is an open-access article that was selected by an in-house editor and fully peer-reviewed by external reviewers. It is distributed in accordance with the Creative Commons Attribution NonCommercial (CC BY-NC 4.0) license, which permits others to distribute, remix, adapt, build upon this work non-commercially, and license their derivative works on different terms, provided the original work is properly cited and the use is non-commercial. See: <http://creativecommons.org/licenses/by-nc/4.0/>

**Received:** July 16, 2021

**Peer-review started:** July 16, 2021

**First decision:** August 19, 2021

**Revised:** September 5, 2021

**Accepted:** November 28, 2021

**Article in press:** November 28, 2021

**Published online:** January 7, 2022

**P-Reviewer:** Dias E, Han IW, Wang X

**S-Editor:** Yan JP

Twenty-four patients were included for analysis. The median age at intervention was 60 years (35-74 years) and 16 (67%) were men. Nineteen patients presented with acute thrombosis (79.2%) and 5 with chronic thrombosis with acute manifestations (20.8%). The most commonly used endovascular modalities were thrombectomy in 12 patients (50.0%) and catheter-directed thrombolysis in 10 patients (41.7%). Technical success was achieved in 18 patients (75%). The 14-d and 30-d primary patency rates were 88.9% and 83.3%, respectively. Adverse events were reported in two patients (8.3%), one marked as grade IIIB, and 1 death marked as grade V. Five-year overall survival rate was 82% (58%-100%).

## CONCLUSION

Endovascular intervention with anticoagulation appears to be effective for managing SMVT. This treatment combination may be considered as first-line therapy for SMVT management in select patients.

**Key Words:** Superior mesenteric venous thrombosis; Endovascular; Anticoagulation; Retrospective; Thrombectomy; Mesenteric; Thrombolysis

©The Author(s) 2022. Published by Baishideng Publishing Group Inc. All rights reserved.

**Core Tip:** Superior mesenteric venous thrombosis (SMVT) is a rare condition with a high mortality rate of up to 23%. In our retrospective study, we investigated the use of endovascular treatments after anticoagulation therapies had failed on patients diagnosed with SMVT. By looking at the technical success and patency rates after intervention, we evaluated the effectiveness of these endovascular interventions.

**Citation:** Alnahhal K, Toskich BB, Nussbaum S, Li Z, Erben Y, Hakaim AG, Farres H. Superior mesenteric venous thrombosis: Endovascular management and outcomes. *World J Clin Cases* 2022; 10(1): 217-226

**URL:** <https://www.wjgnet.com/2307-8960/full/v10/i1/217.htm>

**DOI:** <https://dx.doi.org/10.12998/wjcc.v10.i1.217>

## INTRODUCTION

Acute mesenteric venous thrombosis accounts for 6% to 9% of mesenteric ischemia cases and 1 in 5000 to 15000 hospital admissions[1-3]. Superior mesenteric venous thrombosis (SMVT) is a rare condition but portends a mortality rate of up to 23%[4]. Risk factors for SMVT include hypercoagulable states, intra-abdominal surgery, infection, inflammation, and malignancy.

Systemic anticoagulation in addition to laparotomy for presentations with peritonitis represent conventional approaches to treating SMVT[3,5,6]. Endovascular therapy, such as thrombolysis and/or thrombectomy, is typically used as adjunctive treatment when medical management has failed. To date, most studies that explore endovascular treatment of SMVT have been case reports and small case series. More information regarding this treatment is needed.

This study aims to report on this rare condition to expand the literature base and evaluate the endovascular therapies effects on technical and clinical outcomes on 24 patients diagnosed with SMVT from a large tri-center institution.

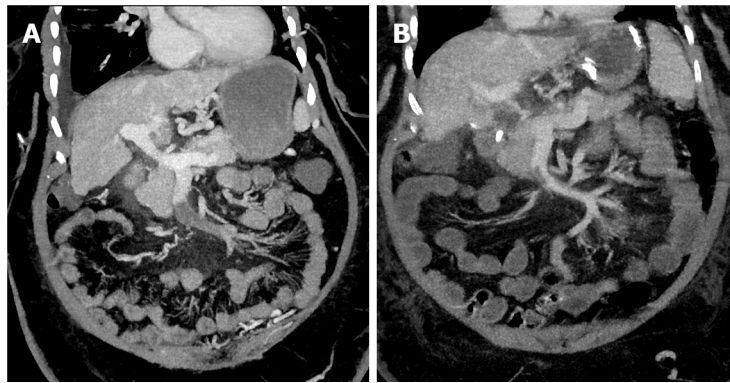
## MATERIALS AND METHODS

### Study design

A retrospective search of the Mayo Clinic Health System electronic medical record and imaging report archive was performed. All patients age 18 years and older who were diagnosed with isolated SMVT or SMVT combined with portal vein thrombosis as an inpatient and underwent both medical and endovascular treatment between January 2000 and December 2019 were included for analysis. Patients were excluded if they did

L-Editor: Filipodia

P-Editor: Yan JP



**Figure 1 Coronal portal venous phase computed tomography demonstrating a cirrhotic liver with ascites, varices, and superior mesenteric vein thrombosis.** Anticoagulation was discontinued due to upper gastrointestinal hemorrhage. As such, the patient underwent endovascular interventions. A: Before the thrombectomy and transjugular intrahepatic portosystemic shunt clinical target volume interventions; B: Post-intervention.

not have sufficient follow-up data of at least 1 mo. Patients with peritonitis were not included in this study as these patients are taken to an operating room and would not undergo endovascular treatment. Twenty-four patients were identified and met our criteria. Patient demographics, presenting symptoms, date of symptom onset, risk factors for SMVT admission and endovascular intervention, endovascular modality(s), technical and clinical outcomes, patency rates, and length of stay. The adverse events were evaluated and reported per Clavien-Dindo classification. The follow-up was until last clinical note recorded in the patients' medical record.

### **Interventional procedures**

Endovascular therapy was initiated after failure of systemic anticoagulation, determined by a lack of clinical improvement (Figure 1). The anticoagulation management was unfractionated heparin or low-molecular-weight heparin started at the time of diagnosis. Percutaneous transhepatic and/or transjugular approaches were used for all interventions. The selection between approaches was operator dependent.

Pharmacomechanical thrombectomy was performed in most patients who underwent thrombectomy using either rheolysis (AngioJet, Boston Scientific Corporation) or aspiration thrombectomy (Penumbra CAT 8 device, Penumbra Inc.). Catheter-directed thrombolysis (CDT) was performed using a multiple side-hole infusion catheter that extended into the thrombosed SMV. Tissue plasminogen activator was used as thrombolytic agent that initiated at an infusion rate of 0.5-1 mg/h in most patients who underwent thrombolysis for a duration ranging from 24 to 72 h with a low-dose heparin infusion at a standard rate of 500 units/h. Other endovascular techniques were employed when lysis and thrombectomy alone were insufficient including transjugular intrahepatic portosystemic shunt creation (TIPS), which was used if there was significant residual underlying portal hypertension after thrombectomy (portal pressure gradient > 12 mmHg) or if there was evidence of rethrombosis related to poor intrahepatic portal perfusion; balloon angioplasty, and self-expanding or balloon-expandable stents were deployed when a persistent flow-limiting lesion (> 50% stenosis) was present after angioplasty.

### **Study end points and definitions**

The end points of the study were to determine both the short- and long-term technical success, and the clinical outcomes of using the endovascular therapeutic options in treating patients diagnosed with SMVT. Short-term technical success was measured as any improvement in SMV flow per completion angiography at the time of intervention. The long-term technical success was represented by the primary and secondary patency rates. Primary patency was defined as the interval from reestablishing initial mesenteric venous flow until the first thrombotic event, seen through ultrasound imaging follow up, or additional intervention. Secondary patency was defined as successful restoration of flow after thrombosis post reintervention until rethrombosis or last follow-up. Portal involvement defined as any thrombus extension into the main portal vein. The clinical outcomes were assessed by reporting the clinical status of the patient at 1 to 2 d following the procedure, reporting the adverse events

via Clavien-Dindo classification, and showing the 5-year survival rate.

### Statistical analysis

Continuous variables were summarized as median (range) and quartiles while categorical variables were reported as frequency (percentage). The Kaplan-Meier method was used to estimate primary patency and overall survival using R version 3.6.2 (<https://www.r-project.org>). *P* values were considered statistically significant if *P* < 0.05. The statistical methods of this study were reviewed by Li Z, MS from Mayo Clinic.

## RESULTS

### Clinical presentation and baseline characteristics

The study population consisted of 24 patients (Table 1). The median age at intervention was 60 years (35-74 years) and 67% (*n* = 16) were men. The median time between presentation to hospital and intervention was 3 d (0-15 d), while the median time from symptom onset to intervention was 8 d (2-35 d). Of 79.2% (*n* = 19) patients presented with acute symptoms while acute on top of chronic symptoms occurred in 20.8% (*n* = 5) of the patients. The most common SMVT risk factors were history of intra-abdominal surgery (*n* = 11, 45.8%), liver cirrhosis (*n* = 11, 45.8%), and malignancy (*n* = 11, 45.8%). Patients presented primarily with abdominal pain 70.8% (*n* = 17), and nausea and vomiting 50% (*n* = 12).

### Laboratory tests, imaging, and treatment modalities

Only 54.2% (*n* = 13) patients had a reported lactate level at presentation, of them, 23.1% (*n* = 3) have hyperlactatemia with a median level of 1.4 mmol/L (range, 0.8-4.8 mg/dL). While 91.7% (*n* = 22) had a reported white blood cell count, where 13.6% (*n* = 3) have leukocytosis with a median count of  $9.2 \times 10^9/L$ ; range,  $3.5-21.9 \times 10^9/L$ . Computed tomography was the most frequently used imaging modality [62.5% (*n* = 15)] followed by the magnetic resonance angiography used in 37.5% (*n* = 9). Among 24 patients, only 2 had isolated SMVT while the portal vein was involved in the other 91.7% (*n* = 22). The distal part of the SMV (defined as the part of the SMV near the tributaries) was involved in 66.7% (*n* = 16), the proximal end (defined as the portion of the SMV proper without tributaries) was involved in 12.5% (*n* = 3), and 20.8% (*n* = 5) had both proximal and distal involvement.

All 24 patients received at least one endovascular modality, while 13 (54.2%) received a combination of treatments (Table 2). Thrombectomy was the most commonly used, which was attempted in 50% (*n* = 12). Out of 12 patients, a pharmacomechanical system (AngioJet device; Boston Scientific Corporation) was performed in 75% (*n* = 9) and aspiration thrombectomy was employed in 25% (*n* = 3) (Figure 2). CDT was attempted in 41.7% (*n* = 10) of the patients, where CDT alone was in 4 patients and in combination with other modalities in 6 patients. In patients who received CDT, eight were treated with tissue plasminogen activator with an infusion rate of 0.5 to 1.0 mg/h over 24 to 72 h and 2 patients received fixed doses of recombinant tissue plasminogen activator (Table 3).

Other treatment modalities were also employed, including stents placed in 37.5% (*n* = 9), TIPS created in 25.0% (*n* = 6), and balloon angioplasty alone performed in 16.7% (*n* = 4). All patients that had a TIPS creation received an intrahepatic stent.

### Success rates and follow-up data

Technical success was achieved in 18 of 24 patients. In these patients, 61.1% (*n* = 11) achieved complete recanalization, and 38.9% (*n* = 7) were established partial recanalization. Three patients underwent more than 1 endovascular intervention: 2 of them with technical success. Out of the 11 patients that had liver cirrhosis, 9 achieved technical success; with only one patient having primary patency failure, and three patients died by the end of the study. An 83.3% (*n* = 20) of the patients demonstrated clinical improvement 48 h following the procedure (Table 2). A single patient experienced symptom progression after intervention.

Median follow-up of the patients was 23 mo (range of 1-145). The median length of stay was 12 d (range of 1-68 d). Primary patency at 14 and 30 d were 88.9% (95%CI: 76%-100%) and 83.3% (95%CI: 68%-100%), respectively (Figure 3). Adverse events were identified in 8.3% (*n* = 2) of patients, one marked as grade IIIB, and 1 death marked as grade V. One patient underwent partial small bowel resection, and the

**Table 1 Patient baseline characteristics (n = 24)**

Measure	Value <sup>1</sup>
Age (yr)	60 (35-74)
Sex	
Male	16 (66.7)
Female	8 (33.3)
Symptoms <sup>2,3</sup>	
Abdominal pain	17 (70.8)
Nausea and vomiting	12 (50.0)
Abdominal distention	9 (37.5)
Constipation	5 (20.8)
Diarrhea (bloody or non-bloody)	3 (12.5)
Hematemesis	1 (4.2)
Signs <sup>2,3</sup>	
Ascites	7 (29.2)
Abdominal tenderness	6 (25.0)
Fever	3 (12.5)
Hypotension (SBP < 90)	1 (4.2)
Jaundice	1 (4.2)
Risk factors <sup>2,3</sup>	
Liver cirrhosis	11 (45.8)
Intra-abdominal surgery	11 (45.8)
Pancreatic cancer	6 (25.0)
Intra-abdominal infection	4 (16.7)
Hepatocellular carcinoma	3 (12.5)
Others	9 (37.5)

<sup>1</sup>Values reported as median (range) or n (%).

<sup>2</sup>Some patients reported more than 1 symptom or risk factor.

<sup>3</sup>Some patients did not report any symptom, sign or risk factor.

SBP: Systolic blood pressure.

second patient had a subcapsular hematoma and intraperitoneal bleeding and died after 6 d.

A total of 6 patients (25%) died at some point during the study, four of which (16.7%) died before the median follow up time of 23 mo. Five-year overall survival rate was 82% (58%-100%).

## DISCUSSION

SMVT is associated with high rates of morbidity and mortality[1]. Our study described and evaluated the outcomes of endovascular treatment of SMVT in 24 patients, with either acute thrombosis or chronic thrombosis with acute symptoms. The acute onset usually presents with crampy upper, middle, or lower-middle abdominal pain in addition to nausea, anorexia, vomiting, diarrhea, and/or bloody stool. Features of portal hypertension are usually reported in the chronic onset[7,8].

Since the presenting symptoms of SMVT are not specific (*e.g.*, abdominal pain and nausea and/or vomiting), early detection and diagnosis of the condition is challenging, leading to a delay in initiating management; thus, more dangerous consequences can emerge, such as intestinal and bowel infarction. The delay of

**Table 2 Treatment options and patient outcomes (n = 24)**

Measure	Value <sup>1</sup>
Endovascular modality <sup>2</sup>	
Thrombectomy	12 (50.0)
Thrombolysis	10 (41.7)
Stent placement	9 (37.5)
TIPS	6 (25.0)
Balloon angioplasty	4 (16.7)
Technical success outcome <sup>3</sup>	18 (75.0)
Complete	11 (61.1)
Partial	7 (38.9)
Clinical outcome	
Resolution	11 (45.8)
Partial improvement	9 (37.5)
Not changed	3 (12.5)
Got worse	1 (4.2)
Clavien-Dindo classification <sup>4</sup>	
Grade I	4 (16.7)
Grade II	5 (20.8)
Grade III	1 (4.2)
Grade IV	0 (0.0)
Grade V	1 (4.2)
Intestinal resection	1 (4.2)
In-hospital time, d	12 (1-68)
Readmission	1 (4.2)
Follow-up duration, mo	23 (1-145)

<sup>1</sup>Values reported as n (%) or median (range).<sup>2</sup>Of 54.2% (n = 13) patients had more than 1 modality.<sup>3</sup>Of 6 patients did not establish a primary flow.<sup>4</sup>Of 13 patients did not develop minor or major complications.

TIPS: Transjugular intrahepatic portosystemic shunt.

management in these patients is also due to the failure of anticoagulation which is always the first line of treatment before moving to endovascular therapy and explains the 3-d median time of presentation-to-intervention that was found. Endovascular therapies are becoming increasingly used, however, the data available regarding their use in literature is insufficient[9-12].

In our study, percutaneous thrombectomy was used to treat 14 patients, most commonly using pharmacomechanical thrombectomy through rheolysis and less commonly using aspiration thrombectomy, either in combination with other modalities, especially CDT, or alone, in case CDT was contraindicated or not indicated. Rabuffi *et al*[10] evaluated the outcomes of 8 patients who were treated by a pharmacomechanical thrombectomy, and showed survival rate of 87.5% and a 12.5% major complication rate at mean follow up of 37 mo, compared to 78.6% and 7.1% in our study at median follow-up of 23 mo.

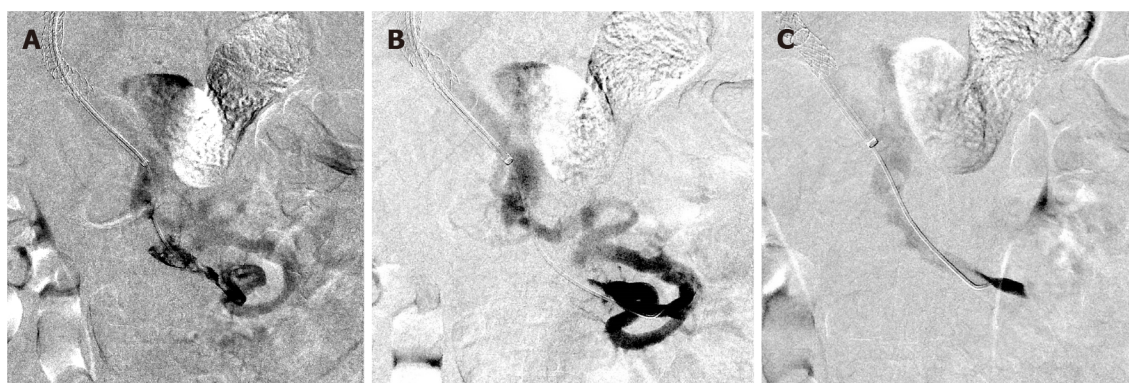Many studies investigating the endovascular thrombolytic therapies have been reported. Andraska *et al*[13] exhibited that thrombolysis achieved a rate of complete or partial recanalization of 91.6% in patients who received this treatment modality alone. Another study[14] evaluated outcomes of performing CDT in 20 patients, demonstrated a complication rate of 60%, and 1 death during hospitalization due to

**Table 3 Thrombectomy and thrombolysis therapy**

Measure	n (%)
Access (n = 24)	
Transhepatic	13 (54.2)
Transjugular	11 (45.8)
Thrombectomy (n = 12)	
Pharmacomechanical	9 (75.0)
Aspiration	3 (25.0)
Thrombolysis (n = 10)	
Thrombolytic agent	
tPA	9 (90.0)
rtPA	1 (10.0)
Infusion rate	
1.0 mg/h	5 (50.0)
0.5 mg/h	3 (30.0)
Fixed dose	2 (20.0)
Infusion duration <sup>1</sup> (n = 8)	
24 h	2 (25.0)
48 h	4 (50.0)
72 h	2 (25.0)

<sup>1</sup>Patients who received fixed doses (n = 2) were excluded.

rtPA: Recombinant plasminogen activator; tPA: Tissue plasminogen activator.



**Figure 2 Laboratory tests, imaging, and treatment modalities.** A and B: Selective superior mesenteric venogram after transjugular intrahepatic portosystemic shunt creation demonstrates a filling defect representing thrombus in the superior mesenteric venous (SMV), hepatofugal flow in a peripheral SMV branch, and a venovenous collateral decompressing the small bowel outflow into the main SMV trunk; C: Superior mesenteric venogram after aspiration and mechanical thrombectomy demonstrates reestablished flow in the previously occluded SMV, nonperfusion for the venovenous collateral, and hepatopetal flow in the peripheral SMV branches.

gastrointestinal hemorrhage and septic shock. In our study, the primary patency was established in 5 of the 6 patients who were treated with CDT combined with other modalities. On the other hand, 3 out of 4 patients who were treated with CDT alone did not reestablish flow. Of those patients, two developed complications, 1 underwent surgical bowel resection after the procedure and the other patient developed a large subcapsular hematoma and subhepatic intraperitoneal hemorrhage. The latter patient had an emergent endovascular embolization where 14 units of packed red blood cells were given, and the patient was transferred to the intensive care unit where he died 6 d later. Their lactate level was 4.8 mmol/L, supporting the evidence that lactic acidosis

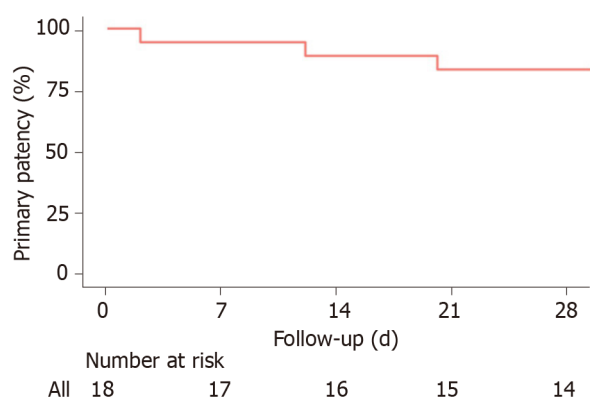


Figure 3 Kaplan-Meier curve of primary patency.

can be associated with higher likelihood of requiring bowel resection[13]. The 13 patients, who received one or more endovascular treatment modality other than the CDT, had a technical success of 92% and none of them underwent bowel resection after the endovascular procedure.

Yang *et al*[14] found among 13 cases who are treated with transcatheter thrombolysis, 4 cases required small bowel resection due to localized bowel infarction and secondary stricture. In our study, only 1 patient, who was still symptomatic for abdominal pain despite the thrombolysis for 72 h, underwent resection of proximal one-third of the jejunum and an ostomy placement after the thrombolysis therapy, which denotes the early detection and diagnosis of the condition and the rapid intervention as well.

TIPS was performed in 9 patients, can be helpful through creating a low-pressure system that assists in the removal of the clots in combination with other treatment modalities such as CDT[10]. Neither hepatic encephalopathy nor pulmonary embolism developed in any of these patients, although TIPS can increase the risk of these complications[10,15].

In a study that included 43 patients who were treated for their ASMVT using multidisciplinary stepwise management, endovascular CDT was performed in 83% ( $n = 36$ ) patients with or without adjunctive procedures, 20 as an initial procedure and 16 were postoperatively, their recanalization rate was 94.44% (*vs* 75% in this study). Bowel resection was required in 18 patients, with 30-d mortality and overall in-hospital mortality rates of 11.63% and 16.28%, respectively. The overall 1-year survival was 83.72% (*vs* 82% 5-year survival rate in our study)[16].

In our study, primary and secondary patencies were reported and those outcomes are not measured in other studies as far as we know. The high rates of the 30-d primary and secondary patencies of 83.3% and 88.9%, respectively, signify the safety and efficacy of using the endovascular interventions in treating those patients; however, the scale used in showing the patency rates and drawing the Kaplan-Meier curve for the primary patency was in days due to rapid occurrence of the rethrombosis events of those 3 patients.

Limitations of our study included its retrospective design. Conducting a large scale randomized controlled trial is not feasible because SMVT is a rare condition and the mechanism for SMVT is variable along with the ethics of trial design in withholding therapy to patients not responding to anticoagulation. Indeed, a study of 24 patients who were diagnosed with an uncommon condition is not considered a small study compared to the studies found in the literature, which are mostly case reports and very small case series. However, with this number of patients ( $n = 24$ ), conducting a statistical analysis was not possible. Overall, despite the aforementioned limitations, our study's findings show that endovascular management for SMVT was associated with high thrombus resolution rates and improvement in patients' clinical outcomes. Further large prospective study is still warranted to provide more significant data about the outcomes of endovascular therapies.

## CONCLUSION

Endovascular intervention with anticoagulation appears to be effective at managing

SMVT and may be considered as first-line therapy along with systemic anticoagulation in select patients.

## ARTICLE HIGHLIGHTS

### Research background

Superior mesenteric venous thrombosis (SMVT) is a rare but deadly condition with mortality rates of up to 23% that is typically treated with anticoagulation therapy and endovascular treatment if this fails.

### Research motivation

Most existing studies looking into endovascular of SMVT are small case series and case reports, and as such more information is needed on treatments for this rare condition.

### Research objectives

This study aimed to evaluate patients diagnosed with SMVT who received endovascular therapy in addition to anticoagulation and report technical and clinical outcomes.

### Research methods

A retrospective analysis of the patients who underwent endovascular treatment for SMVT at Mayo Clinic from 2000-2019 was performed. We explored the success of these endovascular treatments by determining technical success in each case, defined as any improvement in SMV flow following recanalization, and by assessing the primary/secondary patency rates.

### Research results

Twenty-four patients were included for analysis. Of these patients, 19 presented with acute thrombosis, while 5 presented with chronic thrombosis with acute manifestations. The most commonly used endovascular modalities were thrombectomy in 12 patients and catheter-directed thrombolysis in 10 patients. Technical success was achieved in 75% of patients, and the 14-d and 30-d patency rates were 88.9% and 83.3% respectively. The 5-year overall survival rate was 83%.

### Research conclusions

Endovascular interventions in addition to anticoagulation therapy appears to be effective in treating SMVT and may be considered a first-line therapy in select patients.

### Research perspectives

Our research helps build the base of literature on the rare condition of SMVT by providing an evaluation of the technical and clinical endovascular management outcomes. Larger prospective studies looking into the long-term outcomes of these endovascular interventions and anticoagulation therapy may be a future research direction.

## REFERENCES

- 1 Rhee RY, Gloviczki P. Mesenteric venous thrombosis. *Surg Clin North Am* 1997; **77**: 327-338 [PMID: 9146716 DOI: 10.1016/s0039-6109(05)70552-1]
- 2 Brunaud L, Antunes L, Collinet-Adler S, Marchal F, Ayav A, Bresler L, Boissel P. Acute mesenteric venous thrombosis: case for nonoperative management. *J Vasc Surg* 2001; **34**: 673-679 [PMID: 11668323 DOI: 10.1067/mva.2001.117331]
- 3 Harnik IG, Brandt LJ. Mesenteric venous thrombosis. *Vasc Med* 2010; **15**: 407-418 [PMID: 20926500 DOI: 10.1177/1358863X10379673]
- 4 Kim HK, Hwang D, Park S, Lee JM, Huh S. Treatment outcomes and risk factors for bowel infarction in patients with acute superior mesenteric venous thrombosis. *J Vasc Surg Venous Lymphat Disord* 2017; **5**: 638-646 [PMID: 28818214 DOI: 10.1016/j.jvsv.2017.04.011]
- 5 Bergqvist D, Svensson PJ. Treatment of mesenteric vein thrombosis. *Semin Vasc Surg* 2010; **23**: 65-68 [PMID: 20298951 DOI: 10.1053/j.semvscsurg.2009.12.008]
- 6 Kumar S, Sarr MG, Kamath PS. Mesenteric venous thrombosis. *N Engl J Med* 2001; **345**: 1683-

- 1688 [PMID: [11759648](#) DOI: [10.1056/NEJMra010076](#)]
- 7 **Hmoud B**, Singal AK, Kamath PS. Mesenteric venous thrombosis. *J Clin Exp Hepatol* 2014; **4**: 257-263 [PMID: [25755568](#) DOI: [10.1016/j.jceh.2014.03.052](#)]
- 8 **Shibahara K**, Tatsuta K, Orita H, Yonemura T, Kohno H. Superior mesenteric and portal vein thrombosis caused by congenital antithrombin III deficiency: report of a case. *Surg Today* 2007; **37**: 308-310 [PMID: [17387563](#) DOI: [10.1007/s00595-006-3382-7](#)]
- 9 **Yang S**, Zhang L, Liu K, Fan X, Ding W, He C, Wu X, Li J. Postoperative Catheter-Directed Thrombolysis Versus Systemic Anticoagulation for Acute Superior Mesenteric Venous Thrombosis. *Ann Vasc Surg* 2016; **35**: 88-97 [PMID: [27263813](#) DOI: [10.1016/j.avsg.2016.02.019](#)]
- 10 **Rabuffi P**, Vagnarelli S, Bruni A, Antonuccio G, Ambrogi C. Percutaneous Pharmacologic-Mechanical Thrombectomy of Acute Symptomatic Superior Mesenteric Vein Thrombosis. *Cardiovasc Intervent Radiol* 2020; **43**: 46-54 [PMID: [31650241](#) DOI: [10.1007/s00270-019-02354-y](#)]
- 11 **Liu K**, Liu S, Li L, Wang S, Fan X, Wu X, Shi G, Zong H. Evaluation of Endovascular Therapy Combined with Bowel Resection Treatment on Patients with Acute Mesenteric Venous Thrombosis. *Ann Vasc Surg* 2020; **65**: 72-81 [PMID: [31743777](#) DOI: [10.1016/j.avsg.2019.11.015](#)]
- 12 **Hollingshead M**, Burke CT, Mauro MA, Weeks SM, Dixon RG, Jaques PF. Transcatheter thrombolytic therapy for acute mesenteric and portal vein thrombosis. *J Vasc Interv Radiol* 2005; **16**: 651-661 [PMID: [15872320](#) DOI: [10.1097/01.RVI.0000156265.79960.86](#)]
- 13 **Andraska E**, Haga L, Li X, Avgerinos E, Singh M, Chaer R, Madigan M, Eslami MH. Retrograde open mesenteric stenting should be considered as the initial approach to acute mesenteric ischemia. *J Vasc Surg* 2020; **72**: 1260-1268 [PMID: [32276014](#) DOI: [10.1016/j.jvs.2020.02.044](#)]
- 14 **Yang SF**, Liu BC, Ding WW, He CS, Wu XJ, Li JS. Initial transcatheter thrombolysis for acute superior mesenteric venous thrombosis. *World J Gastroenterol* 2014; **20**: 5483-5492 [PMID: [24833878](#) DOI: [10.3748/wjg.v20.i18.5483](#)]
- 15 **Cao G**, Ko GY, Sung KB, Yoon HK, Gwon DI, Kim JH. Treatment of postoperative main portal vein and superior mesenteric vein thrombosis with balloon angioplasty and/or stent placement. *Acta Radiol* 2013; **54**: 526-532 [PMID: [23463860](#) DOI: [10.1177/0284185113475917](#)]
- 16 **Yang S**, Fan X, Ding W, Liu B, Meng J, Xu D, He C, Yu W, Wu X, Li J. Multidisciplinary stepwise management strategy for acute superior mesenteric venous thrombosis: an intestinal stroke center experience. *Thromb Res* 2015; **135**: 36-45 [PMID: [25466834](#) DOI: [10.1016/j.thromres.2014.10.018](#)]



Published by **Baishideng Publishing Group Inc**  
7041 Koll Center Parkway, Suite 160, Pleasanton, CA 94566, USA

**Telephone:** +1-925-3991568

**E-mail:** [bpgoffice@wjgnet.com](mailto:bpgoffice@wjgnet.com)

**Help Desk:** <https://www.f6publishing.com/helpdesk>

<https://www.wjgnet.com>

