

# World Journal of *Clinical Cases*

*World J Clin Cases* 2022 January 7; 10(1): 1-396



### MINIREVIEWS

- 1 Omicron variant (B.1.1.529) of SARS-CoV-2: Mutation, infectivity, transmission, and vaccine resistance  
*Ren SY, Wang WB, Gao RD, Zhou AM*
- 12 Hepatitis B virus reactivation in rheumatoid arthritis  
*Wu YL, Ke J, Zhang BY, Zhao D*
- 23 Paradoxical role of interleukin-33/suppressor of tumorigenicity 2 in colorectal carcinogenesis: Progress and therapeutic potential  
*Huang F, Chen WY, Ma J, He XL, Wang JW*

### ORIGINAL ARTICLE

#### Case Control Study

- 35 Changes in rheumatoid arthritis under ultrasound before and after sinomenine injection  
*Huang YM, Zhuang Y, Tan ZM*
- 43 Benefits of multidisciplinary collaborative care team-based nursing services in treating pressure injury wounds in cerebral infarction patients  
*Gu YH, Wang X, Sun SS*

#### Retrospective Study

- 51 Outcomes and complications of open, laparoscopic, and hybrid giant ventral hernia repair  
*Yang S, Wang MG, Nie YS, Zhao XF, Liu J*
- 62 Surgical resection of intradural extramedullary tumors in the atlantoaxial spine *via* a posterior approach  
*Meng DH, Wang JQ, Yang KX, Chen WY, Pan C, Jiang H*
- 71 Vancomycin lavage for the incidence of acute surgical site infection following primary total hip arthroplasty and total knee arthroplasty  
*Duan MY, Zhang HZ*
- 79 Distribution of transient receptor potential vanilloid-1 channels in gastrointestinal tract of patients with morbid obesity  
*Atas U, Erin N, Tazegul G, Elpek GO, Yıldırım B*
- 91 Value of neutrophil-lymphocyte ratio in evaluating response to percutaneous catheter drainage in patients with acute pancreatitis  
*Gupta P, Das GC, Bansal A, Samanta J, Mandavdhare HS, Sharma V, Naseem S, Gupta V, Yadav TD, Dutta U, Varma N, Sandhu MS, Kochhar R*

- 104** Influence of overweight and obesity on the mortality of hospitalized patients with community-acquired pneumonia  
*Wang N, Liu BW, Ma CM, Yan Y, Su QW, Yin FZ*
- 117** Minimally invasive open reduction of greater tuberosity fractures by a modified suture bridge procedure  
*Kong LP, Yang JJ, Wang F, Liu FX, Yang YL*
- 128** Increased levels of lactate dehydrogenase and hypertension are associated with severe illness of COVID-19  
*Jin ZM, Shi JC, Zheng M, Chen QL, Zhou YY, Cheng F, Cai J, Jiang XG*
- 136** Age, alcohol, sex, and metabolic factors as risk factors for colonic diverticulosis  
*Yan Y, Wu JS, Pan S*
- 143** Evaluation of right-to-left shunt on contrast-enhanced transcranial Doppler in patent foramen ovale-related cryptogenic stroke: Research based on imaging  
*Xiao L, Yan YH, Ding YF, Liu M, Kong LJ, Hu CH, Hui PJ*
- 155** Characterization of focal hypermetabolic thyroid incidentaloma: An analysis with F-18 fluorodeoxyglucose positron emission tomography/computed tomography parameters  
*Lee H, Chung YS, Lee JH, Lee KY, Hwang KH*

### Clinical Trials Study

- 166** Low-dose intralesional injection of 5-fluorouracil and triamcinolone reduces tissue resident memory T cells in chronic eczema  
*Wu Y, Wang GJ, He HQ, Qin HH, Shen WT, Yu Y, Zhang X, Zhou ML, Fei JB*

### Observational Study

- 177** Alterations in blink and masseter reflex latencies in older adults with neurocognitive disorder and/or diabetes mellitus  
*Bricio-Barrios JA, Rios-Bracamontes E, Rios-Silva M, Huerta M, Serrano-Moreno W, Barrios-Navarro JE, Ortiz GG, Huerta-Trujillo M, Guzmán-Esquivel J, Trujillo X*
- 189** Predicting adolescent perfectionism: The role of socio-demographic traits, personal relationships, and media  
*Livazović G, Kuzmanović K*
- 205** Novel m.4268T>C mutation in the mitochondrial tRNA<sup>Leu</sup> gene is associated with hearing loss in two Chinese families  
*Zhao LJ, Zhang ZL, Fu Y*
- 217** Superior mesenteric venous thrombosis: Endovascular management and outcomes  
*Alnahhal K, Toskich BB, Nussbaum S, Li Z, Erben Y, Hakaim AG, Farres H*

### Randomized Controlled Trial

- 227** Zinc carnosine-based modified bismuth quadruple therapy *vs* standard triple therapy for *Helicobacter pylori* eradication: A randomized controlled study  
*Ibrahim N, El Said H, Choukair A*

## CASE REPORT

- 236 Acquired coagulation dysfunction resulting from vitamin K-dependent coagulation factor deficiency associated with rheumatoid arthritis: A case report  
*Huang YJ, Han L, Li J, Chen C*
- 242 Intraoperative thromboelastography-guided transfusion in a patient with factor XI deficiency: A case report  
*Guo WJ, Chen WY, Yu XR, Shen L, Huang YG*
- 249 Positron emission tomography and magnetic resonance imaging combined with computed tomography in tumor volume delineation: A case report  
*Zhou QP, Zhao YH, Gao L*
- 254 Successful response to camrelizumab in metastatic bladder cancer: A case report  
*Xie C, Yuan X, Chen SH, Liu ZY, Lu DL, Xu F, Chen ZQ, Zhong XM*
- 260 HER2 changes to positive after neoadjuvant chemotherapy in breast cancer: A case report and literature review  
*Wang L, Jiang Q, He MY, Shen P*
- 268 Hyper-accuracy three-dimensional reconstruction as a tool for better planning of retroperitoneal liposarcoma resection: A case report  
*Ye MS, Wu HK, Qin XZ, Luo F, Li Z*
- 275 Recurrent postmenopausal bleeding - just endometrial disease or ovarian sex cord-stromal tumor? A case report  
*Wang J, Yang Q, Zhang NN, Wang DD*
- 283 Complex proximal femoral fracture in a young patient followed up for 3 years: A case report  
*Li ZY, Cheng WD, Qi L, Yu SS, Jing JH*
- 289 Bilateral Hypertrophic Olivary Degeneration after Pontine Hemorrhage: A Case Report  
*Zheng B, Wang J, Huang XQ, Chen Z, Gu GF, Luo XJ*
- 296 Clinical characteristics and outcomes of primary intracranial alveolar soft-part sarcoma: A case report  
*Chen JY, Cen B, Hu F, Qiu Y, Xiao GM, Zhou JG, Zhang FC*
- 304 Removal of laparoscopic cerclage stitches *via* laparotomy and rivanol-induced labour: A case report and literature review  
*Na XN, Cai BS*
- 309 Cerebral venous sinus thrombosis in pregnancy: A case report  
*Zhou B, Huang SS, Huang C, Liu SY*
- 316 Eustachian tube teratoma: A case report  
*Li JY, Sun LX, Hu N, Song GS, Dou WQ, Gong RZ, Li CT*

- 323** Protein-losing enteropathy caused by a jejunal ulcer after an internal hernia in Petersen's space: A case report  
*Yasuda T, Sakurazawa N, Kuge K, Omori J, Arai H, Kakinuma D, Watanabe M, Suzuki H, Iwakiri K, Yoshida H*
- 331** Lunate dislocation with avulsed triquetral fracture: A case report  
*Li LY, Lin CJ, Ko CY*
- 338** Clinical manifestations and prenatal diagnosis of Ullrich congenital muscular dystrophy: A case report  
*Hu J, Chen YH, Fang X, Zhou Y, Chen F*
- 345** Diagnosis and guidance of treatment of breast cancer cutaneous metastases by multiple needle biopsy: A case report  
*Li ZH, Wang F, Zhang P, Xue P, Zhu SJ*
- 353** Test of incremental respiratory endurance as home-based, stand-alone therapy in chronic obstructive pulmonary disease: A case report  
*Dosbaba F, Hartman M, Batalik L, Brat K, Plutinsky M, Hnatiak J, Formiga MF, Cahalin LP*
- 361** Diagnostic and surgical challenges of progressive neck and upper back painless masses in Madelung's disease: A case report and review of literature  
*Yan YJ, Zhou SQ, Li CQ, Ruan Y*
- 371** Suspected cerebrovascular air embolism during endoscopic esophageal varices ligation under sedation with fatal outcome: A case report  
*Zhang CMJ, Wang X*
- 381** An atypical primary malignant melanoma arising from the cervical nerve root: A case report and review of literature  
*Shi YF, Chen YQ, Chen HF, Hu X*
- 388** Epidural blood patch for spontaneous intracranial hypotension with subdural hematoma: A case report and review of literature  
*Choi SH, Lee YY, Kim WJ*

**ABOUT COVER**

Editorial Board Member of *World Journal of Clinical Cases*, Ravi Kant, MD, Associate Professor, Division of Endocrinology, Diabetes and Metabolism, Medical University of South Carolina/Anmed Campus, Anderson, SC 29621, United States. rkant82@hotmail.com

**AIMS AND SCOPE**

The primary aim of *World Journal of Clinical Cases* (WJCC, *World J Clin Cases*) is to provide scholars and readers from various fields of clinical medicine with a platform to publish high-quality clinical research articles and communicate their research findings online.

WJCC mainly publishes articles reporting research results and findings obtained in the field of clinical medicine and covering a wide range of topics, including case control studies, retrospective cohort studies, retrospective studies, clinical trials studies, observational studies, prospective studies, randomized controlled trials, randomized clinical trials, systematic reviews, meta-analysis, and case reports.

**INDEXING/ABSTRACTING**

The WJCC is now indexed in Science Citation Index Expanded (also known as SciSearch®), Journal Citation Reports/Science Edition, Scopus, PubMed, and PubMed Central. The 2021 Edition of Journal Citation Reports® cites the 2020 impact factor (IF) for WJCC as 1.337; IF without journal self cites: 1.301; 5-year IF: 1.742; Journal Citation Indicator: 0.33; Ranking: 119 among 169 journals in medicine, general and internal; and Quartile category: Q3. The WJCC's CiteScore for 2020 is 0.8 and Scopus CiteScore rank 2020: General Medicine is 493/793.

**RESPONSIBLE EDITORS FOR THIS ISSUE**

Production Editor: Lin-YuTong Wang; Production Department Director: Xiang Li; Editorial Office Director: Jin-Lei Wang.

**NAME OF JOURNAL**

*World Journal of Clinical Cases*

**ISSN**

ISSN 2307-8960 (online)

**LAUNCH DATE**

April 16, 2013

**FREQUENCY**

Weekly

**EDITORS-IN-CHIEF**

Bao-Gan Peng

**EDITORIAL BOARD MEMBERS**

<https://www.wjgnet.com/2307-8960/editorialboard.htm>

**PUBLICATION DATE**

January 7, 2022

**COPYRIGHT**

© 2022 Baishideng Publishing Group Inc

**INSTRUCTIONS TO AUTHORS**

<https://www.wjgnet.com/bpg/gerinfo/204>

**GUIDELINES FOR ETHICS DOCUMENTS**

<https://www.wjgnet.com/bpg/GerInfo/287>

**GUIDELINES FOR NON-NATIVE SPEAKERS OF ENGLISH**

<https://www.wjgnet.com/bpg/gerinfo/240>

**PUBLICATION ETHICS**

<https://www.wjgnet.com/bpg/GerInfo/288>

**PUBLICATION MISCONDUCT**

<https://www.wjgnet.com/bpg/gerinfo/208>

**ARTICLE PROCESSING CHARGE**

<https://www.wjgnet.com/bpg/gerinfo/242>

**STEPS FOR SUBMITTING MANUSCRIPTS**

<https://www.wjgnet.com/bpg/GerInfo/239>

**ONLINE SUBMISSION**

<https://www.f6publishing.com>

## Cerebral venous sinus thrombosis in pregnancy: A case report

Biao Zhou, Shan-Shan Huang, Can Huang, Shu-Yun Liu

**ORCID number:** Biao Zhou 0000-0003-4785-1593; Shan-Shan Huang 0000-0001-6711-1862; Can Huang 0000-0003-4984-0425; Shu-Yun Liu 0000-0002-6787-3506.

**Author contributions:** Zhou B and Liu SY drafted the manuscript; Zhou B and Huang C contributed to the diagnosis and treatment of the patient; Huang SS and Liu SY revised the manuscript; all authors have read and approved the manuscript and contributed to the design of the study and interpretation of data.

**Informed consent statement:** Informed written consent was obtained from the patient for publication of this report and any accompanying images.

**Conflict-of-interest statement:** The authors declare that they have no conflict of interest.

**CARE Checklist (2016) statement:** The authors have read the CARE Checklist (2016), and the manuscript was prepared and revised according to the CARE Checklist (2016).

**Country/Territory of origin:** China

**Specialty type:** Clinical neurology

**Provenance and peer review:** Unsolicited article; Externally peer reviewed.

**Peer-review model:** Single blind

**Biao Zhou, Can Huang,** Department of Neurology, Dongguan Tungwah Hospital, Dongguan 523000, Guangdong Province, China

**Shan-Shan Huang,** Department of Intensive Care Unit, The Seventh Affiliated Hospital, Sun Yat-Sen University, Shenzhen 518000, Guangdong Province, China

**Shu-Yun Liu,** Department of Neurology, Shenzhen Longhua District Central Hospital, Shenzhen 518000, Guangdong Province, China

**Corresponding author:** Shu-Yun Liu, MD, Chief Doctor, Department of Neurology, Shenzhen Longhua District Central Hospital, No. 187 Guanlan Avenue, Longhua District, Shenzhen 518000, Guangdong Province, China. [liushuyun202104@163.com](mailto:liushuyun202104@163.com)

### Abstract

#### BACKGROUND

Cerebral venous thrombosis (CVT) is a rare but life-threatening disease in pregnant women. Anticoagulation is the first-line therapy for CVT management. However, some patients have poor outcomes despite anticoagulation. Currently, the endovascular treatment of CVT in pregnant women remains controversial. We report a rare case of CVT in a pregnant woman who was successfully treated with two stent retriever devices.

#### CASE SUMMARY

The patient was a 29-year-old pregnant woman. She was first diagnosed with hyperemesis gravidarum due to severe nausea and vomiting for one week. As the disease progressed, she developed acute left hemiplegia. Imaging confirmed the diagnosis of superior sagittal sinus, right transverse sinus and sinus sigmoideus thrombosis. As anticoagulant therapy was ineffective, she underwent thrombectomy. After the mechanical thrombectomy, her headache diminished. Three weeks later, the patient was completely independent. At a 3-mo follow-up, no relapse of symptoms was observed.

#### CONCLUSION

Mechanical thrombectomy may be an effective alternative therapy for CVT in pregnant women if anticoagulation therapy fails.

**Key Words:** Pregnancy; Cerebral venous thrombosis; Anticoagulation; Mechanical thrombectomy; Case report

©The Author(s) 2022. Published by Baishideng Publishing Group Inc. All rights reserved.

**Peer-review report's scientific quality classification**

Grade A (Excellent): 0

Grade B (Very good): B, B, B

Grade C (Good): C

Grade D (Fair): D, D

Grade E (Poor): 0

**Open-Access:** This article is an open-access article that was selected by an in-house editor and fully peer-reviewed by external reviewers. It is distributed in accordance with the Creative Commons Attribution NonCommercial (CC BY-NC 4.0) license, which permits others to distribute, remix, adapt, build upon this work non-commercially, and license their derivative works on different terms, provided the original work is properly cited and the use is non-commercial. See: <http://creativecommons.org/licenses/by-nc/4.0/>

**Received:** July 1, 2021**Peer-review started:** July 1, 2021**First decision:** September 28, 2021**Revised:** November 9, 2021**Accepted:** November 28, 2021**Article in press:** November 28, 2021**Published online:** January 7, 2022**P-Reviewer:** Jatuworapruk K, Lal A, Patel L, Ramesh PV**S-Editor:** Liu JH**L-Editor:** A**P-Editor:** Liu JH

**Core Tip:** Pregnancy-related cerebral venous thrombosis (CVT) is an uncommon and severe disease. Endovascular treatment of CVT in pregnant women remains controversial. We report a rare case of CVT in a pregnant woman who was successfully treated with two stent retriever devices. Given its rare incidence and highly diverse clinical manifestations, the clinical diagnosis of CVT is challenging. In order to avoid misdiagnosis in these high-risk patients, prompt multidisciplinary diagnosis and treatment is essential.

**Citation:** Zhou B, Huang SS, Huang C, Liu SY. Cerebral venous sinus thrombosis in pregnancy: A case report. *World J Clin Cases* 2022; 10(1): 309-315

**URL:** <https://www.wjgnet.com/2307-8960/full/v10/i1/309.htm>

**DOI:** <https://dx.doi.org/10.12998/wjcc.v10.i1.309>

## INTRODUCTION

Cerebral venous thrombosis (CVT) is a rare and severe disease. A recent study found that approximately one-third of CVT patients did not return to paid work, and this was more common in women and patients with parenchymal lesions[1]. According to the 2017 European ESO/EAN Guidelines, anticoagulation is the main therapeutic regimen for CVT in clinical practice[2]. However, some patients have poor outcomes despite anticoagulation. Studies have demonstrated the benefits of endovascular therapy with respect to CVT recanalization[3]. However, due to the low-level of available evidence, the 2017 European guidelines do not make any recommendations, and specific analyses regarding pregnant populations are limited. Here, we report a rare case of CVT in a pregnant woman who underwent endovascular mechanical thrombectomy using two stent retriever devices.

## CASE PRESENTATION

### Chief complaints

A 29-year-old female in the 8<sup>th</sup> week of her first pregnancy presented to the Obstetrics Department of a referral hospital. The patient had nausea, vomiting and persistent headaches for one week prior to admission. Due to severe nausea and vomiting in pregnancy, she was first diagnosed with hyperemesis gravidarum.

### History of present illness

A persistent headache with nausea and non-projectile vomiting occurred 1 wk previously. The headache was mainly characterized by mild-to-moderate, pulsatile headache on both sides of the temple, which was more obvious when shaking her head. The patient had no other discomfort such as fever, blurred vision, hemiplegia, consciousness disturbance, seizures, etc.

### History of past illness

About 8 wk previously, the patient's menstruation ceased. Two weeks ago, she was treated with oral progesterone to prevent miscarriage due to a small amount of intermittent vaginal discharge. She denied a history of hematologic disorders, autoimmune diseases, intracranial and extracranial tumors.

### Personal and family history

The patient denied taking oral contraceptives and denied a family history of hereditary thrombophilia.

### Physical examination

On admission, the patient's main symptoms were a persistent headache, nausea and vomiting. Her vital signs and muscle strength were normal. Three days after admission, she developed a new left-sided motor weakness (4/5). Neurologic consultation was recommended. Neurological examination showed poor spirit, left



limb weakness (4/5), neck stiffness, positive Kernig's sign and positive Babinski's sign on the left. No other focal neurological deficits were found.

### **Laboratory examinations**

Cerebrospinal fluid pressure was 220 mmH<sub>2</sub>O, cerebrospinal fluid cell count and protein were nearly normal, and  $\beta$ -human chorionic gonadotropin was 150073 IU/L. Her D-dimer level was 12.5 mg/L. Other laboratory tests were normal, such as routine blood tests, coagulation function, routine urinalysis, liver function, kidney function, homocysteine, protein C, protein S and so on. Due to an acute onset of neurologic symptoms, and objective findings upon neurologic examination, the most probable diagnosis was CVT.

### **Imaging examinations**

Ultrasound scan was performed, which showed a fetus at 8 wk of gestation (Figure 1A). Prethrombectomy brain magnetic resonance imaging (MRI) combined with magnetic resonance venography revealed superior sagittal sinus, right transverse sinus and sinus sigmoideus thrombosis with a right temporal lobe venous infarct (Figure 1B and C). Post-thrombectomy MRI revealed new lesions in the right frontal lobe and left parietal lobe (Figure 1D).

---

## **FINAL DIAGNOSIS**

---

The patient was diagnosed with CVT.

---

## **TREATMENT**

---

Anticoagulant treatment with subcutaneous low molecular weight heparin (LMWH) administered twice a day was initiated. However, 3 d after admission, her symptoms worsened. The patient developed a right-sided weakness (4/5), and a progressive left limb weakness (3/5). Subsequent MRI confirmed new lesions in the right frontal lobe and left parietal lobe. Selective catheterization of the right internal carotid artery confirmed occlusion of the superior sagittal sinus, as well as the right transverse sinus, and sinus sigmoideus (Figure 2A and B). Despite anticoagulation, the patient's neurological condition declined; therefore, emergency mechanical thrombectomy was performed. She successfully attained occluded superior sagittal sinus recanalization, as well as right transverse sinus, and sinus sigmoideus recanalization (Figure 2C-G). Microscopic appearance of the cerebral embolus specimen was consistent with a mixed thrombus (Figure 2H). As there were some residual thromboses, she continued LMWH therapy on the first post-procedure day. Immediately after the procedure, her headache diminished.

---

## **OUTCOME AND FOLLOW-UP**

---

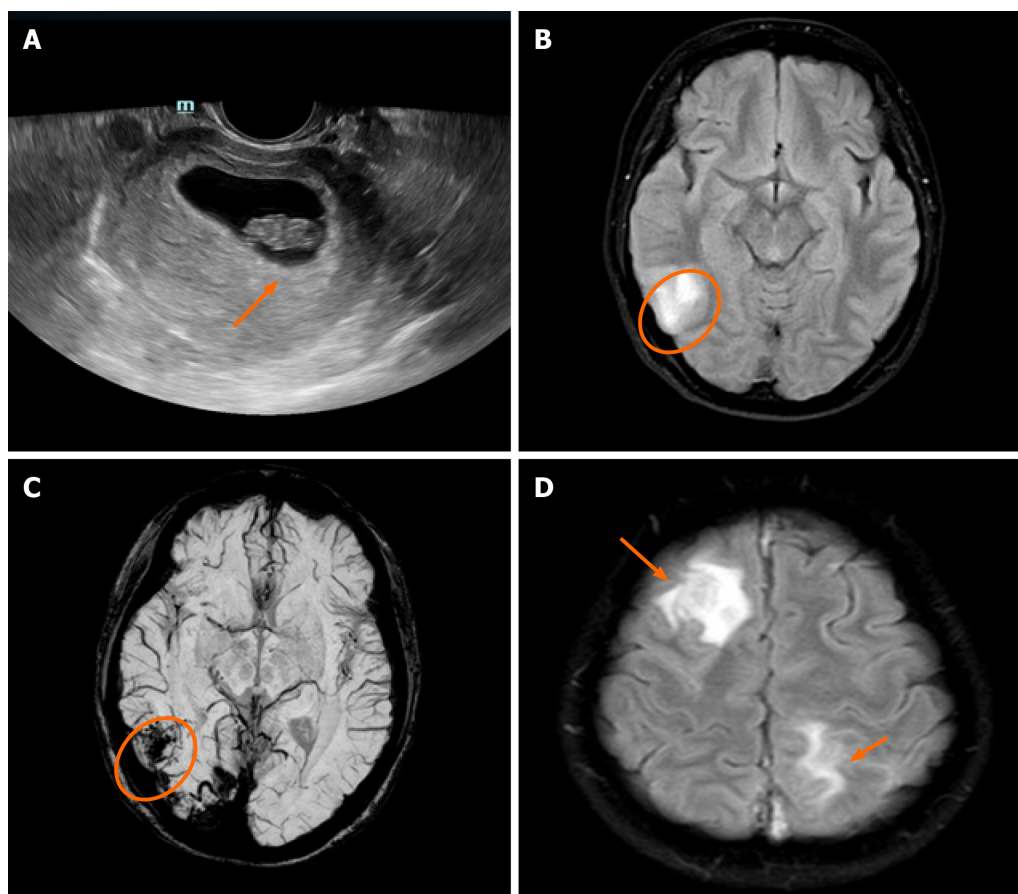
Three weeks after the procedure, the patient was completely independent (modified Rankin Scale score = 0), and at a 3-mo follow-up, symptomatic relapse was not reported.

---

## **DISCUSSION**

---

Primary headaches, such as tension headaches and migraines, frequently occur in pregnant women and are the most common causes of headaches[4]. However, if pregnant women experience new, deteriorating headaches or when the headaches change in character, secondary origins may exist[5]. Pregnancy is a risk factor for secondary headache disorders. Anesthesia for labor, hypercoagulability, as well as hormonal changes are factors for the high incidence of secondary headaches during pregnancy. The most frequent causes of secondary headaches include stroke, subarachnoid hemorrhage, pituitary tumors, CVT, and reversible cerebral vasoconstriction syndrome[4].



**Figure 1** Ultrasound and magnetic resonance imaging. A: Ultrasound shows a fetus at 8 wk of gestation (orange arrow); B: Pre-thrombectomy-diffusion weighted imaging shows restriction in the right temporal lobe (orange circle); C: Pre-thrombectomy susceptibility-weighted imaging shows a large area of low signal region in the right temporal lobe; D: Post-thrombectomy magnetic resonance imaging reveals new lesions in the right frontal lobe and left parietal lobe (orange arrows).

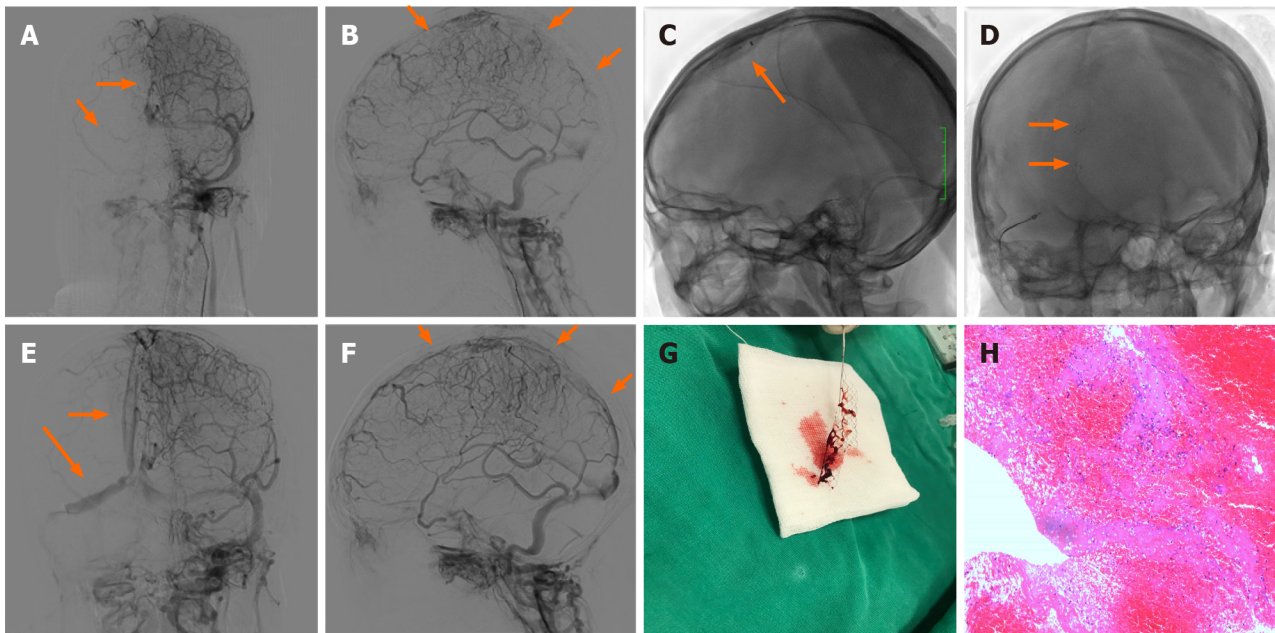
Pregnancy is an important risk factor for CVT. In pregnancy, CVT has a prevalence of 1.2 per 100000 deliveries[6]. An increase in prevalence within the 1<sup>st</sup> trimester is associated with women who have pre-existing thrombophilia who become pregnant. Given its rare incidence and highly diverse clinical manifestations, the clinical diagnosis of CVT is challenging. High incidences of headaches, motor weakness, seizures, and comatose/obtunded status have been reported, in tandem with clinical manifestations among non-pregnant/puerperal patients[7].

Due to its superior diagnostic accuracy, MRI is the most suitable option for diagnosing CVT in pregnant women, especially as it does not expose them to radiation, and it clearly differentiates soft tissues. Recent studies have shown that MRI performed with a 1.5-T magnet is safe for diagnosis in pregnant women at all trimesters[8].

Anticoagulation constitutes the first-line therapeutic option for managing the acute stage of CVT. LMWH has been confirmed to be preferable to unfractionated heparin, as it results in reduced mortality as well as better functional outcomes, with equivalent rates of systemic bleeding[9]. Furthermore, in special populations, such as pregnant women, LMWH cannot traverse the placenta, and adverse reactions associated with teratogenicity or fatal bleeding have not been reported. Therefore, it is a reasonable choice of anticoagulation therapy for CVT patients during pregnancy[10].

In the International Study on Cerebral Vein and Dural Sinus Thrombosis, approximately 13% of cases had poor outcomes even after anticoagulation treatment[7]. The 2017 European ESO/EAN Guidelines recommend that patients with acute CVT who are at a low risk of adverse consequences before treatment should not undergo endovascular treatment.

Currently, although there are no randomized controlled trials regarding the effectiveness and safety of endovascular treatment for CVT, more and more evidence has shown that mechanical thrombectomy is a safe and effective treatment for CVT[3,11]. A 2017 review of 235 patients with CVT and a neurologic presentation described the



**Figure 2 Operating process and outcome.** A and B: Prethrombectomy angiogram confirms occlusion of superior longitudinal sinus, as well as right transverse sinus, and sinus sigmoideus (orange arrows); C and D: Mechanical thrombectomy was performed using two Solitaire stents (orange arrows); E and F: Post-thrombectomy angiogram shows resolution of flow in the superior longitudinal sinus, right transverse sinus and sinus sigmoideus (orange arrows); G: Gross appearance of the partial removed cerebral embolus; H: Microscopic appearance of the cerebral embolus specimen consistent with mixed thrombus.

effectiveness and safety of endovascular treatment for CVT. They found that although 40.2% of patients presented with poor baseline characteristics (encephalopathy or coma), 69.0% of patients achieved complete radiographic resolution of CVT after endovascular treatment, 76% of patients achieved a good clinical outcome (a modified Rankin Scale score of 0-2), and the rate of worsening or new intracranial hemorrhage was only 8.7%.

However, studies on the efficacy and safety of mechanical thrombectomy for CVT in pregnant women are mainly limited to case reports and small series. To date, there are only 12 case reports of mechanical thrombectomy for the treatment of CVT in pregnant women. Table 1 summarizes the reported cases of CVT in pregnant women treated with mechanical thrombectomy from the literature along with our patient[12-19]. In addition to pregnancy, most patients (7/12) have other risk factors, such as antithrombin III deficiency and so on. Because of consciousness disorder or rapid deterioration of neurological function, all the patients underwent thrombectomy with or without thrombolysis. In two patients, thrombectomy resulted in complete restoration of flow (2/8) and in the remaining 6 patients (6/8) partial restoration of flow was achieved. Following thrombectomy, two (2/12) patients experienced non-fatal intracranial hemorrhage, 9 (75%) patients had a good clinical outcome and one patient died.

With regard to the safety of radiation exposure on fetal growth during an endovascular procedure, due to the distance between the mother's head and the uterus, the absorbed fetal radiation dose during endovascular treatment was only 2.8 mGy, which was much less than the risk threshold, and this had very little effect on the fetus[20]. The present review showed that the condition of the fetus was not mentioned in half of the 12 pregnant patients. One pregnancy ended in miscarriage, and five fetuses were normal at the time of discharge or follow-up. None of the infants was found to have either congenital anomalies or neonatal morbidity and mortality.

Therapeutic guidelines for CVT in pregnant women are difficult to establish, as the incidence of CVT in pregnancy is rare. If a patient presents with a new persistent headache and abnormalities on neurologic examination during pregnancy, obstetricians and neurologists should consider CVT, and MRI should be performed immediately. If the condition worsens during anticoagulant therapy, mechanical thrombectomy may be a good remedial treatment option.

**Table 1 Summary of reported cases of cerebral venous thrombosis in pregnant women treated with mechanical thrombectomy**

Ref.	Age	Risk factors	Treatment	Results of post-intervention CTA/DSA	Maternal outcome	Fetal outcome	Complications
Kourtopoulos <i>et al</i> [12], 1994	18	Pregnancy	Open thrombectomy, thrombolysis, heparin + actilyse	NA	mRS = 5 after 3 mo	Healthy	Intracranial hemorrhage
Chow <i>et al</i> [13], 2000	21	Pregnancy, anti-phospholipid antibodies	Heparin, rheolytic thrombectomy, urokinase	Partial restoration of flow	mRS = 0 after 6 mo	NA	None
Ou <i>et al</i> [14], 2003	29	Pregnancy, ovarian hyperstimulation syndrome	Local thrombolysis (urokinase), mechanical thrombectomy, LMWH	Partial restoration of flow	mRS = 2 at discharge	Healthy	None
Falavigna <i>et al</i> [15], 2006	24	Pregnancy	Mechanical lysis + abciximab	Complete restoration of flow	mRS = 0 after 12 mo	Healthy	Intracranial hemorrhage
Li <i>et al</i> [16], 2013	32	Pregnancy, mastoiditis	Mechanical thrombectomy combined with urokinase	NA	mRS = 2 at discharge	NA	None
Li <i>et al</i> [16], 2013	32	Antithrombin III deficiency, pregnancy	Mechanical thrombectomy combined with urokinase	NA	death	NA	None
Li <i>et al</i> [16], 2013	26	Pregnancy	Mechanical thrombectomy combined with urokinase	NA	mRS = 0 at discharge	NA	None
Mokin <i>et al</i> [17], 2015	33	Pregnancy	Heparin, penumbra aspiration catheter and separator	Complete restoration of flow	mRS = 2 at discharge	NA	None
Mokin <i>et al</i> [17], 2015	19	Pregnancy	Heparin, AngioJet	Partial restoration of flow	mRS = 5 at discharge	NA	None
King <i>et al</i> [18], 2016	20	Pregnancy, antithrombin III deficiency	Heparin, mechanical thrombectomy (failed), catheter-directed tPA, heparin + argatroban	Partial restoration of flow	mRS = 2 at discharge	Healthy	None
Serna Candel <i>et al</i> [19], 2019	34	Pregnancy, Heterozygous factor V Leiden mutation	LMWH, aspiration thrombectomy (failed), balloon angioplasty (failed), acetylsalicylic acid, eptifibatide, ticagrelor	Partial restoration of flow	mRS = 2 at discharge	Healthy	None
Our case	29	Pregnancy, antithrombin III deficiency	LMWH, mechanical thrombectomy	Partial restoration of flow	mRS = 1 after 3 mo	Miscarriage	None

CVT: Cerebral venous thrombosis; CTA: Computed tomographic angiogram; DSA: Digital subtraction angiogram; NA: Not available; mRS: Modified Rankin Scale; LMWH: Low-molecular weight heparin; tPA: Tissue plasminogen activator.

## CONCLUSION

Cerebral venous thrombosis is easily misdiagnosed or missed due to its rarity, diverse, and non-specific clinical manifestations during pregnancy. Prompt multidisciplinary diagnosis and treatment is essential. Our case and those reported in the literature show that mechanical thrombectomy may be an effective alternative therapy for CVT in pregnant women who do not respond to standard management.

## REFERENCES

- 1 Lindgren E, Jood K, Tatlisumak T. Vocational outcome in cerebral venous thrombosis: Long-term follow-up study. *Acta Neurol Scand* 2018; **137**: 299-307 [PMID: 29159843 DOI: 10.1111/ane.12875]
- 2 Ferro JM, Boussier MG, Canhão P, Coutinho JM, Crassard I, Dentali F, di Minno M, Maino A, Martinelli I, Masuhr F, de Sousa DA, Stam J; European Stroke Organization. European Stroke Organization guideline for the diagnosis and treatment of cerebral venous thrombosis - Endorsed by the European Academy of Neurology. *Eur Stroke J* 2017; **2**: 195-221 [PMID: 31008314 DOI: 10.1177/2396987317719364]
- 3 Borhani Haghighi A, Mahmoodi M, Edgell RC, Cruz-Flores S, Ghanaati H, Jamshidi M, Zaidat OO. Mechanical thrombectomy for cerebral venous sinus thrombosis: a comprehensive literature review. *Clin Appl Thromb Hemost* 2014; **20**: 507-515 [PMID: 23297370 DOI: 10.1177/1076029612470968]
- 4 Negro A, Delaruelle Z, Ivanova TA, Khan S, Ornello R, Raffaelli B, Terrin A, Reuter U, Mitsikostas



- DD; European Headache Federation School of Advanced Studies (EHF-SAS). Headache and pregnancy: a systematic review. *J Headache Pain* 2017; **18**: 106 [PMID: 29052046 DOI: 10.1186/s10194-017-0816-0]
- 5 **Edlow JA**, Caplan LR, O'Brien K, Tibbles CD. Diagnosis of acute neurological emergencies in pregnant and post-partum women. *Lancet Neurol* 2013; **12**: 175-185 [PMID: 23332362 DOI: 10.1016/S1474-4422(12)70306-X]
  - 6 **James AH**, Bushnell CD, Jamison MG, Myers ER. Incidence and risk factors for stroke in pregnancy and the puerperium. *Obstet Gynecol* 2005; **106**: 509-516 [PMID: 16135580 DOI: 10.1097/01.AOG.0000172428.78411.b0]
  - 7 **Ferro JM**, Canhão P, Stam J, Boussier MG, Barinagarrementeria F; ISCVT Investigators. Prognosis of cerebral vein and dural sinus thrombosis: results of the International Study on Cerebral Vein and Dural Sinus Thrombosis (ISCVT). *Stroke* 2004; **35**: 664-670 [PMID: 14976332 DOI: 10.1161/01.Str.0000117571.76197.26]
  - 8 **Kanekar S**, Bennett S. Imaging of Neurologic Conditions in Pregnant Patients. *Radiographics* 2016; **36**: 2102-2122 [PMID: 27831835 DOI: 10.1148/rg.2016150187]
  - 9 **Qureshi A**, Perera A. Low molecular weight heparin vs unfractionated heparin in the management of cerebral venous thrombosis: A systematic review and meta-analysis. *Ann Med Surg (Lond)* 2017; **17**: 22-26 [PMID: 28392913 DOI: 10.1016/j.amsu.2017.03.016]
  - 10 **Bates SM**, Greer IA, Middeldorp S, Veenstra DL, Prabalos AM, Vandvik PO. VTE, thrombophilia, antithrombotic therapy, and pregnancy: Antithrombotic Therapy and Prevention of Thrombosis, 9th ed: American College of Chest Physicians Evidence-Based Clinical Practice Guidelines. *Chest* 2012; **141**: e691S-e736S [PMID: 22315276 DOI: 10.1378/chest.11-2300]
  - 11 **Ilyas A**, Chen CJ, Raper DM, Ding D, Buell T, Mastorakos P, Liu KC. Endovascular mechanical thrombectomy for cerebral venous sinus thrombosis: a systematic review. *J Neurointerv Surg* 2017; **9**: 1086-1092 [PMID: 28213478 DOI: 10.1136/neurintsurg-2016-012938]
  - 12 **Kourtopoulos H**, Christie M, Rath B. Open thrombectomy combined with thrombolysis in massive intracranial sinus thrombosis. *Acta Neurochir (Wien)* 1994; **128**: 171-173 [PMID: 7847137 DOI: 10.1007/BF01400670]
  - 13 **Chow K**, Gobin YP, Saver J, Kidwell C, Dong P, Viñuela F. Endovascular treatment of dural sinus thrombosis with rheolytic thrombectomy and intra-arterial thrombolysis. *Stroke* 2000; **31**: 1420-1425 [PMID: 10835466 DOI: 10.1161/01.str.31.6.1420]
  - 14 **Ou YC**, Kao YL, Lai SL, Kung FT, Huang FJ, Chang SY, ChangChien CC. Thromboembolism after ovarian stimulation: successful management of a woman with superior sagittal sinus thrombosis after IVF and embryo transfer: case report. *Hum Reprod* 2003; **18**: 2375-2381 [PMID: 14585890 DOI: 10.1093/humrep/deg470]
  - 15 **Falavigna A**, Pontalti JL, Teles AR. [Dural sinus thrombosis: case report]. *Arq Neuropsiquiatr* 2006; **64**: 334-337 [PMID: 16791382 DOI: 10.1590/s0004-282x2006000200032]
  - 16 **Li G**, Zeng X, Hussain M, Meng R, Liu Y, Yuan K, Sikharam C, Ding Y, Ling F, Ji X. Safety and validity of mechanical thrombectomy and thrombolysis on severe cerebral venous sinus thrombosis. *Neurosurgery* 2013; **72**: 730-8; discussion 730 [PMID: 23313983 DOI: 10.1227/NEU.0b013e318285c1d3]
  - 17 **Mokin M**, Lopes DK, Binning MJ, Veznedaroglu E, Liebman KM, Arthur AS, Doss VT, Levy EI, Siddiqui AH. Endovascular treatment of cerebral venous thrombosis: Contemporary multicenter experience. *Interv Neuroradiol* 2015; **21**: 520-526 [PMID: 26055685 DOI: 10.1177/1591019915583015]
  - 18 **King AB**, O'Duffy AE, Kumar AB. Heparin Resistance and Anticoagulation Failure in a Challenging Case of Cerebral Venous Sinus Thrombosis. *Neurohospitalist* 2016; **6**: 118-121 [PMID: 27366296 DOI: 10.1177/1941874415591500]
  - 19 **Serna Candel C**, Hellstern V, Beitlich T, Aguilar Pérez M, Bänzner H, Henkes H. Management of a decompensated acute-on-chronic intracranial venous sinus thrombosis. *Ther Adv Neurol Disord* 2019; **12**: 1756286419895157 [PMID: 31903097 DOI: 10.1177/1756286419895157]
  - 20 **Ishii A**, Miyamoto S. Endovascular treatment in pregnancy. *Neurol Med Chir (Tokyo)* 2013; **53**: 541-548 [PMID: 23979050 DOI: 10.2176/nmc.53.541]



Published by **Baishideng Publishing Group Inc**  
7041 Koll Center Parkway, Suite 160, Pleasanton, CA 94566, USA

**Telephone:** +1-925-3991568

**E-mail:** [bpgoffice@wjgnet.com](mailto:bpgoffice@wjgnet.com)

**Help Desk:** <https://www.f6publishing.com/helpdesk>

<https://www.wjgnet.com>

