

World Journal of *Clinical Cases*

World J Clin Cases 2022 January 7; 10(1): 1-396



Contents

Weekly Volume 10 Number 1 January 7, 2022

MINIREVIEWS

- 1 Omicron variant (B.1.1.529) of SARS-CoV-2: Mutation, infectivity, transmission, and vaccine resistance
Ren SY, Wang WB, Gao RD, Zhou AM
- 12 Hepatitis B virus reactivation in rheumatoid arthritis
Wu YL, Ke J, Zhang BY, Zhao D
- 23 Paradoxical role of interleukin-33/suppressor of tumorigenicity 2 in colorectal carcinogenesis: Progress and therapeutic potential
Huang F, Chen WY, Ma J, He XL, Wang JW

ORIGINAL ARTICLE

Case Control Study

- 35 Changes in rheumatoid arthritis under ultrasound before and after sinomenine injection
Huang YM, Zhuang Y, Tan ZM
- 43 Benefits of multidisciplinary collaborative care team-based nursing services in treating pressure injury wounds in cerebral infarction patients
Gu YH, Wang X, Sun SS

Retrospective Study

- 51 Outcomes and complications of open, laparoscopic, and hybrid giant ventral hernia repair
Yang S, Wang MG, Nie YS, Zhao XF, Liu J
- 62 Surgical resection of intradural extramedullary tumors in the atlantoaxial spine *via* a posterior approach
Meng DH, Wang JQ, Yang KX, Chen WY, Pan C, Jiang H
- 71 Vancomycin lavage for the incidence of acute surgical site infection following primary total hip arthroplasty and total knee arthroplasty
Duan MY, Zhang HZ
- 79 Distribution of transient receptor potential vanilloid-1 channels in gastrointestinal tract of patients with morbid obesity
Atas U, Erin N, Tazegul G, Elpek GO, Yıldırım B
- 91 Value of neutrophil-lymphocyte ratio in evaluating response to percutaneous catheter drainage in patients with acute pancreatitis
Gupta P, Das GC, Bansal A, Samanta J, Mandavdhare HS, Sharma V, Naseem S, Gupta V, Yadav TD, Dutta U, Varma N, Sandhu MS, Kochhar R

- 104** Influence of overweight and obesity on the mortality of hospitalized patients with community-acquired pneumonia
Wang N, Liu BW, Ma CM, Yan Y, Su QW, Yin FZ
- 117** Minimally invasive open reduction of greater tuberosity fractures by a modified suture bridge procedure
Kong LP, Yang JJ, Wang F, Liu FX, Yang YL
- 128** Increased levels of lactate dehydrogenase and hypertension are associated with severe illness of COVID-19
Jin ZM, Shi JC, Zheng M, Chen QL, Zhou YY, Cheng F, Cai J, Jiang XG
- 136** Age, alcohol, sex, and metabolic factors as risk factors for colonic diverticulosis
Yan Y, Wu JS, Pan S
- 143** Evaluation of right-to-left shunt on contrast-enhanced transcranial Doppler in patent foramen ovale-related cryptogenic stroke: Research based on imaging
Xiao L, Yan YH, Ding YF, Liu M, Kong LJ, Hu CH, Hui PJ
- 155** Characterization of focal hypermetabolic thyroid incidentaloma: An analysis with F-18 fluorodeoxyglucose positron emission tomography/computed tomography parameters
Lee H, Chung YS, Lee JH, Lee KY, Hwang KH

Clinical Trials Study

- 166** Low-dose intralesional injection of 5-fluorouracil and triamcinolone reduces tissue resident memory T cells in chronic eczema
Wu Y, Wang GJ, He HQ, Qin HH, Shen WT, Yu Y, Zhang X, Zhou ML, Fei JB

Observational Study

- 177** Alterations in blink and masseter reflex latencies in older adults with neurocognitive disorder and/or diabetes mellitus
Bricio-Barrios JA, Rios-Bracamontes E, Rios-Silva M, Huerta M, Serrano-Moreno W, Barrios-Navarro JE, Ortiz GG, Huerta-Trujillo M, Guzmán-Esquivel J, Trujillo X
- 189** Predicting adolescent perfectionism: The role of socio-demographic traits, personal relationships, and media
Livazović G, Kuzmanović K
- 205** Novel m.4268T>C mutation in the mitochondrial tRNA^{Leu} gene is associated with hearing loss in two Chinese families
Zhao LJ, Zhang ZL, Fu Y
- 217** Superior mesenteric venous thrombosis: Endovascular management and outcomes
Alnahhal K, Toskich BB, Nussbaum S, Li Z, Erben Y, Hakaim AG, Farres H

Randomized Controlled Trial

- 227** Zinc carnosine-based modified bismuth quadruple therapy *vs* standard triple therapy for *Helicobacter pylori* eradication: A randomized controlled study
Ibrahim N, El Said H, Choukair A

CASE REPORT

- 236 Acquired coagulation dysfunction resulting from vitamin K-dependent coagulation factor deficiency associated with rheumatoid arthritis: A case report
Huang YJ, Han L, Li J, Chen C
- 242 Intraoperative thromboelastography-guided transfusion in a patient with factor XI deficiency: A case report
Guo WJ, Chen WY, Yu XR, Shen L, Huang YG
- 249 Positron emission tomography and magnetic resonance imaging combined with computed tomography in tumor volume delineation: A case report
Zhou QP, Zhao YH, Gao L
- 254 Successful response to camrelizumab in metastatic bladder cancer: A case report
Xie C, Yuan X, Chen SH, Liu ZY, Lu DL, Xu F, Chen ZQ, Zhong XM
- 260 HER2 changes to positive after neoadjuvant chemotherapy in breast cancer: A case report and literature review
Wang L, Jiang Q, He MY, Shen P
- 268 Hyper-accuracy three-dimensional reconstruction as a tool for better planning of retroperitoneal liposarcoma resection: A case report
Ye MS, Wu HK, Qin XZ, Luo F, Li Z
- 275 Recurrent postmenopausal bleeding - just endometrial disease or ovarian sex cord-stromal tumor? A case report
Wang J, Yang Q, Zhang NN, Wang DD
- 283 Complex proximal femoral fracture in a young patient followed up for 3 years: A case report
Li ZY, Cheng WD, Qi L, Yu SS, Jing JH
- 289 Bilateral Hypertrophic Olivary Degeneration after Pontine Hemorrhage: A Case Report
Zheng B, Wang J, Huang XQ, Chen Z, Gu GF, Luo XJ
- 296 Clinical characteristics and outcomes of primary intracranial alveolar soft-part sarcoma: A case report
Chen JY, Cen B, Hu F, Qiu Y, Xiao GM, Zhou JG, Zhang FC
- 304 Removal of laparoscopic cerclage stitches *via* laparotomy and rivanol-induced labour: A case report and literature review
Na XN, Cai BS
- 309 Cerebral venous sinus thrombosis in pregnancy: A case report
Zhou B, Huang SS, Huang C, Liu SY
- 316 Eustachian tube teratoma: A case report
Li JY, Sun LX, Hu N, Song GS, Dou WQ, Gong RZ, Li CT

- 323** Protein-losing enteropathy caused by a jejunal ulcer after an internal hernia in Petersen's space: A case report
Yasuda T, Sakurazawa N, Kuge K, Omori J, Arai H, Kakinuma D, Watanabe M, Suzuki H, Iwakiri K, Yoshida H
- 331** Lunate dislocation with avulsed triquetral fracture: A case report
Li LY, Lin CJ, Ko CY
- 338** Clinical manifestations and prenatal diagnosis of Ullrich congenital muscular dystrophy: A case report
Hu J, Chen YH, Fang X, Zhou Y, Chen F
- 345** Diagnosis and guidance of treatment of breast cancer cutaneous metastases by multiple needle biopsy: A case report
Li ZH, Wang F, Zhang P, Xue P, Zhu SJ
- 353** Test of incremental respiratory endurance as home-based, stand-alone therapy in chronic obstructive pulmonary disease: A case report
Dosbaba F, Hartman M, Batalik L, Brat K, Plutinsky M, Hnatiak J, Formiga MF, Cahalin LP
- 361** Diagnostic and surgical challenges of progressive neck and upper back painless masses in Madelung's disease: A case report and review of literature
Yan YJ, Zhou SQ, Li CQ, Ruan Y
- 371** Suspected cerebrovascular air embolism during endoscopic esophageal varices ligation under sedation with fatal outcome: A case report
Zhang CMJ, Wang X
- 381** An atypical primary malignant melanoma arising from the cervical nerve root: A case report and review of literature
Shi YF, Chen YQ, Chen HF, Hu X
- 388** Epidural blood patch for spontaneous intracranial hypotension with subdural hematoma: A case report and review of literature
Choi SH, Lee YY, Kim WJ

ABOUT COVER

Editorial Board Member of *World Journal of Clinical Cases*, Ravi Kant, MD, Associate Professor, Division of Endocrinology, Diabetes and Metabolism, Medical University of South Carolina/Anmed Campus, Anderson, SC 29621, United States. rkant82@hotmail.com

AIMS AND SCOPE

The primary aim of *World Journal of Clinical Cases* (WJCC, *World J Clin Cases*) is to provide scholars and readers from various fields of clinical medicine with a platform to publish high-quality clinical research articles and communicate their research findings online.

WJCC mainly publishes articles reporting research results and findings obtained in the field of clinical medicine and covering a wide range of topics, including case control studies, retrospective cohort studies, retrospective studies, clinical trials studies, observational studies, prospective studies, randomized controlled trials, randomized clinical trials, systematic reviews, meta-analysis, and case reports.

INDEXING/ABSTRACTING

The WJCC is now indexed in Science Citation Index Expanded (also known as SciSearch®), Journal Citation Reports/Science Edition, Scopus, PubMed, and PubMed Central. The 2021 Edition of Journal Citation Reports® cites the 2020 impact factor (IF) for WJCC as 1.337; IF without journal self cites: 1.301; 5-year IF: 1.742; Journal Citation Indicator: 0.33; Ranking: 119 among 169 journals in medicine, general and internal; and Quartile category: Q3. The WJCC's CiteScore for 2020 is 0.8 and Scopus CiteScore rank 2020: General Medicine is 493/793.

RESPONSIBLE EDITORS FOR THIS ISSUE

Production Editor: Lin-YuTong Wang; Production Department Director: Xiang Li; Editorial Office Director: Jin-Lai Wang.

NAME OF JOURNAL

World Journal of Clinical Cases

ISSN

ISSN 2307-8960 (online)

LAUNCH DATE

April 16, 2013

FREQUENCY

Weekly

EDITORS-IN-CHIEF

Bao-Gan Peng

EDITORIAL BOARD MEMBERS

<https://www.wjgnet.com/2307-8960/editorialboard.htm>

PUBLICATION DATE

January 7, 2022

COPYRIGHT

© 2022 Baishideng Publishing Group Inc

INSTRUCTIONS TO AUTHORS

<https://www.wjgnet.com/bpg/gerinfo/204>

GUIDELINES FOR ETHICS DOCUMENTS

<https://www.wjgnet.com/bpg/GerInfo/287>

GUIDELINES FOR NON-NATIVE SPEAKERS OF ENGLISH

<https://www.wjgnet.com/bpg/gerinfo/240>

PUBLICATION ETHICS

<https://www.wjgnet.com/bpg/GerInfo/288>

PUBLICATION MISCONDUCT

<https://www.wjgnet.com/bpg/gerinfo/208>

ARTICLE PROCESSING CHARGE

<https://www.wjgnet.com/bpg/gerinfo/242>

STEPS FOR SUBMITTING MANUSCRIPTS

<https://www.wjgnet.com/bpg/GerInfo/239>

ONLINE SUBMISSION

<https://www.f6publishing.com>



Retrospective Study

Vancomycin lavage for the incidence of acute surgical site infection following primary total hip arthroplasty and total knee arthroplasty

Ming-Yi Duan, Hang-Zhou Zhang

ORCID number: Ming-Yi Duan 0000-0003-0406-0302; Hang-Zhou Zhang 0000-0002-2301-5059.

Author contributions: Duan MY, Zhang HZ contributed equally to this work; and all authors have read and approve the final manuscript.

Institutional review board statement: The study was reviewed and approved by the First Affiliated Hospital of China Medical University Institutional Review Board (Approval No.AF-SOP-07-1.1-01).

Informed consent statement: All study participants, or their legal guardian, provided informed written consent prior to study enrollment.

Conflict-of-interest statement: No conflict of interest.

Data sharing statement: No additional data are available.

Country/Territory of origin: China

Specialty type: Orthopedics

Provenance and peer review: Unsolicited article; Externally peer reviewed.

Peer-review model: Single blind

Peer-review report's scientific

Ming-Yi Duan, Hang-Zhou Zhang, Department of Orthopedics, Joint Surgery and Sports Medicine, First Affiliated Hospital of China Medical University, Shenyang 110001, Liaoning Province, China

Corresponding author: Hang-Zhou Zhang, MD, Doctor, Department of Orthopedics, Joint Surgery and Sports Medicine, First Affiliated Hospital of China Medical University, No. 155 Nanjing North Street, Shenyang 110001, Liaoning Province, China. zhanghz1000@sina.com

Abstract

BACKGROUND

Surgical site infection is a rare but serious complication associated with total joint arthroplasty (TJA). There are limited data on the effectiveness of intrawound irrigation with vancomycin solution (1000 mg/L; 2 L) before wound closure for preventing acute surgical site infection following primary total hip arthroplasty (THA) and total knee arthroplasty (TKA).

AIM

To investigate the effectiveness of prophylactic intraoperative application of vancomycin (1000 mg/L; 2 L) solution vs. plain irrigation in reducing the incidence of acute surgical site infection following primary THA and TKA.

METHODS

A retrospective review of 2725 consecutive patients undergoing THA or TKA from January 2012–December 2019 was performed. These patients received either intrawound irrigation with normal saline before wound closure between January 2012 and December 2015 (group 1, 1018 patients; 453 undergoing THA and 565 undergoing TKA) or intrawound irrigation with vancomycin solution (1000 mg/L) before wound closure between January 2016 and December 2019 (group 2, 1175 patients; 512 undergoing THA and 663 undergoing TKA). The outcomes were the incidences of postoperative surgical site infection and wound healing complications within 3 mo of primary TJA.

RESULTS

There were no significant demographic differences between the 2 groups. There was a significantly higher incidence of acute infection at the surgical site in patients who received intrawound irrigation with normal saline before wound closure than in those who received intrawound irrigation with vancomycin solution (1000 mg/L; 2 L) before wound closure (overall incidence of infection:

quality classification

Grade A (Excellent): 0

Grade B (Very good): 0

Grade C (Good): C

Grade D (Fair): 0

Grade E (Poor): 0

Open-Access: This article is an open-access article that was selected by an in-house editor and fully peer-reviewed by external reviewers. It is distributed in accordance with the Creative Commons Attribution NonCommercial (CC BY-NC 4.0) license, which permits others to distribute, remix, adapt, build upon this work non-commercially, and license their derivative works on different terms, provided the original work is properly cited and the use is non-commercial. See: <http://creativecommons.org/licenses/by-nc/4.0/>

Received: August 10, 2021

Peer-review started: August 10, 2021

First decision: September 2, 2021

Revised: October 21, 2021

Accepted: November 23, 2021

Article in press: November 23, 2021

Published online: January 7, 2022

P-Reviewer: Duca FD

S-Editor: Wang JL

L-Editor: A

P-Editor: Wang JL



group 1, 2.46% *vs* group 2, 0.09%, $P < 0.001$). There was no significant difference in the incidence of wound healing complications between the two groups.

CONCLUSION

Prophylactic irrigation with vancomycin solution (1000 mg/L; 2 L) significantly decreases the incidence of acute surgical site infection after primary TJA. This strategy is a safe, efficacious, and inexpensive method for reducing the incidence of acute surgical site infection after TJA.

Key Words: Total joint arthroplasty; Total hip arthroplasty; Total knee arthroplasty; Vancomycin irrigation; Postoperative acute wound infection; Acute surgical site infection

©The Author(s) 2022. Published by Baishideng Publishing Group Inc. All rights reserved.

Core Tip: Prophylactic irrigation with vancomycin solution (1000 mg/L; 2 L) significantly decreases the incidence of acute surgical site infection after primary total joint arthroplasty (TJA). This represents a safe, efficacious, and inexpensive method for reducing the incidence of acute surgical site infection after TJA.

Citation: Duan MY, Zhang HZ. Vancomycin lavage for the incidence of acute surgical site infection following primary total hip arthroplasty and total knee arthroplasty. *World J Clin Cases* 2022; 10(1): 71-78

URL: <https://www.wjgnet.com/2307-8960/full/v10/i1/71.htm>

DOI: <https://dx.doi.org/10.12998/wjcc.v10.i1.71>

INTRODUCTION

Total joint arthroplasty (TJA) is highly effective for reducing pain and improving quality of life in patients requiring joint replacement[1]. However, implant infections remain a relatively rare but devastating complication associated with this procedure[2-5]. Although improved sterile techniques, wound protection, minimization of contamination, and prophylactic antibiotics (systemic or local antibiotics) have markedly reduced the incidence of surgical site infection following TJA, implants may become infected by direct contact with an infected wound during the procedure or by spread of a superficial wound infection to the fascia lata or bloodborne contamination during or after the procedure[6]. Intraoperative contamination of the surgical wound by bacterial seeding from the air of the operating room, the skin of the patient, or fallen debris or hair from surgical staff is an important cause of surgical site infection following TJA[7-10]. In addition, TJA can lead to hematoma formation, which creates conditions that encourage bacterial growth[10,11], and bacteria can form biofilms that protect them from antimicrobials and the patients' immune response, thus making eradication difficult.

The incidence of postoperative wound infection is estimated to be 0.5%-2% following primary TJA and 3%-7% following revision TJA[6,7,12]. Local application of an antibiotic solution may reduce the contamination of wounds with commensal bacteria from the patient's skin or with airborne bacteria during TJA. Prior studies have demonstrated that compared with plain irrigation, lavage of the surgical wound with diluted vancomycin before closure can decrease the rate of infection following arthroscopic surgery[13-20]. Therefore, the purpose of this retrospective study was to investigate the effectiveness of prophylactic intraoperative application of vancomycin (1000 mg/L; 2 L) solution *vs*. plain irrigation in reducing the incidence of acute surgical site infection following primary total hip arthroplasty (THA) and total knee arthroplasty (TKA).

MATERIALS AND METHODS

After institutional review board approval, we reviewed data for 2725 consecutive patients undergoing primary THA or primary TKA between January 2012 and

December 2019 with a minimum of 3 mo of follow-up. One surgeon performed all the procedures in the given time period. Patients were identified, and data related to patient demographics, baseline characteristics, and comorbidities and operative data were collected from medical records. These cases were retrospectively reviewed for the occurrence of surgical site infections within 3 mo after surgery.

Each patient received standard antibiotic prophylaxis (2 g cefazolin) approximately 30 min before surgery. Antibiotic-loaded cement was used in patients with a higher risk for infection due to a body mass index of > 35, diabetes mellitus, or rheumatoid arthritis. The first 1018 patients (453 undergoing THA and 565 undergoing TKA) received irrigation with 2 L of normal saline after hardware implantation during THA between January 2012 and December 2015 (control group); the subsequent 1175 patients (512 undergoing THA and 663 undergoing TKA) received irrigation with 2 L of vancomycin (1000 mg/L) before wound closure between January 2016 and December 2019 (vancomycin group). Postoperatively, all patients were provided routine antibiotics (1000 mg cefazolin/8 h or 1000 mg vancomycin/12 h for patients who were allergic to penicillin) for 24 h (Figure 1).

Acute infections that occurred within the period of interest were classified as superficial or deep. Superficial infections were defined as infections in which the sutures and anastomosis of the fascial layer were intact without pus or fistula draining from the subfascial layer during debridement. Deep infections were defined as infections involving the drainage of pus from the subfascial layer, with the subfascial layer being open. Superficial wound infections were managed with superficial debridement and antibiotics. Deep infections were treated with debridement, an antibiotic-loaded bone cement spacer, and two-stage revision. Postoperative wound complications such as minor fat liquefaction or erythema were treated with routine wound care. The 3-mo period investigated in this study was defined as the acute infection phase based on the authors' clinical experience, which indicates that 95% of infections occur within this time frame.

Statistical analysis

All analyses were conducted using SPSS version 21.0 software. Between-group differences for continuous variables were evaluated using Student's *t*-test. Between-group differences in the rate of surgical site infection were assessed using the χ^2 test with Yates' correction or the χ^2 test alone when the sample size was < 20 or any value was < 5. Statistical significance was defined as $P < 0.05$.

RESULTS

There were no significant differences in sex, age, duration of surgical procedure, or use of antibiotic-loaded cement between the two groups (Table 1). There was a significantly higher incidence of acute infection at the surgical site in patients who received intrawound irrigation with normal saline prior to wound closure than in patients who received intrawound irrigation with vancomycin solution (1000 mg/L; 2 L) prior to wound closure (Table 2). The overall incidence of infection in group 1 was 2.46%, and that in group 2 was 0.09% ($P < 0.001$).

All patients with acute infection at the surgical site presented with surgical site pain and fever. All 25 patients with infection at the surgical site yielded positive bacteriologic cultures. In the normal saline group, sixteen patients were positive for *Staphylococcus epidermidis*, and 9 patients were positive for *Staphylococcus aureus*. In this same group, 80% (20/25) of the patients with postoperative infection developed the infection within 3 wk (9-20 d).

Only one patient in the vancomycin group had an acute superficial infection at the surgical site (occurring within 2 wk), and the infecting organism was *Staphylococcus epidermidis*.

No significant differences in wound healing or the incidence of complications were observed between the vancomycin group and the normal saline group.

DISCUSSION

This retrospective review of patients undergoing primary TJA, which was undertaken by a single-surgeon team over a ten-year period, suggests that compared with irrigation with normal saline alone, intraoperative irrigation with vancomycin solution

Table 1 Summary of the demographic data

Risk factor	Group 1 (n = 1018)	Group 2 (n = 1175)	P value
Sex, male (%)	46.95	48.09	0.597 ¹
Age (mean ± SD), yr	59.59 ± 10.25	59.98 ± 10.38	0.370 ²
BMI (mean ± SD), kg/m ²	27.50 ± 4.67	27.83 ± 4.82	0.102 ²
Antibiotic-loaded cement usage (%)	18.96	20.26	0.446 ¹
Indication for primary TJA (%)			
Osteoarthritis	81.34	80.85	0.734 ¹
Avascular necrosis	4.91	4.34	0.525 ¹
Inflammatory	2.95	2.13	0.221 ¹
Other	10.80	12.68	0.175 ¹

¹Pearson χ^2 test.²t-test.

Group 1: Irrigation with normal saline; Group 2: Irrigation with vancomycin solution (1000 mg/L; 2 L); the values are presented as numbers (%) or means ± SD. BMI: Body mass index; TJA: Total joint arthroplasty.

Table 2 Incidence of acute surgical site infection, n (%)

Risk factor	Group 1 (n = 1018)	Group 2 (n = 1175)	P value
Superficial infection rate	6 (0.59)	1 (0.09)	0.037 ¹
Deep infection rate	19 (1.86)	0 (0)	< 0.001 ¹
Overall infection rate	25 (2.46)	1 (0.09)	< 0.001 ¹

¹Pearson χ^2 test.

Group 1: Irrigation with normal saline. Group 2: Irrigation with vancomycin.

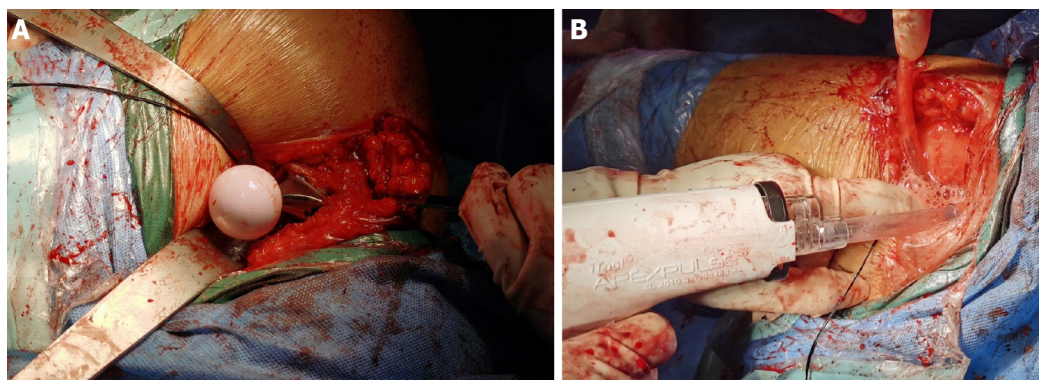


Figure 1 Postoperatively, all patients were provided routine antibiotics for 24 h. A: Total hip arthroplasty wound; B: Intrawound irrigation with vancomycin solution before wound closure.

(1000 mg/L; 2 L) can significantly reduce the incidence of acute infection of the surgical site following primary THA and primary TKA (2.46% *vs* 0.09%, $P < 0.01$).

High concentrations of antibiotics in the surgical wound are necessary to prevent infection throughout the operation from incision to wound closure[18]. Unfortunately, intravenous application yields a relatively low concentration of antibiotics at the surgical site over time (generally above the minimal inhibitory concentration for < one hour)[18]. Minimal toxicity is not associated with the generation of microbial resistance[21,22]. Surgical wounds contain areas that are not reachable by intravenously delivered antibiotics (such as hematomas and ischemic areas).

Intraoperative contamination of the wound is an important risk factor for surgical site infection after joint replacement[7-10]. Wound contamination may result from commensal organisms (present on the patient's skin), airborne bacteria, and occasionally, debris or hair falling from the surgical staff[7-10]. Prophylactic antibiotics have been used to reduce surgical site infections. However, the overuse and misuse of antibiotics in recent years has led to the development of antibiotic-resistant pathogens. Irrigation of surgical wounds with antiseptics has been used to prevent infections during the treatment of open fractures and other surgically related conditions. Vancomycin is an effective prophylactic systemic antibiotic that is used during total knee or hip arthroplasty and drastically reduces the risk of infection[14-17]. Intrawound application of vancomycin powder has been proven to reduce infection rates following spine surgery and to decrease the incidence of surgical site infections; however, the data regarding the use of vancomycin powder during primary TJA are controversial[19,21-25]. In 2010, a prospective, controlled study evaluating the safety and effectiveness of an absorbable calcium hydroxyapatite (Hac) layer mixed with vancomycin and applied to the articular surface of prosthetic implants in preventing deep infections after non-cemented TKA was conducted[19]. Vancomycin paste (a mixture of 2 g absorbable Hac and 1-2 g vancomycin) was applied to the implants in the study group. The rate of early infection was 0% in the study group and 4.1% in the control group. This study shows that local anti-infection treatment is an effective supplement to systemic antibiotic therapy for the prevention of deep infections in non-cemented TKA. The pharmacokinetics of vancomycin powder in thirty-four TJA patients who received 2 g of vancomycin powder intraoperatively were investigated [23]. Serum and wound concentrations were measured at multiple intervals in the 24-h period after closure. The wound concentrations were 922 µg/mL 3 h after closure and 207 µg/mL at 24 h. Vancomycin powder application during TJA produced high therapeutic intrawound concentrations while yielding low systemic levels. However, in 2017, the safety of using vancomycin powder to reduce infection rates was investigated by reviewing the incidence of acute postoperative complications[24]. It was found that compared with control treatment, vancomycin powder was associated with an increased rate of sterile wound complications (4.4% *vs* 0%)[24]. The rate of prosthetic joint infection (PJI) was decreased with the use of vancomycin powder (5.5% *vs* 0.7%). Researchers therefore do not recommend for or against the use of vancomycin powder at the time of wound closure to prevent PJI. Furthermore, a controlled trial was conducted to investigate the efficacy and side effects of local high-dose vancomycin powder application to the joint to prevent PJI following TKA[25]. They found that intrawound administration of vancomycin powder did not decrease the occurrence of PJI following primary TKA and caused aseptic wound complications. Thus, the use of intrawound and intravenous agents for the prevention of PJI after primary TKA is not recommended.

In the present study, no surgical site infections occurred during the 3 mo after surgery in primary TJA patients who received intrawound irrigation with vancomycin solution before wound closure. Intrawound irrigation with vancomycin solution (1000 mg/L; 2 L) before wound closure may create a potent bactericidal environment by producing a high local tissue concentration of antibiotics. A similar technique during TJA was recently described[18]. A study involving > 2000 patients was performed to evaluate the effectiveness of local antibiotic irrigation during surgery for the prevention of acute postoperative infections after TJA. The intraoperative protocol included irrigation with normal saline containing 1000 mg/L vancomycin and 250000 units/L polymyxin at a rate of 2 L per hour. The researchers found that the use of antibiotic irrigation during arthroplasty surgery was highly effective in preventing infection and reported that irrigation with local antibiotics can prevent acute infection, even with prolonged operating times during revision procedures. However, there was a lack of a control group in the study.

This study showed that the prophylactic use of vancomycin solution can significantly decrease the incidence of acute surgical site infection following primary THA and TKA. However, the present investigation had several limitations. First, it was a retrospective study. Second, all patients had a minimum follow-up of 3 mo (acute infection); a longer follow-up period will help detect delayed infections. Third, other factors, such as hip joint materials (ceramic-ceramic and metal-polyethylene), affected the scores in the study, which might have influenced the results between the 2 groups. A prospective, double-blind randomized controlled trial would eliminate these potentially confounding factors.

CONCLUSION

Prophylactic irrigation with vancomycin solution (1000 mg/L; 2 L) significantly reduces the incidence of infection after primary TJA. This strategy is a safe, efficacious, and inexpensive method for reducing the incidence of surgical site infection after TJA.

ARTICLE HIGHLIGHTS

Research background

Total joint arthroplasty (TJA) is highly effective for reducing pain and improving quality of life in patients requiring joint replacement. However, implant infections remain a relatively rare but devastating complication associated with this procedure. Although improved sterile techniques, wound protection, minimization of contamination, and prophylactic antibiotics (systemic or local antibiotics) have markedly reduced the incidence of surgical site infection following TJA, implants may become infected by direct contact with an infected wound during the procedure or by spread of a superficial wound infection to the fascia lata or bloodborne contamination during or after the procedure. Intraoperative contamination of the surgical wound by bacterial seeding from the air of the operating room, the skin of the patient, or fallen debris or hair from surgical staff is an important cause of surgical site infection following TJA. In addition, TJA can lead to hematoma formation, which creates conditions that encourage bacterial growth, and bacteria can form biofilms that protect them from antimicrobials and the patients' immune response, thus making eradication difficult.

Research motivation

The incidence of postoperative wound infection is estimated to be 0.5%-2% following primary TJA and 3%-7% following revision TJA. Local application of an antibiotic solution may reduce the contamination of wounds with commensal bacteria from the patient's skin or with airborne bacteria during TJA. Prior studies have demonstrated that compared with plain irrigation, lavage of the surgical wound with diluted vancomycin before closure can decrease the rate of infection following arthroscopic surgery.

Research objectives

Prior studies have demonstrated that compared with plain irrigation, lavage of the surgical wound with diluted vancomycin before closure can decrease the rate of infection following arthroscopic surgery.

Research methods

One surgeon performed all the procedures in the given time period. Patients were identified, and data related to patient demographics, baseline characteristics, and comorbidities and operative data were collected from medical records. These cases were retrospectively reviewed for the occurrence of surgical site infections within 3 mo after surgery. Each patient received standard antibiotic prophylaxis (2 g cefazolin) approximately 30 min before surgery. Antibiotic-loaded cement was used in patients with a higher risk for infection due to a body mass index of > 35, diabetes mellitus, or rheumatoid arthritis.

Research results

There were no significant differences in sex, age, duration of surgical procedure, or use of antibiotic-loaded cement between the two groups. There was a significantly higher incidence of acute infection at the surgical site in patients who received intrawound irrigation with normal saline prior to wound closure than in patients who received intrawound irrigation with vancomycin solution prior to wound closure. The overall incidence of infection in group 1 was 2.46%, and that in group 2 was 0.09%.

Research conclusions

Prophylactic irrigation with vancomycin solution significantly reduces the incidence of infection after primary TJA. This strategy is a safe, efficacious, and inexpensive method for reducing the incidence of surgical site infection after TJA.

Research perspectives

Prophylactic irrigation with vancomycin solution is a safe, efficacious, and inexpensive method for reducing the incidence of surgical site infection after TJA.

REFERENCES

- 1 **Småbrekke A**, Espehaug B, Havelin LI, Furnes O. Operating time and survival of primary total hip replacements: an analysis of 31,745 primary cemented and uncemented total hip replacements from local hospitals reported to the Norwegian Arthroplasty Register 1987-2001. *Acta Orthop Scand* 2004; **75**: 524-532 [PMID: [15513482](#) DOI: [10.1080/00016470410001376](#)]
- 2 **Davis JS**. Management of bone and joint infections due to *Staphylococcus aureus*. *Intern Med J* 2005; **35** Suppl 2: S79-S96 [PMID: [16271064](#) DOI: [10.1111/j.1444-0903.2005.00982.x](#)]
- 3 **Perencevich EN**, Sands KE, Cosgrove SE, Guadagnoli E, Meara E, Platt R. Health and economic impact of surgical site infections diagnosed after hospital discharge. *Emerg Infect Dis* 2003; **9**: 196-203 [PMID: [12603990](#) DOI: [10.3201/eid0902.020232](#)]
- 4 **Krause R**, Hoenigl M, Valentin T, Zollner-Schwetz I. Debridement, antibiotic therapy, and implant retention in *Staphylococcus aureus* prosthetic joint infections. *Clin Infect Dis* 2013; **56**: 1842-1843 [PMID: [23457078](#) DOI: [10.1093/cid/cit115](#)]
- 5 **Zimmerli W**, Trampuz A, Ochsner PE. Prosthetic-joint infections. *N Engl J Med* 2004; **351**: 1645-1654 [PMID: [15483283](#) DOI: [10.1056/NEJMr040181](#)]
- 6 **Gaine WJ**, Ramamohan NA, Hussein NA, Hullin MG, McCreath SW. Wound infection in hip and knee arthroplasty. *J Bone Joint Surg Br* 2000; **82**: 561-565 [PMID: [10855883](#) DOI: [10.1302/0301-620x.82b4.10305](#)]
- 7 **Ridgeway S**, Wilson J, Charlet A, Kafatos G, Pearson A, Coello R. Infection of the surgical site after arthroplasty of the hip. *J Bone Joint Surg Br* 2005; **87**: 844-850 [PMID: [15911671](#) DOI: [10.1302/0301-620X.87B6.15121](#)]
- 8 **McLorinan GC**, Glenn JV, McMullan MG, Patrick S. Propionibacterium acnes wound contamination at the time of spinal surgery. *Clin Orthop Relat Res* 2005; **67**: 73 [PMID: [16056028](#) DOI: [10.1097/00003086-200508000-00012](#)]
- 9 **Charnley J**, Eftekhari N. Postoperative infection in total prosthetic replacement arthroplasty of the hip-joint. With special reference to the bacterial content of the air of the operating room. *Br J Surg* 1969; **56**: 641-649 [PMID: [5808372](#) DOI: [10.1002/bjs.1800560902](#)]
- 10 **Soohoo NF**, Zingmond DS, Lieberman JR, Ko CY. Optimal timeframe for reporting short-term complication rates after total knee arthroplasty. *J Arthroplasty* 2006; **21**: 705-711 [PMID: [16877157](#) DOI: [10.1016/j.arth.2005.08.015](#)]
- 11 **Galat DD**, McGovern SC, Hanssen AD, Larson DR, Harrington JR, Clarke HD. Early return to surgery for evacuation of a postoperative hematoma after primary total knee arthroplasty. *J Bone Joint Surg Am* 2008; **90**: 2331-2336 [PMID: [18978401](#) DOI: [10.2106/JBJS.G.01370](#)]
- 12 **Jämsen E**, Huhtala H, Puolakka T, Moilanen T. Risk factors for infection after knee arthroplasty. A register-based analysis of 43,149 cases. *J Bone Joint Surg Am* 2009; **91**: 38-47 [PMID: [19122077](#) DOI: [10.2106/JBJS.G.01686](#)]
- 13 **Davis N**, Curry A, Gambhir AK, Panigrahi H, Walker CR, Wilkins EG, Worsley MA, Kay PR. Intraoperative bacterial contamination in operations for joint replacement. *J Bone Joint Surg Br* 1999; **81**: 886-889 [PMID: [10530856](#) DOI: [10.1302/0301-620x.81b5.9545](#)]
- 14 **Pérez-Prieto D**, Portillo ME, Torres-Claramunt R, Pelfort X, Hinarejos P, Monllau JC. Contamination occurs during ACL graft harvesting and manipulation, but it can be easily eradicated. *Knee Surg Sports Traumatol Arthrosc* 2018; **26**: 558-562 [PMID: [28988312](#) DOI: [10.1007/s00167-017-4735-z](#)]
- 15 **Baron JE**, Shamrock AG, Cates WT, Cates RA, An Q, Wolf BR, Bollier MJ, Duchman KR, Westermann RW. Graft Preparation with Intraoperative Vancomycin Decreases Infection After ACL Reconstruction: A Review of 1,640 Cases. *J Bone Joint Surg Am* 2019; **101**: 2187-2193 [PMID: [31609893](#) DOI: [10.2106/JBJS.19.00270](#)]
- 16 **Offerhaus C**, Balke M, Hente J, Gehling M, Blendl S, Höher J. Vancomycin pre-soaking of the graft reduces postoperative infection rate without increasing risk of graft failure and arthrofibrosis in ACL reconstruction. *Knee Surg Sports Traumatol Arthrosc* 2019; **27**: 3014-3021 [PMID: [30666370](#) DOI: [10.1007/s00167-018-5323-6](#)]
- 17 **Figuerola D**, Figuerola F, Calvo R, Lopez M, Goñi I. Presoaking of Hamstring Autografts in Vancomycin Decreases the Occurrence of Infection Following Primary Anterior Cruciate Ligament Reconstruction. *Orthop J Sports Med* 2019; **7**: 2325967119871038 [PMID: [31598528](#) DOI: [10.1177/2325967119871038](#)]
- 18 **Whiteside LA**. Prophylactic peri-operative local antibiotic irrigation. *Bone Joint J* 2016; **98-B**: 23-26 [PMID: [26733636](#) DOI: [10.1302/0301-620X.98B1.36357](#)]
- 19 **Assor M**. Noncemented total knee arthroplasty with a local prophylactic anti-infection agent: a prospective series of 135 cases. *Can J Surg* 2010; **53**: 47-50 [PMID: [20100413](#)]
- 20 **Patel NN**, Guild GN 3rd, Kumar AR. Intrawound vancomycin in primary hip and knee arthroplasty: a safe and cost-effective means to decrease early periprosthetic joint infection. *Arthroplast Today* 2018; **4**: 479-483 [PMID: [30560180](#) DOI: [10.1016/j.artd.2018.07.011](#)]

- 21 **Deirmengian C**, Kardos K, Kilmartin P, Cameron A, Schiller K, Parvizi J. Diagnosing periprosthetic joint infection: has the era of the biomarker arrived? *Clin Orthop Relat Res* 2014; **472**: 3254-3262 [PMID: [24590839](#) DOI: [10.1007/s11999-014-3543-8](#)]
- 22 **Greenblatt DJ**, Koch-Weser J. Clinical pharmacokinetics (second of two parts). *N Engl J Med* 1975; **293**: 964-970 [PMID: [1101062](#) DOI: [10.1056/NEJM197511062931905](#)]
- 23 **Johnson JD**, Nessler JM, Horazdovsky RD, Vang S, Thomas AJ, Marston SB. Serum and Wound Vancomycin Levels After Intrawound Administration in Primary Total Joint Arthroplasty. *J Arthroplasty* 2017; **32**: 924-928 [PMID: [27633945](#) DOI: [10.1016/j.arth.2015.10.015](#)]
- 24 **Dial BL**, Lampley AJ, Green CL, Hallows R. Intrawound Vancomycin Powder in Primary Total Hip Arthroplasty Increases Rate of Sterile Wound Complications. *Hip Pelvis* 2018; **30**: 37-44 [PMID: [29564296](#) DOI: [10.5371/hp.2018.30.1.37](#)]
- 25 **Hanada M**, Nishikino S, Hotta K, Furuhashi H, Hoshino H, Matsuyama Y. Intrawound vancomycin powder increases post-operative wound complications and does not decrease periprosthetic joint infection in primary total and unicompartmental knee arthroplasties. *Knee Surg Sports Traumatol Arthrosc* 2019; **27**: 2322-2327 [PMID: [30968239](#) DOI: [10.1007/s00167-019-05498-z](#)]



Published by **Baishideng Publishing Group Inc**
7041 Koll Center Parkway, Suite 160, Pleasanton, CA 94566, USA

Telephone: +1-925-3991568

E-mail: bpgoffice@wjgnet.com

Help Desk: <https://www.f6publishing.com/helpdesk>

<https://www.wjgnet.com>

