

World Journal of *Clinical Cases*

World J Clin Cases 2022 April 6; 10(10): 2976-3320



Contents

Thrice Monthly Volume 10 Number 10 April 6, 2022

REVIEW

- 2976 Gut microbiota in gastrointestinal diseases during pregnancy
Liu ZZ, Sun JH, Wang WJ
- 2990 Targeting metabolism: A potential strategy for hematological cancer therapy
Tang X, Chen F, Xie LC, Liu SX, Mai HR

MINIREVIEWS

- 3005 Elevated intra-abdominal pressure: A review of current knowledge
Łagosz P, Sokolski M, Biegus J, Tycinska A, Zymlinski R

ORIGINAL ARTICLE

Case Control Study

- 3014 Changes in corneal nerve morphology and function in patients with dry eyes having type 2 diabetes
Fang W, Lin ZX, Yang HQ, Zhao L, Liu DC, Pan ZQ
- 3027 Combined sevoflurane-dexmedetomidine and nerve blockade on post-surgical serum oxidative stress biomarker levels in thyroid cancer patients
Du D, Qiao Q, Guan Z, Gao YF, Wang Q

Retrospective Cohort Study

- 3035 Early warning prevention and control strategies to reduce perioperative venous thromboembolism in patients with gastrointestinal cancer
Lu Y, Chen FY, Cai L, Huang CX, Shen XF, Cai LQ, Li XT, Fu YY, Wei J
- 3047 Dose-response relationship between risk factors and incidence of COVID-19 in 325 hospitalized patients: A multicenter retrospective cohort study
Zhao SC, Yu XQ, Lai XF, Duan R, Guo DL, Zhu Q

Retrospective Study

- 3060 Preventive online and offline health management intervention in polycystic ovary syndrome
Liu R, Li M, Wang P, Yu M, Wang Z, Zhang GZ
- 3069 Evidence-based intervention on postoperative fear, compliance, and self-efficacy in elderly patients with hip fracture
Fu Y, Zhu LJ, Li DC, Yan JL, Zhang HT, Xuan YH, Meng CL, Sun YH
- 3078 Significance of dysplasia in bile duct resection margin in patients with extrahepatic cholangiocarcinoma: A retrospective analysis
Choe JW, Kim HJ, Kim JS

- 3088** Diagnostic value and safety of medical thoracoscopy for pleural effusion of different causes

Liu XT, Dong XL, Zhang Y, Fang P, Shi HY, Ming ZJ

Observational Study

- 3101** Oxaliplatin-induced neuropathy and colo-rectal cancer patient's quality of life: Practical lessons from a prospective cross-sectional, real-world study

Prutianu I, Alexa-Stratulat T, Cristea EO, Nicolau A, Moisuc DC, Covrig AA, Ivanov K, Croitoru AE, Miron MI, Dinu MI, Ivanov AV, Marinca MV, Radu I, Gafton B

- 3113** Breast-conserving surgery and sentinel lymph node biopsy for breast cancer and their correlation with the expression of polyligand proteoglycan-1

Li FM, Xu DY, Xu Q, Yuan Y

SYSTEMATIC REVIEWS

- 3121** Clinical significance of aberrant left hepatic artery during gastrectomy: A systematic review

Tao W, Peng D, Cheng YX, Zhang W

META-ANALYSIS

- 3131** Betel quid chewing and oral potential malignant disorders and the impact of smoking and drinking: A meta-analysis

Lin HJ, Wang XL, Tian MY, Li XL, Tan HZ

- 3143** Effects of physical exercise on the quality-of-life of patients with haematological malignancies and thrombocytopenia: A systematic review and meta-analysis

Yang YP, Pan SJ, Qiu SL, Tung TH

CASE REPORT

- 3156** Primary malignant peritoneal mesothelioma mimicking tuberculous peritonitis: A case report

Lin LC, Kuan WY, Shiu BH, Wang YT, Chao WR, Wang CC

- 3164** Endoscopic submucosal dissection combined with adjuvant chemotherapy for early-stage neuroendocrine carcinoma of the esophagus: A case report

Tang N, Feng Z

- 3170** Lymph-node-first presentation of Kawasaki disease in a 12-year-old girl with cervical lymphadenitis caused by *Mycoplasma pneumoniae*: A case report

Kim N, Choi YJ, Na JY, Oh JW

- 3178** Tuberculosis-associated hemophagocytic lymphohistiocytosis misdiagnosed as systemic lupus erythematosus: A case report

Chen WT, Liu ZC, Li MS, Zhou Y, Liang SJ, Yang Y

- 3188** Migration of a Hem-o-Lok clip to the renal pelvis after laparoscopic partial nephrectomy: A case report

Sun J, Zhao LW, Wang XL, Huang JG, Fan Y

- 3194** Ectopic intrauterine device in the bladder causing cystolithiasis: A case report
Yu HT, Chen Y, Xie YP, Gan TB, Gou X
- 3200** Giant tumor resection under ultrasound-guided nerve block in a patient with severe asthma: A case report
Liu Q, Zhong Q, Zhou NN, Ye L
- 3206** Myomatous erythrocytosis syndrome: A case report
Shu XY, Chen N, Chen BY, Yang HX, Bi H
- 3213** Middle thyroid vein tumor thrombus in metastatic papillary thyroid microcarcinoma: A case report and review of literature
Gui Y, Wang JY, Wei XD
- 3222** Severe pneumonia and acute myocardial infarction complicated with pericarditis after percutaneous coronary intervention: A case report
Liu WC, Li SB, Zhang CF, Cui XH
- 3232** IgA nephropathy treatment with traditional Chinese medicine: A case report
Zhang YY, Chen YL, Yi L, Gao K
- 3241** Appendico-vesicocolonic fistula: A case report and review of literature
Yan H, Wu YC, Wang X, Liu YC, Zuo S, Wang PY
- 3251** *Scedosporium apiospermum* infection of the lumbar vertebrae: A case report
Shi XW, Li ST, Lou JP, Xu B, Wang J, Wang X, Liu H, Li SK, Zhen P, Zhang T
- 3261** Woman diagnosed with obsessive-compulsive disorder became delusional after childbirth: A case report
Lin SS, Gao JF
- 3268** Emphysematous pyelonephritis: Six case reports and review of literature
Ma LP, Zhou N, Fu Y, Liu Y, Wang C, Zhao B
- 3278** Atypical infantile-onset Pompe disease with good prognosis from mainland China: A case report
Zhang Y, Zhang C, Shu JB, Zhang F
- 3284** *Mycobacterium tuberculosis* bacteremia in a human immunodeficiency virus-negative patient with liver cirrhosis: A case report
Lin ZZ, Chen D, Liu S, Yu JH, Liu SR, Zhu ML
- 3291** Cervical aortic arch with aneurysm formation and an anomalous right subclavian artery and left vertebral artery: A case report
Wu YK, Mao Q, Zhou MT, Liu N, Yu X, Peng JC, Tao YY, Gong XQ, Yang L, Zhang XM
- 3297** Dedifferentiated chondrosarcoma of the middle finger arising from a solitary enchondroma: A case report
Yonezawa H, Yamamoto N, Hayashi K, Takeuchi A, Miwa S, Igarashi K, Morinaga S, Asano Y, Saito S, Tome Y, Ikeda H, Nojima T, Tsuchiya H

- 3306** Endoscopic-catheter-directed infusion of diluted (-)-noradrenaline for atypical hemobilia caused by liver abscess: A case report
Zou H, Wen Y, Pang Y, Zhang H, Zhang L, Tang LJ, Wu H
- 3313** *Pneumocystis jiroveci* pneumonia after total hip arthroplasty in a dermatomyositis patient: A case report
Hong M, Zhang ZY, Sun XW, Wang WG, Zhang QD, Guo WS

ABOUT COVER

Editorial Board Member of *World Journal of Clinical Cases*, Hui-Jeong Hwang, MD, PhD, Associate Professor, Department of Cardiology, Kyung Hee University Hospital at Gangdong, Kyung Hee University College of Medicine, Seoul 05278, South Korea. neonic7749@hanmail.net

AIMS AND SCOPE

The primary aim of *World Journal of Clinical Cases* (WJCC, *World J Clin Cases*) is to provide scholars and readers from various fields of clinical medicine with a platform to publish high-quality clinical research articles and communicate their research findings online.

WJCC mainly publishes articles reporting research results and findings obtained in the field of clinical medicine and covering a wide range of topics, including case control studies, retrospective cohort studies, retrospective studies, clinical trials studies, observational studies, prospective studies, randomized controlled trials, randomized clinical trials, systematic reviews, meta-analysis, and case reports.

INDEXING/ABSTRACTING

The WJCC is now indexed in Science Citation Index Expanded (also known as SciSearch®), Journal Citation Reports/Science Edition, Scopus, PubMed, and PubMed Central. The 2021 Edition of Journal Citation Reports® cites the 2020 impact factor (IF) for WJCC as 1.337; IF without journal self cites: 1.301; 5-year IF: 1.742; Journal Citation Indicator: 0.33; Ranking: 119 among 169 journals in medicine, general and internal; and Quartile category: Q3. The WJCC's CiteScore for 2020 is 0.8 and Scopus CiteScore rank 2020: General Medicine is 493/793.

RESPONSIBLE EDITORS FOR THIS ISSUE

Production Editor: *Xu Guo*; Production Department Director: *Xiang Li*; Editorial Office Director: *Jin-Lai Wang*.

NAME OF JOURNAL

World Journal of Clinical Cases

ISSN

ISSN 2307-8960 (online)

LAUNCH DATE

April 16, 2013

FREQUENCY

Thrice Monthly

EDITORS-IN-CHIEF

Bao-Gan Peng, Jerzy Tadeusz Chudek, George Kontogeorgos, Maurizio Serati, Ja Hyeon Ku

EDITORIAL BOARD MEMBERS

<https://www.wjgnet.com/2307-8960/editorialboard.htm>

PUBLICATION DATE

April 6, 2022

COPYRIGHT

© 2022 Baishideng Publishing Group Inc

INSTRUCTIONS TO AUTHORS

<https://www.wjgnet.com/bpg/gerinfo/204>

GUIDELINES FOR ETHICS DOCUMENTS

<https://www.wjgnet.com/bpg/GerInfo/287>

GUIDELINES FOR NON-NATIVE SPEAKERS OF ENGLISH

<https://www.wjgnet.com/bpg/gerinfo/240>

PUBLICATION ETHICS

<https://www.wjgnet.com/bpg/GerInfo/288>

PUBLICATION MISCONDUCT

<https://www.wjgnet.com/bpg/gerinfo/208>

ARTICLE PROCESSING CHARGE

<https://www.wjgnet.com/bpg/gerinfo/242>

STEPS FOR SUBMITTING MANUSCRIPTS

<https://www.wjgnet.com/bpg/GerInfo/239>

ONLINE SUBMISSION

<https://www.f6publishing.com>



Elevated intra-abdominal pressure: A review of current knowledge

Piotr Łagosz, Mateusz Sokolski, Jan Biegus, Agnieszka Tycinska, Robert Zymlinski

Specialty type: Medicine, research and experimental

Provenance and peer review: Unsolicited article; Externally peer reviewed.

Peer-review model: Single blind

Peer-review report's scientific quality classification

Grade A (Excellent): 0
Grade B (Very good): B
Grade C (Good): C
Grade D (Fair): 0
Grade E (Poor): 0

P-Reviewer: Oprea V

Received: June 16, 2021

Peer-review started: June 16, 2021

First decision: September 5, 2021

Revised: September 20, 2021

Accepted: February 22, 2022

Article in press: February 22, 2022

Published online: April 6, 2022



Piotr Łagosz, Mateusz Sokolski, Jan Biegus, Robert Zymlinski, Department of Heart Diseases, Wrocław Medical University, Wrocław 50-367, Poland

Piotr Łagosz, Mateusz Sokolski, Jan Biegus, Robert Zymlinski, Institute of Heart Diseases, University Clinical Hospital, Wrocław 50-556, Poland

Agnieszka Tycinska, Department of Cardiology, Medical University of Białystok, Białystok 15-089, Poland

Corresponding author: Piotr Łagosz, MD, Academic Research, Research Scientist, Teacher, Institute of Heart Diseases, Wrocław Medical University, Borowska 213, Wrocław 50-556, Poland. plagosz1@gmail.com

Abstract

Elevated intra-abdominal pressure (IAP) is a known cause of increased morbidity and mortality among critically ill patients. Intra-abdominal hypertension (IAH) and abdominal compartment syndrome can lead to rapid deterioration of organ function and the development of multiple organ failure. Raised IAP affects every system and main organ in the human body. Even marginally sustained IAH results in malperfusion and may disrupt the process of recovery. Yet, despite being so common, this potentially lethal condition often goes unnoticed. In 2004, the World Society of the Abdominal Compartment Syndrome, an international multidisciplinary consensus group, was formed to provide unified definitions, improve understanding and promote research in this field. Simple, reliable and nearly costless standardized methods of non-invasive measurement and monitoring of bladder pressure allow early recognition of IAH and timely optimized management. The correct, structured approach to treatment can have a striking effect and fully restore homeostasis. In recent years, significant progress has been made in this area with the contribution of surgeons, internal medicine specialists and anesthesiologists. Our review focuses on recent advances in order to present the complex underlying pathophysiology and guidelines concerning diagnosis, monitoring and treatment of this life-threatening condition.

Key Words: Abdominal compartment syndrome; Intra-abdominal hypertension; Intra-abdominal pressure; Multiple organ failure; Abdominal perfusion pressure

©The Author(s) 2022. Published by Baishideng Publishing Group Inc. All rights reserved.

Core Tip: Elevated intra-abdominal pressure is a common, life-threatening condition associated with increased morbidity and mortality. Unrecognized intra-abdominal hypertension (IAH) quickly leads to the development of multiple organ failure; therefore, vigilance is necessary in relation to high-risk patients. Monitoring bladder pressure in this group allows early recognition of IAH/abdominal compartment syndrome and timely intervention which can have a striking effect and fully restore homeostasis. Although the progress made in recent years is significant, there are still open questions which leave room for future research.

Citation: Łagosz P, Sokolski M, Biegus J, Tycinska A, Zymlinski R. Elevated intra-abdominal pressure: A review of current knowledge. *World J Clin Cases* 2022; 10(10): 3005-3013

URL: <https://www.wjgnet.com/2307-8960/full/v10/i10/3005.htm>

DOI: <https://dx.doi.org/10.12998/wjcc.v10.i10.3005>

INTRODUCTION

Increased intra-abdominal pressure (IAP) has drawn attention and become an accentuated condition in critically ill patients over the last few years[1-3]. IAP is defined as pressure concealed within the abdominal cavity, which is relative to the respiratory phase and abdominal wall resistance. It was first recognized in the 19th century with a recent increase of interest and publications in this field. In 1863, Marey noticed a link between the respiratory system and abdominal pressure for the first time. Promptly after this discovery, a damaging effect on other organs was described, inspiring scientists to explore this phenomenon in animal models in the early 20th century. In the following years, surgeons made a significant contribution to understanding gastrointestinal, cardiac and pulmonary complications and restoring their function through decompression of the abdominal cavity. Accumulation of clinical data throughout the last decades has led to a better understanding of underlying pathophysiology and its consequences. The impact of elevated IAP is not only limited to deterioration of intra-abdominal organs function but rather directly and indirectly influences different systems and main organs[4]. Untreated pre-existing comorbidities, abdominal trauma or surgical interventions and extra-abdominal diseases like chronic kidney disease, heart failure or impaired respiratory function, exacerbate the harmful effects of elevated IAP. In these high-risk subpopulations, even marginal sustained rise in IAP results in malperfusion and potential subsequent multiple organ failure.

In 2004, the World Society of the Abdominal Compartment Syndrome (WSACS), an international multidisciplinary consensus group, was formed from critical care, surgical and trauma experts to provide standardized definitions, promote research in this field and improve survival of patients affected by intra-abdominal hypertension (IAH) and abdominal compartment syndrome (ACS). WSACS specialists published new definitions and recommendations for IAP measurement and management. According to created guidelines, normal IAP in critically ill adults ranges approximately from 5 mmHg to 7 mmHg. IAH is defined as a sustained or repeated rise in IAP above 12 mmHg and is divided into four grades, namely grade I: 12-15 mmHg, grade II: 16-20 mmHg, grade III: 21-25 mmHg and grade IV: > 25 mmHg. ACS is defined as a sustained IAP > 20 mmHg associated with new organ dysfunction or failure[5].

The following review focuses on current knowledge of elevated IAP, its relationship with deterioration of organ function and structured management of this condition which can be applied in general internal and surgical practice.

EPIDEMIOLOGY AND RISK FACTORS

A series of the latest studies indicates a high prevalence of IAH ranging from 28% to 71% depending on the studied cohort of patients admitted to critical care units. In comparison, ACS developed in 3%-12% of admissions. Moreover, IAH was a significant and independent predictor for short- and long-term mortality and was significantly associated with severe organ failures and prolonged stay in the hospital [6-8]. Depending on the study, ICU mortality was considerably higher in IAH and ACS groups compared to normal IAP, and the grade of IAH was inversely related to outcome. According to the study conducted by Smit *et al*[6], both intensive care and 90-d mortality were higher in IAH (4.8% and 15.2%, respectively) and ACS (16.7% and 38.9%, respectively) in comparison to patients with normal IAP (1.2% and 7.1%, respectively). In addition, mechanical ventilation with positive pressure, obesity, sepsis, positive fluid balance, acute respiratory distress syndrome and anemia were indicated repeatedly as risk factors of IAH development[9].

Table 1 Effect of intra-abdominal hypertension on different systems

Location	Effect of IAH
Central nervous system	↑ Intracranial pressure ↓ Cerebral perfusion pressure ↓ Venous outflow ↑ Intracerebral venous pooling
Thorax	↑ Intrathoracic pressure ↑ Inferior vena cava diameter ↓ Wall compliance
Cardiovascular system	↑ Obstruction of vena cava ↓ Venous return (preload) ↓ Cardiac output ↓ Ventricular compliance and contractility ↑ Compression of the aorta and systemic vasculature ↑ Systemic vascular resistance (afterload) ↑ Compression of pulmonary parenchyma ↑ Pulmonary vascular resistance ↑ Central venous pressure ↑ Pulmonary artery occlusion pressure
Lungs	Atelectasis ↓ Compliance ↑ Infection rate Alveolar volutrauma ↑ Peak inspiratory pressure ↑ Mean airway pressure ↑ Ventilation-perfusion mismatch ↑ Pulmonary dead space ↑ PaCO ₂ ↓ PaO ₂
Abdomen	↓ Abdominal perfusion pressure ↓ Wall compliance ↓ Wall blood flow ↓ Celiac and mesenteric blood flow ↑ Mesenteric venous pressure ↑ Visceral swelling ↑ Ischaemia ↑ Feeding intolerance ↓ Intramucosal pH Bacterial translocation
Liver	↓ Portal blood flow ↓ Hepatic artery blood flow ↓ Hepatic vein blood flow ↓ Lactate clearance

Kidney	↓ Renal blood flow
	↑ Renal venous pressure
	↑ Renal vascular resistance
	↓ Glomerular filtration rate
	↓ Diuresis
	↑ Blood urea nitrogen concentration
	↑ Serum creatinine
	↑ Activation of renin-angiotensin-aldosterone axis
	↑ Antidiuretic hormone release

IAH: Intra-abdominal hypertension.

PATHOPHYSIOLOGY

The complicated pathophysiology of raised IAP remains poorly understood. The deteriorated function of organs has been observed for years but this complex network of interactions is now being rediscovered (Table 1).

The abdominopelvic cavity is the body chamber defined by rigid bone structures and soft tissue. A slow increase in internal pressure causes the walls to expand but their abilities to compensate are limited. When they are exceeded, a force applied to the diaphragm causes a cephalic shift which was first described in 1922. This movement results in a reduced volume of the thoracic cavity and changed distribution of pressures. This concept which is called abdominal compliance (AC) is defined as a measure of the capability of abdominal expansion, which depends on the elasticity of the abdomen and diaphragm, and can be expressed as a change in intra-abdominal volume per change in IAP. AC depends on both these components and its dynamic of changes over time is thus hard to evaluate AC directly. Nevertheless, it should be considered an important component of IAP, playing a significant role in organ interactions and end-organ perfusion. Understanding AC helps in applying the right management strategies and preventing the consequences of increased IAP. Particularly patients with IAH and reduced AC can benefit even from a small reduction in IAV[10,11].

Reduction of thorax volume caused by deviation of the diaphragm is accompanied by an elevation of the thoracic pressure which declines the preload and thus cardiac output[12-14]. Such alterations were observed already at pressures of 10 mmHg in animal models[15]. The unfavorable effect can be aggravated additionally by hypovolemia. A rise in IAP followed by higher intrathoracic pressure results in impairment of ventricular compliance and compression of systemic and pulmonary arteries leading to an increasing afterload[16]. A combination of these factors affects the venous system. Reduction in venous return can be observed due to increased pressure in the vena cava and is proportional to the increase in pressure in the abdominal cavity[12]. Data suggest that fluid resuscitation improves venous return and thus diminishes the negative effect of increased afterload[16]. Furthermore, patients are at risk of deep venous thrombosis because of a rise in hydrostatic pressure throughout veins and the formation of peripheral edemas.

Compression of pulmonary tissue results in a higher intrapulmonary shunt fraction; therefore, it may contribute to the development of respiratory failure. This effect begins with an IAP > 16 mmHg. Alterations in dynamic and static spirometry variables are observed. A decrease in vital capacity, residual capacity and an increase in pleural, inspiratory and peak pressures are prevalent[17].

Deterioration of alveolar blood flow, ventilation-perfusion mismatch and atelectasis are presented with hypercarbia and hypoxemia in arterial blood samples and are frequently accompanied by infective complications[18].

In the state of elevated IAP, renal function should be considered at all times during therapy. The pressure determining the proper blood flow through the abdominal organs is called the abdominal perfusion pressure (APP). It is calculated using the mean arterial pressure (MAP) and IAP. APP results from the difference between these two variables.

The organ most exposed to changes in IAP is the kidney. The divertive parameter from APP that refers directly to kidney function is called the renal filtration gradient (RFG). The RFG, assuming a pressure in the proximal tubule is equal to IAP, can be calculated from the formula $RFG = MAP - 2 \times IAP$. Acute kidney injury induced by declined renal blood flow, venous congestion and parenchymal compression is a common finding among all patients with IAH[19-23].

As a response, the renin-angiotensin-aldosterone axis is chronically activated and an increase in antidiuretic hormone concentration can be observed[24]. A large decrease in urine sodium concentration is demonstrated which contributes to the development of diuretic resistance and further disturbs the fluid balance[25,26]. The effect of IAH on the kidney is highly dependent on pressure value. With an

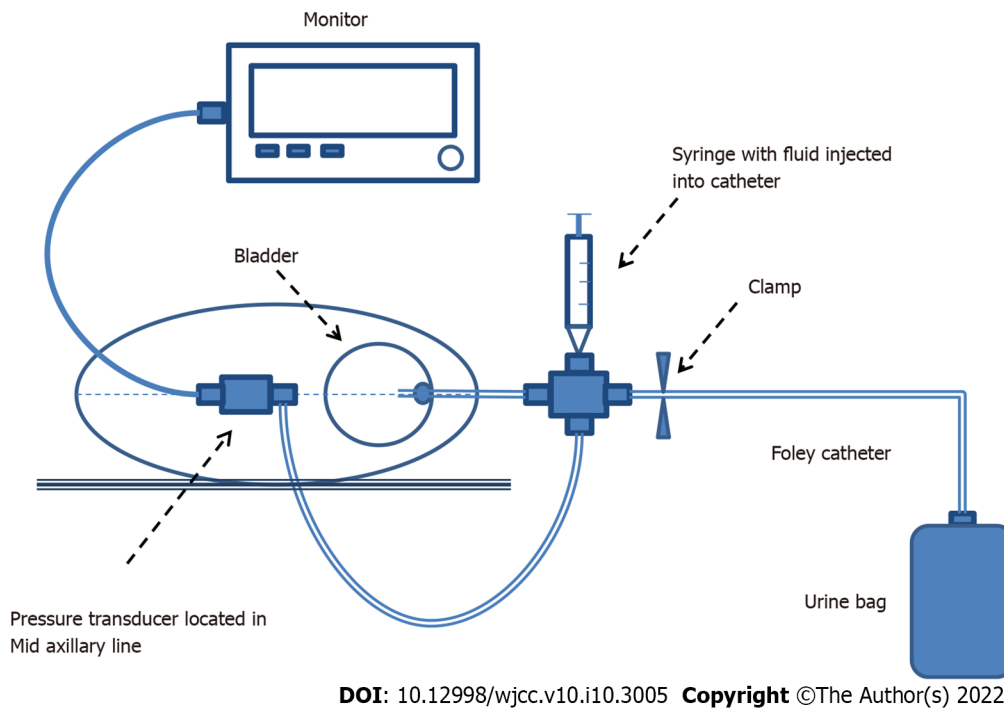


Figure 1 Transvesical system for measuring intra-abdominal pressure.

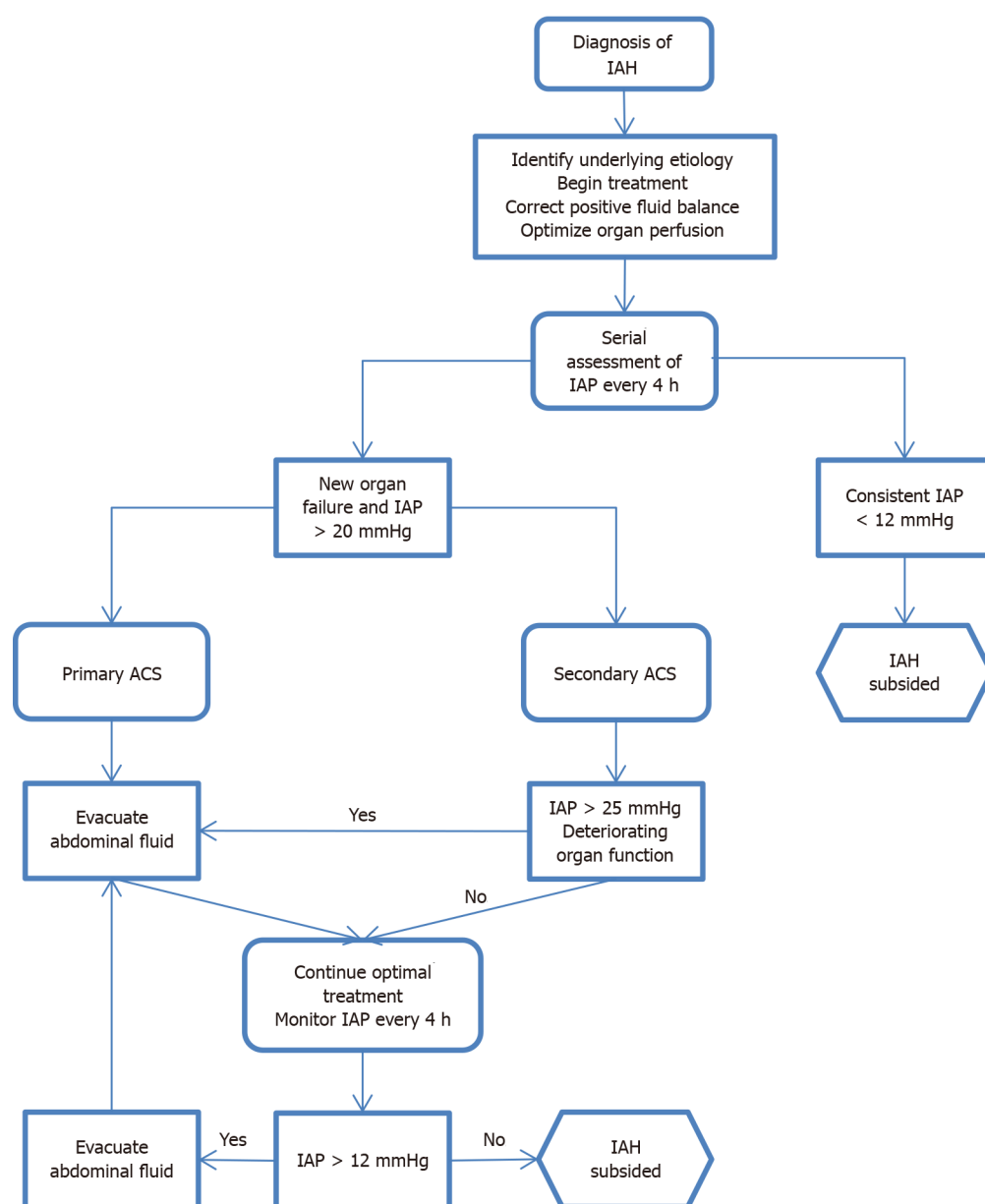
IAP between 15 and 20 mmHg, reduced renal filtration pressure leads to oliguria (2-5 mL/kg per hour of diuresis) followed by the development of anuria at 30 mmHg. Also, an IAP of 20 mmHg causes an increase in renal vascular resistance by 500% and 1500% at 40 mmHg[27]. These changes shunt blood from the kidney, start glomerular necrosis, cause tubular damage and progress towards renal insufficiency[19].

The influence of IAP on the gastrointestinal tract cannot be ignored. Reduced blood flow combined with compression leads to venous hypertension in the visceral vascular system causing edema in the intestinal tissue. Along with it, the pressure in the abdominal cavity also increases, promoting further ischemic changes, malabsorption syndrome, bacterial flora translocation, metabolic acidosis and finally increasing mortality. A specific scale has been developed to predict mortality caused by intestinal dysfunction in patients with IAH[28]. Hepatic complications are common as the liver is sensitive to changes in abdominal pressure. In conditions of IAH, both hepatic blood vessel and portal vein blood flow is decreased. As a response to congestion, hepatocellular injury occurs[29]. Compromised mitochondrial function results in altered glucose metabolism and increased lactic acid concentration. This effect has been observed at an IAP of only 10 mmHg with preserved normal mean arterial blood pressure and cardiac output[13].

Venous blood return from the cerebrum affected by elevated pressure in the abdomen and thorax can cause an increase of intracranial venous blood volume, a rise in intracranial pressure and a decrease in cerebral perfusion pressure[12]. These factors lead to cerebral edema and worsening of neurological functions[30,31].

DIAGNOSIS

Physical examination has been proven unreliable and imprecise in IAH diagnosis[32-34]. Since monitoring IAP is of fundamental importance for profiling patients and guiding therapy, different methods of its assessment have been proposed. The first attempts to measure IAP were associated with an invasive peritoneal puncture procedure and the direct measurement of IAP using a peritoneal dialysis catheter. In the past, other methods like intramuscular continuous automatic piezoresistive pressure reading were confirmed as precise and consistent with non-direct measurements in porcine models. However, it has not been evaluated for safety and reliability in the ICU environment. Therefore, other less invasive methods have been developed as an alternative. IAP can be estimated by recording bladder pressure (using a Foley catheter), stomach pressure (using a nasogastric or gastrostomy tube), rectal pressure (using a balloon catheter) or inferior vena cava pressure. Transurethral measurement gained special recognition among these measurements because of its simplicity, reliability, consistency and low cost. The bladder is a passive reservoir which reflects IAP accurately[35]. In this technique, a Foley catheter is inserted into a vesicle and filled with 25 mL of saline, which guarantees the transfer of



DOI: 10.12998/wjcc.v10.i10.3005 Copyright ©The Author(s) 2022.

Figure 2 Diagnostic algorithm for elevated intra-abdominal pressure. ACS: Abdominal compartment syndrome; IAH: Intra-abdominal hypertension; IAP: Intra-abdominal pressure.

hydrostatic pressure between the bladder wall and the pressure measuring device. As a device, a simple standpipe or conventional electronic transducer can be used. The tip of the pressure tube is connected to the catheter to prevent air from entering the line and avoid dampened readings (Figure 1). Recently, commercially produced measurement kits have been available on the market. WSACS recommends measuring IAP every 4 h in the complete supine position without abdominal muscle activity and at end-expiration phase. The transducer should be zeroed at the mid-axillary line level and at the level of the iliac crest for 30-60 s after installation of body temperature fluid to allow bladder detrusor muscle relaxation. This reduces inaccuracy and ensures reproducibility of the measurement. While using standpipe, reading in cmH₂O should be converted to mmHg. Intravesical measurement is a gold standard for indirect measurement proposed by WSACS, although it is only suitable for intermittent use [36,37].

MEDICAL MANAGEMENT

The goal of the treatment is to reduce IAP, restore regular systemic perfusion, reduce risk and avoid permanent end-organ damage. To achieve it, WSACS recommends a strategy that consists of improving abdominal wall compliance, evacuating intra-luminal contents and excessive abdominal fluid

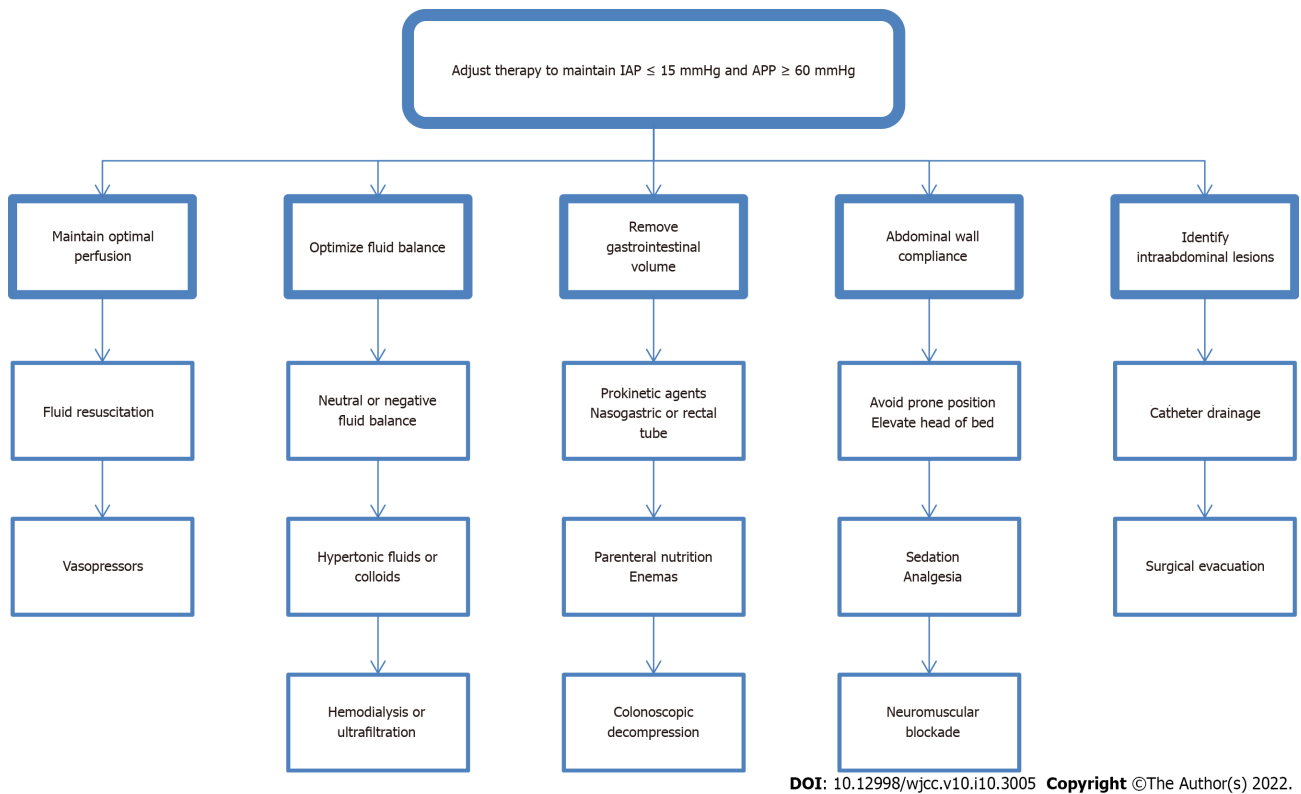


Figure 3 Treating algorithm for elevated intra-abdominal pressure. APP: Abdominal perfusion pressure; IAP: Intra-abdominal pressure.

collections, correcting positive fluid balance and supporting organs. However, it is essential to remember that clinical judgment and physical examination are far from accurate estimating IAP. Therefore, the ACS management algorithm has been developed to help clinicians in the process of decision-making. This integrated approach results in improved outcomes and higher economic efficiency.

As soon as IAH is diagnosed, actions should be taken to lower the pressure inside the abdominal cavity. Underlying etiology has to be identified and treated. To improve wall compliance, sedation and neuromuscular blockade can be initiated. If possible, the head of the bed angle should be under 30 degrees. Intra-luminal contents can be removed by nasogastric or rectal decompression, and prokinetic drugs can be applied. Invasive procedures like paracentesis or percutaneous drainage are recommended for evacuating residual fluid from the abdomen. The options of correcting the fluid balance include diuretics, colloids or hypertonic fluids, hemodialysis and ultrafiltration. If all of the above have failed, surgical intervention might be indicated. Abdominal decompression technique called open abdomen (OA) therapy is proven to enhance renal function and urine output, improve cardiac index and lung compliance[38]. These changes have major repercussions on hemodynamics. Lowered CVP and higher tidal volume are observed, which physicians must be prepared for and adjust resuscitation as well as parameters of mechanical ventilation appropriately. The intensivist should optimize the process aiming for early fascial closure to avoid delayed extubation, development of fistulas and septic complications of extended OA therapy. Hypothermia, coagulopathy and acidosis are general concerns that should be addressed. Choosing optimal therapy requires a personalized approach. After implementing appropriate treatment, IAP should be monitored with serial assessments every 4 h (Figures 2 and 3).

CONCLUSION

Elevated IAP is a common, life-threatening condition associated with increased morbidity and mortality. Unrecognized IAH quickly leads to the development of multiple organ failure, therefore, vigilance is necessary in relation to high-risk patients. Monitoring bladder pressure in this group allows early recognition of IAH/ACS and consequently, timely intervention, which can have a striking effect and fully restore homeostasis. Although the progress made in recent years is significant, there are still open questions which leaves room for future research.

FOOTNOTES

Author contributions: Łagosz P was main author and study designer; Łagosz P, Sokolski M, Biegus J, Tycinska A and Zymlinski R analyzed the data and wrote the manuscript; Zymlinski R supervised the process; all authors have read and approve the final manuscript.

Conflict-of-interest statement: The authors declare no conflict of interest.

Open-Access: This article is an open-access article that was selected by an in-house editor and fully peer-reviewed by external reviewers. It is distributed in accordance with the Creative Commons Attribution NonCommercial (CC BY-NC 4.0) license, which permits others to distribute, remix, adapt, build upon this work non-commercially, and license their derivative works on different terms, provided the original work is properly cited and the use is non-commercial. See: <https://creativecommons.org/licenses/by-nc/4.0/>

Country/Territory of origin: Poland

ORCID number: Piotr Łagosz 0000-0003-2682-4131; Mateusz Sokolski 0000-0001-9925-3566; Jan Biegus 0000-0001-9977-7722; Agnieszka Tycinska 0000-0001-7855-7261; Robert Zymlinski 0000-0003-1483-7381.

S-Editor: Gao CC

L-Editor: Filipodia

P-Editor: Gao CC

REFERENCES

- 1 **Ball CG**, Kirkpatrick AW, McBeth P. The secondary abdominal compartment syndrome: not just another post-traumatic complication. *Can J Surg* 2008; **51**: 399-405 [PMID: 18841232]
- 2 **Malbrain ML**, Chiumello D, Pelosi P, Wilmer A, Brienza N, Malcangi V, Bihari D, Innes R, Cohen J, Singer P, Japiassu A, Kurtop E, De Keulenaer BL, Daelemans R, Del Turco M, Cosimini P, Ranieri M, Jacquet L, Laterre PF, Gattinoni L. Prevalence of intra-abdominal hypertension in critically ill patients: a multicentre epidemiological study. *Intensive Care Med* 2004; **30**: 822-829 [PMID: 14758472 DOI: 10.1007/s00134-004-2169-9]
- 3 **Kimball EJ**, Kim W, Cheatham ML, Malbrain ML. Clinical awareness of intra-abdominal hypertension and abdominal compartment syndrome in 2007. *Acta Clin Belg* 2007; **62** Suppl 1: 66-73 [PMID: 24881702 DOI: 10.1179/acb.2007.62.s1.009]
- 4 **Cheatham ML**. Abdominal compartment syndrome: pathophysiology and definitions. *Scand J Trauma Resusc Emerg Med* 2009; **17**: 10 [PMID: 19254364 DOI: 10.1186/1757-7241-17-10]
- 5 **Malbrain ML**, Cheatham ML, Kirkpatrick A, Sugrue M, Parr M, De Waele J, Balogh Z, Leppäniemi A, Olvera C, Ivatury R, D'Amours S, Wendon J, Hillman K, Johansson K, Kolkman K, Wilmer A. Results from the International Conference of Experts on Intra-abdominal Hypertension and Abdominal Compartment Syndrome. I. Definitions. *Intensive Care Med* 2006; **32**: 1722-1732 [PMID: 16967294 DOI: 10.1007/s00134-006-0349-5]
- 6 **Smit M**, Koopman B, Dieperink W, Hulscher JBF, Hofker HS, van Meurs M, Zijlstra JG. Intra-abdominal hypertension and abdominal compartment syndrome in patients admitted to the ICU. *Ann Intensive Care* 2020; **10**: 130 [PMID: 33001288 DOI: 10.1186/s13613-020-00746-9]
- 7 **Reintam Blaser A**, Regli A, De Keulenaer B, Kimball EJ, Starkopf L, Davis WA, Greiffenstein P, Starkopf J; Incidence, Risk Factors, and Outcomes of Intra-Abdominal (IROI) Study Investigators. Incidence, Risk Factors, and Outcomes of Intra-Abdominal Hypertension in Critically Ill Patients-A Prospective Multicenter Study (IROI Study). *Crit Care Med* 2019; **47**: 535-542 [PMID: 30608280 DOI: 10.1097/CCM.0000000000003623]
- 8 **Murtaza G**, Pal KM, Jajja MR, Nawaz Z, Koondhar R, Nasim S. Intra abdominal hypertension; incidence, prevalence and outcomes in a mixed intensive care unit: Prospective cohort study. *Int J Surg* 2015; **19**: 67-71 [PMID: 25980395 DOI: 10.1016/j.ijsu.2015.05.014]
- 9 **Holodinsky JK**, Roberts DJ, Ball CG, Blaser AR, Starkopf J, Zygun DA, Stelfox HT, Malbrain ML, Jaeschke RC, Kirkpatrick AW. Risk factors for intra-abdominal hypertension and abdominal compartment syndrome among adult intensive care unit patients: a systematic review and meta-analysis. *Crit Care* 2013; **17**: R249 [PMID: 24144138 DOI: 10.1186/cc13075]
- 10 **Blaser AR**, Björck M, De Keulenaer B, Regli A. Abdominal compliance: A bench-to-bedside review. *J Trauma Acute Care Surg* 2015; **78**: 1044-1053 [PMID: 25909429 DOI: 10.1097/TA.0000000000000616]
- 11 **Malbrain ML**, Roberts DJ, De Laet I, De Waele JJ, Sugrue M, Schachtrupp A, Duchesne J, Van Ramshorst G, De Keulenaer B, Kirkpatrick AW, Ahmadi-Noorbakhsh S, Mulier J, Ivatury R, Pracca F, Wise R, Pelosi P. The role of abdominal compliance, the neglected parameter in critically ill patients - a consensus review of 16. Part 1: definitions and pathophysiology. *Anaesthesiol Intensive Ther* 2014; **46**: 392-405 [PMID: 25432558 DOI: 10.5603/AIT.2014.0062]
- 12 **Caldwell CB**, Ricotta JJ. Changes in visceral blood flow with elevated intraabdominal pressure. *J Surg Res* 1987; **43**: 14-20 [PMID: 3599981 DOI: 10.1016/0022-4804(87)90041-2]
- 13 **Diebel LN**, Wilson RF, Dulchavsky SA, Saxe J. Effect of increased intra-abdominal pressure on hepatic arterial, portal venous, and hepatic microcirculatory blood flow. *J Trauma* 1992; **33**: 279-82; discussion 282 [PMID: 1507294 DOI: 10.1097/00005373-199208000-00019]
- 14 **Luca A**, Cirera I, García-Pagán JC, Feu F, Pizcueta P, Bosch J, Rodés J. Hemodynamic effects of acute changes in intra-abdominal pressure in patients with cirrhosis. *Gastroenterology* 1993; **104**: 222-227 [PMID: 8419245 DOI: 10.1053/gastro.1993.104022227]

- 10.1016/0016-5085(93)90855-7]
- 15 **Richardson JD**, Trinkle JK. Hemodynamic and respiratory alterations with increased intra-abdominal pressure. *J Surg Res* 1976; **20**: 401-404 [PMID: 933497 DOI: 10.1016/0022-4804(76)90112-8]
 - 16 **Ridings PC**, Bloomfield GL, Blocher CR, Sugerman HJ. Cardiopulmonary effects of raised intra-abdominal pressure before and after intravascular volume expansion. *J Trauma* 1995; **39**: 1071-1075 [PMID: 7500396 DOI: 10.1097/00005373-199512000-00010]
 - 17 **Obeid F**, Saba A, Fath J, Guslits B, Chung R, Sorensen V, Buck J, Horst M. Increases in intra-abdominal pressure affect pulmonary compliance. *Arch Surg* 1995; **130**: 544-7; discussion 547 [PMID: 7748095 DOI: 10.1001/archsurg.1995.01430050094016]
 - 18 **Aprahamian C**, Wittmann DH, Bergstein JM, Quebbeman EJ. Temporary abdominal closure (TAC) for planned relaparotomy (etappenlavage) in trauma. *J Trauma* 1990; **30**: 719-723 [PMID: 2191142 DOI: 10.1097/00005373-199006000-00011]
 - 19 **Mullens W**, Abrahams Z, Skouri HN, Francis GS, Taylor DO, Starling RC, Paganini E, Tang WH. Elevated intra-abdominal pressure in acute decompensated heart failure: a potential contributor to worsening renal function? *J Am Coll Cardiol* 2008; **51**: 300-306 [PMID: 18206740 DOI: 10.1016/j.jacc.2007.09.043]
 - 20 **Mullens W**, Abrahams Z, Francis GS, Sokos G, Taylor DO, Starling RC, Young JB, Tang WHW. Importance of venous congestion for worsening of renal function in advanced decompensated heart failure. *J Am Coll Cardiol* 2009; **53**: 589-596 [PMID: 19215833 DOI: 10.1016/j.jacc.2008.05.068]
 - 21 **Talizin TB**, Tsuda MS, Tanita MT, Kauss IAM, Festti J, Carrilho CMDM, Grion CMC, Cardoso LTQ. Acute kidney injury and intra-abdominal hypertension in burn patients in intensive care. *Rev Bras Ter Intensiva* 2018; **30**: 15-20 [PMID: 29742223 DOI: 10.5935/0103-507x.20180001]
 - 22 **Smit M**, van Meurs M, Zijlstra JG. Intra-Abdominal Pressure, Acute Kidney Injury, and Obesity in Critical Illness. *Crit Care Med* 2016; **44**: e766-e767 [PMID: 27428143 DOI: 10.1097/CCM.0000000000001779]
 - 23 **Stone HH**, Fulenwider JT. Renal decapsulation in the prevention of post-ischemic oliguria. *Ann Surg* 1977; **186**: 343-355 [PMID: 407854 DOI: 10.1097/00000658-197709000-00012]
 - 24 **Le Roith D**, Bark H, Nyska M, Glick SM. The effect of abdominal pressure on plasma antidiuretic hormone levels in the dog. *J Surg Res* 1982; **32**: 65-69 [PMID: 6172664 DOI: 10.1016/0022-4804(82)90186-x]
 - 25 **Nguyen VQ**, Gadiraju TV, Patel H, Park M, Le Jemtel TH, Jaiswal A. Intra-abdominal Hypertension: An Important Consideration for Diuretic Resistance in Acute Decompensated Heart Failure. *Clin Cardiol* 2016; **39**: 37-40 [PMID: 26687765 DOI: 10.1002/clc.22489]
 - 26 **Mullens W**, Damman K, Harjola VP, Mebazaa A, Brunner-La Rocca HP, Martens P, Testani JM, Tang WHW, Orso F, Rossignol P, Metra M, Filippatos G, Seferovic PM, Ruschitzka F, Coats AJ. The use of diuretics in heart failure with congestion - a position statement from the Heart Failure Association of the European Society of Cardiology. *Eur J Heart Fail* 2019; **21**: 137-155 [PMID: 30600580 DOI: 10.1002/ejhf.1369]
 - 27 **Harman PK**, Kron IL, McLachlan HD, Freedlender AE, Nolan SP. Elevated intra-abdominal pressure and renal function. *Ann Surg* 1982; **196**: 594-597 [PMID: 7125746 DOI: 10.1097/00000658-198211000-00015]
 - 28 **Reintam A**, Parm P, Kitus R, Starkopf J, Kern H. Gastrointestinal failure score in critically ill patients: a prospective observational study. *Crit Care* 2008; **12**: R90 [PMID: 18625051 DOI: 10.1186/cc6958]
 - 29 **Lima R**, Silva PL, Capelozzi VL, Oliveira MG, Santana MCE, Cruz FF, Pelosi P, Schanaider A, Malbrain MLNG, Rocco PRM. Early impact of abdominal compartment syndrome on liver, kidney and lung damage in a rodent model. *Anaesthesiol Intensive Ther* 2017; **49**: 130-138 [PMID: 28502073 DOI: 10.5603/AIT.a2017.0021]
 - 30 **Luce JM**, Huseby JS, Kirk W, Butler J. Mechanism by which positive end-expiratory pressure increases cerebrospinal fluid pressure in dogs. *J Appl Physiol Respir Environ Exerc Physiol* 1982; **52**: 231-235 [PMID: 7037710 DOI: 10.1152/jappl.1982.52.1.231]
 - 31 **Bloomfield GL**, Dalton JM, Sugerman HJ, Ridings PC, DeMaria EJ, Bullock R. Treatment of increasing intracranial pressure secondary to the acute abdominal compartment syndrome in a patient with combined abdominal and head trauma. *J Trauma* 1995; **39**: 1168-1170 [PMID: 7500414 DOI: 10.1097/00005373-199512000-00028]
 - 32 **Malbrain ML**. Different techniques to measure intra-abdominal pressure (IAP): time for a critical re-appraisal. *Intensive Care Med* 2004; **30**: 357-371 [PMID: 14730376 DOI: 10.1007/s00134-003-2107-2]
 - 33 **De Waele JJ**, De Laet I, Malbrain ML. Rational intraabdominal pressure monitoring: how to do it? *Acta Clin Belg* 2007; **62** Suppl 1: 16-25 [PMID: 24881697 DOI: 10.1179/acb.2007.62.s1.004]
 - 34 **Hunt L**, Frost SA, Hillman K, Newton PJ, Davidson PM. Management of intra-abdominal hypertension and abdominal compartment syndrome: a review. *J Trauma Manag Outcomes* 2014; **8**: 2 [PMID: 24499574 DOI: 10.1186/1752-2897-8-2]
 - 35 **Lopes AM**, Morgado M, Niza MMRE, Franca N, Mestrinho L, Félix N, Dourado A. Biophysical Validation of Intra-Abdominal Pressure and Transurethral Method. *J Vet Sci Med Diagn* 2016; **5** [DOI: 10.4172/2325-9590.1000196]
 - 36 **Zymliński R**, Biegus J, Sokolski M, Jankowska EA, Banasiak W, Ponikowski P. Validation of transurethral intraabdominal pressure measurement in acute heart failure. *Pol Arch Intern Med* 2018; **128**: 403-405 [PMID: 29968700 DOI: 10.20452/pamw.4290]
 - 37 **Milanesi R**, Caregnato RC. Intra-abdominal pressure: an integrative review. *Einstein (Sao Paulo)* 2016; **14**: 423-430 [PMID: 26958978 DOI: 10.1590/S1679-45082016RW3088]
 - 38 **Ertel W**, Oberholzer A, Platz A, Stocker R, Trentz O. Incidence and clinical pattern of the abdominal compartment syndrome after "damage-control" laparotomy in 311 patients with severe abdominal and/or pelvic trauma. *Crit Care Med* 2000; **28**: 1747-1753 [PMID: 10890613 DOI: 10.1097/00003246-200006000-00008]



Published by **Baishideng Publishing Group Inc**
7041 Koll Center Parkway, Suite 160, Pleasanton, CA 94566, USA

Telephone: +1-925-3991568

E-mail: bpgoffice@wjgnet.com

Help Desk: <https://www.f6publishing.com/helpdesk>

<https://www.wjgnet.com>

