

World Journal of *Clinical Cases*

World J Clin Cases 2022 April 6; 10(10): 2976-3320



Contents

Thrice Monthly Volume 10 Number 10 April 6, 2022

REVIEW

- 2976 Gut microbiota in gastrointestinal diseases during pregnancy
Liu ZZ, Sun JH, Wang WJ
- 2990 Targeting metabolism: A potential strategy for hematological cancer therapy
Tang X, Chen F, Xie LC, Liu SX, Mai HR

MINIREVIEWS

- 3005 Elevated intra-abdominal pressure: A review of current knowledge
Łagosz P, Sokolski M, Biegus J, Tycinska A, Zymlinski R

ORIGINAL ARTICLE

Case Control Study

- 3014 Changes in corneal nerve morphology and function in patients with dry eyes having type 2 diabetes
Fang W, Lin ZX, Yang HQ, Zhao L, Liu DC, Pan ZQ
- 3027 Combined sevoflurane-dexmedetomidine and nerve blockade on post-surgical serum oxidative stress biomarker levels in thyroid cancer patients
Du D, Qiao Q, Guan Z, Gao YF, Wang Q

Retrospective Cohort Study

- 3035 Early warning prevention and control strategies to reduce perioperative venous thromboembolism in patients with gastrointestinal cancer
Lu Y, Chen FY, Cai L, Huang CX, Shen XF, Cai LQ, Li XT, Fu YY, Wei J
- 3047 Dose-response relationship between risk factors and incidence of COVID-19 in 325 hospitalized patients: A multicenter retrospective cohort study
Zhao SC, Yu XQ, Lai XF, Duan R, Guo DL, Zhu Q

Retrospective Study

- 3060 Preventive online and offline health management intervention in polycystic ovary syndrome
Liu R, Li M, Wang P, Yu M, Wang Z, Zhang GZ
- 3069 Evidence-based intervention on postoperative fear, compliance, and self-efficacy in elderly patients with hip fracture
Fu Y, Zhu LJ, Li DC, Yan JL, Zhang HT, Xuan YH, Meng CL, Sun YH
- 3078 Significance of dysplasia in bile duct resection margin in patients with extrahepatic cholangiocarcinoma: A retrospective analysis
Choe JW, Kim HJ, Kim JS

- 3088** Diagnostic value and safety of medical thoracoscopy for pleural effusion of different causes

Liu XT, Dong XL, Zhang Y, Fang P, Shi HY, Ming ZJ

Observational Study

- 3101** Oxaliplatin-induced neuropathy and colo-rectal cancer patient's quality of life: Practical lessons from a prospective cross-sectional, real-world study

Prutianu I, Alexa-Stratulat T, Cristea EO, Nicolau A, Moisuc DC, Covrig AA, Ivanov K, Croitoru AE, Miron MI, Dinu MI, Ivanov AV, Marinca MV, Radu I, Gafton B

- 3113** Breast-conserving surgery and sentinel lymph node biopsy for breast cancer and their correlation with the expression of polyligand proteoglycan-1

Li FM, Xu DY, Xu Q, Yuan Y

SYSTEMATIC REVIEWS

- 3121** Clinical significance of aberrant left hepatic artery during gastrectomy: A systematic review

Tao W, Peng D, Cheng YX, Zhang W

META-ANALYSIS

- 3131** Betel quid chewing and oral potential malignant disorders and the impact of smoking and drinking: A meta-analysis

Lin HJ, Wang XL, Tian MY, Li XL, Tan HZ

- 3143** Effects of physical exercise on the quality-of-life of patients with haematological malignancies and thrombocytopenia: A systematic review and meta-analysis

Yang YP, Pan SJ, Qiu SL, Tung TH

CASE REPORT

- 3156** Primary malignant peritoneal mesothelioma mimicking tuberculous peritonitis: A case report

Lin LC, Kuan WY, Shiu BH, Wang YT, Chao WR, Wang CC

- 3164** Endoscopic submucosal dissection combined with adjuvant chemotherapy for early-stage neuroendocrine carcinoma of the esophagus: A case report

Tang N, Feng Z

- 3170** Lymph-node-first presentation of Kawasaki disease in a 12-year-old girl with cervical lymphadenitis caused by *Mycoplasma pneumoniae*: A case report

Kim N, Choi YJ, Na JY, Oh JW

- 3178** Tuberculosis-associated hemophagocytic lymphohistiocytosis misdiagnosed as systemic lupus erythematosus: A case report

Chen WT, Liu ZC, Li MS, Zhou Y, Liang SJ, Yang Y

- 3188** Migration of a Hem-o-Lok clip to the renal pelvis after laparoscopic partial nephrectomy: A case report

Sun J, Zhao LW, Wang XL, Huang JG, Fan Y

- 3194** Ectopic intrauterine device in the bladder causing cystolithiasis: A case report
Yu HT, Chen Y, Xie YP, Gan TB, Gou X
- 3200** Giant tumor resection under ultrasound-guided nerve block in a patient with severe asthma: A case report
Liu Q, Zhong Q, Zhou NN, Ye L
- 3206** Myomatous erythrocytosis syndrome: A case report
Shu XY, Chen N, Chen BY, Yang HX, Bi H
- 3213** Middle thyroid vein tumor thrombus in metastatic papillary thyroid microcarcinoma: A case report and review of literature
Gui Y, Wang JY, Wei XD
- 3222** Severe pneumonia and acute myocardial infarction complicated with pericarditis after percutaneous coronary intervention: A case report
Liu WC, Li SB, Zhang CF, Cui XH
- 3232** IgA nephropathy treatment with traditional Chinese medicine: A case report
Zhang YY, Chen YL, Yi L, Gao K
- 3241** Appendico-vesicocolonic fistula: A case report and review of literature
Yan H, Wu YC, Wang X, Liu YC, Zuo S, Wang PY
- 3251** *Scedosporium apiospermum* infection of the lumbar vertebrae: A case report
Shi XW, Li ST, Lou JP, Xu B, Wang J, Wang X, Liu H, Li SK, Zhen P, Zhang T
- 3261** Woman diagnosed with obsessive-compulsive disorder became delusional after childbirth: A case report
Lin SS, Gao JF
- 3268** Emphysematous pyelonephritis: Six case reports and review of literature
Ma LP, Zhou N, Fu Y, Liu Y, Wang C, Zhao B
- 3278** Atypical infantile-onset Pompe disease with good prognosis from mainland China: A case report
Zhang Y, Zhang C, Shu JB, Zhang F
- 3284** *Mycobacterium tuberculosis* bacteremia in a human immunodeficiency virus-negative patient with liver cirrhosis: A case report
Lin ZZ, Chen D, Liu S, Yu JH, Liu SR, Zhu ML
- 3291** Cervical aortic arch with aneurysm formation and an anomalous right subclavian artery and left vertebral artery: A case report
Wu YK, Mao Q, Zhou MT, Liu N, Yu X, Peng JC, Tao YY, Gong XQ, Yang L, Zhang XM
- 3297** Dedifferentiated chondrosarcoma of the middle finger arising from a solitary enchondroma: A case report
Yonezawa H, Yamamoto N, Hayashi K, Takeuchi A, Miwa S, Igarashi K, Morinaga S, Asano Y, Saito S, Tome Y, Ikeda H, Nojima T, Tsuchiya H

- 3306** Endoscopic-catheter-directed infusion of diluted (-)-noradrenaline for atypical hemobilia caused by liver abscess: A case report
Zou H, Wen Y, Pang Y, Zhang H, Zhang L, Tang LJ, Wu H
- 3313** *Pneumocystis jiroveci* pneumonia after total hip arthroplasty in a dermatomyositis patient: A case report
Hong M, Zhang ZY, Sun XW, Wang WG, Zhang QD, Guo WS

ABOUT COVER

Editorial Board Member of *World Journal of Clinical Cases*, Hui-Jeong Hwang, MD, PhD, Associate Professor, Department of Cardiology, Kyung Hee University Hospital at Gangdong, Kyung Hee University College of Medicine, Seoul 05278, South Korea. neonic7749@hanmail.net

AIMS AND SCOPE

The primary aim of *World Journal of Clinical Cases* (WJCC, *World J Clin Cases*) is to provide scholars and readers from various fields of clinical medicine with a platform to publish high-quality clinical research articles and communicate their research findings online.

WJCC mainly publishes articles reporting research results and findings obtained in the field of clinical medicine and covering a wide range of topics, including case control studies, retrospective cohort studies, retrospective studies, clinical trials studies, observational studies, prospective studies, randomized controlled trials, randomized clinical trials, systematic reviews, meta-analysis, and case reports.

INDEXING/ABSTRACTING

The WJCC is now indexed in Science Citation Index Expanded (also known as SciSearch®), Journal Citation Reports/Science Edition, Scopus, PubMed, and PubMed Central. The 2021 Edition of Journal Citation Reports® cites the 2020 impact factor (IF) for WJCC as 1.337; IF without journal self cites: 1.301; 5-year IF: 1.742; Journal Citation Indicator: 0.33; Ranking: 119 among 169 journals in medicine, general and internal; and Quartile category: Q3. The WJCC's CiteScore for 2020 is 0.8 and Scopus CiteScore rank 2020: General Medicine is 493/793.

RESPONSIBLE EDITORS FOR THIS ISSUE

Production Editor: *Xu Guo*; Production Department Director: *Xiang Li*; Editorial Office Director: *Jin-Lai Wang*.

NAME OF JOURNAL

World Journal of Clinical Cases

ISSN

ISSN 2307-8960 (online)

LAUNCH DATE

April 16, 2013

FREQUENCY

Thrice Monthly

EDITORS-IN-CHIEF

Bao-Gan Peng, Jerzy Tadeusz Chudek, George Kontogeorgos, Maurizio Serati, Ja Hyeon Ku

EDITORIAL BOARD MEMBERS

<https://www.wjgnet.com/2307-8960/editorialboard.htm>

PUBLICATION DATE

April 6, 2022

COPYRIGHT

© 2022 Baishideng Publishing Group Inc

INSTRUCTIONS TO AUTHORS

<https://www.wjgnet.com/bpg/gerinfo/204>

GUIDELINES FOR ETHICS DOCUMENTS

<https://www.wjgnet.com/bpg/GerInfo/287>

GUIDELINES FOR NON-NATIVE SPEAKERS OF ENGLISH

<https://www.wjgnet.com/bpg/gerinfo/240>

PUBLICATION ETHICS

<https://www.wjgnet.com/bpg/GerInfo/288>

PUBLICATION MISCONDUCT

<https://www.wjgnet.com/bpg/gerinfo/208>

ARTICLE PROCESSING CHARGE

<https://www.wjgnet.com/bpg/gerinfo/242>

STEPS FOR SUBMITTING MANUSCRIPTS

<https://www.wjgnet.com/bpg/GerInfo/239>

ONLINE SUBMISSION

<https://www.f6publishing.com>



Severe pneumonia and acute myocardial infarction complicated with pericarditis after percutaneous coronary intervention: A case report

Wei-Chao Liu, Shun-Bao Li, Chen-Feng Zhang, Xiang-Hui Cui

Specialty type: Cardiac and Cardiovascular Systems

Provenance and peer review: Unsolicited article; Externally peer reviewed.

Peer-review model: Single blind

Peer-review report's scientific quality classification

Grade A (Excellent): 0
Grade B (Very good): B
Grade C (Good): C, C
Grade D (Fair): 0
Grade E (Poor): 0

P-Reviewer: Anandan H, Fujimori S, Teragawa H

Received: October 3, 2021

Peer-review started: October 3, 2021

First decision: January 11, 2022

Revised: January 25, 2022

Accepted: February 23, 2022

Article in press: February 23, 2022

Published online: April 6, 2022



Wei-Chao Liu, Shun-Bao Li, Chen-Feng Zhang, Xiang-Hui Cui, The Third Ward of the Department of Cardiology, Baoding No. 1 Central Hospital, Baoding 071000, Hebei Province, China

Corresponding author: Shun-Bao Li, MD, Chief Physician, The Third Ward of the Department of Cardiology, Baoding No. 1 Central Hospital, No. 320 of North Great Wall Street, Baoding 071000, Hebei Province, China. lishunbao.good@163.com

Abstract

BACKGROUND

Cases of severe pneumonia complicated with acute myocardial infarction (AMI) with good prognosis after percutaneous coronary intervention (PCI) are rare, especially those with postoperative pericarditis and intestinal obstruction.

CASE SUMMARY

A 53-year-old male patient was admitted to the emergency department of our hospital because of paroxysmal chest tightness for 4 d, aggravated with chest pain for 12 h. The symptoms, electrocardiography, biochemical parameters, echocardiography and chest computed tomography confirmed the diagnosis of severe pneumonia complicated with AMI. The patient was treated with antiplatelet aggregation, anticoagulation, lipid regulation, vasodilation, anti-infective agents and direct PCI. The patient was discharged after 3 wk of treatment. Follow-up showed that the patient was asymptomatic without recurrence.

CONCLUSION

For patients with severe pneumonia complicated with AMI, PCI and antibiotic therapy is a life-saving strategy.

Key Words: Severe pneumonia; Acute myocardial infarction; Percutaneous coronary intervention; Pericarditis; Intestinal obstruction; Case report

©The Author(s) 2022. Published by Baishideng Publishing Group Inc. All rights reserved.

Core Tip: Severe pneumonia complicated with acute myocardial infarction (AMI) is a critical and rare disease in clinic. Patients with good prognosis after emergency percutaneous coronary intervention (PCI) combined with antibiotic treatment have been rarely reported. We here report a case of severe pneumonia and AMI complicated with pericarditis and intestinal obstruction after direct PCI. The patient had a good prognosis after anti-infective and symptomatic treatment.

Citation: Liu WC, Li SB, Zhang CF, Cui XH. Severe pneumonia and acute myocardial infarction complicated with pericarditis after percutaneous coronary intervention: A case report. *World J Clin Cases* 2022; 10(10): 3222-3231

URL: <https://www.wjgnet.com/2307-8960/full/v10/i10/3222.htm>

DOI: <https://dx.doi.org/10.12998/wjcc.v10.i10.3222>

INTRODUCTION

The cause of death of patients with severe pneumonia is not only pneumonia itself, but also the complications of pneumonia[1,2]. There is evidence showing that acute pulmonary infection can increase the incidence of cardiovascular adverse events[3].

Successful percutaneous coronary intervention (PCI) for severe pneumonia complicated with acute myocardial infarction (AMI) is rare. Here, we report a case of severe pneumonia complicated with AMI successfully treated with PCI and antibiotics. Written informed consent was obtained from the patient for publication of this case report.

CASE PRESENTATION

Chief complaints

A 53-year-old male patient was admitted to the emergency department of our hospital because of intermittent chest tightness for 4 d, aggravated with chest pain for 12 h.

History of present illness

Four days before admission, the patient developed intermittent chest tightness and cough after catching a cold, which was relieved after a few minutes. Twelve hours before admission, the patient had persistent chest tightness with chest and back pain, cough, dyspnea and difficulty lying flat, and the symptoms could not be relieved. The patient had no fever, yellow sputum, hemoptysis, abdominal pain or diarrhea.

History of past illness

The patient had a history of type 2 diabetes and chronic cerebral infarction without any sequelae.

Physical examination

The patient's temperature was 36.8°C, pulse rate was 82 beats/min, respiratory rate was 16 breaths/min and blood pressure was 134/86 mmHg. The respiratory sound of both lungs was reduced and a small amount of dry and wet rales could be heard in the middle and lower lungs. The heart rate was 82 beats/min, the heart rhythm was uniform, and there was no obvious murmur in the auscultation area of each valve or pericardial friction sound. There was no edema in either lower limbs. The pathological signs were negative.

Laboratory examinations

Routine blood tests showed that the leukocyte count was $14.36 \times 10^9/L$ (reference range: 3.5×10^9 - $9.5 \times 10^9/L$), neutrophil count $11.45 \times 10^9/L$ (reference range: 1.8×10^9 - $6.3 \times 10^9/L$) and neutrophil ratio 79.70% (reference range: 40.0%-75.0%). C-reactive protein (CRP) was 106.0 mg/L (reference range: 0-6.0 mg/L). Procalcitonin (PCT) was 0.30 ng/mL (reference range: 0-0.25 ng/mL). The markers of myocardial necrosis showed that creatine kinase isozyme (CK-MB) was 223.85 U/L (reference range: 0-24.0 U/L), myoglobin (Myo) 3091.0 ng/mL (reference range: 28 - 72 ng/mL) and high-sensitivity troponin T (hs-TNT) was 4963.0 pg/mL (reference range: 12.70-24.90 pg/mL). The precursor of amino terminal-B-type natriuretic peptide (NT-proBNP) was 717.0 pg/mL (reference range: ≤ 125 pg/mL). D-dimer was 0.45 mg/L (reference range: 0-0.55 mg/L).

Imaging examinations

Electrocardiography (ECG) showed sinus rhythm, pathological Q waves on III, aVF leads and high and

sharp T waves on V1-V5 Leads (Figure 1A). Chest computed tomography (CT) showed multiple patchy high-density shadows in both lungs, bilateral pleural effusion and enlarged hilar shadows (Figure 2A). Color Doppler echocardiography showed left atrial enlargement, a small amount of aortic regurgitation and tricuspid regurgitation, decreased left ventricular diastolic function (grade II), and normal left ventricular systolic function.

FINAL DIAGNOSIS

The patient was finally diagnosed with severe pneumonia complicated with non-ST-segment elevation myocardial infarction (NSTEMI).

TREATMENT

The patient was treated with antiplatelet aggregation, anticoagulation, lipid regulation, plaque stabilization, coronary artery expansion, anti-infective agents and noninvasive ventilator-assisted respiration. The next day, the chest pain worsened without significant remission. Emergency coronary angiography (CAG) was performed, and showed that the coronary arteries were left dominant with localized mild stenosis at the proximal left anterior descending branch (LAD), complete occlusion at the proximal circumflex branch (LCX) and diffuse stenosis at the distal right coronary artery (RCA), the heaviest of which was about 90% (Figure 3A). Considering that the LCX was the offending vessel, interventional therapy was administered. A Resolute 3.0 mm × 22 mm stent was implanted at the proximal LCX. After reperfusion therapy, there was no residual stenosis or dissection of the LCX, and the blood flow of thrombolysis in myocardial infarction (TIMI) was grade 3 (Figure 3B).

However, the patient still complained of chest pain and shortness of breath after the operation. Postoperative ECG showed sinus rhythm and ST-segment elevation on leads V2-V6 of the anterior wall (Figure 1B). Because acute thrombosis or reinfarction was not excluded, emergency CAG was performed again after explaining the condition to the patient's family. The second CAG showed that the original stent of the LCX was unobstructed and there were no significant dynamic changes or thrombus in the LAD and the RCA (Figure 3C). The patient complained of left chest pain after the operation. The pain worsened when turning the body and breathing, accompanied by chest tightness, shortness of breath, inability to lie flat, without expectoration or fever. On physical examination, wet rales could be heard in both lungs, the heart rate was 90 beats/min, the rhythm was uniform and pericardial friction sound appeared. ECG showed that the ST-segment of V2-V6 Leads increased with arch back downward, which was consistent with the characteristics of pericarditis. Repeated blood tests showed that the leukocyte count was $12.64 \times 10^9/L$ and neutrophil ratio was 79.30%. CRP increased to 360.0 mg/L. PCT increased to 0.99 ng/mL. CK-MB was 34.8 U/L, Myo was 59.1 ng/mL and hs-TNT was 3860.0 pg/mL. NT-proBNP increased to 3801.0 pg/mL. D-dimer was 0.84 mg/L. Repeated chest CT showed multiple patchy high-density shadows in both lungs and bilateral pleural effusion, which was significantly worse than before (Figure 2B). Echocardiography showed left ventricular enlargement, segmental wall motion abnormality, aortic valve calcification with a small amount of regurgitation and tricuspid regurgitation, and reduced left ventricular diastolic function (grade II) and left ventricular systolic function. According to the symptoms of chest pain, new pericardial friction sound, ST-segment arch back downward elevation on ECG, elevated CRP and PCT, reduced markers of myocardial necrosis, and findings of chest CT and echocardiography, it was considered that pneumonia was aggravated and AMI was complicated with pericarditis.

Considering the aggravation of pulmonary infection and heart failure, the antibiotics were upgraded from levofloxacin to biapenem combined with moxifloxacin, and the recombinant human brain natriuretic peptide was pumped intravenously to treat heart failure. Six days later, the patient's symptoms of chest pain and shortness of breath were significantly relieved. ECG showed sinus rhythm and the elevation of ST-segment on leads V2-V6 decreased obviously. Chest CT showed multiple patchy high-density shadows and the pleural effusion was obviously absorbed (Figure 2C). Blood test showed that the leukocyte count decreased to $5.68 \times 10^9/L$, neutrophil count decreased to $3.63 \times 10^9/L$, neutrophil ratio decreased to 63.9 %, CRP decreased to 138.00 mg/L, PCT decreased to 0.23 ng/mL, CK-MB decreased to 26.8 U/L and NT-proBNP decreased to 710.70 pg/mL. D-dimer increased to 4.4 mg/L. Based on the disappearance of chest pain and pericardial friction sound, the ST-segment depression on ECG, inflammatory absorption on chest CT and the decreased inflammatory indexes, the patient's pneumonia and pericarditis were considered significantly improved.

However, the patient complained of abdominal pain, abdominal distention and inability to defecate. Blood tests showed that the leukocyte count, the neutrophil count, the neutrophil ratio and the D-dimer increased again. Bedside abdominal X-ray showed intestinal dilatation and gas-fluid levels, which supported the diagnosis of intestinal obstruction (Figure 4A). The patient was given an enema, gastrointestinal motility, gastrointestinal decompression and anti-infective treatment. Three days later, the patient could defecate and exhaust on his own and the symptoms of abdominal pain and distention

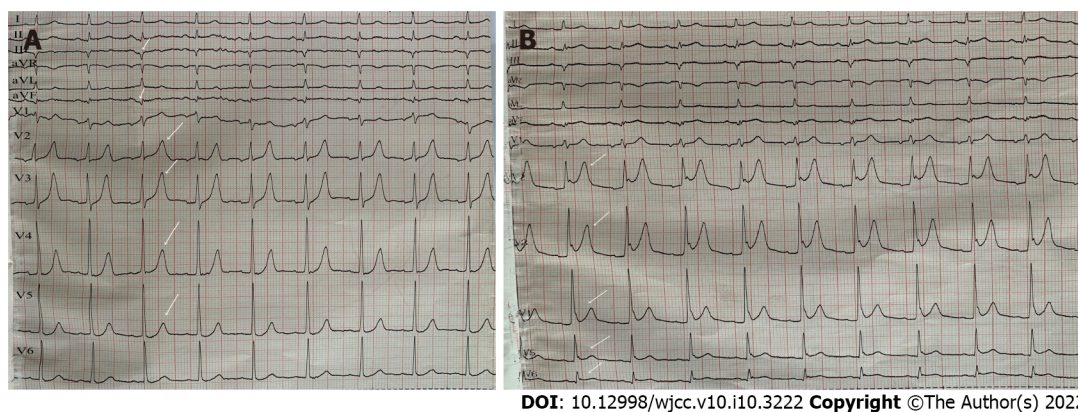


Figure 1 Electrocardiography of the patient. A: Electrocardiography (ECG) at admission showed sinus rhythm, pathological Q waves on III, aVF leads and high and sharp T waves on V2-V5 leads (white arrow); B: Postoperative ECG showed sinus rhythm and ST-segment elevation on leads V2-V6 of the anterior wall (white arrow).

disappeared. Abdominal X-ray showed that the intestinal obstruction disappeared (Figure 4B).

Four days later, no chest pain, shortness of breath or any other discomfort were observed. Blood tests showed that the leukocyte count, the neutrophil count, neutrophil ratio, CRP and PCT all decreased. But the D-dimer increased to 7.39 mg/L, and deep venous thrombosis and pulmonary embolism were excluded. Color Doppler ultrasound of deep veins of both lower limbs showed no obvious thrombosis. Pulmonary embolism was not seen on enhanced pulmonary CT, but the pleural effusion was more than before (Figure 5). Paracentesis of the pleura was carried out. It was found that the color of pleural effusion was red and turbid, the Rivalta test was positive, the leukocyte count was $1077 \times 10^6/L$ (reference range: $< 8 \times 10^6/L$), red blood cell counts $149784 \times 10^6/L$ (reference range: $< 5000 \times 10^6/L$), monocytes accounted for 86% and the multinucleated cells accounted for 14% in leukocyte classification. The pleural effusion biochemistry showed that albumin was 18.17 g/L, globulin 19.86 g/L, lactate dehydrogenase 688.96 U/L, chlorine 103.55 mmol/L, glucose 10.12 mmol/L and adenosine deaminase 12.85 U/L. No cancer cells were found by pathological examination of the hydrothorax. The tumor markers and antinuclear antibody spectrum were negative. Finally, it was considered that the increased D-dimer was related to the bloody pleural effusion, which was secondary to severe pneumonia. After thoracic drainage and effective anti-infective treatment, the symptoms of chest pain and shortness of breath disappeared completely and the condition improved significantly. Blood tests showed that the leukocyte count, the neutrophil count, the neutrophil ratio and PCT were all decreased to the normal range. CRP decreased to 18.6 mg/L and D-dimer decreased to 5.33 mg/L. The patient's condition improved and he was discharged from hospital.

OUTCOME AND FOLLOW-UP

Two weeks later, the patient went to the clinic for follow-up. The patient had no symptoms. Routine blood tests showed that the leukocyte count was $5.88 \times 10^9/L$, neutrophil count $3.23 \times 10^9/L$, and neutrophil ratio 54.9%. CRP decreased to 6.83 mg/L. D-dimer decreased to 2.19 mg/L. NT-proBNP decreased to 679.8 pg/mL. Chest CT showed that the patchy high-density shadows and pleural effusion were almost absorbed (Figure 2D). Six weeks later, follow-up examinations showed that the leukocyte count was $6.07 \times 10^9/L$, neutrophil count $3.66 \times 10^9/L$, and neutrophil ratio 60.2%. CRP decreased to 1.76 mg/L. D-dimer decreased to 0.24 mg/L, which was normal (Table 1). The prognosis of the patient was good.

DISCUSSION

Some studies have shown that there is a correlation between community-acquired pneumonia (CAP) and AMI[4]. AMI is found in 15% of patients with severe pneumonia and there is a significant association between AMI and the pneumonia severity index score. AMI is the possible cause of death in patients with severe pneumonia[5]. Other studies have suggested that the incidence of CAP complicated with acute coronary syndrome is 0.7% to 11%[6,7]. A total of 50 119 patients were included in the study of Perry *et al*[8], which showed that about 1.5% of patients with pneumonia had AMI within 90 d, which was the largest number of cases in previous studies about cardiovascular events after pneumonia. Rae's study suggested that the cause of death of most patients with severe pneumonia was cardiac arrest,

Table 1 Blood tests of the patient from admission to discharge and follow-up

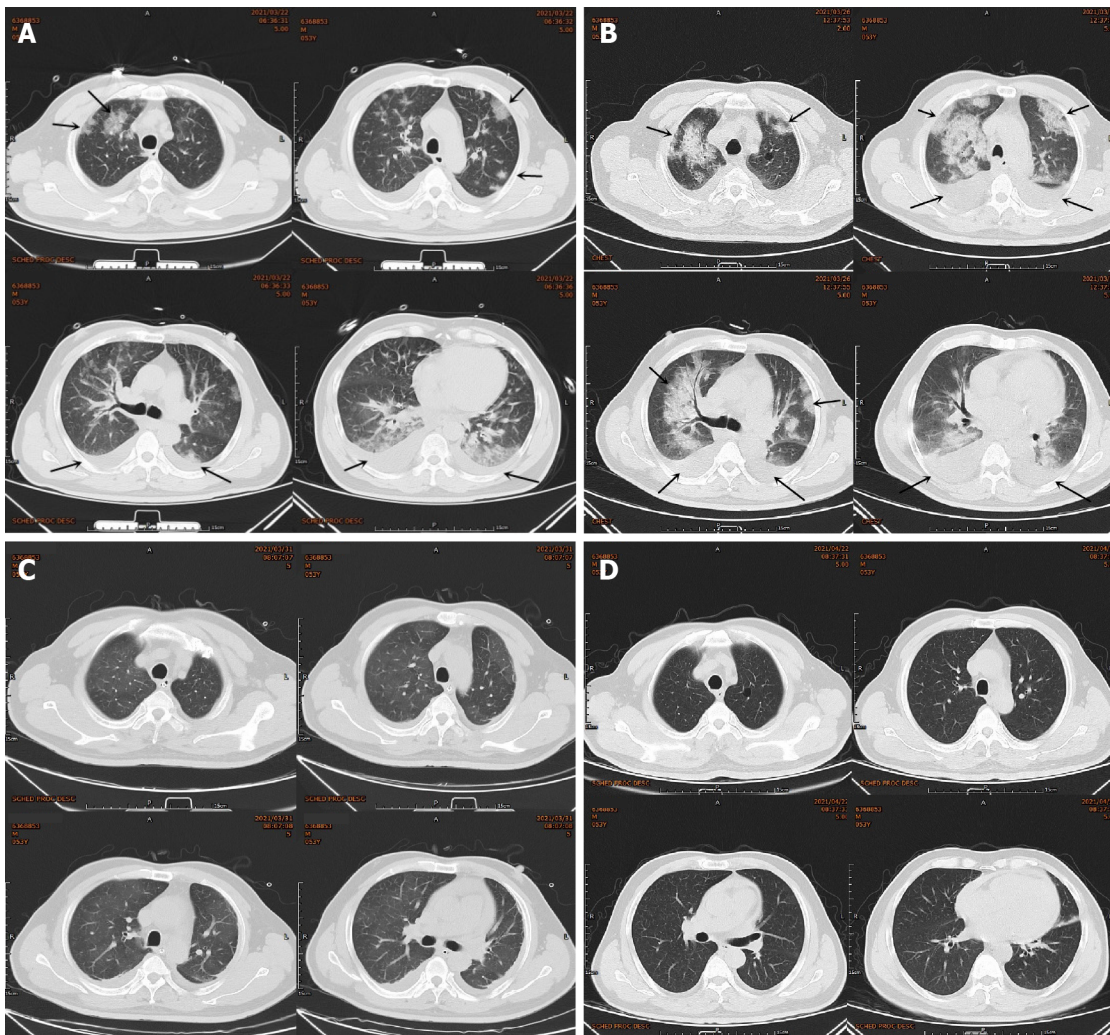
Blood test	Mar 22 nd	Mar 23 rd	Mar 25 th	Mar 26 th	Mar 27 th	Mar 28 th	Mar 29 th	Mar 31 st	Apr 1 st	Apr 2 nd	Apr 4 th	Apr 6 th	Apr 8 th	Apr 13 th	Apr 22 nd	Apr 29 th	Jun 3 rd
Leukocyte count (3.5×10^9 - 9.5×10^9 /L)	14.36	12.29	12.64	8.82	5.92	6.13	5.68	10.11	10.78	9.73	6.28	5.75	4.52	5.96	5.19	5.88	6.07
Neutrophil count (1.8×10^9 - 6.3×10^9 /L)	11.45	10.23	10.02	7.21	4.13	3.97	3.63	7.90	8.68	7.72	4.66	4.19	2.92	3.84	3.21	3.23	3.66
Lymphocyte count (1.1×10^9 - 3.2×10^9 /L)	2.16	1.24	1.32	1.06	0.98	1.42	1.31	1.49	1.44	1.44	1.15	1.13	1.03	1.38	1.43	2.07	1.80
Monocyte count (0.1×10^9 - 3.6×10^9 /L)	0.64	1.02	1.10	0.64	0.32	0.62	0.53	0.64	0.49	0.40	0.35	0.32	0.38	0.52	0.34	0.37	0.37
Neutrophil ratio (40.0%-75.0%)	79.7	83.3	79.3	81.8	69.7	64.7	63.9	78.2	80.5	79.4	74.2	72.8	64.7	64.4	61.7	54.9	60.2
CK-MB (0-24 U/L)	223.8	129.4	49.0	34.8	33.6	13.96	26.8	34.0	25.9	39.0	23.6	17.2	13.9	-	11.1	14.6	-
NT-proBNP (≤ 125 pg/mL)	717.0	1266	3801	3638	1686	1364	710.7	1319	801.9	848.8	-	-	-	1168	718.2	679.8	-
CRP (0.00-6.00 mg/L)	8.86	106.0	360.0	-	-	-	138.0	-	-	73.9	27.4	15.5	12.9	18.6	9.42	6.83	1.76
PCT (0-0.25 ng/mL)	0.08	0.30	0.99	0.68	0.52	-	0.23	0.19	-	0.10	0.05	0.05	0.01	0.01	-	-	-
D-dimer (0-0.55 mg/L)	0.45	0.31	0.84	-	2.91	2.54	4.40	5.72	6.44	7.72	7.99	7.39	7.31	5.33	6.99	2.19	0.24

CK-MB: Creatine kinase isozyme; NT-proBNP: Precursor of amino terminal-B-type natriuretic peptide; CRP: C-reactive protein; PCT: Procalcitonin.

arrhythmia, AMI and heart failure. About one third of pneumonia patients have cardiovascular complications during hospitalization. The risk of AMI is highest in the first few days of CAP and decreases over time. One year after CAP, the risk of AMI remains increased[9]. Another study showed that the incidence of CAP complicated with AMI was about 3.1% in patients aged > 65 years, while the incidence of AMI was about 1.0% in those under 65 years[10]. In our case report, the patient was only 53 years old, but after severe pneumonia, he was complicated with AMI, pericarditis, intestinal obstruction and pleural effusion which is rare.

Studies have shown that plaque rupture or *in situ* thrombosis formation caused by acute pneumonia is the main etiology of pneumonia complicated with AMI[11]. Acute pneumonia can cause an increase of proinflammatory factors, which can then lead to atherosclerotic inflammatory changes, endothelial dysfunction, atheroma instability, rupture of the atheromatous plaque, increased fibrinogen levels, and prothrombotic vascular conditions[12-16]. Another etiology of AMI caused by pneumonia is platelet activation. The elevated neutrophils adhere to the surface of vascular endothelial cells, then promote expression of inflammatory factors and adhesion molecules, which leads to an increase of thromboxane synthesis, platelet aggregation and vasoconstriction[9,17]. Ventilation-perfusion mismatching and intrapulmonary shunt caused by severe pneumonia can aggravate hypoxia. Systemic inflammatory response can lead to organ hypoperfusion and multiple organ failure. The heart is one of the most vulnerable organs.

The main clinical manifestations of pneumonia are cough, expectoration, fever and dyspnea. In the present case, the patient had cough and dyspnea, but there was no fever in the whole disease course. Due to different types of pneumonia, different severity of pneumonia, different incidence groups and

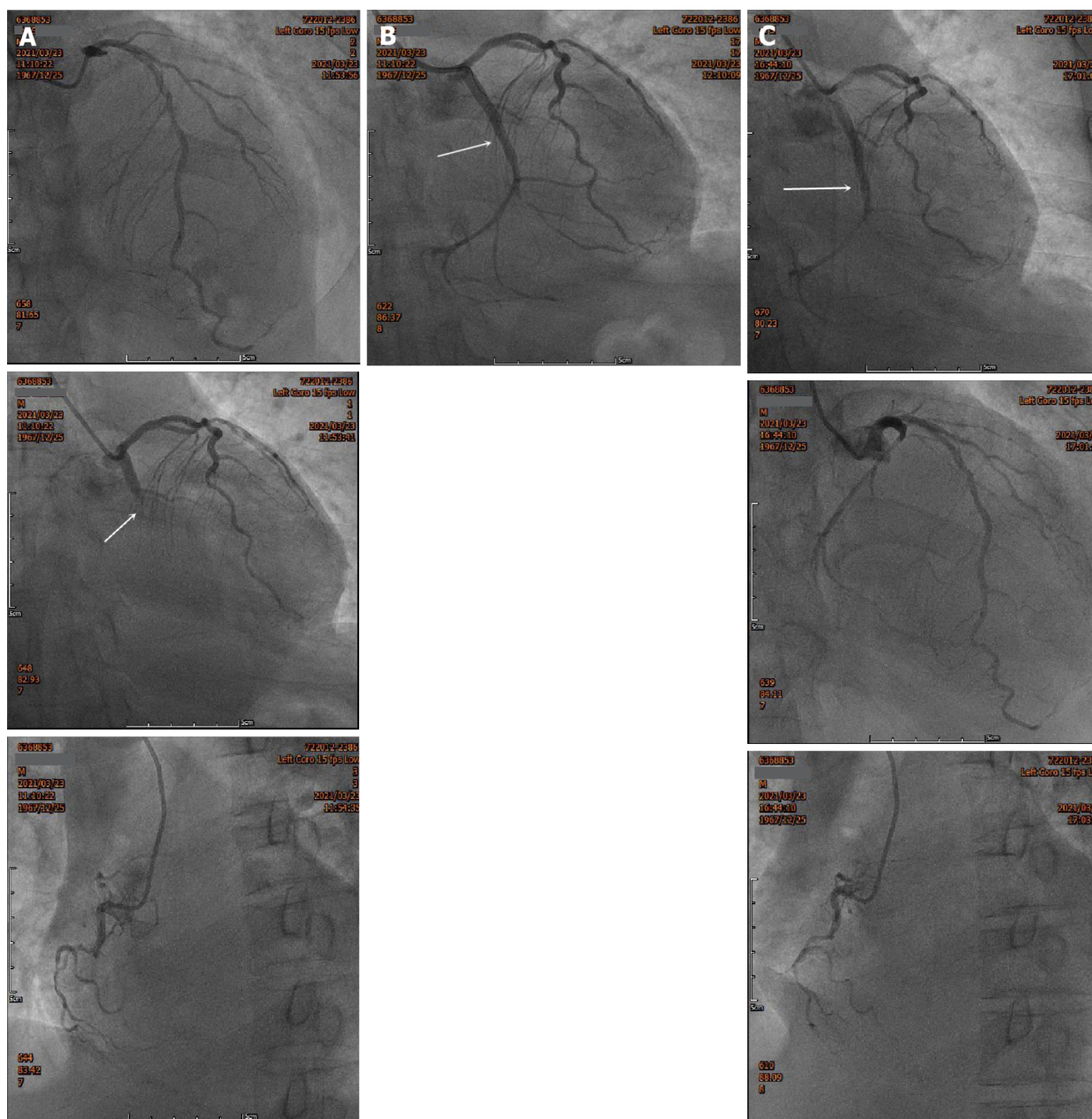


DOI: 10.12998/wjcc.v10.i10.3222 Copyright ©The Author(s) 2022.

Figure 2 Chest computed tomography of the patient. A: Chest computed tomography (CT) showed multiple patchy high-density shadows in both lungs, and bilateral pleural effusion and enlarged hilar shadows (black arrow); B: Repeated chest CT showed multiple patchy high-density shadows in both lungs and bilateral pleural effusion, which was significantly worse than before (black arrow); C: Repeated chest CT showed the multiple patchy high-density shadows and the pleural effusion were obviously absorbed; D: Repeated Chest CT showed that the patchy high-density shadows and the pleural effusion were almost absorbed.

other factors, some patients with pneumonia may not have fever. The causes of pneumonia without fever maybe explained as follows. First, in the early stage of pneumonia, because of its short infection time, small number of pathogens and relatively weak pathogenicity, it can- not stimulate the body to produce fever. Second, some elderly patients may not have fever in the event of lung infection due to their aging and weakened nerve reflex. Third, in case of severe pneumonia, due to the extremely poor state of the body, it is impossible to induce fever. In the present case, the patient had severe pneumonia and AMI at the same time. The body was in a serious state of stress. The stress state can increase the secretion of pituitary and adrenocortical hormones. Excessive glucocorticoids inhibit the immune response, resulting in weakening of the response to pathogens, thus reducing the body's resistance ability. In addition, in the acute phase of AMI, echocardiography showed only diastolic dysfunction and no systolic dysfunction, which may be related to the early myocardial ischemia, but the infarct area was not large enough to affect the systolic function. Moreover, many patients with acute NSTEMI were confirmed by CAG that most of the infarct related vessels were circumflex and intermediate branches, and a few were left main artery lesions.

For patients with severe pneumonia complicated with AMI, prompt reperfusion combined with targeted anti-infective therapy is still preferred. According to the 2020 European Society of Cardiology (ESC) guidelines for the management of acute coronary syndromes in patients presenting without persistent ST-segment elevation, early interventional therapy (< 24 h) should be adopted for patients with established diagnosis of NSTEMI, with new continuous ST/T dynamic changes (with or without symptoms), cardiac arrest and resuscitation without ST-segment elevation or cardiogenic shock, and GRACE score > 140[18]. Timely and effective opening of the infarct-related vessels can effectively prevent the occurrence of complications such as heart failure, arrhythmia, cardiac arrest and cardiac rupture, so as to improve the survival rate of patients. Prompt and appropriate antimicrobial therapy is



DOI: 10.12998/wjcc.v10.i10.3222 Copyright © The Author(s) 2022.

Figure 3 Emergency coronary angiography images of the patient. A: Emergency coronary angiography (CAG) showed that the coronary arteries were left dominant with localized mild stenosis at the proximal left anterior descending branch (LAD), complete occlusion at the proximal circumflex branch (LCX) (white arrow) and diffuse stenosis at the distal RCA, the heaviest of which was about 90%; B: CAG after reperfusion therapy showed that there was no residual stenosis or dissection of the LCX and the TIMI blood flow was grade 3 (white arrow); C: Secondary CAG showed that the original stent of the proximal LCX was unobstructed (white arrow) and there were no significant dynamic changes or thrombus in the LAD and the RCA.

still a crucial treatment for severe pneumonia. The therapeutic effect of antibiotics can be optimized by adjusting the drug according to their pharmacodynamic and pharmacokinetic characteristics[19]. Multidisciplinary clinical guideline research shows that the combined application of anti-coccal and anti-bacilli drugs has a good therapeutic effect in severe pneumonia or pneumonia caused by atypical pathogens. In addition, some studies have shown that immunomodulators, glucocorticoids, macrolides and statins have certain adjuvant therapeutic effects in severe pneumonia[20]. For patients with acute hypoxemic respiratory failure, noninvasive or invasive ventilation is needed to correct hypoxic respiratory failure[21].

For patients with severe pneumonia complicated with AMI, there is no definite evidence proving that emergency PCI can improve the long-term prognosis until now. A prospective cohort study showed that for patients with AMI after infection, the mortality during hospitalization was 13% in the PCI group *vs* 8% in the non-PCI group, and the 1-year mortality was 24% in the PCI group *vs* 19% in the non-PCI group. This study indicates that PCI might not improve short-term and long-term prognosis in patients with angiography-confirmed coronary stenosis[22]. However, our patient who had severe pneumonia

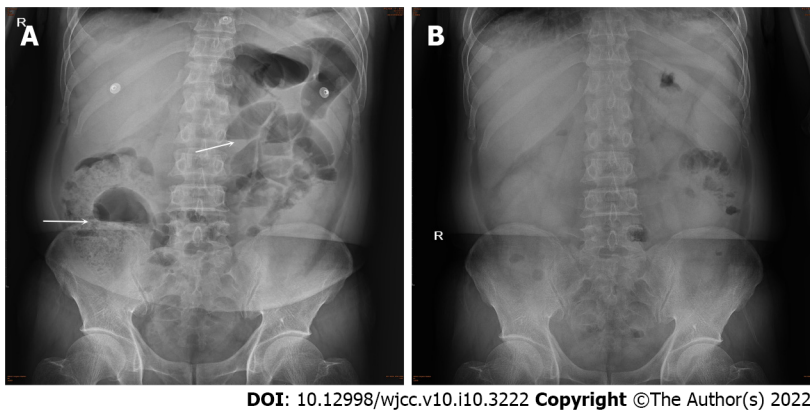


Figure 4 Abdominal X-ray images of the patient. A: Beside abdominal X-ray showed intestinal dilatation and gas-fluid levels, which supported the diagnosis of intestinal obstruction (white arrow); B: Repeated abdominal X-ray showed that the intestinal obstruction disappeared.

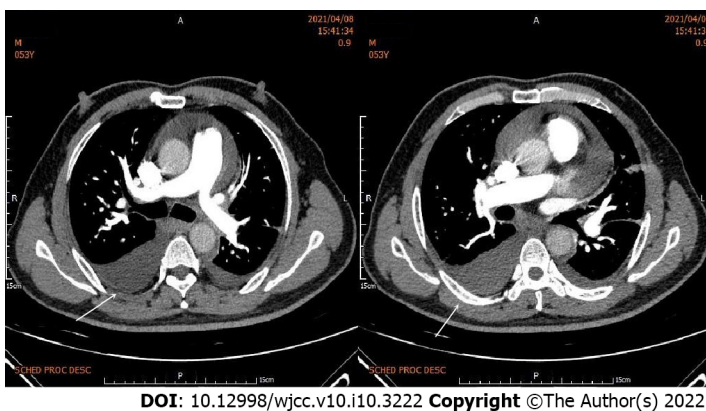

Figure 5 Pulmonary embolism was not seen on enhanced pulmonary computed tomography, but the pleural effusion increased (white arrow).

complicated with AMI had good prognosis after emergency PCI combined with effective anti-infective treatment.

CONCLUSION

Severe pneumonia complicated with AMI, pericarditis and intestinal obstruction is rare clinically. Our case report shows that emergency PCI combined with effective antibiotic treatment can save the lives of patients with severe pneumonia complicated with AMI, pericarditis and intestinal obstruction.

ACKNOWLEDGEMENTS

We thank all of our colleagues at the Department of Cardiology and the Department of Medical Imaging, Baoding No. 1 Central Hospital.

FOOTNOTES

Author contributions: Liu WC and Cui XH were the patient's physicians, reviewed the literature and contributed to manuscript drafting; Zhang CF reviewed the literature and contributed to manuscript drafting; Li SB was responsible for revision of the manuscript; all authors issued final approval for the version to be submitted.

Informed consent statement: Informed written consent was obtained from the patient for publication of this report and any accompanying images.

Conflict-of-interest statement: The authors declare that they have no conflict of interest.

CARE Checklist (2016) statement: The authors have read the CARE Checklist (2016), and the manuscript was prepared and revised according to the CARE Checklist (2016).

Open-Access: This article is an open-access article that was selected by an in-house editor and fully peer-reviewed by external reviewers. It is distributed in accordance with the Creative Commons Attribution NonCommercial (CC BY-NC 4.0) license, which permits others to distribute, remix, adapt, build upon this work non-commercially, and license their derivative works on different terms, provided the original work is properly cited and the use is non-commercial. See: <https://creativecommons.org/licenses/by-nc/4.0/>

Country/Territory of origin: China

ORCID number: Wei-Chao Liu 0000-0002-3569-7050; Shun-Bao Li 0000-0001-5963-5551; Chen-Feng Zhang 0000-0003-4652-8866; Xiang-Hui Cui 0000-0001-9993-752X.

S-Editor: Wang JL

L-Editor: A

P-Editor: Wang JL

REFERENCES

- 1 **Mortensen EM**, Coley CM, Singer DE, Marrie TJ, Obrosky DS, Kapoor WN, Fine MJ. Causes of death for patients with community-acquired pneumonia: results from the Pneumonia Patient Outcomes Research Team cohort study. *Arch Intern Med* 2002; **162**: 1059-1064 [PMID: 11996618 DOI: 10.1001/archinte.162.9.1059]
- 2 **Chalmers JD**. ICU admission and severity assessment in community-acquired pneumonia. *Crit Care* 2009; **13**: 156 [PMID: 19591640 DOI: 10.1186/cc7889]
- 3 **Singanayagam A**, Singanayagam A, Elder DH, Chalmers JD. Is community-acquired pneumonia an independent risk factor for cardiovascular disease? *Eur Respir J* 2012; **39**: 187-196 [PMID: 21737556 DOI: 10.1183/09031936.00049111]
- 4 **Viasus D**, Garcia-Vidal C, Manresa F, Dorca J, Gudiol F, Carratalà J. Risk stratification and prognosis of acute cardiac events in hospitalized adults with community-acquired pneumonia. *J Infect* 2013; **66**: 27-33 [PMID: 22981899 DOI: 10.1016/j.jinf.2012.09.003]
- 5 **Ramirez J**, Aliberti S, Mirsaeidi M, Peyrani P, Filardo G, Amir A, Moffett B, Gordon J, Blasi F, Bordon J. Acute myocardial infarction in hospitalized patients with community-acquired pneumonia. *Clin Infect Dis* 2008; **47**: 182-187 [PMID: 18533841 DOI: 10.1086/589246]
- 6 **Cangemi R**, Calvieri C, Falcone M, Bucci T, Bertazzoni G, Scarpellini MG, Barillà F, Taliani G, Violi F; SIXTUS Study Group. Relation of Cardiac Complications in the Early Phase of Community-Acquired Pneumonia to Long-Term Mortality and Cardiovascular Events. *Am J Cardiol* 2015; **116**: 647-651 [PMID: 26089009 DOI: 10.1016/j.amjcard.2015.05.028]
- 7 **Postma DF**, Spitoni C, van Werkhoven CH, van Elden LJR, Oosterheert JJ, Bonten MJM. Cardiac events after macrolides or fluorquinolones in patients hospitalized for community-acquired pneumonia: post-hoc analysis of a cluster-randomized trial. *BMC Infect Dis* 2019; **19**: 17 [PMID: 30612559 DOI: 10.1186/s12879-018-3630-7]
- 8 **Perry TW**, Pugh MJ, Waterer GW, Nakashima B, Orihuela CJ, Copeland LA, Restrepo MI, Anzueto A, Mortensen EM. Incidence of cardiovascular events after hospital admission for pneumonia. *Am J Med* 2011; **124**: 244-251 [PMID: 21396508 DOI: 10.1016/j.amjmed.2010.11.014]
- 9 **Rae N**, Finch S, Chalmers JD. Cardiovascular disease as a complication of community-acquired pneumonia. *Curr Opin Pulm Med* 2016; **22**: 212-218 [PMID: 26886878 DOI: 10.1097/MCP.0000000000000261]
- 10 **Kang Y**, Fang XY, Wang D, Wang XJ. Factors associated with acute myocardial infarction in older patients after hospitalization with community-acquired pneumonia: a cross-sectional study. *BMC Geriatr* 2021; **21**: 113 [PMID: 33563232 DOI: 10.1186/s12877-021-02056-6]
- 11 **Aliberti S**, Ramirez JA. Cardiac diseases complicating community-acquired pneumonia. *Curr Opin Infect Dis* 2014; **27**: 295-301 [PMID: 24685550 DOI: 10.1097/QCO.0000000000000055]
- 12 **Corrales-Medina VF**, Musher DM, Shachkina S, Chirinos JA. Acute pneumonia and the cardiovascular system. *Lancet* 2013; **381**: 496-505 [PMID: 23332146 DOI: 10.1016/S0140-6736(12)61266-5]
- 13 **Corrales-Medina VF**, Madjid M, Musher DM. Role of acute infection in triggering acute coronary syndromes. *Lancet Infect Dis* 2010; **10**: 83-92 [PMID: 20113977 DOI: 10.1016/S1473-3099(09)70331-7]
- 14 **Peyrani P**, Ramirez J. What is the association of cardiovascular events with clinical failure in patients with community-acquired pneumonia? *Infect Dis Clin North Am* 2013; **27**: 205-210 [PMID: 23398875 DOI: 10.1016/j.idc.2012.11.010]
- 15 **Crawford VL**, McNerlan SE, Stout RW. Seasonal changes in platelets, fibrinogen and factor VII in elderly people. *Age Ageing* 2003; **32**: 661-665 [PMID: 14600009 DOI: 10.1093/ageing/afg113]
- 16 **Woodhouse PR**, Khaw KT, Plummer M, Foley A, Meade TW. Seasonal variations of plasma fibrinogen and factor VII activity in the elderly: winter infections and death from cardiovascular disease. *Lancet* 1994; **343**: 435-439 [PMID: 7508540 DOI: 10.1016/S0140-6736(94)92689-1]
- 17 **Feldman C**, Anderson R. Community-Acquired Pneumonia: Pathogenesis of Acute Cardiac Events and Potential Adjunctive Therapies. *Chest* 2015; **148**: 523-532 [PMID: 25951315 DOI: 10.1378/chest.15-0484]
- 18 **Collet JP**, Thiele H, Barbato E, Barthélémy O, Bauersachs J, Bhatt DL, Dendale P, Dorobantu M, Edvardsen T, Folliquet

- T, Gale CP, Gilard M, Jobs A, Jüni P, Lambrinou E, Lewis BS, Mehilli J, Meliga E, Merkely B, Mueller C, Roffi M, Rutten FH, Sibbing D, Siontis GCM; ESC Scientific Document Group. 2020 ESC Guidelines for the management of acute coronary syndromes in patients presenting without persistent ST-segment elevation. *Eur Heart J* 2021; **42**: 1289-1367 [PMID: 32860058 DOI: 10.1093/eurheartj/ehaa575]
- 19 **De Pascale G**, Bello G, Tumbarello M, Antonelli M. Severe pneumonia in intensive care: cause, diagnosis, treatment and management: a review of the literature. *Curr Opin Pulm Med* 2012; **18**: 213-221 [PMID: 22388582 DOI: 10.1097/MCP.0b013e328351f9bd]
- 20 **Sibila O**, Restrepo MI, Anzueto A. What is the best antimicrobial treatment for severe community-acquired pneumonia (including the role of steroids and statins and other immunomodulatory agents). *Infect Dis Clin North Am* 2013; **27**: 133-147 [PMID: 23398870 DOI: 10.1016/j.idc.2012.11.014]
- 21 **Arabi YM**, Fowler R, Hayden FG. Critical care management of adults with community-acquired severe respiratory viral infection. *Intensive Care Med* 2020; **46**: 315-328 [PMID: 32040667 DOI: 10.1007/s00134-020-05943-5]
- 22 **Putot A**, Chagué F, Manckoundia P, Brunel P, Beer JC, Cottin Y, Zeller M. Post-Infectious Myocardial Infarction: Does Percutaneous Coronary Intervention Improve Outcomes? *J Clin Med* 2020; **9** [PMID: 32466424 DOI: 10.3390/jcm9061608]



Published by **Baishideng Publishing Group Inc**
7041 Koll Center Parkway, Suite 160, Pleasanton, CA 94566, USA

Telephone: +1-925-3991568

E-mail: bpgoffice@wjgnet.com

Help Desk: <https://www.f6publishing.com/helpdesk>

<https://www.wjgnet.com>

