

World Journal of *Clinical Cases*

World J Clin Cases 2022 April 6; 10(10): 2976-3320



Contents

Thrice Monthly Volume 10 Number 10 April 6, 2022

REVIEW

- 2976 Gut microbiota in gastrointestinal diseases during pregnancy
Liu ZZ, Sun JH, Wang WJ
- 2990 Targeting metabolism: A potential strategy for hematological cancer therapy
Tang X, Chen F, Xie LC, Liu SX, Mai HR

MINIREVIEWS

- 3005 Elevated intra-abdominal pressure: A review of current knowledge
Łagosz P, Sokolski M, Biegus J, Tycinska A, Zymlinski R

ORIGINAL ARTICLE

Case Control Study

- 3014 Changes in corneal nerve morphology and function in patients with dry eyes having type 2 diabetes
Fang W, Lin ZX, Yang HQ, Zhao L, Liu DC, Pan ZQ
- 3027 Combined sevoflurane-dexmedetomidine and nerve blockade on post-surgical serum oxidative stress biomarker levels in thyroid cancer patients
Du D, Qiao Q, Guan Z, Gao YF, Wang Q

Retrospective Cohort Study

- 3035 Early warning prevention and control strategies to reduce perioperative venous thromboembolism in patients with gastrointestinal cancer
Lu Y, Chen FY, Cai L, Huang CX, Shen XF, Cai LQ, Li XT, Fu YY, Wei J
- 3047 Dose-response relationship between risk factors and incidence of COVID-19 in 325 hospitalized patients: A multicenter retrospective cohort study
Zhao SC, Yu XQ, Lai XF, Duan R, Guo DL, Zhu Q

Retrospective Study

- 3060 Preventive online and offline health management intervention in polycystic ovary syndrome
Liu R, Li M, Wang P, Yu M, Wang Z, Zhang GZ
- 3069 Evidence-based intervention on postoperative fear, compliance, and self-efficacy in elderly patients with hip fracture
Fu Y, Zhu LJ, Li DC, Yan JL, Zhang HT, Xuan YH, Meng CL, Sun YH
- 3078 Significance of dysplasia in bile duct resection margin in patients with extrahepatic cholangiocarcinoma: A retrospective analysis
Choe JW, Kim HJ, Kim JS

- 3088** Diagnostic value and safety of medical thoracoscopy for pleural effusion of different causes

Liu XT, Dong XL, Zhang Y, Fang P, Shi HY, Ming ZJ

Observational Study

- 3101** Oxaliplatin-induced neuropathy and colo-rectal cancer patient's quality of life: Practical lessons from a prospective cross-sectional, real-world study

Prutianu I, Alexa-Stratulat T, Cristea EO, Nicolau A, Moisuc DC, Covrig AA, Ivanov K, Croitoru AE, Miron MI, Dinu MI, Ivanov AV, Marinca MV, Radu I, Gafton B

- 3113** Breast-conserving surgery and sentinel lymph node biopsy for breast cancer and their correlation with the expression of polyligand proteoglycan-1

Li FM, Xu DY, Xu Q, Yuan Y

SYSTEMATIC REVIEWS

- 3121** Clinical significance of aberrant left hepatic artery during gastrectomy: A systematic review

Tao W, Peng D, Cheng YX, Zhang W

META-ANALYSIS

- 3131** Betel quid chewing and oral potential malignant disorders and the impact of smoking and drinking: A meta-analysis

Lin HJ, Wang XL, Tian MY, Li XL, Tan HZ

- 3143** Effects of physical exercise on the quality-of-life of patients with haematological malignancies and thrombocytopenia: A systematic review and meta-analysis

Yang YP, Pan SJ, Qiu SL, Tung TH

CASE REPORT

- 3156** Primary malignant peritoneal mesothelioma mimicking tuberculous peritonitis: A case report

Lin LC, Kuan WY, Shiu BH, Wang YT, Chao WR, Wang CC

- 3164** Endoscopic submucosal dissection combined with adjuvant chemotherapy for early-stage neuroendocrine carcinoma of the esophagus: A case report

Tang N, Feng Z

- 3170** Lymph-node-first presentation of Kawasaki disease in a 12-year-old girl with cervical lymphadenitis caused by *Mycoplasma pneumoniae*: A case report

Kim N, Choi YJ, Na JY, Oh JW

- 3178** Tuberculosis-associated hemophagocytic lymphohistiocytosis misdiagnosed as systemic lupus erythematosus: A case report

Chen WT, Liu ZC, Li MS, Zhou Y, Liang SJ, Yang Y

- 3188** Migration of a Hem-o-Lok clip to the renal pelvis after laparoscopic partial nephrectomy: A case report

Sun J, Zhao LW, Wang XL, Huang JG, Fan Y

- 3194** Ectopic intrauterine device in the bladder causing cystolithiasis: A case report
Yu HT, Chen Y, Xie YP, Gan TB, Gou X
- 3200** Giant tumor resection under ultrasound-guided nerve block in a patient with severe asthma: A case report
Liu Q, Zhong Q, Zhou NN, Ye L
- 3206** Myomatous erythrocytosis syndrome: A case report
Shu XY, Chen N, Chen BY, Yang HX, Bi H
- 3213** Middle thyroid vein tumor thrombus in metastatic papillary thyroid microcarcinoma: A case report and review of literature
Gui Y, Wang JY, Wei XD
- 3222** Severe pneumonia and acute myocardial infarction complicated with pericarditis after percutaneous coronary intervention: A case report
Liu WC, Li SB, Zhang CF, Cui XH
- 3232** IgA nephropathy treatment with traditional Chinese medicine: A case report
Zhang YY, Chen YL, Yi L, Gao K
- 3241** Appendico-vesicocolonic fistula: A case report and review of literature
Yan H, Wu YC, Wang X, Liu YC, Zuo S, Wang PY
- 3251** *Scedosporium apiospermum* infection of the lumbar vertebrae: A case report
Shi XW, Li ST, Lou JP, Xu B, Wang J, Wang X, Liu H, Li SK, Zhen P, Zhang T
- 3261** Woman diagnosed with obsessive-compulsive disorder became delusional after childbirth: A case report
Lin SS, Gao JF
- 3268** Emphysematous pyelonephritis: Six case reports and review of literature
Ma LP, Zhou N, Fu Y, Liu Y, Wang C, Zhao B
- 3278** Atypical infantile-onset Pompe disease with good prognosis from mainland China: A case report
Zhang Y, Zhang C, Shu JB, Zhang F
- 3284** *Mycobacterium tuberculosis* bacteremia in a human immunodeficiency virus-negative patient with liver cirrhosis: A case report
Lin ZZ, Chen D, Liu S, Yu JH, Liu SR, Zhu ML
- 3291** Cervical aortic arch with aneurysm formation and an anomalous right subclavian artery and left vertebral artery: A case report
Wu YK, Mao Q, Zhou MT, Liu N, Yu X, Peng JC, Tao YY, Gong XQ, Yang L, Zhang XM
- 3297** Dedifferentiated chondrosarcoma of the middle finger arising from a solitary enchondroma: A case report
Yonezawa H, Yamamoto N, Hayashi K, Takeuchi A, Miwa S, Igarashi K, Morinaga S, Asano Y, Saito S, Tome Y, Ikeda H, Nojima T, Tsuchiya H

- 3306** Endoscopic-catheter-directed infusion of diluted (-)-noradrenaline for atypical hemobilia caused by liver abscess: A case report
Zou H, Wen Y, Pang Y, Zhang H, Zhang L, Tang LJ, Wu H
- 3313** *Pneumocystis jiroveci* pneumonia after total hip arthroplasty in a dermatomyositis patient: A case report
Hong M, Zhang ZY, Sun XW, Wang WG, Zhang QD, Guo WS

ABOUT COVER

Editorial Board Member of *World Journal of Clinical Cases*, Hui-Jeong Hwang, MD, PhD, Associate Professor, Department of Cardiology, Kyung Hee University Hospital at Gangdong, Kyung Hee University College of Medicine, Seoul 05278, South Korea. neonic7749@hanmail.net

AIMS AND SCOPE

The primary aim of *World Journal of Clinical Cases* (WJCC, *World J Clin Cases*) is to provide scholars and readers from various fields of clinical medicine with a platform to publish high-quality clinical research articles and communicate their research findings online.

WJCC mainly publishes articles reporting research results and findings obtained in the field of clinical medicine and covering a wide range of topics, including case control studies, retrospective cohort studies, retrospective studies, clinical trials studies, observational studies, prospective studies, randomized controlled trials, randomized clinical trials, systematic reviews, meta-analysis, and case reports.

INDEXING/ABSTRACTING

The WJCC is now indexed in Science Citation Index Expanded (also known as SciSearch®), Journal Citation Reports/Science Edition, Scopus, PubMed, and PubMed Central. The 2021 Edition of Journal Citation Reports® cites the 2020 impact factor (IF) for WJCC as 1.337; IF without journal self cites: 1.301; 5-year IF: 1.742; Journal Citation Indicator: 0.33; Ranking: 119 among 169 journals in medicine, general and internal; and Quartile category: Q3. The WJCC's CiteScore for 2020 is 0.8 and Scopus CiteScore rank 2020: General Medicine is 493/793.

RESPONSIBLE EDITORS FOR THIS ISSUE

Production Editor: Xu Guo; Production Department Director: Xiang Li; Editorial Office Director: Jin-Lai Wang.

NAME OF JOURNAL

World Journal of Clinical Cases

ISSN

ISSN 2307-8960 (online)

LAUNCH DATE

April 16, 2013

FREQUENCY

Thrice Monthly

EDITORS-IN-CHIEF

Bao-Gan Peng, Jerzy Tadeusz Chudek, George Kontogeorgos, Maurizio Serati, Ja Hyeon Ku

EDITORIAL BOARD MEMBERS

<https://www.wjgnet.com/2307-8960/editorialboard.htm>

PUBLICATION DATE

April 6, 2022

COPYRIGHT

© 2022 Baishideng Publishing Group Inc

INSTRUCTIONS TO AUTHORS

<https://www.wjgnet.com/bpg/gerinfo/204>

GUIDELINES FOR ETHICS DOCUMENTS

<https://www.wjgnet.com/bpg/GerInfo/287>

GUIDELINES FOR NON-NATIVE SPEAKERS OF ENGLISH

<https://www.wjgnet.com/bpg/gerinfo/240>

PUBLICATION ETHICS

<https://www.wjgnet.com/bpg/GerInfo/288>

PUBLICATION MISCONDUCT

<https://www.wjgnet.com/bpg/gerinfo/208>

ARTICLE PROCESSING CHARGE

<https://www.wjgnet.com/bpg/gerinfo/242>

STEPS FOR SUBMITTING MANUSCRIPTS

<https://www.wjgnet.com/bpg/GerInfo/239>

ONLINE SUBMISSION

<https://www.f6publishing.com>



IgA nephropathy treatment with traditional Chinese medicine: A case report

Ying-Yu Zhang, Yan-Lin Chen, Lan Yi, Kun Gao

Specialty type: Medicine, research and experimental

Provenance and peer review: Unsolicited article; Externally peer reviewed.

Peer-review model: Single blind

Peer-review report's scientific quality classification

Grade A (Excellent): 0
Grade B (Very good): 0
Grade C (Good): C, C
Grade D (Fair): D
Grade E (Poor): 0

P-Reviewer: Cabezuelo AS, Yorioka N

Received: November 21, 2021

Peer-review started: November 21, 2021

First decision: December 27, 2021

Revised: January 9, 2022

Accepted: February 23, 2022

Article in press: February 23, 2022

Published online: April 6, 2022



Ying-Yu Zhang, Yan-Lin Chen, Lan Yi, Kun Gao, Division of Nephrology, The Affiliated Hospital of Nanjing University of Chinese Medicine, Nanjing 210029, Jiangsu Province, China

Ying-Yu Zhang, Yan-Lin Chen, Lan Yi, Kun Gao, Division of Nephrology, Jiangsu Province Hospital of Chinese Medicine, Nanjing 210029, Jiangsu Province, China

Lan Yi, Kun Gao, Inheritance Studio of Chinese Medicine Master Yan-Qin Zou, The Affiliated Hospital of Nanjing University of Chinese Medicine, Nanjing 210029, Jiangsu Province, China

Corresponding author: Kun Gao, MD, Professor, Division of Nephrology, The Affiliated Hospital of Nanjing University of Chinese Medicine, No. 155 Hanzhong Road, Qinhuai District, Nanjing 210029, Jiangsu Province, China. kungao@njucm.edu.cn

Abstract

BACKGROUND

IgA nephropathy (IgAN) is a common primary glomerular disease that leads to end-stage renal disease with poor therapy efficacy. Traditional Chinese medicine (TCM) is effective in the treatment of IgAN and has the potential to become an alternative treatment for IgAN. Professor Yan-Qin Zou is a nephropathy expert, a National Chinese Medicine Master, and an heir to the Menghe School of Medicine.

CASE SUMMARY

A 28-year-old man had positive urinary protein and elevated serum creatinine (Scr) results and was diagnosed with IgAN 2-3 years prior to the outpatient department visit at our hospital in 2017. Professor Zou used the following methods to treat the patient: Invigorating the spleen and tonifying the kidney, removing dampness and clearing turbidity, quickening the blood and transforming stasis, and freeing vessels and regulating collaterals. She adjusted the prescription in accordance with the patient's symptoms. After 6 mo of treatment, the symptoms had resolved and serological indexes were also decreased [Scr from 288.5 to 188.6 $\mu\text{mol/L}$, blood urea nitrogen (BUN) from 10.9 to 9.5 mmol/L , serum uric acid (UA) from 612 to 503 $\mu\text{mol/L}$]. During follow-up, BUN, Scr, and UA levels remained stable.

CONCLUSION

Professor Zou's therapeutic strategy to treat IgAN using TCM was efficacious and a good reference for application.

Key Words: Traditional Chinese medicine; IgA nephropathy; Primary glomerular disease; Case report

©The Author(s) 2022. Published by Baishideng Publishing Group Inc. All rights reserved.

Core Tip: IgA nephropathy (IgAN) is a common primary glomerular disease leading to end-stage renal disease with poor prognosis. Traditional Chinese medicine (TCM) is an alternative treatment for IgAN. Professor Yan-Qin Zou, one of the National Chinese Medicine Masters, has accumulated rich and unique experience in TCM diagnosis and treatment of nephropathy. This case report analyses an IgAN patient receiving TCM treatment with satisfying clinical efficacy. Professor Zou's therapeutic strategy to treat IgAN using TCM was efficacious and a good reference for clinical application.

Citation: Zhang YY, Chen YL, Yi L, Gao K. IgA nephropathy treatment with traditional Chinese medicine: A case report. *World J Clin Cases* 2022; 10(10): 3232-3240

URL: <https://www.wjgnet.com/2307-8960/full/v10/i10/3232.htm>

DOI: <https://dx.doi.org/10.12998/wjcc.v10.i10.3232>

INTRODUCTION

IgA nephropathy (IgAN) is one of the most common forms of primary nephritis and is characterized by mesangial proliferation and diffused IgA deposition in the mesangium[1]. In China, IgAN accounts for 45.26% of primary glomerulonephritis cases[2]. To date, corticosteroids, immunosuppressive agents, and symptomatic treatment have been the main therapeutic strategies, but the long-term treatment efficacy and safety need to be improved[3]. Preserving the renal function remains a major challenge for nephrologists[4]. A new target, sodium-dependent glucose transporters 2 (SGLT2), has reportedly shown efficacy in IgAN, but the high incidence of urinary tract infections has limited the use of SGLT2 inhibitors[5]. Resultingly, increasing attention has been paid to traditional Chinese medicine (TCM).

TCM has a long history in the treatment of kidney diseases in Eastern Asia[6]. Over recent decades, the efficacy and safety of TCM in treating kidney diseases have improved considerably[7,8], as documented studies have confirmed[9,10]. TCM thus has the potential to become an alternative treatment for IgAN[11,12]. However, high quality studies remain scarce. Professor Yan-Qin Zou, a National Chinese Medicine Master and the fourth-generation heir of the Bo-Xiong Fei family, is a well-known nephrology expert in TCM. Professor Zou has been engaged in clinical work for nearly 60 years and has accumulated rich and unique experience in treating nephropathy using TCM methods[13].

Therapies that successfully delay the progression of IgAN remain limited. Once the condition has progressed to renal failure, there are no effective methods to stop the decline of kidney function[14]. This case report describes a patient suffering from renal failure due to IgAN. He received TCM treatment with improvement in renal function, thus demonstrating Professor Zou's therapeutic strategy for treating IgAN. We hope this report could provide a valuable reference for the treatment of IgAN with TCM.

CASE PRESENTATION

Chief complaints

The patient's chief complaint was positive urinary protein and elevated serum creatinine (Scr) levels.

History of present illness

A 28-year-old man had positive urinary protein (++) and elevated Scr (149 $\mu\text{mol/L}$) test results in 2014. He underwent renal biopsy in February 2015 and was diagnosed with "IgAN, mesangial proliferative glomerulonephritis with sclerosis". Since then, the patient had been taking losartan (100 mg daily) and ketosteril (α -ketoacid tablets; 2.52 g/3 times daily). He first visited the outpatient department at our hospital on June 1, 2017. At this visit, malaise, waist soreness, acid reflux, and bubbles in the urine were the main clinical manifestations. The patient also complained of frequent urination at night. His tongue was light red with a yellow coating, his pulse was slippery (meaning that his pulse was beating freely and smoothly like the movement of abacus beads), and his pharynx was red.

The patient visited the outpatient department again on August 2, 2017. At this visit, waist soreness and fatigue were resolved. The patient's stomach discomfort was also alleviated. However, he still had a sore throat and spermatorrhea.

At his 3rd visit on September 28, 2017, serological indexes were stable. Clinical manifestations such as waist soreness, fatigue, pharynx discomfort, spermatorrhea, and epigastric discomfort were unchanged.

At the 4th visit on October 26, 2017, serological indexes had decreased significantly. The patient's epigastric discomfort had improved, but waist soreness remained.

At the patient's 5th visit on November 23, 2017, his clinical symptoms including waist soreness, fatigue, spermatorrhea, and epigastric discomfort were all resolved, and the serological indexes had also decreased.

History of past illness

The patient has no history of a relevant illness.

Personal and family history

The patient has no family history of a similar illness.

Physical examination

On admission, the patient's blood pressure was 120/80 mmHg, and no abnormalities were detected during the physical examination, including the cardiopulmonary system. There was no edema in either lower limb.

Laboratory examinations

The serological and urinary indexes are shown in Table 1.

Imaging examinations

Renal ultrasound showed no obvious abnormality.

Pathological analysis

Under light microscopy, a renal biopsy sample contained 25 glomeruli, among which there were 15 glomeruli with global sclerosis and no crescent. The remaining glomeruli were enlarged with approximately 90-110 cells/glomerulus. There were some mesangial areas with severe matrix hyperplasia with 2-3 cells/mesangium. The basement membrane was normal and the structure of capillary loop remained open. Complete sclerosis was seen in some glomeruli. Masson Stain was negative.

There were moderate lesions in the tubulointerstitium with indistinct tubular structure, no tubular atrophy, some swollen and degenerated tubular epithelial cells and some vacuolar degeneration. Focal fibrosis (40%) and more inflammatory cell infiltration could be seen in the interstitial area.

Immunofluorescence showed classic prominent IgA deposits.

FINAL DIAGNOSIS

Accordingly, the patient was diagnosed with IgAN (mesangial proliferative glomerulonephritis with sclerosis), Hass III[15], M0E0S0T1[16].

TREATMENT

The symptoms that were present at the patient's first visit are described in TCM as kidney and spleen deficiency, dampness, turbidity, blood stasis, and collateral disharmony. After differentiation, Professor Zou initiated TCM therapy, namely by invigorating the spleen and tonifying the kidney, removing dampness and clearing turbidity, quickening the blood and transforming stasis, and freeing vessels and regulating collaterals.

The patient's TCM prescription included the following: (1) Taizishen (*Pseudostellaria heterophylla*) 15 g; (2) Shenghuangqi (*Radix astragali*) 30 g; (3) Chaobaizhu (fried *Rhizoma atractylodis macrocephalae*) 10 g; (4) Shengyiyiren (*Semen coicis*) 30 g; (5) Fuling (*Poria*) 30 g; (6) Fushen (*Poria cocos*) 30 g; (7) Jiangcan (*Bombyx batryticatus*) 15 g; (8) Niubangzi (*Fructus arctii*) 10 g; (9) Huangshukuihua (*Abelmoschus manihot*) 30 g; (10) Shiwei (*Pyrrosia shearerii*) 20 g; (11) Chuanduan (*Dipsacus asper*) 15 g; (12) Sangjisheng (*Ramulus taxilli*) 15 g; (13) Yinchen (*Herba artemisiae scopariae*) 30 g; (14) Tufuling (*Smilax glabra*) 30 g; (15) Shengpuhuang (*Pollen typhae*) 30 g; (16) Danshen (*Radix salviae miltiorrhizae*) 20 g; (17) Chishao (*Radix paeoniae rubra*) 15 g; (18) Honghua (*Flos carthami*) 10 g; (19) Wulingzhi (*Troglodytes xanthipes*) 30 g; (20) Shudahuang (cooked *Radix et rhizoma rhei*) 12 g; (21) Cheqianzi (*Semen plantaginis*) 30 g; (22) Donglingcao (*Rabdosia rubescens*) 10 g; (23) Yumixu (*Zea mays*) 30 g; (24) Bixie (*Dioscoreae hypoglaucae*) 20 g; and (25) Walengzi (*Arca subcrenata*) 40 g. A dose of Chinese medicinal herbs is decocted twice, and the juice is mixed. The herbs were taken twice a day.

Table 1 Serological and urinary indexes

Date	BUN (mmol/L)	Scr (μmol/L)	Cys C (mg/L)	UA (μmol/L)	PRO	BLD
June 1, 2017	10.9	288.5	-	612	(-)	(-)
August 2, 2017	8.1	211	-	621	(±)	(-)
September 28, 2017	11	213.6	2.83	618	(±)	(-)
October 26, 2017	9.4	182.6	2.6	630	(±)	(-)
November 23, 2017	9.5	188.6	2.46	503	(±)	(-)
January 18, 2018	9.3	181.4	-	636	(±)	(-)
February 8, 2018	10.5	198.1	-	508	(±)	(-)
March 8, 2018	10.3	189.8	-	530	(±)	(-)
April 4, 2018	10.6	199	2.45	500	(+)	(-)

BLD: Urinary red blood cell; BUN: Blood urea nitrogen; Cys C: Serum cystatin C; PRO: Urine protein; Scr: Serum creatinine; UA: Serum uric acid; (-): 0; (±): 0.5; (+): 1.

At the patient's 2nd visit, his clinical symptoms were resolved, and the serological indexes were improved. Professor Zou strengthened the therapy of clearing damp-heat and turbidity along with relieving pharynx discomfort and detoxifying in accordance with the abovementioned treatment principles. The patient's prescription included the prescription from visit 1, but the amount of Tufuling (*Smilax glabra*) was increased to 50 g, Shudahuang (cooked *Radix et rhizoma rhei*) was increased to 20 g, and the following were added: (1) Zisuye (*Folium perilla leaf*) 30 g; (2) Tusizi (*Semen cuscuteae*) 15 g; (3) Xuanshen (*Radix scrophulariae*) 10 g; (4) Jinyinhua (*Flos lonicerae*) 10 g; and (5) Baihuasheshecao (*Oldenlandia diffusa*) 30 g.

At the patient's 3rd visit, Professor Zou strengthened the therapy of tonifying the kidney while maintaining the power of discharging turbidity and detoxifying. In addition to the initial prescription, Duzhong (*Cortex eucommiae*) 15 g; Huainiuxi (*Radix achyranthis bidentatae*) 10 g; Nvzhenzi (*Fructus ligustri lucidi*) 20 g and Gouqizi (*Fructus lycii*) 20 g were added to tonify both kidney Yin and kidney Yang. Jixuecao (*Centella asiatica*) 30 g; Baihuasheshecao (*Oldenlandia diffusa*) 30 g and Shenggancao (*Radix glycyrrhizae*) 6 g were added to purge turbidity and aid detoxification, which are effective for reducing creatinine. Jiangcan (*Bombyx batryticatus*); niubangzi (*Fructus arctii*); Donglingcao (*Rabdosia rubescens*); Bixie (*Dioscoreae hypoglaucae*) and Walengzi (*Arca subcrenata*) were removed when the abovementioned drugs were added at the third visit. Because Shudahuang (cooked *Radix et rhizoma rhei*) can also help to quicken the blood, transform stasis, and free the vessels, Chishao (*Radix paeoniae rubra*) and Honghua (*Flos carthami*) were removed because there was enough power to promote blood circulation in the previous treatment.

At the 4th visit, Professor Zou strengthened the therapy to tonify the kidney and clear the pharynx, adding Duanlonggu (*Os draconis*) 40 g; Duanmuli (*Concha ostreae*) 40 g; Gouji (*Cibotium barometz*) 20 g and Tusizi (*Semen cuscuteae*) 15 g to the last prescription.

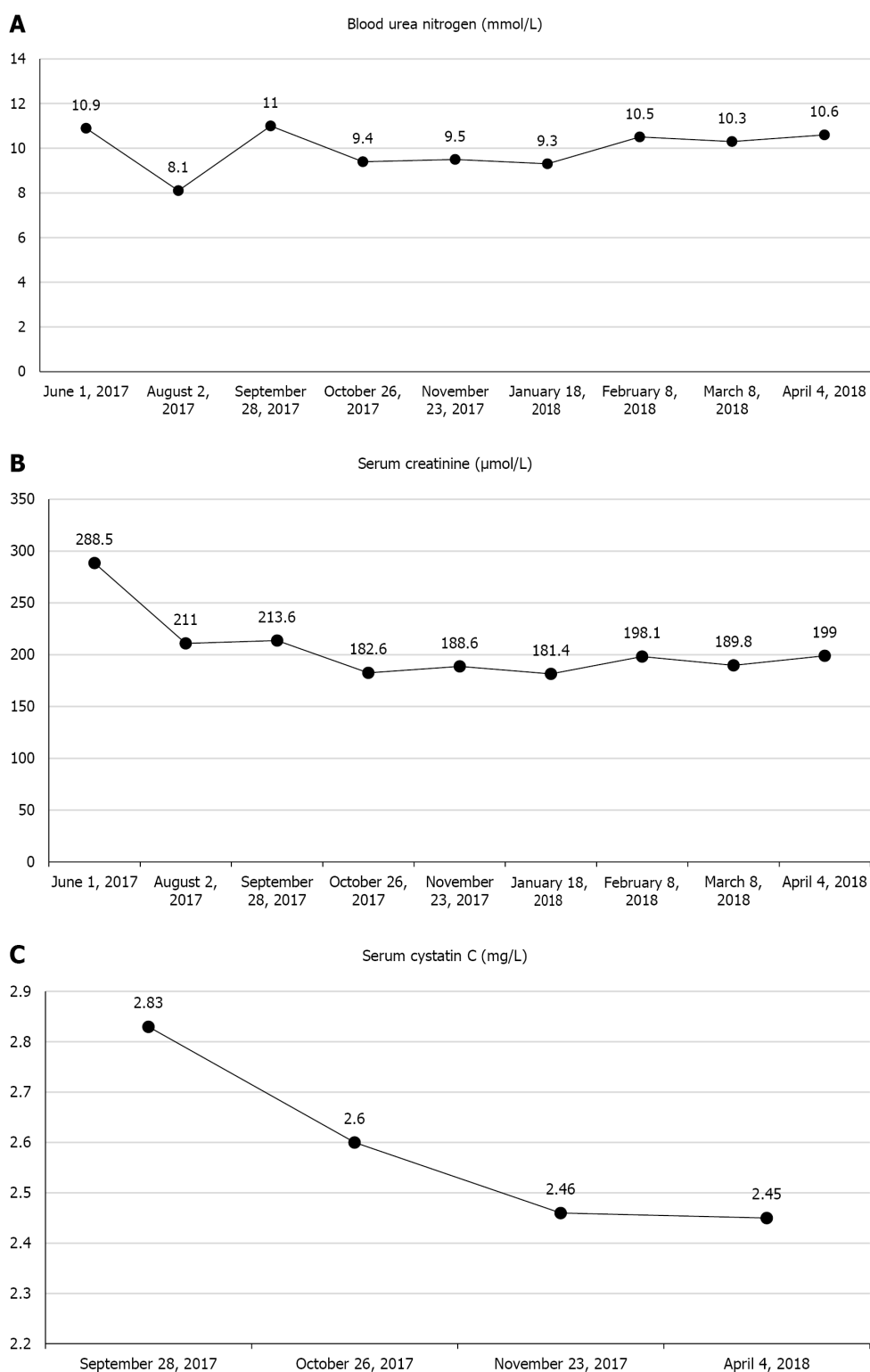
At the 5th visit, the patient's clinical symptoms were resolved, and the serological indexes were also decreased. Over the following 5 mo, Professor Zou prescribed the original treatment principles (i.e., Invigorating the spleen and tonifying the kidney, removing dampness and clearing turbidity, quickening the blood and transforming stasis, and freeing vessels and regulating collaterals).

OUTCOME AND FOLLOW-UP

The patient's symptoms and discomfort were resolved. As shown in Figure 1, during the 1-year follow-up, renal function was improved as evidenced by the stable level of BUN, Scr, serum cystatin C and UA. As shown in Figure 2, urinary red blood cell remained negative, and urinary protein maintained negative or trace findings.

DISCUSSION

A typical clinical manifestation of IgAN is hematuria with or without proteinuria, hypertension, and impaired renal function[1]. Some patients with IgAN gradually progress to chronic renal failure 10-20 years after their diagnosis[17]. The efficacy of conventional therapy is limited because of side effects.



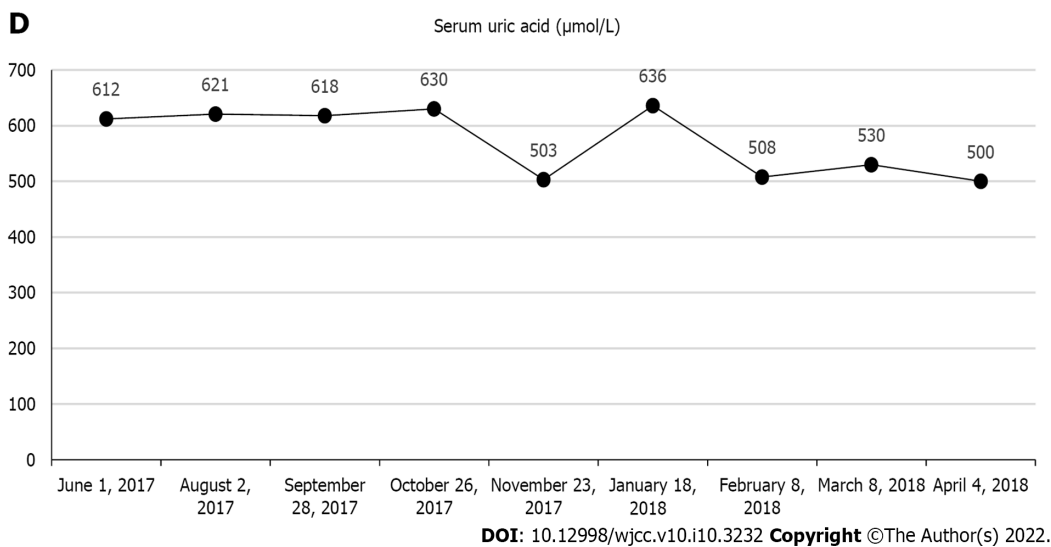


Figure 1 Patient's blood index during follow-up. A: The patient's blood urea nitrogen level remained stable; B: The patient's serum creatinine level gradually decreased and remained stable below $200 \mu\text{mol/L}$; C: The patient's serum cystatin C level constantly decreased; D: The patient's serum uric acid level decreased from $600 \mu\text{mol/L}$ to $500 \mu\text{mol/L}$. There was an increase in the uric acid level on January 18, 2018, which may have resulted from the previous cold or the patient's overeating. These were not recorded, and overall, the uric acid level trended downwards.

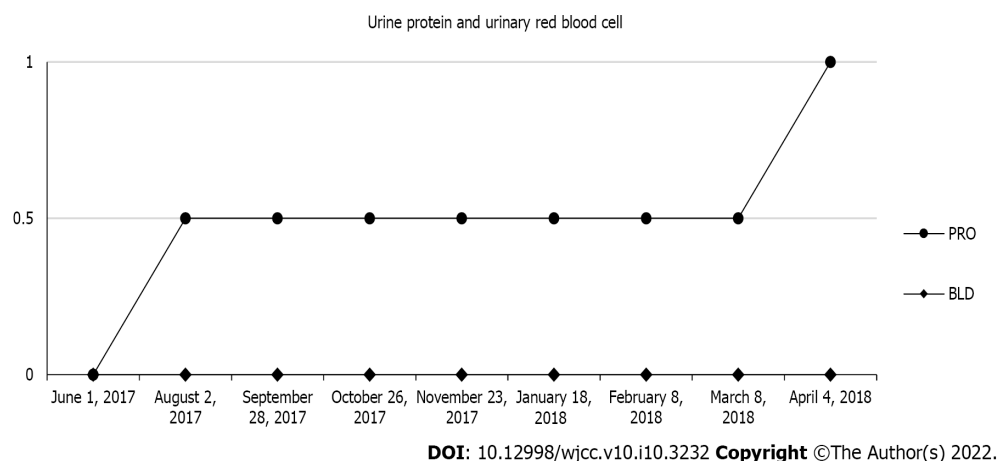


Figure 2 Change in urine protein level and urinary red blood cell level. During follow-up, the patient's urine protein level and urinary red blood cell level kept stable. There was an increase in urine protein level during the last follow-up. But because of the loss of subsequent follow-up, the patient's later urine protein level was unknown. PRO: Urine protein; BLD: Urinary red blood cell.

Treatment using TCM is worth considering because it has shown good safety and therapeutic effects.

TCM pathogenesis and IgAN therapy

IgAN is in the edema and hematuria category in TCM[18]. In ancient times, doctors had a comprehensive theory on pathogenesis, diagnosis, and therapy for kidney diseases, as recorded in the Yellow Emperor's Canon of Medicine Plain Conversation: "All dampness, swelling and turgidity is ascribed to the spleen." Professor Zou proposes that IgAN pathogenesis is a mixture of deficiency and excess. Patients with IgAN are susceptible to outer pathogen infection because of lung Qi deficiency, in accordance with TCM theory. Qi deficiency in the kidney, spleen, and lung is the internal basis that contributes to damp-heat production as a pathological factor throughout the course of IgAN. Additionally, the long-term existence of the dampness pathogen suppresses Qi and leads to Qi stagnation. Qi stagnation makes it difficult for blood to circulate smoothly. In summary, the main cause of IgAN is derived from kidney, spleen and lung deficiency, which is accompanied by dampness, damp-heat, blood stasis and wind-pathogen. Improving deficiency and eliminating excess pathogenic factors constituted Professor Zou's main clinical therapeutic strategy.

Case study

In this case, Professor Zou initially distinguished between deficiency syndrome and excess syndrome, giving consideration to both improving the deficiency and expelling pathogenic factors. The patient was treated on the basis of the disease stage and its course. In the early stage of therapy, pathogenic factors were prominent. Professor Zou strengthened the therapy of purging turbidity and detoxifying to gradually eliminate the damp-heat and blood stasis from the body. Malaise and waist soreness in the morning indicated kidney and spleen deficiency, while acid reflux, increased Scr and UA levels and bubbles in the urine demonstrated turbidity and dampness. She used treatment measures to tonify the kidney and spleen, purge turbidity and clear dampness, promote blood circulation and remove blood stasis. After the first treatment, the waist and stomach symptoms were relieved and serology indexes were improved. However, the patient's throat discomfort and an increase in spermatorrhea demonstrated persisting kidney deficiency. At the following visits, the deficiency syndrome was the main target. Professor Zou strengthened the therapy of invigorating the kidney, spleen and lung to improve Qi. Throughout the disease treatment, Professor Zou focused on tonifying the kidney and spleen and clearing away damp-heat. After almost 6 mo of treatment, the patient's symptoms were resolved, and Scr and UA levels were significantly lower. There was an increase in the UA level on January 18, 2018, which may have resulted from the previous cold or the patient's overeating. These were not recorded and overall, the UA level trended downwards. Over the subsequent follow-up, renal function remained stable.

Common compatibility and dosage

For herb selection, Professor Zou prefers mild and gentle herbs to invigorate the kidney and spleen because warm and hot drugs can easily hurt Yin, and greasy drugs can easily cause dampness stagnation. She uses drugs such as: (1) Taizishen (*Pseudostellaria heterophylla*); (2) Shenghuangqi (*Radix astragali*); (3) Chaobaizhu (fried *Rhizoma atractylodis macrocephalae*); (4) Shengyiyiren (*Semen coicis*), (5) Fuling (*Poria*); and (6) Fushen (*Poria cocos*). Furthermore, the mechanism of kidney diseases in TCM theory is the disorder of Yin and Yang in the lower abdomen (Xia-jiao), and it is difficult for the herbs to reach the disease center because Xia-jiao is located in the lower part of the body[19]. However, the course of kidney disease is often long and persistent. Professor Zou used a combination of herbs and larger drug doses to balance Yin and Yang in the lower abdomen. The following herbs are often used for purging turbidity and detoxifying: (1) Huangshukuihua (*Abelmoschus manihot*); (2) Shiwei (*Pyrrosia shearerii*); (3) Yinchen (*Herba artemisiae scopariae*); (4) Tufuling (*Smilax glabra*); (5) Shudahuang (cooked *Radix et rhizoma rei*); (6) Cheqianzi (*Semen plantaginis*); (6) Donglingcao (*Rabdosia rubescens*); (7) Yumixu (*Zea mays*); (8) Bixie (*Dioscoreae hypoglaucae*); (9) Baihuasheshecao (*Oldenlandia diffusa*); (10) Xuanshen (*Radix scrophulariae*); and (11) Jinyinhua (*Flos lonicerae*). For proteinuria, drugs such as: (1) Jiangcan (*Bombyx batryticatus*); (2) Niubangzi (*Fructus arctii*); and (3) Huangshukuihua (*Abelmoschus manihot*) are commonly used[20-22]. Modern pharmacological research suggests that the major effects of herbal medicine are related to anti-inflammatory, antioxidative, antifibrotic and immunomodulatory pathways [6,12,23].

Characteristics and comparison with similar treatment

Most TCM practitioners consider that Qi and Yin deficiencies are the leading causes of IgAN and propose that the treatment of IgAN should be based on reinforcing Qi and replenishing Yin[24]. In contrast to the general TCM treatment, Professor Zou suggests that kidney deficiency is the most fundamental internal factor in the occurrence of IgAN and the treatment of IgAN should be based on tonifying the kidney and harmonizing other viscera. In addition, the spleen also plays an important role in the pathogenesis of IgAN. In TCM theory, the spleen governs the transportation and transformation of nutrients and water and it controls the function of spleen-qi to elevate food nutrients[17]. Tonifying the spleen is conducive to controlling proteinuria and improving metabolism. Recently, some powerful drugs, such as Leigongteng (*Tripterygium wilfordii*), have been proven to be protective against kidney diseases[25]. However, although these powerful drugs may have obvious short-term effects, they may easily hurt healthy Qi. Professor Zou advocates mild drugs to gradually dissipate the pathogenic factors without side effects. Unique academic thought and exquisite herbal selection reflect the power of Professor Zou as a National Chinese Medicine Master.

Limitations

Herein, we report only one case, which has limited reference value to reflect Professor Zou's treatment experience. However, we followed the patient for nearly 1 year and did not observe any subsequent disease relapse. Finally, 24-hour urine protein quantification is also an important laboratory indicator for IgAN, but we did not have access to these results because the patient did not undergo this test in the outpatient setting.

CONCLUSION

IgAN is a prevalent type of glomerular disease in most Western and Asian countries. TCM therapy uses natural medicines that can reduce proteinuria and Scr and improve symptoms such as back pain in a long-term regimen. Professor Zou is a TCM specialist in treatment of IgAN. Her main therapeutic strategies for treating this disease focus on improving deficiency and eliminating excess pathogenic factors. This case provides a specific method and an effective reference for clinical application of TCM to treat IgAN. Our findings indicate that TCM can play an important role in the treatment of IgAN and is worth consideration as a worldwide treatment option.

ACKNOWLEDGEMENTS

We thank Li W for editing the English text of a draft of this manuscript and Sun PC for helping to revise the manuscript.

FOOTNOTES

Author contributions: Zhang YY wrote the paper; Chen YL and Yi L helped to collect the patient's information; Gao K supervised Zhang YY while writing the paper and helped to revise the manuscript.

Supported by Delaying the Progression of Renal Failure in Chronic Kidney Disease Project, No. JD2019SZ10 and Jiangsu Chinese Medicine Science and Technology Development Projects, No. YB201913.

Informed consent statement: Informed written consent was obtained from the patient's parents for publication of this report and any accompanying images.

Conflict-of-interest statement: The authors declare that they have no conflict of interest.

CARE Checklist (2016) statement: The authors have read the CARE Checklist (2016), and the manuscript was prepared and revised according to the CARE Checklist (2016).

Open-Access: This article is an open-access article that was selected by an in-house editor and fully peer-reviewed by external reviewers. It is distributed in accordance with the Creative Commons Attribution NonCommercial (CC BY-NC 4.0) license, which permits others to distribute, remix, adapt, build upon this work non-commercially, and license their derivative works on different terms, provided the original work is properly cited and the use is non-commercial. See: <https://creativecommons.org/licenses/by-nc/4.0/>

Country/Territory of origin: China

ORCID number: Ying-Yu Zhang 0000-0002-6684-3989; Yan-Lin Chen 0000-0002-7663-729X; Lan Yi 0000-0002-7600-3000; Kun Gao 0000-0003-3236-4944.

S-Editor: Guo XR

L-Editor: Filipodia

P-Editor: Guo XR

REFERENCES

- Rodrigues JC, Haas M, Reich HN. IgA Nephropathy. *Clin J Am Soc Nephrol* 2017; **12**: 677-686 [PMID: 28159829 DOI: 10.2215/CJN.07420716]
- Li LS, Liu ZH. Epidemiologic data of renal diseases from a single unit in China: analysis based on 13,519 renal biopsies. *Kidney Int* 2004; **66**: 920-923 [PMID: 15327382 DOI: 10.1111/j.1523-1755.2004.00837.x]
- Feehally J, Floege J, Tonelli M, Richard J Johnson. Comprehensive Clinical Nephrology. 6th ed. Edinburgh: Elsevier, 2019: 270
- Nagy J, Sági B, Máté J, Vas T, Kovács T. [Considerations on the treatment of IgA nephropathy on the basis of the results of the latest studies (STOP-IgAN, TESTING, NEFIGAN)]. *Orv Hetil* 2017; **158**: 1946-1952 [PMID: 29199436 DOI: 10.1556/650.2017.30924]
- Heerspink HJL, Stefánsson BV, Correa-Rotter R, Chertow GM, Greene T, Hou FF, Mann JFE, McMurray JJV, Lindberg M, Rossing P, Sjöström CD, Toto RD, Langkilde AM, Wheeler DC; DAPA-CKD Trial Committees and Investigators. Dapagliflozin in Patients with Chronic Kidney Disease. *N Engl J Med* 2020; **383**: 1436-1446 [PMID: 32970396 DOI: 10.1056/NEJMoa2024816]
- Li X, Wang H. Chinese herbal medicine in the treatment of chronic kidney disease. *Adv Chronic Kidney Dis* 2005; **12**: 276-

- 281 [PMID: [16010642](#) DOI: [10.1016/j.ackd.2005.03.007](#)]
- 7 **Zhong Y**, Menon MC, Deng Y, Chen Y, He JC. Recent Advances in Traditional Chinese Medicine for Kidney Disease. *Am J Kidney Dis* 2015; **66**: 513-522 [PMID: [26015275](#) DOI: [10.1053/j.ajkd.2015.04.013](#)]
 - 8 **Peng A**, Gu Y, Lin SY. Herbal treatment for renal diseases. *Ann Acad Med Singap* 2005; **34**: 44-51 [PMID: [15726219](#)]
 - 9 **Zhang L**, Li P, Xing CY, Zhao JY, He YN, Wang JQ, Wu XF, Liu ZS, Zhang AP, Lin HL, Ding XQ, Yin AP, Yuan FH, Fu P, Hao L, Miao LN, Xie RJ, Wang R, Zhou CH, Guan GJ, Hu Z, Lin S, Chang M, Zhang M, He LQ, Mei CL, Wang L, Chen X. Efficacy and safety of *Abelmoschus manihot* for primary glomerular disease: a prospective, multicenter randomized controlled clinical trial. *Am J Kidney Dis* 2014; **64**: 57-65 [PMID: [24631042](#) DOI: [10.1053/j.ajkd.2014.01.431](#)]
 - 10 **Li W**, He W, Xia P, Sun W, Shi M, Zhou Y, Zhu W, Zhang L, Liu B, Zhu J, Zhu Y, Zhou E, Sun M, Gao K. Total Extracts of *Abelmoschus manihot* L. Attenuates Adriamycin-Induced Renal Tubule Injury via Suppression of ROS-ERK1/2-Mediated NLRP3 Inflammasome Activation. *Front Pharmacol* 2019; **10**: 567 [PMID: [31191310](#) DOI: [10.3389/fphar.2019.00567](#)]
 - 11 **Lu WI**, Lu DP. Impact of chinese herbal medicine on american society and health care system: perspective and concern. *Evid Based Complement Alternat Med* 2014; **2014**: 251891 [PMID: [24719641](#) DOI: [10.1155/2014/251891](#)]
 - 12 **Wojcikowski K**, Johnson DW, Gobe G. Herbs or natural substances as complementary therapies for chronic kidney disease: ideas for future studies. *J Lab Clin Med* 2006; **147**: 160-166 [PMID: [16581343](#) DOI: [10.1016/j.lab.2005.11.011](#)]
 - 13 **Yi L**, Zhou EC, Gao K, Zhong Y, Li HW. Traditional Chinese Medicine Master Zou Yanqin's Experience on Treating Chronic Kidney Disease with the Academic Thought of "Harmonizing and Mild Therapeutic Method". *Nanjing Zhongyiyao Daxue Xuebao* 2020; **36**: 552-556
 - 14 **Ammirati AL**. Chronic Kidney Disease. *Rev Assoc Med Bras (1992)* 2020; **66** Suppl 1: s03-s09 [PMID: [31939529](#) DOI: [10.1590/1806-9282.66.S1.3](#)]
 - 15 **Haas M**. Histologic subclassification of IgA nephropathy: a clinicopathologic study of 244 cases. *Am J Kidney Dis* 1997; **29**: 829-842 [PMID: [9186068](#) DOI: [10.1016/s0272-6386\(97\)90456-x](#)]
 - 16 **Working Group of the International IgA Nephropathy Network and the Renal Pathology Society**, Cattaran DC, Coppo R, Cook HT, Feehally J, Roberts IS, Troyanov S, Alpers CE, Amore A, Barratt J, Berthouix F, Bonsib S, Bruijn JA, D'Agati V, D'Amico G, Emancipator S, Emma F, Ferrario F, Fervenza FC, Florquin S, Fogo A, Geddes CC, Groene HJ, Haas M, Herzenberg AM, Hill PA, Hogg RJ, Hsu SI, Jennette JC, Joh K, Julian BA, Kawamura T, Lai FM, Leung CB, Li LS, Li PK, Liu ZH, Mackinnon B, Mezzano S, Schena FP, Tomino Y, Walker PD, Wang H, Weening JJ, Yoshikawa N, Zhang H. The Oxford classification of IgA nephropathy: rationale, clinicopathological correlations, and classification. *Kidney Int* 2009; **76**: 534-545 [PMID: [19571791](#) DOI: [10.1038/ki.2009.243](#)]
 - 17 **Wang HY**. Nephrology. 3rd ed. Beijing: People's Health Publishing House, 2008: 993, 1001
 - 18 **Zuo YF**. A Newly Compiled Practical English-Chinese Library of Traditional Chinese Medicine Internal Medicine of Traditional Medicine. 1st ed. Shanghai: Publishing House of Shanghai University of Traditional Chinese Medicine, 2002: 260
 - 19 **Zuo YF**. A Newly Compiled Practical English-Chinese Library of Traditional Chinese Medicine Basic Theory of Traditional Medicine. 1st ed. Shanghai: Publishing House of Shanghai University of Traditional Chinese Medicine, 2002: 62-63, 81-82
 - 20 **Hu M**, Yu Z, Wang J, Fan W, Liu Y, Li J, Xiao H, Li Y, Peng W, Wu C. Traditional Uses, Origins, Chemistry and Pharmacology of *Bombyx batryticatus*: A Review. *Molecules* 2017; **22** [PMID: [29053625](#) DOI: [10.3390/molecules22101779](#)]
 - 21 **Gao Q**, Yang M, Zuo Z. Overview of the anti-inflammatory effects, pharmacokinetic properties and clinical efficacies of arctigenin and arctiin from *Arctium lappa* L. *Acta Pharmacol Sin* 2018; **39**: 787-801 [PMID: [29698388](#) DOI: [10.1038/aps.2018.32](#)]
 - 22 **Li N**, Tang H, Wu L, Ge H, Wang Y, Yu H, Zhang X, Ma J, Gu HF. Chemical constituents, clinical efficacy and molecular mechanisms of the ethanol extract of *Abelmoschus manihot* flowers in treatment of kidney diseases. *Phytother Res* 2021; **35**: 198-206 [PMID: [32716080](#) DOI: [10.1002/ptr.6818](#)]
 - 23 **Tapsell LC**, Hemphill I, Cobiac L, Patch CS, Sullivan DR, Fenech M, Roodenrys S, Keogh JB, Clifton PM, Williams PG, Fazio VA, Inge KE. Health benefits of herbs and spices: the past, the present, the future. *Med J Aust* 2006; **185**: S1-S24 [PMID: [17022438](#) DOI: [10.5694/j.1326-5377.2006.tb00548.x](#)]
 - 24 **Wang XH**, Lang R, Liang Y, Zeng Q, Chen N, Yu RH. Traditional Chinese Medicine in Treating IgA Nephropathy: From Basic Science to Clinical Research. *J Transl Int Med* 2021; **9**: 161-167 [PMID: [34900626](#) DOI: [10.2478/jtim-2021-0021](#)]
 - 25 **Zhong Y**, Deng Y, Chen Y, Chuang PY, Cijiang He J. Therapeutic use of traditional Chinese herbal medications for chronic kidney diseases. *Kidney Int* 2013; **84**: 1108-1118 [PMID: [23868014](#) DOI: [10.1038/ki.2013.276](#)]



Published by **Baishideng Publishing Group Inc**
7041 Koll Center Parkway, Suite 160, Pleasanton, CA 94566, USA

Telephone: +1-925-3991568

E-mail: bpgoffice@wjgnet.com

Help Desk: <https://www.f6publishing.com/helpdesk>

<https://www.wjgnet.com>

