

World Journal of *Clinical Cases*

World J Clin Cases 2022 April 6; 10(10): 2976-3320



Contents

Thrice Monthly Volume 10 Number 10 April 6, 2022

REVIEW

- 2976 Gut microbiota in gastrointestinal diseases during pregnancy
Liu ZZ, Sun JH, Wang WJ
- 2990 Targeting metabolism: A potential strategy for hematological cancer therapy
Tang X, Chen F, Xie LC, Liu SX, Mai HR

MINIREVIEWS

- 3005 Elevated intra-abdominal pressure: A review of current knowledge
Łagosz P, Sokolski M, Biegus J, Tycinska A, Zymlinski R

ORIGINAL ARTICLE

Case Control Study

- 3014 Changes in corneal nerve morphology and function in patients with dry eyes having type 2 diabetes
Fang W, Lin ZX, Yang HQ, Zhao L, Liu DC, Pan ZQ
- 3027 Combined sevoflurane-dexmedetomidine and nerve blockade on post-surgical serum oxidative stress biomarker levels in thyroid cancer patients
Du D, Qiao Q, Guan Z, Gao YF, Wang Q

Retrospective Cohort Study

- 3035 Early warning prevention and control strategies to reduce perioperative venous thromboembolism in patients with gastrointestinal cancer
Lu Y, Chen FY, Cai L, Huang CX, Shen XF, Cai LQ, Li XT, Fu YY, Wei J
- 3047 Dose-response relationship between risk factors and incidence of COVID-19 in 325 hospitalized patients: A multicenter retrospective cohort study
Zhao SC, Yu XQ, Lai XF, Duan R, Guo DL, Zhu Q

Retrospective Study

- 3060 Preventive online and offline health management intervention in polycystic ovary syndrome
Liu R, Li M, Wang P, Yu M, Wang Z, Zhang GZ
- 3069 Evidence-based intervention on postoperative fear, compliance, and self-efficacy in elderly patients with hip fracture
Fu Y, Zhu LJ, Li DC, Yan JL, Zhang HT, Xuan YH, Meng CL, Sun YH
- 3078 Significance of dysplasia in bile duct resection margin in patients with extrahepatic cholangiocarcinoma: A retrospective analysis
Choe JW, Kim HJ, Kim JS

- 3088** Diagnostic value and safety of medical thoracoscopy for pleural effusion of different causes

Liu XT, Dong XL, Zhang Y, Fang P, Shi HY, Ming ZJ

Observational Study

- 3101** Oxaliplatin-induced neuropathy and colo-rectal cancer patient's quality of life: Practical lessons from a prospective cross-sectional, real-world study

Prutianu I, Alexa-Stratulat T, Cristea EO, Nicolau A, Moisuc DC, Covrig AA, Ivanov K, Croitoru AE, Miron MI, Dinu MI, Ivanov AV, Marinca MV, Radu I, Gafton B

- 3113** Breast-conserving surgery and sentinel lymph node biopsy for breast cancer and their correlation with the expression of polyligand and proteoglycan-1

Li FM, Xu DY, Xu Q, Yuan Y

SYSTEMATIC REVIEWS

- 3121** Clinical significance of aberrant left hepatic artery during gastrectomy: A systematic review

Tao W, Peng D, Cheng YX, Zhang W

META-ANALYSIS

- 3131** Betel quid chewing and oral potential malignant disorders and the impact of smoking and drinking: A meta-analysis

Lin HJ, Wang XL, Tian MY, Li XL, Tan HZ

- 3143** Effects of physical exercise on the quality-of-life of patients with haematological malignancies and thrombocytopenia: A systematic review and meta-analysis

Yang YP, Pan SJ, Qiu SL, Tung TH

CASE REPORT

- 3156** Primary malignant peritoneal mesothelioma mimicking tuberculous peritonitis: A case report

Lin LC, Kuan WY, Shiu BH, Wang YT, Chao WR, Wang CC

- 3164** Endoscopic submucosal dissection combined with adjuvant chemotherapy for early-stage neuroendocrine carcinoma of the esophagus: A case report

Tang N, Feng Z

- 3170** Lymph-node-first presentation of Kawasaki disease in a 12-year-old girl with cervical lymphadenitis caused by *Mycoplasma pneumoniae*: A case report

Kim N, Choi YJ, Na JY, Oh JW

- 3178** Tuberculosis-associated hemophagocytic lymphohistiocytosis misdiagnosed as systemic lupus erythematosus: A case report

Chen WT, Liu ZC, Li MS, Zhou Y, Liang SJ, Yang Y

- 3188** Migration of a Hem-o-Lok clip to the renal pelvis after laparoscopic partial nephrectomy: A case report

Sun J, Zhao LW, Wang XL, Huang JG, Fan Y

- 3194** Ectopic intrauterine device in the bladder causing cystolithiasis: A case report
Yu HT, Chen Y, Xie YP, Gan TB, Gou X
- 3200** Giant tumor resection under ultrasound-guided nerve block in a patient with severe asthma: A case report
Liu Q, Zhong Q, Zhou NN, Ye L
- 3206** Myomatous erythrocytosis syndrome: A case report
Shu XY, Chen N, Chen BY, Yang HX, Bi H
- 3213** Middle thyroid vein tumor thrombus in metastatic papillary thyroid microcarcinoma: A case report and review of literature
Gui Y, Wang JY, Wei XD
- 3222** Severe pneumonia and acute myocardial infarction complicated with pericarditis after percutaneous coronary intervention: A case report
Liu WC, Li SB, Zhang CF, Cui XH
- 3232** IgA nephropathy treatment with traditional Chinese medicine: A case report
Zhang YY, Chen YL, Yi L, Gao K
- 3241** Appendico-vesicocolonic fistula: A case report and review of literature
Yan H, Wu YC, Wang X, Liu YC, Zuo S, Wang PY
- 3251** *Scedosporium apiospermum* infection of the lumbar vertebrae: A case report
Shi XW, Li ST, Lou JP, Xu B, Wang J, Wang X, Liu H, Li SK, Zhen P, Zhang T
- 3261** Woman diagnosed with obsessive-compulsive disorder became delusional after childbirth: A case report
Lin SS, Gao JF
- 3268** Emphysematous pyelonephritis: Six case reports and review of literature
Ma LP, Zhou N, Fu Y, Liu Y, Wang C, Zhao B
- 3278** Atypical infantile-onset Pompe disease with good prognosis from mainland China: A case report
Zhang Y, Zhang C, Shu JB, Zhang F
- 3284** *Mycobacterium tuberculosis* bacteremia in a human immunodeficiency virus-negative patient with liver cirrhosis: A case report
Lin ZZ, Chen D, Liu S, Yu JH, Liu SR, Zhu ML
- 3291** Cervical aortic arch with aneurysm formation and an anomalous right subclavian artery and left vertebral artery: A case report
Wu YK, Mao Q, Zhou MT, Liu N, Yu X, Peng JC, Tao YY, Gong XQ, Yang L, Zhang XM
- 3297** Dedifferentiated chondrosarcoma of the middle finger arising from a solitary enchondroma: A case report
Yonezawa H, Yamamoto N, Hayashi K, Takeuchi A, Miwa S, Igarashi K, Morinaga S, Asano Y, Saito S, Tome Y, Ikeda H, Nojima T, Tsuchiya H

- 3306** Endoscopic-catheter-directed infusion of diluted (-)-noradrenaline for atypical hemobilia caused by liver abscess: A case report
Zou H, Wen Y, Pang Y, Zhang H, Zhang L, Tang LJ, Wu H
- 3313** *Pneumocystis jiroveci* pneumonia after total hip arthroplasty in a dermatomyositis patient: A case report
Hong M, Zhang ZY, Sun XW, Wang WG, Zhang QD, Guo WS

ABOUT COVER

Editorial Board Member of *World Journal of Clinical Cases*, Hui-Jeong Hwang, MD, PhD, Associate Professor, Department of Cardiology, Kyung Hee University Hospital at Gangdong, Kyung Hee University College of Medicine, Seoul 05278, South Korea. neonic7749@hanmail.net

AIMS AND SCOPE

The primary aim of *World Journal of Clinical Cases* (*WJCC*, *World J Clin Cases*) is to provide scholars and readers from various fields of clinical medicine with a platform to publish high-quality clinical research articles and communicate their research findings online.

WJCC mainly publishes articles reporting research results and findings obtained in the field of clinical medicine and covering a wide range of topics, including case control studies, retrospective cohort studies, retrospective studies, clinical trials studies, observational studies, prospective studies, randomized controlled trials, randomized clinical trials, systematic reviews, meta-analysis, and case reports.

INDEXING/ABSTRACTING

The *WJCC* is now indexed in Science Citation Index Expanded (also known as SciSearch®), Journal Citation Reports/Science Edition, Scopus, PubMed, and PubMed Central. The 2021 Edition of Journal Citation Reports® cites the 2020 impact factor (IF) for *WJCC* as 1.337; IF without journal self cites: 1.301; 5-year IF: 1.742; Journal Citation Indicator: 0.33; Ranking: 119 among 169 journals in medicine, general and internal; and Quartile category: Q3. The *WJCC*'s CiteScore for 2020 is 0.8 and Scopus CiteScore rank 2020: General Medicine is 493/793.

RESPONSIBLE EDITORS FOR THIS ISSUE

Production Editor: *Xu Guo*; Production Department Director: *Xiang Li*; Editorial Office Director: *Jin-Lai Wang*.

NAME OF JOURNAL

World Journal of Clinical Cases

ISSN

ISSN 2307-8960 (online)

LAUNCH DATE

April 16, 2013

FREQUENCY

Thrice Monthly

EDITORS-IN-CHIEF

Bao-Gan Peng, Jerzy Tadeusz Chudek, George Kontogeorgos, Maurizio Serati, Ja Hyeon Ku

EDITORIAL BOARD MEMBERS

<https://www.wjgnet.com/2307-8960/editorialboard.htm>

PUBLICATION DATE

April 6, 2022

COPYRIGHT

© 2022 Baishideng Publishing Group Inc

INSTRUCTIONS TO AUTHORS

<https://www.wjgnet.com/bpg/gerinfo/204>

GUIDELINES FOR ETHICS DOCUMENTS

<https://www.wjgnet.com/bpg/GerInfo/287>

GUIDELINES FOR NON-NATIVE SPEAKERS OF ENGLISH

<https://www.wjgnet.com/bpg/gerinfo/240>

PUBLICATION ETHICS

<https://www.wjgnet.com/bpg/GerInfo/288>

PUBLICATION MISCONDUCT

<https://www.wjgnet.com/bpg/gerinfo/208>

ARTICLE PROCESSING CHARGE

<https://www.wjgnet.com/bpg/gerinfo/242>

STEPS FOR SUBMITTING MANUSCRIPTS

<https://www.wjgnet.com/bpg/GerInfo/239>

ONLINE SUBMISSION

<https://www.f6publishing.com>



Atypical infantile-onset Pompe disease with good prognosis from mainland China: A case report

Ying Zhang, Cheng Zhang, Jian-Bo Shu, Fang Zhang

Specialty type: Medicine, research and experimental

Provenance and peer review: Unsolicited article; Externally peer reviewed.

Peer-review model: Single blind

Peer-review report's scientific quality classification

Grade A (Excellent): A

Grade B (Very good): 0

Grade C (Good): C

Grade D (Fair): 0

Grade E (Poor): 0

P-Reviewer: Moshref L, Dai HY

Received: November 20, 2021

Peer-review started: November 20, 2021

First decision: January 11, 2022

Revised: January 29, 2022

Accepted: February 20, 2022

Article in press: February 20, 2022

Published online: April 6, 2022



Ying Zhang, Cheng Zhang, Fang Zhang, Department of Neonatal, Tianjin Children's Hospital (Tianjin University Children's Hospital), Tianjin 300134, China

Jian-Bo Shu, Tianjin Key Laboratory of Birth Defects for Prevention and Treatment, Tianjin Pediatric Research Institute, Tianjin Children's Hospital (Tianjin University Children's Hospital), Tianjin 300134, China

Corresponding author: Ying Zhang, MD, Department of Neonatal, Tianjin Children's Hospital (Tianjin University Children's Hospital), No. 238 Longyan Road, Beichen District, Tianjin 300134, China. yingzhangqh@126.com

Abstract

BACKGROUND

Pompe disease has a broad disease spectrum, including infantile-onset Pompe disease (IOPD) and late-onset Pompe disease (LOPD) forms. It is a type of glycogen storage disorder belonging to autosomal recessive genetic disease, for an estimated incidence of 1/40000 among the neonatal population. In severe cases, the natural course is characterized by death due to cardiopulmonary failure in the first year after birth. However, the clinical outcomes have improved since the emergence of enzyme replacement therapy (ERT) was widely used.

CASE SUMMARY

The reported female case in China was an atypical IOPD, which demonstrates an unusual presentation of glycogen accumulation syndrome type II without obvious skeletal muscle involvement, and reviewed physical examination, biochemical examinations, chest radiograph, and acid α -glucosidase (GAA) mutation analysis. After 4-mo specific ERT, the case received 12-mo follow-up. Moreover, the patient has obtained a very good prognosis under ERT.

CONCLUSION

For the atypical IOPD patients, early diagnosis and treatment may contribute to good prognosis.

Key Words: Pompe disease; Rare genetic disease; Enzyme replacement therapy; Infantile-onset Pompe disease; Case report

©The Author(s) 2022. Published by Baishideng Publishing Group Inc. All rights reserved.

Core Tip: Infantile-onset Pompe disease (IOPD), a form of Pompe disease, is a rare autosomal recessive genetic disease occurred in infants, who represent hypertrophic cardiomyopathy, because of unusual accumulation of glycogen or acid maltase deficiency. More than 90% patients died before 1 year old. In this manuscript, we report a female case which is an atypical IOPD with novel inherited pathogenic heterozygous variants for acid α -glucosidase gene have not been reported before, and the patient has obtained a good prognosis under the enzyme replacement therapy.

Citation: Zhang Y, Zhang C, Shu JB, Zhang F. Atypical infantile-onset Pompe disease with good prognosis from mainland China: A case report. *World J Clin Cases* 2022; 10(10): 3278-3283

URL: <https://www.wjgnet.com/2307-8960/full/v10/i10/3278.htm>

DOI: <https://dx.doi.org/10.12998/wjcc.v10.i10.3278>

INTRODUCTION

Pompe disease has a broad disease spectrum, including infantile-onset type (IOPD) and late-onset type (LOPD). Its typical symptoms are proximal muscle weakness and respiratory insufficiency in childhood or late adulthood. And the disease is also known as glycogen storage disease type II or acid maltase deficiency with a rare type of acid α -glucosidase (GAA) deficiency in the lysosome[1]. It is a type of glycogen storage disorders which belongs to autosomal recessive (AR) genetic disease in neonatal period with an estimated incidence of 1/40000, apart from African Americans, the population with a higher incidence is located in southern China[2-4]. In severe cases with an infantile onset or an early onset, the natural course is characterized by death due to cardiopulmonary failure in the first year after birth[5-7]. However, the clinical outcomes have improved significantly since the rise of the emergence of enzyme replacement therapy (ERT)[8,9].

The case in this manuscript focuses on a girl born in northern China, which is an atypical IOPD case. The case shows an unusual presentation of glycogen accumulation syndrome type II without obvious skeletal muscle involvement, and with two novel inherited pathogenic heterozygous variants for GAA gene. Moreover, the patient has obtained a very ideal prognosis under the ERT.

CASE PRESENTATION

Chief complaints

Jaundice, without muscle weakness nor hypotonia.

History of present illness

The case was first hospitalized for jaundice, without more accompanying symptoms at the age of 25 d, no muscle weakness nor hypotonia. While the classical IOPD occurs, early manifestations of muscle weaknesses are often seen, together with cardiomyopathy or cardiac hypertrophy.

Apart from the special features above, the patient is an atypical IOPD. This female patient is Han nationality, native of Shandong China, and 25 d after birth. The current weight of the patient when given the diagnosis is 4.09 kg, normal growth and development, breathing 32 times/min, regular rhythm, no cyanosis, normal crying, normal mental and breastfeeding status, stool yellow paste 2-3 times a day, urine yellow and clear. And the identification of IOPD was only after examinations.

Personal and family history

The patient's mother was with a background of G4P2, 40 + 6 wk gestation, normal delivery, birth weight 3.45 kg, the family denied the history of asphyxia rescue, denied amniotic fluid, umbilical cord and placenta abnormalities. Newborns are normal after birth, breastfed. The father is 43-year-old and the mother is 32-year-old, both in good health and not in close marriage. The mother had previously voluntarily induced two abortions. G1P1 was a 14-year-old boy, healthy, and denied history of gestational diabetes and genetic diseases.

Physical examination

The current weight of the patient when given the diagnosis is 4.09 kg, normal growth and development, breathing 32 times/min, regular rhythm, no cyanosis, normal crying, normal mental and breastfeeding status, stool yellow paste 2-3 times a day, urine yellow and clear. Yellowish skin, visual bilirubin 10-15 mg/dL, and no skin rash. Moreover, bregma 1.5 cm × 1.5 cm, flat and soft, no positive signs on cardiopulmonary abdominal examination, 1.0 cm below the right rib of the liver, sharp soft edges, free movement of limbs, normal muscle tension, primitive reflexes can be elicited, and peripheral circulation

is normal also.

Laboratory examinations

Biochemical examinations: direct bilirubin (DB): 12.2 $\mu\text{mol/L}$ (0-6.8 $\mu\text{mol/L}$), indirect bilirubin (IB): 128.2 $\mu\text{mol/L}$ (1.7-10.2 $\mu\text{mol/L}$), total bile acid (TBA): 17 $\mu\text{mol/L}$ (0.1-10.0 $\mu\text{mol/L}$), creatine kinase (CK): 833 U/L (18.0-198.0 U/L), creatine kinase myocardial band (CKMB): 19 U/L (0-18 U/L), alanine transaminase (ALT): 67 U/L (0-40 U/L), aspartate transaminase (AST): 153 U/L (0-37 U/L), lactate dehydrogenase (LDH): 673 U/L (135.0-215.0 U/L), and γ -glutamyl transpeptidase (γ -GT): 83 U/L (3.0-50.0 U/L). Electrolytes, and blood sugar level are all normal. There is no abnormality in thyroid function. No specific fatty acid abnormalities were found in the screening of hematuria metabolic disease. There was no obvious abnormality shown by electromyography. GAA mutation analysis is "c.859-2A>T" and "c.1861T>G p.Trp621Gly" (Figures 1 and 2).

Imaging examinations

B-mode ultrasound images on the liver, gallbladder, spleen and brain showed no abnormalities. The chest radiograph shows that the left heart margin is full. Echocardiography suggests left and right ventricular hypertrophy (LVPW left ventricular posterior wall 8-12 mm, RVAW right ventricular anterior wall 6-7 mm, IVS interventricular septum 12-15 mm).

FINAL DIAGNOSIS

IOPD.

TREATMENT

The child was given specific ERT (Myozyme 20 mg/kg intravenous drip every 2 wk) for 4 mo after the diagnosis.

OUTCOME AND FOLLOW-UP

Follow-up until now (12 mo after birth), the patient can stand with her normal muscle strength in the limbs, no dyspnea, and monitoring echocardiography showing reduced ventricular wall hypertrophy (LVPW left ventricular posterior wall 4.7 mm, RVAW right ventricular wall 3.5 mm, IVS ventricular septum 6 mm).

DISCUSSION

GAA (lysosomal acid α -glucosidase, NM_000152.5) is located in chromosome 17q25.3, containing 20 exons to encode a 925 amino acid precursor enzyme. By now, more than 500 recessive mutations have been reported in the autosomal GAA gene[10,11]. Some mutations (DNA variants) are associated with pathogenicity of Pompe disease. For example, the "c.1843G>A; p.Gly615Arg" homozygote, "IVS1-13T>G/c.-32-13t>g" heterozygous, and "c.-1402A>T p.I468F" heterozygous were pathogenic in unrelated classical IOPD patients[12]. Pompe disease is the first having available metabolic myopathy having targeted ERT. Genotyping is always included in enzyme replacement programs and for carries tests in relatives[13]. The case is a classic IOPD with cardiomyopathy[14]. When performed GAA mutation analysis on DNA samples from the case and her parents, we found a compound heterozygote having 2 novel mutations, "c.859-2A>T" and "c.1861T>G p.Trp621Gly". Since Pompe disease is one type of AR lysosomal storage disorder, at least one of her parents is a heterozygote. Interestingly, the "c.859-2A>T" was identified in the DNA sample from her mother, while "c.1861T>G p.Trp621Gly" was found from her father. Based on the mechanism of Pompe disease, the parents should pay attention to the negligible recurrence risk of the next generation.

The classical IOPD, early manifestations of muscle weakness are often seen, and also the cardiomyopathy or cardiac hypertrophy[15]. While in this case the patient was first hospitalized just for jaundice, without more accompanying symptoms at the age of her 25 d, no muscle weakness nor hypotonia. The Neonatal jaundice, as we all know, refers to the neonatal period, caused by abnormal bilirubin metabolism, which could be presented as a typical high blood bilirubin level, appearance of skin and/or mucous membrane and/or scleral yellow staining[16]. Also, the neonatal jaundice is divided into physiological and pathological types. For the pathological one, with a longer duration, usually occurs 24 h after birth, and lasts for more than 2 wk, or 4 wk among premature infants, the daily serum bilirubin

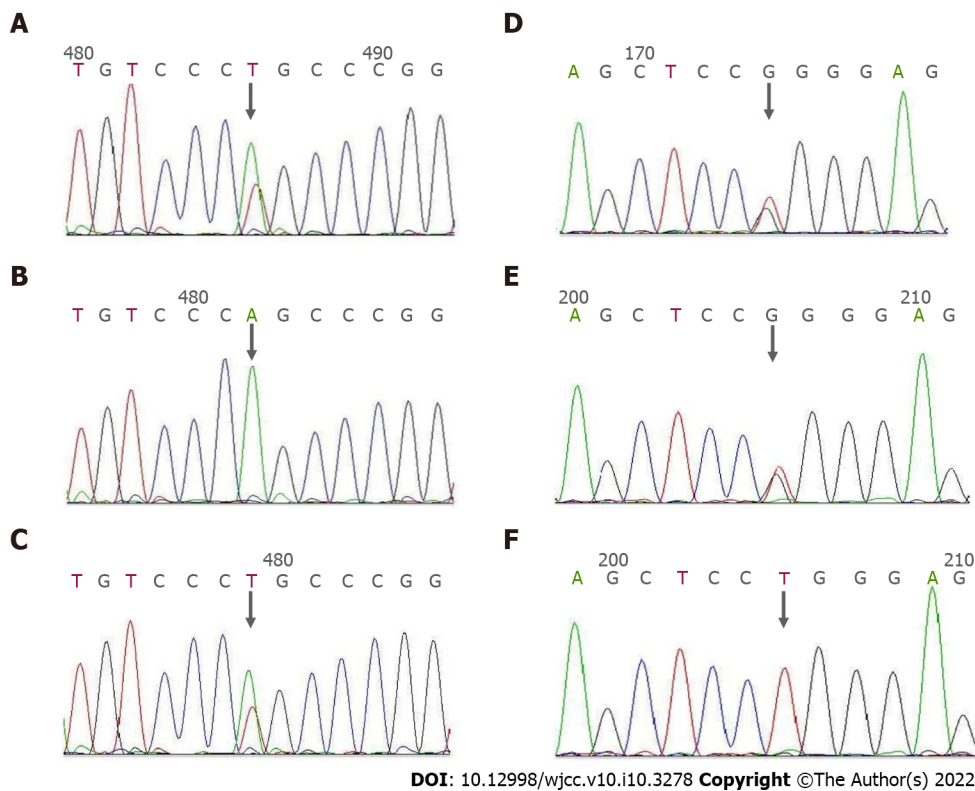


Figure 1 Acid α -glucosidase gene sequencing results. A: The fourth intron c.859-2A>T heterozygous mutation carried by the proband; B: The father of the proband c.859-2A>T locus no abnormality; C: The proband c.859-2A>T heterozygous mutation carried by the mother of the proband; D: c.1861T>G heterozygous mutation in the fifth exon carried by the proband; E: c.1861T>G heterozygous mutation carried by the father of the proband Synthetic mutation; F: There is no abnormality at c.1861T>G of the mother of the proband. The arrow indicates the mutation site.

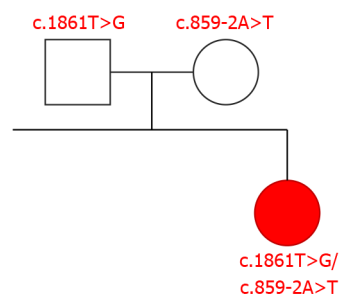


Figure 2 A molecular diagnosis and the asymptomatic parents.

risers by more than 5 mg/dL or > 0.5 mg/dL per hour. Accompanying the pathological jaundice is not much reported, whether the disorder of glycogen metabolism is potentially associated with disorders of metabolism is unknown, or in this case the accompanying is just a coincidence, needs further exploration among larger sample size of similar patients[17-19]. Apart from the above, the patient also obtained a higher level for ALT, AST and γ -GT, together with the abnormal higher level for DB, IB and TBA, which are typical symptoms in jaundice, all suggested potential abnormal for liver function. However the potential association between the jaundice and Pompe is also unknown and needs further exploration[20,21].

Poor prognosis is the top challenge in clinical and research fields concerning with Pompe disease. reslGAA in children with IOPD results in almost or complete loss of their exercise capacity, and severe symptoms usually appear within a few months after birth for the sake of cardiac insufficiency, respiratory failure and other manifestations[5]. Most of the sick children's surviving time is no longer than 1 year. However, using reorganized human GAA (rhGAA) or by the adopting of ERT can achieve an extending of lifetime. Moreover, the early diagnosis and early treatment is the key to the ideal therapeutic effect[22]. And in this case, good prognosis was found after 12-mos' follow-up, which may owe to early diagnosis and treatment.

CONCLUSION

In general, the case at 25 d after birth due to jaundice came to the outpatient clinic, with no muscle weakness, no feeding difficulties, nor dyspnea or other clinical manifestations. During routine examinations, CK was found to be abnormally high and ECG showed left and right ventricular hypertrophy. Further echocardiography confirmed left and right ventricular hypertrophy. Therefore, considering the possibility of Pompe disease, improving genetic and enzymatic testing, and confirming Pompe disease, enzymology is the key of the diagnosis. The activity of GAA in peripheral blood leukocytes of this child was 0.7 nmol/(mg protein.hr) in this case. The case represents an unusual presentation of glycogen accumulation syndrome Type II without obvious skeletal muscle involvement, and with novel inherited pathogenic heterozygous variants in the GAA gene. Moreover, the patient has obtained a very good prognosis under ERT.

FOOTNOTES

Author contributions: Zhang Y and Zhang C contributed equally to this work; Zhang Y and Zhang C designed the research study and performed the research; Zhang C and Shu JB contributed new reagents and analytic tools; Zhang Y, Zhang C and Zhang F analyzed the data and wrote the manuscript; all authors have read and approve the final manuscript.

Supported by Tianjin Municipal Health Commission, China, No. ZC20060.

Informed consent statement: We confirm that we have read the issues involved in ethical publication and declare that this manuscript is consistent with the guidelines. All procedures performed in the study involving human participants were in accordance with the ethical standards of the institutional and/or national research committees and with the Helsinki Declaration(as revised in 2013). Written informed consent was obtained from the patient for publication of this study and any accompanying images.

Conflict-of-interest statement: No conflict of interest was reported for all authors.

CARE Checklist (2016) statement: The authors have read the CARE Checklist (2016), and the manuscript was prepared and revised according to the CARE Checklist (2016).

Open-Access: This article is an open-access article that was selected by an in-house editor and fully peer-reviewed by external reviewers. It is distributed in accordance with the Creative Commons Attribution NonCommercial (CC BY-NC 4.0) license, which permits others to distribute, remix, adapt, build upon this work non-commercially, and license their derivative works on different terms, provided the original work is properly cited and the use is non-commercial. See: <https://creativecommons.org/licenses/by-nc/4.0/>

Country/Territory of origin: China

ORCID number: Ying Zhang 0000-0001-7921-1385; Cheng Zhang 0000-0001-8876-7959; Jian-Bo Shu 0000-0001-5735-9194; Fang Zhang 0000-0002-5464-9265.

S-Editor: Gao CC

L-Editor: A

P-Editor: Gao CC

REFERENCES

- 1 **Kishnani PS**, Hwu WL; Pompe Disease Newborn Screening Working Group. Introduction to the Newborn Screening, Diagnosis, and Treatment for Pompe Disease Guidance Supplement. *Pediatrics* 2017; **140**: S1-S3 [PMID: 29162672 DOI: 10.1542/peds.2016-0280B]
- 2 **Reuser AJJ**, van der Ploeg AT, Chien YH, Llerena J Jr, Abbott MA, Clemens PR, Kimonis VE, Leslie N, Maruti SS, Sanson BJ, Araujo R, Periquet M, Toscano A, Kishnani PS, On Behalf Of The Pompe Registry Sites. GAA variants and phenotypes among 1,079 patients with Pompe disease: Data from the Pompe Registry. *Hum Mutat* 2019; **40**: 2146-2164 [PMID: 31342611 DOI: 10.1002/humu.23878]
- 3 **Semplicini C**, Letard P, De Antonio M, Taouagh N, Perniconi B, Bouhour F, Echaniz-Laguna A, Orlikowski D, Sacconi S, Salort-Campana E, Solé G, Zagnoli F, Hamroun D, Froissart R, Caillaud C, Laforêt P; French Pompe Study Group. Late-onset Pompe disease in France: molecular features and epidemiology from a nationwide study. *J Inher Metab Dis* 2018; **41**: 937-946 [PMID: 30155607 DOI: 10.1007/s10545-018-0243-7]
- 4 **Kishnani PS**, Hwu WL, Mandel H, Nicolino M, Yong F, Corzo D; Infantile-Onset Pompe Disease Natural History Study Group. A retrospective, multinational, multicenter study on the natural history of infantile-onset Pompe disease. *J Pediatr* 2006; **148**: 671-676 [PMID: 16737883 DOI: 10.1016/j.jpeds.2005.11.033]

- 5 **Gupta N**, Kazi ZB, Nampoothiri S, Jagdeesh S, Kabra M, Puri RD, Muranjan M, Kalaivani M, Rehder C, Bali D, Verma IC, Kishnani PS. Clinical and Molecular Disease Spectrum and Outcomes in Patients with Infantile-Onset Pompe Disease. *J Pediatr* 2020; **216**: 44-50.e5 [PMID: [31606152](#) DOI: [10.1016/j.jpeds.2019.08.058](#)]
- 6 **Ficioglu C**, Ahrens-Nicklas RC, Barch J, Cuddapah SR, DiBoscio BS, DiPerna JC, Gordon PL, Henderson N, Menello C, Luongo N, Ortiz D, Xiao R. Newborn Screening for Pompe Disease: Pennsylvania Experience. *Int J Neonatal Screen* 2020; **6** [PMID: [33202836](#) DOI: [10.3390/ijns6040089](#)]
- 7 **van der Ploeg AT**, Reuser AJ. Pompe's disease. *Lancet* 2008; **372**: 1342-1353 [PMID: [18929906](#) DOI: [10.1016/S0140-6736\(08\)61555-X](#)]
- 8 **Bellotti AS**, Andreoli L, Ronchi D, Bresolin N, Comi GP, Corti S. Molecular Approaches for the Treatment of Pompe Disease. *Mol Neurobiol* 2020; **57**: 1259-1280 [PMID: [31713816](#) DOI: [10.1007/s12035-019-01820-5](#)]
- 9 **Colella P**, Mingozzi F. Gene Therapy for Pompe Disease: The Time is now. *Hum Gene Ther* 2019; **30**: 1245-1262 [PMID: [31298581](#) DOI: [10.1089/hum.2019.109](#)]
- 10 **Qiu WJ**, Wang X, Wang Y, Ye J, Han LS, Zhang HW, Gu XF. [Establishment and clinical application of dried blood spots and mixed leukocytes for determination of acid alpha-glucosidase activity]. *Zhonghua Er Ke Za Zhi* 2010; **48**: 55-59 [PMID: [20441705](#)]
- 11 **Tarallo A**, Carissimo A, Gatto F, Nusco E, Toscano A, Musumeci O, Coletta M, Karali M, Acampora E, Damiano C, Minopoli N, Fecarotta S, Della Casa R, Mongini T, Vercelli L, Santoro L, Ruggiero L, Deodato F, Taurisano R, Bembi B, Dardis A, Banfi S, Pijnappel WWP, van der Ploeg AT, Parenti G. microRNAs as biomarkers in Pompe disease. *Genet Med* 2019; **21**: 591-600 [PMID: [29997386](#) DOI: [10.1038/s41436-018-0103-8](#)]
- 12 **Dasouki M**, Jawdat O, Almadhoun O, Pasnoor M, McVey AL, Abuzinadah A, Herbelin L, Barohn RJ, Dimachkie MM. Pompe disease: literature review and case series. *Neurol Clin* 2014; **32**: 751-776, ix [PMID: [25037089](#) DOI: [10.1016/j.necl.2014.04.010](#)]
- 13 **Labrijn-Marks I**, Somers-Bolman GM, In 't Groen SLM, Hoogveen-Westerveld M, Kroos MA, Ala-Mello S, Amaral O, Miranda CS, Mavridou I, Michelakakis H, Naess K, Verheijen FW, Hoefsloot LH, Dijkhuizen T, Benjamins M, van den Hout HJM, van der Ploeg AT, Pijnappel WWMP, Saris JJ, Halley DJ. Segmental and total uniparental isodisomy (UPiD) as a disease mechanism in autosomal recessive lysosomal disorders: evidence from SNP arrays. *Eur J Hum Genet* 2019; **27**: 919-927 [PMID: [30737479](#) DOI: [10.1038/s41431-019-0348-y](#)]
- 14 **Case LE**, Beckemeyer AA, Kishnani PS. Infantile Pompe disease on ERT: update on clinical presentation, musculoskeletal management, and exercise considerations. *Am J Med Genet C Semin Med Genet* 2012; **160C**: 69-79 [PMID: [22252989](#) DOI: [10.1002/ajmg.c.31321](#)]
- 15 **McCall AL**, Salemi J, Bhanap P, Strickland LM, Elmallah MK. The impact of Pompe disease on smooth muscle: a review. *J Smooth Muscle Res* 2018; **54**: 100-118 [PMID: [30787211](#) DOI: [10.1540/jsmr.54.100](#)]
- 16 **Fawaz R**, Baumann U, Ekong U, Fischler B, Hadzic N, Mack CL, McLin VA, Molleston JP, Neimark E, Ng VL, Karpen SJ. Guideline for the Evaluation of Cholestatic Jaundice in Infants: Joint Recommendations of the North American Society for Pediatric Gastroenterology, Hepatology, and Nutrition and the European Society for Pediatric Gastroenterology, Hepatology, and Nutrition. *J Pediatr Gastroenterol Nutr* 2017; **64**: 154-168 [PMID: [27429428](#) DOI: [10.1097/MPG.0000000000001334](#)]
- 17 **Abbey P**, Kandasamy D, Naranje P. Neonatal Jaundice. *Indian J Pediatr* 2019; **86**: 830-841 [PMID: [30790186](#) DOI: [10.1007/s12098-019-02856-0](#)]
- 18 **Siu SL**, Chan LW, Kwong AN. Clinical and biochemical characteristics of infants with prolonged neonatal jaundice. *Hong Kong Med J* 2018; **24**: 270-276 [PMID: [29807952](#) DOI: [10.12809/hkmj176990](#)]
- 19 **Aldeiri B**, Giamouris V, Pushparajah K, Miller O, Baker A, Davenport M. Cardiac-associated biliary atresia (CABA): a prognostic subgroup. *Arch Dis Child* 2021; **106**: 68-72 [PMID: [32690577](#) DOI: [10.1136/archdischild-2020-319122](#)]
- 20 **Rathore S**, Kumar V, Kumar R S. A critical review on neonatal hyperbilirubinemia-an Ayurvedic perspective. *J Ayurveda Integr Med* 2020; **11**: 190-196 [PMID: [31628007](#) DOI: [10.1016/j.jaim.2018.08.006](#)]
- 21 **Mitra S**, Rennie J. Neonatal jaundice: aetiology, diagnosis and treatment. *Br J Hosp Med (Lond)* 2017; **78**: 699-704 [PMID: [29240507](#) DOI: [10.12968/hmed.2017.78.12.699](#)]
- 22 **Ronzitti G**, Collaud F, Laforet P, Mingozzi F. Progress and challenges of gene therapy for Pompe disease. *Ann Transl Med* 2019; **7**: 287 [PMID: [31392199](#) DOI: [10.21037/atm.2019.04.67](#)]



Published by **Baishideng Publishing Group Inc**
7041 Koll Center Parkway, Suite 160, Pleasanton, CA 94566, USA

Telephone: +1-925-3991568

E-mail: bpgoffice@wjgnet.com

Help Desk: <https://www.f6publishing.com/helpdesk>

<https://www.wjgnet.com>

