

World Journal of *Clinical Cases*

World J Clin Cases 2022 April 16; 10(11): 3321-3638



REVIEW

- 3321** Encouraging specific biomarkers-based therapeutic strategies for hepatocellular carcinoma
Yao M, Yang JL, Wang DF, Wang L, Chen Y, Yao DF

ORIGINAL ARTICLE

Clinical and Translational Research

- 3334** Autophagy-related long non-coding RNA prognostic model predicts prognosis and survival of melanoma patients
Qiu Y, Wang HT, Zheng XF, Huang X, Meng JZ, Huang JP, Wen ZP, Yao J
- 3352** Identification of circ_0000375 and circ_0011536 as novel diagnostic biomarkers of colorectal cancer
Yin TF, Du SY, Zhao DY, Sun XZ, Zhou YC, Wang QQ, Zhou GYJ, Yao SK

Retrospective Study

- 3369** Echocardiography in the diagnosis of Shone's complex and analysis of the causes for missed diagnosis and misdiagnosis
Li YD, Meng H, Pang KJ, Li MZ, Xu N, Wang H, Li SJ, Yan J
- 3379** Predictors and prognostic impact of post-operative atrial fibrillation in patients with hip fracture surgery
Bae SJ, Kwon CH, Kim TY, Chang H, Kim BS, Kim SH, Kim HJ
- 3389** Added value of systemic inflammation markers for monitoring response to neoadjuvant chemotherapy in breast cancer patients
Ke ZR, Chen W, Li MX, Wu S, Jin LT, Wang TJ
- 3401** Washed microbiota transplantation reduces serum uric acid levels in patients with hyperuricaemia
Cai JR, Chen XW, He YJ, Wu B, Zhang M, Wu LH

Clinical Trials Study

- 3414** Concurrent chemoradiotherapy using gemcitabine and nedaplatin in recurrent or locally advanced head and neck squamous cell carcinoma
Huo RX, Jin YY, Zhuo YX, Ji XT, Cui Y, Wu XJ, Wang YJ, Zhang L, Zhang WH, Cai YM, Zheng CC, Cui RX, Wang QY, Sun Z, Wang FW

META-ANALYSIS

- 3426** Effect of enhanced recovery after surgery on inflammatory bowel disease surgery: A meta-analysis
Peng D, Cheng YX, Tao W, Tang H, Ji GY
- 3436** Accuracy of ultrasound elastography for predicting breast cancer response to neoadjuvant chemotherapy: A systematic review and meta-analysis
Chen W, Fang LX, Chen HL, Zheng JH

- 3449** Association of chronic obstructive pulmonary disease with mild cognitive impairment and dementia risk: A systematic review and meta-analysis

Zhao LY, Zhou XL

CASE REPORT

- 3461** Circulating tumor DNA genomic profiling reveals the complicated olaparib-resistance mechanism in prostate cancer salvage therapy: A case report

Yuan F, Liu N, Yang MZ, Zhang XT, Luo H, Zhou H

- 3472** Difference and similarity between type A interrupted aortic arch and aortic coarctation in adults: Two case reports

Ren SX, Zhang Q, Li PP, Wang XD

- 3478** Combination therapy (toripalimab and lenvatinib)-associated toxic epidermal necrolysis in a patient with metastatic liver cancer: A case report

Huang KK, Han SS, He LY, Yang LL, Liang BY, Zhen QY, Zhu ZB, Zhang CY, Li HY, Lin Y

- 3485** Unusual glomus tumor of the lower leg: A case report

Wang HY, Duan P, Chen H, Pan ZY

- 3490** Pulmonary *Cladosporium* infection coexisting with subcutaneous *Corynespora cassiicola* infection in a patient: A case report

Wang WY, Luo HB, Hu JQ, Hong HH

- 3496** Preoperational diagnosis and management of breast ductal carcinoma *in situ* arising within fibroadenoma: Two case reports

Wu J, Sun KW, Mo QP, Yang ZR, Chen Y, Zhong MC

- 3505** Reconstruction of complex chest wall defects: A case report

Huang SC, Chen CY, Qiu P, Yan ZM, Chen WZ, Liang ZZ, Luo KW, Li JW, Zhang YQ, Huang BY

- 3511** Young children with multidrug-resistant epilepsy and vagus nerve stimulation responding to perampanel: A case report

Yang H, Yu D

- 3518** Intramedullary nailing for pathological fractures of the proximal humerus caused by multiple myeloma: A case report and review of literature

Xu GQ, Wang G, Bai XD, Wang XJ

- 3527** Double tracheal stents reduce side effects of progression of malignant tracheoesophageal fistula treated with immunotherapy: A case report

Li CA, Yu WX, Wang LY, Zou H, Ban CJ, Wang HW

- 3533** Ankylosing spondylitis complicated with andersson lesion in the lower cervical spine: A case report

Peng YJ, Zhou Z, Wang QL, Liu XF, Yan J

- 3541** Severe gastric insufflation and consequent atelectasis caused by gas leakage using AIR-Q laryngeal mask airway: A case report

Zhao Y, Li P, Li DW, Zhao GF, Li XY

- 3547** Hypereosinophilic syndrome presenting as acute ischemic stroke, myocardial infarction, and arterial involvement: A case report
Sun RR, Chen TZ, Meng M
- 3553** Cytochrome P450 family 17 subfamily A member 1 mutation causes severe pseudohermaphroditism: A case report
Gong Y, Qin F, Li WJ, Li LY, He P, Zhou XJ
- 3561** Patellar dislocation following distal femoral replacement after extra-articular knee resection for bone sarcoma: A case report
Kubota Y, Tanaka K, Hirakawa M, Iwasaki T, Kawano M, Itonaga I, Tsumura H
- 3573** Qingchang decoction retention enema may induce clinical and mucosal remission in left-sided ulcerative colitis: A case report
Li PH, Tang Y, Wen HZ
- 3579** Anti-nuclear matrix protein 2+ juvenile dermatomyositis with severe skin ulcer and infection: A case report and literature review
Wang YT, Zhang Y, Tang T, Luo C, Liu MY, Xu L, Wang L, Tang XM
- 3587** Ultrasound-guided local ethanol injection for fertility-preserving cervical pregnancy accompanied by fetal heartbeat: Two case reports
Kakinuma T, Kakinuma K, Matsuda Y, Ohwada M, Yanagida K, Kaijima H
- 3593** Successful apatinib treatment for advanced clear cell renal carcinoma as a first-line palliative treatment: A case report
Wei HP, Mao J, Hu ZL
- 3601** Del(5q) and inv(3) in myelodysplastic syndrome: A rare case report
Liang HP, Luo XC, Zhang YL, Liu B
- 3609** Papillary thyroid microcarcinoma with contralateral lymphatic skip metastasis and breast cancer: A case report
Ding M, Kong YH, Gu JH, Xie RL, Fei J
- 3615** Contrast-enhanced ultrasound manifestations of synchronous combined hepatocellular-cholangiocarcinoma and hepatocellular carcinoma: A case report
Gao L, Huang JY, Lu ZJ, Lu Q
- 3624** Thyrotoxicosis after a massive levothyroxine ingestion: A case report
Du F, Liu SW, Yang H, Duan RX, Ren WX
- 3630** Pleomorphic adenoma of the left lacrimal gland recurred and transformed into myoepithelial carcinoma after multiple operations: A case report
Huang WP, Li LM, Gao JB

ABOUT COVER

Editorial Board Member of *World Journal of Clinical Cases*, Chi-Yuan Yeh, MD, PhD, Assistant Professor, Chief Doctor, radiation oncology, Tungs' Taichung MetroHarbor Hospital, Taichung 43503, Taiwan.
peteryeh46@gmail.com

AIMS AND SCOPE

The primary aim of *World Journal of Clinical Cases* (WJCC, *World J Clin Cases*) is to provide scholars and readers from various fields of clinical medicine with a platform to publish high-quality clinical research articles and communicate their research findings online.

WJCC mainly publishes articles reporting research results and findings obtained in the field of clinical medicine and covering a wide range of topics, including case control studies, retrospective cohort studies, retrospective studies, clinical trials studies, observational studies, prospective studies, randomized controlled trials, randomized clinical trials, systematic reviews, meta-analysis, and case reports.

INDEXING/ABSTRACTING

The WJCC is now indexed in Science Citation Index Expanded (also known as SciSearch®), Journal Citation Reports/Science Edition, Scopus, PubMed, and PubMed Central. The 2021 Edition of Journal Citation Reports® cites the 2020 impact factor (IF) for WJCC as 1.337; IF without journal self cites: 1.301; 5-year IF: 1.742; Journal Citation Indicator: 0.33; Ranking: 119 among 169 journals in medicine, general and internal; and Quartile category: Q3. The WJCC's CiteScore for 2020 is 0.8 and Scopus CiteScore rank 2020: General Medicine is 493/793.

RESPONSIBLE EDITORS FOR THIS ISSUE

Production Editor: Hua-Ge Yin, Production Department Director: Xiang Li, Editorial Office Director: Jin-Lai Wang.

NAME OF JOURNAL

World Journal of Clinical Cases

ISSN

ISSN 2307-8960 (online)

LAUNCH DATE

April 16, 2013

FREQUENCY

Thrice Monthly

EDITORS-IN-CHIEF

Bao-Gan Peng, Jerzy Tadeusz Chudek, George Kontogeorgos, Maurizio Serati, Ja Hyeon Ku

EDITORIAL BOARD MEMBERS

<https://www.wjgnet.com/2307-8960/editorialboard.htm>

PUBLICATION DATE

April 16, 2022

COPYRIGHT

© 2022 Baishideng Publishing Group Inc

INSTRUCTIONS TO AUTHORS

<https://www.wjgnet.com/bpg/gerinfo/204>

GUIDELINES FOR ETHICS DOCUMENTS

<https://www.wjgnet.com/bpg/GerInfo/287>

GUIDELINES FOR NON-NATIVE SPEAKERS OF ENGLISH

<https://www.wjgnet.com/bpg/gerinfo/240>

PUBLICATION ETHICS

<https://www.wjgnet.com/bpg/GerInfo/288>

PUBLICATION MISCONDUCT

<https://www.wjgnet.com/bpg/gerinfo/208>

ARTICLE PROCESSING CHARGE

<https://www.wjgnet.com/bpg/gerinfo/242>

STEPS FOR SUBMITTING MANUSCRIPTS

<https://www.wjgnet.com/bpg/GerInfo/239>

ONLINE SUBMISSION

<https://www.f6publishing.com>



Pulmonary *Cladosporium* infection coexisting with subcutaneous *Corynespora cassiicola* infection in a patient: A case report

Wei-Yi Wang, Hong-Bin Luo, Jun-Qi Hu, Hui-Hua Hong

Specialty type: Respiratory system

Provenance and peer review:

Unsolicited article; Externally peer reviewed.

Peer-review model: Single blind

Peer-review report's scientific quality classification

Grade A (Excellent): 0

Grade B (Very good): 0

Grade C (Good): C

Grade D (Fair): 0

Grade E (Poor): 0

P-Reviewer: Kamimura K, Japan

Received: July 31, 2021

Peer-review started: July 31, 2021

First decision: October 22, 2021

Revised: October 30, 2021

Accepted: February 27, 2022

Article in press: February 27, 2022

Published online: April 16, 2022



Wei-Yi Wang, Jun-Qi Hu, Hui-Hua Hong, Department of Respiratory Medicine, The First Affiliated Hospital of Zhejiang Chinese Medical University (Zhejiang Provincial Hospital of Traditional Chinese Medicine), Hangzhou 310006, Zhejiang Province, China

Hong-Bin Luo, Department of Dermatology, The First Affiliated Hospital of Zhejiang Chinese Medical University (Zhejiang Provincial Hospital of Traditional Chinese Medicine), Hangzhou 310006, Zhejiang Province, China

Corresponding author: Hui-Hua Hong, MD, Chief Physician, Department of Respiratory Medicine, The First Affiliated Hospital of Zhejiang Chinese Medical University (Zhejiang Provincial Hospital of Traditional Chinese Medicine), No. 54 Youdian Road, Hangzhou 310006, Zhejiang Province, China. hjh999@163.com

Abstract

BACKGROUND

Cladosporium and *Corynespora cassiicola* (*C. cassiicola*) infections rarely occur in humans. Mutations in human caspase recruitment domain protein 9 (CARD9) are reported to be associated with fungal diseases. Pulmonary *Cladosporium* infection coexisting with subcutaneous *C. cassiicola* infection in a patient with a CARD9 mutation has not been reported in the literature.

CASE SUMMARY

A 68-year-old male patient was hospitalized for hypertrophic erythema and deep ulcers on the left upper extremity. He was diagnosed with pneumonia caused by *Cladosporium*, as identified through bronchoalveolar lavage fluid analysis, and deep dermatophytosis caused by *C. cassiicola*, as identified through morphological characteristics of the wound secretion culture. He underwent antifungal therapy (voriconazole) and recovered successfully. He carried two mutations in CARD9 (chr9:139266425 and chr9:139262240) and was therefore susceptible to fungal infections.

CONCLUSION

This case study is the first to report the coexistence of pulmonary *Cladosporium* infection and subcutaneous *C. cassiicola* infection in a patient with CARD9 mutation. Our findings will be helpful in enriching the phenotypic spectrum of fungal infections underlying CARD9 deficiency.

Key Words: *Cladosporium*; *Corynespora cassiicola*; Caspase recruitment domain protein

9; Lung lesion; Dermatitis; Case report

©The Author(s) 2022. Published by Baishideng Publishing Group Inc. All rights reserved.

Core Tip: The genus *Cladosporium* and *Corynespora cassiicola* (*C. cassiicola*) rarely cause human infections. Patient with caspase recruitment domain protein 9 (CARD9) mutation is reported to be more susceptible to fungal infections. Our case study is the first to report the coexistence of pulmonary *Cladosporium* infection and subcutaneous *C. cassiicola* infection in a patient with CARD9 mutation. Multiple fungal infections in patients with CARD9 mutation are worth clinicians' attention.

Citation: Wang WY, Luo HB, Hu JQ, Hong HH. Pulmonary *Cladosporium* infection coexisting with subcutaneous *Corynespora cassiicola* infection in a patient: A case report. *World J Clin Cases* 2022; 10(11): 3490-3495

URL: <https://www.wjgnet.com/2307-8960/full/v10/i11/3490.htm>

DOI: <https://dx.doi.org/10.12998/wjcc.v10.i11.3490>

INTRODUCTION

Cladosporium and *Corynespora cassiicola* (*C. cassiicola*), which are common plant pathogens existing in both indoor and outdoor environments, rarely cause illness in humans[1,2]. Pulmonary *Cladosporium* infection and subcutaneous *C. cassiicola* infection have been separately documented in the literature[3, 4]. Thus far, however, there have been no reports on the coexistence of pulmonary *Cladosporium* infection and subcutaneous *C. cassiicola* infection in humans. Mutations in human caspase recruitment domain protein 9 (CARD9) lead to an autosomal recessive primary immunodeficiency disorder, resulting in the development of a wide spectrum of fungal infections[5]. Herein, we present a case of pulmonary *Cladosporium* coexisting with subcutaneous *C. cassiicola* infection with CARD9 deficiency in a patient who was successfully treated with voriconazole.

CASE PRESENTATION

Chief complaints

A 68-year-old male farmer who was a non-smoker was admitted to the hospital for hypertrophic erythema and deep ulcers on the left upper extremity (Figure 1A) on 18 July 2019.

History of present illness

The patient had a six-month history of red, itchy rash on the left upper extremity.

History of past illness

The patient had a ten-year history of hypertension and a six-month history of sleep disorder.

Personal and family history

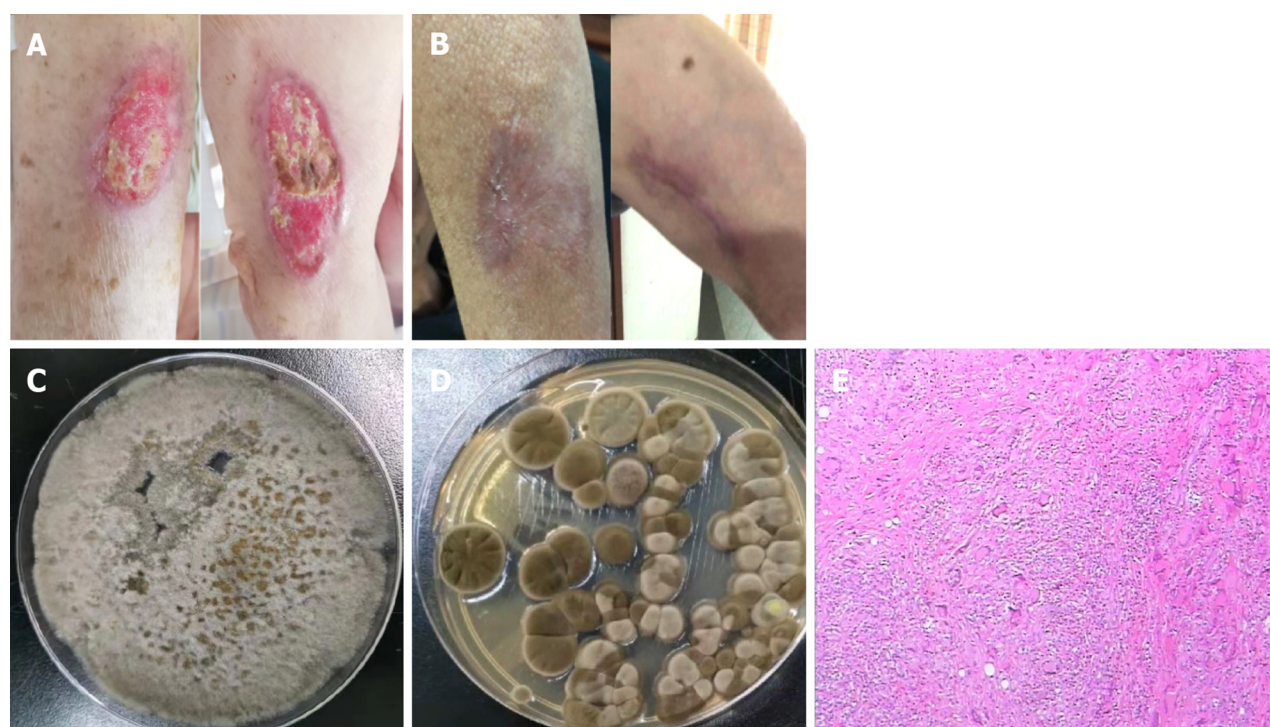
The patient had no remarkable personal or family history.

Physical examination

Initial medical examination showed a heart rate of 77 beats/min, respiratory rate of 18 breaths/min, body temperature of 36.8 °C, and blood pressure of 137/94 mmHg.

Laboratory examinations

Routine blood test results were normal (white blood cell count in serum of $5.1 \times 10^9/L$, absolute neutrophil count of $3.4 \times 10^9/L$, C-reactive protein of 1 mg/L). Serum cryptococcal antigen, antineutrophil cytoplasmic antibodies, antinuclear antibodies, human immunodeficiency virus antibody tests, HIV antibodies, and syphilis antibody tests were negative. The serum IgE level of *Aspergillus fumigatus* was low (0.1 KU/L). A skin biopsy was performed 4 d after hospital admission, which showed partial squamous hyperplasia with a dermal granulomatous lesion (Figure 1E). *C. cassiicola* was identified according to the morphological characteristics of the wound secretion culture (Figure 1C). The patient underwent bronchoscopy 6 d after admission, with a positive result for the bronchoalveolar lavage fluid (BALF) galactomannan test (with a value of 2.16), and BALF culture revealed the presence of *Cladosporium* (Figure 1D). Two mutations in CARD9 were detected by ChIP-seq using high-throughput



DOI: 10.12998/wjcc.v10.i11.3490 Copyright © The Author(s) 2022.

Figure 1 Symptoms, culture and pathology. A: Hypertrophic erythema and deep ulcers on the left upper extremity; B: The ulcer on the left upper extremity had completely healed after treatment; C: Wound secretion culture revealed *Corynespora cassiicola*; D: Bronchoalveolar lavage fluid culture analysis revealed the presence of *Cladosporium*; E: Skin biopsy showed a partial squamous hyperplasia with a dermal granulomatous lesion.

sequencing (detection region: exon region of approximately 20000 genes in the human genome; detection strategy: the explicit disease-causing genes included in OMIM database “2018.11” were analyzed) in the present case: (1) chromosomal location: chr9:139266425; nucleotide change: c.106C>T; and (2) chromosomal location: chr9:139262240; nucleotide change: c.1118G>C.

Imaging examinations

Chest computed tomography revealed the presence of multiple nodules with multiple patchy areas in both lungs (Figure 2).

FINAL DIAGNOSIS

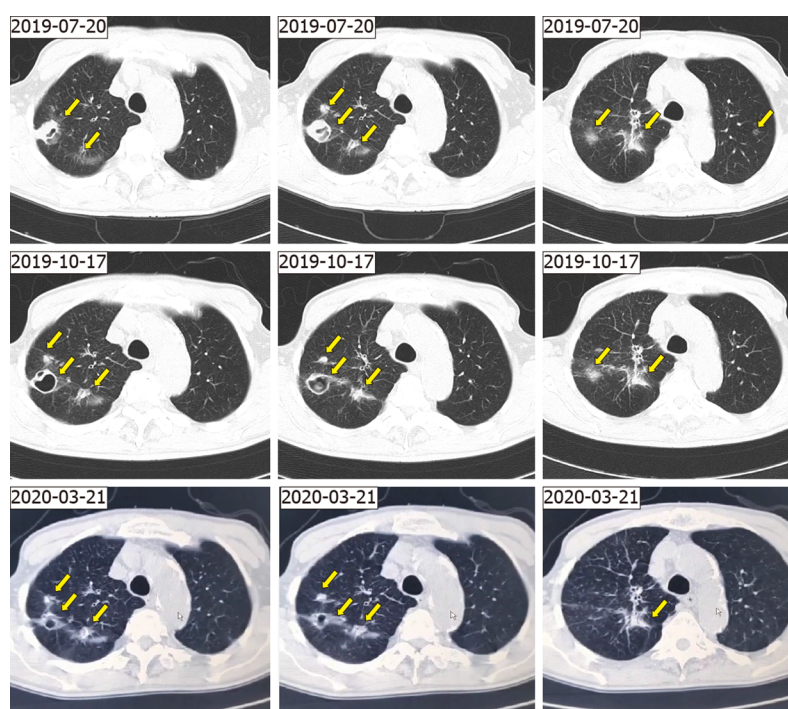
We made a final diagnosis of pneumonia caused by *Cladosporium* as well as deep dermatophytosis caused by *C. cassiicola*.

TREATMENT

Piperacillin-tazobactam 3.375 g intravenous drip was administered every 8 h for 7 d, and then antifungal therapy (voriconazole: 200 mg twice daily for 3 mo) was initiated. The ulcer on the left upper extremity healed completely after one month of treatment (Figure 1B).

OUTCOME AND FOLLOW-UP

Follow-up imaging after 3 mo revealed very good resolution of the lesions in the lung (Figure 2). The lung lesions continued to shrink for 5 mo after antifungal therapy was discontinued (Figure 2).



DOI: 10.12998/wjcc.v10.i11.3490 Copyright © The Author(s) 2022.

Figure 2 Imaging. A chest computed tomography scan showing multiple nodules with multiple patchy areas in both lungs (arrow).

DISCUSSION

Our case involved coexistence of pulmonary *Cladosporium* infection and subcutaneous *C. cassiicola* infection in a patient with CARD9 mutation.

The genus *Cladosporium* has been reported to cause several different types of opportunistic infections, including subcutaneous and deep infections, in humans and animals[1]. *Cladosporium* spores, which potentially lead to the development of respiratory allergy problems such as asthma, rarely cause pulmonary infection[6]. *Cladosporium* can affect the lungs, bronchi, and pulmonary artery branches, as revealed by our literature review[3,7-10]. *Cladosporium* spores can reach the lungs by inhalation[11]. The patient in the present case was a farmer; therefore, it is highly likely he was infected by *Cladosporium* via inhalation.

C. cassiicola, a member of *Pleosporales*, is a common plant pathogen[12]. Subcutaneous *C. cassiicola* infection in humans is extremely rare, and only six cases have been reported thus far[4,13-16]. In these cases, erythematous change, ulcer, plaque, nodule, and erosion were clinical symptoms of all cases, and the face or extremities were the infection sites. Antifungal therapy has resulted in successful treatment outcomes in most cases, though two patients with CARD9 mutations did not respond well[4,13-16].

As a member of the CARD protein family, CARD9 plays an important role in the activation of antifungal mechanisms[17]. It is a key adaptor that can mediate Dectin-1-, Dectin-2-, and Mincle-induced activation of transcription factors through formation of the CARD9-B cell lymphoma/leukaemia-10-mucosa-associated lymphoid tissue lymphoma translocation protein 1 complex in response to fungal infection[5]. These activated transcription factors mediate translation of key cytokines such as nuclear factor κ B, which promotes T-helper cell (Th)1/Th17 differentiation, stimulating antifungal mechanisms in innate cells[18]. CARD9 mutation is a rare inborn error of immunity and probably leads to impaired protection against fungal infections[19]. However, detailed and comprehensive reports on CARD9 deficiency susceptibility to fungal infection, clinical characteristics, diagnostic methods, and prognosis are still lacking. Human CARD9 deficiency is reported to be responsible for the spontaneous development of persistent and severe fungal infections (such as infections caused by *Candida albicans*, *Candida dubliniensis*, *Phialophora verrucosa*, *Trichophyton violaceum*, *Candida* sp., *Trichophyton mentagrophytes*, *Exophiala* sp., *Trichophyton rubrum*, and *Corynespora cassiicola*)[17,20]. Conversely, *Cladosporium* infection has not been reported.

The appropriate antifungal therapy for CARD9 deficiency is mostly empirical. Antifungal agents itraconazole and voriconazole have been used for the treatment of pulmonary *Cladosporium* infection, whereas amphotericin B, voriconazole, posaconazole, liposomes, and itraconazole have been used to treat subcutaneous *Corynespora cassiicola* infection[13-16]. Voriconazole had a very good therapeutic effect in our case. However, there is still no definitive conclusion on the antifungal treatment of these two diseases, including suitable medicine, reasonable dose, and course, which warrants further

research.

CONCLUSION

A good prognosis for fungal infection is associated with prompt identification and proper treatment. Given the findings of our case and the results of our literature review, multiple fungal infections in patients with CARD9 mutations are worthy of clinicians' attention. Further study into the clinical characteristics and pathogenesis of CARD9 deficiency will yield new insight into therapeutic measures for protecting humans from these devastating fungal diseases.

ACKNOWLEDGEMENTS

We acknowledge the contributions of Mr. Jun-Min Cao for the research assistance.

FOOTNOTES

Author contributions: Hong HH performed the postoperative evaluation and diagnosis; Wang WY reviewed the literature and contributed to manuscript drafting; Luo HB and Hu JQ collected the medical data; and all authors issued final approval for the submitted version.

Informed consent statement: Informed written consent was obtained from the patient for publication of this report and any accompanying images.

Conflict-of-interest statement: The authors declare that they have no conflict of interest.

CARE Checklist (2016) statement: The authors have read the CARE Checklist (2016), and the manuscript was prepared and revised according to the CARE Checklist (2016).

Open-Access: This article is an open-access article that was selected by an in-house editor and fully peer-reviewed by external reviewers. It is distributed in accordance with the Creative Commons Attribution NonCommercial (CC BY-NC 4.0) license, which permits others to distribute, remix, adapt, build upon this work non-commercially, and license their derivative works on different terms, provided the original work is properly cited and the use is non-commercial. See: <https://creativecommons.org/licenses/by-nc/4.0/>

Country/Territory of origin: China

ORCID number: Wei-Yi Wang 0000-0003-2563-6294; Hong-Bin Luo 0000-0002-7308-3439; Jun-Qi Hu 0000-0002-6100-4609; Hui-Hua Hong 0000-0001-8431-7379.

S-Editor: Zhang H

L-Editor: A

P-Editor: Zhang H

REFERENCES

- 1 Sandoval-Denis M, Gené J, Sutton DA, Wiederhold NP, Cano-Lira JF, Guarro J. New species of *Cladosporium* associated with human and animal infections. *Persoonia* 2016; **36**: 281-298 [PMID: 27616793 DOI: 10.3767/003158516X691951]
- 2 Yamada H, Takahashi N, Hori N, Asano Y, Mochizuki K, Ohkusu K, Nishimura K. Rare case of fungal keratitis caused by *Corynespora cassiicola*. *J Infect Chemother* 2013; **19**: 1167-1169 [PMID: 23494266 DOI: 10.1007/s10156-013-0579-8]
- 3 Kwon-Chung KJ, Schwartz IS, Rybak BJ. A pulmonary fungus ball produced by *Cladosporium cladosporioides*. *Am J Clin Pathol* 1975; **64**: 564-568 [PMID: 1239189 DOI: 10.1093/ajcp/64.4.564]
- 4 Xie Z, Wu W, Meng D, Zhang Q, Ma Y, Liu W, Chen J. A case of Phaeohyphomycosis caused by *Corynespora cassiicola* infection. *BMC Infect Dis* 2018; **18**: 444 [PMID: 30170557 DOI: 10.1186/s12879-018-3342-z]
- 5 De Bruyne M, Hoste L, Bogaert DJ, Van den Bossche L, Tavernier SJ, Parthoens E, Migaud M, Konopnicki D, Yombi JC, Lambrecht BN, van Daele S, Alves de Medeiros AK, Brochez L, Beyaert R, De Baere E, Puel A, Casanova JL, Goffard JC, Savvides SN, Haerynck F, Staal J, Dullaers M. A *CARD9* Founder Mutation Disrupts NF- κ B Signaling by Inhibiting BCL10 and MALT1 Recruitment and Signalingosome Formation. *Front Immunol* 2018; **9**: 2366 [PMID: 30429846 DOI: 10.3389/fimmu.2018.02366]
- 6 Rick EM, Woolnough K, Pashley CH, Wardlaw AJ. Allergic Fungal Airway Disease. *J Invest Allergol Clin Immunol* 2016; **26**: 344-354 [PMID: 27996940 DOI: 10.18176/jiaci.0122]
- 7 Castro AS, Oliveira A, Lopes V. Pulmonary phaeohyphomycosis: a challenge to the clinician. *Eur Respir Rev* 2013; **22**:

- 187-188 [PMID: [23728874](#) DOI: [10.1183/09059180.00007512](#)]
- 8 **Keyser A**, Schmid FX, Linde HJ, Merk J, Birnbaum DE. Disseminated Cladophialophora bantiana infection in a heart transplant recipient. *J Heart Lung Transplant* 2002; **21**: 503-505 [PMID: [11927230](#) DOI: [10.1016/s1053-2498\(01\)00357-6](#)]
 - 9 **Brenner SA**, Morgan J, Rickert PD, Rimland D. Cladophialophora bantiana isolated from an AIDS patient with pulmonary infiltrates. *J Med Vet Mycol* 1996; **34**: 427-429 [PMID: [8971633](#) DOI: [10.1080/02681219680000751](#)]
 - 10 **Arango-Franco CA**, Moncada-Vélez M, Beltrán CP, Berrío I, Mogollón C, Restrepo A, Trujillo M, Osorio SD, Castro L, Gómez LV, Muñoz AM, Molina V, Del Río Cobaleda DY, Ruiz AC, Garcés C, Alzate JF, Cabarcas F, Orrego JC, Casanova JL, Bustamante J, Puel A, Arias AA, Franco JL. Early-Onset Invasive Infection Due to *Corynespora cassiicola* Associated with Compound Heterozygous *CARD9* Mutations in a Colombian Patient. *J Clin Immunol* 2018; **38**: 794-803 [PMID: [30264381](#) DOI: [10.1007/s10875-018-0549-0](#)]
 - 11 **Ismail MA**. Deterioration and spoilage of peanuts and desiccated coconuts from two sub-Saharan tropical East African countries due to the associated mycobiota and their degradative enzymes. *Mycopathologia* 2001; **150**: 67-84 [PMID: [11407493](#) DOI: [10.1023/a:1010863507652](#)]
 - 12 **Chen C**, Li Q, Fu R, Wang J, Fan Z, Chen X, Lu D. Characterization of the complete mitochondrial genome of *Corynespora cassiicola* (Pleosporales: Dothideomycetes), with its phylogenetic analysis. *Mitochondrial DNA B Resour* 2019; **4**: 2938-2939 [PMID: [33365801](#) DOI: [10.1080/23802359.2019.1662753](#)]
 - 13 **Grava S**, Lopes FA, Cavallazzi RS, Grassi MF, Svidzinski TI. A rare case of hemorrhagic pneumonia due to *Cladosporium cladosporioides*. *J Bras Pneumol* 2016; **42**: 392-394 [PMID: [27812642](#) DOI: [10.1590/S1806-37562016000000079](#)]
 - 14 **Lv GX**, Ge YP, Shen YN, Li M, Zhang X, Chen H, Deng S, de Hoog GS, Liu WD. Phaeohyphomycosis caused by a plant pathogen, *Corynespora cassiicola*. *Med Mycol* 2011; **49**: 657-661 [PMID: [21281061](#) DOI: [10.3109/13693786.2011.553635](#)]
 - 15 **Wang CH**, Chen WT, Ting SW, Sun PL. Subcutaneous Fungal Infection Caused by a Non-sporulating Strain of *Corynespora cassiicola* Successfully Treated with Terbinafine. *Mycopathologia* 2019; **184**: 691-697 [PMID: [31606812](#) DOI: [10.1007/s11046-019-00393-0](#)]
 - 16 **Huang HK**, Liu CE, Liou JH, Hsiue HC, Hsiao CH, Hsueh PR. Subcutaneous infection caused by *Corynespora cassiicola*, a plant pathogen. *J Infect* 2010; **60**: 188-190 [PMID: [19925826](#) DOI: [10.1016/j.jinf.2009.11.002](#)]
 - 17 **Drummond RA**, Lionakis MS. Mechanistic Insights into the Role of C-Type Lectin Receptor/*CARD9* Signaling in Human Antifungal Immunity. *Front Cell Infect Microbiol* 2016; **6**: 39 [PMID: [27092298](#) DOI: [10.3389/fcimb.2016.00039](#)]
 - 18 **Drummond RA**, Saijo S, Iwakura Y, Brown GD. The role of Syk/*CARD9* coupled C-type lectins in antifungal immunity. *Eur J Immunol* 2011; **41**: 276-281 [PMID: [21267996](#) DOI: [10.1002/eji.201041252](#)]
 - 19 **Vaezi A**, Fakhim H, Abtahian Z, Khodavaisy S, Geramishoar M, Alizadeh A, Meis JF, Badali H. Frequency and Geographic Distribution of *CARD9* Mutations in Patients With Severe Fungal Infections. *Front Microbiol* 2018; **9**: 2434 [PMID: [30369919](#) DOI: [10.3389/fmicb.2018.02434](#)]
 - 20 **Yan XX**, Yu CP, Fu XA, Bao FF, Du DH, Wang C, Wang N, Wang SF, Shi ZX, Zhou GZ, Tian HQ, Liu H, Zhang FR. *CARD9* mutation linked to *Corynespora cassiicola* infection in a Chinese patient. *Br J Dermatol* 2016; **174**: 176-179 [PMID: [26440558](#) DOI: [10.1111/bjd.14082](#)]



Published by **Baishideng Publishing Group Inc**
7041 Koll Center Parkway, Suite 160, Pleasanton, CA 94566, USA

Telephone: +1-925-3991568

E-mail: bpgoffice@wjgnet.com

Help Desk: <https://www.f6publishing.com/helpdesk>

<https://www.wjgnet.com>

