


World Journal of *Clinical Cases*

World J Clin Cases 2022 April 16; 10(11): 3321-3638



REVIEW

- 3321** Encouraging specific biomarkers-based therapeutic strategies for hepatocellular carcinoma
Yao M, Yang JL, Wang DF, Wang L, Chen Y, Yao DF

ORIGINAL ARTICLE

Clinical and Translational Research

- 3334** Autophagy-related long non-coding RNA prognostic model predicts prognosis and survival of melanoma patients
Qiu Y, Wang HT, Zheng XF, Huang X, Meng JZ, Huang JP, Wen ZP, Yao J
- 3352** Identification of circ_0000375 and circ_0011536 as novel diagnostic biomarkers of colorectal cancer
Yin TF, Du SY, Zhao DY, Sun XZ, Zhou YC, Wang QQ, Zhou GYJ, Yao SK

Retrospective Study

- 3369** Echocardiography in the diagnosis of Shone's complex and analysis of the causes for missed diagnosis and misdiagnosis
Li YD, Meng H, Pang KJ, Li MZ, Xu N, Wang H, Li SJ, Yan J
- 3379** Predictors and prognostic impact of post-operative atrial fibrillation in patients with hip fracture surgery
Bae SJ, Kwon CH, Kim TY, Chang H, Kim BS, Kim SH, Kim HJ
- 3389** Added value of systemic inflammation markers for monitoring response to neoadjuvant chemotherapy in breast cancer patients
Ke ZR, Chen W, Li MX, Wu S, Jin LT, Wang TJ
- 3401** Washed microbiota transplantation reduces serum uric acid levels in patients with hyperuricaemia
Cai JR, Chen XW, He YJ, Wu B, Zhang M, Wu LH

Clinical Trials Study

- 3414** Concurrent chemoradiotherapy using gemcitabine and nedaplatin in recurrent or locally advanced head and neck squamous cell carcinoma
Huo RX, Jin YY, Zhuo YX, Ji XT, Cui Y, Wu XJ, Wang YJ, Zhang L, Zhang WH, Cai YM, Zheng CC, Cui RX, Wang QY, Sun Z, Wang FW

META-ANALYSIS

- 3426** Effect of enhanced recovery after surgery on inflammatory bowel disease surgery: A meta-analysis
Peng D, Cheng YX, Tao W, Tang H, Ji GY
- 3436** Accuracy of ultrasound elastography for predicting breast cancer response to neoadjuvant chemotherapy: A systematic review and meta-analysis
Chen W, Fang LX, Chen HL, Zheng JH

- 3449** Association of chronic obstructive pulmonary disease with mild cognitive impairment and dementia risk: A systematic review and meta-analysis

Zhao LY, Zhou XL

CASE REPORT

- 3461** Circulating tumor DNA genomic profiling reveals the complicated olaparib-resistance mechanism in prostate cancer salvage therapy: A case report

Yuan F, Liu N, Yang MZ, Zhang XT, Luo H, Zhou H

- 3472** Difference and similarity between type A interrupted aortic arch and aortic coarctation in adults: Two case reports

Ren SX, Zhang Q, Li PP, Wang XD

- 3478** Combination therapy (toripalimab and lenvatinib)-associated toxic epidermal necrolysis in a patient with metastatic liver cancer: A case report

Huang KK, Han SS, He LY, Yang LL, Liang BY, Zhen QY, Zhu ZB, Zhang CY, Li HY, Lin Y

- 3485** Unusual glomus tumor of the lower leg: A case report

Wang HY, Duan P, Chen H, Pan ZY

- 3490** Pulmonary *Cladosporium* infection coexisting with subcutaneous *Corynespora cassiicola* infection in a patient: A case report

Wang WY, Luo HB, Hu JQ, Hong HH

- 3496** Preoperational diagnosis and management of breast ductal carcinoma *in situ* arising within fibroadenoma: Two case reports

Wu J, Sun KW, Mo QP, Yang ZR, Chen Y, Zhong MC

- 3505** Reconstruction of complex chest wall defects: A case report

Huang SC, Chen CY, Qiu P, Yan ZM, Chen WZ, Liang ZZ, Luo KW, Li JW, Zhang YQ, Huang BY

- 3511** Young children with multidrug-resistant epilepsy and vagus nerve stimulation responding to perampanel: A case report

Yang H, Yu D

- 3518** Intramedullary nailing for pathological fractures of the proximal humerus caused by multiple myeloma: A case report and review of literature

Xu GQ, Wang G, Bai XD, Wang XJ

- 3527** Double tracheal stents reduce side effects of progression of malignant tracheoesophageal fistula treated with immunotherapy: A case report

Li CA, Yu WX, Wang LY, Zou H, Ban CJ, Wang HW

- 3533** Ankylosing spondylitis complicated with andersson lesion in the lower cervical spine: A case report

Peng YJ, Zhou Z, Wang QL, Liu XF, Yan J

- 3541** Severe gastric insufflation and consequent atelectasis caused by gas leakage using AIR-Q laryngeal mask airway: A case report

Zhao Y, Li P, Li DW, Zhao GF, Li XY

- 3547** Hypereosinophilic syndrome presenting as acute ischemic stroke, myocardial infarction, and arterial involvement: A case report
Sun RR, Chen TZ, Meng M
- 3553** Cytochrome P450 family 17 subfamily A member 1 mutation causes severe pseudohermaphroditism: A case report
Gong Y, Qin F, Li WJ, Li LY, He P, Zhou XJ
- 3561** Patellar dislocation following distal femoral replacement after extra-articular knee resection for bone sarcoma: A case report
Kubota Y, Tanaka K, Hirakawa M, Iwasaki T, Kawano M, Itonaga I, Tsumura H
- 3573** Qingchang decoction retention enema may induce clinical and mucosal remission in left-sided ulcerative colitis: A case report
Li PH, Tang Y, Wen HZ
- 3579** Anti-nuclear matrix protein 2+ juvenile dermatomyositis with severe skin ulcer and infection: A case report and literature review
Wang YT, Zhang Y, Tang T, Luo C, Liu MY, Xu L, Wang L, Tang XM
- 3587** Ultrasound-guided local ethanol injection for fertility-preserving cervical pregnancy accompanied by fetal heartbeat: Two case reports
Kakinuma T, Kakinuma K, Matsuda Y, Ohwada M, Yanagida K, Kaijima H
- 3593** Successful apatinib treatment for advanced clear cell renal carcinoma as a first-line palliative treatment: A case report
Wei HP, Mao J, Hu ZL
- 3601** Del(5q) and inv(3) in myelodysplastic syndrome: A rare case report
Liang HP, Luo XC, Zhang YL, Liu B
- 3609** Papillary thyroid microcarcinoma with contralateral lymphatic skip metastasis and breast cancer: A case report
Ding M, Kong YH, Gu JH, Xie RL, Fei J
- 3615** Contrast-enhanced ultrasound manifestations of synchronous combined hepatocellular-cholangiocarcinoma and hepatocellular carcinoma: A case report
Gao L, Huang JY, Lu ZJ, Lu Q
- 3624** Thyrotoxicosis after a massive levothyroxine ingestion: A case report
Du F, Liu SW, Yang H, Duan RX, Ren WX
- 3630** Pleomorphic adenoma of the left lacrimal gland recurred and transformed into myoepithelial carcinoma after multiple operations: A case report
Huang WP, Li LM, Gao JB

ABOUT COVER

Editorial Board Member of *World Journal of Clinical Cases*, Chi-Yuan Yeh, MD, PhD, Assistant Professor, Chief Doctor, radiation oncology, Tungs' Taichung MetroHarbor Hospital, Taichung 43503, Taiwan.
peteryeh46@gmail.com

AIMS AND SCOPE

The primary aim of *World Journal of Clinical Cases* (WJCC, *World J Clin Cases*) is to provide scholars and readers from various fields of clinical medicine with a platform to publish high-quality clinical research articles and communicate their research findings online.

WJCC mainly publishes articles reporting research results and findings obtained in the field of clinical medicine and covering a wide range of topics, including case control studies, retrospective cohort studies, retrospective studies, clinical trials studies, observational studies, prospective studies, randomized controlled trials, randomized clinical trials, systematic reviews, meta-analysis, and case reports.

INDEXING/ABSTRACTING

The WJCC is now indexed in Science Citation Index Expanded (also known as SciSearch®), Journal Citation Reports/Science Edition, Scopus, PubMed, and PubMed Central. The 2021 Edition of Journal Citation Reports® cites the 2020 impact factor (IF) for WJCC as 1.337; IF without journal self cites: 1.301; 5-year IF: 1.742; Journal Citation Indicator: 0.33; Ranking: 119 among 169 journals in medicine, general and internal; and Quartile category: Q3. The WJCC's CiteScore for 2020 is 0.8 and Scopus CiteScore rank 2020: General Medicine is 493/793.

RESPONSIBLE EDITORS FOR THIS ISSUE

Production Editor: Hua-Ge Yin; Production Department Director: Xiang Li; Editorial Office Director: Jin-Lai Wang.

NAME OF JOURNAL

World Journal of Clinical Cases

ISSN

ISSN 2307-8960 (online)

LAUNCH DATE

April 16, 2013

FREQUENCY

Thrice Monthly

EDITORS-IN-CHIEF

Bao-Gan Peng, Jerzy Tadeusz Chudek, George Kontogeorgos, Maurizio Serati, Ja Hyeon Ku

EDITORIAL BOARD MEMBERS

<https://www.wjgnet.com/2307-8960/editorialboard.htm>

PUBLICATION DATE

April 16, 2022

COPYRIGHT

© 2022 Baishideng Publishing Group Inc

INSTRUCTIONS TO AUTHORS

<https://www.wjgnet.com/bpg/gerinfo/204>

GUIDELINES FOR ETHICS DOCUMENTS

<https://www.wjgnet.com/bpg/GerInfo/287>

GUIDELINES FOR NON-NATIVE SPEAKERS OF ENGLISH

<https://www.wjgnet.com/bpg/gerinfo/240>

PUBLICATION ETHICS

<https://www.wjgnet.com/bpg/GerInfo/288>

PUBLICATION MISCONDUCT

<https://www.wjgnet.com/bpg/gerinfo/208>

ARTICLE PROCESSING CHARGE

<https://www.wjgnet.com/bpg/gerinfo/242>

STEPS FOR SUBMITTING MANUSCRIPTS

<https://www.wjgnet.com/bpg/GerInfo/239>

ONLINE SUBMISSION

<https://www.f6publishing.com>



Reconstruction of complex chest wall defects: A case report

Sheng-Chao Huang, Chun-Yan Chen, Pu Qiu, Ze-Ming Yan, Wei-Zhang Chen, Zhong-Zheng Liang, Kang-Wei Luo, Jian-Wen Li, Yuan-Qi Zhang, Bao-Yi Huang

Specialty type: Medicine, research and experimental

Provenance and peer review:

Unsolicited article; Externally peer reviewed.

Peer-review model: Single blind

Peer-review report's scientific quality classification

Grade A (Excellent): A

Grade B (Very good): 0

Grade C (Good): C

Grade D (Fair): 0

Grade E (Poor): 0

P-Reviewer: Feizi A, Iran; Kapritsou M, Greece

Received: December 15, 2021

Peer-review started: December 15, 2021

First decision: January 26, 2022

Revised: February 3, 2022

Accepted: February 27, 2022

Article in press: February 27, 2022

Published online: April 16, 2022



Sheng-Chao Huang, Chun-Yan Chen, Pu Qiu, Ze-Ming Yan, Wei-Zhang Chen, Zhong-Zheng Liang, Kang-Wei Luo, Jian-Wen Li, Yuan-Qi Zhang, Bao-Yi Huang, Department of Vascular, Thyroid, and Breast Surgery, Affiliated Hospital of Guangdong Medical University, Zhanjiang 524000, Guangdong Province, China

Corresponding author: Yuan-Qi Zhang, PhD, Dean, Department of Vascular, Thyroid, and Breast Surgery, Affiliated Hospital of Guangdong Medical University, No. 57 Renmin Avenue South, Xiashan District, Zhanjiang 524000, Guangdong Province, China. 31428319@qq.com

Abstract

BACKGROUND

Chronic radiative chest wall ulcers are common in patients undergoing radiation therapy. If not treated early, then symptoms such as erosion, bleeding and infection will appear on the skin. In severe cases, ulcers invade the ribs and pleura, presenting a mortality risk. Small ulcers can be repaired with pedicle flaps. Because radioactive ulcers often invade the thorax, surgeons need to remove large areas of skin and muscle, and sometimes ribs. Repairing large chest wall defects are a challenge for surgeons.

CASE SUMMARY

A 74-year-old female patient was admitted to our department with chest wall skin ulceration after radiation therapy for left breast cancer. The patient was diagnosed with chronic radioactive ulceration. After multidisciplinary discussion, the authors performed expansive resection of the chest wall ulcers and repaired large chest wall defects using a deep inferior epigastric perforator (DIEP) flap combined with a high-density polyethylene (HDPE) patch. The patient was followed-up 6 mo after the operation. No pigmentation or edema was found in the flap.

CONCLUSION

DIEP flap plus HDPE patch is one of the better treatments for radiation-induced chest wall ulcers.

Key Words: Deep inferior epigastric perforator flap; High-density polyethylene patch; Breast cancer; Chest wall; Chronic radiation-induced ulcer; Case report

©The Author(s) 2022. Published by Baishideng Publishing Group Inc. All rights reserved.

Core Tip: In recent years, with the development of microsurgical techniques and breast reconstruction techniques and the wide application of autologous flap transplantation, breast surgeons have provided new ideas for the treatment of chronic radiation-induced ulcers of the chest wall. Deep inferior epigastric perforator flap combined with a high-density polyethylene patch is a promising treatment for chronic radiation-induced ulcers of the chest wall.

Citation: Huang SC, Chen CY, Qiu P, Yan ZM, Chen WZ, Liang ZZ, Luo KW, Li JW, Zhang YQ, Huang BY. Reconstruction of complex chest wall defects: A case report. *World J Clin Cases* 2022; 10(11): 3505-3510

URL: <https://www.wjgnet.com/2307-8960/full/v10/i11/3505.htm>

DOI: <https://dx.doi.org/10.12998/wjcc.v10.i11.3505>

INTRODUCTION

The incidence of chest wall ulcers due to chronic radiation is about 25%-30%. The radiation dose, radiation time and patient's condition are the risk factors known to affect its occurrence. It has been reported that radiation doses exceeding 70 Gy/7 wk/30 fractions are prone to cause such ulcers[1]. Radiation-induced ulcers of the chest wall are secondary, progressive and irreversible, with a duration of as short as several months and as long as years or decades. Moreover, they can be classified as a special type of protracted wound. In addition, radiation can cause vascular contracture, reduce the amount of blood supplied to the skin, induce fibrosis of the skin, and directly impair the repair function of the skin tissue[2-5].

Chronic radiation-induced ulcers of the chest wall are often associated with infection and easily cause rib necrosis and osteomyelitis. This seriously affects the quality of life of patients and is a detriment to a patient's confidence in treating cancer. In the past, surgeons have tried to treat it with debridement and dressing change or skin grafting, but it is difficult to achieve the ideal therapeutic effect. At present, chest wall reconstruction includes two parts: Bone reconstruction of the chest wall, and soft tissue reconstruction of the chest wall. The former uses biological or artificial materials to restore stability of the chest wall, while the latter realizes the tightness of the chest wall by transferring its own tissue flap to cover the defect. In the repair of the chest wall, titanium alloy plates and high-density polyethylene (HDPE) patches are two commonly used materials. Some scholars have pointed out that HDPE patches have sufficient toughness and can better maintain the stability of the chest wall without interference with radiotherapy[6]. In terms of soft tissue repair, a banded myocutaneous flap is better to repair chest wall defects; however, the excessive muscle harvested during the surgery causes the patient sustains greater trauma, resulting in prolonged recovery time and affecting the subsequent treatment of patients. Due to the development of microsurgical techniques, the application of free flaps to repair chest wall defects has become a clinical hot spot.

In this report, the breast cancer patient suffered from a chronic radiation-induced ulcer of the chest wall combined with necrosis of the second to fifth ribs. The chest wall defect was repaired by deep inferior epigastric perforator (DIEP) flap combined with a HDPE patch, with good postoperative recovery.

CASE PRESENTATION

Chief complaints

A 74-year-old female patient was admitted for a radioactive ulcer on the chest wall for more than 4 mo.

History of present illness

The patient's chest wall ulcer occurred 1 wk after the 6th radiotherapy treatment and lasted about 4 mo. The area of the ulcer was 4 cm × 6 cm. The surface of the ulcer was dirty, and the basal granulation tissue was sparse. The ulcer surface bled easily, which indicated that it was closely attached to deep tissue. The ulcer was hard and surrounded by scar tissue.

History of past illness

The patient underwent modified radical mastectomy of the left breast in our department 5 mo prior. The patient did not have hypertension, diabetes or hyperlipidemia.

Personal and family history

Personal and family history was unremarkable.

Physical examination

An irregularly shaped ulcer was observed on the surface of the skin of the left chest wall and measuring 4 cm × 6 cm. It was accompanied by red coloration, fishy odor, and pus-like discharge. The skin around the ulcer was red and swollen, hard in consistency and tender (Figure 1A). No significantly enlarged lymph nodes were palpable in the left axilla or supraclavicular region.

Laboratory examinations

All laboratory tests were normal.

Imaging examinations

Chest computed tomography: Irregular subcutaneous soft tissue of the left anterior chest wall and multiple small nodular high-density shadows in the local area were observed. These were predicted to change after radiotherapy. Slightly disordered structure of the left axilla was also observed but no enlarged lymph nodes were found.

MULTIDISCIPLINARY EXPERT CONSULTATION

The consultation included specialists in breast surgery, thoracic surgery and radiology. After discussion by several specialists, the decision was made to perform an expanded excision of the ulcer on the chest wall of the patient, including the invaded muscle and ribs. Then, the thoracic defect would be repaired with a patch, and the chest wall defect would be covered with a free flap (Figure 1B).

FINAL DIAGNOSIS

Radiation-induced ulcer of the left chest wall (Figure 1C).

TREATMENT

DIEP flap combined with an HDPE patch was used to repair the chest wall ulcer (Figure 1D and E).

OUTCOME AND FOLLOW-UP

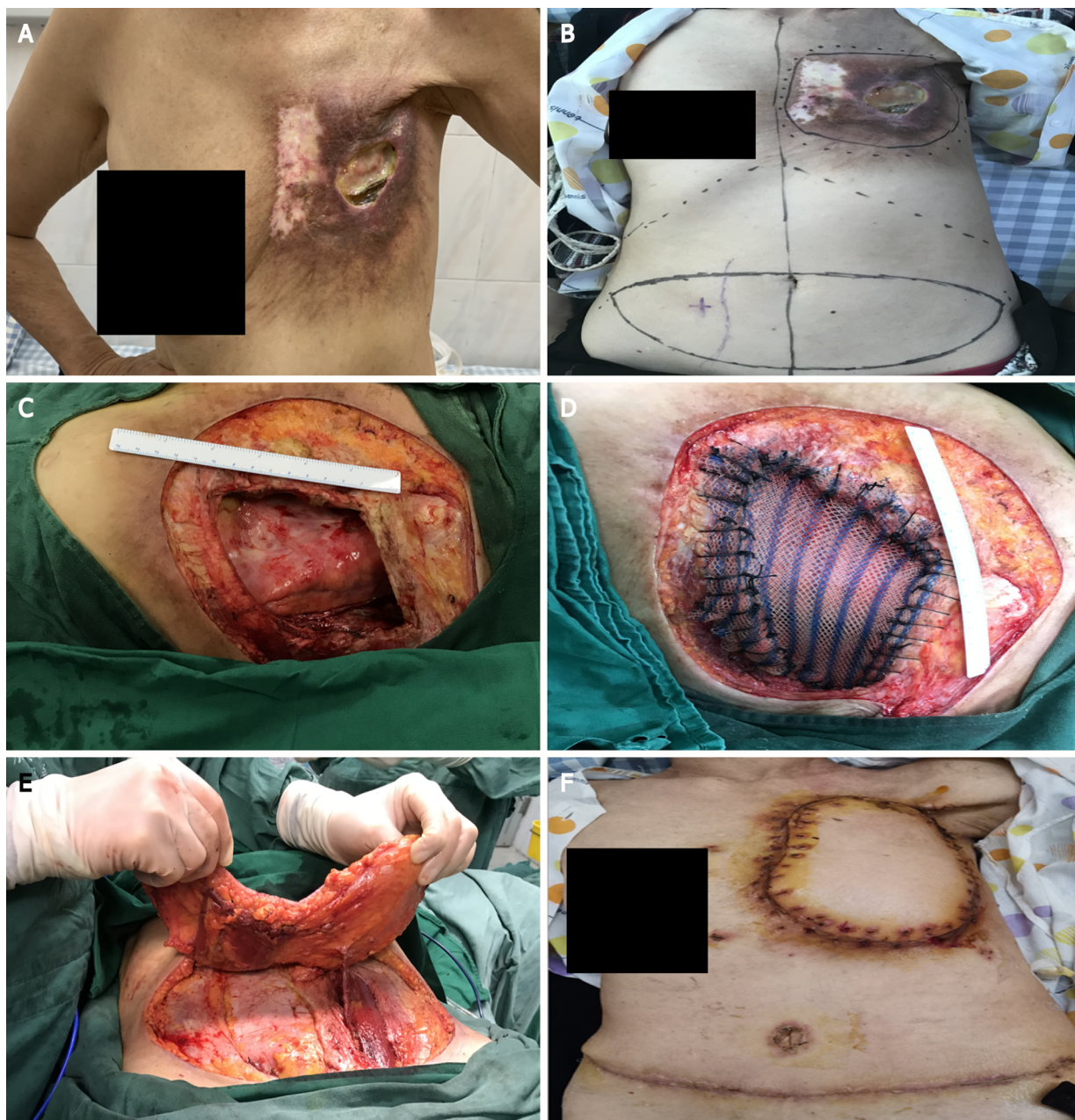The patient was followed-up for 6 mo after the operation. The skin flap showed no pigmentation and no edema. The skin growth and healing of the donor site were acceptable. The donor site was not complicated with abdominal skin necrosis, abdominal bulge, abdominal weakness, nor abdominal hernia (Figure 1F).

DISCUSSION

Although radiotherapy equipment, technology and design have been developed to varying degrees in recent years, the occurrence of chronic radiation-induced ulcers of the chest wall are still common when radiation therapy is received after breast cancer surgery.

According to scholars, conservative treatment of radiation-induced ulcers using debridement, dressing change and antibiotics is ineffective for most patients[7]. Many clinicians have tried different methods to treat chronic radiation-induced ulcers of the chest wall. According to Nishimoto *et al*[8], an ideal therapeutic effect was observed in 4 patients upon transfusing platelet-rich plasma and simultaneous skin grafting. Other studies have reported that chronic radiation-induced ulcers of the chest wall have been cured by intravenous infusion of plasma-purified mannan-binding lectin to patients[9,10]. Researchers have also conducted an animal experiment (in guinea pigs) and administered arginine glutamate after artificially causing radiation-induced ulcers, and the therapeutic effect of the ulcers was adequate[10,11]. However, due to individual differences, the above treatment has not been widely promoted in clinical practice, and surgical treatment is still the main treatment.

Radiation injury causes soft tissue damage and leads to necrosis of the sternum and ribs. Surgical reconstruction of the chest wall includes two parts: Thoracic reconstruction and soft tissue repair. It is generally believed that if the anterolateral chest wall defect is less than 6 cm × 6 cm and the posterior chest wall defect is less than 10 cm × 10 cm, then generally no thoracic reconstruction is required[10,12]. Soft tissue coverage alone can eliminate the abnormal respiratory movement of the chest wall after



DOI: 10.12998/wjcc.v10.i11.3505 Copyright © The Author(s) 2022.

Figure 1 Physical examination and surgery. A: Chest wall ulcer; B: Preoperative design; C: Chest wall defect measurement; D: Bone thoracic repair; E: Flap acquisition; F: Skin flap shaping.

surgery. However, large defects require thoracic reconstruction to restore the firmness and stability of the thorax in order to protect the viscera and maintain normal respiration.

In the reconstruction of the bony chest wall, two kinds of synthetic materials titanium alloy plates and HDPE soft patch are mostly used. HDPE patches have good toughness and elicit minimal aseptic inflammatory response. In a short time, human tissue can grow on the patch and cover the cavity in the body, which is conducive to wound repair. In addition, the patch is easy to cut and use during surgery. However, compared with a titanium alloy plate, its hardness and support force are not satisfactory. Occasionally, when the patient breathes, the HDPE patch suture loosens, which results in deformation of the chest wall. However, HDPE patches do not interfere with subsequent radiation therapy.

Thorough debridement and myocutaneous flap coverage of the defect are the preferred methods for the surgical treatment of chest wall ulcers. When debridement of thoracic ulcers is performed, it is required to remove the injured skin and subcutaneous soft tissue, necrotic ribs, sternum, clavicle and surrounding muscle fibrous tissue as much as possible. The choice of myocutaneous flaps, such as latissimus dorsi flap, pectoralis major flap and rectus abdominis flap, is preferred[6]. These myocutaneous flaps have the advantages of rich tissue volume, stable vascular pedicle course, and easy operation. However, due to the harvesting of a large amount of autologous muscles from patients, they

cause greater trauma to individuals and result in a longer recovery time, which may delay the subsequent treatment time. In contrast, pedicle musculocutaneous flaps are difficult to cover large wounds due to their small incision area.

In this case, DIEP soft tissue was used to repair the chest wall defect. Without harvesting the muscle, there was a sufficient amount of tissue to cover the defect, which was less invasive to the patient and had less recovery time, that did not disrupt subsequent radiotherapy. However, compared with other myocutaneous flaps, DIEP has a relatively small amount of tissue and cannot be used to cover deeper or larger defects. Moreover, the operation of DIEP is relatively complex and requires knowledge and expertise in microvascular anastomosis surgery, which is difficult to promote in clinical practice.

The main characteristics of this case were: (1) Intraoperative use of DIEP does not cut the rectus abdominis muscle, making it less invasive to the patient and shortening the postoperative recovery time; and (2) Intraoperative use of HDPE patches can maintain stability of the chest wall and does not interfere with the patient's subsequent radiotherapy.

CONCLUSION

In summary, for patients with smaller chest wall defects accompanied by rib necrosis, DIEP combined with HDPE patch repair can be used to obtain satisfactory clinical efficacy and reduce the occurrence of postoperative complications. This may be a better way to treat large chest wall radiation-induced ulcers.

FOOTNOTES

Author contributions: Zhang YQ contributed to conception and design of the case report; Li JW contributed administrative support; Huang SC and Qiu P contributed to provision of study materials or patients; Liang ZZ, Yan ZM and Luo KW contributed to collection and assembly of data; Huang BY, Chen CY and Chen WZ contributed to data analysis and interpretation; Qiu P, Chen CY, Huang SC, Yan ZM, Chen WZ, Liang ZZ, Luo KW, Huang BY, Li JW and Zhang YQ contributed to manuscript writing and final approval of the manuscript.

Informed consent statement: The patient's consent was obtained for the anonymized release of the case data.

Conflict-of-interest statement: The authors declare no conflicts of interest.

CARE Checklist (2016) statement: The authors have read the CARE Checklist (2016), and the manuscript was prepared and revised according to the CARE Checklist (2016).

Open-Access: This article is an open-access article that was selected by an in-house editor and fully peer-reviewed by external reviewers. It is distributed in accordance with the Creative Commons Attribution NonCommercial (CC BY-NC 4.0) license, which permits others to distribute, remix, adapt, build upon this work non-commercially, and license their derivative works on different terms, provided the original work is properly cited and the use is non-commercial. See: <https://creativecommons.org/licenses/by-nc/4.0/>

Country/Territory of origin: China

ORCID number: Sheng-Chao Huang 0000-0002-8713-8365; Chun-Yan Chen 0000-0002-7541-9784; Pu Qiu 0000-0003-0792-8808; Ze-Ming Yan 0000-0002-8473-7063; Wei-Zhang Chen 0000-0002-4668-6760; Zhong-Zheng Liang 0000-0002-6223-852X; Kang-Wei Luo 0000-0003-2742-5626; Jian-Wen Li 0000-0002-7657-1876; Yuan-Qi Zhang 0000-0002-7206-2353; Bao-Yi Huang 0000-0002-4282-2008.

S-Editor: Fan JR

L-Editor: A

P-Editor: Fan JR

REFERENCES

- 1 **Zhou Y**, Zhang Y. Single- versus 2-stage reconstruction for chronic post-radiation chest wall ulcer: A 10-year retrospective study of chronic radiation-induced ulcers. *Medicine (Baltimore)* 2019; **98**: e14567 [PMID: 30813173 DOI: 10.1097/MD.00000000000014567]
- 2 **Futran ND**, Trotti A, Gwede C. Pentoxifylline in the treatment of radiation-related soft tissue injury: preliminary observations. *Laryngoscope* 1997; **107**: 391-395 [PMID: 9121320 DOI: 10.1097/00005537-199703000-00022]
- 3 **Arnold PG**, Pairolero PC. Reconstruction of the radiation-damaged chest wall. *Surg Clin North Am* 1989; **69**: 1081-1089 [PMID: 2675349 DOI: 10.1016/s0039-6109(16)44939-x]
- 4 **Feldmeier JJ**. Hyperbaric oxygen therapy and delayed radiation injuries (soft tissue and bony necrosis): 2012 update. *Undersea Hyperb Med* 2012; **39**: 1121-1139 [PMID: 23342770 DOI: 10.1038/mtna.2012.47]

- 5 **Enomoto M**, Yagishita K, Okuma K, Oyaizu T, Kojima Y, Okubo A, Maeda T, Miyamoto S, Okawa A. Hyperbaric oxygen therapy for a refractory skin ulcer after radical mastectomy and radiation therapy: a case report. *J Med Case Rep* 2017; **11**: 5 [PMID: [28049509](#) DOI: [10.1186/s13256-016-1168-0](#)]
- 6 **Hameed A**, Akhtar S, Naqvi A, Pervaiz Z. Reconstruction of complex chest wall defects by using polypropylene mesh and a pedicled latissimus dorsi flap: a 6-year experience. *J Plast Reconstr Aesthet Surg* 2008; **61**: 628-635 [PMID: [17656168](#) DOI: [10.1016/j.bjps.2007.04.011](#)]
- 7 **Fujioka M**. Surgical Reconstruction of Radiation Injuries. *Adv Wound Care (New Rochelle)* 2014; **3**: 25-37 [PMID: [24761342](#) DOI: [10.1089/wound.2012.0405](#)]
- 8 **Nishimoto S**, Fukuda K, Kawai K, Fujiwara T, Tsumano T, Fujita K, Kakibuchi M. Supplementation of bone marrow aspirate-derived platelet-rich plasma for treating radiation-induced ulcer after cardiac fluoroscopic procedures: A preliminary report. *Indian J Plast Surg* 2012; **45**: 109-114 [PMID: [22754164](#) DOI: [10.4103/0970-0358.96599](#)]
- 9 **Maaløe N**, Bonde C, Laursen I, Christiansen M, Hölmich LR. Mannan-binding lectin and healing of a radiation-induced chronic ulcer--a case report on mannan-binding lectin replacement therapy. *J Plast Reconstr Aesthet Surg* 2011; **64**: e146-e148 [PMID: [21353657](#) DOI: [10.1016/j.bjps.2011.01.013](#)]
- 10 **Zhou Y**, Guan X, Zhang Y. Staged repair of chronic chest wall radiation ulcer. *J Tissue Eng* 2014; **10**: 335-338 [DOI: [10.3969/j.issn.1673-0364.2014.06.009](#)]
- 11 **Khalin I**, Kocherga G. Arginine glutamate improves healing of radiation-induced skin ulcers in guinea pigs. *Int J Radiat Biol* 2013; **89**: 1108-1115 [PMID: [23786463](#) DOI: [10.3109/09553002.2013.817698](#)]
- 12 **Chang RR**, Mehrara BJ, Hu QY, Disa JJ, Cordeiro PG. Reconstruction of complex oncologic chest wall defects: a 10-year experience. *Ann Plast Surg* 2004; **52**: 471-9; discussion 479 [PMID: [15096930](#) DOI: [10.1097/01.sap.0000122653.09641.f8](#)]



Published by **Baishideng Publishing Group Inc**
7041 Koll Center Parkway, Suite 160, Pleasanton, CA 94566, USA

Telephone: +1-925-3991568

E-mail: bpgoffice@wjgnet.com

Help Desk: <https://www.f6publishing.com/helpdesk>

<https://www.wjgnet.com>

