

World Journal of *Clinical Cases*

World J Clin Cases 2022 April 16; 10(11): 3321-3638



REVIEW

- 3321** Encouraging specific biomarkers-based therapeutic strategies for hepatocellular carcinoma
Yao M, Yang JL, Wang DF, Wang L, Chen Y, Yao DF

ORIGINAL ARTICLE

Clinical and Translational Research

- 3334** Autophagy-related long non-coding RNA prognostic model predicts prognosis and survival of melanoma patients
Qiu Y, Wang HT, Zheng XF, Huang X, Meng JZ, Huang JP, Wen ZP, Yao J
- 3352** Identification of circ_0000375 and circ_0011536 as novel diagnostic biomarkers of colorectal cancer
Yin TF, Du SY, Zhao DY, Sun XZ, Zhou YC, Wang QQ, Zhou GYJ, Yao SK

Retrospective Study

- 3369** Echocardiography in the diagnosis of Shone's complex and analysis of the causes for missed diagnosis and misdiagnosis
Li YD, Meng H, Pang KJ, Li MZ, Xu N, Wang H, Li SJ, Yan J
- 3379** Predictors and prognostic impact of post-operative atrial fibrillation in patients with hip fracture surgery
Bae SJ, Kwon CH, Kim TY, Chang H, Kim BS, Kim SH, Kim HJ
- 3389** Added value of systemic inflammation markers for monitoring response to neoadjuvant chemotherapy in breast cancer patients
Ke ZR, Chen W, Li MX, Wu S, Jin LT, Wang TJ
- 3401** Washed microbiota transplantation reduces serum uric acid levels in patients with hyperuricaemia
Cai JR, Chen XW, He YJ, Wu B, Zhang M, Wu LH

Clinical Trials Study

- 3414** Concurrent chemoradiotherapy using gemcitabine and nedaplatin in recurrent or locally advanced head and neck squamous cell carcinoma
Huo RX, Jin YY, Zhuo YX, Ji XT, Cui Y, Wu XJ, Wang YJ, Zhang L, Zhang WH, Cai YM, Zheng CC, Cui RX, Wang QY, Sun Z, Wang FW

META-ANALYSIS

- 3426** Effect of enhanced recovery after surgery on inflammatory bowel disease surgery: A meta-analysis
Peng D, Cheng YX, Tao W, Tang H, Ji GY
- 3436** Accuracy of ultrasound elastography for predicting breast cancer response to neoadjuvant chemotherapy: A systematic review and meta-analysis
Chen W, Fang LX, Chen HL, Zheng JH

- 3449** Association of chronic obstructive pulmonary disease with mild cognitive impairment and dementia risk: A systematic review and meta-analysis

Zhao LY, Zhou XL

CASE REPORT

- 3461** Circulating tumor DNA genomic profiling reveals the complicated olaparib-resistance mechanism in prostate cancer salvage therapy: A case report

Yuan F, Liu N, Yang MZ, Zhang XT, Luo H, Zhou H

- 3472** Difference and similarity between type A interrupted aortic arch and aortic coarctation in adults: Two case reports

Ren SX, Zhang Q, Li PP, Wang XD

- 3478** Combination therapy (toripalimab and lenvatinib)-associated toxic epidermal necrolysis in a patient with metastatic liver cancer: A case report

Huang KK, Han SS, He LY, Yang LL, Liang BY, Zhen QY, Zhu ZB, Zhang CY, Li HY, Lin Y

- 3485** Unusual glomus tumor of the lower leg: A case report

Wang HY, Duan P, Chen H, Pan ZY

- 3490** Pulmonary *Cladosporium* infection coexisting with subcutaneous *Corynespora cassiicola* infection in a patient: A case report

Wang WY, Luo HB, Hu JQ, Hong HH

- 3496** Preoperational diagnosis and management of breast ductal carcinoma *in situ* arising within fibroadenoma: Two case reports

Wu J, Sun KW, Mo QP, Yang ZR, Chen Y, Zhong MC

- 3505** Reconstruction of complex chest wall defects: A case report

Huang SC, Chen CY, Qiu P, Yan ZM, Chen WZ, Liang ZZ, Luo KW, Li JW, Zhang YQ, Huang BY

- 3511** Young children with multidrug-resistant epilepsy and vagus nerve stimulation responding to perampanel: A case report

Yang H, Yu D

- 3518** Intramedullary nailing for pathological fractures of the proximal humerus caused by multiple myeloma: A case report and review of literature

Xu GQ, Wang G, Bai XD, Wang XJ

- 3527** Double tracheal stents reduce side effects of progression of malignant tracheoesophageal fistula treated with immunotherapy: A case report

Li CA, Yu WX, Wang LY, Zou H, Ban CJ, Wang HW

- 3533** Ankylosing spondylitis complicated with andersson lesion in the lower cervical spine: A case report

Peng YJ, Zhou Z, Wang QL, Liu XF, Yan J

- 3541** Severe gastric insufflation and consequent atelectasis caused by gas leakage using AIR-Q laryngeal mask airway: A case report

Zhao Y, Li P, Li DW, Zhao GF, Li XY

- 3547** Hypereosinophilic syndrome presenting as acute ischemic stroke, myocardial infarction, and arterial involvement: A case report
Sun RR, Chen TZ, Meng M
- 3553** Cytochrome P450 family 17 subfamily A member 1 mutation causes severe pseudohermaphroditism: A case report
Gong Y, Qin F, Li WJ, Li LY, He P, Zhou XJ
- 3561** Patellar dislocation following distal femoral replacement after extra-articular knee resection for bone sarcoma: A case report
Kubota Y, Tanaka K, Hirakawa M, Iwasaki T, Kawano M, Itonaga I, Tsumura H
- 3573** Qingchang decoction retention enema may induce clinical and mucosal remission in left-sided ulcerative colitis: A case report
Li PH, Tang Y, Wen HZ
- 3579** Anti-nuclear matrix protein 2+ juvenile dermatomyositis with severe skin ulcer and infection: A case report and literature review
Wang YT, Zhang Y, Tang T, Luo C, Liu MY, Xu L, Wang L, Tang XM
- 3587** Ultrasound-guided local ethanol injection for fertility-preserving cervical pregnancy accompanied by fetal heartbeat: Two case reports
Kakinuma T, Kakinuma K, Matsuda Y, Ohwada M, Yanagida K, Kaijima H
- 3593** Successful apatinib treatment for advanced clear cell renal carcinoma as a first-line palliative treatment: A case report
Wei HP, Mao J, Hu ZL
- 3601** Del(5q) and inv(3) in myelodysplastic syndrome: A rare case report
Liang HP, Luo XC, Zhang YL, Liu B
- 3609** Papillary thyroid microcarcinoma with contralateral lymphatic skip metastasis and breast cancer: A case report
Ding M, Kong YH, Gu JH, Xie RL, Fei J
- 3615** Contrast-enhanced ultrasound manifestations of synchronous combined hepatocellular-cholangiocarcinoma and hepatocellular carcinoma: A case report
Gao L, Huang JY, Lu ZJ, Lu Q
- 3624** Thyrotoxicosis after a massive levothyroxine ingestion: A case report
Du F, Liu SW, Yang H, Duan RX, Ren WX
- 3630** Pleomorphic adenoma of the left lacrimal gland recurred and transformed into myoepithelial carcinoma after multiple operations: A case report
Huang WP, Li LM, Gao JB

ABOUT COVER

Editorial Board Member of *World Journal of Clinical Cases*, Chi-Yuan Yeh, MD, PhD, Assistant Professor, Chief Doctor, radiation oncology, Tungs' Taichung MetroHarbor Hospital, Taichung 43503, Taiwan.
peteryeh46@gmail.com

AIMS AND SCOPE

The primary aim of *World Journal of Clinical Cases* (WJCC, *World J Clin Cases*) is to provide scholars and readers from various fields of clinical medicine with a platform to publish high-quality clinical research articles and communicate their research findings online.

WJCC mainly publishes articles reporting research results and findings obtained in the field of clinical medicine and covering a wide range of topics, including case control studies, retrospective cohort studies, retrospective studies, clinical trials studies, observational studies, prospective studies, randomized controlled trials, randomized clinical trials, systematic reviews, meta-analysis, and case reports.

INDEXING/ABSTRACTING

The WJCC is now indexed in Science Citation Index Expanded (also known as SciSearch®), Journal Citation Reports/Science Edition, Scopus, PubMed, and PubMed Central. The 2021 Edition of Journal Citation Reports® cites the 2020 impact factor (IF) for WJCC as 1.337; IF without journal self cites: 1.301; 5-year IF: 1.742; Journal Citation Indicator: 0.33; Ranking: 119 among 169 journals in medicine, general and internal; and Quartile category: Q3. The WJCC's CiteScore for 2020 is 0.8 and Scopus CiteScore rank 2020: General Medicine is 493/793.

RESPONSIBLE EDITORS FOR THIS ISSUE

Production Editor: Hua-Ge Yin; Production Department Director: Xiang Li; Editorial Office Director: Jin-Lai Wang.

NAME OF JOURNAL

World Journal of Clinical Cases

ISSN

ISSN 2307-8960 (online)

LAUNCH DATE

April 16, 2013

FREQUENCY

Thrice Monthly

EDITORS-IN-CHIEF

Bao-Gan Peng, Jerzy Tadeusz Chudek, George Kontogeorgos, Maurizio Serati, Ja Hyeon Ku

EDITORIAL BOARD MEMBERS

<https://www.wjgnet.com/2307-8960/editorialboard.htm>

PUBLICATION DATE

April 16, 2022

COPYRIGHT

© 2022 Baishideng Publishing Group Inc

INSTRUCTIONS TO AUTHORS

<https://www.wjgnet.com/bpg/gerinfo/204>

GUIDELINES FOR ETHICS DOCUMENTS

<https://www.wjgnet.com/bpg/GerInfo/287>

GUIDELINES FOR NON-NATIVE SPEAKERS OF ENGLISH

<https://www.wjgnet.com/bpg/gerinfo/240>

PUBLICATION ETHICS

<https://www.wjgnet.com/bpg/GerInfo/288>

PUBLICATION MISCONDUCT

<https://www.wjgnet.com/bpg/gerinfo/208>

ARTICLE PROCESSING CHARGE

<https://www.wjgnet.com/bpg/gerinfo/242>

STEPS FOR SUBMITTING MANUSCRIPTS

<https://www.wjgnet.com/bpg/GerInfo/239>

ONLINE SUBMISSION

<https://www.f6publishing.com>



Ankylosing spondylitis complicated with andersson lesion in the lower cervical spine: A case report

Yu-Jian Peng, Zhuang Zhou, Qian-Liang Wang, Xiao-Feng Liu, Jun Yan

Specialty type: Orthopedics

Provenance and peer review:

Unsolicited article; Externally peer reviewed.

Peer-review model: Single blind

Peer-review report's scientific quality classification

Grade A (Excellent): 0

Grade B (Very good): B

Grade C (Good): C

Grade D (Fair): 0

Grade E (Poor): 0

P-Reviewer: Cure E, Turkey; Hui Yang, China

Received: September 18, 2021

Peer-review started: September 18, 2021

First decision: December 10, 2021

Revised: December 18, 2021

Accepted: February 27, 2022

Article in press: February 27, 2022

Published online: April 16, 2022



Yu-Jian Peng, Qian-Liang Wang, Xiao-Feng Liu, Jun Yan, Department of Orthopedics, the Second Affiliated Hospital of Soochow University, Suzhou 215004, Jiangsu Province, China

Zhuang Zhou, Department of Pain, the Second Affiliated Hospital of Soochow University, Suzhou 215004, Jiangsu Province, China

Corresponding author: Jun Yan, MD, Chief Physician, Director, Department of Orthopedics, the Second Affiliated Hospital of Soochow University, No. 1055 San-Xiang Road, Suzhou 215004, Jiangsu Province, China. cxyanjuan@hotmail.com

Abstract

BACKGROUND

Andersson lesion (AL) is an uncommon complication in ankylosing spondylitis (AS), which is characterized by nonneoplastic bone destruction and often appears as bone destruction and sclerosis in the vertebral body and/or the area involving the intervertebral disc. According to the literature, Andersson lesion commonly occur in the thoracic and lumbar spine and rarely in the cervical spine.

CASE SUMMARY

This case involved a 78-year-old man with a long history of AS who developed AL in the cervical spine (C5/6 and C6/7). One-stage anterior-posterior approach surgery was successfully performed. At the 6-month follow-up, the pain was significantly reduced, and the limb function was gradually improved.

CONCLUSION

AL uncharacteristically appears in the cervical spine and tends to be misdiagnosed as vertebral metastases or spinal tuberculosis. Posterior combined with anterior surgery achieves solid biological stabilization in the treatment of AL bone destruction.

Key Words: Andersson lesion; Ankylosing spondylitis; Cervical fracture; Case report

©The Author(s) 2022. Published by Baishideng Publishing Group Inc. All rights reserved.

Core Tip: This case involved an Andersson lesion in the cervical spine that occurred in an ankylosing spondylitis patient and was very rare. The Andersson lesion was diagnosed based on orthopaedist clinical experience, imaging examinations and final pathology results. This case report provides a reference for the clinical diagnosis of such cases.

Citation: Peng YJ, Zhou Z, Wang QL, Liu XF, Yan J. Ankylosing spondylitis complicated with andersson lesion in the lower cervical spine: A case report. *World J Clin Cases* 2022; 10(11): 3533-3540

URL: <https://www.wjgnet.com/2307-8960/full/v10/i11/3533.htm>

DOI: <https://dx.doi.org/10.12998/wjcc.v10.i11.3533>

INTRODUCTION

Andersson lesion (AL) are characterized by nonneoplastic bone destruction, which is an uncommon phenomenon in late-stage ankylosing spondylitis (AS) and often appears as erosive focal changes with sclerosis widely distributed in the region of the vertebral end plate[1,2]. The prevalence of AL-complicating AS ranges from 1.5% to > 28%[3,4]. With the development of AL, these pathological and destructive changes of the spine may lead to progressive, localized and pain-intolerable kyphosis deformities and even neurological defects, which must be treated in severe cases[5,6]. AS is a chronic active nonunion state with unstable posterior column fractures or unfused facet joints associated with vertebral lesion[7]. Since nonspecific inflammation is the main pathological manifestation, Andersson lesion commonly occur in the region of the thoracic and lumbar spine but rarely in the cervical spine[8]. We successfully treated a patient with nonneoplastic and noninfectious bone destruction of the C6 vertebral body, who had a history of ankylosing spondylitis for decades, which resulted in nonunion involving the middle and posterior columns, characteristics of an Andersson lesion. To the best of our knowledge, this is the first report of unstable fractures of AS with C6 aggressive bone destruction and accumulation of three columns of the cervical spine.

CASE PRESENTATION

Chief complaints

A 78-year-old male farmer was admitted to our hospital with neck pain, worsened numbness and increased disability due to an accidental fall a month prior. He had neck pain and a limited range of motions, but he had no symptoms of fever, night sweats or increased nocturnal pain.

History of present illness

This patient had a history of AS and mobility impairments for decades. He had progressive symptoms of neck pain for 3 mo complicated with left upper limb pain and numbness without obvious cause.

History of past illness

He had no history of diabetes, tuberculosis or tumour. He had undergone thoracolumbar fracture surgery more than ten years ago.

Personal and family history

The patient denied family history.

Physical examination

Physical examination revealed a restricted cervical range of motion. The muscle power of the left upper limbs was grade IV with slightly decreased sensation. The Hoffman signs of both upper limbs were negative, and bilateral Babinski signs were negative in the lower extremities.

Laboratory examinations

Routine blood analysis revealed a slight increase in the neutrophil ratio (77.4%) with normal haematocrit and leukocyte counts. Prothrombin and partial thromboplastin times were almost normal, and d-dimers were increased at 1.56 µg/mL. Serum C-reactive protein was increased at 55.6 mg/dL (normal range < 10 mg/dL). The blood serum tumour marker analysis showed that ferroprotein increased at 516 ng/mL (normal range 30-400 ng/mL), and prostate-specific antigen marginally increased to 8.53 ng/mL (normal range < 4 ng/mL).

Imaging examinations

Radiography and computed tomography (CT) scans revealed typical ankylosing spondylitis in the entire spine, *i.e.*, bamboo-like changes; a pathological fracture changed from the C6 vertebra and accumulated at the upper and lower endplates to spinous processes (Figure 1). Magnetic resonance imaging (MRI) showed C6 new-onset vertebral compression fractures and oedema spread from the anterior region of the C6 spinal centrum to the spinous process and supraspinous ligaments, which were complicated by the degenerative cervical instability and compression of the spinal cord due to the injured cervical spinal stenosis (Figure 2).

FINAL DIAGNOSIS

The final diagnosis of the presented case was Andersson lesion in the lower cervical spine.

TREATMENT

The patient underwent surgery for instrumented stabilization through anterior combined posterior approaches. First, the patient's body temperature was normal throughout the examination. Second, he was convinced that he had no history of tuberculosis or malignant visceral tumours, and all tuberculosis-related laboratory tests or tumour markers were negative. To restore cervical stability, we performed a combined posterior and anterior fixation approach with pedicle screws under a C-arm perspective (Figure 3). In brief, after exposure of C4-T2 with a posterior midline incision, part of the C5 and C6 Laminae were removed using an ultrasonic osteotome; the structure in the spinal canal was exposed, and posterior spinal canal decompression was completed. Under the guidance of C-arm fluoroscopy, the lateral mass or pedicle screws (8 in total, brand: Medtronic) were placed after positioning, drilling and sounding on the side mass of C4, C5 and C7 and the pedicle of T2; a connecting rod (Brand: Medtronic) was used to connect the fixing screws. Next, anterior surgery in the supine position was performed to expose the C6 vertebral body. Under the microscope, the C6 vertebral body and the upper and lower endplates were scraped with a curette. Then, we removed the granulation tissue for pathological examination and bacterial culture, and a short titanium mesh (Brand: Medtronic) was used to support and fix between the C5 Lower endplate and the C6 residual vertebral body. Anterior cervical plates and screws (Brand: Medtronic) were placed in front of C4-T1. To prevent screw loosening caused by osteoporosis, we used bone cement to strengthen the nail channels.

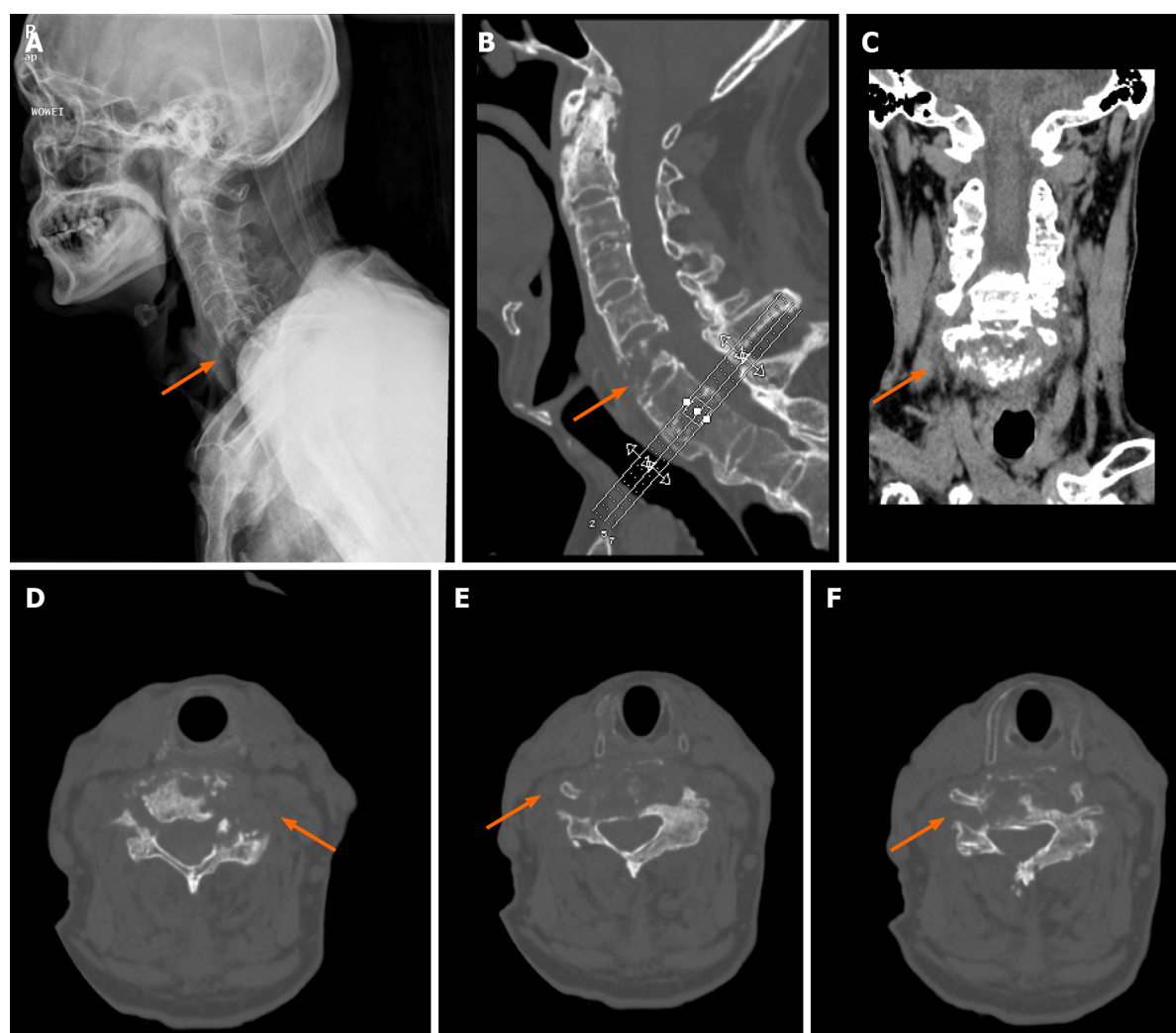
OUTCOME AND FOLLOW-UP

The operation was very successful, and the pathology indicated hyperplastic and fibrous bone tissue with dead bone reaction with no indications of tumour cells and negative bacterial culture results (Figure 4). A postoperative double-check CT scan revealed that the internal fixation device was firm and reliable, and the stability of the cervical spine recovered well. Six months after the operation, the patient reported that the symptoms of pain and numbness were notably relieved and almost returned to normal. The follow-up X-ray images of the cervical spine AL showed that the balance of the coronal plane and sagittal plane recovered well (Figure 5).

DISCUSSION

Andersson first described the characteristics of destructive lesion of the vertebral body and/or intervertebral disc in patients with ankylosing spondylitis in 1937[8]. Since then, they have been known as Andersson lesion, spondylodiscitis, spinal pseudarthroses and destructive spondylopathy[9,10]. This uncertainty in the naming of AL is mainly due to the lack of consistency in the etiology and pathology of the characteristics of these lesions. To date, two mainstream possible mechanisms have been reported. First, these lesions are considered to have a chronic nonspecific inflammatory nature and are attributed to the disease characteristics of ankylosing spondylitis. The other explanation is that they originate from traumatic injury and are characterized by constitute mechanical stress fracture, spinal nonunion or pseudarthroses after trauma[11-13]. Generally, the entire spine of patients with ankylosing spondylitis is susceptible. However, clinically, the most common site of this lesion is the thoracic and lumbar spine, especially the thoracolumbar transition area, *i.e.*, T10-L2, possibly since this area is defined as the transition area of high stress in anatomy and biomechanics[14-16].

Previous reports on AL mainly involved the thoracic vertebrae and lumbar vertebrae regions, but there were almost no reports of AL in the cervical vertebrae. This is the first study to show nonneo-



DOI: 10.12998/wjcc.v10.i11.3533 Copyright © The Author(s) 2022.

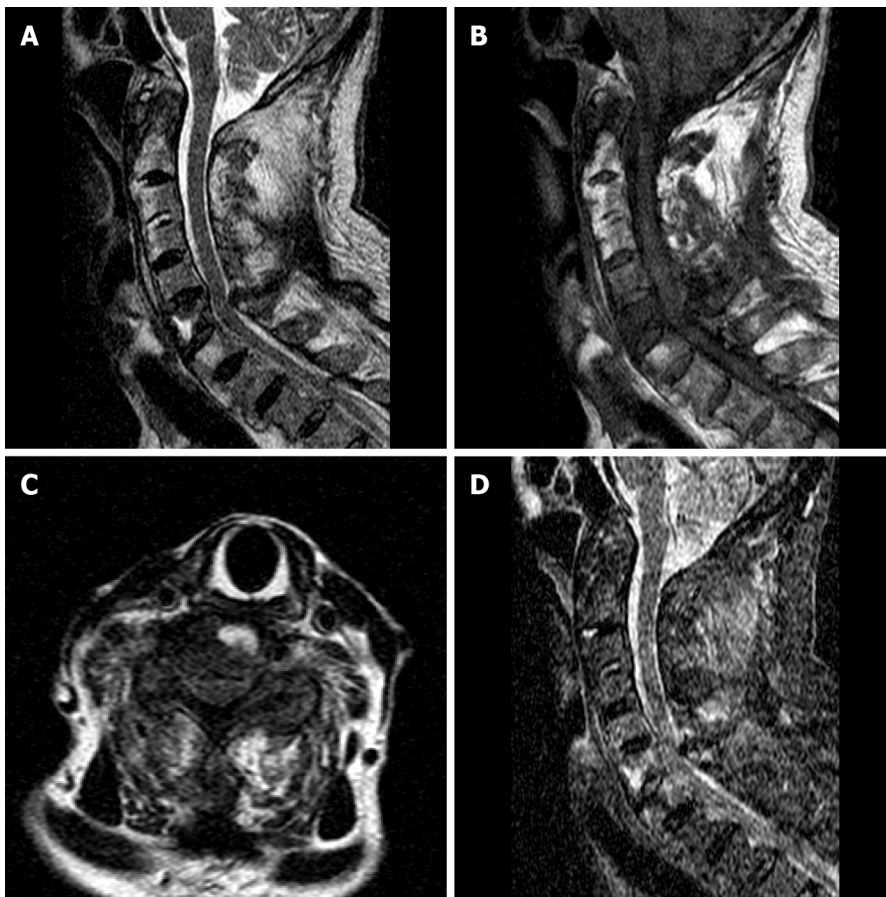
Figure 1 Preoperative X-ray and computed tomography. A: Lateral X-ray view, an arrow shows pathological fracture; B: CT sagittal image, an arrow shows pathological fracture; C: Computed tomography (CT) coronal image, an arrow shows pathological fracture; D-F: CT axial images at different slice levels, an arrow shows pathological fracture.

plastic destructive lesion in the lower cervical vertebrae and the induction of cervical trauma injury.

This patient had a recent history of trauma, and the destructive lesion in the C6 vertebra was almost consistent with the characteristics of imaging, pathology and biomechanics of the Andersson lesion (bone destruction caused by chronic compression). Thus, we suspected that these unstable lower cervical spine fractures resulted from trauma with Andersson lesion, although the location was different from that previously reported (mainly in the thoracic and lumbar vertebrae). Most AL patients have been middle-aged and elderly men with or without AS symptoms for decades. The common clinical manifestations are local intolerable and progressive pain of the thoracolumbar spine and local severe pain after mild trauma with dysfunction[12].

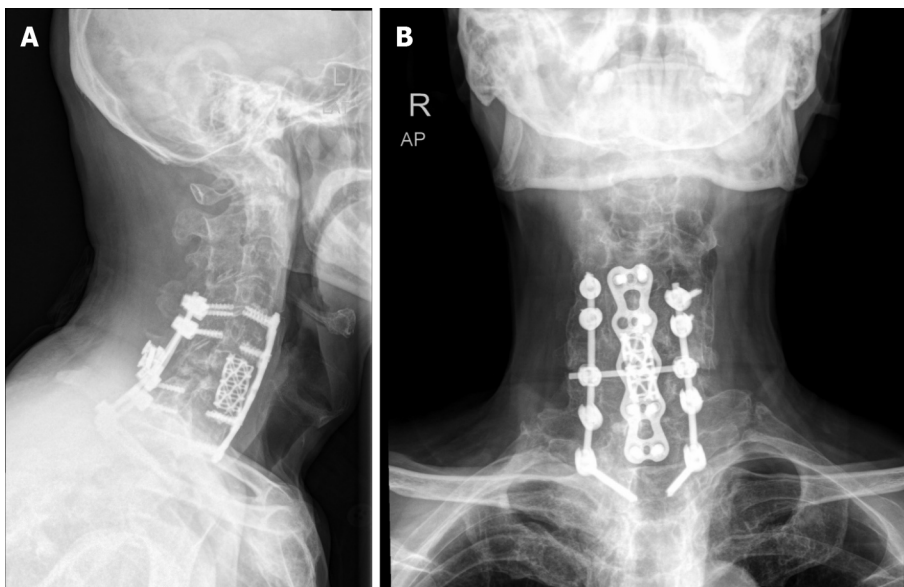
When combined with spinal cord nerve injury, some patients have serious symptoms such as numbness, muscle weakness, incomplete paralysis or even paraplegia. X-ray examination can preliminarily detect the degree of erosive bone destruction. Computed tomography is more accurate and stereoscopic than X-ray in displaying bone lesion, especially in assessing the location of spinal cord compression, the involvement of the spinal canal, the severity of vertebral destruction and the injury mechanism. In addition, MRI can provide information about the involvement of soft tissue around the spine, and the state of the spinal cord and nerve is clearer.

Based on the imaging findings for this patient, AL might be easily misdiagnosed for spinal tuberculosis or spinal metastasis because these conditions are mostly identified by bone destruction. In addition, both AL and spinal tuberculosis may be characterized by the narrowed intervertebral space, hyperosteoecy and late sclerosis[13]. Unlike AL, most patients with spinal tuberculosis have low fever, night sweats and other systemic symptoms in the early stage, and the anti-tuberculosis treatment is effective. Similarly, patients with spinal metastases often have symptoms in primary organs, such as gastrointestinal tumours and prostate cancer. Spinal metastases are common in the thoracolumbar spine, and cervical metastases are rarely reported. With detailed physical examination and previous AS



DOI: 10.12998/wjcc.v10.i11.3533 Copyright © The Author(s) 2022.

Figure 2 Preoperative magnetic resonance imaging. A: Sagittal T2-weighted image; B: Sagittal T1-weighted image; C: Axial T2-weighted image; D: Sagittal STIR image.

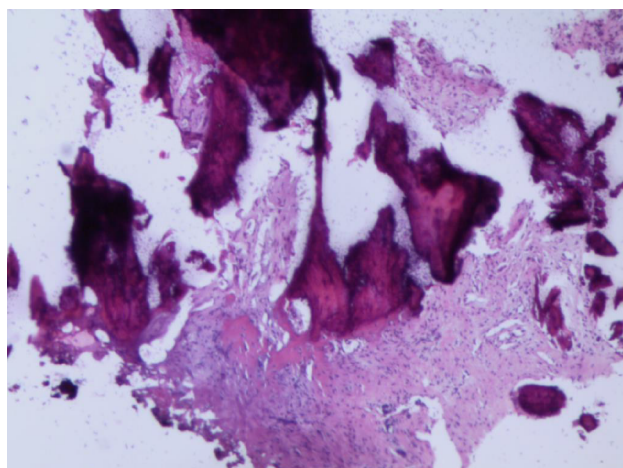


DOI: 10.12998/wjcc.v10.i11.3533 Copyright © The Author(s) 2022.

Figure 3 Postoperative X-ray. A: Lateral X-ray view; B: Anteroposterior X-ray view.

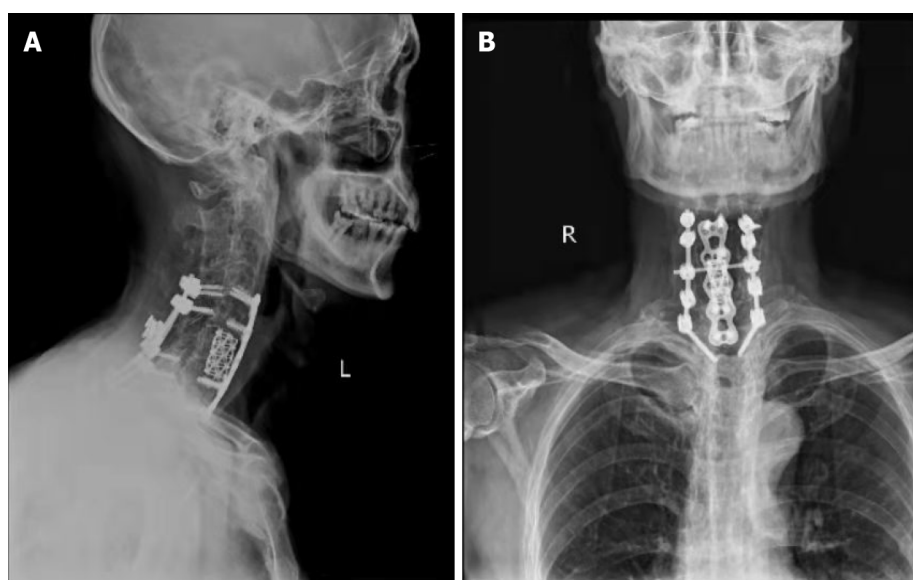
disease history, laboratory markers, X-ray, CT and magnetic resonance examination are vitally important for the diagnosis of AL.

To the best of our knowledge, there are no exact and consistent guidelines on how to systematically treat AL[17]. Conservative treatment, including NSAIDs and anti-TNF- α therapy, is often initially



DOI: 10.12998/wjcc.v10.i11.3533 Copyright © The Author(s) 2022.

Figure 4 Pathology picture.



DOI: 10.12998/wjcc.v10.i11.3533 Copyright © The Author(s) 2022.

Figure 5 10 months postoperative X-ray. A: Lateral X-ray view; B: Anteroposterior X-ray view.

suggested, and some researchers have confirmed that conservative treatment is safe and effective[8]. Nevertheless, there is still no recognized evidence that these drugs can help the treatment of symptomatic AL, although they have been proven to be effective in patients with ankylosing spondylitis. Therefore, surgical treatment is recommended to reduce unbearable pain, kyphosis deformity, biomechanical instability or neurological deficits caused by trauma[18-21]. Our patient had a mild traumatic fracture involving three columns of the cervical spine secondary to Andersson lesion. To reconstruct the stability of the cervical spine and fully decompress the spinal canal, we chose the posterior with the anterior approach for surgery. According to our experience, successful interbody fusion through surgery (one-stage internal fixation) is the safest and most effective choice to treat AL.

CONCLUSION

In summary, AL constitutes a relatively infrequent nonneoplastic bone destruction in patients with AS. Our report provides a meaningful reference for the diagnosis, differential diagnosis, treatment and prognosis of AL. Surgery is a more reasonable choice to treat AL with unstable cervical fracture, especially for patients with kyphosis and dysfunction caused by nerve compression. Fusion is critical, and complete decompression is fundamental in the treatment of Andersson lesion.

FOOTNOTES

Author contributions: Peng YJ performed the study, collected data, and drafted the manuscript; Zhou Z and Wang QL collected data, performed literature searches and interpreted the data; Liu XF and Yan J made critical revisions to the manuscript; all authors have read and approved the version of the article presented for publication

Supported by the National Natural Science Foundation of China, No. 81902239 and the Natural Science Foundation of Jiangsu Province, No. BK20191169.

Informed consent statement: Written informed consent was obtained from the patient for the publication of this case report and the accompanying images.

Conflict-of-interest statement: The authors have no conflicts of interests to disclose.

CARE Checklist (2016) statement: The authors have read the CARE Checklist (2016), and the manuscript was prepared and revised according to the CARE Checklist (2016).

Open-Access: This article is an open-access article that was selected by an in-house editor and fully peer-reviewed by external reviewers. It is distributed in accordance with the Creative Commons Attribution NonCommercial (CC BY-NC 4.0) license, which permits others to distribute, remix, adapt, build upon this work non-commercially, and license their derivative works on different terms, provided the original work is properly cited and the use is non-commercial. See: <https://creativecommons.org/licenses/by-nc/4.0/>

Country/Territory of origin: China

ORCID number: Yu-Jian Peng 0000-0001-6927-6599; Zhuang Zhou 0000-0002-9050-2578; Qian-Liang Wang 0000-0002-0785-2594; Xiao-Feng Liu 0000-0003-3405-1247; Jun Yan 0000-0003-3640-1714.

S-Editor: Ma YJ

L-Editor: A

P-Editor: Ma YJ

REFERENCES

- 1 Wu M, Yan F, Ping A, Lei J. Effects of Andersson lesion treatment in ankylosing spondylitis: A medical record review study focused on medium- to long-term outcomes. *Int J Rheum Dis* 2020; **23**: 753-762 [PMID: 32266777 DOI: 10.1111/1756-185X.13826]
- 2 Ji X, Su M, Chen J, Wang X, Cai X. A novel method for plastic particle sizing in suspension based on acoustic impedance spectrum. *Ultrasonics* 2017; **77**: 224-230 [PMID: 28260691 DOI: 10.1016/j.ultras.2017.01.024]
- 3 Shao J, Gao YZ, Gao K, Yu ZH. Ankylosing Spondylitis Complicated with Atlantoaxial Dislocation and Destruction of the Dens and Lateral Atlantoaxial Joint: A Case Report. *JBJS Case Connect* 2019; **9**: e0216 [PMID: 31833976 DOI: 10.2106/JBJS.CC.19.00216]
- 4 Fu X, Zhang Y, Jiang W, Monnot AD, Bates CA, Zheng W. Regulation of copper transport crossing brain barrier systems by Cu-ATPases: effect of manganese exposure. *Toxicol Sci* 2014; **139**: 432-451 [PMID: 24614235 DOI: 10.1093/toxsci/kfu048]
- 5 Zhang X, Wang Y, Wu B, Hu W, Zhang Z. Treatment of Andersson lesion-complicating ankylosing spondylitis via transpedicular subtraction and disc resection osteotomy, a retrospective study. *Eur Spine J* 2016; **25**: 2587-2595 [PMID: 26346847 DOI: 10.1007/s00586-015-4213-6]
- 6 Barman A, Sinha MK, Rao PB. Discovertebral (Andersson) lesion of the Ankylosing Spondylitis, a cause of autonomic dysreflexia in spinal cord injury. *Spinal Cord Ser Cases* 2016; **2**: 16008 [PMID: 28053752 DOI: 10.1038/scsanc.2016.8]
- 7 Liang Y, Tang X, Zhao Y, Wang Z. Posterior wedge osteotomy and debridement for Andersson lesion with severe kyphosis in ankylosing spondylitis. *J Orthop Surg Res* 2017; **12**: 54 [PMID: 28359323 DOI: 10.1186/s13018-017-0556-5]
- 8 Wang HF, Bi C, Chen ZQ. [Research progress on Andersson lesion in ankylosing spondylitis]. *Zhonghua Wai Ke Za Zhi* 2017; **55**: 798-800 [PMID: 29050182 DOI: 10.3760/cma.j.issn.0529-5815.2017.10.020]
- 9 Van Royen BJ, Kastelijns RC, Noske DP, Oner FC, Smit TH. Transpedicular wedge resection osteotomy for the treatment of a kyphotic Andersson lesion-complicating ankylosing spondylitis. *Eur Spine J* 2006; **15**: 246-252 [PMID: 16151717 DOI: 10.1007/s00586-005-1008-1]
- 10 Obradov M, Schönfeld DH, Franssen MJ, de Rooy DJ. Andersson lesion in ankylosing spondylitis. *JBR-BTR* 2001; **84**: 71 [PMID: 11374644]
- 11 Queiro R, Tejón P, Alonso S, Alperi M, Ballina J. Erosive discovertebral lesion (Andersson lesion) as the first sign of disease in axial psoriatic arthritis. *Scand J Rheumatol* 2013; **42**: 220-225 [PMID: 23311864 DOI: 10.3109/03009742.2012.739637]
- 12 Dhakad U, Das SK. Andersson lesion in ankylosing spondylitis. *BMJ Case Rep* 2013; **2013** [PMID: 23559648 DOI: 10.1136/bcr-2012-008404]
- 13 Park YS, Kim JH, Ryu JA, Kim TH. The Andersson lesion in ankylosing spondylitis: distinguishing between the inflammatory and traumatic subtypes. *J Bone Joint Surg Br* 2011; **93**: 961-966 [PMID: 21705571 DOI: 10.1302/0301-620X.93B7.26337]

- 14 **Wang G**, Zhuo N, Tian F, Wen Z, Li J. Andersson lesion in the lumbar spine of SAPHO syndrome. *Rheumatology (Oxford)* 2022; **61**: 877 [PMID: [33974076](#) DOI: [10.1093/rheumatology/keab417](#)]
- 15 **Qin W**, Yang P, Zhou F, Mao H, Yang H. Andersson Lesion Occurring in the Lumbosacral Segment of a Young Man: A Case Report and Literature Review. *World Neurosurg* 2020; **143**: 419-422 [PMID: [32798782](#) DOI: [10.1016/j.wneu.2020.07.146](#)]
- 16 **Hu X**, Kong Y, Li B. Andersson Lesion in the Thoracic Spine. *J Clin Rheumatol* 2021; **27**: e258 [PMID: [32398510](#) DOI: [10.1097/RHU.0000000000001402](#)]
- 17 **Yang F**, Yang L, Ren E, Yang Y, Wang J, Kang X. Surgical Treatment of Ankylosing Spondylitis with Andersson Lesion. *J Coll Physicians Surg Pak* 2019; **29**: S135-S137 [PMID: [31779768](#) DOI: [10.29271/jcpsp.2019.12.S135](#)]
- 18 **Dave BR**, Kulkarni M, Patidar V, Devanand D, Mayi S, Reddy C, Singh M, Rai RR, Krishnan A. Results of in situ fixation of Andersson lesion by posterior approach in 35 cases. *Musculoskelet Surg* 2021 [PMID: [34037925](#) DOI: [10.1007/s12306-021-00712-z](#)]
- 19 **Ding K**, Zhu J, Chen H, Tian Y, Hao D. [Debridement and interbody fusion via posterior pedicle lateral approach for ankylosing spondylitis with thoracolumbar Andersson lesion]. *Zhongguo Xiu Fu Chong Jian Wai Ke Za Zhi* 2019; **33**: 1474-1479 [PMID: [31823543](#) DOI: [10.7507/1002-1892.201904068](#)]
- 20 **Shaik I**, Bhojraj SY, Prasad G, Nagad PB, Patel PM, Kashikar AD, Kumar N. Management of Andersson Lesion in Ankylosing Spondylitis Using the Posterior-Only Approach: A Case Series of 18 Patients. *Asian Spine J* 2018; **12**: 1017-1027 [PMID: [30322255](#) DOI: [10.31616/asj.2018.12.6.1017](#)]
- 21 **Rajoli SR**, Kanna RM, Aiyer SN, Shetty AP, Rajasekaran S. Circumferential Fusion through All-Posterior Approach in Andersson Lesion. *Asian Spine J* 2017; **11**: 444-453 [PMID: [28670413](#) DOI: [10.4184/asj.2017.11.3.444](#)]



Published by **Baishideng Publishing Group Inc**
7041 Koll Center Parkway, Suite 160, Pleasanton, CA 94566, USA

Telephone: +1-925-3991568

E-mail: bpgoffice@wjgnet.com

Help Desk: <https://www.f6publishing.com/helpdesk>

<https://www.wjgnet.com>

