

# World Journal of *Clinical Cases*

*World J Clin Cases* 2022 April 26; 10(12): 3639-3968



**EVIDENCE REVIEW**

- 3639** Tilt and decentration with various intraocular lenses: A narrative review  
*Chen XY, Wang YC, Zhao TY, Wang ZZ, Wang W*

**REVIEW**

- 3647** Role of zonula occludens in gastrointestinal and liver cancers  
*Ram AK, Vairappan B*

**MINIREVIEWS**

- 3662** Pathophysiological mechanisms of hepatic stellate cells activation in liver fibrosis  
*Garbuzenko DV*

**ORIGINAL ARTICLE****Retrospective Cohort Study**

- 3677** Predictors of unfavorable outcome at 90 days in basilar artery occlusion patients  
*Chiu YC, Yang JL, Wang WC, Huang HY, Chen WL, Yen PS, Tseng YL, Chen HH, Tsai ST*

**Retrospective Study**

- 3686** Role of multidetector computed tomography in patients with acute infectious colitis  
*Yu SJ, Heo JH, Choi EJ, Kim JH, Lee HS, Kim SY, Lim JH*
- 3698** Efficacy and prognostic factors of neoadjuvant chemotherapy for triple-negative breast cancer  
*Ding F, Chen RY, Hou J, Guo J, Dong TY*
- 3709** Relationship between subgroups of central and lateral lymph node metastasis in clinically node-negative papillary thyroid carcinoma  
*Zhou J, Li DX, Gao H, Su XL*
- 3720** Nomogram to predict postoperative complications in elderly with total hip replacement  
*Tan XJ, Gu XX, Ge FM, Li ZY, Zhang LQ*
- 3729** Flap failure prediction in microvascular tissue reconstruction using machine learning algorithms  
*Shi YC, Li J, Li SJ, Li ZP, Zhang HJ, Wu ZY, Wu ZY*
- Observational Study**
- 3739** Surgery in platinum-resistant recurrent epithelial ovarian carcinoma  
*Zhao LQ, Gao W, Zhang P, Zhang YL, Fang CY, Shou HF*

- 3754** Anorectal dysfunction in patients with mid-low rectal cancer after surgery: A pilot study with three-dimensional high-resolution manometry

Pi YN, Xiao Y, Wang ZF, Lin GL, Qiu HZ, Fang XC

#### Randomized Controlled Trial

- 3764** Effect of wrist-ankle acupuncture on propofol dosage during painless colonoscopy: A randomized controlled prospective study

He T, Liu C, Lu ZX, Kong LL, Li Y, Xu Z, Dong YJ, Hao W

#### META-ANALYSIS

- 3773** Melatonin intervention to prevent delirium in hospitalized patients: A meta-analysis

You W, Fan XY, Lei C, Nie CC, Chen Y, Wang XL

- 3787** Risk factors for hospital readmissions in pneumonia patients: A systematic review and meta-analysis

Fang YY, Ni JC, Wang Y, Yu JH, Fu LL

#### CASE REPORT

- 3801** Anti-programmed death 1 antibody in the treatment of coexistent *Mycobacterium fortuitum* and lung cancer: A case report

Zhang CC, Chen P

- 3808** Acute pancreatitis-induced thrombotic thrombocytopenic purpura: A case report

Wang CH, Jin HF, Liu WG, Guo Y, Liu Z

- 3814** Successful management of life-threatening aortoesophageal fistula: A case report and review of the literature

Zhong XQ, Li GX

- 3822** Isolated coagulopathy without classic CRAB symptoms as the initial manifestation of multiple myeloma: A case report

Zhang Y, Xu F, Wen JJ, Shi L, Zhou QL

- 3828** Evaluation of intracoronary function after reduction of ventricular rate by esmolol in severe stenotic myocardial bridge: A case report

Sun LJ, Yan DG, Huang SW

- 3834** Pediatric living donor liver transplantation using liver allograft after *ex vivo* backtable resection of hemangioma: A case report

Li SX, Tang HN, Lv GY, Chen X

- 3842** Kimura's disease in soft palate with clinical and histopathological presentation: A case report

Li W

- 3849** Combined targeted therapy and immunotherapy in anaplastic thyroid carcinoma with distant metastasis: A case report

Ma DX, Ding XP, Zhang C, Shi P

- 3856** Successful multimodality treatment of metastatic gallbladder cancer: A case report and review of literature  
*Zhang B, Li S, Liu ZY, Peiris KGK, Song LF, Liu MC, Luo P, Shang D, Bi W*
- 3866** Ischemic colitis after receiving the second dose of a COVID-19 inactivated vaccine: A case report  
*Cui MH, Hou XL, Liu JY*
- 3872** Cryoballoon pulmonary vein isolation and left atrial appendage occlusion prior to atrial septal defect closure: A case report  
*Wu YC, Wang MX, Chen GC, Ruan ZB, Zhang QQ*
- 3879** Surgical treatment for a combined anterior cruciate ligament and posterior cruciate ligament avulsion fracture: A case report  
*Yoshida K, Hakozaiki M, Kobayashi H, Kimura M, Konno S*
- 3886** Successful robot-assisted partial nephrectomy for giant renal hilum angiomyolipoma through the retroperitoneal approach: A case report  
*Luo SH, Zeng QS, Chen JX, Huang B, Wang ZR, Li WJ, Yang Y, Chen LW*
- 3893** Cryptococcal antigen testing of lung tissue homogenate improves pulmonary cryptococcosis diagnosis: Two case reports  
*Wang WY, Zheng YL, Jiang LB*
- 3899** Combined use of extracorporeal membrane oxygenation with interventional surgery for acute pancreatitis with pulmonary embolism: A case report  
*Yan LL, Jin XX, Yan XD, Peng JB, Li ZY, He BL*
- 3907** Dynamic navigation system-guided trans-inferior alveolar nerve implant placement in the atrophic posterior mandible: A case report  
*Chen LW, Zhao XE, Yan Q, Xia HB, Sun Q*
- 3916** Anti-glomerular basement membrane disease with IgA nephropathy: A case report  
*Guo C, Ye M, Li S, Zhu TT, Rao XR*
- 3923** Amniotic membrane transplantation in a patient with impending perforated corneal ulcer caused by *Streptococcus mitis*: A case report and review of literature  
*Hsiao FC, Meir YJJ, Yeh LK, Tan HY, Hsiao CH, Ma DHK, Wu WC, Chen HC*
- 3930** Steriod for Autoimmune pancreatitis complicating by gastric varices: A case report  
*Hao NB, Li X, Hu WW, Zhang D, Xie J, Wang XL, Li CZ*
- 3936** Antithrombotic treatment strategy for patients with coronary artery ectasia and acute myocardial infarction: A case report  
*Liu RF, Gao XY, Liang SW, Zhao HQ*
- 3944** Mesh plug erosion into the small intestine after inguinal hernia repair: A case report  
*Xie TH, Wang Q, Ha SN, Cheng SJ, Niu Z, Ren XX, Sun Q, Jin XS*
- 3951** Recurrence of infectious mononucleosis in adults after remission for 3 years: A case report  
*Zhang XY, Teng QB*

- 3959** Vertical direction impaction of kissing molars: A case report

*Wen C, Jiang R, Zhang ZQ, Lei B, Yan YZ, Zhong YQ, Tang L*

**LETTER TO THE EDITOR**

- 3966** Comment on “Outcomes of different minimally invasive surgical treatments for vertebral compression fractures: An observational study”

*Ma L, Luo ZW, Sun YY*

**ABOUT COVER**

Editorial Board Member of *World Journal of Clinical Cases*, Potluri Leela Ravishankar, MDS, Professor, Department of Periodontics, SRM Kattankulathur Dental College and Hospital, SRM University, Chennai 603203, Tamil Nadu, India. plrs6@yahoo.com

**AIMS AND SCOPE**

The primary aim of *World Journal of Clinical Cases* (WJCC, *World J Clin Cases*) is to provide scholars and readers from various fields of clinical medicine with a platform to publish high-quality clinical research articles and communicate their research findings online.

WJCC mainly publishes articles reporting research results and findings obtained in the field of clinical medicine and covering a wide range of topics, including case control studies, retrospective cohort studies, retrospective studies, clinical trials studies, observational studies, prospective studies, randomized controlled trials, randomized clinical trials, systematic reviews, meta-analysis, and case reports.

**INDEXING/ABSTRACTING**

The WJCC is now indexed in Science Citation Index Expanded (also known as SciSearch®), Journal Citation Reports/Science Edition, Scopus, PubMed, and PubMed Central. The 2021 Edition of Journal Citation Reports® cites the 2020 impact factor (IF) for WJCC as 1.337; IF without journal self cites: 1.301; 5-year IF: 1.742; Journal Citation Indicator: 0.33; Ranking: 119 among 169 journals in medicine, general and internal; and Quartile category: Q3. The WJCC's CiteScore for 2020 is 0.8 and Scopus CiteScore rank 2020: General Medicine is 493/793.

**RESPONSIBLE EDITORS FOR THIS ISSUE**

Production Editor: *Ying-Yi Yuan*, Production Department Director: *Xu Guo*, Editorial Office Director: *Jin-Lei Wang*.

**NAME OF JOURNAL**

*World Journal of Clinical Cases*

**ISSN**

ISSN 2307-8960 (online)

**LAUNCH DATE**

April 16, 2013

**FREQUENCY**

Thrice Monthly

**EDITORS-IN-CHIEF**

Bao-Gan Peng, Jerzy Tadeusz Chudek, George Kontogeorgos, Maurizio Serati, Ja Hyeon Ku

**EDITORIAL BOARD MEMBERS**

<https://www.wjgnet.com/2307-8960/editorialboard.htm>

**PUBLICATION DATE**

April 26, 2022

**COPYRIGHT**

© 2022 Baishideng Publishing Group Inc

**INSTRUCTIONS TO AUTHORS**

<https://www.wjgnet.com/bpg/gerinfo/204>

**GUIDELINES FOR ETHICS DOCUMENTS**

<https://www.wjgnet.com/bpg/GerInfo/287>

**GUIDELINES FOR NON-NATIVE SPEAKERS OF ENGLISH**

<https://www.wjgnet.com/bpg/gerinfo/240>

**PUBLICATION ETHICS**

<https://www.wjgnet.com/bpg/GerInfo/288>

**PUBLICATION MISCONDUCT**

<https://www.wjgnet.com/bpg/gerinfo/208>

**ARTICLE PROCESSING CHARGE**

<https://www.wjgnet.com/bpg/gerinfo/242>

**STEPS FOR SUBMITTING MANUSCRIPTS**

<https://www.wjgnet.com/bpg/GerInfo/239>

**ONLINE SUBMISSION**

<https://www.f6publishing.com>



## Ischemic colitis after receiving the second dose of a COVID-19 inactivated vaccine: A case report

Mei-Hua Cui, Xiao-Lin Hou, Jun-Yuan Liu

**Specialty type:** Gastroenterology and hepatology

**Provenance and peer review:** Unsolicited article; Externally peer reviewed.

**Peer-review model:** Single blind

**Peer-review report's scientific quality classification**

Grade A (Excellent): 0  
Grade B (Very good): 0  
Grade C (Good): C, C, C  
Grade D (Fair): 0  
Grade E (Poor): 0

**P-Reviewer:** Fan X, United States; Kumar A, India; Musoni L, Morocco

**Received:** August 16, 2021

**Peer-review started:** August 16, 2021

**First decision:** October 22, 2021

**Revised:** November 4, 2021

**Accepted:** March 6, 2022

**Article in press:** March 6, 2022

**Published online:** April 26, 2022



Mei-Hua Cui, Xiao-Lin Hou, Jun-Yuan Liu, Department of Gastroenterology, Aerospace Center Hospital, Beijing 100049, China

**Corresponding author:** Mei-Hua Cui, PhD, Doctor, Department of Gastroenterology, Aerospace Center Hospital, No. 15 Yuquan Road, Haidian District, Beijing 100049, China.  
[cuimeih@sina.com](mailto:cuimeih@sina.com)

### Abstract

#### BACKGROUND

The outbreak of the coronavirus disease 2019 (COVID-19) caused by the severe acute respiratory syndrome coronavirus 2 has been the most important clinical challenge worldwide since January 2020. COVID-19 inactivated vaccines play a crucial role in reducing the rates of morbidity and mortality.

#### CASE SUMMARY

We presented a 48-year-old woman from Haidian District, Beijing, China who developed ischemic colitis after receiving the second dose of COVID-19 inactivated vaccine. Computed tomography of the abdomen showed edema and bowel wall thickening with hypodensity in the sigmoid colon and descending colon. Colonoscopy revealed hyperemia, edema and erosion of the mucosa with superficial ulceration and a yellow-white coating at the descending colon and sigmoid colon. The symptoms were relieved after 1 wk of receiving pinaverium bromide (50 mg, tid) and aspirin enteric-coated tablets (0.1 g, qd).

#### CONCLUSION

The possible occurrence of ischemic colitis should be considered after administration of the COVID-19 inactivated vaccines.

**Key Words:** COVID-19; Vaccine; Ischemic colitis; Adverse event; Case report

©The Author(s) 2022. Published by Baishideng Publishing Group Inc. All rights reserved.

**Core Tip:** Coronavirus disease 2019 (COVID-19) inactivated vaccines play a crucial role in reducing the rates of morbidity and mortality. The adverse events after administration of inactivated vaccines are varied and need to be profoundly studied in clinical practice. This report described the relationship between the administration of the COVID-19 inactivated vaccine with ischemic colitis and its possible causes. The potential mechanism behind the development of ischemic colitis needs further exploration to better understand and manage unforeseen complications of COVID-19 inactivated vaccines.

**Citation:** Cui MH, Hou XL, Liu JY. Ischemic colitis after receiving the second dose of a COVID-19 inactivated vaccine: A case report. *World J Clin Cases* 2022; 10(12): 3866-3871

**URL:** <https://www.wjgnet.com/2307-8960/full/v10/i12/3866.htm>

**DOI:** <https://dx.doi.org/10.12998/wjcc.v10.i12.3866>

## INTRODUCTION

The outbreak of the coronavirus disease 2019 (COVID-19) caused by the severe acute respiratory syndrome coronavirus 2 (SARS-CoV-2) has been the most important clinical challenge worldwide since January 2020. While the spread of COVID-19 in China has been effectively controlled, the pandemic has not ceased. To date, COVID-19 has affected more than 128 million individuals causing over 2.8 million deaths worldwide[1]. The COVID-19 pandemic is globally considered as the primary health threat[2]. Although the mortality rate of COVID-19 is low, individuals with diabetes or hypertension are at a higher risk of mortality[3,4].

Individuals encountered a variety of mental health challenges during the COVID-19 pandemic[5]. Given the lack of a specific treatment strategy for COVID-19, the development of vaccines against COVID-19 is a milestone. To date, diverse types of vaccines for COVID-19 have been proposed including messenger RNA (mRNA), non-replicating and replicating vectors, inactivated viruses, protein subunits, viral-like particles, DNA vaccines and live attenuated vaccines[6-8]. Two inactivated vaccines, the China National Biotec Group SARS-CoV-2 vaccine and the CoronaVac vaccine (Sinovac Biotech Ltd., China) have been adopted for mass vaccination within mainland China. Although the inactivated vaccine is well-tolerated in the general population[9], some rare or serious adverse events may occur. We have attempted to present a case of ischemic colitis following the administration of an inactivated vaccine.

## CASE PRESENTATION

### Chief complaints

A 48-year-old woman from Haidian District, Beijing, China was admitted into the gastroenterology department due to abdominal pain accompanied by hematochezia for 1 d.

### History of present illness

The patient had received the second dose of the COVID-19 inactivated vaccine (4 ug/0.5 mL) in her deltoid muscle of the upper arm 1 d prior to her admission to our hospital and she did not experience any obvious discomfort during the injection. She experienced acute pain in the middle of her lower abdomen 1 h after the injection followed by 2 episodes of defecation characterized by small amounts of loose yellow stools. Subsequently, this was followed by more than 10 episodes of defecation characterized by small amounts of loose stools with hematochezia. These episodes were associated with fatigue. She did not present with nausea, vomiting, fever, dizziness or palpitations. The symptoms lasted for approximately 14 h before the appearance of abdominal pain and the hematochezia was gradually resolved spontaneously.

### History of past illness

The patient's diet history was normal and she did not experience adverse events after receiving the first dose of COVID-19 inactivated vaccine. A previous physical examination revealed that she had hyperlipidemia but she did not receive treatment and a normal bowel movement was noted.

### Personal and family history

There is no personal and family history.



### Physical examination

In addition to confirming a normal menstrual cycle, physical examination revealed the following outcomes: Body mass index (BMI) of 21.1 kg/m<sup>2</sup>; body temperature of 36.2°C; heart rate of 80 beats/min; respiratory rate of 19 breaths/min; and blood pressure of 140/85 mmHg. Upon undergoing abdominal examination, her abdomen was soft with tenderness in the left lower quadrant and no rebound pain or muscle tension. Upon undergoing digital rectal examination, there were no masses and no blood was found in the finger sleeve.

### Laboratory examinations

The results of hematological tests showed a normal C-reactive protein level, and the results of routine blood examination were as follows: D-dimer 329 ug/L; fibrinogen degradation product 2.5 mg/L; glucose 7.35 mmol/L; and lactic acid 2.60 mmol/L. The testing of nucleic acids, IgM and IgG showed negative results.

### Imaging examinations

Computed tomography of the abdomen showed edema and bowel wall thickening with hypodensity in the sigmoid colon and descending colon (Figure 1). Colonoscopy revealed hyperemia, edema and erosion of the mucosa with superficial ulceration and a yellow-white coating located at the descending colon and sigmoid colon (Figure 2).

---

## FINAL DIAGNOSIS

---

Based on the above-mentioned results, the patient was diagnosed with ischemic colitis.

---

## TREATMENT

---

The symptoms of the disease were relieved after admission to our hospital and the disease was in complete remission after administration of pinaverium bromide (50 mg, tid) and aspirin enteric-coated tablets (0.1 g, qd) for 1 wk.

---

## OUTCOME AND FOLLOW-UP

---

The patient did not present with abdominal pain or hematochezia and the frequency of defecation was once/day with soft yellow stool.

---

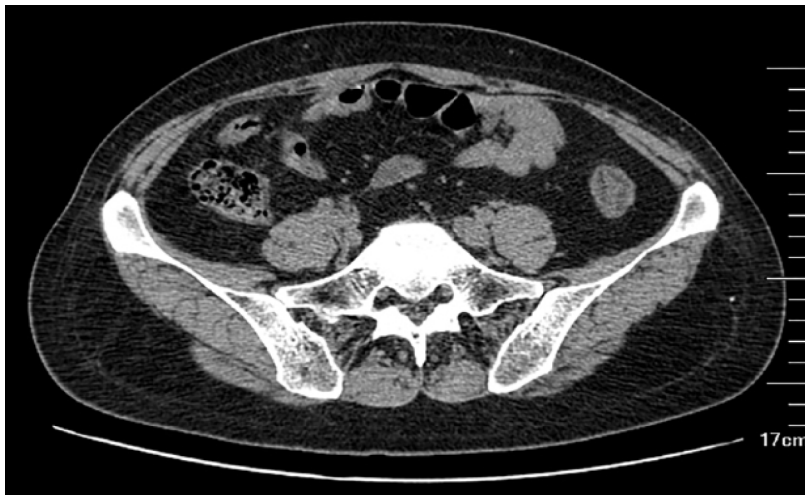## DISCUSSION

---

More than 24 million doses of the COVID-19 vaccines have been administered in China as of January 31, 2021[10]. As the safety profile of vaccines could affect vaccination acceptance, resulting in the control of the COVID-19 pandemic, it is imperative to report all suspected adverse events. The incidence of anaphylaxis following the administration of the COVID-19 inactivated vaccines was recently reported at nearly 1.4 cases per one million doses[11]. The present study found that recipients of the second dose of COVID-19 inactivated vaccines experienced ischemic colitis, indicating the necessity of clinicians' higher attention to vaccination in clinical practice.

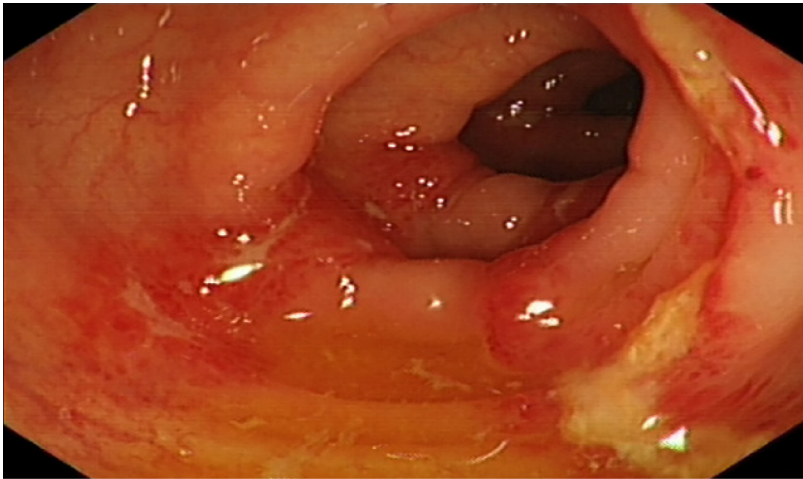
Two doses of inactivated vaccines against COVID-19 were reported to provide a highly effective defense against antibody-dependent infection which is associated with higher efficiency and genetic stability[12]. Several studies have addressed the safety of COVID-19 inactivated vaccines. For instance, Xia *et al*[13,15] performed an interim analysis of two randomized clinical trials and found the most common adverse events, including injection site pain and fever which was experienced within 7 d after the administration of the vaccine, and these adverse events were mild and self-limited. Zhang *et al*[14] conducted a phase 1/2 clinical trial on healthy adults who were aged 18-59-years-old, and reported that the most common adverse events encountered from days 1 to 14 included fatigue and injection-site pain. However, as a newly developed inactivated vaccine, its safety still needs to be verified in the general population through long-term follow-up and rare adverse events must be considered in clinical practice. The present study, for the first time, reported a woman who experienced ischemic colitis after administration of a second dose of the COVID-19 inactivated vaccine.

Hypercoagulable states impairing arterial blood supply to the colon potentially induced by the COVID-19 vaccine could be a potential cause of ischemic colitis[16]. Other risk factors for ischemic colitis include atherosclerosis, abdominal vascular disease and autoimmune disease which all can lead



DOI: 10.12998/wjcc.v10.i12.3866 Copyright ©The Author(s) 2022.

**Figure 1** Results of the computed tomography of the abdomen showing edema and bowel wall thickening with hypodensity in the sigmoid colon and descending colon.



DOI: 10.12998/wjcc.v10.i12.3866 Copyright ©The Author(s) 2022.

**Figure 2** Results of colonoscopy illustrating hyperemia, edema and erosion of the mucosa with superficial ulceration and a yellow-white coating located at the descending colon and sigmoid colon.

to reduced intestinal blood flow. These in turn may give rise to hypercoagulable states such as suffering from malignant tumors, portal hypertension, hematological disease, hypertension, coronary heart disease, diabetes, constipation, cardiogenic embolism, chronic obstructive pulmonary disease and abdominal surgery[17,18]. The medical history of the patient was normal except for a previous diagnosis of hyperlipidemia.

The onset time of ischemic colitis was closely correlated to the administration of the COVID-19 vaccines and a potential association could not be ruled out. Although the specific pathogenesis is elusive, the inflammation and immune reaction caused by vaccine administration could induce a hypercoagulable state. However, the levels of D-dimer and fibrinogen degradation product were normal which may be due to the acute onset of disease. Other inflammatory indices were normal as well. Increased intestinal peristalsis with sustained muscle contractions after vaccine administration could lead to the increase of intestinal pressure and vasospasm, in which the reduced blood volume due to frequent episodes of diarrhea could cause abdominal wall defects, mucosal ischemia, impaired metabolic function, acidosis, necrosis, gastric mucosal injury and bleeding[19].

Our patient received an inactivated vaccine which retained the immunogenicity of the virus without its pathogenic effect. Hence, although ischemic colitis can be induced by COVID-19, ischemic colitis in this patient might not be caused by SARS-CoV-2[20-22]. Studies have demonstrated that SARS-CoV-2 uses angiotensin-converting enzyme 2 (ACE2) receptor to facilitate viral entry into target cells. ACE-2 is expressed in pulmonary alveolar epithelial cells and throughout the gastrointestinal tract, including the colonic mucosa, thereby playing an important role in the development of ischemic colitis[23-25]. The

present episode was transient with rapidly resolving symptoms indicating a relatively benign prognosis. Therefore, the inactivated vaccine should be applied against COVID-19 owing to the extremely low incidence of ischemic colitis.

## CONCLUSION

This report described the temporal relationship between the administration of the COVID-19 inactivated vaccine with ischemic colitis and discussed its possible causes. The potential mechanism behind the development of ischemic colitis in the present case remained obscure and further evaluation is required to understand and manage unforeseen complications of COVID-19 inactivated vaccines. Patients with abdominal pain accompanied by hematochezia at 1 d after administration of COVID-19 inactivated vaccines should be cautiously managed in clinical practice.

## FOOTNOTES

**Author contributions:** Cui MH conceived and designed the case report, analyzed the data and wrote the manuscript; Hou XL participated in discussion and analysis of the case; Liu JY performed the literature review; All the authors read and approved the final version of this manuscript.

**Informed consent statement:** Written informed consent was obtained from the patient for publication of this case report and accompanying images.

**Conflict-of-interest statement:** The authors declare that they have no conflict of interest.

**CARE Checklist (2016) statement:** The authors have read the CARE Checklist (2016), and the manuscript was prepared and revised according to the CARE Checklist (2016).

**Open-Access:** This article is an open-access article that was selected by an in-house editor and fully peer-reviewed by external reviewers. It is distributed in accordance with the Creative Commons Attribution NonCommercial (CC BY-NC 4.0) license, which permits others to distribute, remix, adapt, build upon this work non-commercially, and license their derivative works on different terms, provided the original work is properly cited and the use is non-commercial. See: <https://creativecommons.org/licenses/by-nc/4.0/>

**Country/Territory of origin:** China

**ORCID number:** Mei-Hua Cui 0000-0001-8707-3031; Xiao-Lin Hou 0000-0002-6729-7481; Jun-Yuan Liu 0000-0002-3594-0444.

**S-Editor:** Wu YXJ

**L-Editor:** Filipodia

**P-Editor:** Wu YXJ

## REFERENCES

- 1 **World Health Organization.** WHO coronavirus disease (COVID-19) dashboard. [cited March 2021]. Available from: <https://covid19.who.int/>
- 2 **Sun J,** He WT, Wang L, Lai A, Ji X, Zhai X, Li G, Suchard MA, Tian J, Zhou J, Veit M, Su S. COVID-19: Epidemiology, Evolution, and Cross-Disciplinary Perspectives. *Trends Mol Med* 2020; **26**: 483-495 [PMID: 32359479 DOI: 10.1016/j.molmed.2020.02.008]
- 3 **Guan WJ,** Ni ZY, Hu Y, Liang WH, Ou CQ, He JX, Liu L, Shan H, Lei CL, Hui DSC, Du B, Li LJ, Zeng G, Yuen KY, Chen RC, Tang CL, Wang T, Chen PY, Xiang J, Li SY, Wang JL, Liang ZJ, Peng YX, Wei L, Liu Y, Hu YH, Peng P, Wang JM, Liu JY, Chen Z, Li G, Zheng ZJ, Qiu SQ, Luo J, Ye CJ, Zhu SY, Zhong NS; China Medical Treatment Expert Group for Covid-19. Clinical Characteristics of Coronavirus Disease 2019 in China. *N Engl J Med* 2020; **382**: 1708-1720 [PMID: 32109013 DOI: 10.1056/NEJMoa2002032]
- 4 **Fang L,** Karakiulakis G, Roth M. Are patients with hypertension and diabetes mellitus at increased risk for COVID-19 infection? *Lancet Respir Med* 2020; **8**: e21 [PMID: 32171062 DOI: 10.1016/S2213-2600(20)30116-8]
- 5 **Meo SA,** Abukhalaf AA, Alomar AA, Sattar K, Klonoff DC. COVID-19 Pandemic: Impact of Quarantine on Medical Students' Mental Wellbeing and Learning Behaviors. *Pak J Med Sci* 2020; **36**: S43-S48 [PMID: 32582313 DOI: 10.12669/pjms.36.COVID19-S4.2809]
- 6 **Romero JR,** Bernstein HH. COVID-19 Vaccines: A Primer for Clinicians. *Pediatr Ann* 2020; **49**: e532-e536 [PMID: 33290571 DOI: 10.3928/19382359-20201116-01]
- 7 **Sharma O,** Sultan AA, Ding H, Trigg CR. A Review of the Progress and Challenges of Developing a Vaccine for COVID-19. *Front Immunol* 2020; **11**: 585354 [PMID: 33163000 DOI: 10.3389/fimmu.2020.585354]

- 8 **Korang SK**, Juul S, Nielsen EE, Feinberg J, Siddiqui F, Ong G, Klingenberg S, Veroniki AA, Bu F, Thabane L, Thomsen AR, Jakobsen JC, Gluud C. Vaccines to prevent COVID-19: a protocol for a living systematic review with network meta-analysis including individual patient data (The LIVING VACCINE Project). *Syst Rev* 2020; **9**: 262 [PMID: [33218366](#) DOI: [10.1186/s13643-020-01516-1](#)]
- 9 **Haque A**, Pant AB. Efforts at COVID-19 Vaccine Development: Challenges and Successes. *Vaccines (Basel)* 2020; **8** [PMID: [33291245](#) DOI: [10.3390/vaccines8040739](#)]
- 10 The Cumulative Vaccination of SARS-CoV-2 Vaccines in China Has Exceeded 24 Million Doses. Available from: <https://news.cctv.com/2021/01/31/ARTIQJMVtbU2HQJUrSS5DIsJY210131.shtml>.
- 11 **McNeil MM**, Weintraub ES, Duffy J, Sukumaran L, Jacobsen SJ, Klein NP, Hambidge SJ, Lee GM, Jackson LA, Irving SA, King JP, Kharbanda EO, Bednarczyk RA, DeStefano F. Risk of anaphylaxis after vaccination in children and adults. *J Allergy Clin Immunol* 2016; **137**: 868-878 [PMID: [26452420](#) DOI: [10.1016/j.jaci.2015.07.048](#)]
- 12 **Wang H**, Zhang Y, Huang B, Deng W, Quan Y, Wang W, Xu W, Zhao Y, Li N, Zhang J, Liang H, Bao L, Xu Y, Ding L, Zhou W, Gao H, Liu J, Niu P, Zhao L, Zhen W, Fu H, Yu S, Zhang Z, Xu G, Li C, Lou Z, Xu M, Qin C, Wu G, Gao GF, Tan W, Yang X. Development of an Inactivated Vaccine Candidate, BBIBP-CorV, with Potent Protection against SARS-CoV-2. *Cell* 2020; **182**: 713-721.e9 [PMID: [32778225](#) DOI: [10.1016/j.cell.2020.06.008](#)]
- 13 **Xia S**, Duan K, Zhang Y, Zhao D, Zhang H, Xie Z, Li X, Peng C, Zhang W, Yang Y, Chen W, Gao X, You W, Wang X, Wang Z, Shi Z, Wang Y, Yang X, Zhang L, Huang L, Wang Q, Lu J, Guo J, Zhou W, Wan X, Wu C, Wang W, Huang S, Du J, Meng Z, Pan A, Yuan Z, Shen S, Guo W. Effect of an Inactivated Vaccine Against SARS-CoV-2 on Safety and Immunogenicity Outcomes: Interim Analysis of 2 Randomized Clinical Trials. *JAMA* 2020; **324**: 951-960 [PMID: [32789505](#) DOI: [10.1001/jama.2020.15543](#)]
- 14 **Zhang Y**, Zeng G, Pan H, Li C, Hu Y, Chu K, Han W, Chen Z, Tang R, Yin W, Chen X, Liu X, Jiang C, Li J, Yang M, Song Y, Wang X, Gao Q, Zhu F. Safety, tolerability, and immunogenicity of an inactivated SARS-CoV-2 vaccine in healthy adults aged 18-59 years: a randomised, double-blind, placebo-controlled, phase 1/2 clinical trial. *Lancet Infect Dis* 2021; **21**: 181-192 [PMID: [33217362](#) DOI: [10.1016/S1473-3099\(20\)30843-4](#)]
- 15 **Xia S**, Zhang Y, Wang Y, Wang H, Yang Y, Gao GF, Tan W, Wu G, Xu M, Lou Z, Huang W, Xu W, Huang B, Wang W, Zhang W, Li N, Xie Z, Ding L, You W, Zhao Y, Yang X, Liu Y, Wang Q, Huang L, Xu G, Luo B, Liu P, Guo W. Safety and immunogenicity of an inactivated SARS-CoV-2 vaccine, BBIBP-CorV: a randomised, double-blind, placebo-controlled, phase 1/2 trial. *Lancet Infect Dis* 2021; **21**: 39-51 [PMID: [33069281](#) DOI: [10.1016/S1473-3099\(20\)30831-8](#)]
- 16 **Tsimperidis AG**, Kapsoritakis AN, Linardou IA, Psychos AK, Papageorgiou AA, Vamvakopoulos NC, Kyriakou DS, Potamianos SP. The role of hypercoagulability in ischemic colitis. *Scand J Gastroenterol* 2015; **50**: 848-855 [PMID: [25656775](#) DOI: [10.3109/00365521.2015.1010568](#)]
- 17 **Midian-Singh R**, Polen A, Durishin C, Crock RD, Whittier FC, Fahmy N. Ischemic colitis revisited: a prospective study identifying hypercoagulability as a risk factor. *South Med J* 2004; **97**: 120-123 [PMID: [14982257](#) DOI: [10.1097/01.SMJ.0000066655.54770.88](#)]
- 18 **Twohig PA**, Desai A, Skeans J, Waghay N. Quantifying risk factors for ischemic colitis: A nationwide, retrospective cohort study. *Indian J Gastroenterol* 2020; **39**: 398-404 [PMID: [32797386](#) DOI: [10.1007/s12664-020-01049-4](#)]
- 19 **Yngvadottir Y**, Karlsdottir BR, Hreinsson JP, Ragnarsson G, Mitev RUM, Jonasson JG, Möller PH, Björnsson ES. The incidence and outcome of ischemic colitis in a population-based setting. *Scand J Gastroenterol* 2017; **52**: 704-710 [PMID: [28276832](#) DOI: [10.1080/00365521.2017.1291718](#)]
- 20 **Chan KH**, Lim SL, Damati A, Maruboyina SP, Bondili L, Abu Hanoud A, Slim J. Coronavirus disease 2019 (COVID-19) and ischemic colitis: An under-recognized complication. *Am J Emerg Med* 2020; **38**: 2758.e1-2758.e4 [PMID: [32499176](#) DOI: [10.1016/j.ajem.2020.05.072](#)]
- 21 **Paul T**, Joy AR, Alsoub HARS, Parambil JV. Case Report: Ischemic Colitis in Severe COVID-19 Pneumonia: An Unforeseen Gastrointestinal Complication. *Am J Trop Med Hyg* 2021; **104**: 63-65 [PMID: [33146121](#) DOI: [10.4269/ajtmh.20-1262](#)]
- 22 **González Lázaro P**, Lomas Meneses A, Del Val Zaballos F, Morandeira Rivas A. Ischemic colitis and short bowel disease due to coronavirus disease 2019 (COVID 19). *Clin Nutr ESPEN* 2020; **40**: 406-407 [PMID: [33183570](#) DOI: [10.1016/j.clnesp.2020.08.009](#)]
- 23 **Li W**, Moore MJ, Vasilieva N, Sui J, Wong SK, Berne MA, Somasundaran M, Sullivan JL, Luzuriaga K, Greenough TC, Choe H, Farzan M. Angiotensin-converting enzyme 2 is a functional receptor for the SARS coronavirus. *Nature* 2003; **426**: 450-454 [PMID: [14647384](#) DOI: [10.1038/nature02145](#)]
- 24 **Hamming I**, Timens W, Bulthuis ML, Lely AT, Navis G, van Goor H. Tissue distribution of ACE2 protein, the functional receptor for SARS coronavirus. A first step in understanding SARS pathogenesis. *J Pathol* 2004; **203**: 631-637 [PMID: [15141377](#) DOI: [10.1002/path.1570](#)]
- 25 **Xiao F**, Tang M, Zheng X, Liu Y, Li X, Shan H. Evidence for Gastrointestinal Infection of SARS-CoV-2. *Gastroenterology* 2020; **158**: 1831-1833.e3 [PMID: [32142773](#) DOI: [10.1053/j.gastro.2020.02.055](#)]



Published by **Baishideng Publishing Group Inc**  
7041 Koll Center Parkway, Suite 160, Pleasanton, CA 94566, USA

**Telephone:** +1-925-3991568

**E-mail:** [bpgoffice@wjgnet.com](mailto:bpgoffice@wjgnet.com)

**Help Desk:** <https://www.f6publishing.com/helpdesk>

<https://www.wjgnet.com>

