

World Journal of *Clinical Cases*

World J Clin Cases 2022 May 6; 10(13): 3969-4326



Contents

Thrice Monthly Volume 10 Number 13 May 6, 2022

REVIEW

- 3969** COVID-19 and liver diseases, what we know so far
Elnaggar M, Abomhaya A, Elkhattib I, Dawoud N, Doshi R

MINIREVIEWS

- 3981** Amputation stump management: A narrative review
Choo YJ, Kim DH, Chang MC

ORIGINAL ARTICLE

Clinical and Translational Research

- 3989** Solute carrier family 2 members 1 and 2 as prognostic biomarkers in hepatocellular carcinoma associated with immune infiltration
Peng Q, Hao LY, Guo YL, Zhang ZQ, Ji JM, Xue Y, Liu YW, Lu JL, Li CG, Shi XL

Retrospective Cohort Study

- 4020** Role of clinical data and multidetector computed tomography findings in acute superior mesenteric artery embolism
Yang JS, Xu ZY, Chen FX, Wang MR, Cong RC, Fan XL, He BS, Xing W

Retrospective Study

- 4033** Effect of calcium supplementation on severe hypocalcemia in patients with secondary hyperparathyroidism after total parathyroidectomy
Liu J, Fan XF, Yang M, Huang LP, Zhang L
- 4042** Comparison of clinical efficacy and postoperative inflammatory response between laparoscopic and open radical resection of colorectal cancer
He LH, Yang B, Su XQ, Zhou Y, Zhang Z
- 4050** Three-dimensional echocardiographic assessment of left ventricular volume in different heart diseases using a fully automated quantification software
Pan CK, Zhao BW, Zhang XX, Pan M, Mao YK, Yang Y
- 4064** Clinical effect of ultrasound-guided nerve block and dexmedetomidine anesthesia on lower extremity operative fracture reduction
Ao CB, Wu PL, Shao L, Yu JY, Wu WG
- 4072** Correlation between thrombopoietin and inflammatory factors, platelet indices, and thrombosis in patients with sepsis: A retrospective study
Xu WH, Mo LC, Shi MH, Rao H, Zhan XY, Yang M

Observational Study

- 4084** High plasma CD40 ligand level is associated with more advanced stages and worse prognosis in colorectal cancer

Herold Z, Herold M, Herczeg G, Fodor A, Szasz AM, Dank M, Somogyi A

- 4097** Metabolic dysfunction is associated with steatosis but no other histologic features in nonalcoholic fatty liver disease

Dai YN, Xu CF, Pan HY, Huang HJ, Chen MJ, Li YM, Yu CH

Randomized Controlled Trial

- 4110** Effect of Xuebijing injection on myocardium during cardiopulmonary bypass: A prospective, randomized, double blind trial

Jin ZH, Zhao XQ, Sun HB, Zhu JL, Gao W

META-ANALYSIS

- 4119** Perioperative respiratory muscle training improves respiratory muscle strength and physical activity of patients receiving lung surgery: A meta-analysis

Yang MX, Wang J, Zhang X, Luo ZR, Yu PM

CASE REPORT

- 4131** Delayed diffuse lamellar keratitis after small-incision lenticule extraction related to immunoglobulin A nephropathy: A case report

Dan TT, Liu TX, Liao YL, Li ZZ

- 4137** Large vessel vasculitis with rare presentation of acute rhabdomyolysis: A case report and review of literature

Fu LJ, Hu SC, Zhang W, Ye LQ, Chen HB, Xiang XJ

- 4145** Primitive neuroectodermal tumor of the prostate in a 58-year-old man: A case report

Tian DW, Wang XC, Zhang H, Tan Y

- 4153** Bilateral superficial cervical plexus block for parathyroidectomy during pregnancy: A case report

Chung JY, Lee YS, Pyeon SY, Han SA, Huh H

- 4161** Primary myelofibrosis with thrombophilia as first symptom combined with thalassemia and Gilbert syndrome: A case report

Wufuer G, Wufuer K, Ba T, Cui T, Tao L, Fu L, Mao M, Duan MH

- 4171** Late contralateral recurrence of retinal detachment in incontinentia pigmenti: A case report

Cai YR, Liang Y, Zhong X

- 4177** Pregnancy and delivery after augmentation cystoplasty: A case report and review of literature

Ruan J, Zhang L, Duan MF, Luo DY

- 4185** Acute pancreatitis as a rare complication of gastrointestinal endoscopy: A case report

Dai MG, Li LF, Cheng HY, Wang JB, Ye B, He FY

- 4190** Paraneoplastic neurological syndrome with positive anti-Hu and anti-Yo antibodies: A case report
Li ZC, Cai HB, Fan ZZ, Zhai XB, Ge ZM
- 4196** Primary pulmonary meningioma: A case report and review of the literature
Zhang DB, Chen T
- 4207** Anesthesia of a patient with congenital cataract, facial dysmorphism, and neuropathy syndrome for posterior scoliosis: A case report
Hudec J, Kosinova M, Prokopova T, Filipovic M, Repko M, Stourac P
- 4214** Extensive myocardial calcification in critically ill patients receiving extracorporeal membrane oxygenation: A case report
Sui ML, Wu CJ, Yang YD, Xia DM, Xu TJ, Tang WB
- 4220** Trigeminal extracranial thermocoagulation along with patient-controlled analgesia with esketamine for refractory postherpetic neuralgia after herpes zoster ophthalmicus: A case report
Tao JC, Huang B, Luo G, Zhang ZQ, Xin BY, Yao M
- 4226** Thrombotic pulmonary embolism of inferior vena cava during caesarean section: A case report and review of the literature
Jiang L, Liang WX, Yan Y, Wang SP, Dai L, Chen DJ
- 4236** EchoNavigator virtual marker and Agilis NxT steerable introducer facilitate transseptal transcatheter closure of mitral paravalvular leak
Hsu JC, Khoi CS, Huang SH, Chang YY, Chen SL, Wu YW
- 4242** Primary isolated central nervous system acute lymphoblastic leukemia with *BCR-ABL1* rearrangement: A case report
Chen Y, Lu QY, Lu JY, Hong XL
- 4249** Coexistence of meningioma and other intracranial benign tumors in non-neurofibromatosis type 2 patients: A case report and review of literature
Hu TH, Wang R, Wang HY, Song YF, Yu JH, Wang ZX, Duan YZ, Liu T, Han S
- 4264** Treatment of condylar osteophyte in temporomandibular joint osteoarthritis with muscle balance occlusal splint and long-term follow-up: A case report
Lan KW, Chen JM, Jiang LL, Feng YF, Yan Y
- 4273** Hepatic perivascular epithelioid cell tumor: A case report
Li YF, Wang L, Xie YJ
- 4280** Multiple stress fractures of unilateral femur: A case report
Tang MT, Liu CF, Liu JL, Saijilafu, Wang Z
- 4288** Enigmatic rapid organization of subdural hematoma in a patient with epilepsy: A case report
Lv HT, Zhang LY, Wang XT

- 4294** Spinal canal decompression for hypertrophic neuropathy of the cauda equina with chronic inflammatory demyelinating polyradiculoneuropathy: A case report
Ye L, Yu W, Liang NZ, Sun Y, Duan LF
- 4301** Primary intracranial extraskeletal myxoid chondrosarcoma: A case report and review of literature
Zhu ZY, Wang YB, Li HY, Wu XM
- 4314** Mass brain tissue lost after decompressive craniectomy: A case report
Li GG, Zhang ZQ, Mi YH

LETTER TO THE EDITOR

- 4321** Improving outcomes in geriatric surgery: Is there more to the equation?
Goh SSN, Chia CL
- 4324** Capillary leak syndrome: A rare cause of acute respiratory distress syndrome
Juneja D, Kataria S

ABOUT COVER

Editorial Board Member of *World Journal of Clinical Cases*, Kai Zhang, PhD, Professor, Department of Psychiatry, Chaohu Hospital of Anhui Medical University, Hefei 238000, Anhui Province, China. zhangkai@ahmu.edu.cn

AIMS AND SCOPE

The primary aim of *World Journal of Clinical Cases* (WJCC, *World J Clin Cases*) is to provide scholars and readers from various fields of clinical medicine with a platform to publish high-quality clinical research articles and communicate their research findings online.

WJCC mainly publishes articles reporting research results and findings obtained in the field of clinical medicine and covering a wide range of topics, including case control studies, retrospective cohort studies, retrospective studies, clinical trials studies, observational studies, prospective studies, randomized controlled trials, randomized clinical trials, systematic reviews, meta-analysis, and case reports.

INDEXING/ABSTRACTING

The WJCC is now indexed in Science Citation Index Expanded (also known as SciSearch®), Journal Citation Reports/Science Edition, Scopus, PubMed, and PubMed Central. The 2021 Edition of Journal Citation Reports® cites the 2020 impact factor (IF) for WJCC as 1.337; IF without journal self cites: 1.301; 5-year IF: 1.742; Journal Citation Indicator: 0.33; Ranking: 119 among 169 journals in medicine, general and internal; and Quartile category: Q3. The WJCC's CiteScore for 2020 is 0.8 and Scopus CiteScore rank 2020: General Medicine is 493/793.

RESPONSIBLE EDITORS FOR THIS ISSUE

Production Editor: Xu Guo; Production Department Director: Xiang Li; Editorial Office Director: Jin-Lei Wang.

NAME OF JOURNAL

World Journal of Clinical Cases

ISSN

ISSN 2307-8960 (online)

LAUNCH DATE

April 16, 2013

FREQUENCY

Thrice Monthly

EDITORS-IN-CHIEF

Bao-Gan Peng, Jerzy Tadeusz Chudek, George Kontogeorgos, Maurizio Serati, Ja Hyeon Ku

EDITORIAL BOARD MEMBERS

<https://www.wjgnet.com/2307-8960/editorialboard.htm>

PUBLICATION DATE

May 6, 2022

COPYRIGHT

© 2022 Baishideng Publishing Group Inc

INSTRUCTIONS TO AUTHORS

<https://www.wjgnet.com/bpg/gerinfo/204>

GUIDELINES FOR ETHICS DOCUMENTS

<https://www.wjgnet.com/bpg/GerInfo/287>

GUIDELINES FOR NON-NATIVE SPEAKERS OF ENGLISH

<https://www.wjgnet.com/bpg/gerinfo/240>

PUBLICATION ETHICS

<https://www.wjgnet.com/bpg/GerInfo/288>

PUBLICATION MISCONDUCT

<https://www.wjgnet.com/bpg/gerinfo/208>

ARTICLE PROCESSING CHARGE

<https://www.wjgnet.com/bpg/gerinfo/242>

STEPS FOR SUBMITTING MANUSCRIPTS

<https://www.wjgnet.com/bpg/GerInfo/239>

ONLINE SUBMISSION

<https://www.f6publishing.com>



Spinal canal decompression for hypertrophic neuropathy of the cauda equina with chronic inflammatory demyelinating polyradiculoneuropathy: A case report

Lei Ye, Wei Yu, Nai-Zheng Liang, Ying Sun, Li-Fen Duan

Specialty type: Pediatrics

Provenance and peer review:

Unsolicited article; Externally peer reviewed.

Peer-review model: Single blind

Peer-review report's scientific quality classification

Grade A (Excellent): 0
Grade B (Very good): B, B
Grade C (Good): C
Grade D (Fair): 0
Grade E (Poor): 0

P-Reviewer: Al-Ani RM, Iraq;
Ojukwu DI, United States

Received: November 20, 2021

Peer-review started: November 20, 2021

First decision: December 27, 2021

Revised: January 5, 2022

Accepted: March 7, 2022

Article in press: March 7, 2022

Published online: May 6, 2022



Lei Ye, Wei Yu, Nai-Zheng Liang, Department of Neurosurgery, The Kunming Children's Hospital, Kunming 650100, Yunnan Province, China

Ying Sun, Li-Fen Duan, Department of Epilepsy, The Kunming Children's Hospital, Kunming 650100, Yunnan Province, China

Corresponding author: Li-Fen Duan, MD, Doctor, Department of Epilepsy, The Kunming Children's Hospital, No. 288 Qianxing Road, Xishan District, Kunming 650100, Yunnan Province, China. duanlifeng@etny.cn

Abstract

BACKGROUND

Hypertrophic neuropathy of the cauda equina (HNCE) is a rare disease, especially in children. It can be caused by different etiological agents such as inflammation, tumor or hereditary factors. Currently, there is no uniform standard for clinical treatment of HNCE. Furthermore, it is unclear whether spinal canal decompression is beneficial for patients with HNCE.

CASE SUMMARY

We report the case of a 13-year-old boy with enlargement of the cauda equina. The onset of the disease began at the age of 6 years and was initially marked by radiating pain in the buttocks and thighs after leaning over and weakness in the lower limbs when climbing a ladder. The child did not receive any medical treatment. As the disease slowly progressed, the child needed the help of others to walk, and he had a trendelenburg gait. He underwent spinal canal decompression and a nerve biopsy during his hospital stay. A diagnosis of chronic inflammatory demyelinating polyradiculoneuropathy was made based on electrophysiological findings and pathological examination results. Immunoglobulin or hormone therapy was recommended during hospitalization, but his mother refused. After discharge, the boy's mother helped him carry out postoperative rehabilitation training at home. His lower-limb muscle strength gradually increased, and he could stand upright and take steps. Six mo after surgery, the child was readmitted and began immunoglobulin therapy. Long-term oral steroid treatment was initiated after discharge. The movement and sensation of the lower limbs were further improved, and the boy could walk normally 1 year after surgery.

CONCLUSION

Spinal canal decompression can improve the clinical symptoms of HNCE caused by inflammation, even in children. When combined with specific etiological interventions, spinal cord decompression can lead to optimal outcomes.

Key Words: Child; Cauda equina; Polyradiculoneuropathy; Chronic inflammatory demyelinating polyradiculoneuropathy; Laminectomy; Case report

©The Author(s) 2022. Published by Baishideng Publishing Group Inc. All rights reserved.

Core Tip: The rare case reported here thoroughly illustrates that chronic inflammatory demyelinating polyradiculoneuropathy can result in hypertrophic neuropathy of the cauda equina (HNCE) in children. This case provides new insights into the management of childhood chronic inflammatory demyelinating polyradiculoneuropathy. We demonstrated that laminectomy, followed by adjunct therapy, is a safe and effective treatment of HNCE. At the same time, etiological diagnosis is very important.

Citation: Ye L, Yu W, Liang NZ, Sun Y, Duan LF. Spinal canal decompression for hypertrophic neuropathy of the cauda equina with chronic inflammatory demyelinating polyradiculoneuropathy: A case report. *World J Clin Cases* 2022; 10(13): 4294-4300

URL: <https://www.wjgnet.com/2307-8960/full/v10/i13/4294.htm>

DOI: <https://dx.doi.org/10.12998/wjcc.v10.i13.4294>

INTRODUCTION

Hypertrophic neuropathy (HN) is very uncommon in clinical settings and has been described as a form of hereditary motor and sensory neuropathy or acquired demyelination neuropathy in the literature[1]. It can be characterized as a chronic progressive clinical process that mainly affects the peripheral nerve. HN involving the whole cauda equina is even more uncommon and is exceedingly rarely reported in children. There is no uniform standard for clinical treatment of HN of the cauda equina. We report a case of childhood-onset HN of the cauda equina caused by chronic inflammatory demyelinating polyradiculoneuropathy (CIDP).

CASE PRESENTATION

Chief complaints

A 13-year-old Asian boy presented to our facility with reduced muscular strength of both lower limbs, abnormalities in gait, and paresthesia.

History of present illness

The patient had shown progressive reduced muscular strength of both lower limbs, abnormalities in gait, and paresthesia from 6 years old. He initially presented with radiating pain in the buttocks and thighs after bending over and weakness in both lower limbs when climbing steps. Intermittent symptoms gradually developed into a persistent decline in muscle strength of the lower limbs (particularly in the distal lower extremities) and gait instability.

History of past illness

There was no associated history of trauma.

Personal and family history

There was no inherited disorders in the patient's family history.

Physical examination

The patient's level of consciousness, neurological physical examination, and upper limb activities were within normal limits. The muscle strength of both lower extremities was grade IV. The patient needed the help of others to walk, and he had a trendelenburg gait. He had numbness after acupuncture below the hip, and hypoalgesia and hypoesthesia were more obvious in the distal extremities. Additional presentation symptoms included bilateral abolished tendon reflexes, extension contracture of the ankles, and restricted toe movement. Other symptoms such as pathological reflexes, incontinence, scoliosis,

atrophy of the muscles of the lower extremities, and rashes were not noted.

Laboratory examinations

Examination of the cerebrospinal fluid (CSF) revealed normal cell numbers. The patient's CSF protein level was 0.55 g/L (reference range 0.1-0.4 g/L).

Imaging examinations

Magnetic resonance imaging (MRI) of the lumbosacral spine was performed 7 years after symptom onset. The patient underwent MRI with T1- and T2-weighted imaging and T1-contrast-enhanced sequences. Findings demonstrated that diffuse thickening of the cauda equina nerve roots filled the entire spinal canal, even extending to the intervertebral foramen and the paravertebral space (Figure 1). The cauda equina nerve roots also showed a low T1 signal and a slightly higher T2 signal, with mild enhancement. Brain MRI findings were within normal limits.

Further diagnostic work-up

Electrophysiological testing demonstrated that nerve conduction velocity in both lower limbs was decreased. The compound muscle action potential of the femoral nerve, tibial nerve, common peroneal nerve, the sensory nerve action potential, and the F wave were not detected. When multiple lower-limb muscles were lightly contracted, electromyography showed increased motor unit potentials (MUP), long-duration MUP, and increased polyphasic potentials.

Whole-exome sequencing was performed on deoxyribonucleic acid extracted from the patient's peripheral blood, with no disease-causing variant identified.

Neuropathological examination demonstrated a remarkable reduction in the density of myelinated fibers and hyperplasia of the schwann cells, forming onion bulb wrappings of myelinated fibers and blood vessels, and a small population of perivascular macrophages. In addition, immunohistochemical analysis showed positivity for the S-100 protein antibody and negativity for epithelial membrane antigen (EMA) (Figure 2).

FINAL DIAGNOSIS

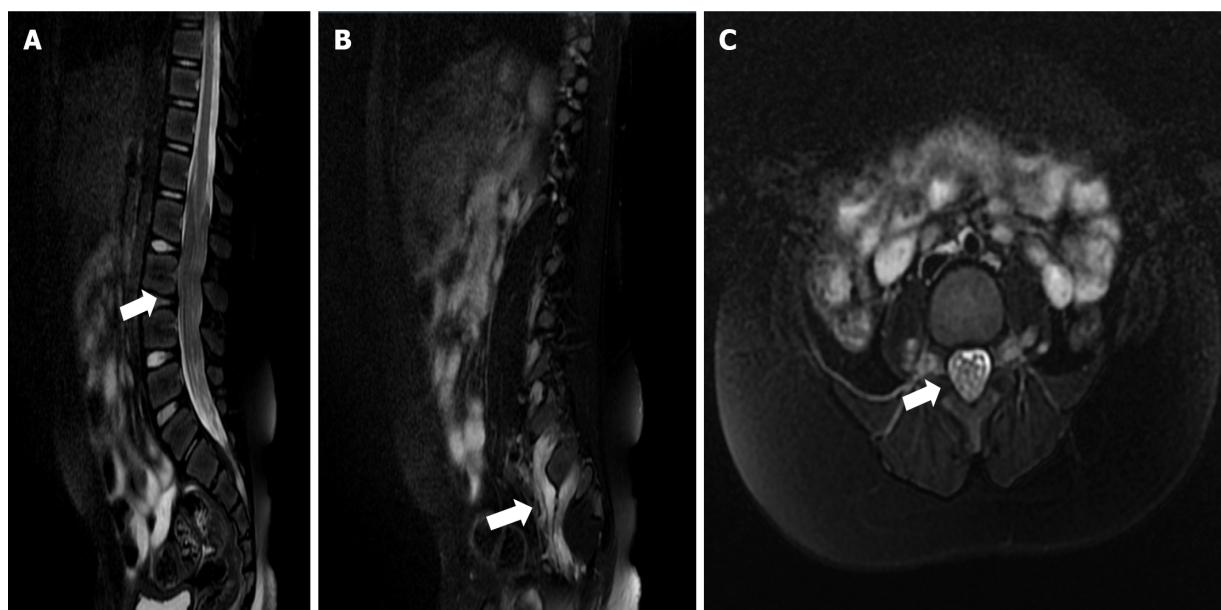
Based on the combination of findings, CIDP was finally diagnosed.

TREATMENT

With the consent of his parents, the child underwent spinal canal decompression at vertebrae L1-L5 and biopsy of a nerve root of the cauda equina. The surgical procedure was performed with intraoperative neuromonitoring (motor and somatosensory evoked potentials). The bilateral tibialis anterior muscles, quadriceps femoris, gastrocnemius, and sphincter were selected for electromyography. The spinal dural sac was expanded, the local pressure of the spinal dural sac was increased, and the cauda equina nerve roots were hypertrophic and extruding from the spinal dural opening (Figure 3). A cauda equina nerve root that did not elicit a motor response was selected through nerve stimulation and was surgically resected for pathological examination. We enlarged the spinal dural sac and removed the spinous processes and laminae of L1-L5. The patient recovered well after surgery, and no surgical complications occurred. Early postoperative neurological function remained stable. Immunotherapy and hormone therapy were recommended for the patient, however, his family refused them.

OUTCOME AND FOLLOW-UP

When the patient returned for a follow-up visit 6 mo after the surgery, he could limp, and his walking posture had improved, however, he still complained of numbness in the distal lower limbs. He was re-admitted and administered intravenous immunoglobulin treatment at 6 mo post-surgery, and long-term oral steroid treatment was initiated after discharge. Oral prednisone was initially prescribed at 1 mg/kg/d. After 2 mo, the dosage was gradually reduced to 5 mg/kg/d with 2 wk intervals between doses. The patient continued maintenance therapy using prednisone (10 mg/d) for 1 year. Liver and kidney function and electrolytes were examined regularly during prednisone treatment, but no abnormal results were found. The symptoms further improved by the follow-up visit 1 year after the operation, including near-normal muscle strength of both lower limbs and partial recovery of sensory function. The boy could walk upright independently, however, he still complained of numbness of the distal lower extremities.



DOI: 10.12998/wjcc.v10.i13.4294 Copyright ©The Author(s) 2022.

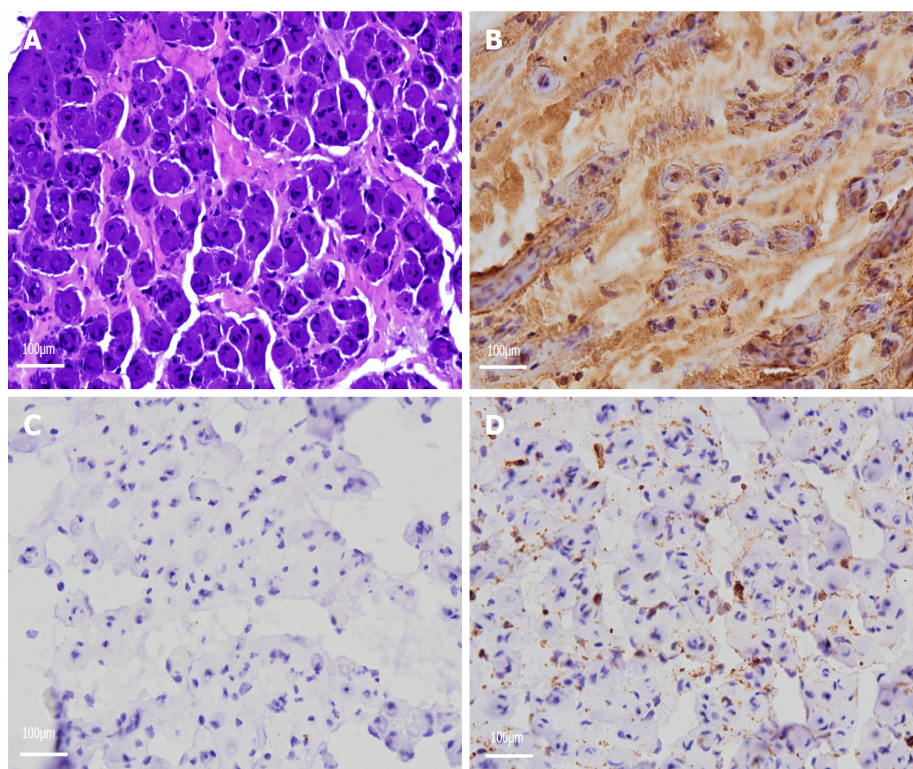
Figure 1 Image of T2-weighted magnetic resonance imaging. A: Diffuse thickening of nerve roots in the spinal canal is seen on magnetic resonance imaging (MRI) sagittal T2 slices (white arrow); B: Extraforaminal nerve root also showed signs of thickening on MRI sagittal T2 slices (white arrow); C: The spinal canal was almost filled with hypertrophic cauda equina on MRI axial T2 slices (white arrow).

DISCUSSION

CIDP is an immune-mediated peripheral neuropathy characterized by progressive or recurrent sensory and motor dysfunctions[2]. The estimated incidence of CIDP is approximate 0.33 per 100000 population, and the prevalence of CIDP is approximate 2.81 per 100000[3], which is significantly higher than in children, at less than 1 per 2000000[4]. For several years, elements of macrophage-mediated demyelination have been considered as characteristic of immune-mediated peripheral neuropathies[5]. However, macrophages have a positive role in nerve regeneration, as they can remove debris after myelin injury and regulate schwann cell remyelination[6]. Macrophages not only cause myelin destruction, but also promote myelin regeneration, resulting in the characteristic “onion bulb” changes seen in CIDP nerve biopsy specimens. These structures result from redundant schwann cell proliferation, indicating repeated segmental degeneration and regeneration of the myelin sheath and elucidating the mechanism of the extensive proliferation of the peripheral nervous system after injury [7].

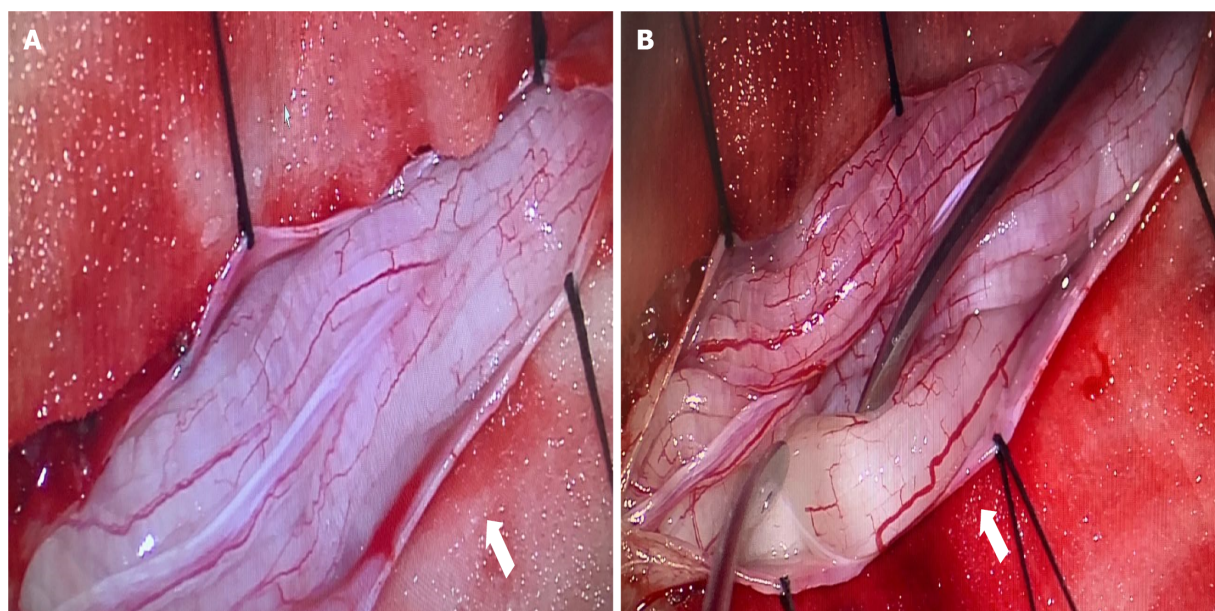
HN frequently manifests as thickening of the peripheral nerves, accompanied by neurological dysfunction. It is generally a slowly progressive disease and is rare in children. HN can be caused by a variety of diseases, such as CIDP, intrathecal schwannoma, hereditary motor and sensory neuropathy type I (charcot-marie-tooth disease) and type III (dejerine sottas disease), neurofibromatosis, amyloidosis, lymphoma, and leprosy[8]. Although cranial nerve involvement is rare, it has been reported to affect the trigeminal, oculomotor, facial, and auditory nerves[9-12]. HN of the cauda equina is exceedingly rare and can cause symptoms similar to those of spinal stenosis. Hypertrophic nerve roots occupy and narrow the lumbar spinal canal, resulting in symptoms similar to those of typical lumbar spinal stenosis[13].

The signal abnormality of HN can be observed *via* B-mode ultrasound and MRI. Hypoechoic masses in B-mode ultrasound images could represent neural edema and acute inflammatory response, while hyperechoic enlargement could indicate fibrosis, onion bulb formation, and remyelination after chronic demyelination[14]. However, B-mode ultrasound is usually more sensitive to isolated peripheral HN. Considering the patient’s clinical symptoms, we initially suspected that the lesion might have been located in the spinal cord, hence, we chose MRI instead of B-mode ultrasound imaging. MRI may demonstrate hypertrophic nerve roots as multifocal and asymmetrical or diffuse. The different patterns of HN likely reflect the unique mechanisms of nerve demyelination of different etiologies[15]. Histopathological sections of hypertrophic nerve caused by CIDP usually display characteristic changes such as “onion bulbs”. Onion bulbs are mainly formed by the proliferation of schwann cells, which are positive for the S-100 protein anti-body[16]. Other diseases that cause hypertrophic nerve roots can present with changes similar to onion bulbs, for example, in the case of intrasheath schwannomas, the proliferation of peripheral nerve cells is the main cause of hypertrophic nerve roots. These cells surround one or more axons and their schwann cell sheaths, therefore, EMA is positive[17]. This distinguishes between perineuroma and schwannoma, as well as inflammatory and acquired polyneuropathy



DOI: 10.12998/wjcc.v10.i13.4294 Copyright ©The Author(s) 2022.

Figure 2 Pathological findings. A: Toluidine blue staining of a cross-section of the nerve root demonstrated numerous onion bulbs and significant loss of large myelinated axons (Magnification: 200 ×); B: Immunohistochemical staining for S100 protein showing positivity of the onion bulbs (Magnification: 200 ×); C: Immunohistochemical staining for epithelial membrane antigen showing negativity of the onion bulbs (Magnification: 200 ×); D: Immunohistochemical staining for leukocyte common antigen showing negativity of the onion bulbs (Magnification: 200 ×).



DOI: 10.12998/wjcc.v10.i13.4294 Copyright ©The Author(s) 2022.

Figure 3 Gross intraoperative view. A: Diffuse enlargement of exposed nerve roots (white arrow); B: The nerve root of the cauda equina selected for biopsy (white arrow).

[18]. In this case, the immunohistochemical result exhibited positivity for S-100 proteins, and inflammatory cells were visible under the electron microscope; hence, CIDP was diagnosed. The etiology of HN is crucial and sometimes difficult to diagnose by non-invasive examination. Nerve biopsy examination is a useful method for discriminating between inflammatory and non-inflammatory

neurological disorders[19].

Alternative treatments for CIDP include intravenous immunoglobulin, corticosteroids, or plasmapheresis[20]. Patients with IgG4 subclass antibodies may not tolerate standard CIDP treatment, however, they may show significant improvement after treatment with rituximab (a monoclonal anti-CD20 antibody that can eliminate B cells)[21]. Neurological decompression surgery has been reported as a treatment for some patients with HN. Lee *et al*[22] reported that an adult patient with cauda equina hypertrophy caused by CIDP received intravenous immunoglobulin injection and spinal canal decompression at segments L2-L5. The patient's symptoms were significantly improved after surgery. Lyons[19] reported another case with HN of the cauda equina who showed clinical symptom improvement after spinal canal decompression and intravenous immunoglobulin treatment. Conversely, O'Ferrall *et al*[23] reported a patient with aggravated symptoms who was treated with laminar decompression combined with intravenous immunoglobulin and eventually improved after plasmapheresis. All these patients with CIDP underwent spinal canal decompression with disparate results. Our case demonstrates that symptoms can improve even if only spinal canal decompression is performed. This may result from cauda equina nerve edema and inflammatory response to local pressure relief. We consider that neurological decompression is effective for HN with high signal on T2 MRI sequence images. However, neurological decompression did not alleviate the degree of inflammatory demyelination. Our patient achieved the greatest improvement in clinical symptoms after receiving hormone therapy. Thus, we think that surgical treatment combined with interventions targeted at a specific etiology is more suitable for treating patients with HN of cauda equina.

CONCLUSION

Spinal canal decompression can improve sensory and motor functions in HN of the cauda equina caused by inflammation, even in children. Surgery combined with specific etiology intervention is the best way to achieve the optimal outcome.

ACKNOWLEDGEMENTS

We are deeply indebted to Professor Yang L who guided us throughout our writing of this report.

FOOTNOTES

Author contributions: Ye L was the patient's neurosurgeon and contributed to manuscript-drafting; Duan LF, Liang NZ, Yu W and Sun Y reviewed the literature; all authors issued final approval for the version to be submitted.

Supported by the Yunnan Provincial Department of Science and Technology Kunming Medical University Application Foundation Research Joint Fund Project, No. 202001AY070001-273; the Epilepsy Research Fund of China Anti-Epilepsy Association, No. CQ-B-2021-04; and the Kunming Health Science and Technology Talent Training Project and "100 thousand" Project Training Plan, No. 2021-SW (province)-23.

Informed consent statement: Informed written consent was obtained from the patient for publication of this report and any accompanying images.

Conflict-of-interest statement: The authors declare that they have no conflict of interest.

CARE Checklist (2016) statement: The authors have read the CARE Checklist (2016), and the manuscript was prepared and revised according to the CARE Checklist (2016).

Open-Access: This article is an open-access article that was selected by an in-house editor and fully peer-reviewed by external reviewers. It is distributed in accordance with the Creative Commons Attribution NonCommercial (CC BY-NC 4.0) license, which permits others to distribute, remix, adapt, build upon this work non-commercially, and license their derivative works on different terms, provided the original work is properly cited and the use is non-commercial. See: <https://creativecommons.org/licenses/by-nc/4.0/>

Country/Territory of origin: China

ORCID number: Lei Ye 0000-0002-2016-784X; Wei Yu 0000-0002-6035-9299; Nai-Zheng Liang 0000-0002-1348-1726; Ying Sun 0000-0003-2790-0650; Li-Fen Duan 0000-0002-8514-9191.

S-Editor: Guo XR

L-Editor: A

P-Editor: Guo XR

REFERENCES

- 1 Landrieu P, Baets J, De Jonghe P. Hereditary motor-sensory, motor, and sensory neuropathies in childhood. *Handb Clin Neurol* 2013; **113**: 1413-1432 [PMID: 23622364 DOI: 10.1016/B978-0-444-59565-2.00011-3]
- 2 Allen JA. Chronic Demyelinating Polyneuropathies. *Continuum (Minneapolis)* 2017; **23**: 1310-1331 [PMID: 28968364 DOI: 10.1212/CON.0000000000000517]
- 3 Broers MC, Bunschoten C, Nieboer D, Lingsma HF, Jacobs BC. Incidence and Prevalence of Chronic Inflammatory Demyelinating Polyradiculoneuropathy: A Systematic Review and Meta-Analysis. *Neuroepidemiology* 2019; **52**: 161-172 [PMID: 30669140 DOI: 10.1159/000494291]
- 4 McLeod JG, Pollard JD, Macaskill P, Mohamed A, Spring P, Khurana V. Prevalence of chronic inflammatory demyelinating polyneuropathy in New South Wales, Australia. *Ann Neurol* 1999; **46**: 910-913 [PMID: 10589544]
- 5 Vallat JM, Mathis S, Vegezzi E, Richard L, Duchesne M, Gallouedec G, Corcia P, Magy L, Uncini A, Devaux J. Antibody- and macrophage-mediated segmental demyelination in chronic inflammatory demyelinating polyneuropathy: clinical, electrophysiological, immunological and pathological correlates. *Eur J Neurol* 2020; **27**: 692-701 [PMID: 31769579 DOI: 10.1111/ene.14133]
- 6 Stratton JA, Holmes A, Rosin NL, Sinha S, Vohra M, Burma NE, Trang T, Midha R, Biernaskie J. Macrophages Regulate Schwann Cell Maturation after Nerve Injury. *Cell Rep* 2018; **24**: 2561-2572.e6 [PMID: 30184491 DOI: 10.1016/j.celrep.2018.08.004]
- 7 Jessen KR, Mirsky R, Lloyd AC. Schwann Cells: Development and Role in Nerve Repair. *Cold Spring Harb Perspect Biol* 2015; **7**: a020487 [PMID: 25957303 DOI: 10.1101/cshperspect.a020487]
- 8 Pinto MV, Spinner RJ, Staff NP. A treatable hypertrophic neuropathy. *Pract Neurol* 2019; **19**: 80-82 [PMID: 30448766 DOI: 10.1136/practneurol-2018-002083]
- 9 Lim JJ, Clark HB, Grande AW. Isolated Hypertrophic Neuropathy of the Oculomotor Nerve. *World Neurosurg* 2017; **98**: 880.e1-880.e4 [PMID: 27876664 DOI: 10.1016/j.wneu.2016.11.048]
- 10 Jordan JE, Lane B, Marks M, Chang Y, Weinberger M. Cranial hypertrophic interstitial neuropathy. *AJNR Am J Neuroradiol* 1992; **13**: 1552-1554 [PMID: 1442431]
- 11 Kania RE, Cazals-Hatem D, Bouccara D, Cyna-Gorse F, Lisovoski F, Hénin D, Sterkers O. Hypertrophic neuropathy of the facial nerve. *Ann Otol Rhinol Laryngol* 2001; **110**: 257-262 [PMID: 11269771 DOI: 10.1177/000348940111000310]
- 12 Neely JG, Armstrong D, Benson J, Neblett C. "Onion bulb" formation associated with a solitary neoplasm of the eighth nerve sheath. *Am J Otolaryngol* 1981; **2**: 307-313 [PMID: 7325305 DOI: 10.1016/s0196-0709(81)80040-3]
- 13 Ishida K, Wada Y, Tsunemi T, Kanda T, Mizusawa H. Marked hypertrophy of the cauda equina in a patient with chronic inflammatory demyelinating polyradiculoneuropathy presenting as lumbar stenosis. *J Neurol* 2005; **252**: 239-240 [PMID: 15729537 DOI: 10.1007/s00415-005-0632-3]
- 14 Grimm A, Schubert V, Axer H, Ziemann U. Giant nerves in chronic inflammatory polyradiculoneuropathy. *Muscle Nerve* 2017; **55**: 285-289 [PMID: 27463360 DOI: 10.1002/mus.25272]
- 15 Yoshii S, Shibuya K, Yokota H, Ikehara H, Shiohama T, Sawada D, Kuwabara S, Fujii K. Magnetic resonance neurography in diagnosing childhood chronic inflammatory demyelinating polyradiculoneuropathy. *Brain Dev* 2021; **43**: 352-356 [PMID: 33433331 DOI: 10.1016/j.braindev.2020.10.001]
- 16 Koszyca B, Jones N, Kneebone C, Blumbergs P. Localized hypertrophic neuropathy: a case report and review of the literature. *Clin Neuropathol* 2009; **28**: 54-58 [PMID: 19216221 DOI: 10.5414/npp28054]
- 17 Norris B, Gonzales M, Drummond KJ. Solitary localized hypertrophic neuropathy of the cauda equina. *J Clin Neurosci* 2011; **18**: 712-714 [PMID: 21345679 DOI: 10.1016/j.jocn.2010.08.021]
- 18 Boyanton BL Jr, Jones JK, Shenaq SM, Hicks MJ, Bhattacharjee MB. Intraneural perineurioma: a systematic review with illustrative cases. *Arch Pathol Lab Med* 2007; **131**: 1382-1392 [PMID: 17824794 DOI: 10.5858/2007-131-1382-IPASRW]
- 19 Lyons MK. Nerve rootlet and fascicular biopsy in patients with hypertrophic inflammatory neuropathy. *Neurologist* 2009; **15**: 40-41 [PMID: 19131857 DOI: 10.1097/NRL.0b013e31817882c8]
- 20 Oaklander AL, Lunn MP, Hughes RA, van Schaik IN, Frost C, Chalk CH. Treatments for chronic inflammatory demyelinating polyradiculoneuropathy (CIDP): an overview of systematic reviews. *Cochrane Database Syst Rev* 2017; **1**: CD010369 [PMID: 28084646 DOI: 10.1002/14651858.CD010369.pub2]
- 21 Querol L, Rojas-García R, Diaz-Manera J, Barcena J, Pardo J, Ortega-Moreno A, Sedano MJ, Seró-Ballesteros L, Carvajal A, Ortiz N, Gallardo E, Illa I. Rituximab in treatment-resistant CIDP with antibodies against paranodal proteins. *Neurol Neuroimmunol Neuroinflamm* 2015; **2**: e149 [PMID: 26401517 DOI: 10.1212/NXI.0000000000000149]
- 22 Lee SE, Park SW, Ha SY, Nam TK. A case of cauda equina syndrome in early-onset chronic inflammatory demyelinating polyneuropathy clinically similar to charcot-marie-tooth disease type 1. *J Korean Neurosurg Soc* 2014; **55**: 370-374 [PMID: 25237436 DOI: 10.3340/jkns.2014.55.6.370]
- 23 O'Ferrall EK, Gendron D, Guiot MC, Hall J, Sinnreich M. Lower motor neuron syndrome due to cauda equina hypertrophy with onion bulbs. *Muscle Nerve* 2013; **48**: 301-305 [PMID: 23424031 DOI: 10.1002/mus.23816]



Published by **Baishideng Publishing Group Inc**
7041 Koll Center Parkway, Suite 160, Pleasanton, CA 94566, USA

Telephone: +1-925-3991568

E-mail: bpgoffice@wjgnet.com

Help Desk: <https://www.f6publishing.com/helpdesk>

<https://www.wjgnet.com>

