

# World Journal of *Clinical Cases*

*World J Clin Cases* 2022 May 16; 10(14): 4327-4712



### OPINION REVIEW

- 4327 Emerging role of biosimilars in the clinical care of inflammatory bowel disease patients  
*Najeeb H, Yasmin F, Surani S*

### MINIREVIEWS

- 4334 Practical insights into chronic management of hepatic Wilson's disease  
*Lynch EN, Campani C, Innocenti T, Dragoni G, Forte P, Galli A*
- 4348 Adipose-derived stem cells in the treatment of hepatobiliary diseases and sepsis  
*Satilmis B, Cicek GS, Cicek E, Akbulut S, Sahin TT, Yilmaz S*

### ORIGINAL ARTICLE

#### Clinical and Translational Research

- 4357 Learning curve for a surgeon in robotic pancreaticoduodenectomy through a "G"-shaped approach: A cumulative sum analysis  
*Wei ZG, Liang CJ, Du Y, Zhang YP, Liu Y*
- 4368 Clinical and prognostic significance of expression of phosphoglycerate mutase family member 5 and Parkin in advanced colorectal cancer  
*Wu C, Feng ML, Jiao TW, Sun MJ*

#### Case Control Study

- 4380 Significance of preoperative peripheral blood neutrophil-lymphocyte ratio in predicting postoperative survival in patients with multiple myeloma bone disease  
*Xu ZY, Yao XC, Shi XJ, Du XR*

#### Retrospective Study

- 4395 Association between depression and malnutrition in pulmonary tuberculosis patients: A cross-sectional study  
*Fang XE, Chen DP, Tang LL, Mao YJ*
- 4404 Pancreatic cancer incidence and mortality patterns in 2006-2015 and prediction of the epidemiological trend to 2025 in China  
*Yin MY, Xi LT, Liu L, Zhu JZ, Qian LJ, Xu CF*
- 4414 Evaluation of short- and medium-term efficacy and complications of ultrasound-guided ablation for small liver cancer  
*Zhong H, Hu R, Jiang YS*

- 4425** Hematopoiesis reconstitution and anti-tumor effectiveness of Pai-Neng-Da capsule in acute leukemia patients with haploidentical hematopoietic stem cell transplantation

*Yuan JJ, Lu Y, Cao JJ, Pei RZ, Gao RL*

- 4436** Oral and maxillofacial pain as the first sign of metastasis of an occult primary tumour: A fifteen-year retrospective study

*Shan S, Liu S, Yang ZY, Wang TM, Lin ZT, Feng YL, Pakezhati S, Huang XF, Zhang L, Sun GW*

- 4446** Reduced serum high-density lipoprotein cholesterol levels and aberrantly expressed cholesterol metabolism genes in colorectal cancer

*Tao JH, Wang XT, Yuan W, Chen JN, Wang ZJ, Ma YB, Zhao FQ, Zhang LY, Ma J, Liu Q*

### Observational Study

- 4460** Correlation of pressure gradient in three hepatic veins with portal pressure gradient

*Wang HY, Song QK, Yue ZD, Wang L, Fan ZH, Wu YF, Dong CB, Zhang Y, Meng MM, Zhang K, Jiang L, Ding HG, Zhang YN, Yang YP, Liu FQ*

- 4470** Multi-slice spiral computed tomography in diagnosing unstable pelvic fractures in elderly and effect of less invasive stabilization

*Huang JG, Zhang ZY, Li L, Liu GB, Li X*

### SYSTEMATIC REVIEWS

- 4480** Distribution and changes in hepatitis C virus genotype in China from 2010 to 2020

*Yang J, Liu HX, Su YY, Liang ZS, Rao HY*

### CASE REPORT

- 4494** Bow hunter's syndrome successfully treated with a posterior surgical decompression approach: A case report and review of literature

*Orlandi N, Cavallieri F, Grisendi I, Romano A, Ghadirpour R, Napoli M, Moratti C, Zanichelli M, Pascarella R, Valzania F, Zedde M*

- 4502** Histological remission of eosinophilic esophagitis under asthma therapy with IL-5 receptor monoclonal antibody: A case report

*Huguenot M, Bruhm AC, Essig M*

- 4509** Cutaneous mucosa-associated lymphoid tissue lymphoma complicating Sjögren's syndrome: A case report and review of literature

*Liu Y, Zhu J, Huang YH, Zhang QR, Zhao LL, Yu RH*

- 4519** Plexiform neurofibroma of the cauda equina with follow-up of 10 years: A case report

*Chomanskis Z, Juskys R, Cepkus S, Dulko J, Hendrixson V, Ruksenas O, Rocka S*

- 4528** Mixed porokeratosis with a novel mevalonate kinase gene mutation: A case report

*Xu HJ, Wen GD*

- 4535** Isolated pancreatic injury caused by abdominal massage: A case report

*Sun BL, Zhang LL, Yu WM, Tuo HF*

- 4541** Bronchiolar adenoma with unusual presentation: Two case reports  
*Du Y, Wang ZY, Zheng Z, Li YX, Wang XY, Du R*
- 4550** Periodontal-orthodontic interdisciplinary management of a “periodontally hopeless” maxillary central incisor with severe mobility: A case report and review of literature  
*Jiang K, Jiang LS, Li HX, Lei L*
- 4563** Anesthesia management for cesarean section in a pregnant woman with odontogenic infection: A case report  
*Ren YL, Ma YS*
- 4569** Convulsive-like movements as the first symptom of basilar artery occlusive brainstem infarction: A case report  
*Wang TL, Wu G, Liu SZ*
- 4574** Globe luxation may prevent myopia in a child: A case report  
*Li Q, Xu YX*
- 4580** Computer tomography-guided negative pressure drainage treatment of intrathoracic esophagojejunal anastomotic leakage: A case report  
*Jiang ZY, Tao GQ, Zhu YF*
- 4586** Primary or metastatic lung cancer? Sebaceous carcinoma of the thigh: A case report  
*Wei XL, Liu Q, Zeng QL, Zhou H*
- 4594** Perianesthesia emergency repair of a cut endotracheal tube’s inflatable tube: A case report  
*Wang TT, Wang J, Sun TT, Hou YT, Lu Y, Chen SG*
- 4601** Diagnosis of cytomegalovirus encephalitis using metagenomic next-generation sequencing of blood and cerebrospinal fluid: A case report  
*Xu CQ, Chen XL, Zhang DS, Wang JW, Yuan H, Chen WF, Xia H, Zhang ZY, Peng FH*
- 4608** Primary sigmoid squamous cell carcinoma with liver metastasis: A case report  
*Li XY, Teng G, Zhao X, Zhu CM*
- 4617** Acute recurrent cerebral infarction caused by moyamoya disease complicated with adenomyosis: A case report  
*Zhang S, Zhao LM, Xue BQ, Liang H, Guo GC, Liu Y, Wu RY, Li CY*
- 4625** Serum-negative Sjogren's syndrome with minimal lesion nephropathy as the initial presentation: A case report  
*Li CY, Li YM, Tian M*
- 4632** Successful individualized endodontic treatment of severely curved root canals in a mandibular second molar: A case report  
*Xu LJ, Zhang JY, Huang ZH, Wang XZ*

- 4640** Successful treatment in one myelodysplastic syndrome patient with primary thrombocytopenia and secondary deep vein thrombosis: A case report  
*Liu WB, Ma JX, Tong HX*
- 4648** Diagnosis of an extremely rare case of malignant adenomyoepithelioma in pleomorphic adenoma: A case report  
*Zhang WT, Wang YB, Ang Y, Wang HZ, Li YX*
- 4654** Management about intravesical histological transformation of prostatic mucinous carcinoma after radical prostatectomy: A case report  
*Bai SJ, Ma L, Luo M, Xu H, Yang L*
- 4661** Hepatopulmonary metastases from papillary thyroid microcarcinoma: A case report  
*Yang CY, Chen XW, Tang D, Yang WJ, Mi XX, Shi JP, Du WD*
- 4669** PD-1 inhibitor in combination with fruquintinib therapy for initial unresectable colorectal cancer: A case report  
*Zhang HQ, Huang CZ, Wu JY, Wang ZL, Shao Y, Fu Z*
- 4676** Cutaneous metastasis from esophageal squamous cell carcinoma: A case report  
*Zhang RY, Zhu SJ, Xue P, He SQ*
- 4684** Rare pattern of Maisonneuve fracture: A case report  
*Zhao B, Li N, Cao HB, Wang GX, He JQ*
- 4691** Suprasellar cistern tuberculoma presenting as unilateral ocular motility disorder and ptosis: A case report  
*Zhao BB, Tian C, Fu LJ, Zhang XB*
- 4698** Development of plasma cell dyscrasias in a patient with chronic myeloid leukemia: A case report  
*Zhang N, Jiang TD, Yi SH*
- 4704** Ovarian growing teratoma syndrome with multiple metastases in the abdominal cavity and liver: A case report  
*Hu X, Jia Z, Zhou LX, Kakongoma N*

**LETTER TO THE EDITOR**

- 4709** Perfectionism and mental health problems: Limitations and directions for future research  
*Nazari N*

**ABOUT COVER**

Editorial Board Member of *World Journal of Clinical Cases*, Jamir Pitton Rissardo, MD, Academic Research, Adjunct Associate Professor, Research Associate, Department of Medicine, Federal University of Santa Maria, Santa Maria 97105110, Brazil. jamirrissardo@gmail.com

**AIMS AND SCOPE**

The primary aim of *World Journal of Clinical Cases* (WJCC, *World J Clin Cases*) is to provide scholars and readers from various fields of clinical medicine with a platform to publish high-quality clinical research articles and communicate their research findings online.

WJCC mainly publishes articles reporting research results and findings obtained in the field of clinical medicine and covering a wide range of topics, including case control studies, retrospective cohort studies, retrospective studies, clinical trials studies, observational studies, prospective studies, randomized controlled trials, randomized clinical trials, systematic reviews, meta-analysis, and case reports.

**INDEXING/ABSTRACTING**

The WJCC is now indexed in Science Citation Index Expanded (also known as SciSearch®), Journal Citation Reports/Science Edition, Scopus, PubMed, and PubMed Central. The 2021 Edition of Journal Citation Reports® cites the 2020 impact factor (IF) for WJCC as 1.337; IF without journal self cites: 1.301; 5-year IF: 1.742; Journal Citation Indicator: 0.33; Ranking: 119 among 169 journals in medicine, general and internal; and Quartile category: Q3. The WJCC's CiteScore for 2020 is 0.8 and Scopus CiteScore rank 2020: General Medicine is 493/793.

**RESPONSIBLE EDITORS FOR THIS ISSUE**

Production Editor: Hua-Ge Yin, Production Department Director: Xu Guo, Editorial Office Director: Jin-Lei Wang.

**NAME OF JOURNAL**

*World Journal of Clinical Cases*

**ISSN**

ISSN 2307-8960 (online)

**LAUNCH DATE**

April 16, 2013

**FREQUENCY**

Thrice Monthly

**EDITORS-IN-CHIEF**

Bao-Gan Peng, Jerzy Tadeusz Chudek, George Kontogeorgos, Maurizio Serati, Ja Hyeon Ku

**EDITORIAL BOARD MEMBERS**

<https://www.wjgnet.com/2307-8960/editorialboard.htm>

**PUBLICATION DATE**

May 16, 2022

**COPYRIGHT**

© 2022 Baishideng Publishing Group Inc

**INSTRUCTIONS TO AUTHORS**

<https://www.wjgnet.com/bpg/gerinfo/204>

**GUIDELINES FOR ETHICS DOCUMENTS**

<https://www.wjgnet.com/bpg/GerInfo/287>

**GUIDELINES FOR NON-NATIVE SPEAKERS OF ENGLISH**

<https://www.wjgnet.com/bpg/gerinfo/240>

**PUBLICATION ETHICS**

<https://www.wjgnet.com/bpg/GerInfo/288>

**PUBLICATION MISCONDUCT**

<https://www.wjgnet.com/bpg/gerinfo/208>

**ARTICLE PROCESSING CHARGE**

<https://www.wjgnet.com/bpg/gerinfo/242>

**STEPS FOR SUBMITTING MANUSCRIPTS**

<https://www.wjgnet.com/bpg/GerInfo/239>

**ONLINE SUBMISSION**

<https://www.f6publishing.com>



## Histological remission of eosinophilic esophagitis under asthma therapy with IL-5 receptor monoclonal antibody: A case report

Marc Huguenot, Anne-Catherine Bruhm, Manfred Essig

**Specialty type:** Gastroenterology and hepatology

**Provenance and peer review:** Unsolicited article; Externally peer reviewed.

**Peer-review model:** Single blind

**Peer-review report's scientific quality classification**

Grade A (Excellent): 0  
Grade B (Very good): 0  
Grade C (Good): C  
Grade D (Fair): D, D  
Grade E (Poor): 0

**P-Reviewer:** Iovino P, Italy; Kreisel W, Germany; Visaggi P, Italy

**Received:** September 27, 2021

**Peer-review started:** September 27, 2021

**First decision:** December 4, 2021

**Revised:** December 17, 2021

**Accepted:** March 25, 2022

**Article in press:** March 25, 2022

**Published online:** May 16, 2022



**Marc Huguenot, Anne-Catherine Bruhm, Manfred Essig**, Department of Gastroenterology and Internal Medicine, Tiefenau Hospital, Bern 3004, Switzerland

**Corresponding author:** Marc Huguenot, MD, Chief Physician, Department of Gastroenterology and Internal Medicine, Tiefenau Hospital, Tiefenastrasse 112, Bern 3004, Switzerland. [marc.huguenot@gmail.com](mailto:marc.huguenot@gmail.com)

### Abstract

#### BACKGROUND

Benralizumab is a monoclonal antibody targeting the IL-5 receptor used in the treatment of asthma. The use of benralizumab in other conditions is only emerging and could represent a therapeutic option for other eosinophil-associated diseases. Here, we report the case of a patient suffering from eosinophilic esophagitis and asthma who achieved histological remission of eosinophilic esophagitis (EoE) under benralizumab treatment for his asthma.

#### CASE SUMMARY

Our patient was a 56-year-old white male with a history of eosinophilic esophagitis and severe asthma. After years of usual treatments, including topical steroids, biological treatment with mepolizumab, and standard asthma treatment, only poor control of both conditions was obtained. A control gastroscopy after the initiation of benralizumab showed complete histological remission of his EoE.

#### CONCLUSION

Our case shows the effects of therapy with a novel agent not yet approved for this condition but for other diseases, with histological resolution of EoE after treatment. Complete clinical remission was not observed, which exemplifies the complex nature of EoE, its associated psychosomatic burden, and the chronicity of the disease. Nevertheless, monoclonal antibodies targeting the Th2 response and, in our case, an IL5 receptor antagonist, achieved complete histological remission, which was not the case with an antibody against IL-5, which was also initiated to treat asthma.

**Key Words:** Eosinophilic esophagitis; Benralizumab, Eosinophilic asthma; Case report

©The Author(s) 2022. Published by Baishideng Publishing Group Inc. All rights reserved.



**Core Tip:** Born in 1965, our patient developed the first symptoms of dyspepsia and food impaction at the age of 28. Eosinophilic esophagitis was diagnosed 19 years later in 2012. The first treatment began in 2013 with oral topical glucocorticoids. With concomitant therapy-resistant asthma, treatment with mepolizumab was initiated in addition to standard asthma therapy in 2016. Because of again suboptimal control of asthma, therapy was switched to benralizumab in 2019. In subsequent gastroscopies, histological remission was observed, but our patient reported pain in the esophagus and further food impaction. This case harbors typical aspects of the complexity of treating eosinophilic esophagitis.

**Citation:** Huguenot M, Bruhm AC, Essig M. Histological remission of eosinophilic esophagitis under asthma therapy with IL-5 receptor monoclonal antibody: A case report. *World J Clin Cases* 2022; 10(14): 4502-4508

**URL:** <https://www.wjgnet.com/2307-8960/full/v10/i14/4502.htm>

**DOI:** <https://dx.doi.org/10.12998/wjcc.v10.i14.4502>

## INTRODUCTION

We report the case of a patient with eosinophilic esophagitis (EoE) with concomitant severe asthma who achieved complete histological resolution of the first after the initiation of therapy with benralizumab for asthma.

Until now, benralizumab has been approved only for severe eosinophilic asthma based on three studies[1-3].

## CASE PRESENTATION

### Chief complaints

Intermittent dysphagia and poorly controlled asthma.

### History of present illness

Born in 1965, our patient developed the first symptoms of dyspepsia and food impaction at the age of 28. The diagnosis of EoE was made 19 years later in 2012 on the basis of symptoms, endoscopy, and histology. We only have part of the histology report at hand and it only mentions slightly active eosinophilic esophagitis, no signs of thrush or virus infection, and no dysplasia. We do not know the eosinophilic count at that time. Celiac disease and inflammatory bowel diseases as other disorders possibly presenting with esophageal eosinophilia were excluded at that time. The first treatment began in 2013 with oral topical glucocorticoids (fluticasone, off-label, and from 2016 onwards switched to budesonide mostly, but intermittent back to fluticasone). Difficulties with swallowing intensified, despite consistent therapy with oral glucocorticoids. The following gastroscopy in December 2014 showed strictures in the esophagogastric area, which were treated with argon plasma coagulation and dilation with bougies, with reported clinical improvement. The same year, asthma was diagnosed, exhaled NO was 39 ppb and the medication for asthma was as follows: Inhaled combination of formoterol and budesonide, ciclesonide, and, as needed salbutamol. Gastroesophageal reflux disease (GERD) was diagnosed in 2015 via 24-h pH-metry.

Because of therapy-resistant asthma, the first biological treatment with mepolizumab was initiated in addition to standard asthma therapy in 2016 at a dose of 100 mg s.c. monthly. Both as a follow-up and because of increasing dysphagia, the patient underwent another gastroscopy in October 2018. Histology showed 20 eosinophils per high-power field in the distal esophagus and 19 eosinophils per high-power field in the proximal esophagus. Because of suboptimal control of asthma (exhaled NO 34 ppb to that time), the standard asthma therapy was switched to benralizumab between January and March 2019 at a dose of 30 mg s.c. monthly for the first 3 mo and then once every 2 mo until today. In the patient's regular consultations with a pneumologist both before and after treatment with mepolizumab and benralizumab, only partly controlled asthma was described according to GINA guidelines (waking due to asthma, daytime symptoms more than twice a week, use of short acting beta agonist as reliever more than twice a week, and activity limitation due to asthma).

The patient also had recurrent exacerbations of his asthma. The exact number cannot be assessed from the medical history available to us. At least three exacerbations in 2015 and one exacerbation due to an influenza A infection in March 2019 even needed a 4-d hospitalization. For these exacerbations, he received systemic pulse steroid therapy. In September 2019, the patient discontinued oral topical glucocorticoids (budesonide), reporting vertigo.



**History of past illness**

Delay between symptoms and diagnosis is not uncommon in EoE and correlates with the development of esophageal strictures[4]. Common symptoms of EoE in teenagers and adults are dysphagia, food impaction, abdominal pain, chronic reflux symptoms, heartburn, and spontaneous rupture of the esophagus. Younger children can present nausea, vomiting, feeding difficulties, and growth retardation [5].

**Psychosomatic aspects**

The usual delay to diagnosis and the chronic nature of EoE predispose patients to associated psychiatric conditions. A retrospective study between 2002 and 2018 showed that psychiatric comorbidities are common in EoE, with the most common comorbidities being anxiety and depression. Approximately one-third of adults had a diagnosis of a psychiatric condition, and just as many received a prescription medication for a psychiatric illness. The longer the duration of symptoms preceding diagnosis, the more likely that psychiatric comorbidities were found[6]. A recent review article stated the necessity for more research, as there is not even a single prospective study; therefore, the effect of these comorbidities on patients with EoE remains unclear. In addition, anxiety could be driven by limited treatment options[7].

**Personal and family history**

Other comorbidities were moderate obstructive sleep apnea syndrome diagnosed in June 2016, postnasal drip syndrome, hiatal hernia diagnosed in December 2014, ectopic gastric mucosa diagnosed in April 2015, allergic rhinoconjunctivitis, status post prostatectomy for prostatic hyperplasia, status post cholecystectomy, status post multiple vertebral surgeries, and status post left shoulder surgery. Although there is no documented diagnosis for a psychiatric comorbidity, a medical report from December 2019 mentioned treatment with escitalopram and mirtazapin in the patient's medication list, suggesting that the patient might have suffered from depression.

**Physical examination**

Not applicable.

**Laboratory examinations**

Histologic examination of esophageal biopsies.

**Imaging examinations**

Gastroscopy in May 2019 (Figure 1).

---

**FINAL DIAGNOSIS**


---

Eosinophilic esophagitis.

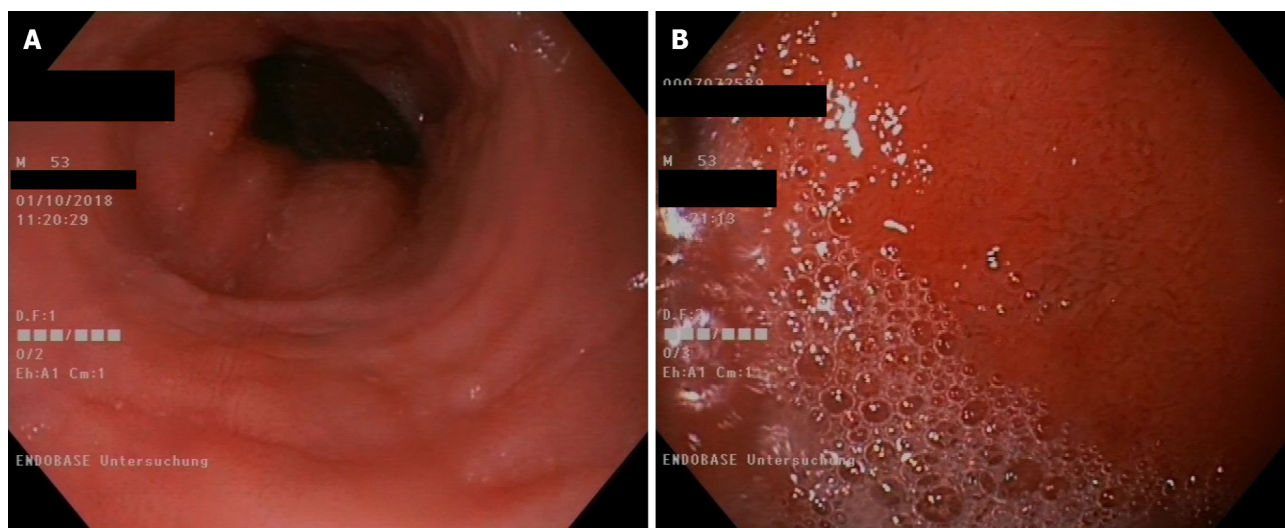
---

**TREATMENT**


---

For many years, our patient received a proton pump inhibitor (PPI) and budesonide, a swallowed glucocorticoid, according to guidelines, but there was neither clinical nor histological improvement. The dilation of esophageal strictures provided a temporary relief of symptoms. It is difficult to assess the exact diet of our patient, and it is unknown if he practiced dietary restrictions. The patient was on anti-IL5 mepolizumab since October 2016, for approximately 2.5 years, but interestingly, only after treatment with the IL-5 receptor antagonist benralizumab were there no eosinophils found in the esophageal mucosa. This histological remission was observed on May 2019, only approximately 4 mo after treatment began with the IL-5 receptor antagonist. Perhaps a lower concentration of mepolizumab (100 mg), which was the dose that our patient received, was just not enough to reduce the number of eosinophils in tissues. As the patient was under PPIs and topical swallowed glucocorticoids for years and a gastroscopy (October 2018) under this medication showed increased eosinophils, we do not think it likely that this medication with PPI and glucocorticoids alone could have had an impact on the histologic remission. Although they might have contributed to that.

In retrospect, it is difficult to assess the exact medication and the small changes in the medication that the patient received. One problem is that he visited many different specialists in different locations for second opinions. Treatment with systemic glucocorticoids over a longer time than for the exacerbations was not reported. He was under a PPI (esomeprazole) at least since February 2015 and in changing dosages (from esomeprazole 20 mg twice daily to esomeprazole 40 mg twice daily). In March 2019, which was shortly before the gastroscopy in May 2019 (Figure 1) showed a full depletion of eosinophils in the esophagus, it is stated that the dosage was esomeprazole 40 mg twice daily. It is not known whether the patient tried an elimination diet.



DOI: 10.12998/wjcc.v10.i14.4502 Copyright ©The Author(s) 2022.

**Figure 1** Esophagus and bulb after treatment. A: Esophagus; B: Bulbus.

This case harbors typical aspects of the complexity of treating EoE and includes a long interval between the initial symptoms and diagnosis, the interaction with other eosinophilic conditions, psychiatric comorbidities or associated symptoms and chronic illnesses and possible new therapeutic approaches.

## OUTCOME AND FOLLOW-UP

Although our patient showed objective improvement of his disease under treatment with benralizumab in terms of total depletion of eosinophils in peripheral blood samples as well as in the histological examination, with zero eosinophilic granulocytes (0/high power field), there was limited clinical improvement.

The patient has only partially controlled asthma according to GINA guidelines. He is dependent on inhaled corticosteroids but not systemic corticosteroids. Dyspnea and coughing are troubling at night, but his comorbidity of obstructive sleep apnea syndrome and postnasal drip syndrome likely play a role, in addition to his asthma. He experiences limitations in daily life, cannot perform physical work, and can perform office work only 2 h/d. This goes along with findings that IL-5-receptor targeted therapy leads to fewer exacerbations and lesser steroid dependence but not to many improvements in lung function itself or bronchial hyperreactivity[8]. Indeed, the spirometry results in the case of our patient remained approximately the same.

There also seems to be limited clinical improvement concerning the patient's gastrointestinal symptoms. Intermittent dysphagia was present when he underwent the last gastroscopy, where the histological evaluation showed no signs of eosinophils under benralizumab treatment. The resolution of esophageal strictures under therapy is still debated, but it is generally assumed that esophageal strictures are not responsive to medical therapy. The subepithelial fibrosis associated with strictures, especially in adults with long-lasting disease, is less reversible by anti-IL-5 therapy.

With the patient's long history of nearly 30 years of EoE, pain chronification and underlying psychiatric condition are possible.

## DISCUSSION

### EoE

EoE is a chronic condition affecting both adults and children[4] characterized by symptoms related to esophageal dysfunction and esophageal eosinophilia. Other causes of esophageal eosinophilia, such as GERD, parasitic infections, vasculitis, and Morbus Crohn's disease, should be excluded[9]. EoE is a chronic antigen-mediated or immune-mediated disease. Most antigens seem to be food-based[9].

The pathogenesis of EoE is multifactorial and not fully understood. Genetic predisposition, environmental factors (microbiome, breastfeeding, and population density), and food antigens play a role. These antigens stimulate Th2 cells, which produce different cytokines, one of which is IL-5, which activates eosinophils, leading to the inflammation of the esophagus[10].

Due to the probable allergic nature of EoE, the avoidance of triggers in food or aeroallergens could cure the disease. Treatment includes both pharmacological and dietary measures. Triggers cannot be identified in every case, and the pharmacological treatment includes PPIs and topical steroids.

Historically, the complex interplay between gastroesophageal reflux and eosinophilic esophagitis has been assumed to represent the same entity.

In previous years, patients with pathological results in pH-metry were categorized as GERD patients, and GERD and EoE were seen as two distinct diseases. Since 2011, a patient who responded to PPI therapy, independent of the pH measurement, was considered to have PPI-responsive EoE (PPI-REE). Now, we know that GERD and PPI-REE are hardly distinguishable from each other (clinically or histologically). The term PPI-REE disappeared from the actual guidelines.

Some cases of EoE respond to a PPI alone, and these cases could represent this associated condition. Up to 40% of children with EoE experience remission under a PPI alone. This subset of patients are considered to have PPI-responsive eosinophilic esophagitis (PPI-REE)[11]. Why this group experiences symptom relief when others do not is unclear. However, GERD may be difficult to rule out because neither the response to PPIs nor the duration of exposure to esophageal acid, measured by means of ambulatory pH monitoring, definitively distinguishes GERD from eosinophilic esophagitis[12].

There is an association of EoE with atopic disorders such as asthma, rhinitis, eczema, and food allergies[9,13].

### **Anti-IL-5 drug mechanisms**

IL-5 is one of the cytokines responsible for the activation of eosinophils by binding to their IL-5R $\alpha$  receptors, resulting in subsequent activation of the NF- $\kappa$ B pathway. From a pathophysiological point of view, this activation of the NF- $\kappa$ B pathway causes tissue damage due to endothelial cell damage, changed repair mechanisms, and fibrosis. There are humanized monoclonal antibodies such as mepolizumab and reslizumab that target IL-5, blocking its binding to the receptor. Benralizumab targets the alpha subunit of the IL-5 receptor itself and inhibits the described pathway. Moreover, the antibody benralizumab, through its Fc region, is able to recruit NK cells, mast cells, and basophils and to induce antibody-dependent cellular cytotoxicity.

The result is an entire depletion of eosinophils in the bone marrow and blood and a significant decrease of eosinophils in sputum and tissue[14,15]. With their eosinophil-depleting effect, theoretically, there is a possible application of anti-IL-5 drugs in every disease associated with the pathological presence of eosinophils, namely, eosinophilic asthma, eosinophilic esophagitis, hypereosinophilic syndrome, and eosinophilic granulomatosis with polyangiitis[16].

### **Existing data on IL-5 and EoE**

A systematic review confirmed that anti-IL-5 monoclonal antibodies do not lead to histological depletion of eosinophils or to the improvement of clinical discomfort[17]. One can speculate on the reason for this; perhaps, unlike IL-5 antibodies, IL-5-receptor antibodies can induce cytotoxicity against eosinophils, as described earlier. Other biological drugs targeting the Th2 response, such as anti-IL-13 antibodies, are under evaluation[10].

### **Studies examining IL-5 or IL-5-receptor antagonists in EoE**

Most studies had a very small study population size. Only two studies included adults, both with very small sample sizes and with a relatively short follow-up. The most recent study was from 2018, and the others were from 2012 or earlier. First, there was a clear lack of recent studies. Second, there was a lack of studies with a meaningful number of adult participants. Additionally, there have been no clinical studies that examine the effect of IL-5 receptor antagonists in patients with EoE (mepolizumab and reslizumab are IL-5 antagonists).

A multicenter randomized double blind, parallel group, placebo-controlled phase 3 study is recruiting at the moment to investigate the use of benralizumab for eosinophilic esophagitis (MESSINA; ClinicalTrials.gov Identifier: NCT04543409), measuring clinical and histological outcomes.

---

## **CONCLUSION**

In our case, it is unclear as well whether the patient's remaining discomforts have a purely somatic cause or are influenced by psychiatric comorbidity. There is a known discrepancy between symptom relief and histological disappearance of eosinophils, as well as a discussion about which of these should be considered to evaluate therapy success. Further studies, one already ongoing, should bring better answers to this question.

## FOOTNOTES

**Author contributions:** Huguenot M and Bruhm AC contributed equally to this article; Essig M revised the manuscript.

**Informed consent statement:** The patient gave informed consent to the publication of this article and general consent is applicable.

**Conflict-of-interest statement:** The authors declare that there are no conflicts of interest for this article.

**CARE Checklist (2016) statement:** The authors have read the CARE Checklist (2016), and the manuscript was prepared and revised according to the CARE Checklist (2016).

**Open-Access:** This article is an open-access article that was selected by an in-house editor and fully peer-reviewed by external reviewers. It is distributed in accordance with the Creative Commons Attribution NonCommercial (CC BY-NC 4.0) license, which permits others to distribute, remix, adapt, build upon this work non-commercially, and license their derivative works on different terms, provided the original work is properly cited and the use is non-commercial. See: <https://creativecommons.org/licenses/by-nc/4.0/>

**Country/Territory of origin:** Switzerland

**ORCID number:** Marc Huguenot 0000-0002-1618-1710; Anne-Catherine Bruhm 0000-0003-0590-4765; Manfred Essig 0000-0002-7940-2795.

**S-Editor:** Liu JH

**L-Editor:** Wang TQ

**P-Editor:** Liu JH

## REFERENCES

- 1 **Bleecker ER**, FitzGerald JM, Chanez P, Papi A, Weinstein SF, Barker P, Sproule S, Gilmartin G, Aurivillius M, Werkström V, Goldman M; SIROCCO study investigators. Efficacy and safety of benralizumab for patients with severe asthma uncontrolled with high-dosage inhaled corticosteroids and long-acting  $\beta_2$ -agonists (SIROCCO): a randomised, multicentre, placebo-controlled phase 3 trial. *Lancet* 2016; **388**: 2115-2127 [PMID: 27609408 DOI: 10.1016/S0140-6736(16)31324-1]
- 2 **FitzGerald JM**, Bleecker ER, Nair P, Korn S, Ohta K, Lommatzsch M, Ferguson GT, Busse WW, Barker P, Sproule S, Gilmartin G, Werkström V, Aurivillius M, Goldman M; CALIMA study investigators. Benralizumab, an anti-interleukin-5 receptor  $\alpha$  monoclonal antibody, as add-on treatment for patients with severe, uncontrolled, eosinophilic asthma (CALIMA): a randomised, double-blind, placebo-controlled phase 3 trial. *Lancet* 2016; **388**: 2128-2141 [PMID: 27609406 DOI: 10.1016/S0140-6736(16)31322-8]
- 3 **Nair P**, Wenzel S, Rabe KF, Bourdin A, Lugogo NL, Kuna P, Barker P, Sproule S, Ponnarambil S, Goldman M; ZONDA Trial Investigators. Oral Glucocorticoid-Sparing Effect of Benralizumab in Severe Asthma. *N Engl J Med* 2017; **376**: 2448-2458 [PMID: 28530840 DOI: 10.1056/NEJMoa1703501]
- 4 **Schoepfer AM**, Safroneeva E, Bussmann C, Kuchen T, Portmann S, Simon HU, Straumann A. Delay in diagnosis of eosinophilic esophagitis increases risk for stricture formation in a time-dependent manner. *Gastroenterology* 2013; **145**: 1230-6.e1 [PMID: 23954315 DOI: 10.1053/j.gastro.2013.08.015]
- 5 **Dellon ES**, Hirano I. Epidemiology and Natural History of Eosinophilic Esophagitis. *Gastroenterology* 2018; **154**: 319-332.e3 [PMID: 28774845 DOI: 10.1053/j.gastro.2017.06.067]
- 6 **Reed CC**, Corder SR, Kim E, Sanders E, Tappata M, Eluri S, Dellon ES. Psychiatric Comorbidities and Psychiatric Medication Use Are Highly Prevalent in Patients With Eosinophilic Esophagitis and Associate With Clinical Presentation. *Am J Gastroenterol* 2020; **115**: 853-858 [PMID: 32195733 DOI: 10.14309/ajg.0000000000000597]
- 7 **Taft TH**, Guadagnoli L, Edlynn E. Anxiety and Depression in Eosinophilic Esophagitis: A Scoping Review and Recommendations for Future Research. *J Asthma Allergy* 2019; **12**: 389-399 [PMID: 31849499 DOI: 10.2147/JAA.S193045]
- 8 **Farne HA**, Wilson A, Powell C, Bax L, Milan SJ. Anti-IL5 therapies for asthma. *Cochrane Database Syst Rev* 2017; **9**: CD010834 [PMID: 28933516 DOI: 10.1002/14651858.CD010834.pub3]
- 9 **Furuta GT**, Katzka DA. Eosinophilic Esophagitis. *N Engl J Med* 2015; **373**: 1640-1648 [PMID: 26488694 DOI: 10.1056/NEJMra1502863]
- 10 **Schoepfer AM**, Straumann A, Safroneeva E. Pharmacologic Treatment of Eosinophilic Esophagitis: An Update. *Gastrointest Endosc Clin N Am* 2018; **28**: 77-88 [PMID: 29129301 DOI: 10.1016/j.giec.2017.07.007]
- 11 **Molina-Infante J**, Ferrando-Lamana L, Ripoll C, Hernandez-Alonso M, Mateos JM, Fernandez-Bermejo M, Dueñas C, Fernandez-Gonzalez N, Quintana EM, Gonzalez-Nuñez MA. Esophageal eosinophilic infiltration responds to proton pump inhibition in most adults. *Clin Gastroenterol Hepatol* 2011; **9**: 110-117 [PMID: 20920599 DOI: 10.1016/j.cgh.2010.09.019]
- 12 **Moawad FJ**, Schoepfer AM, Safroneeva E, Ally MR, Chen YJ, Maydonovitch CL, Wong RK. Eosinophilic oesophagitis and proton pump inhibitor-responsive oesophageal eosinophilia have similar clinical, endoscopic and histological findings. *Aliment Pharmacol Ther* 2014; **39**: 603-608 [PMID: 24461332 DOI: 10.1111/apt.12636]

- 13 **Dellon ES**, Gonsalves N, Hirano I, Furuta GT, Liacouras CA, Katzka DA; American College of Gastroenterology. ACG clinical guideline: Evidence-based approach to the diagnosis and management of esophageal eosinophilia and eosinophilic esophagitis (EoE). *Am J Gastroenterol* 2013; **108**: 679-92; quiz 693 [PMID: [23567357](#) DOI: [10.1038/ajg.2013.71](#)]
- 14 **Caminati M**, Menzella F, Guidolin L, Senna G. Targeting eosinophils: severe asthma and beyond. *Drugs Context* 2019; **8**: 212587 [PMID: [31391853](#) DOI: [10.7573/dic.212587](#)]
- 15 **Roufosse F**. Targeting the Interleukin-5 Pathway for Treatment of Eosinophilic Conditions Other than Asthma. *Front Med (Lausanne)* 2018; **5**: 49 [PMID: [29682504](#) DOI: [10.3389/fmed.2018.00049](#)]
- 16 **Hassani M**, Koenderman L. Immunological and hematological effects of IL-5(R $\alpha$ )-targeted therapy: An overview. *Allergy* 2018; **73**: 1979-1988 [PMID: [29611207](#) DOI: [10.1111/all.13451](#)]
- 17 **Sawas T**, Dhalla S, Sayyar M, Pasricha PJ, Hernaez R. Systematic review with meta-analysis: pharmacological interventions for eosinophilic oesophagitis. *Aliment Pharmacol Ther* 2015; **41**: 797-806 [PMID: [25728929](#) DOI: [10.1111/apt.13147](#)]



Published by **Baishideng Publishing Group Inc**  
7041 Koll Center Parkway, Suite 160, Pleasanton, CA 94566, USA

**Telephone:** +1-925-3991568

**E-mail:** [bpgoffice@wjgnet.com](mailto:bpgoffice@wjgnet.com)

**Help Desk:** <https://www.f6publishing.com/helpdesk>

<https://www.wjgnet.com>

