

World Journal of *Clinical Cases*

World J Clin Cases 2022 May 26; 10(15): 4713-5123



Contents

Thrice Monthly Volume 10 Number 15 May 26, 2022

EDITORIAL

- 4713 Diet and intestinal bacterial overgrowth: Is there evidence?

Souza C, Rocha R, Cotrim HP

MINIREVIEWS

- 4717 Definition and classification of acute-on-chronic liver diseases

Zhang YY, Meng ZJ

- 4726 Management of neurosurgical patients during coronavirus disease 2019 pandemics: The Ljubljana, Slovenia experience

Velmar T, Bosnjak R

ORIGINAL ARTICLE

Clinical and Translational Research

- 4737 Glycolytic and fatty acid oxidation genes affect the treatment and prognosis of liver cancer

Zou JY, Huang YJ, He J, Tang ZX, Qin L

- 4761 Detection of a novel panel of 24 genes with high frequencies of mutation in gastric cancer based on next-generation sequencing

Zeng HH, Yang Z, Qiu YB, Bashir S, Li Y, Xu M

Case Control Study

- 4776 Outcomes of cervical degenerative disc disease treated by anterior cervical discectomy and fusion with self-locking fusion cage

Zhang B, Jiang YZ, Song QP, An Y

- 4785 Impact of COVID-19 pandemic on clinicopathological features of transplant recipients with hepatocellular carcinoma: A case-control study

Akbulut S, Sahin TT, Ince V, Yilmaz S

Retrospective Study

- 4799 Risk factors and optimal predictive scoring system of mortality for children with acute paraquat poisoning

Song Y, Wang H, Tao YH

- 4810 Application effect of thoracoscopic tricuspid valvuloplasty in geriatric patients with tricuspid valve disease

Jiang W, Long XM, Wei KQ, Li SC, Zhang Z, He BF, Li H

- 4818 Endoscopic ultrasonography in the evaluation of condition and prognosis of ulcerative colitis

Jin RF, Chen YM, Chen RP, Ye HJ

- 4827** Dynamic interaction nursing intervention on functional rehabilitation and self-care ability of patients after aneurysm surgery

Xie YE, Huang WC, Li YP, Deng JH, Huang JT

Clinical Trials Study

- 4836** Validations of new cut-offs for surgical drains management and use of computerized tomography scan after pancreatoduodenectomy: The DALCUT trial

Caputo D, Coppola A, La Vaccara V, Passa R, Carbone L, Ciccozzi M, Angeletti S, Coppola R

Observational Study

- 4843** Psychosocial adaptation and influencing factors among patients with chemotherapy-induced peripheral neuropathy

Zhou X, Wang DY, Ding CY, Liu H, Sun ZQ

META-ANALYSIS

- 4856** Outcome of the efficacy of Chinese herbal medicine for functional constipation: A systematic review and meta-analysis

Lyu Z, Fan Y, Bai Y, Liu T, Zhong LL, Liang HF

CASE REPORT

- 4878** Familial gastrointestinal stromal tumors with *KIT* germline mutation in a Chinese family: A case report

Yuan W, Huang W, Ren L, Xu C, Luan LJ, Huang J, Xue AW, Fang Y, Gao XD, Shen KT, Lv JH, Hou YY

- 4886** Nonfunctional pancreatic neuroendocrine tumours misdiagnosed as autoimmune pancreatitis: A case report and review of literature

Lin ZQ, Li X, Yang Y, Wang Y, Zhang XY, Zhang XX, Guo J

- 4895** Sudden deafness as a prodrome of cerebellar artery infarction: Three case reports

Li BL, Xu JY, Lin S

- 4904** Importance of abdominal X-ray to confirm the position of levonorgestrel-releasing intrauterine system: A case report

Maebayashi A, Kato K, Hayashi N, Nagaishi M, Kawana K

- 4911** Bedside ultrasonic localization of the nasogastric tube in a patient with severe COVID-19: A case report

Zhu XJ, Liu SX, Li QT, Jiang YJ

- 4917** Paradoxical herniation after decompressive craniectomy provoked by mannitol: A case report

Du C, Tang HJ, Fan SM

- 4923** Targeted next-generation sequencing identifies a novel nonsense mutation in ANK1 for hereditary spherocytosis: A case report

Fu P, Jiao YY, Chen K, Shao JB, Liao XL, Yang JW, Jiang SY

- 4929** Nonfunctional bladder paraganglioma misdiagnosed as hemangioma: A case report

Chen J, Yang HF

- 4935** Special type of Wernekink syndrome in midbrain infarction: Four case reports
Yang YZ, Hu WX, Zhai HJ
- 4942** Primary extraskeletal Ewing's sarcoma of the lumbar nerve root: A case report
Lei LH, Li F, Wu T
- 4949** Yellow nail syndrome accompanied by minimal-change nephrotic syndrome: A case report
Zhang YN, Wang MH, Yu WC, Cheng W, Cong JP, Huang XP, Wang FF
- 4957** Total femur replacement with 18 years of follow-up: A case report
Yang YH, Chen JX, Chen QY, Wang Y, Zhou YB, Wang HW, Yuan T, Sun HP, Xie L, Yao ZH, Yang ZZ
- 4964** Male metaplastic breast cancer with poor prognosis: A case report
Kim HY, Lee S, Kim DI, Jung CS, Kim JY, Nam KJ, Choo KS, Jung YJ
- 4971** CD8-positive indolent T-Cell lymphoproliferative disorder of the gastrointestinal tract: A case report and review of literature
Weng CY, Ye C, Fan YH, Lv B, Zhang CL, Li M
- 4985** Bone flare after initiation of novel hormonal therapy in patients with metastatic hormone-sensitive prostate cancer: A case report
Li KH, Du YC, Yang DY, Yu XY, Zhang XP, Li YX, Qiao L
- 4991** Postoperative infection of the skull base surgical site due to suppurative parotitis: A case report
Zhao Y, Zhao Y, Zhang LQ, Feng GD
- 4998** Blunt aortic injury-traumatic aortic isthmus pseudoaneurysm with right iliac artery dissection aneurysm: A case report
Fang XX, Wu XH, Chen XF
- 5005** Extensive complex thoracoabdominal aortic aneurysm salvaged by surgical graft providing landing zone for endovascular graft: A case report
Jang AY, Oh PC, Kang JM, Park CH, Kang WC
- 5012** Gastric heterotopia of colon found cancer workup in liver abscess: A case report
Park JG, Suh JI, Kim YU
- 5018** Clinical manifestations and gene analysis of Hutchinson-Gilford progeria syndrome: A case report
Zhang SL, Lin SZ, Zhou YQ, Wang WQ, Li JY, Wang C, Pang QM
- 5025** Neurocutaneous melanosis with an intracranial cystic-solid meningeal melanoma in an adult: A case report and review of literature
Liu BC, Wang YB, Liu Z, Jiao Y, Zhang XF
- 5036** Metastasis of liver cancer to the thyroid after surgery: A case report
Zhong HC, Sun ZW, Cao GH, Zhao W, Ma K, Zhang BY, Feng YJ

- 5042** Spontaneous liver rupture following SARS-CoV-2 infection in late pregnancy: A case report
Ambrož R, Stašek M, Molnár J, Špička P, Klos D, Hambálek J, Skanderová D
- 5051** Carotid blowout syndrome caused by chronic infection: A case report
Xie TH, Zhao WJ, Li XL, Hou Y, Wang X, Zhang J, An XH, Liu LT
- 5057** Is repeat wide excision plus radiotherapy of localized rectal melanoma another choice before abdominoperineal resection? A case report
Chiu HT, Pu TW, Yen H, Liu T, Wen CC
- 5064** Metaplastic breast cancer with chondrosarcomatous differentiation combined with concurrent bilateral breast cancer: A case report
Yang SY, Li Y, Nie JY, Yang ST, Yang XJ, Wang MH, Zhang J
- 5072** Rare solitary splenic metastasis from a thymic carcinoma detected on fluorodeoxyglucose-positron emission tomography: A case report
Tsai YH, Lin KH, Huang TW
- 5077** Type A aortic dissection following heart transplantation: A case report
Zeng Z, Yang LJ, Zhang C, Xu F
- 5082** Catheter-related infections caused by *Mycobacterium abscessus* in a patient with motor neurone disease: A case report
Pan SF, Zhang YY, Wang XZ, Sun JJ, Song SL, Tang YR, Wang JL
- 5088** Clear aligner treatment for a four-year-old patient with anterior cross-bite and facial asymmetry: A case report
Zou YR, Gan ZQ, Zhao LX
- 5097** Knot impingement after arthroscopic rotator cuff repair mimicking infection: A case report
Kim DH, Jeon JH, Choi BC, Cho CH
- 5103** Solitary primary pulmonary synovial sarcoma: A case report
He WW, Huang ZX, Wang WJ, Li YL, Xia QY, Qiu YB, Shi Y, Sun HM
- 5111** Anesthetic management for intraoperative acute pulmonary embolism during inferior vena cava tumor thrombus surgery: A case report
Hsu PY, Wu EB
- 5119** Delayed diagnosis of arytenoid cartilage dislocation after tracheal intubation in the intensive care unit: A case report
Yan WQ, Li C, Chen Z

ABOUT COVER

Editorial Board Member of *World Journal of Clinical Cases*, Jing Yang, MD, Associate Professor, Department of the First General Surgery, Gansu Provincial Hospital, Lanzhou 730000, Gansu Province, China. 21634604@qq.com

AIMS AND SCOPE

The primary aim of *World Journal of Clinical Cases* (WJCC, *World J Clin Cases*) is to provide scholars and readers from various fields of clinical medicine with a platform to publish high-quality clinical research articles and communicate their research findings online.

WJCC mainly publishes articles reporting research results and findings obtained in the field of clinical medicine and covering a wide range of topics, including case control studies, retrospective cohort studies, retrospective studies, clinical trials studies, observational studies, prospective studies, randomized controlled trials, randomized clinical trials, systematic reviews, meta-analysis, and case reports.

INDEXING/ABSTRACTING

The WJCC is now indexed in Science Citation Index Expanded (also known as SciSearch®), Journal Citation Reports/Science Edition, Scopus, PubMed, and PubMed Central. The 2021 Edition of Journal Citation Reports® cites the 2020 impact factor (IF) for WJCC as 1.337; IF without journal self cites: 1.301; 5-year IF: 1.742; Journal Citation Indicator: 0.33; Ranking: 119 among 169 journals in medicine, general and internal; and Quartile category: Q3. The WJCC's CiteScore for 2020 is 0.8 and Scopus CiteScore rank 2020: General Medicine is 493/793.

RESPONSIBLE EDITORS FOR THIS ISSUE

Production Editor: Ying-Yi Yuan; **Production Department Director:** Xiang Li; **Editorial Office Director:** Jin-Lei Wang.

NAME OF JOURNAL

World Journal of Clinical Cases

ISSN

ISSN 2307-8960 (online)

LAUNCH DATE

April 16, 2013

FREQUENCY

Thrice Monthly

EDITORS-IN-CHIEF

Bao-Gan Peng, Jerzy Tadeusz Chudek, George Kontogeorgos, Maurizio Serati, Ja Hyeon Ku

EDITORIAL BOARD MEMBERS

<https://www.wjgnet.com/2307-8960/editorialboard.htm>

PUBLICATION DATE

May 26, 2022

COPYRIGHT

© 2022 Baishideng Publishing Group Inc

INSTRUCTIONS TO AUTHORS

<https://www.wjgnet.com/bpg/gerinfo/204>

GUIDELINES FOR ETHICS DOCUMENTS

<https://www.wjgnet.com/bpg/GerInfo/287>

GUIDELINES FOR NON-NATIVE SPEAKERS OF ENGLISH

<https://www.wjgnet.com/bpg/gerinfo/240>

PUBLICATION ETHICS

<https://www.wjgnet.com/bpg/GerInfo/288>

PUBLICATION MISCONDUCT

<https://www.wjgnet.com/bpg/gerinfo/208>

ARTICLE PROCESSING CHARGE

<https://www.wjgnet.com/bpg/gerinfo/242>

STEPS FOR SUBMITTING MANUSCRIPTS

<https://www.wjgnet.com/bpg/GerInfo/239>

ONLINE SUBMISSION

<https://www.f6publishing.com>



Yellow nail syndrome accompanied by minimal-change nephrotic syndrome: A case report

Ya-Nan Zhang, Mei-Hua Wang, Wen-Cheng Yu, Wei Cheng, Jin-Peng Cong, Xue-Peng Huang, Fang-Fang Wang

Specialty type: Respiratory system

Provenance and peer review:

Unsolicited article; Externally peer reviewed.

Peer-review model: Single blind

Peer-review report's scientific quality classification

Grade A (Excellent): 0
Grade B (Very good): 0
Grade C (Good): C
Grade D (Fair): D
Grade E (Poor): 0

P-Reviewer: Moshref L, Saudi Arabia; Yorioka N, Japan

Received: October 13, 2021

Peer-review started: October 13, 2021

First decision: December 10, 2021

Revised: December 27, 2021

Accepted: April 3, 2022

Article in press: April 3, 2022

Published online: May 26, 2022



Ya-Nan Zhang, Mei-Hua Wang, Wen-Cheng Yu, Wei Cheng, Jin-Peng Cong, Fang-Fang Wang, Department of Respiratory and Critical Care Medicine, The Affiliated Hospital of Qingdao University, Qingdao 266000, Shandong Province, China

Xue-Peng Huang, Department of Respiratory and Critical Care Medicine, People's Hospital of Rizhao Lanshan, Rizhao 276800, Shandong Province, China

Corresponding author: Fang-Fang Wang, Doctor, MD, Attending Doctor, Department of Respiratory and Critical Care Medicine, The Affiliated Hospital of Qingdao University, No. 16 Jiangsu Road, Qingdao 266000, Shandong Province, China. yaorao1984@163.com

Abstract

BACKGROUND

In most cases of yellow nail syndrome (YNS), the classic triad of yellow nails, lymphedema and respiratory manifestations rarely manifest simultaneously. Therefore, diagnosis is delayed or frequently missed.

CASE SUMMARY

We report a 62-year-old YNS patient presenting with bilateral pleural, pericardial and peritoneal effusions who, 2 mo later, developed minimal-change nephrotic syndrome. After treatment with vitamin E, clarithromycin and prednisone for 3 mo, effusions in the chest, pericardium and abdominal cavity decreased while urine protein levels returned to within normal ranges.

CONCLUSION

Clinicians should consider the possibility of YNS for patients presenting with multiple serous effusions and nephrotic syndromes.

Key Words: Yellow nail syndrome; Pleural effusion; Pericardial effusion; Peritoneal effusion; Nephrotic syndrome; Case report

©The Author(s) 2022. Published by Baishideng Publishing Group Inc. All rights reserved.

Core Tip: Yellow nail syndrome (YNS) is a rare disease characterized by yellow nails, lymphedema and respiratory manifestations. However, few patients have a complete triad. We present a rare case of the classical triad in a patient with concomitant minimal-change nephrotic syndrome. And as far as we know, this is the first report about multiple effusions caused by YNS. This case highlights the variety of clinical manifestations, especially in comorbid cases, leading to delayed or missed diagnosis. Therefore, once YNS is considered, it is recommended to improve relevant examinations of the lymphatic system for further determinations.

Citation: Zhang YN, Wang MH, Yu WC, Cheng W, Cong JP, Huang XP, Wang FF. Yellow nail syndrome accompanied by minimal-change nephrotic syndrome: A case report. *World J Clin Cases* 2022; 10(15): 4949-4956

URL: <https://www.wjgnet.com/2307-8960/full/v10/i15/4949.htm>

DOI: <https://dx.doi.org/10.12998/wjcc.v10.i15.4949>

INTRODUCTION

Yellow nail syndrome (YNS) is a rare disorder characterized by yellow nails, lymphedema, and respiratory manifestations; two of which are sufficient for the diagnosis of YNS. The complete triad is present only in 27% to 60% of patients[1], and symptoms may occur years apart, which delays diagnosis. Adults aged > 50 years are highly susceptible to this disease, and a few pediatric cases have been reported[2,3]. Currently, the pathogenesis of YNS has not been fully elucidated. Some cases have previously been reported in families[4], with most members acquiring the disease. Lymphatic involvement and microvasculopathy are the most important pathological changes. In this report, we describe a case of YNS with bilateral pleural, pericardial and peritoneal effusions as well as a secondary nephrotic syndrome.

CASE PRESENTATION

Chief complaints

Dyspnea, cough, expectoration and abdominal distension for 1 mo.

History of present illness

A 62-year-old man presented with a 1-mo history of dyspnea, cough, expectoration and abdominal distension. Due to mild proteinuria, hypoalbuminemia and elevated blood creatinine levels, he was diagnosed with glomerulonephritis at the local hospital, and was treated with diuretics and drugs to lower urine protein levels. Despite treatment, dyspnea worsened. Therefore he was referred to our hospital for further treatment.

History of past illness

The patient reported no history of hepatitis, tuberculosis or heart disease before.

Personal and family history

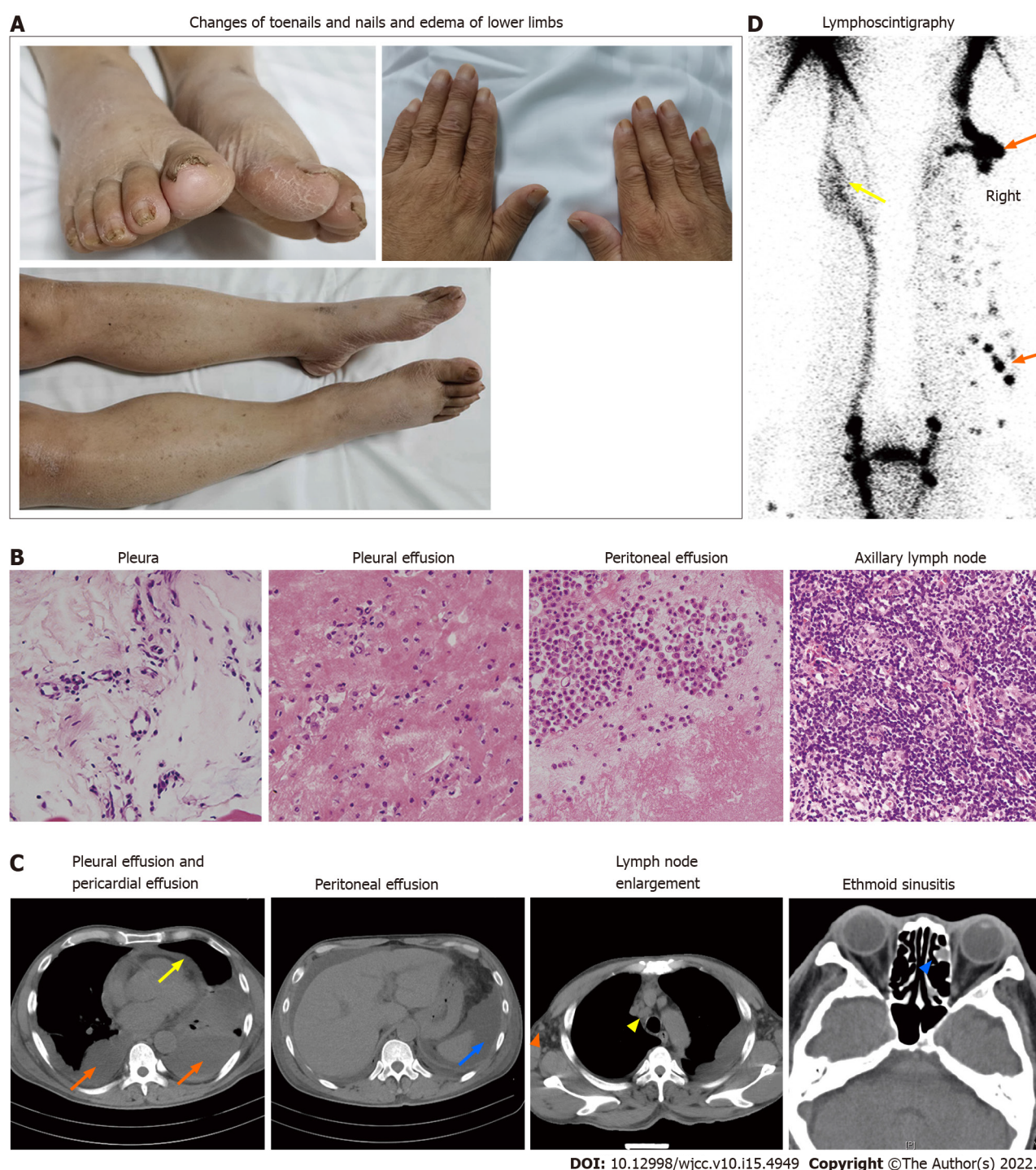
The patient reported no personal or family history.

Physical examination

Physical examination revealed multiple effusions in the chest, pericardium and abdominal cavity, accompanied by nonpitting edema of the chest and abdominal walls, as well as pitting edema of both lower limbs (heavier in the right lower limb). The patient's toenails were thickened and yellow, with increased curvature and slow growth (0.2 mm/wk), as were his nails (Figure 1A).

Laboratory examinations

Clinical assessment revealed mild proteinuria (0.32 g/24 h), severe hypoalbuminemia (23.39 g/L), elevated serum creatinine levels (139 μ mol/L) and D-dimer (3270 pg/mL) levels. Even though white blood cell counts were elevated (11.33×10^9 /L), the neutrophil/lymphocyte ratio was normal. Blood coagulation, electrolytes, serum lipids, antinuclear antibodies, extractable nuclear antigens spectrum, antineutrophil cytoplasmic antibodies, immunoglobulin (κ and λ light chains), hepatitis virus detection, double-stranded DNA, tumor markers, T-cell interferon- release assays and B-type natriuretic peptide were all normal. We performed bilateral thoracentesis and abdominal puncture to detect tuberculosis and tumors. Both pleural and peritoneal effusions were composed of exudates, mainly lymphocytes



DOI: 10.12998/wjcc.v10.i15.4949 Copyright ©The Author(s) 2022.

Figure 1 Clinical findings and laboratory examination of the patient. A: Nails and toenails were thickened and yellow, with increased curvature. Edema was found in both lower limbs, especially in the right side; B: No tumor cells or granulomatous structures were found in hematoxylin and eosin staining images (400×) of pleura, pleural effusion, peritoneal effusion and axillary lymph nodes; C: Computed tomography (CT) images showed bilateral pleural effusions (orange arrows), pericardial effusions (yellow arrow), and peritoneal effusions (blue arrow); positron emission tomography (PET)/CT images showed enlarged axillary (orange triangle) and mediastinal (yellow triangle) lymph nodes and ethmoid sinusitis (blue triangle); D: Radionuclide lymphoscintigraphy showed that lymphatic vessels of the right lower limb were interrupted, the imaging agent (^{99}Tc -antimony sulfide colloid) was accumulated in the subcutaneous tissue (orange arrows) and collateral circulation appeared in the lymphatic vessels below the left knee (yellow arrows).

(60% and 77%, respectively). Chyle test of the pleural fluid was positive. There were no tumor cells in the pleura, pleural as well as peritoneal effusions (Figure 1B), and the tuberculosis nucleic acid test was negative. Lymph node biopsy (right axillary) (Figure 1B) revealed proliferative lesions of the lymphoid tissue, lymphatic sinuses and lymphoid follicles. The toenails were negative for fungi or parasites.

Imaging examinations

Effusions in these areas, subcutaneous edema, pleural thickening, and enlarged axillary as well as

mediastinal lymph nodes were confirmed by computed tomography (CT) (Figure 1C). Positron emission tomography (PET)/CT scans revealed multiple symmetrical distributions of enlarged lymph nodes in the neck, chest, abdomen, pelvis, and left ethmoid sinusitis (Figure 1C). Doppler echocardiography revealed pericardial effusion and a mild decrease of the left ventricular diastolic function. Radionuclide lymphoscintigraphy revealed interrupted lymphatic vessels of the right lower limb, with the imaging agent being accumulated in subcutaneous tissues, inguinal lymph nodes on the right side were not clear, and lymphatic vessels of the left lower limb exhibited collateral circulations (Figure 1D).

FINAL DIAGNOSIS

YNS.

TREATMENT

The patient was treated with vitamin E (0.6 g/d) and clarithromycin (0.5 g/d).

OUTCOME AND FOLLOW-UP

After 1 mo of treatment, dyspnea, pleural effusions, pericardial effusions, ascites and systemic edema were relieved (Figure 2A). However, proteinuria was significantly elevated (4.87 g/24 h). Renal biopsy confirmed minimal-change nephrotic syndrome (Figure 3A and B). The combination of clinical and laboratory findings revealed that the patient had nephrotic syndrome. Therefore, he was treated with oral metoprolol (8 mg/d). Two months later, his proteinuria had been relieved. The clinical course and therapy of the patients are shown in Figure 4.

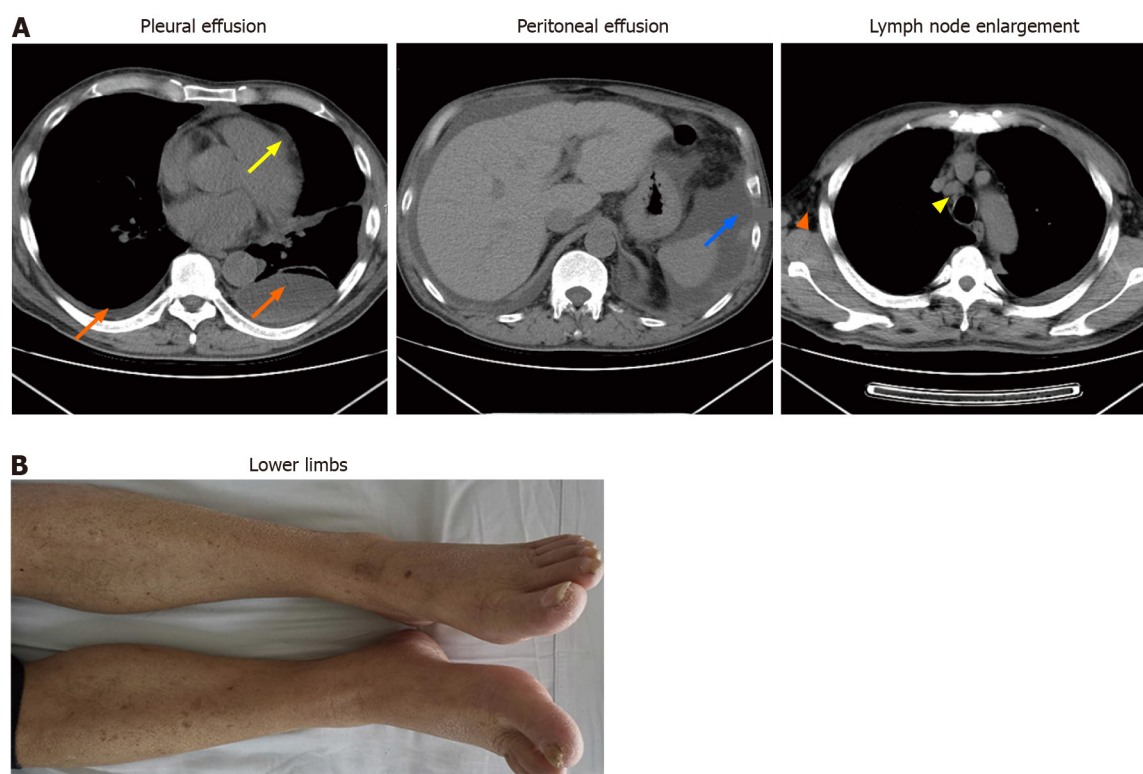
DISCUSSION

The first case of YNS was reported by Heller in 1927. The prevalence of YNS has not been fully established; however, based on the number of reported cases, it is estimated that it is less than 1/1000000[5]. Moreover, its pathogenesis has not been conclusively evaluated. At present, it is considered to be as a result of abnormal lymphatic functions, including lymphatic dysplasia, chylothorax and obstructed lymphatic drainage caused by lymphatic vessel damage, among others. YNS patients also present with various comorbidities, including nephrotic syndrome, endocrine diseases, infections and malignant tumors[6-9]. There may also be complications caused by abnormal lymphatic functions in different parts.

Yellow nail is a characteristic manifestation of YNS. The patients have dark nail discoloration, which varies from pale yellow to more or less dark green, thickening of the nail layer, excess bending, onycholysis and slow growth[5]. These physical signs can appear alone, without lymphedema or respiratory manifestations. Our patient's toenails were thickened and yellow, with increased curvature and slow growth (0.2 mm/wk), as were his nails (Figure 1A). Microscopic examination of nail slices revealed that normal loose fibrous blood vessels had been replaced with dense collagen fibers[10]. Accumulation of the lipofuscin pigment explains the yellow discoloration. These pathological changes are attributed to poor lymph drainage under the nail[11].

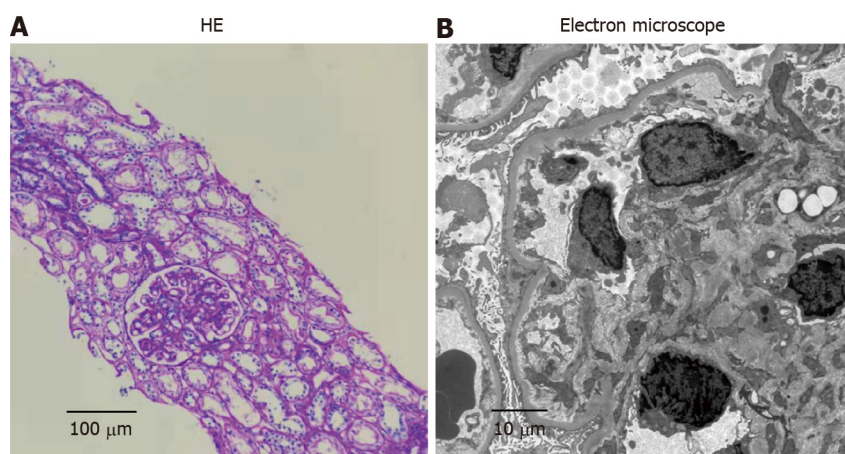
Lung involvement in YNS, which occurs in 56%-71% of the patients, diversely affects some parts of the respiratory tract with a variety of clinical manifestations[5]. Chronic cough, pleural effusion and bronchiectasis are common pulmonary manifestations of YNS[12]. In a meta-analysis, 68.3% of the YNS patients had bilateral pleural effusions and 95% of effusions were described as exudates (median protein level: 4.2 g/dL) with lymphocytic predominance in 96%[13]. In our case, bilateral pleural effusions were the main clinical manifestation (Figure 1C) and presented as chylothorax exudates. These findings are consistent with those of a previous report[14]. Thoracic duct and lymphatic vessel rupture or obstruction in the thoracic cavity is associated with lymph accumulation in the pleural cavity to produce chylothorax. Besides, the patient developed pericardial and peritoneal effusions (Figure 1C). As far as we know, this is the first report about multiple effusions caused by YNS.

Lymphedema has been reported in 29%-80% of previous cases, and may be the first signal to seek medical care[12]. Lymphedema mainly affects both lower limbs[14]. Lymphoscintigraphy is an effective imaging modality that is widely used for differential diagnosis of lymphedema and for determining the extent of the disease[15]. Lymphoscintigraphy of this case revealed that lymphatic vessels of the right lower limb were interrupted and collateral circulation appeared in the lymphatic vessels below the left knee which resulted in edema of both lower limbs (Figure 1D).



DOI: 10.12998/wjcc.v10.i15.4949 Copyright ©The Author(s) 2022.

Figure 2 Clinical findings and laboratory examination of the patient after treatment. A: bilateral pleural effusion (orange arrow), pericardial effusion (yellow arrow) and peritoneal effusion (blue arrow) decreased significantly after treatment; the enlarged lymph nodes in the axilla (orange triangle) and mediastinum (yellow triangle) shrink to the normal range; B: The edema in both lower limbs resolved.



DOI: 10.12998/wjcc.v10.i15.4949 Copyright ©The Author(s) 2022.

Figure 3 Renal biopsy confirmed the diagnosis of minimal-change nephrotic syndrome. A: Mild glomerular mesangial hyperplasia under light microscopy (200×); B: Glomerular podocytes fusion under electron microscopy (2500×).

Sinusitis is common among YNS patients. A previous study reported that 44 of 85 YNS patients had chronic rhinosinusitis, which presented with nasal/postnasal drainage (94%), obstruction/congestion (81%), facial pain/pressure (33%) and anosmia (8%)[16]. Sinusitis of this patient was confirmed by imaging studies, with no obvious symptoms (Figure 1C). There are many causes of sinusitis, including microbial infections, allergies, and abnormal anatomical structures. The lymphatic tissue plays an important role in immune responses.

In addition, YNS patients can also present with multiple comorbidities, including nephrotic syndrome, endocrine diseases, infections, and malignant neoplasms. There are three reports on the presence of nephrotic syndrome in YNS[17-19]; two of which were minimal nephritic syndrome change. At the time of reporting, clinical examination of this case was almost complete, and diseases associated with related symptoms such as infections, tumor and immunity excluded. Due to heavy proteinuria, a

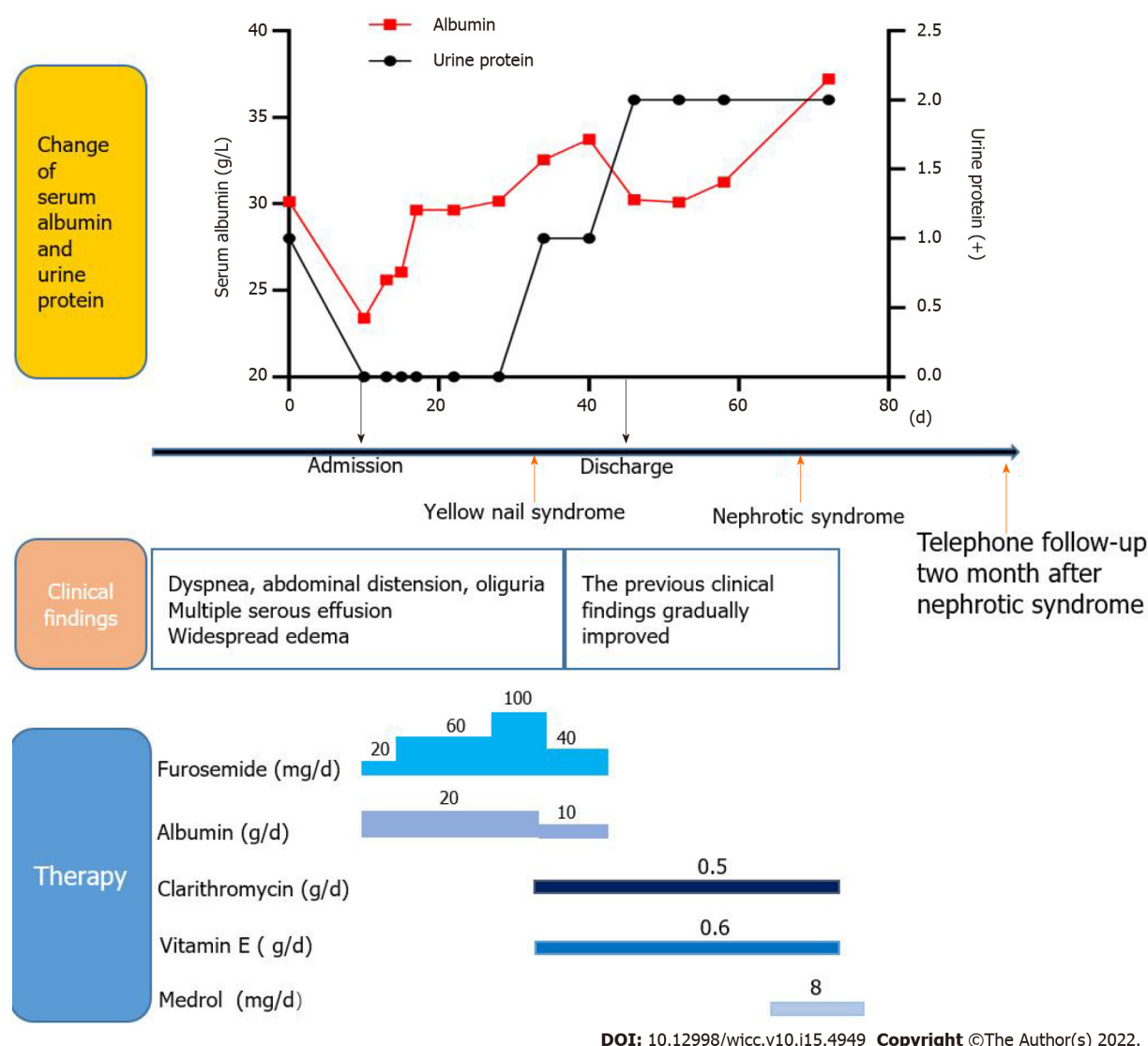


Figure 4 The changes of serum albumin and urinary protein, clinical manifestations and therapeutic drugs were summarized in chronological order.

diagnosis of nephrotic syndrome was made, and subsequent renal biopsy confirmed minimal-change nephrotic syndrome (Figure 3), similar to a previous report[19]. The pathogenic association between YNS and minimal change nephrotic syndrome is unclear. Yáñez *et al*[18] suggested a causal relationship between the two disorders. Gupta *et al*[20] found a striking deficiency of naive CD4⁺ and CD8⁺ T cells and total B cells, and increased transitional B cells in YNS patients. Furthermore, the dysfunction of T cells and B cells has been confirmed to play a central role in minimal change nephrotic syndrome[21]. We postulate that YNS patients may have extensive lymphatic dysfunctions, and renal lymphatic drainage is blocked, resulting in antibody stasis and deposition in the glomerular capillary network, leading to pathophysiological changes of nephrotic syndromes.

The main therapeutic options for YNS include clinical management of yellow nails, pleural effusion and lymphedema. Vitamin E is also a potential therapeutic option, although its efficacy and putative mechanisms have not been established. Somatostatin analogs, primarily octreotide, have also been used to treat pleural effusions and lymphedema, with varying outcomes[5]. In YNS patients, anti-inflammatory activities of macrolides might improve systemic inflammation, which reduces lymphedema and promotes nail growth[22]. Algain[23] reported the first and only case of a YNS patient who failed to respond to fluconazole and vitamin E, but showed near-complete recovery after administration with terbinafine and topical minoxidil. In this case, the patient was administered with vitamin E, clarithromycin and oral metoprolol. Subsequently, his dyspnea, pleural effusions, pericardial effusions, ascites and systemic edema (Figure 2A and B) were relieved, hypoalbuminemia was also corrected, while proteinuria gradually reduced.

CONCLUSION

The classic triad is not present in many cases of YNS, especially in comorbid cases, leading to delayed or missed diagnosis. Once YNS is considered, it is recommended to improve relevant examinations of the lymphatic system for further determinations. There is a need to establish a more systematic, comprehensive as well as standardized diagnosis and treatment options for this disease.

FOOTNOTES

Author contributions: Cheng W and Wang MH analyzed and interpreted the patient data regarding the disease; Cong JP and Wang MH performed the histological examination of the pleura and pleural effusion; Huang XP performed the histological examination of kidney; Zhang YN and Wang FF was major contributors in writing the manuscript; Yu WC reviewed and corrected the manuscript; all authors issued final approval for the version to be submitted.

Informed consent statement: All study participants, or their legal guardian, provided informed written consent prior to study enrollment.

Conflict-of-interest statement: The authors declare that they have no conflict of interest.

CARE Checklist (2016) statement: The authors have read the CARE Checklist (2016), and the manuscript was prepared and revised according to the CARE Checklist (2016).

Open-Access: This article is an open-access article that was selected by an in-house editor and fully peer-reviewed by external reviewers. It is distributed in accordance with the Creative Commons Attribution NonCommercial (CC BY-NC 4.0) license, which permits others to distribute, remix, adapt, build upon this work non-commercially, and license their derivative works on different terms, provided the original work is properly cited and the use is non-commercial. See: <https://creativecommons.org/licenses/by-nc/4.0/>

Country/Territory of origin: China

ORCID number: Ya-Nan Zhang 0000-0002-5382-6944; Mei-Hua Wang 0000-0002-7876-0726; Wen-Cheng Yu 0000-0001-8274-2742; Wei Cheng 0000-0002-2965-5698; Jin-Peng Cong 0000-0003-2638-8667; Xue-Peng Huang 0000-0002-1578-6219; Fang-Fang Wang 0000-0003-1954-5660.

S-Editor: Liu JH

L-Editor: Kerr C

P-Editor: Liu JH

REFERENCES

- 1 **Aslam MZ**, De Loughry G, O'Brien B. Anaesthesia and orphan diseases: Yellow nail syndrome. *Eur J Anaesthesiol* 2020; **37**: 728-730 [PMID: 32692084 DOI: 10.1097/EJA.0000000000001169]
- 2 **Hsu TY**, Lin CC, Lee MD, Chang BP, Tsai JD. Titanium Dioxide in Toothpaste Causing Yellow Nail Syndrome. *Pediatrics* 2017; **139** [PMID: 27940507 DOI: 10.1542/peds.2016-0546]
- 3 **Cecchini M**, Doumit J, Kanigsberg N. Atypical presentation of congenital yellow nail syndrome in a 2-year-old female. *J Cutan Med Surg* 2013; **17**: 66-68 [PMID: 23364154 DOI: 10.2310/7750.2012.12015]
- 4 **Razi E**. Familial yellow nail syndrome. *Dermatol Online J* 2006; **12**: 15 [PMID: 16638408]
- 5 **Vignes S**, Baran R. Yellow nail syndrome: a review. *Orphanet J Rare Dis* 2017; **12**: 42 [PMID: 28241848 DOI: 10.1186/s13023-017-0594-4]
- 6 **Emerson PA**. Yellow nails, lymphoedema, and pleural effusions. *Thorax* 1966; **21**: 247-253 [PMID: 5914998 DOI: 10.1136/thx.21.3.247]
- 7 **Beer DJ**, Pereira W Jr, Snider GL. Pleural effusion associated with primary lymphedema: a perspective on the yellow nail syndrome. *Am Rev Respir Dis* 1978; **117**: 595-599 [PMID: 629489 DOI: 10.1164/arrd.1978.117.3.595]
- 8 **Lewis M**, Kallenbach J, Zaltzman M, Conlan A, Zwi S, Abramowitz J. Pleurectomy in the management of massive pleural effusion associated with primary lymphoedema: demonstration of abnormal pleural lymphatics. *Thorax* 1983; **38**: 637-639 [PMID: 6612658 DOI: 10.1136/thx.38.8.637]
- 9 **Uchida T**, Uchida Y, Takahashi M, Masaki K, Sato H, Iemura H, Shinomiya S, Nakamura H, Nagata M. Yellow Nail Syndrome in Which Intranodal Lymphangiography Contributed to the Diagnosis. *Intern Med* 2021; **60**: 3599-3603 [PMID: 34092726 DOI: 10.2169/internalmedicine.6499-20]
- 10 **DeCoste SD**, Imber MJ, Baden HP. Yellow nail syndrome. *J Am Acad Dermatol* 1990; **22**: 608-611 [PMID: 2319021 DOI: 10.1016/0190-9622(90)70081-r]
- 11 **Norton L**. Further observations on the yellow nail syndrome with therapeutic effects of oral alpha-tocopherol. *Cutis* 1985; **36**: 457-462 [PMID: 4075838]
- 12 **Piraccini BM**, Urciuoli B, Starace M, Tosti A, Balestri R. Yellow nail syndrome: clinical experience in a series of 21

- patients. *J Dtsch Dermatol Ges* 2014; **12**: 131-137 [PMID: [24134631](#) DOI: [10.1111/ddg.12216](#)]
- 13 **Valdés L**, Huggins JT, Gude F, Ferreiro L, Alvarez-Dobaño JM, Golpe A, Toubes ME, González-Barcala FJ, José ES, Sahn SA. Characteristics of patients with yellow nail syndrome and pleural effusion. *Respirology* 2014; **19**: 985-992 [PMID: [25123563](#) DOI: [10.1111/resp.12357](#)]
- 14 **Maldonado F**, Ryu JH. Yellow nail syndrome. *Curr Opin Pulm Med* 2009; **15**: 371-375 [PMID: [19373089](#) DOI: [10.1097/MCP.0b013e32832ad45a](#)]
- 15 **Kwon HR**, Hwang JH, Mun GH, Hyun SH, Moon SH, Lee KH, Choi JY. Predictive role of lymphoscintigraphy undergoing lymphovenous anastomosis in patients with lower extremity lymphedema: a preliminary study. *BMC Med Imaging* 2021; **21**: 188 [PMID: [34879819](#) DOI: [10.1186/s12880-021-00713-1](#)]
- 16 **Gutierrez CN**, Low CM, Stokken JK, Choby G, O'Brien EK. Characterization of Sinus Disease in Patients with Yellow Nail Syndrome. *Am J Rhinol Allergy* 2020; **34**: 156-161 [PMID: [31603343](#) DOI: [10.1177/1945892419881253](#)]
- 17 **Cockram CS**, Richards P. Yellow nails and nephrotic syndrome. *Br J Dermatol* 1979; **101**: 707-709 [PMID: [534618](#) DOI: [10.1111/j.1365-2133.1979.tb05651.x](#)]
- 18 **Yáñez S**, Val-Bernal JF, Fernández-Llaca H. Yellow nails and minimal change nephrotic syndrome. *Nephron* 1999; **82**: 180-182 [PMID: [10364711](#) DOI: [10.1159/000045395](#)]
- 19 **Sakiyama T**, Shimizu T, Funakoshi T, Saito M. Case of yellow nail syndrome accompanied by nephrotic syndrome. *J Dermatol* 2016; **43**: 585-586 [PMID: [26704457](#) DOI: [10.1111/1346-8138.13239](#)]
- 20 **Gupta S**, Samra D, Yel L, Agrawal S. T and B cell deficiency associated with yellow nail syndrome. *Scand J Immunol* 2012; **75**: 329-335 [PMID: [21995335](#) DOI: [10.1111/j.1365-3083.2011.02653.x](#)]
- 21 **Kim SH**, Park SJ, Han KH, Kronbichler A, Saleem MA, Oh J, Lim BJ, Shin JI. Pathogenesis of minimal change nephrotic syndrome: an immunological concept. *Korean J Pediatr* 2016; **59**: 205-211 [PMID: [27279884](#) DOI: [10.3345/kjp.2016.59.5.205](#)]
- 22 **Matsubayashi S**, Suzuki M, Suzuki T, Shiozawa A, Kobayashi K, Ishii S, Iikura M, Izumi S, Kudo K, Sugiyama H. Effectiveness of clarithromycin in patients with yellow nail syndrome. *BMC Pulm Med* 2018; **18**: 138 [PMID: [30111321](#) DOI: [10.1186/s12890-018-0707-4](#)]
- 23 **Algain M**. Yellow Nail Syndrome Successfully Treated with Oral Terbinafine and Topical Minoxidil. *Clin Cosmet Investig Dermatol* 2021; **14**: 249-252 [PMID: [33746514](#) DOI: [10.2147/CCID.S301197](#)]



Published by **Baishideng Publishing Group Inc**
7041 Koll Center Parkway, Suite 160, Pleasanton, CA 94566, USA

Telephone: +1-925-3991568

E-mail: bpgoffice@wjgnet.com

Help Desk: <https://www.f6publishing.com/helpdesk>

<https://www.wjgnet.com>

