

World Journal of *Clinical Cases*

World J Clin Cases 2022 May 26; 10(15): 4713-5123



EDITORIAL

- 4713 Diet and intestinal bacterial overgrowth: Is there evidence?

Souza C, Rocha R, Cotrim HP

MINIREVIEWS

- 4717 Definition and classification of acute-on-chronic liver diseases

Zhang YY, Meng ZJ

- 4726 Management of neurosurgical patients during coronavirus disease 2019 pandemics: The Ljubljana, Slovenia experience

Velmar T, Bosnjak R

ORIGINAL ARTICLE

Clinical and Translational Research

- 4737 Glycolytic and fatty acid oxidation genes affect the treatment and prognosis of liver cancer

Zou JY, Huang YJ, He J, Tang ZX, Qin L

- 4761 Detection of a novel panel of 24 genes with high frequencies of mutation in gastric cancer based on next-generation sequencing

Zeng HH, Yang Z, Qiu YB, Bashir S, Li Y, Xu M

Case Control Study

- 4776 Outcomes of cervical degenerative disc disease treated by anterior cervical discectomy and fusion with self-locking fusion cage

Zhang B, Jiang YZ, Song QP, An Y

- 4785 Impact of COVID-19 pandemic on clinicopathological features of transplant recipients with hepatocellular carcinoma: A case-control study

Akbulut S, Sahin TT, Ince V, Yilmaz S

Retrospective Study

- 4799 Risk factors and optimal predictive scoring system of mortality for children with acute paraquat poisoning

Song Y, Wang H, Tao YH

- 4810 Application effect of thoracoscopic tricuspid valvuloplasty in geriatric patients with tricuspid valve disease

Jiang W, Long XM, Wei KQ, Li SC, Zhang Z, He BF, Li H

- 4818 Endoscopic ultrasonography in the evaluation of condition and prognosis of ulcerative colitis

Jin RF, Chen YM, Chen RP, Ye HJ

- 4827** Dynamic interaction nursing intervention on functional rehabilitation and self-care ability of patients after aneurysm surgery

Xie YE, Huang WC, Li YP, Deng JH, Huang JT

Clinical Trials Study

- 4836** Validations of new cut-offs for surgical drains management and use of computerized tomography scan after pancreatoduodenectomy: The DALCUT trial

Caputo D, Coppola A, La Vaccara V, Passa R, Carbone L, Ciccozzi M, Angeletti S, Coppola R

Observational Study

- 4843** Psychosocial adaptation and influencing factors among patients with chemotherapy-induced peripheral neuropathy

Zhou X, Wang DY, Ding CY, Liu H, Sun ZQ

META-ANALYSIS

- 4856** Outcome of the efficacy of Chinese herbal medicine for functional constipation: A systematic review and meta-analysis

Lyu Z, Fan Y, Bai Y, Liu T, Zhong LL, Liang HF

CASE REPORT

- 4878** Familial gastrointestinal stromal tumors with *KIT* germline mutation in a Chinese family: A case report

Yuan W, Huang W, Ren L, Xu C, Luan LJ, Huang J, Xue AW, Fang Y, Gao XD, Shen KT, Lv JH, Hou YY

- 4886** Nonfunctional pancreatic neuroendocrine tumours misdiagnosed as autoimmune pancreatitis: A case report and review of literature

Lin ZQ, Li X, Yang Y, Wang Y, Zhang XY, Zhang XX, Guo J

- 4895** Sudden deafness as a prodrome of cerebellar artery infarction: Three case reports

Li BL, Xu JY, Lin S

- 4904** Importance of abdominal X-ray to confirm the position of levonorgestrel-releasing intrauterine system: A case report

Maebayashi A, Kato K, Hayashi N, Nagaishi M, Kawana K

- 4911** Bedside ultrasonic localization of the nasogastric tube in a patient with severe COVID-19: A case report

Zhu XJ, Liu SX, Li QT, Jiang YJ

- 4917** Paradoxical herniation after decompressive craniectomy provoked by mannitol: A case report

Du C, Tang HJ, Fan SM

- 4923** Targeted next-generation sequencing identifies a novel nonsense mutation in ANK1 for hereditary spherocytosis: A case report

Fu P, Jiao YY, Chen K, Shao JB, Liao XL, Yang JW, Jiang SY

- 4929** Nonfunctional bladder paraganglioma misdiagnosed as hemangioma: A case report

Chen J, Yang HF

- 4935** Special type of Werneck syndrome in midbrain infarction: Four case reports
Yang YZ, Hu WX, Zhai HJ
- 4942** Primary extraskeletal Ewing's sarcoma of the lumbar nerve root: A case report
Lei LH, Li F, Wu T
- 4949** Yellow nail syndrome accompanied by minimal-change nephrotic syndrome: A case report
Zhang YN, Wang MH, Yu WC, Cheng W, Cong JP, Huang XP, Wang FF
- 4957** Total femur replacement with 18 years of follow-up: A case report
Yang YH, Chen JX, Chen QY, Wang Y, Zhou YB, Wang HW, Yuan T, Sun HP, Xie L, Yao ZH, Yang ZZ
- 4964** Male metaplastic breast cancer with poor prognosis: A case report
Kim HY, Lee S, Kim DI, Jung CS, Kim JY, Nam KJ, Choo KS, Jung YJ
- 4971** CD8-positive indolent T-Cell lymphoproliferative disorder of the gastrointestinal tract: A case report and review of literature
Weng CY, Ye C, Fan YH, Lv B, Zhang CL, Li M
- 4985** Bone flare after initiation of novel hormonal therapy in patients with metastatic hormone-sensitive prostate cancer: A case report
Li KH, Du YC, Yang DY, Yu XY, Zhang XP, Li YX, Qiao L
- 4991** Postoperative infection of the skull base surgical site due to suppurative parotitis: A case report
Zhao Y, Zhao Y, Zhang LQ, Feng GD
- 4998** Blunt aortic injury-traumatic aortic isthmus pseudoaneurysm with right iliac artery dissection aneurysm: A case report
Fang XX, Wu XH, Chen XF
- 5005** Extensive complex thoracoabdominal aortic aneurysm salvaged by surgical graft providing landing zone for endovascular graft: A case report
Jang AY, Oh PC, Kang JM, Park CH, Kang WC
- 5012** Gastric heterotopia of colon found cancer workup in liver abscess: A case report
Park JG, Suh JI, Kim YU
- 5018** Clinical manifestations and gene analysis of Hutchinson-Gilford progeria syndrome: A case report
Zhang SL, Lin SZ, Zhou YQ, Wang WQ, Li JY, Wang C, Pang QM
- 5025** Neurocutaneous melanosis with an intracranial cystic-solid meningeal melanoma in an adult: A case report and review of literature
Liu BC, Wang YB, Liu Z, Jiao Y, Zhang XF
- 5036** Metastasis of liver cancer to the thyroid after surgery: A case report
Zhong HC, Sun ZW, Cao GH, Zhao W, Ma K, Zhang BY, Feng YJ

- 5042** Spontaneous liver rupture following SARS-CoV-2 infection in late pregnancy: A case report
Ambrož R, Stašek M, Molnár J, Špička P, Klos D, Hambálek J, Skanderová D
- 5051** Carotid blowout syndrome caused by chronic infection: A case report
Xie TH, Zhao WJ, Li XL, Hou Y, Wang X, Zhang J, An XH, Liu LT
- 5057** Is repeat wide excision plus radiotherapy of localized rectal melanoma another choice before abdominoperineal resection? A case report
Chiu HT, Pu TW, Yen H, Liu T, Wen CC
- 5064** Metaplastic breast cancer with chondrosarcomatous differentiation combined with concurrent bilateral breast cancer: A case report
Yang SY, Li Y, Nie JY, Yang ST, Yang XJ, Wang MH, Zhang J
- 5072** Rare solitary splenic metastasis from a thymic carcinoma detected on fluorodeoxyglucose-positron emission tomography: A case report
Tsai YH, Lin KH, Huang TW
- 5077** Type A aortic dissection following heart transplantation: A case report
Zeng Z, Yang LJ, Zhang C, Xu F
- 5082** Catheter-related infections caused by *Mycobacterium abscessus* in a patient with motor neurone disease: A case report
Pan SF, Zhang YY, Wang XZ, Sun JJ, Song SL, Tang YR, Wang JL
- 5088** Clear aligner treatment for a four-year-old patient with anterior cross-bite and facial asymmetry: A case report
Zou YR, Gan ZQ, Zhao LX
- 5097** Knot impingement after arthroscopic rotator cuff repair mimicking infection: A case report
Kim DH, Jeon JH, Choi BC, Cho CH
- 5103** Solitary primary pulmonary synovial sarcoma: A case report
He WW, Huang ZX, Wang WJ, Li YL, Xia QY, Qiu YB, Shi Y, Sun HM
- 5111** Anesthetic management for intraoperative acute pulmonary embolism during inferior vena cava tumor thrombus surgery: A case report
Hsu PY, Wu EB
- 5119** Delayed diagnosis of arytenoid cartilage dislocation after tracheal intubation in the intensive care unit: A case report
Yan WQ, Li C, Chen Z

ABOUT COVER

Editorial Board Member of *World Journal of Clinical Cases*, Jing Yang, MD, Associate Professor, Department of the First General Surgery, Gansu Provincial Hospital, Lanzhou 730000, Gansu Province, China. 21634604@qq.com

AIMS AND SCOPE

The primary aim of *World Journal of Clinical Cases* (WJCC, *World J Clin Cases*) is to provide scholars and readers from various fields of clinical medicine with a platform to publish high-quality clinical research articles and communicate their research findings online.

WJCC mainly publishes articles reporting research results and findings obtained in the field of clinical medicine and covering a wide range of topics, including case control studies, retrospective cohort studies, retrospective studies, clinical trials studies, observational studies, prospective studies, randomized controlled trials, randomized clinical trials, systematic reviews, meta-analysis, and case reports.

INDEXING/ABSTRACTING

The WJCC is now indexed in Science Citation Index Expanded (also known as SciSearch®), Journal Citation Reports/Science Edition, Scopus, PubMed, and PubMed Central. The 2021 Edition of Journal Citation Reports® cites the 2020 impact factor (IF) for WJCC as 1.337; IF without journal self cites: 1.301; 5-year IF: 1.742; Journal Citation Indicator: 0.33; Ranking: 119 among 169 journals in medicine, general and internal; and Quartile category: Q3. The WJCC's CiteScore for 2020 is 0.8 and Scopus CiteScore rank 2020: General Medicine is 493/793.

RESPONSIBLE EDITORS FOR THIS ISSUE

Production Editor: Ying-Yi Yuan; **Production Department Director:** Xiang Li; **Editorial Office Director:** Jin-Lei Wang.

NAME OF JOURNAL

World Journal of Clinical Cases

ISSN

ISSN 2307-8960 (online)

LAUNCH DATE

April 16, 2013

FREQUENCY

Thrice Monthly

EDITORS-IN-CHIEF

Bao-Gan Peng, Jerzy Tadeusz Chudek, George Kontogeorgos, Maurizio Serati, Ja Hyeon Ku

EDITORIAL BOARD MEMBERS

<https://www.wjgnet.com/2307-8960/editorialboard.htm>

PUBLICATION DATE

May 26, 2022

COPYRIGHT

© 2022 Baishideng Publishing Group Inc

INSTRUCTIONS TO AUTHORS

<https://www.wjgnet.com/bpg/gerinfo/204>

GUIDELINES FOR ETHICS DOCUMENTS

<https://www.wjgnet.com/bpg/GerInfo/287>

GUIDELINES FOR NON-NATIVE SPEAKERS OF ENGLISH

<https://www.wjgnet.com/bpg/gerinfo/240>

PUBLICATION ETHICS

<https://www.wjgnet.com/bpg/GerInfo/288>

PUBLICATION MISCONDUCT

<https://www.wjgnet.com/bpg/gerinfo/208>

ARTICLE PROCESSING CHARGE

<https://www.wjgnet.com/bpg/gerinfo/242>

STEPS FOR SUBMITTING MANUSCRIPTS

<https://www.wjgnet.com/bpg/GerInfo/239>

ONLINE SUBMISSION

<https://www.f6publishing.com>



Total femur replacement with 18 years of follow-up: A case report

Yi-Hao Yang, Jia-Xiang Chen, Qiu-Yun Chen, Yu Wang, Yao-Bin Zhou, Hong-Wei Wang, Tao Yuan, Hong-Pu Sun, Lin Xie, Zhi-Hong Yao, Zuo-Zhang Yang

Specialty type: Orthopedics

Provenance and peer review:

Unsolicited article; Externally peer reviewed.

Peer-review model: Single blind

Peer-review report's scientific quality classification

Grade A (Excellent): 0
Grade B (Very good): 0
Grade C (Good): C
Grade D (Fair): D
Grade E (Poor): 0

P-Reviewer: Hakozaiki M, Japan;
Limaïem F, Tunisia

Received: October 17, 2021

Peer-review started: October 17, 2021

First decision: December 17, 2021

Revised: December 27, 2021

Accepted: April 9, 2022

Article in press: April 9, 2022

Published online: May 26, 2022



Yi-Hao Yang, Jia-Xiang Chen, Qiu-Yun Chen, Yu Wang, Tao Yuan, Hong-Pu Sun, Zhi-Hong Yao, Zuo-Zhang Yang, Department of Orthopaedics, The Third Affiliated Hospital of Kunming Medical University, Yunnan Cancer Hospital, Yunnan Cancer Center, Kunming 650118, Yunnan Province, China

Yao-Bin Zhou, Hong-Wei Wang, Department of Orthopaedics, The People's Hospital of Fuyuan, Fuyuan County, Qujing 655500, Yunnan Province, China

Lin Xie, Department of Medical Oncology, The Third Affiliated Hospital of Kunming Medical University, Yunnan Cancer Hospital, Yunnan Cancer Center, Kunming 650118, Yunnan Province, China

Corresponding author: Zuo-Zhang Yang, MD, Professor, Department of Orthopaedics, The Third Affiliated Hospital of Kunming Medical University, Yunnan Cancer Hospital, Yunnan Cancer Center, No 519 Kunzhou Road, Xishan District, Kunming 650118, Yunnan Province, China. yangzuo Zhang@163.com

Abstract

BACKGROUND

Osteosarcoma is one of the most common primary malignant bone tumors and is more common in adolescents. The femur is the most common site of osteosarcoma, and many patients require total femur replacement. We reviewed the relevant literature and case findings, summarized and analyzed this case in combination with relevant literature, and in doing so improved the understanding of the technology.

CASE SUMMARY

The case we report was a 15-year-old patient who was admitted to the hospital 15 days after the discovery of a right thigh mass. The diagnosis was osteosarcoma of the right femoral shaft. After completion of neoadjuvant chemotherapy and preoperative preparation, total right femoral resection + artificial total femoral replacement was performed. Then, chemotherapy was continued after surgery. The patient recovered well after treatment, and the function of the affected limb was good. No recurrence, metastasis, prosthesis loosening, dislocation, fracture or other complications were found during 18 years of follow-up. At present, the patient can still work and lives normally. The results of the medium- and long-term follow-up were satisfactory.

CONCLUSION

Artificial total femur replacement is a feasible limb salvage operation for patients

with femoral malignant tumors, and the results of medium- and long-term follow-up are satisfactory.

Key Words: Total femur replacement; Osteosarcoma; Medium and long-term follow-up; Case report

©The Author(s) 2022. Published by Baishideng Publishing Group Inc. All rights reserved.

Core Tip: Artificial total femur replacement is a feasible limb salvage operation for patients with femoral malignant tumors, and the results of medium- and long-term follow-up are satisfactory.

Citation: Yang YH, Chen JX, Chen QY, Wang Y, Zhou YB, Wang HW, Yuan T, Sun HP, Xie L, Yao ZH, Yang ZZ. Total femur replacement with 18 years of follow-up: A case report. *World J Clin Cases* 2022; 10(15): 4957-4963

URL: <https://www.wjgnet.com/2307-8960/full/v10/i15/4957.htm>

DOI: <https://dx.doi.org/10.12998/wjcc.v10.i15.4957>

INTRODUCTION

Osteosarcoma is one of the most common primary malignant bone tumors and is more common in adolescents[1] than in adults. Since the 1970s, with the application of neoadjuvant chemotherapy, the 5-year survival rate of osteosarcoma patients has exceeded 70%[2]. After the 20th century, due to the development of reconstruction materials and surgical techniques, limb salvage has become the mainstream treatment for limb osteosarcoma patients, and 85% of patients in early and middle stages can undergo limb salvage therapy[3]. Osteosarcoma can occur in bones throughout the body, with the femur being the most common site of osteosarcoma, usually in the metaphysis of the femur[4]. However, as the frequency of cases increase, several abnormalities in case presentation stand out; for example, tumors may have jumping lesions at the other end of the femur; malignant tumors in the proximal or distal tumors may have a wide range of invasion, reaching or even exceeding 1/2 of the femur; and backbone malignant tumors involve the proximal and distal femurs. In these cases, only hip amputation or hemipelvic amputation can be performed. In 1965, Buchman *et al*[5] performed the world's first total femur replacement. The application of artificial total femoral replacement surgery avoids amputation, retains the movement and weight-bearing function of the affected limb, reduces psychological trauma, and greatly improves quality of life[6]. We report a case of artificial total femoral prosthesis replacement for stage IIB osteosarcoma of the femoral shaft and follow-up for 18 years. Combined with relevant literature reports, cases of this type are summarized and analyzed to improve the understanding of this procedure.

CASE PRESENTATION

Chief complaints

Find a mass in the middle and lower part of the right thigh with pain for 15 d.

History of present illness

A 15-year-old male patient was admitted to the hospital on August 5, 2003, after finding a mass in the middle to lower part of the right thigh with pain going back 15 d.

History of past illness

There was no previous history of pain.

Personal and family history

There is no history of family inheritance.

Physical examination

Physical examination demonstrated that the patient's general condition was good, and palpation of systemic superficial lymph node did not reveal swelling. No abnormalities were found in the heart, lungs or abdomen. There was localized swelling to the middle and lower thigh, and a 10 cm × 6 cm × 4 cm mass was found, characterized by hard, fixed, unclear boundaries, tenderness, increasing local skin

temperature and filling superficial veins. Left lower limb blood flow and feeling were good, and the muscle strength was grade 4.

Laboratory examinations

Blood routine was normal, ALP 222U/L.

Imaging examinations

X-ray showed osteolytic destruction of the middle and lower segments of the right femur, accompanied by a periosteal reaction (Figure 1A and B). Enneking staging was IIB.

FINAL DIAGNOSIS

Conventional osteosarcoma of the right femur (Enneking stage: G2T2M0 Stage IIB).

TREATMENT

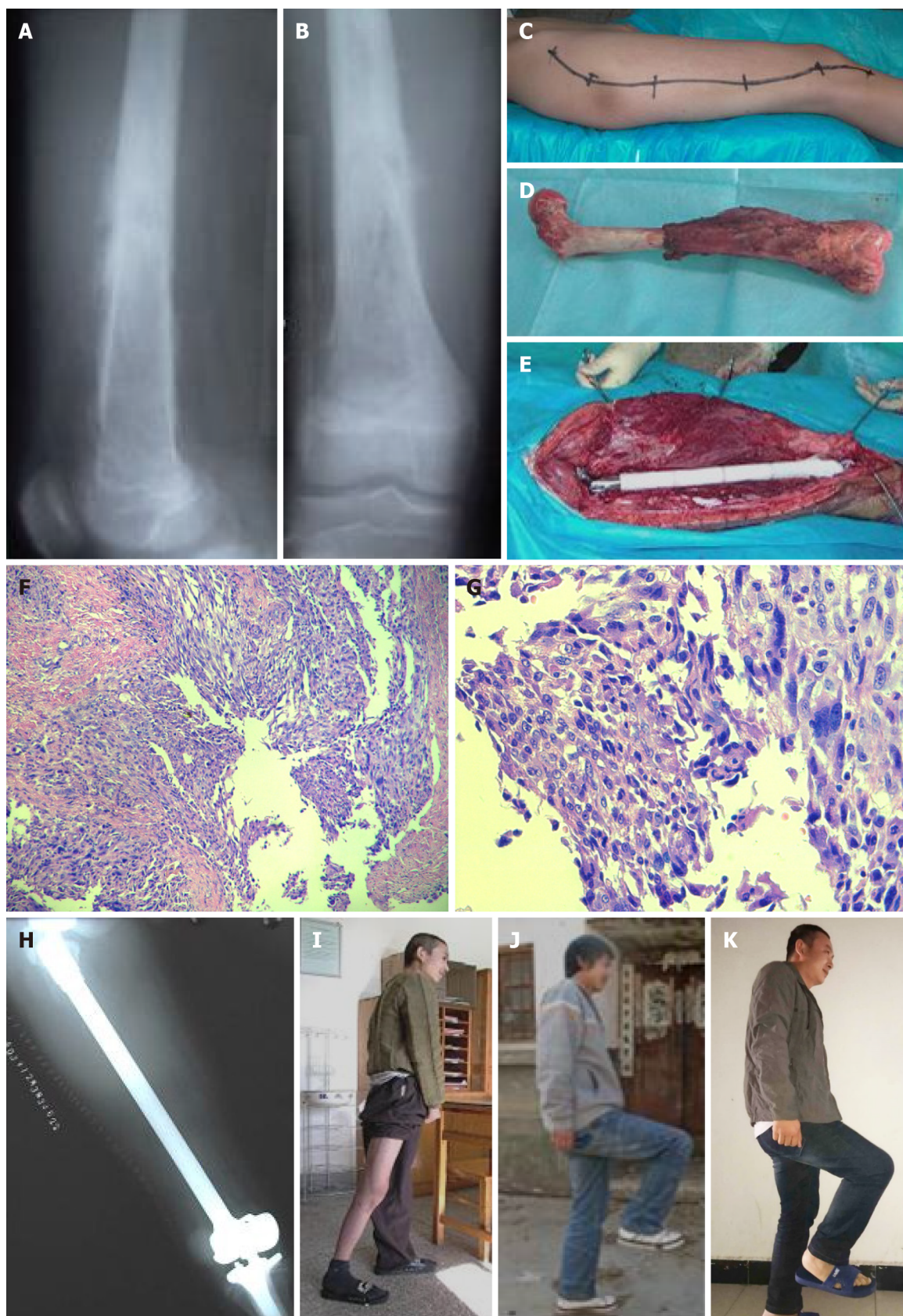
Biopsy of the mass revealed right femoral osteosarcoma. Adjuvant chemotherapy with doxorubicin, cisplatin, high-dose methotrexate and vincristine was administered on September 1, 2003. Thigh pain was relieved after chemotherapy, and the mass was reduced to 8 cm × 4 cm × 2 cm. Artificial total femoral replacement under general anesthesia (compartment resection of osteosarcoma) was performed on November 20, 2003. The Watson Jones incision of the hip joint was performed during surgery, which then extended to the outside of the knee joint along the outside of the thigh and distal end, starting from 3.5 cm above the tip of the femoral trochanter and ending at the lateral edge of the tibial tubercle (Figure 1C). The whole femur was resected at the surgical margin of the tumor response area (Figure 1D). According to tumor knee arthroplasty standards, the tibial plateau and medullary cavity were repaired, and a bone cement-type artificial tibia prosthesis was partially implanted and fixed in the tibial medullary cavity; attention was given to avoid varus or angulation deformities in the tibial axis. According to the size of the acetabulum, an appropriate double-acting femoral head was selected, and the reduction and rotation axes of the knee joint were installed (Figure 1E). The anteversion angle of the femoral neck was kept at 15-20°. To wash, establish hemostasis and repair the hip joint, large and small rotor stumps were sutured with the iliopsoas, gluteus maximus and gluteus medius to the ear-shaped holes of the artificial femur, the large and small trochanter attachments were reconstructed, the knee joint capsule was repaired, the lateral femoral muscle, tensor fascia lata, and iliotibial tract covering the prosthesis were sutured, and the subcutaneous tissue and skin were sutured. Two negative pressure drainage tubes were placed on the right hip and lateral knee. After the operation, the hip joint strap was fixed externally, the right lower limb was abducted 15-20° in a neutral position, and the patient was given "Ding" shoes to wear in order to prevent lower extremity external rotation. The drainage tube was pulled out 5 d after the operation, and the X-ray revealed that the prosthesis was in good position, with no dislocation (Figure 1H). After 5 d, the right quadriceps, ankle and toe functions were exercised. The postoperative pathological diagnosis was osteosarcoma of the right femur, which was considered conventional according to the WHO classification of bone tumors (Figure 1F-G). The sutures were removed 18 d after the operation, and incision I/a had healed. Chemotherapy was initiated 4 wk after surgery with the same scheme as before.

OUTCOME AND FOLLOW-UP

At the 6th week, the patient began to walk on crutches, kept a neutral position of abduction, and was told not to cross his knees, bend his legs, squat excessively or bend his hip no more than 90°. The patient returned to the hospital for re-examination 1 year (Figure 1I) and 4 years (Figure 1J) after surgery. Presently, the patient was followed up after 18 years (Figure 1K). There was no local tumor recurrence, with no metastasis in either lung. X-ray showed that there were no complications, including loosening, dislocation or fracture of the artificial femur. At present, the patient still works and lives normally.

LITERATURE REVIEW

To review the cases of femoral shaft malignant tumors treated by artificial whole femoral prostheses in China and abroad, we used the following literature search terms: ("total femur replacement" or "total femoral replacement" or "total femur and knee joint replacement" or "total femoral and knee joint replacement" or "total femoral endoprosthetic replacement") and ("malignant bone tumor" or "bone



DOI: 10.12998/wjcc.v10.i15.4957 Copyright ©The Author(s) 2022.

Figure 1 Imaging examinations. A and B: X-ray illustrates osteolytic destruction in the middle and lower segments of the right femur, with significant periosteal reaction; C-E: Intraoperative condition; F-G: 4×10, 40×10 magnification photomicrograph, respectively, hematoxylin and eosin; H: Postoperative X-ray; I-K: Postoperative follow up after the 1, 4 and 18 years.

neoplasm" or "bone cancer" or "bone malignant tumor" or "malignant tumor of bone" or "osteosarcoma" or "Ewing sarcoma" or "chondrosarcoma"). Our search encompassed 40 years of cases in Medline and China Zhiwang. Using this strategy, we found a total of 446 cases in 37 studies. The relevant literature reports are summarized in [Supplementary Table 1](#).

DISCUSSION

Due to existing methods of neoadjuvant chemotherapy combined with complete tumor resection and limb reconstruction have achieved satisfactory clinical results. For patients whose soft tissue conditions are not poor, the main neurovasculature is not invaded, certain limb functions can be preserved after surgery and local recurrence rate will not be increased, limb salvage surgery can be performed[7]. This osteosarcoma case included a wide range of tumor invasion and was easily combined with pathological fractures. Autologous tumor bone replantation has problems, since it is difficult to retain the intact bone shell, and the strength is reduced after inactivation of the tumor bone. Allogeneic bone replacement requires a long healing time, and has a higher propensity for fractures and joint degeneration, while artificial joints have high strength and are specially formulated according to the patient's clinical needs to fill bone defects and rebuild joint function. Patients can also bear weight and exercise soon after surgery[8]. In this case, the right femoral lesion had exceeded 1/2 the length of the femur. If lengthened knee arthroplasty had been used, the prosthesis could easily loosen due to the large leverage force and the lack of surrounding soft tissue fixation, and the tumor may recur due to the insufficient osteotomy plane. Therefore, artificial total femoral replacement was the best treatment for this case. Our experience was that during the operation, we should protect the normal muscle tissue, firmly reconstruct the attachment points of the large and small rotator muscles, repair the hip and knee joint capsule, and rebuild the muscle balance. After the operation, we should emphasize the correct posture and correct functional exercise, which plays an important role in reducing the incidence of complications and improving the limb function of patients.

Total femoral prosthesis replacement is an ideal method for removing malignant femoral tumors to preserve the limbs and maximize the function of the lower extremities. It is necessary however to pay attention to the surgical indications and case selection to determine if surgical border resection is required during the operation. Currently, the recognized surgical indications for consideration include [9-13]: (1) Malignant tumors originating from the femoral shaft accumulate in the proximal or distal femur; (2) tumors in the proximal or distal femur which have jumping lesions at the other end; (3) patients who can still save their limbs by total femoral replacement to prevent local tumor recurrence; (4) the replacement of the proximal or distal femur prosthesis or composite prosthesis fails, due to the nonunion of bone, fracture or loosening of the prosthesis, which cannot be repaired by other methods; (5) patients with multiple bone metastases on a single limb with pathological fractures who are expected to survive for > 6 mo; or (6) some benign lesions with repeated pathological fractures and long healing time and appear to have limb deformities, which have seriously affected the patient's work and quality of life. The patient described here meets indication[1]. Due to the expansion of the indications for artificial total femoral replacement, the procedure has been gradually applied to nontumor lesions, including revision of hip and knee joint replacements with serious bone defects and invalid conventional methods or serious hip and knee arthritis on the same limb side, among other conditions.

Since Buchman's first customized cobalt chromium molybdenum alloy femoral prosthesis was applied[5] the design of the whole femoral prosthesis has been improving with the progress of biomaterial technology. Early prostheses were all homemade[14], later developed into custom-made prostheses[9,15-18], and then assembled prostheses[15,16]. At present, patients can use assembled prostheses without waiting for the prosthesis to be manufactured, and they can also be assembled according to their own specific conditions. Metal materials have also evolved from titanium nitride[15] and stainless steel[19] to titanium alloys[20]. The prosthesis used in this patient was a customized titanium alloy prosthesis, and the design was based on the patient's bilateral total femoral X-ray. The length of the customized prosthesis was the same as the healthy leg or slightly shorter by 1-2 cm, and the size of the femoral head was similarly measured. A bipolar artificial femoral head is recommended to reduce the dislocation of the hip joint prosthesis[21]. The use of a rotary axis knee joint can reduce the loosening of the knee prosthesis[22]. In recent years, there have also been many special types of total femoral prostheses developed. Since traditional total femoral replacement requires the removal of many muscle attachment points, the function of the affected limb is poor after surgery, and hip dislocation is more common. Ward *et al*[10] and Gorter *et al*[23] have developed a full-femoral intramedullary prosthesis to replace the traditional full-femoral prosthesis. This surgical method retains the attachment points of some bones and muscles, maintains stability to the maximum extent, and yields better function. Additionally, complications of hip dislocation cannot easily occur, and the risk of incision infection is also reduced. To solve the problem of unequal lengths of the lower limbs after total femoral replacement in children, Schindler *et al*[24] designed an extendable total femoral prosthesis. In response to the problem of deep infection and abscess formation after total femoral replacement, Glehr *et al*[25] applied a silver ion-coated total femoral prosthesis to reduce the incidence of postoperative infection.

complications.

There are few reports including long-term follow-up after total femoral replacement surgery, which are mainly based on case reports. The main reason for this is related to the poor effect of postoperative radiotherapy and chemotherapy, the early occurrence of distant metastasis and the short overall survival period. It is generally acknowledged that the first case of total femoral replacement was performed by Professor Buchman in 1965, but actually, the earliest case can be traced back to 1952 and was also performed by Professor Buchman. This case was followed up for 35 years and is also the case with the longest follow-up time reported in the literature. It was reported by Present in 1990[14]. This case was diagnosed as having multiple fibrous dysplasia in the left femur and secondary low-grade chondrosarcoma. Thirty-two years after total femoral replacement, the patient underwent hip arthroplasty due to severe pain in the thigh and sinus formation. Postoperative examination showed that there was no recurrence of the tumor. Nakamura *et al*[21] reported 2 patients with total femoral replacement surgery, including over 10 years of follow-up. One case was diagnosed as osteosarcoma with skin necrosis that occurred after the operation requiring a skin graft. There was no loosening, dislocation or local recurrence of the prosthesis after 12 years of follow-up. The MSTS score of the postoperative patients was 60%. Another patient was diagnosed with Ewing's sarcoma, and sciatic nerve palsy occurred after surgery, requiring external fixation and crutches. After 11 years of follow-up, no prosthesis loosening, dislocation, or local recurrence was found. The functional MSTS score of the patient after operation was 63%. The patient in this paper was followed up for 18 years. The patient did not experience local tumor recurrence or distant metastasis. The images suggest that the prosthesis has not been loosened, dislocated, or broken. The patient could walk normally on crutches, and the current MSTS score was reported as 67%.

CONCLUSION

Artificial total femur replacement is a feasible limb salvage operation for patients with femoral malignant tumors, and the results of medium- and long-term follow-up are satisfactory.

FOOTNOTES

Author contributions: Yang YH collected the data of case, reviewed the literatures and drafted the manuscripts; Chen JX and Chen QY help to collect the data of the case; Yang ZZ, Yuan T, and Sun HP carried out the operation and revised the manuscript; Xie L and Yao ZH reviewed the literatures and revised the manuscript; Wang Y, Zhou YB and Wang HW were collecting medical images; all authors read and approved the final manuscript; Yang YH, Chen JX, Chen QY, Wang Y, Zhou YB, and Wang HW are co-first authors.

Supported by National Natural Science Foundation of China, No. 81972764, and No. 81960488; the Joint Special Funds for the Department of Science and Technology of Yunnan Province-Kunming Medical University, No. 2018FE001-060, and No. 2019FE001-152; Scientific Research Projects of Internal Research Institutions of Medical and Health Units in Yunnan Province, No. 2017NS196, No. 2017NS197, and No. 2018NS069.

Informed consent statement: The patient and the families were informed that related data and attached images in the case would be submitted for publication. Since they had signed the Informed Consent Form.

Conflict-of-interest statement: The authors declare that they have no conflicts of interests.

CARE Checklist (2016) statement: The authors have read the CARE Checklist (2016), and the manuscript was prepared and revised according to the CARE Checklist (2016).

Open-Access: This article is an open-access article that was selected by an in-house editor and fully peer-reviewed by external reviewers. It is distributed in accordance with the Creative Commons Attribution NonCommercial (CC BY-NC 4.0) license, which permits others to distribute, remix, adapt, build upon this work non-commercially, and license their derivative works on different terms, provided the original work is properly cited and the use is non-commercial. See: <https://creativecommons.org/licenses/by-nc/4.0/>

Country/Territory of origin: China

ORCID number: Yi-Hao Yang 0000-0001-5284-8749; Jia-Xiang Chen 0000-0002-2022-2298; Qiu-Yun Chen 0000-0003-3347-1194; Yu Wang 0000-0001-9249-7947; Yao-Bin Zhou 0000-0002-8158-302X; Hong-Wei Wang 0000-0001-7649-0622; Tao Yuan 0000-0002-5494-8003; Hong-Pu Sun 0000-0002-3924-418X; Lin Xie 0000-0001-8455-8121; Zhi-Hong Yao 0000-0003-2616-9704; Zuo-Zhang Yang 0000-0002-0763-5805.

S-Editor: Liu JH

L-Editor: A

P-Editor: Liu JH

REFERENCES

- 1 Yang Y, Han L, He Z, Li X, Yang S, Yang J, Zhang Y, Li D, Yang Y, Yang Z. Advances in limb salvage treatment of osteosarcoma. *J Bone Oncol* 2018; 10: 36-40 [PMID: 29296558 DOI: 10.1016/j.jbo.2017.11.005]
- 2 Bernthal NM, Federman N, Eilber FR, Nelson SD, Eckardt JJ, Eilber FC, Tap WD. Long-term results (>25 years) of a randomized, prospective clinical trial evaluating chemotherapy in patients with high-grade, operable osteosarcoma. *Cancer* 2012; 118: 5888-5893 [PMID: 22648705 DOI: 10.1002/cncr.27651]
- 3 Federman N, Bernthal N, Eilber FC, Tap WD. The multidisciplinary management of osteosarcoma. *Curr Treat Options Oncol* 2009; 10: 82-93 [PMID: 19238553 DOI: 10.1007/s11864-009-0087-3]
- 4 Yao W, Cai Q, Wang J, Gao S. Treatment of osteosarcoma around the knee in skeletally immature patients. *Oncol Lett* 2017; 14: 5241-5248 [PMID: 29113159 DOI: 10.3892/ol.2017.6903]
- 5 Buchman J. Total femur and knee joint replacement with a vitallium endoprosthesis. *Bull Hosp Joint Dis* 1965; 26: 21-34 [PMID: 14333593 DOI: 10.5373/jardcs/v12sp4/20201511]
- 6 Yonemoto T, Kamibeppu K, Ishii T, Iwata S, Hagiwara Y, Tatezaki S. Psychosocial outcomes in long-term survivors of high-grade osteosarcoma: a Japanese single-center experience. *Anticancer Res* 2009; 29: 4287-4290 [PMID: 19846988 DOI: 10.1159/000113038]
- 7 Fujiki M, Kimura T, Takushima A. Limb-salvage surgery with vascular reconstruction after lower extremity sarcoma resection: A systematic review and meta-analysis. *Microsurgery* 2020; 40: 404-413 [PMID: 31903669 DOI: 10.1002/micr.30553]
- 8 Plötz W, Rechl H, Burgkart R, Messmer C, Schelter R, Hipp E, Gradingner R. Limb salvage with tumor endoprostheses for malignant tumors of the knee. *Clin Orthop Relat Res* 2002; 207-215 [PMID: 12461376 DOI: 10.1097/00003086-200212000-00027]
- 9 Marcove RC, Lewis MM, Rosen G, Huvoos AG. Total femur and total knee replacement. A preliminary report. *Clin Orthop Relat Res* 1977; 147-152 [PMID: 271530 DOI: 10.1097/00003086-197707000-00024]
- 10 Ward WG, Dorey F, Eckardt JJ. Total femoral endoprosthetic reconstruction. *Clin Orthop Relat Res* 1995; 195-206 [PMID: 7634705 DOI: 10.1097/00003086-199507000-00027]
- 11 Guo C, Gan L, Tu ZQ. Total femoral prosthesis replacement in the treatment of recurrent osteosarcoma. *Huaxi Yixue Za Zhi* 2003; 86-87 [DOI: 10.3969/j.issn.1002-0179.2003.01.066]
- 12 Berend KR, Lombardi AV Jr, Mallory TH, Adams JB, Dodds KL. Total femoral arthroplasty for salvage of end-stage prosthetic disease. *Clin Orthop Relat Res* 2004; 162-170 [PMID: 15552153 DOI: 10.1097/01.blo.0000142351.88039.e8]
- 13 Lombardi AV Jr, Berend KR. The shattered femur: radical solution options. *J Arthroplasty* 2006; 21: 107-111 [PMID: 16781442 DOI: 10.1016/j.arth.2006.01.007]
- 14 Present DA, Kuschner SH. Total femur replacement. A case report with 35-year follow-up study. *Clin Orthop Relat Res* 1990; 166-167 [PMID: 2295169 DOI: 10.1097/00003086-199002000-00027]
- 15 Hu QT, Jiang QW, Su GL, Shen JZ, Shen X. Total femur and adjacent joint replacement with endoprosthesis: report of 2 cases. *Chin Med J (Engl)* 1980; 93: 86-89 [PMID: 6768517 DOI: 10.2106/00004623-198163010-00023]
- 16 Steinbrink K, Engelbrecht E, Fenelon GC. The total femoral prosthesis. A preliminary report. *J Bone Joint Surg Br* 1982; 64: 305-312 [PMID: 7096396 DOI: 10.1302/0301-620x.64b3.7096396]
- 17 Capanna R, Ruggieri P, Biagini R, Gamberini G, Rock M, Campanacci M. Subtotal and total femoral resection: an alternative to total femoral prosthetic replacement. *Int Orthop* 1986; 10: 121-126 [PMID: 27743061 DOI: 10.1007/bf00267753]
- 18 Nerubay J, Katznelson A, Tichler T, Rubinstein Z, Morag B, Bubis JJ. Total femoral replacement. *Clin Orthop Relat Res* 1988; 143-148 [PMID: 3349669 DOI: 10.1097/00003086-198804000-00018]
- 19 Natarajan MV, Balasubramanian N, Jayasankar V, Sameer M. Endoprosthetic reconstruction using total femoral custom mega prosthesis in malignant bone tumours. *Int Orthop* 2009; 33: 1359-1363 [PMID: 19259671 DOI: 10.1007/s00264-009-0737-x]
- 20 Ahmed AR. Total femur replacement. *Arch Orthop Trauma Surg* 2010; 130: 171-176 [PMID: 19644695 DOI: 10.1007/s00402-009-0945-2]
- 21 Nakamura S, Kusuzaki K, Murata H, Takeshita H, Hirata M, Hashiguchi S, Hirasawa Y. More than 10 years of follow-up of two patients after total femur replacement for malignant bone tumor. *Int Orthop* 2000; 24: 176-178 [PMID: 10990394 DOI: 10.1007/s002640000145]
- 22 Sevelde F, Schuh R, Hofstaetter JG, Schinhan M, Windhager R, Funovics PT. Total Femur Replacement After Tumor Resection: Limb Salvage Usually Achieved But Complications and Failures are Common. *Clin Orthop Relat Res* 2015; 473: 2079-2087 [PMID: 25832007 DOI: 10.1007/s11999-015-4282-1]
- 23 Gorter J, Ploegmakers JJW, Ten Have BLEF, Schreuder HWB, Jutte PC. The push-through total femoral prosthesis offers a functional alternative to total femoral replacement: a case series. *Int Orthop* 2017; 41: 2237-2244 [PMID: 28361217 DOI: 10.1007/s00264-017-3467-5]
- 24 Schindler OS, Cannon SR, Briggs TW, Blunn GW, Grimer RJ, Walker PS. Use of extendable total femoral replacements in children with malignant bone tumors. *Clin Orthop Relat Res* 1998; 157-170 [PMID: 9917713 DOI: 10.1097/00003086-199812000-00021]
- 25 Glehr M, Leithner A, Friesenbichler J, Goessler W, Avian A, Andreou D, Maurer-Ertl W, Windhager R, Tunn PU. Argyria following the use of silver-coated megaprostheses: no association between the development of local argyria and elevated silver levels. *Bone Joint J* 2013; 95-B: 988 [PMID: 23814255 DOI: 10.1302/0301-620X.95B7.31124]



Published by **Baishideng Publishing Group Inc**
7041 Koll Center Parkway, Suite 160, Pleasanton, CA 94566, USA

Telephone: +1-925-3991568

E-mail: bpgoffice@wjgnet.com

Help Desk: <https://www.f6publishing.com/helpdesk>

<https://www.wjgnet.com>

