

# World Journal of *Clinical Cases*

*World J Clin Cases* 2022 June 16; 10(17): 5518-5933



### MINIREVIEWS

- 5518** Occult hepatitis B — the result of the host immune response interaction with different genomic expressions of the virus  
*Gherlan GS*
- 5531** Pulmonary complications of portal hypertension: The overlooked decompensation  
*Craciun R, Mocan T, Procopet B, Nemes A, Tefas C, Sparchez M, Mocan LP, Sparchez Z*
- 5541** Ethical review of off-label drugs during the COVID-19 pandemic  
*Li QY, Lv Y, An ZY, Dai NN, Hong X, Zhang Y, Liang LJ*

### ORIGINAL ARTICLE

#### Case Control Study

- 5551** Gut peptide changes in patients with obstructive jaundice undergoing biliary drainage: A prospective case control study  
*Pavić T, Pelajić S, Blažević N, Kralj D, Milošević M, Mikolasevic I, Lerotic I, Hrabar D*

#### Retrospective Cohort Study

- 5566** Longitudinal assessment of liver stiffness by transient elastography for chronic hepatitis C patients  
*Mezina A, Krishnan A, Woreta TA, Rubenstein KB, Watson E, Chen PH, Rodriguez-Watson C*

#### Retrospective Study

- 5577** Clinical evaluation of prone position ventilation in the treatment of acute respiratory distress syndrome induced by sepsis  
*Xia WH, Yang CL, Chen Z, Ouyang CH, Ouyang GQ, Li QG*
- 5586** Three-dimensional arterial spin labeling and diffusion kurtosis imaging in evaluating perfusion and infarct area size in acute cerebral ischemia  
*Jiang YY, Zhong ZL, Zuo M*
- 5595** Intrathecal methotrexate in combination with systemic chemotherapy in glioblastoma patients with leptomeningeal dissemination: A retrospective analysis  
*Kang X, Chen F, Yang SB, Wang YL, Qian ZH, Li Y, Lin H, Li P, Peng YC, Wang XM, Li WB*
- 5606** Hepatic epithelioid hemangioendothelioma: Clinical characteristics, diagnosis, treatment, and prognosis  
*Zhao M, Yin F*
- 5620** Difference between type 2 gastroesophageal varices and isolated fundic varices in clinical profiles and portosystemic collaterals  
*Song YH, Xiang HY, Si KK, Wang ZH, Zhang Y, Liu C, Xu KS, Li X*

- 5634** Assessment of incidental focal colorectal uptake by analysis of fluorine-18 fluorodeoxyglucose positron emission tomography parameters

*Lee H, Hwang KH, Kwon KA*

### Observational Study

- 5646** "Zero ischemia" laparoscopic partial nephrectomy by high-power GreenLight laser enucleation for renal carcinoma: A single-center experience

*Zhang XM, Xu JD, Lv JM, Pan XW, Cao JW, Chu J, Cui XG*

- 5655** High Eckardt score and previous treatment were associated with poor postperoral endoscopic myotomy pain control: A retrospective study

*Chen WN, Xu YL, Zhang XG*

- 5667** Higher volume growth rate is associated with development of worrisome features in patients with branch duct-intraductal papillary mucinous neoplasms

*Innocenti T, Danti G, Lynch EN, Dragoni G, Gottin M, Fedeli F, Palatresi D, Biagini MR, Milani S, Miele V, Galli A*

### Prospective Study

- 5680** Application of a new anatomic hook-rod-pedicle screw system in young patients with lumbar spondylolysis: A pilot study

*Li DM, Li YC, Jiang W, Peng BG*

### META-ANALYSIS

- 5690** Systematic review of Yougui pills combined with levothyroxine sodium in the treatment of hypothyroidism

*Liu XP, Zhou YN, Tan CE*

### CASE REPORT

- 5702** Allogeneic stem cell transplantation-A curative treatment for paroxysmal nocturnal hemoglobinuria with PIGT mutation: A case report

*Schenone L, Notarantonio AB, Latger-Cannard V, Fremeaux-Bacchi V, De Carvalho-Bittencourt M, Rubio MT, Muller M, D'Aveni M*

- 5708** Gray zone lymphoma effectively treated with cyclophosphamide, doxorubicin, vincristine, prednisolone, and rituximab chemotherapy: A case report

*Hojo N, Nagasaki M, Mihara Y*

- 5717** Diagnosis of spontaneous isolated superior mesenteric artery dissection with ultrasound: A case report

*Zhang Y, Zhou JY, Liu J, Bai C*

- 5723** Adrenocorticotrophic hormone-secreting pancreatic neuroendocrine carcinoma with multiple organ infections and widespread thrombosis: A case report

*Yoshihara A, Nishihama K, Inoue C, Okano Y, Eguchi K, Tanaka S, Maki K, Fridman D'Alessandro V, Takeshita A, Yasuma T, Uemura M, Suzuki T, Gabazza EC, Yano Y*

- 5732** Management of the palato-radicular groove with a periodontal regenerative procedure and prosthodontic treatment: A case report

*Ling DH, Shi WP, Wang YH, Lai DP, Zhang YZ*

- 5741** Combined thoracic paravertebral block and interscalene brachial plexus block for modified radical mastectomy: A case report  
*Hu ZT, Sun G, Wang ST, Li K*
- 5748** Chondromyxoid fibroma of the cervical spine: A case report  
*Li C, Li S, Hu W*
- 5756** Preterm neonate with a large congenital hemangioma on maxillofacial site causing thrombocytopenia and heart failure: A case report  
*Ren N, Jin CS, Zhao XQ, Gao WH, Gao YX, Wang Y, Zhang YF*
- 5764** Simultaneous multiple primary malignancies diagnosed by endoscopic ultrasound-guided fine-needle aspiration: A case report  
*Yang J, Zeng Y, Zhang JW*
- 5770** Neuroendocrine tumour of the descending part of the duodenum complicated with schwannoma: A case report  
*Zhang L, Zhang C, Feng SY, Ma PP, Zhang S, Wang QQ*
- 5776** Massive hemothorax following internal jugular vein catheterization under ultrasound guidance: A case report  
*Kang H, Cho SY, Suk EH, Ju W, Choi JY*
- 5783** Unilateral adrenal tuberculosis whose computed tomography imaging characteristics mimic a malignant tumor: A case report  
*Liu H, Tang TJ, An ZM, Yu YR*
- 5789** Modified membrane fixation technique in a severe continuous horizontal bone defect: A case report  
*Wang LH, Ruan Y, Zhao WY, Chen JP, Yang F*
- 5798** Surgical repair of an emergent giant hepatic aneurysm with an abdominal aortic dissection: A case report  
*Wen X, Yao ZY, Zhang Q, Wei W, Chen XY, Huang B*
- 5805** Heterotopic ossification beneath the upper abdominal incision after radical gastrectomy: Two case reports  
*Zhang X, Xia PT, Ma YC, Dai Y, Wang YL*
- 5810** Non-alcoholic Wernicke encephalopathy in an esophageal cancer patient receiving radiotherapy: A case report  
*Zhang Y, Wang L, Jiang J, Chen WY*
- 5816** New approach for the treatment of vertical root fracture of teeth: A case report and review of literature  
*Zhong X, Yan P, Fan W*
- 5825** Ultrasound-guided microwave ablation as a palliative treatment for mycosis fungoides eyelid involvement: A case report  
*Chen YW, Yang HZ, Zhao SS, Zhang Z, Chen ZM, Feng HH, An MH, Wang KK, Duan R, Chen BD*
- 5833** Pulp revascularization on an adult mandibular right second premolar: A case report  
*Yang YQ, Wu BL, Zeng JK, Jiang C, Chen M*

- 5841** Barrett's esophagus in a patient with bulimia nervosa: A case report  
*Gouda A, El-Kassas M*
- 5846** Spontaneous gallbladder perforation and colon fistula in hypertriglyceridemia-related severe acute pancreatitis: A case report  
*Wang QP, Chen YJ, Sun MX, Dai JY, Cao J, Xu Q, Zhang GN, Zhang SY*
- 5854** Beware of gastric tube in esophagectomy after gastric radiotherapy: A case report  
*Yurttas C, Wichmann D, Gani C, Bongers MN, Singer S, Thiel C, Koenigsrainer A, Thiel K*
- 5861** Transition from minimal change disease to focal segmental glomerulosclerosis related to occupational exposure: A case report  
*Tang L, Cai Z, Wang SX, Zhao WJ*
- 5869** Lung adenocarcinoma metastasis to paranasal sinus: A case report  
*Li WJ, Xue HX, You JQ, Chao CJ*
- 5877** Follicular lymphoma presenting like marginal zone lymphoma: A case report  
*Peng HY, Xiu YJ, Chen WH, Gu QL, Du X*
- 5884** Primary renal small cell carcinoma: A case report  
*Xie K, Li XY, Liao BJ, Wu SC, Chen WM*
- 5893** Gitelman syndrome: A case report  
*Chen SY, Jie N*
- 5899** High-frame-rate contrast-enhanced ultrasound findings of liver metastasis of duodenal gastrointestinal stromal tumor: A case report and literature review  
*Chen JH, Huang Y*
- 5910** Tumor-like disorder of the brachial plexus region in a patient with hemophilia: A case report  
*Guo EQ, Yang XD, Lu HR*
- 5916** Response to dacomitinib in advanced non-small-cell lung cancer harboring the rare delE709\_T710insD mutation: A case report  
*Xu F, Xia ML, Pan HY, Pan JW, Shen YH*
- 5923** Loss of human epidermal receptor-2 in human epidermal receptor-2+ breast cancer after neoadjuvant treatment: A case report  
*Yu J, Li NL*

**LETTER TO THE EDITOR**

- 5929** Repetitive transcranial magnetic stimulation for post-traumatic stress disorder: Lights and shadows  
*Concerto C, Lanza G, Fisticaro F, Pennisi M, Rodolico A, Torrisi G, Bella R, Aguglia E*

**ABOUT COVER**

Editorial Board Member of *World Journal of Clinical Cases*, Raden Andri Primadhi, MD, PhD, Assistant Professor, Surgeon, Department of Orthopaedics and Traumatology, Universitas Padjadjaran Medical School, Hasan Sadikin Hospital, Bandung 40161, Indonesia. randri@unpad.ac.id

**AIMS AND SCOPE**

The primary aim of *World Journal of Clinical Cases* (WJCC, *World J Clin Cases*) is to provide scholars and readers from various fields of clinical medicine with a platform to publish high-quality clinical research articles and communicate their research findings online.

WJCC mainly publishes articles reporting research results and findings obtained in the field of clinical medicine and covering a wide range of topics, including case control studies, retrospective cohort studies, retrospective studies, clinical trials studies, observational studies, prospective studies, randomized controlled trials, randomized clinical trials, systematic reviews, meta-analysis, and case reports.

**INDEXING/ABSTRACTING**

The WJCC is now indexed in Science Citation Index Expanded (also known as SciSearch®), Journal Citation Reports/Science Edition, Scopus, PubMed, and PubMed Central. The 2021 Edition of Journal Citation Reports® cites the 2020 impact factor (IF) for WJCC as 1.337; IF without journal self cites: 1.301; 5-year IF: 1.742; Journal Citation Indicator: 0.33; Ranking: 119 among 169 journals in medicine, general and internal; and Quartile category: Q3. The WJCC's CiteScore for 2020 is 0.8 and Scopus CiteScore rank 2020: General Medicine is 493/793.

**RESPONSIBLE EDITORS FOR THIS ISSUE**

Production Editor: Hua-Ge Yin, Production Department Director: Xiang Li, Editorial Office Director: Jin-Lai Wang.

**NAME OF JOURNAL**

*World Journal of Clinical Cases*

**ISSN**

ISSN 2307-8960 (online)

**LAUNCH DATE**

April 16, 2013

**FREQUENCY**

Thrice Monthly

**EDITORS-IN-CHIEF**

Bao-Gan Peng, Jerzy Tadeusz Chudek, George Kontogeorgos, Maurizio Serati, Ja Hyeon Ku

**EDITORIAL BOARD MEMBERS**

<https://www.wjgnet.com/2307-8960/editorialboard.htm>

**PUBLICATION DATE**

June 16, 2022

**COPYRIGHT**

© 2022 Baishideng Publishing Group Inc

**INSTRUCTIONS TO AUTHORS**

<https://www.wjgnet.com/bpg/gerinfo/204>

**GUIDELINES FOR ETHICS DOCUMENTS**

<https://www.wjgnet.com/bpg/GerInfo/287>

**GUIDELINES FOR NON-NATIVE SPEAKERS OF ENGLISH**

<https://www.wjgnet.com/bpg/gerinfo/240>

**PUBLICATION ETHICS**

<https://www.wjgnet.com/bpg/GerInfo/288>

**PUBLICATION MISCONDUCT**

<https://www.wjgnet.com/bpg/gerinfo/208>

**ARTICLE PROCESSING CHARGE**

<https://www.wjgnet.com/bpg/gerinfo/242>

**STEPS FOR SUBMITTING MANUSCRIPTS**

<https://www.wjgnet.com/bpg/GerInfo/239>

**ONLINE SUBMISSION**

<https://www.f6publishing.com>



Observational Study

# High Eckardt score and previous treatment were associated with poor postperoral endoscopic myotomy pain control: A retrospective study

Wan-Nan Chen, Yao-Lin Xu, Xiao-Guang Zhang

**Specialty type:** Medicine, research and experimental

**Provenance and peer review:** Unsolicited article; Externally peer reviewed.

**Peer-review model:** Single blind

**Peer-review report's scientific quality classification**

Grade A (Excellent): 0  
Grade B (Very good): 0  
Grade C (Good): 0  
Grade D (Fair): 0  
Grade E (Poor): 0

**P-Reviewer:** Cascella M, Italy;  
Pallav K, United States

**Received:** November 13, 2021

**Peer-review started:** November 13, 2021

**First decision:** December 27, 2021

**Revised:** March 25, 2022

**Accepted:** April 4, 2022

**Article in press:** April 4, 2022

**Published online:** June 16, 2022



**Wan-Nan Chen, Xiao-Guang Zhang,** Department of Anesthesia, Zhongshan Hospital, Fudan University, Shanghai 200032, China

**Yao-Lin Xu,** Department of General Surgery, Zhongshan Hospital Fudan University, Shanghai 200032, China

**Corresponding author:** Xiao-Guang Zhang, MD, Doctor, Department of Anesthesia, Zhongshan Hospital, Fudan University, No. 180 Fenglin Road, Xuhui District, Shanghai 200032, China. [zhang.xiaoguang@zs-hospital.sh.cn](mailto:zhang.xiaoguang@zs-hospital.sh.cn)

## Abstract

### BACKGROUND

Peroral endoscopic myotomy (POEM) is a safe and effective endoscopic treatment for achalasia. However, postoperative pain management for these patients is often neglected by anesthesiologists because of the short operative time, short hospital stay and the minimally invasive nature of the procedure.

### AIM

To assess the pain and sleep quality of achalasia patients receiving the POEM procedure and investigate factors that affect postoperative pain.

### METHODS

This observational study included patients with achalasia who underwent POEM at Zhongshan Hospital from December 2017 to March 2018. General anesthesia was performed with endotracheal intubation. The postoperative visual analog scale (VAS), postoperative sleep quality, basic patient information, and surgical parameters were collected. Depending on whether the 12-h post-POEM VAS score was less than 4, patients were divided into two groups, a well-controlled pain group and a poorly controlled pain group. Univariate, multivariate, and stepwise logistic regression analyses were used to investigate risk factors for poor pain control. A prediction model of post-POEM pain risk was established in the form of a nomogram. The calibration curve and receiver operating characteristic curve were used to evaluate the clinical usage of the prediction model. Repeated measures analysis of variance and simple effect analysis were used to verify whether differences in the VAS and sleep scores of the high- and low-risk groups, divided by the model from the raw data, were statistically significant.



## RESULTS

A total of 45 eligible patients were included. Multivariate logistic regression and further stepwise logistic regression analysis found that the preoperative Eckardt score [odds ratio (OR): 1.82, 95% confidence interval (CI): 1.17-2.84,  $P < 0.001$ ], previous treatment (OR: 7.59, 95% CI: 1.12-51.23,  $P = 0.037$ ) and the distance between the end of the muscle incision and the cardia (OR: 1.52, 95% CI: 0.79-293.93,  $P = 0.072$ ) were risk factors for post-POEM pain. Repeated measures analysis of variance demonstrated that VAS ( $P = 0.0097$ ) and sleep scores ( $P = 0.043$ ) were higher in the high-risk group, and the interactions between the two main effects were obvious (VAS score:  $P = 0.019$ , sleep score:  $P = 0.035$ ). Further simple effect analysis found that VAS scores were higher in the high-risk group at 2 h, 6 h and 12 h ( $P = 0.005$ ,  $P = 0.019$ ,  $P < 0.001$ ), and sleep scores were higher in the high-risk group at day 1 ( $P = 0.006$ ).

## CONCLUSION

Achalasia patients who underwent POEM experienced serious postoperative pain, which may affect sleep quality. A higher Eckardt score, previous treatment, and a longer distance between the muscle incision ending and the cardia were risk factors for poor post-POEM pain control.

**Key Words:** Achalasia; Peroral endoscopic myotomy; Anesthesia; Postoperative pain; Sleep quality; Nomogram

©The Author(s) 2022. Published by Baishideng Publishing Group Inc. All rights reserved.

**Core Tip:** Post-peroral endoscopic myotomy (POEM) pain management has been neglected by anesthesiologists and endoscopists. In the present study, we found that achalasia patients experienced moderate to severe postoperative pain after the POEM procedure. The preoperative Eckardt score, previous treatment, and a longer distance between the muscle incision ending and the cardia were high risk factors for postoperative pain.

**Citation:** Chen WN, Xu YL, Zhang XG. High Eckardt score and previous treatment were associated with poor postperoral endoscopic myotomy pain control: A retrospective study. *World J Clin Cases* 2022; 10(17): 5655-5666

**URL:** <https://www.wjgnet.com/2307-8960/full/v10/i17/5655.htm>

**DOI:** <https://dx.doi.org/10.12998/wjcc.v10.i17.5655>

## INTRODUCTION

Achalasia is a decrease in esophageal tension and esophageal dilation caused by a reduction in esophageal ganglion cells, disappearance of the thoracic esophagus, and diastolic dysfunction of the lower esophageal sphincter (LES). Clinical symptoms include dysphagia, gastroesophageal reflux, chest pain, weight loss, and anemia[1]. The incidence of achalasia is approximately 1.6/100000, regardless of sex and ethnicity, and is higher in younger patients[2-4].

Noninvasive treatments for achalasia include endoscopic botulinum toxin injection, esophageal stenting, and pneumatic balloon dilation. Invasive treatment can be performed with cardiomyotomy (also known as Heller surgery), which involves permanent surgical cutting of the LES[5,6]. In 2010, peroral endoscopic myotomy (POEM) was introduced as a clinical application by Inoue *et al*[7], and its use has rapidly spread worldwide. POEM surgery is a safe and effective treatment for achalasia, as verified by a large number of clinical studies, and has become a first-line treatment for achalasia[8], replacing Heller surgery and other noninvasive treatments.

Several published studies mainly focused on comparing the postoperative pain of achalasia patients receiving either the POEM procedure or laparoscopic Heller's myelotomy (LMH), but their conclusions were inconsistent[9-13]. Meanwhile, postoperative pain management differs among studies, varying from oral opioids and intravenous nonsteroidal anti-inflammatory drugs to intraoperative nerve block [10-12,14]. There was little general agreement on the postoperative pain management of achalasia patients. Thus, the authors conducted this retrospective study to examine the postoperative pain intensity of achalasia patients receiving the POEM procedure and to investigate possible risk factors for postoperative pain.



## MATERIALS AND METHODS

### **Patient identification and data collection**

This study was approved by the Ethics Committee of Zhongshan Hospital at Fudan University, No. B2018-004R. This was a preliminary study for a prospective study conducted at the Department of Anesthesiology within Zhongshan Hospital at Fudan University.

**Inclusion criteria:** (1) Male or female. Age between 18 and 75 years; (2) With diagnosis of achalasia; (3) Received POEM surgery in Zhongshan Hospital Fudan University from November 2017 to April 2018; (4) Complete anesthesia record and operative report; and (5) Signed informed consent.

**Exclusion criteria:** (1) Past experience with Heller surgery or POEM surgery; (2) Preoperative chronic pain management; and (3) Cognitive dysfunction or an inability to attend follow-up.

The diagnosis of achalasia was established based on the following: (1) Clinical symptoms; (2) X-ray angiography of the esophagus and sputum; (3) Esophagogastroduodenoscopy; (4) Esophageal manometry; and (5) Chest computed tomography (CT) scan[15].

### **Measurement**

The main results collected were the visual analog scale (VAS) scores at 2 h, 6 h, 12 h, 24 h, and 36 h after surgery. The secondary results collected were sleep quality on the night of surgery and on the night of the first day after surgery. A self-reported sleep questionnaire was used to investigate postoperative sleep quality, which included 6 yes-or-no questions. A score of 1 indicated the best quality sleep, and the highest score of 6 indicated the worst sleep quality. A correlation analysis of postoperative pain scores at each follow-up time with postoperative sleep quality and pain scores with related factors was performed. Related factors included the following: (1) Patient demographic information (sex, age, illness duration, disease grade and previous treatment); and (2) Surgical parameters (surgical time, anesthesia time, tunnel length, length of muscle incision, length between the muscle incision ending and the cardia, and perioperative opioid dose).

### **POEM surgical procedure**

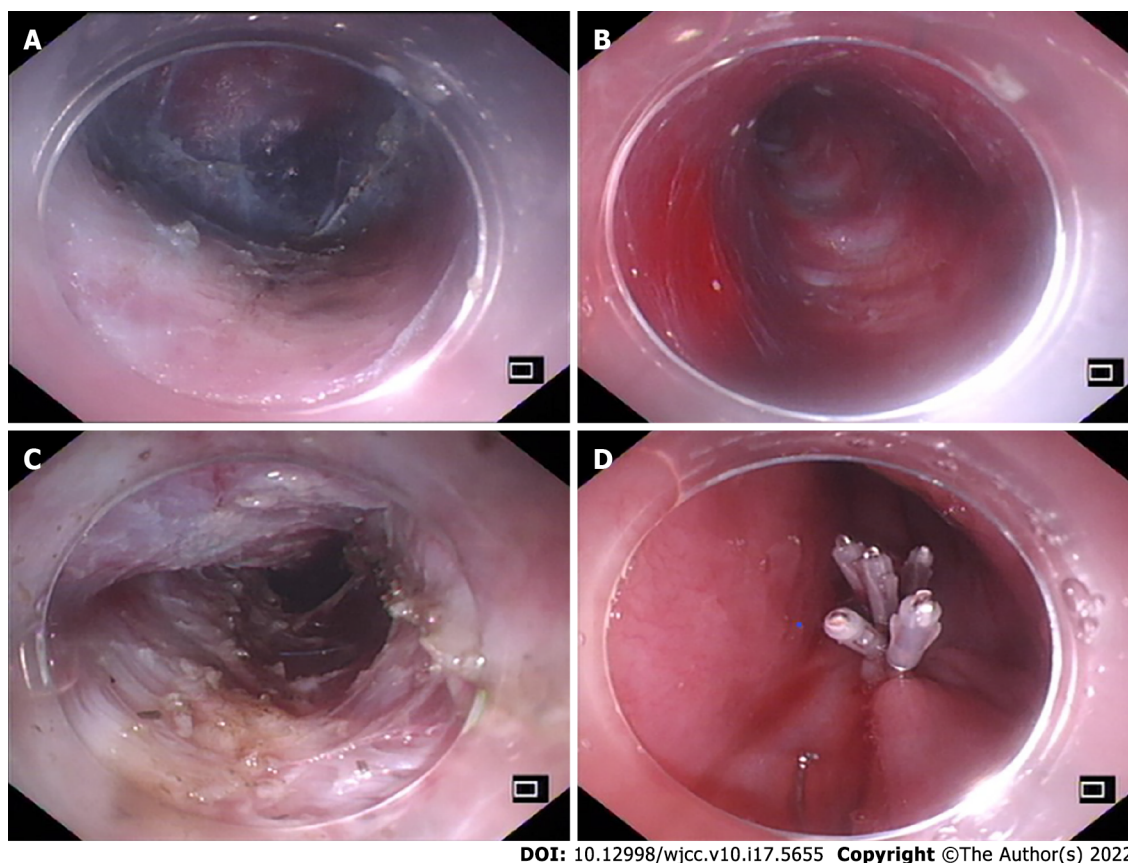
POEM surgery was performed at the endoscopy center of the hospital by endoscopic specialists who had received specialized POEM surgery training. Saline was submucosally injected 10-12 cm above the gastroesophageal junction (GEJ), and the mucosal layer was longitudinally cut to form a mucosal opening to expose the stratum submucosa (Figure 1A). Submucosal injection was performed while the mucosa was separated to form a submucosal tunnel (3-4 cm) to the distal end of the GEJ (Figure 1B). The myometrial incision was performed from the distal end of the mucosal tunnel opening at 2 cm to at least 2 cm to the distal end of the GEJ (Figure 1C). After proper hemostasis, the mucosal opening was closed with a hemostatic clip (Figure 1D). To avoid the occurrence of air-related complications, carbon dioxide inflation was continued throughout the procedure (Figure 2).

### **Anesthesia method**

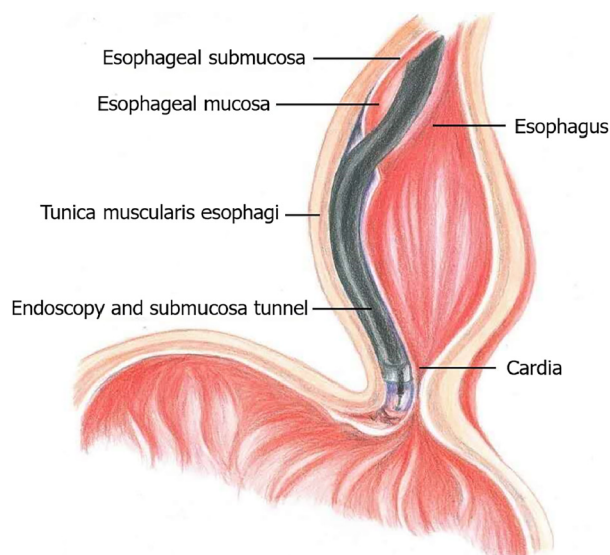
The procedures were performed on patients under general anesthesia with endotracheal intubation. Patients were maintained on carbohydrate drinks the day before the procedure, and oral intake was withheld for 12 h before the surgery. Esophagoscopy was performed while the patients were awake to clear the esophagus. Rapid sequence induction was employed with propofol (2-2.5 mg/kg), succinylcholine (2 mg/kg) and remifentanyl (1 µg/kg). Anesthesia was maintained with desflurane (0.8 MAC), fentanyl 2-4 µg/kg, remifentanyl 0.05-0.1 µg/kg *per min*. Cis-atracurium (0.03 mg/kg *per hour*) was used to assist intraoperative mechanical ventilation. The ventilator was set up as follows: Tidal volume 8 mL/kg, respiratory rate 10-12/min, and etCO<sub>2</sub> maintained between 35-45 mmHg. A protective ventilation strategy was adopted to maintain the peak airway pressure below 30 mmHg and the plateau airway pressure below 25 mmHg. A certain degree of hypercapnia was considered as acceptable (etCO<sub>2</sub> lower than 60 mmHg). Two grams of acetaminophen and 4 mg of ondansetron were given before the end of the operation. After the operation, the awakened patients were sent to the postanesthesia care unit (PACU) with a 25 µg titration of fentanyl to maintain a VAS score < 4 and were sent to the ward after a one-hour observation period. To control postoperative pain, 3 mg of dizocine was given intravenously at 8 pm on the day of the surgery and at 8 am on the first day after surgery.

### **Adverse events**

Although these were quite rare, POEM-related adverse events included postoperative transfer to the intensive care unit, unstable vital signs, readmission, change to open surgery, postoperative invasive operation, delayed mucosal barrier failure, delayed bleeding and transfusion of blood, hydrothorax, pneumothorax, and extended hospital stay (> 5 d) due to functional impairment[16]. Anesthesia-related adverse events included reflux aspiration, delayed awakening time for more than 30 min, reintubation, postoperative nausea and vomiting.



**Figure 1 The peroral endoscopic myotomy procedure.** A: The mucosal layer was longitudinally cut to form a mucosal opening to expose the stratum submucosa; B: Submucosal injection was performed while the mucosa was separated to form a submucosal tunnel (3-4 cm) to the distal end of the gastroesophageal junction (GEJ); C: The myometrial incision was performed from the distal end of the mucosal tunnel opening at 2 cm to at least 2 cm to the distal end of the GEJ; D: After proper hemostasis, the mucosal opening was closed with a hemostatic clip.



**Figure 2 Illustration of the main peroral endoscopic myotomy procedure.**

### Statistical analysis

The data were expressed as numerical values and percentages, and continuous data were expressed using the mean  $\pm$  SD. All patients were divided into groups according to the 12-h postoperative VAS score; the poorly controlled pain group had a VAS score greater than or equal to 4, and the well-controlled pain group had a VAS score less than 4. Student's *t* test or the Wilcoxon rank sum test was

used to compare quantitative variables, and the chi-square test or Fisher's exact test was used for qualitative variables. Univariate, multivariate, and stepwise logistic regression analyses were used to determine risk factors for poor pain control. The nomogram was formed by the optimal model fitted by logistic regression analysis. The area under the receiver operating characteristic curve (AUC) of the model was evaluated. Repeated measures analysis and of variance and simple effect analysis were used to verify whether the differences in the VAS and sleep scores between the high- and low-risk groups, divided by the model from the raw data, were statistically significant. *P* values over 0.05 were considered as statistically significant. The test was two-sided. All analyses were performed using RStudio software version 1.3.1093.

## RESULTS

### **Patient basic information and surgical parameters**

The flowchart of patient selection is summarized in [Figure 3](#). Forty-five patients were enrolled with a mean age of  $43.2 \pm 15.7$  years, including 24 males and 21 females. The average duration of symptoms was  $6.0 \pm 6.3$  years, with an average preoperative Eckardt score of  $7.6 \pm 2.1$  and esophageal dilation of  $42.9 \pm 10.7$  cm. Ten (22.2%) patients had a past history of treatment ([Table 1](#)).

With regard to the surgical procedure, the mean surgery and anesthesia times were  $61.3 \pm 18.8$  min and  $74.1 \pm 21.0$  min, respectively. The average submucosal tunnel length, myotomy length, and distance between the muscle incision ending and the cardia were  $12.7 \pm 1.2$  cm,  $10.7 \pm 1.1$  cm, and  $2.1 \pm 0.3$  cm, respectively. Thirty-seven patients (82.2%) were administered 100 µg fentanyl during the surgery, and 8 patients (17.8%) were given 150 µg fentanyl. The total intraoperative remifentanyl dose was  $265.5 \pm 90.8$  µg. No patient received fentanyl in the PACU ([Table 1](#)).

### **Risk factors for poor post-POEM pain control**

A 12-h postoperative VAS score  $\geq 4$  was defined as poor post-POEM pain control. As shown in [Table 1](#), patients with poorly controlled postoperative pain had prolonged symptom duration (VAS  $\geq 4$  vs VAS  $< 4$ , 7.5 years vs 4.1 years,  $P = 0.019$ ), a higher preoperative Eckardt score (VAS  $\geq 4$  vs VAS  $< 4$ , 8.4 vs 6.7,  $P = 0.013$ ), and a larger esophageal diameter (VAS  $\geq 4$  vs VAS  $< 4$ , 46.3 mm vs 39 mm,  $P = 0.022$ ). Further univariate logistic regression analyses demonstrated that the preoperative Eckardt score ( $P = 0.011$ ) and preoperative esophageal dilatation ( $P = 0.028$ ) were potential risk factors for poor pain control. Multivariate logistic regression analysis and further stepwise logistic regression were used to exclude the internal effects of the participants, and the optimal fitted model for the risk of poor pain control was constructed. We found that the preoperative Eckardt score (OR: 1.82, 95%CI: 1.17-2.84,  $P < 0.001$ ), previous treatment (OR: 7.59, 95%CI: 1.12-51.23,  $P = 0.037$ ) and the distance between the muscle incision ending and the cardia (OR: 1.52, 95%CI: 0.79-293.93,  $P = 0.072$ ) were risk factors and were included in the model for predicting postoperative pain ([Table 2](#)).

### **Nomogram construction and verification**

We further built a nomogram, as shown in [Figure 4](#), to illustrate and visualize the relationship between the potential risk factors and postoperative pain. To calculate the risk for postoperative pain, each parameter was assigned a point vertically corresponding to the "points" axis, and the sum of the points was plotted on the "total points" axis. The risk of poor post-POEM pain control is the value on the "Risk of poor pain control" axis at the vertical position from the corresponding point on the "Total Points" axis. To evaluate the effect of the nomogram, we used the raw data for internal verification to obtain the calibration and receiver operating characteristic curve (ROC) curves. The calibration curve demonstrated good agreement between the predicted value and the actual value ([Figure 5A](#)). The ROC curve reflected a good classification ability, with an AUC value of 0.822 and an optimal cutoff of 0.730 ([Figure 5B](#)).

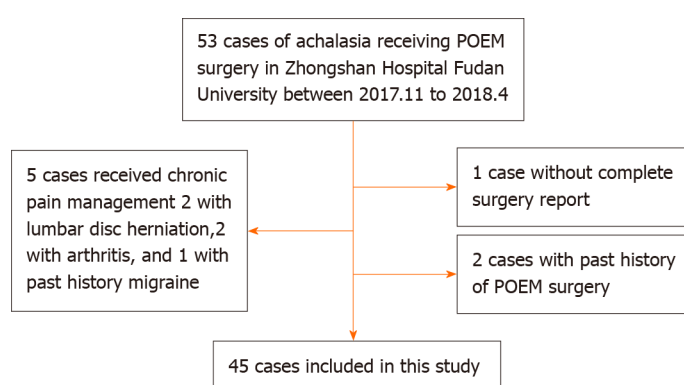
### **Validation of the model using the VAS and sleep scores**

Patients were then divided into high- and low-risk groups according to the calculated cutoff from the ROC curve. To investigate whether postoperative VAS and sleep scores differed between the groups, a repeated measures analysis of variance was conducted, and we found that patients in the high-risk group had higher VAS ( $P = 0.0097$ ) and sleep scores ( $P = 0.043$ ) ([Table 3](#)). A further simple effect analysis found that VAS scores were higher in the high-risk group at 2 h, 6 h and 12 h ( $P = 0.005$ ,  $P = 0.019$ ,  $P < 0.001$ ), and sleep scores were higher in the high-risk group at day 1 ( $P = 0.006$ ) ([Table 4](#)). Line charts of the VAS and sleep scores of the two groups are presented to visually represent the trend in their variation ([Figure 6](#)).

**Table 1 Basic characteristics according to the visual analog scale at 12 h after surgery (mean  $\pm$  SD)**

	Total	VAS < 4	VAS $\geq$ 4	P value
<b>Sex (%)</b>				
Female	21 (46.7)	8 (38.1)	13 (54.2)	0.44
Male	24 (53.3)	13 (61.9)	11 (45.8)	
<b>Age</b>	43.2 $\pm$ 15.7	45.0 $\pm$ 18.0	41.5 $\pm$ 13.6	0.60
<b>Symptom duration (yr)</b>	6.0 $\pm$ 6.3	4.1 $\pm$ 4.9	7.5 $\pm$ 7.0	0.019
<b>Eckardt score</b>	7.6 $\pm$ 2.1	6.7 $\pm$ 2.2	8.4 $\pm$ 1.6	0.013
<b>Esophageal diameter (mm)</b>	42.9 $\pm$ 10.7	39.0 $\pm$ 10.0	46.3 $\pm$ 10.4	0.022
<b>Esophageal dilatation classification (%)</b>				
I	20 (44.4)	13 (61.9)	7 (29.2)	0.088
II	21 (46.7)	7 (33.3)	14 (58.3)	
III	4 (8.9)	1 (4.8)	3 (12.5)	
<b>Previous treatment (%)</b>				
No	35 (77.8)	19 (90.5)	16 (66.7)	0.078
Yes	10 (22.2)	2 (9.5)	8 (33.3)	
<b>Operative time (min)</b>	61.3 $\pm$ 18.8	58.8 $\pm$ 16.9	63.5 $\pm$ 20.4	0.46
<b>Anesthesia time (min)</b>	74.1 $\pm$ 21.0	72.1 $\pm$ 17.5	75.8 $\pm$ 23.9	0.73
<b>Tunnel length (cm)</b>	12.7 $\pm$ 1.2	12.6 $\pm$ 0.6	12.8 $\pm$ 1.5	0.56
<b>Myotomy length (cm)</b>	10.7 $\pm$ 1.1	10.6 $\pm$ 0.7	10.8 $\pm$ 1.4	0.35
<b>Distance from muscle incision ending to cardia (cm)</b>	2.1 $\pm$ 0.3	2.0 $\pm$ 0.2	2.2 $\pm$ 0.4	0.22
<b>Fentanyl dosage (ug) (%)</b>				
100	37 (82.2)	16 (76.2)	21 (87.5)	0.44
150	8 (17.8)	5 (23.8)	3 (12.5)	
<b>Remifentanil dosage (ug)</b>	265.5 $\pm$ 90.8	264.8 $\pm$ 85.3	266.1 $\pm$ 97.2	1.0

VAS: Visual analog scale.



DOI: 10.12998/wjcc.v10.i17.5655 Copyright ©The Author(s) 2022.

**Figure 3 Flowchart of patient selection.** POEM: Peroral endoscopic myotomy.

## DISCUSSION

Postoperative pain management of achalasia patients who undergo the POEM procedure is often neglected by anesthesiologists due to the short operative time and minimally invasive nature of the POEM procedure. In this retrospective study, we included 45 achalasia patients who received POEM at our medical center, evaluated their postoperative pain intensity and sleep quality, and explored factors



**Table 2 Univariate and multivariate logistic regression analyses of poor pain control, defined as those whose 12-h visual analog scale score was greater than 3**

Parameter	Univariate		Multivariate	
	OR (95%CI)	P value	OR (95%CI)	P value
Sex	0.52 (0.16-1.71)	0.283		
Age	0.99 (0.95-1.02)	0.45		
Duration	1.12 (0.98-1.27)	0.091		
Eckardt Score	1.64 (1.12-2.40)	0.011	1.82 (1.17-2.84)	< 0.001
Esophageal diameter	1.07 (1.01-1.14)	0.028		
Esophageal dilatation classification	3.71 (1.02-13.51)	0.046		
	5.57 (0.48-64.09)	0.17		
Previous treatment	4.75 (0.88-25.65)	0.07	7.59 (1.12-51.23)	0.037
Operative time	1.01 (0.98-1.05)	0.40		
Anesthesia time	1.01 (0.98-1.04)	0.55		
Tunnel length	1.18 (0.69-2.01)	0.54		
Myotomy length	1.20 (0.69-2.09)	0.52		
Distance from muscle incision ending to cardia	4.00 (0.41-39.00)	0.23	1.52 (0.79-293.93)	0.072
Fentanyl dosage	0.46 (0.095-2.20)	0.33		
Remifentanyl dosage	1.00 (0.99-1.01)	0.96		

**Table 3 Repeated measures analysis of variance of visual analog scale and sleep scores**

		F value	P value
VAS	Groups	7.33	0.0097
	Time	226.47	< 0.001
	Groups: Time	3.03	0.019
Sleep score	Groups	4.35	0.043
	Time	138.57	< 0.001
	Groups: Time	4.72	0.035

VAS: Visual analog scale.

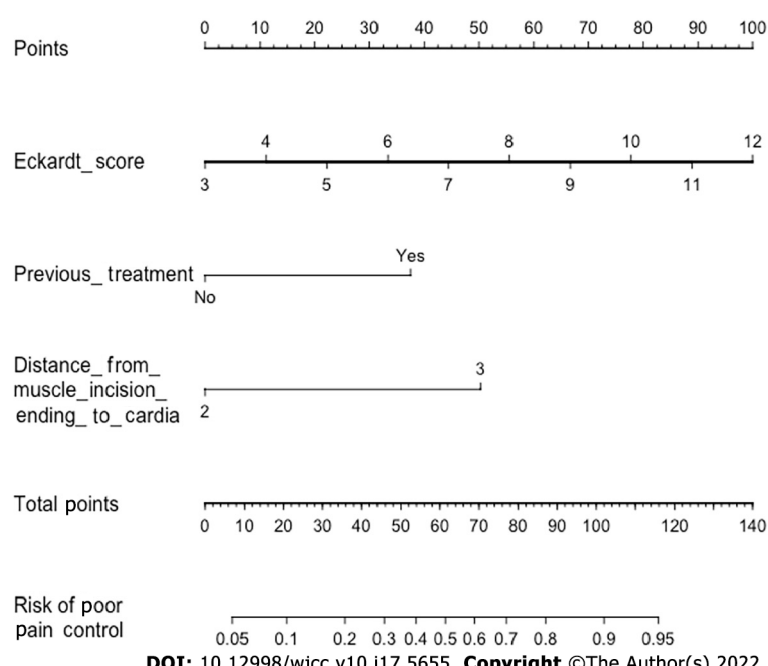
associated with post-POEM pain. Our results demonstrated that patients with postoperative VAS scores (12 h after surgery) greater than or equal to 4 had longer symptom durations, higher preoperative Eckardt scores, and larger esophageal diameters. The Eckardt score, previous treatment for achalasia, and the distance between the muscle incision ending and the cardia were associated with poor postoperative pain control and were further included in the model for predicting postoperative pain. Patients in the high-risk group had higher VAS and sleep scores.

POEM has been proven to be a safe and effective endoscopic procedure for treating achalasia[16,17]. Previous studies on anesthesia management in POEM procedures have mostly focused on intraoperative anesthesia, reflux aspiration, and anesthesia-related complications[18-20]. Tanaka *et al*[18] administered remifentanyl during surgery, and patients complained of postoperative upper abdominal pain. Twenty of the twenty-eight enrolled patients received diclofenac sodium turunda within 24 h after surgery, among whom 3 patients were given additional pentazocine. Nishihara *et al*[20] also delivered remifentanyl during surgery but did not report any information about postoperative pain. Another retrospective study of 12 patients performed by Misra *et al*[21] revealed that patients had mild to moderate pain after POEM. These patients received fentanyl, hydromorphone, morphine, acetaminophen, oxycodone, and ketorolac as postoperative analgesia; however, there were no records on opioid use during surgery. Thus, the present study is the first retrospective study incorporating complete anesthesia management data and medical records to evaluate postoperative pain intensity and investigate potential risk factors among achalasia patients who underwent POEM.

**Table 4 Simple effect analysis of variance of visual analog scale and sleep scores**

		F value	P value
VAS	Risk (2 h)	8.34	0.005
	Risk (6 h)	5.71	0.019
	Risk (12 h)	12.91	< 0.001
	Risk (24 h)	1.42	0.24
	Risk (36 h)	0.69	0.41
Sleep score	Risk (day 1)	8.05	0.006
	Risk (day 2)	0.80	0.375

VAS: Visual analog scale.

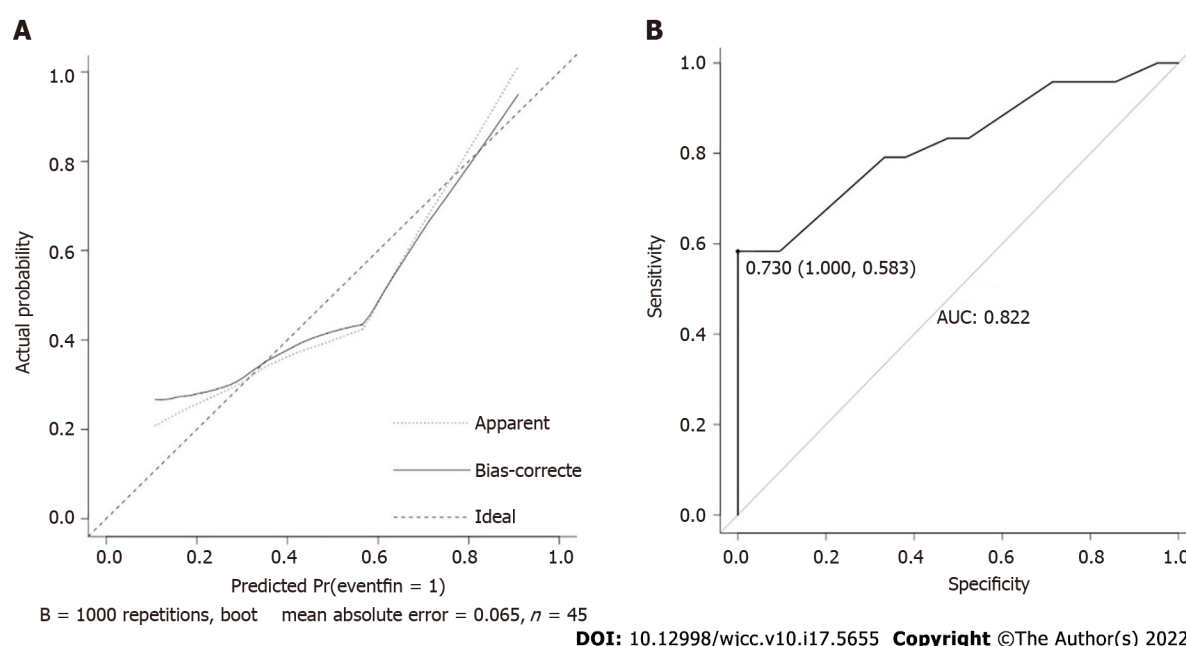


**Figure 4** The nomogram was constructed from 3 parameters (Table 2). To calculate a patient's risk for poor pain control, defined as a visual analog scale score greater than or equal to 4 at 12 h after peroral endoscopic myotomy (POEM), each parameter was assigned a point by its vertical correspondence to the "points" axis, and the sum of the points was plotted on the "total points" axis. The risk for poor post-POEM pain control is the value on the "Risk of poor pain control" axis at a vertical position from the corresponding point on the "Total Points" axis.

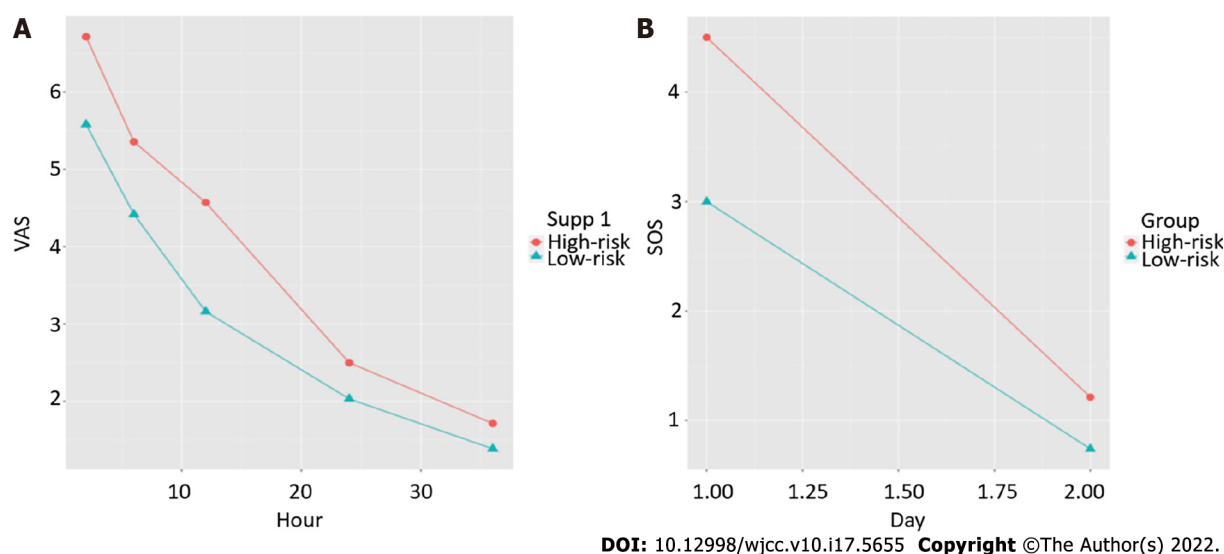
No patient complained of pain during the telephone follow-up on the 28<sup>th</sup> day after surgery, suggesting that POEM may not lead to chronic pain. This result was consistent with previous research conducted by Misra *et al*[21], which revealed that postoperative pain associated with the POEM procedure seldom lasts for months.

A comparison of the baseline characteristics between groups demonstrated that patients who suffered from postoperative pain had longer symptom durations, higher Eckardt scores and larger esophageal diameters, *i.e.*, more severe cases. Further stepwise logistic regression analyses showed that a higher Eckardt score and previous treatment for achalasia were associated with poor postoperative pain control (VAS  $\geq 4$  at 12 h after surgery). Patients with higher Eckardt scores had worse symptoms of achalasia and were also more likely to have relapsed or intractable achalasia, resulting in increased surgical difficulty and greater surgical wounds, which may contribute to severe postoperative pain. Interestingly, we also found that the 12-h postoperative VAS score was associated with the distance between the muscle incision ending and the cardia; the longer the distance, the more severe the pain. However, there was no significant difference between the VAS  $< 4$  and VAS  $\geq 4$  groups in terms of surgical parameters. The suggestion for the range of submucosal tunnels was from 10-12 cm above the GEJ to 3-4 cm below the GEJ[7]. Previous studies showed that patients with shorter tunnels ( $10.7 \pm 1.4$  cm) had fewer complications than those with longer tunnels ( $13.1 \pm 0.8$  cm)[22]. Meanwhile, the range of myotomy is still controversial. It was suggested that excess myotomy was unnecessary, while





**Figure 5 Calibration plots and receiver operating characteristic curve of the nomogram for prediction.** A: The calibration plot is the comparison between predicted and actual outcomes. The dashed line is a reference line, indicating where an ideal nomogram would lie; B: Receiver operating characteristic curve of the nomogram with an area under the receiver operating characteristic curve of 0.822 and an optimal cutoff of 0.730.



**Figure 6 Line charts of the means of the high- and low-risk groups, divided from the raw data, by the nomogram over time.** A: Line chart of the visual analog scale; B: Line chart of the sleep score. VAS: Visual analog scale.

insufficient myotomy may lead to recurrence. A muscle incision ending within 3 cm of the cardia was recommended. However, commonly used endoscopic markers of the gastric side are inaccurate, particularly in patients who have received previous treatment, such as balloon dilation or Botox injection of the LES[23]. Thus, anesthesiologists and endoscopists should pay attention to not only the surgical procedure itself but also the severity of achalasia.

With the small number of patients enrolled in this study, meaningful conclusions are still limited to some degree. This was an observational study performed during the early stage of an randomized controlled trial (RCT), and we will further explore the optimal approach to postoperative analgesia in patients who underwent POEM surgery in the RCT study and will cooperate with endoscopists to explore the effect of the POEM modus operandi (intrapleural tunnel length and myotomy position) on postoperative pain.

In summary, achalasia patients who underwent the POEM procedure experienced moderate to severe postoperative pain that required pain management. Patients with higher preoperative Eckardt scores, previous treatments, and longer distances between the muscle incision ending and the cardia may have

a higher risk for postoperative pain.

---

## CONCLUSION

Achalasia patients receiving POEM surgery experienced moderate to severe postoperative pain, which affected their sleep quality. Patients with higher preoperative Eckardt scores, previous treatments, and longer distances between the muscle incision ending and the cardia have a higher risk for poor postoperative pain control. Anesthetists and endoscopists should pay more attention to the severity of achalasia than to the POEM procedure itself when evaluating the risk for post-POEM pain.

## ARTICLE HIGHLIGHTS

### **Research background**

Postoperative pain management for peroral endoscopic myotomy (POEM) is often neglected by anesthesiologists because of the short operative time, short hospital stay and the minimally invasive nature of the procedure.

### **Research motivation**

The authors conducted this retrospective study to examine the postoperative pain intensity of achalasia patients receiving the POEM procedure and to investigate possible risk factors for postoperative pain.

### **Research objectives**

To achieve better postoperative pain management.

### **Research methods**

We included patients with achalasia who underwent POEM at Zhongshan Hospital from December 2017 to March 2018. The postoperative visual analog scale, postoperative sleep quality, basic patient information, and surgical parameters were collected.

### **Research results**

The preoperative Eckardt score [odds ratio (OR): 1.82, 95% confidence interval (CI): 1.17-2.84,  $P < 0.001$ ], previous treatment (OR: 7.59, 95%CI: 1.12-51.23,  $P = 0.037$ ) and the distance between the end of the muscle incision and the cardia (OR: 1.52, 95%CI: 0.79-293.93,  $P = 0.072$ ) were risk factors for post-POEM pain.

### **Research conclusions**

Achalasia patients who underwent POEM experienced serious postoperative pain, which may affect sleep quality. A higher Eckardt score, previous treatment, and a longer distance between the muscle incision ending and the cardia were risk factors for poor post-POEM pain control.

### **Research perspectives**

We will further explore the optimal approach to postoperative analgesia in patients who underwent POEM surgery in the randomized controlled trial study and will cooperate with endoscopists to explore the effect of the POEM modus operandi (intrapleural tunnel length and myotomy position) on postoperative pain.

---

## FOOTNOTES

**Author contributions:** Chen WN and Xu YL contributed equally to this work; Chen WN designed the research; Chen WN and Zhang XG managed the clinical process; Xu YL collected clinical data; Chen WN and Xu YL wrote the manuscript; Zhang XG revised the manuscript.

**Institutional review board statement:** The study was reviewed and approved by the Ethics Committee of Zhongshan Hospital affiliated with Fudan University, No. B2018-004R.

**Conflict-of-interest statement:** There are no conflicts of interest related to this study.

**Data sharing statement:** Technical appendix, statistical code, and dataset available from the corresponding author at [zhang.xiaoguang@zs-hospital.sh.cn](mailto:zhang.xiaoguang@zs-hospital.sh.cn).

**STROBE statement:** The authors have read the STROBE Statement—checklist of items, and the manuscript was prepared and revised according to the STROBE Statement—checklist of items.

**Open-Access:** This article is an open-access article that was selected by an in-house editor and fully peer-reviewed by external reviewers. It is distributed in accordance with the Creative Commons Attribution NonCommercial (CC BY-NC 4.0) license, which permits others to distribute, remix, adapt, build upon this work non-commercially, and license their derivative works on different terms, provided the original work is properly cited and the use is non-commercial. See: <https://creativecommons.org/licenses/by-nc/4.0/>

**Country/Territory of origin:** China

**ORCID number:** Wan-Nan Chen 0000-0003-1236-2386; Yao-Lin Xu 0000-0002-0971-518X; Xiao-Guang Zhang 0000-0002-4636-792X.

**S-Editor:** Fan JR

**L-Editor:** A

**P-Editor:** Yu HG

## REFERENCES

- 1 Winter H, Shukla R, Elshaer M, Riaz AA. Current management of achalasia—a review. *Br J Med Pract* 2015; **8**: a810
- 2 O'Neill OM, Johnston BT, Coleman HG. Achalasia: a review of clinical diagnosis, epidemiology, treatment and outcomes. *World J Gastroenterol* 2013; **19**: 5806-5812 [PMID: 24124325 DOI: 10.3748/wjg.v19.i35.5806]
- 3 Sadowski DC, Ackah F, Jiang B, Svenson LW. Achalasia: incidence, prevalence and survival. A population-based study. *Neurogastroenterol Motil* 2010; **22**: e256-e261 [PMID: 20465592 DOI: 10.1111/j.1365-2982.2010.01511.x]
- 4 Francis DL, Katzka DA. Achalasia: update on the disease and its treatment. *Gastroenterology* 2010; **139**: 369-374 [PMID: 20600038 DOI: 10.1053/j.gastro.2010.06.024]
- 5 Campos GM, Vittinghoff E, Rabl C, Takata M, Gadenstätter M, Lin F, Ciofica R. Endoscopic and surgical treatments for achalasia: a systematic review and meta-analysis. *Ann Surg* 2009; **249**: 45-57 [PMID: 19106675 DOI: 10.1097/SLA.0b013e31818e43ab]
- 6 Boeckstaens GE, Annese V, des Varannes SB, Chaussade S, Costantini M, Cuttitta A, Elizalde JI, Fumagalli U, Gaudric M, Rohof WO, Smout AJ, Tack J, Zwinderman AH, Zaninotto G, Busch OR; European Achalasia Trial Investigators. Pneumatic dilation versus laparoscopic Heller's myotomy for idiopathic achalasia. *N Engl J Med* 2011; **364**: 1807-1816 [PMID: 21561346 DOI: 10.1056/NEJMoa1010502]
- 7 Inoue H, Minami H, Kobayashi Y, Sato Y, Kaga M, Suzuki M, Satodate H, Odaka N, Itoh H, Kudo S. Peroral endoscopic myotomy (POEM) for esophageal achalasia. *Endoscopy* 2010; **42**: 265-271 [PMID: 20354937 DOI: 10.1055/s-0029-1244080]
- 8 Pasricha PJ, Hawari R, Ahmed I, Chen J, Cotton PB, Hawes RH, Kalloo AN, Kantsevoy SV, Gostout CJ. Submucosal endoscopic esophageal myotomy: a novel experimental approach for the treatment of achalasia. *Endoscopy* 2007; **39**: 761-764 [PMID: 17703382 DOI: 10.1055/s-2007-966764]
- 9 Murata H, Ichinomiya T, Hara T. Anesthesia for peroral endoscopic myotomy in Japan. *Curr Opin Anaesthesiol* 2019; **32**: 511-516 [PMID: 30994477 DOI: 10.1097/ACO.0000000000000742]
- 10 Hungness ES, Teitelbaum EN, Santos BF, Arafat FO, Pandolfino JE, Kahrilas PJ, Soper NJ. Comparison of perioperative outcomes between peroral esophageal myotomy (POEM) and laparoscopic Heller myotomy. *J Gastrointest Surg* 2013; **17**: 228-235 [PMID: 23054897 DOI: 10.1007/s11605-012-2030-3]
- 11 Docimo S Jr, Mathew A, Shope AJ, Winder JS, Haluck RS, Pauli EM. Reduced postoperative pain scores and narcotic use favor per-oral endoscopic myotomy over laparoscopic Heller myotomy. *Surg Endosc* 2017; **31**: 795-800 [PMID: 27338580 DOI: 10.1007/s00464-016-5034-3]
- 12 Ujiki MB, Yetasook AK, Zapf M, Linn JG, Carbray JM, Denham W. Peroral endoscopic myotomy: A short-term comparison with the standard laparoscopic approach. *Surgery* 2013; **154**: 893-7; discussion 897 [PMID: 24074429 DOI: 10.1016/j.surg.2013.04.042]
- 13 Talukdar R, Inoue H, Nageshwar Reddy D. Efficacy of peroral endoscopic myotomy (POEM) in the treatment of achalasia: a systematic review and meta-analysis. *Surg Endosc* 2015; **29**: 3030-3046 [PMID: 25539695 DOI: 10.1007/s00464-014-4040-6]
- 14 Elmunzer BJ, Lewis BR, Miller KF, Wolf BJ, Zeiler L, Gutman DA, Elias P, Tansel A, Moran RA, Bolin ED. Paravertebral anesthetic nerve block for pain control after peroral endoscopic myotomy. *Tech Innov Gastrointest Endosc* 2021; **23**: 297-303 [PMID: 34870251 DOI: 10.1016/j.tige.2021.06.006]
- 15 Vaezi MF, Pandolfino JE, Vela MF. ACG clinical guideline: diagnosis and management of achalasia. *Am J Gastroenterol* 2013; **108**: 1238-49; quiz 1250 [PMID: 23877351 DOI: 10.1038/ajg.2013.196]
- 16 Zhang XC, Li QL, Xu MD, Chen SY, Zhong YS, Zhang YQ, Chen WF, Ma LL, Qin WZ, Hu JW, Cai MY, Yao LQ, Zhou PH. Major perioperative adverse events of peroral endoscopic myotomy: a systematic 5-year analysis. *Endoscopy* 2016; **48**: 967-978 [PMID: 27448052 DOI: 10.1055/s-0042-110397]
- 17 Li QL, Wu QN, Zhang XC, Xu MD, Zhang W, Chen SY, Zhong YS, Zhang YQ, Chen WF, Qin WZ, Hu JW, Cai MY, Yao LQ, Zhou PH. Outcomes of per-oral endoscopic myotomy for treatment of esophageal achalasia with a median follow-up of 49 months. *Gastrointest Endosc* 2018; **87**: 1405-1412.e3 [PMID: 29108981 DOI: 10.1016/j.gie.2017.10.031]

- 18 **Tanaka E**, Murata H, Minami H, Sumikawa K. Anesthetic management of peroral endoscopic myotomy for esophageal achalasia: a retrospective case series. *J Anesth* 2014; **28**: 456-459 [PMID: [24185834](#) DOI: [10.1007/s00540-013-1735-0](#)]
- 19 **Löser B**, Werner YB, Punke MA, Saugel B, Haas S, Reuter DA, Mann O, Duprée A, Schachschal G, Rösch T, Petzoldt M. Anesthetic considerations for patients with esophageal achalasia undergoing peroral endoscopic myotomy: a retrospective case series review. *Can J Anaesth* 2017; **64**: 480-488 [PMID: [28116675](#) DOI: [10.1007/s12630-017-0820-5](#)]
- 20 **Nishihara Y**, Yoshida T, Ooi M, Obata N, Izuta S, Mizobuchi S. Anesthetic management and associated complications of peroral endoscopic myotomy: A case series. *World J Gastrointest Endosc* 2018; **10**: 193-199 [PMID: [30283602](#) DOI: [10.4253/wjge.v10.i9.193](#)]
- 21 **Misra L**, Fukami N, Nikolic K, Trentman TL. Peroral endoscopic myotomy: procedural complications and pain management for the perioperative clinician. *Med Devices (Auckl)* 2017; **10**: 53-59 [PMID: [28260955](#) DOI: [10.2147/MDER.S115632](#)]
- 22 **Ma XB**, Linghu EQ, Wang NJ, Wang XD, Du H, Meng JY, Wang HB, Zhu J, Tang P, Huang QY, Zhao XW, Chai GQ, Kong JY, Qiu XY. Application of peroral endoscopic myotomy with short tunnel for Ling IIc type achalasia. *Chin J Laparoscopic Sur* 2014; **7**: 271-274 [DOI: [10.1007/s00464-018-6414-7](#)]
- 23 **Grimes KL**, Inoue H, Onimaru M, Ikeda H, Tansawet A, Bechara R, Tanaka S. Double-scope per oral endoscopic myotomy (POEM): a prospective randomized controlled trial. *Surg Endosc* 2016; **30**: 1344-1351 [PMID: [26173548](#) DOI: [10.1007/s00464-015-4396-2](#)]



Published by **Baishideng Publishing Group Inc**  
7041 Koll Center Parkway, Suite 160, Pleasanton, CA 94566, USA

**Telephone:** +1-925-3991568

**E-mail:** [bpgoffice@wjgnet.com](mailto:bpgoffice@wjgnet.com)

**Help Desk:** <https://www.f6publishing.com/helpdesk>

<https://www.wjgnet.com>

