

World Journal of *Clinical Cases*

World J Clin Cases 2022 June 16; 10(17): 5518-5933



MINIREVIEWS

- 5518** Occult hepatitis B — the result of the host immune response interaction with different genomic expressions of the virus
Gherlan GS
- 5531** Pulmonary complications of portal hypertension: The overlooked decompensation
Craciun R, Mocan T, Procopet B, Nemes A, Tefas C, Sparchez M, Mocan LP, Sparchez Z
- 5541** Ethical review of off-label drugs during the COVID-19 pandemic
Li QY, Lv Y, An ZY, Dai NN, Hong X, Zhang Y, Liang LJ

ORIGINAL ARTICLE

Case Control Study

- 5551** Gut peptide changes in patients with obstructive jaundice undergoing biliary drainage: A prospective case control study
Pavić T, Pelajić S, Blažević N, Kralj D, Milošević M, Mikolasevic I, Lerotic I, Hrabar D

Retrospective Cohort Study

- 5566** Longitudinal assessment of liver stiffness by transient elastography for chronic hepatitis C patients
Mezina A, Krishnan A, Woreta TA, Rubenstein KB, Watson E, Chen PH, Rodriguez-Watson C

Retrospective Study

- 5577** Clinical evaluation of prone position ventilation in the treatment of acute respiratory distress syndrome induced by sepsis
Xia WH, Yang CL, Chen Z, Ouyang CH, Ouyang GQ, Li QG
- 5586** Three-dimensional arterial spin labeling and diffusion kurtosis imaging in evaluating perfusion and infarct area size in acute cerebral ischemia
Jiang YY, Zhong ZL, Zuo M
- 5595** Intrathecal methotrexate in combination with systemic chemotherapy in glioblastoma patients with leptomeningeal dissemination: A retrospective analysis
Kang X, Chen F, Yang SB, Wang YL, Qian ZH, Li Y, Lin H, Li P, Peng YC, Wang XM, Li WB
- 5606** Hepatic epithelioid hemangioendothelioma: Clinical characteristics, diagnosis, treatment, and prognosis
Zhao M, Yin F
- 5620** Difference between type 2 gastroesophageal varices and isolated fundic varices in clinical profiles and portosystemic collaterals
Song YH, Xiang HY, Si KK, Wang ZH, Zhang Y, Liu C, Xu KS, Li X

- 5634** Assessment of incidental focal colorectal uptake by analysis of fluorine-18 fluorodeoxyglucose positron emission tomography parameters

Lee H, Hwang KH, Kwon KA

Observational Study

- 5646** "Zero ischemia" laparoscopic partial nephrectomy by high-power GreenLight laser enucleation for renal carcinoma: A single-center experience

Zhang XM, Xu JD, Lv JM, Pan XW, Cao JW, Chu J, Cui XG

- 5655** High Eckardt score and previous treatment were associated with poor postperoral endoscopic myotomy pain control: A retrospective study

Chen WN, Xu YL, Zhang XG

- 5667** Higher volume growth rate is associated with development of worrisome features in patients with branch duct-intraductal papillary mucinous neoplasms

Innocenti T, Danti G, Lynch EN, Dragoni G, Gottin M, Fedeli F, Palatresi D, Biagini MR, Milani S, Miele V, Galli A

Prospective Study

- 5680** Application of a new anatomic hook-rod-pedicle screw system in young patients with lumbar spondylolysis: A pilot study

Li DM, Li YC, Jiang W, Peng BG

META-ANALYSIS

- 5690** Systematic review of Yougui pills combined with levothyroxine sodium in the treatment of hypothyroidism

Liu XP, Zhou YN, Tan CE

CASE REPORT

- 5702** Allogeneic stem cell transplantation-A curative treatment for paroxysmal nocturnal hemoglobinuria with PIGT mutation: A case report

Schenone L, Notarantonio AB, Latger-Cannard V, Fremeaux-Bacchi V, De Carvalho-Bittencourt M, Rubio MT, Muller M, D'Aveni M

- 5708** Gray zone lymphoma effectively treated with cyclophosphamide, doxorubicin, vincristine, prednisolone, and rituximab chemotherapy: A case report

Hojo N, Nagasaki M, Mihara Y

- 5717** Diagnosis of spontaneous isolated superior mesenteric artery dissection with ultrasound: A case report

Zhang Y, Zhou JY, Liu J, Bai C

- 5723** Adrenocorticotrophic hormone-secreting pancreatic neuroendocrine carcinoma with multiple organ infections and widespread thrombosis: A case report

Yoshihara A, Nishihama K, Inoue C, Okano Y, Eguchi K, Tanaka S, Maki K, Fridman D'Alessandro V, Takeshita A, Yasuma T, Uemura M, Suzuki T, Gabazza EC, Yano Y

- 5732** Management of the palato-radicular groove with a periodontal regenerative procedure and prosthodontic treatment: A case report

Ling DH, Shi WP, Wang YH, Lai DP, Zhang YZ

- 5741** Combined thoracic paravertebral block and interscalene brachial plexus block for modified radical mastectomy: A case report
Hu ZT, Sun G, Wang ST, Li K
- 5748** Chondromyxoid fibroma of the cervical spine: A case report
Li C, Li S, Hu W
- 5756** Preterm neonate with a large congenital hemangioma on maxillofacial site causing thrombocytopenia and heart failure: A case report
Ren N, Jin CS, Zhao XQ, Gao WH, Gao YX, Wang Y, Zhang YF
- 5764** Simultaneous multiple primary malignancies diagnosed by endoscopic ultrasound-guided fine-needle aspiration: A case report
Yang J, Zeng Y, Zhang JW
- 5770** Neuroendocrine tumour of the descending part of the duodenum complicated with schwannoma: A case report
Zhang L, Zhang C, Feng SY, Ma PP, Zhang S, Wang QQ
- 5776** Massive hemothorax following internal jugular vein catheterization under ultrasound guidance: A case report
Kang H, Cho SY, Suk EH, Ju W, Choi JY
- 5783** Unilateral adrenal tuberculosis whose computed tomography imaging characteristics mimic a malignant tumor: A case report
Liu H, Tang TJ, An ZM, Yu YR
- 5789** Modified membrane fixation technique in a severe continuous horizontal bone defect: A case report
Wang LH, Ruan Y, Zhao WY, Chen JP, Yang F
- 5798** Surgical repair of an emergent giant hepatic aneurysm with an abdominal aortic dissection: A case report
Wen X, Yao ZY, Zhang Q, Wei W, Chen XY, Huang B
- 5805** Heterotopic ossification beneath the upper abdominal incision after radical gastrectomy: Two case reports
Zhang X, Xia PT, Ma YC, Dai Y, Wang YL
- 5810** Non-alcoholic Wernicke encephalopathy in an esophageal cancer patient receiving radiotherapy: A case report
Zhang Y, Wang L, Jiang J, Chen WY
- 5816** New approach for the treatment of vertical root fracture of teeth: A case report and review of literature
Zhong X, Yan P, Fan W
- 5825** Ultrasound-guided microwave ablation as a palliative treatment for mycosis fungoides eyelid involvement: A case report
Chen YW, Yang HZ, Zhao SS, Zhang Z, Chen ZM, Feng HH, An MH, Wang KK, Duan R, Chen BD
- 5833** Pulp revascularization on an adult mandibular right second premolar: A case report
Yang YQ, Wu BL, Zeng JK, Jiang C, Chen M

- 5841** Barrett's esophagus in a patient with bulimia nervosa: A case report
Gouda A, El-Kassas M
- 5846** Spontaneous gallbladder perforation and colon fistula in hypertriglyceridemia-related severe acute pancreatitis: A case report
Wang QP, Chen YJ, Sun MX, Dai JY, Cao J, Xu Q, Zhang GN, Zhang SY
- 5854** Beware of gastric tube in esophagectomy after gastric radiotherapy: A case report
Yurttas C, Wichmann D, Gani C, Bongers MN, Singer S, Thiel C, Koenigsrainer A, Thiel K
- 5861** Transition from minimal change disease to focal segmental glomerulosclerosis related to occupational exposure: A case report
Tang L, Cai Z, Wang SX, Zhao WJ
- 5869** Lung adenocarcinoma metastasis to paranasal sinus: A case report
Li WJ, Xue HX, You JQ, Chao CJ
- 5877** Follicular lymphoma presenting like marginal zone lymphoma: A case report
Peng HY, Xiu YJ, Chen WH, Gu QL, Du X
- 5884** Primary renal small cell carcinoma: A case report
Xie K, Li XY, Liao BJ, Wu SC, Chen WM
- 5893** Gitelman syndrome: A case report
Chen SY, Jie N
- 5899** High-frame-rate contrast-enhanced ultrasound findings of liver metastasis of duodenal gastrointestinal stromal tumor: A case report and literature review
Chen JH, Huang Y
- 5910** Tumor-like disorder of the brachial plexus region in a patient with hemophilia: A case report
Guo EQ, Yang XD, Lu HR
- 5916** Response to dacomitinib in advanced non-small-cell lung cancer harboring the rare delE709_T710insD mutation: A case report
Xu F, Xia ML, Pan HY, Pan JW, Shen YH
- 5923** Loss of human epidermal receptor-2 in human epidermal receptor-2+ breast cancer after neoadjuvant treatment: A case report
Yu J, Li NL

LETTER TO THE EDITOR

- 5929** Repetitive transcranial magnetic stimulation for post-traumatic stress disorder: Lights and shadows
Concerto C, Lanza G, Fisicaro F, Pennisi M, Rodolico A, Torrisi G, Bella R, Aguglia E

ABOUT COVER

Editorial Board Member of *World Journal of Clinical Cases*, Raden Andri Primadhi, MD, PhD, Assistant Professor, Surgeon, Department of Orthopaedics and Traumatology, Universitas Padjadjaran Medical School, Hasan Sadikin Hospital, Bandung 40161, Indonesia. randri@unpad.ac.id

AIMS AND SCOPE

The primary aim of *World Journal of Clinical Cases* (WJCC, *World J Clin Cases*) is to provide scholars and readers from various fields of clinical medicine with a platform to publish high-quality clinical research articles and communicate their research findings online.

WJCC mainly publishes articles reporting research results and findings obtained in the field of clinical medicine and covering a wide range of topics, including case control studies, retrospective cohort studies, retrospective studies, clinical trials studies, observational studies, prospective studies, randomized controlled trials, randomized clinical trials, systematic reviews, meta-analysis, and case reports.

INDEXING/ABSTRACTING

The WJCC is now indexed in Science Citation Index Expanded (also known as SciSearch®), Journal Citation Reports/Science Edition, Scopus, PubMed, and PubMed Central. The 2021 Edition of Journal Citation Reports® cites the 2020 impact factor (IF) for WJCC as 1.337; IF without journal self cites: 1.301; 5-year IF: 1.742; Journal Citation Indicator: 0.33; Ranking: 119 among 169 journals in medicine, general and internal; and Quartile category: Q3. The WJCC's CiteScore for 2020 is 0.8 and Scopus CiteScore rank 2020: General Medicine is 493/793.

RESPONSIBLE EDITORS FOR THIS ISSUE

Production Editor: Hua-Ge Yin, Production Department Director: Xiang Li, Editorial Office Director: Jin-Lai Wang.

NAME OF JOURNAL

World Journal of Clinical Cases

ISSN

ISSN 2307-8960 (online)

LAUNCH DATE

April 16, 2013

FREQUENCY

Thrice Monthly

EDITORS-IN-CHIEF

Bao-Gan Peng, Jerzy Tadeusz Chudek, George Kontogeorgos, Maurizio Serati, Ja Hyeon Ku

EDITORIAL BOARD MEMBERS

<https://www.wjgnet.com/2307-8960/editorialboard.htm>

PUBLICATION DATE

June 16, 2022

COPYRIGHT

© 2022 Baishideng Publishing Group Inc

INSTRUCTIONS TO AUTHORS

<https://www.wjgnet.com/bpg/gerinfo/204>

GUIDELINES FOR ETHICS DOCUMENTS

<https://www.wjgnet.com/bpg/GerInfo/287>

GUIDELINES FOR NON-NATIVE SPEAKERS OF ENGLISH

<https://www.wjgnet.com/bpg/gerinfo/240>

PUBLICATION ETHICS

<https://www.wjgnet.com/bpg/GerInfo/288>

PUBLICATION MISCONDUCT

<https://www.wjgnet.com/bpg/gerinfo/208>

ARTICLE PROCESSING CHARGE

<https://www.wjgnet.com/bpg/gerinfo/242>

STEPS FOR SUBMITTING MANUSCRIPTS

<https://www.wjgnet.com/bpg/GerInfo/239>

ONLINE SUBMISSION

<https://www.f6publishing.com>



Management of the palato-radicular groove with a periodontal regenerative procedure and prosthodontic treatment: A case report

Dan-Hua Ling, Wei-Ping Shi, Yan-Hong Wang, Dan-Ping Lai, Yan-Zhen Zhang

Specialty type: Dentistry, oral surgery and medicine

Provenance and peer review:

Unsolicited article; Externally peer reviewed.

Peer-review model: Single blind

Peer-review report's scientific quality classification

Grade A (Excellent): 0

Grade B (Very good): B

Grade C (Good): C, C

Grade D (Fair): 0

Grade E (Poor): E

P-Reviewer: Rakhshan V, Iran; Rakhshan V, Iran; Scribante A, Italy; Scribante A, Italy

Received: October 28, 2021

Peer-review started: October 28, 2021

First decision: December 27, 2021

Revised: January 9, 2022

Accepted: April 9, 2022

Article in press: April 9, 2022

Published online: June 16, 2022



Dan-Hua Ling, Wei-Ping Shi, Dan-Ping Lai, Yan-Zhen Zhang, Department of Comprehensive Dentistry, The Second Affiliated Hospital of Zhejiang University School of Medicine, Hangzhou 310052, Zhejiang Province, China

Yan-Hong Wang, Department of Comprehensive Dentistry, Jiangnan Hospital Affiliated to Zhejiang Chinese Medical University, Hangzhou 311221, Zhejiang Province, China

Corresponding author: Yan-Zhen Zhang, MA, Chief Physician, Department of Comprehensive Dentistry, The Second Affiliated Hospital of Zhejiang University School of Medicine, No. 1511 Jianghong Road, Binjiang District, Hangzhou 310052, Zhejiang Province, China. 2191004@zju.edu.cn

Abstract

BACKGROUND

Palato-radicular groove (PRG) is defined as an anomalous formation of teeth. The etiology of PRG remains unclear. The prognosis of a tooth with a PRG is unfavorable. The treatment of combined periodontal-endodontic lesions requires multidisciplinary management to control the progression of bone defects. Some researchers reported cases that had short-term observations. The management of teeth with PRGs is of great clinical significance. However, to date, no case reports have been documented on the use of bone regeneration and prosthodontic treatment for PRGs.

CASE SUMMARY

This case reported the management of a 40-year-old male patient with the chief complaint of slight mobility and abscess in the upper right anterior tooth for 15 d and was diagnosed with type II PRG of tooth 12 with combined endodontic-periodontal lesions. The accumulation of plaque and calculus caused primary periodontitis and a secondary endodontic infection. A multidisciplinary management approach was designed that included root canal therapy, groove sealing, a periodontal regenerative procedure, and prosthodontic treatment. During a 2-year follow-up period, a good prognosis was observed.

CONCLUSION

This report indicates that bone regeneration and prosthodontic treatment may contribute to the long-term favorable prognosis of teeth with PRGs.

Key Words: Palato-radicular groove; Bone regeneration treatment; Prosthodontic

treatment; Maxillary lateral incisor; Dentistry; Periodontology; Case report

©The Author(s) 2022. Published by Baishideng Publishing Group Inc. All rights reserved.

Core Tip: The prognosis of a tooth with a palato-radicular groove (PRG) is unfavorable. The treatment of combined periodontal-endodontic lesions requires multidisciplinary management to control the progression of bone defects. Some researchers reported cases that had short-term observations. However, to date, no case reports have described the use of both bone regeneration treatment and prosthodontic treatment for PRG. Herein, we report a patient with PRG who was treated with bone regeneration and prosthodontic treatments, and 2 years of follow-up showed a good prognosis. This report indicates that bone regeneration and prosthodontic treatment may contribute to the long-term favorable prognosis of teeth with PRGs.

Citation: Ling DH, Shi WP, Wang YH, Lai DP, Zhang YZ. Management of the palato-radicular groove with a periodontal regenerative procedure and prosthodontic treatment: A case report. *World J Clin Cases* 2022; 10(17): 5732-5740

URL: <https://www.wjgnet.com/2307-8960/full/v10/i17/5732.htm>

DOI: <https://dx.doi.org/10.12998/wjcc.v10.i17.5732>

INTRODUCTION

Palato-radicular groove (PRG) is defined as an anomalous formation of teeth that begins in the central fossa of the maxillary incisors, extends over the cingulum, and continues apically to varying depths and distances of the root surface[1]. The etiology of PRGs remains unclear. The most common proposals of PRG development include the following four hypotheses: (1) An abnormality in embryonic development, such as in folding of Hertwig's epithelial root sheath; (2) a variant of dens invaginatus; (3) genetic alteration; and (4) an attempt to form another root[2,3].

PRG usually occurs on the palatal side of the maxillary incisors that do not have dental caries or trauma[4,5]. The incidence of PRG ranges from 0.9% to 9.6% in extracted maxillary incisors[6,7] and from 2.8% to 10% in clinical studies[4,8]. Khan *et al*[9] reported a higher incidence of PRG in lateral incisors (13.4%) than in central incisors (7.6%). Various factors could account for this difference in prevalence rate, such as different diagnostic criteria, differences in examination methodologies, or ethnic/racial differences.

Micro-computed tomography (CT) and cone-beam CT have been widely used to observe lateral incisors with PRG. Gu[10] classified PRG into three types according to the depth and length of the radicular groove. Type I PRG has a short groove with limited length to the coronal third of the root. Type II PRG has a long groove, and its length is beyond the coronal third of the root, while its depth is often shallow. This implies that the root canal system of the tooth with a type II PRG is often simple. Type III PRG has a long and deep groove, which indicates a complex root canal system. However, this classification cannot be accurately applied in clinical practice because of complex cases and extremely small structures[11].

Teeth with deep grooves are more likely to show signs of periodontal disease such as bleeding, deep pocket depth, and endodontic-periodontal lesions[12]. Some researchers believe that there are multiple communication channels that exist between periodontal tissues and pulp, such as the apical foramen, accessory foramina, lateral canals, and dentin tubules[3]. Plaque and calculus accumulated in the periodontal pocket may extend into the bottom part of the deep groove with pulpal involvement[13]. The prognosis of a tooth with a PRG is unfavorable. It is influenced by several factors, such as the depth and length of the PRG, the anatomical morphology of the infected root canal system, and the severity of periodontal osseous defects[3].

Multidisciplinary management might be a better approach for treating PRG, but the current evidence is limited. To date, no case reports have observed multidisciplinary management, including endodontic treatment, bone regeneration treatment, and prosthodontic treatment, in the treatment of PRG. This study reports a patient with a type II PRG that was treated with this multidisciplinary approach and his observed prognosis during a 2-year period.

CASE PRESENTATION

Chief complaints

A 40-year-old male patient was admitted to the Department of General Dentistry, The Second Affiliated Hospital of Zhejiang University School of Medicine, with the chief complaint of slight mobility and abscess in the upper right anterior tooth for 15 d.

History of present illness

Slight mobility and abscess in the upper right anterior tooth for 15 d.

History of past illness

He experienced no pain or trauma in this region during the last 10 years.

Personal and family history

There was no personal or family history.

Physical examination

On examination, tooth 12 had an intact crown without defect or fracture, but it did not respond to electric pulp testing (DY310, Denjoy Dental, Changsha, Hunan Province, China). The mobility of tooth 12 was grade I, and it showed a sensitive response to percussion. There was a sinus tract on the buccal gingival surface close to tooth 12 (Figure 1A).

Laboratory examinations

Periodontal examination using a probe (KPC15, Shanghai Kangqiao Dental Instruments Factory, Shanghai, China) revealed a 14 mm depth on the distal side of the root (Figure 1B). The vitality test (Denjoy Dental, Changsha, Hunan Province, China) of tooth 12 was negative. A PRG emerged from the cingulum, which extended to the gingival sulcus and continued disto-apically down to the lingual aspect of the root (Figure 1C).

Imaging examinations

A cone-beam CT scan (Planmeca Romexis Viewer 4.5.0R, Planmeca Oy, Helsinki, Finland) revealed a radiolucency around the distal and palatal side of the root (Figure 1D and E). Dimensional reconstruction (Asentajankatu 6, FIN-00880, Helsinki, Finland) visualized a large bone defect and a long PRG extending up to the apical part of the tooth (Figure 1F and G).

FINAL DIAGNOSIS

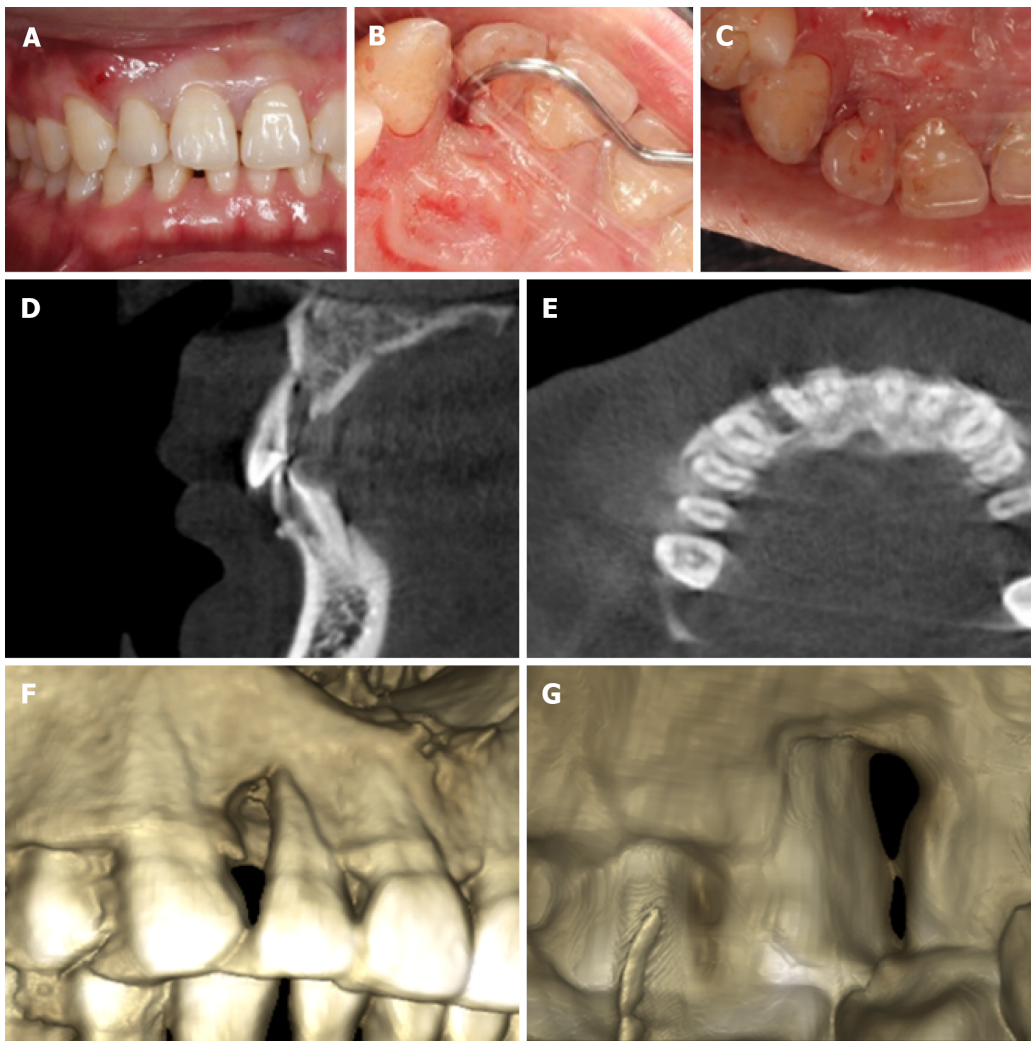
Based on the patient's history and clinical and radiographic examination findings, the lesion was diagnosed as a type II PRG with combined endodontic-periodontal lesions. The PRG caused accumulation of plaque and calculus, which in turn caused primary periodontitis and a secondary endodontic infection.

TREATMENT

A multidisciplinary management plan was designed, which comprised root canal therapy, groove sealing, periodontal regenerative procedures, and prosthodontic treatment. The patient signed the informed consent form after being informed about the treatment plan and the possible long-term prognosis of tooth 12.

Periodontal nonsurgical treatment was performed to remove the localized calculus. Root canal therapy was started under the isolation of a rubber dam after 1 wk. Cleaning and shaping were performed with K-files (Mani, Tochigi, Japan) and NiTi hand files (Dentsply Maillefer, Ballaigues, Switzerland). The canal was irrigated with 1% sodium hypochlorite and 0.9% normal saline. Canal filling was completed with gutta-percha (Gapadent, Tianjin, China) and iRoot SP (Innovative BioCeramix, Vancouver, BC, Canada) using the cold lateral compaction technique. The access cavity of the crown was filled with composite resin (3 M ESPE, St. Paul, MN, United States).

Two weeks later, the sinus tract disappeared just before periodontal surgery (Figure 2A). The surgical area (labiopalatine mucosa of teeth 13-22) was disinfected with 5% povidone-iodine after gargling with 0.2% chlorhexidine for 1 min, followed by local anesthesia with 5 mL of 2% lidocaine mixed with 1:100000 epinephrine. A full-thickness mucoperiosteal flap was reflected from the distal side of tooth 13 to the mesial side of tooth 11. The granulation tissue was curetted, and the surface of the root was planned with gracey curette number 5/6 (Hu-Friedy Mfg. Co., Chicago, IL, United States). After degran-



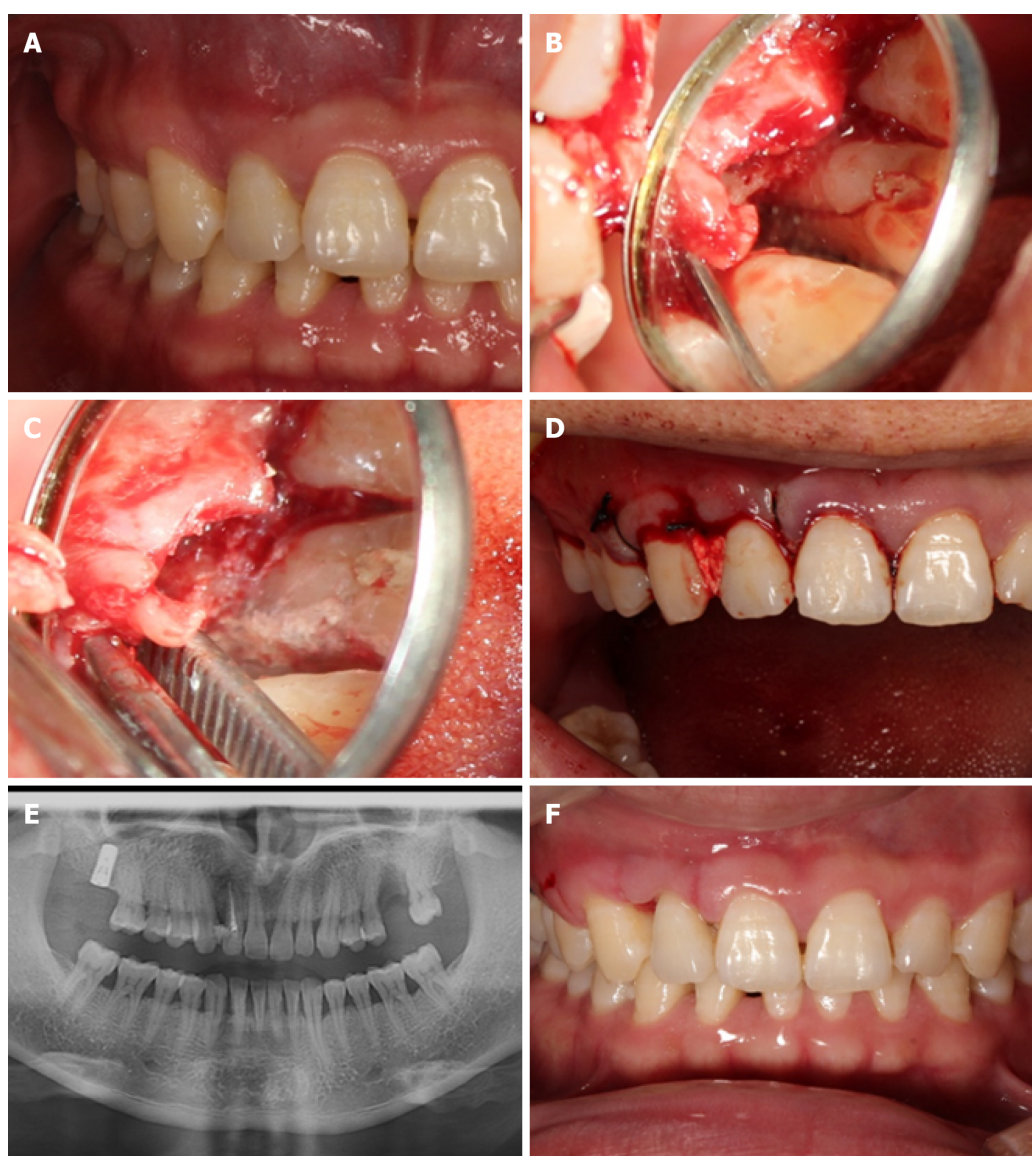
DOI: 10.12998/wjcc.v10.i17.5732 Copyright ©The Author(s) 2022.

Figure 1 Tooth 12 with a complex palato-radicular groove and bone defect. A: First visit photograph showed a sinus tract on the buccal gingival surface; B: Periodontal examination revealed a deep probing depth on the distal aspect of the tooth; C: Preoperative photograph showed a groove that emerged from the cingulum; D: Preoperative cone beam computed tomography showed a palatal radiolucency close to the apex of tooth 12; E: Axial view of the middle third section of tooth 12 showed radiolucency around the distal aspect of the root; F: Dimensional reconstruction showing a large bone defect around tooth 12; G: Dimensional reconstruction showed a groove starting from the cingulum and extending to the palatal aspect of the root.

ulation, a 6 mm × 14 mm pear-shaped defect was exposed (Figure 2B). A deep groove was visible extending to the apical part of the root. This groove was prepared with high-speed round diamond (Mani, Tochigi, Japan) under dental microscopy. Minocycline hydrochloride ointment was then applied for 5 min on the root to remove endotoxin. The area was isolated with a gelatin sponge (Jiangxi Xiangen Medical, Nanchang, Jiangxi Province, China) for hemostasis. The PRG was then sealed completely with iRoot BP Plus (Innovative BioCeramix, Vancouver, BC, Canada) (Figure 2C). Periodontal-guided tissue regeneration was performed using a 0.5 g bone graft (Geistlich Biomaterials, Wolhusen, Switzerland) and a 10 mm × 15 mm resorbable membrane (Geistlich Biomaterials, Wolhusen, Switzerland). The flap was sutured with a 3-0 black silk suture (Huawei Medical, Hangzhou, Zhejiang Province, China), and a periodontal dressing was placed (PULPDENT Corporation, Watertown, MA, United States) (Figure 2D). Postoperative panoramic radiography was performed after 2 h (Figure 2E). Cefuroxime axetil (500 mg twice a day for 3 d) and acetaminophen (325 mg twice a day for 1 d) were prescribed after surgery. The patient had no symptoms or discomfort, and sutures were removed after 8 d (Figure 2F).

OUTCOME AND FOLLOW-UP

The patient was re-examined at 6 wk, 3 mo, and 1 year, and 2 years after surgery. The healing was uneventful. At 1 year, there was a reduction in the pocket depth from 13 mm to 3 mm without bleeding. To prevent food impaction, veneer preparation was performed for tooth 12, and a lithium disilicate veneer (Ivoclar Vivadent, Schaan, Liechtenstein) was made to close the space between tooth 12 and



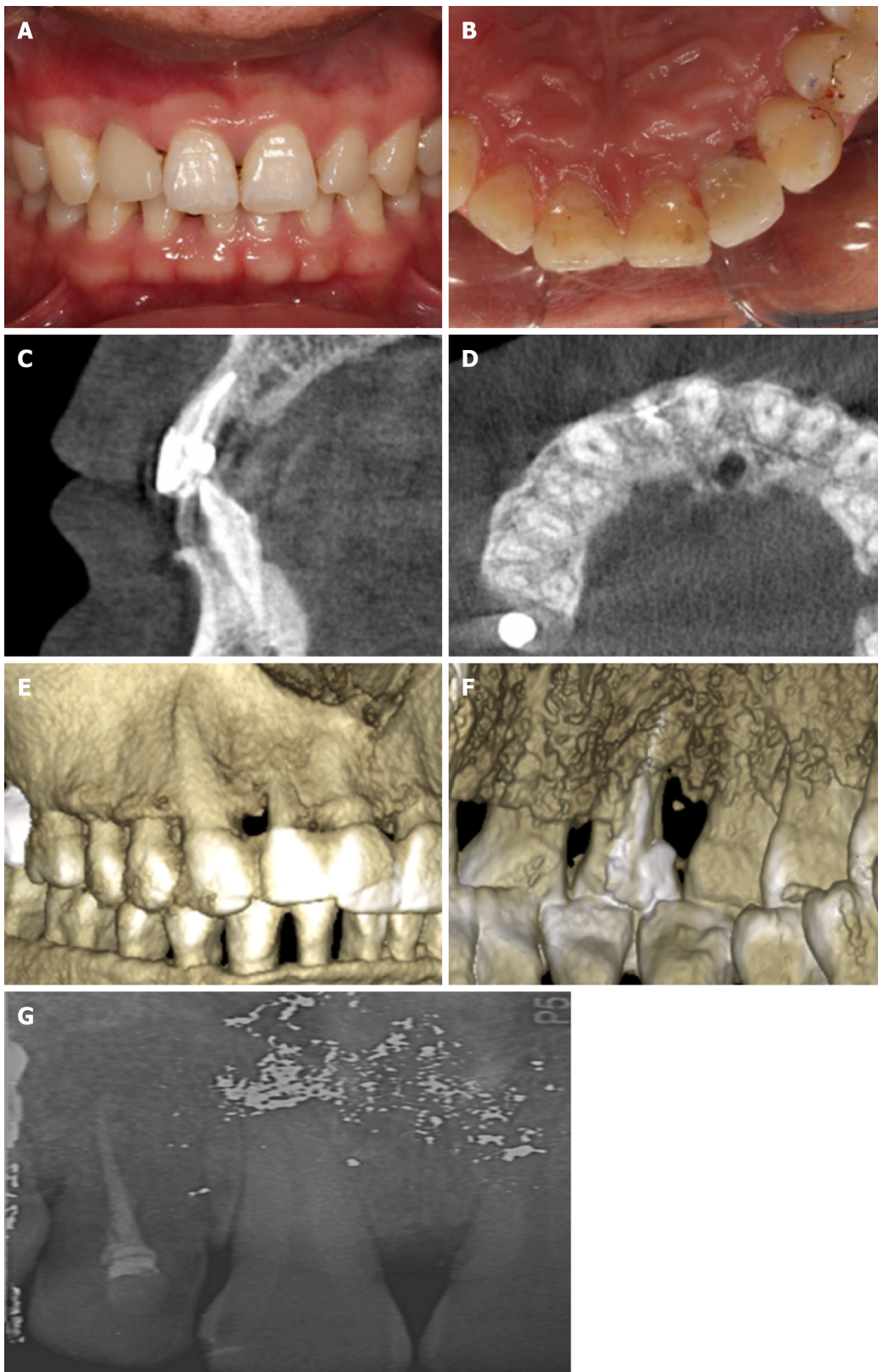
DOI: 10.12998/wjcc.v10.i17.5732 Copyright ©The Author(s) 2022.

Figure 2 Multidisciplinary management of tooth 12. (A) The sinus tract disappeared after root canal treatment; (B) A teardrop-shaped defect and a deep groove; (C) Palato-radicular groove sealed with iRoot BP Plus; (D) Suturing; (E) Postoperative panoramic radiography; (F) Image after removing sutures.

tooth 13 (Figure 3A and B). Postoperative cone-beam CT at 1 year showed significant bone formation around the tooth under dimensional reconstruction, and the PRG disappeared (Figure 3C and D). Dimensional reconstruction showed that the bone defect around tooth 12 disappeared. The sealing material was stable, and the groove became flat (Figure 3E and F). At 2 years, tooth 12 showed mild inflammation with dental calculus. However, the periapical radiograph confirmed that the alveolar bone around tooth 12 was stable (Figure 3G). Periodontal nonsurgical treatment was performed immediately.

DISCUSSION

Early diagnosis and treatment of a PRG may significantly improve its prognosis. Without periodontal disease and pulp impairment, conservative treatment, such as sealing the groove, can prevent complications[14]. Based on preoperative imaging findings, the patient was diagnosed with a type II PRG. Usually, shallow grooves are less likely to cause endodontic-periodontal lesions because the communication between the dental pulp and the periodontium is blocked. However, in the present case, the groove of tooth 12 was close to the apical part of the root. The apical foramen and accessory foramina may act as possible communication channels between periodontal infection and the pulp. Interdisciplinary approaches are recommended for managing such situations, such as degranulation of the defect, groove sealing, endodontic treatment, bone regeneration treatment, and prosthodontic



DOI: 10.12998/wjcc.v10.i17.5732 Copyright ©The Author(s) 2022.

Figure 3 Two-year follow-up after surgery. A: Buccal view of the clinical photograph after veneer preparation; B: Palatal view of the clinical photograph after veneer preparation; C: Postoperative cone beam computed tomography at 1 year showed the disappearance of diffuse radiolucency; D: Axial view of the middle third section of tooth 12 showed the filling of the bone defect around the distal aspect of the root; E: Dimensional reconstruction showed disappearance of the bone defect around tooth 12; F: Dimensional reconstruction showed that the groove was sealed; G: Periapical radiograph at the 2-year recall.

treatment[15]. Some unknown variables can significantly influence the oral environment. The use of probiotics[16] and natural compounds[17] can modify clinical and microbiological parameters in periodontal patients. They might also alter the outcomes of the technique described in the present

report. All these variables should be considered in future clinical trials. Although sealing the groove in type II PRGs remain controversial, some studies insist that root planning can achieve attachment[14,18]. The final goal of all treatments to make the root surface flat and smooth prevents the formation of plaque and calculus, which could lead to periodontal involvement[19]. There are various therapeutic options available, but the clinical cases are complex and need further exploration.

Many materials have been used for sealing grooves, such as amalgam, composite resin, glass ionomer cement, mineral trioxide aggregate, and iRoot BP plus. Glass ionomer cement has been widely used in the past 10 years, and its advantages include an antibacterial effect, chemical bonding ability, fluoride release property, and ability to attach to epithelial tissue[14,20]. Mineral trioxide aggregates show better biocompatibility. It exhibits lower microleakage when applied to seal the root canal and the periapical tissues[21]. However, the mean setting time of mineral trioxide aggregate is 165.5 min. This implies that mineral trioxide aggregate is unstable and may be washed away during setting[22]. iRoot BP Plus is a convenient and premixed hydraulic bioceramic putty that is newly developed for root canal repair and surgical applications. It shows a shorter setting time and better sealing ability than mineral trioxide aggregates[23]. iRoot BP Plus was also proven to trigger the osteogenic capacity of bone marrow mesenchymal stem cells[24]. Hence, we chose iRoot BP Plus as the sealing material. The healing of the tooth was uneventful, and the bone around the defect was stable after 2 years. To date, no studies have reported the results of iRoot BP Plus used in sealing PRGs. The present case may provide a clinical basis for a new application of this material. Additionally, laser[25] and ozone[26] therapies have been proposed for periodontal health, showing promising results. Future reports are required to test these therapies for PRG.

Restoration with porcelain veneers is the most conservative treatment according to the concept of minimally invasive dentistry. The final goals of this restorative treatment are to save tooth structure and restore function and esthetics. However, the aim of restoring the tooth with a veneer in the present case was to close the space between tooth 12 and tooth 13. Consequently, both food impaction and secondary periodontal problems were prevented. After 2 years of follow-up, the color of the veneer and alveolar bone was found to be stable. This suggests that prosthodontic treatment is necessary for the multidisciplinary management of PRG.

Multidisciplinary management might be a better option for optimal clinical outcomes for complex cases. However, when patients have an extensive groove area and severe complications, even a multidisciplinary approach with the combination of conservative treatment and local surgery cannot result in a favorable prognosis. Intentional extraction of a problematic tooth and subsequent reimplantation might be an alternative option for these patients[27]. On the other hand, this case report still deserves further investigation to confirm the actual role of the present multidisciplinary treatment considering the limited sample size.

CONCLUSION

We report a patient with a type II PRG who was treated with multidisciplinary treatment, including endodontic treatment, bone regeneration treatment, and prosthodontic treatment. The results of a 2-year follow-up indicate that bone regeneration and prosthodontic treatment may contribute to the long-term favorable prognosis of teeth with PRGs, which deserves further investigation.

FOOTNOTES

Author contributions: Ling DH and Zhang YZ contributed to the conception of the study; Shi WP designed the work; Wang YH and Lai DP contributed to the acquisition of the case; Zhang YZ revised the manuscript critically for important intellectual content; all authors have read the manuscript and gave their final approval of the version to be published.

Supported by the Young Innovative Talents of Zhejiang Province, No. 2022RC158.

Informed consent statement: Informed written consent was obtained from the patient for publication of this report and any accompanying images.

Conflict-of-interest statement: The authors declare that they have no conflict of interest.

CARE Checklist (2016) statement: The authors have read the CARE Checklist (2016), and the manuscript was prepared and revised according to the CARE Checklist (2016).

Open-Access: This article is an open-access article that was selected by an in-house editor and fully peer-reviewed by external reviewers. It is distributed in accordance with the Creative Commons Attribution NonCommercial (CC BY-NC 4.0) license, which permits others to distribute, remix, adapt, build upon this work non-commercially, and license their derivative works on different terms, provided the original work is properly cited and the use is non-

commercial. See: <https://creativecommons.org/licenses/by-nc/4.0/>

Country/Territory of origin: China

ORCID number: Dan-Hua Ling 0000-0002-6961-9237; Wei-Ping Shi 0000-0003-3441-0959; Yan-Hong Wang 0000-0002-7383-2866; Dan-Ping Lai 0000-0001-7248-8955; Yan-Zhen Zhang 0000-0001-7890-6281.

S-Editor: Guo XR

L-Editor: Filipodia

P-Editor: Guo XR

REFERENCES

- Gadagi JS**, Elavarasu S, Ananda D, Murugan T. Successful treatment of osseous lesion associated with palatoradicular groove using local drug delivery and guided tissue regeneration: A report of two cases. *J Pharm Bioallied Sci* 2012; **4**: S157-S160 [PMID: 23066240 DOI: 10.4103/0975-7406.100258]
- Ennes JP**, Lara VS. Comparative morphological analysis of the root developmental groove with the palato-gingival groove. *Oral Dis* 2004; **10**: 378-382 [PMID: 15533215 DOI: 10.1111/j.1601-0825.2004.01009.x]
- Kim HJ**, Choi Y, Yu MK, Lee KW, Min KS. Recognition and management of palatogingival groove for tooth survival: a literature review. *Restor Dent Endod* 2017; **42**: 77-86 [PMID: 28503472 DOI: 10.5395/rde.2017.42.2.77]
- Kishan KV**, Hegde V, Ponnappa KC, Girish TN, Ponappa MC. Management of palato radicular groove in a maxillary lateral incisor. *J Nat Sci Biol Med* 2014; **5**: 178-181 [PMID: 24678222 DOI: 10.4103/0976-9668.127322]
- Hungund S**, Kumar M. Palato-radicular groove and localized periodontitis: a series of case reports. *J Contemp Dent Pract* 2010; **11**: 056-062 [PMID: 20978725 DOI: 10.5005/jcdp-11-5-56]
- Aksoy U**, Kermeoğlu F, Kalender A, Eren H, Kolsuz ME, Orhan K. Cone-beam computed tomography evaluation of palatogingival grooves: A retrospective study with literature review. *Oral Radiol* 2017; **33**: 193-198 [DOI: 10.1007/s1282-017-0288-6]
- Storrer CM**, Sanchez PL, Romito GA, Pustiglioni FE. Morphometric study of length and grooves of maxillary lateral incisor roots. *Arch Oral Biol* 2006; **51**: 649-654 [PMID: 16615990 DOI: 10.1016/j.archoralbio.2006.02.008]
- Iqbal N**, Tirmazi SM, Majeed HA, Munir MB. Prevalence of palato gingival groove in maxillary lateral incisors. *Pak Oral Dent J* 2011; **31**: 424-426
- Khan AM**, Shah SA, Alam F, Ullah A, Humayun A, Nisar S, Mian FM. Frequency of palatogingival groove in maxillary incisors. *Pak Oral Dent J* 2019; **39**: 82-84
- Gu YC**. A micro-computed tomographic analysis of maxillary lateral incisors with radicular grooves. *J Endod* 2011; **37**: 789-792 [PMID: 21787490 DOI: 10.1016/j.joen.2011.03.002]
- Tan X**, Zhang L, Zhou W, Li Y, Ning J, Chen X, Song D, Zhou X, Huang D. Palatal Radicular Groove Morphology of the Maxillary Incisors: A Case Series Report. *J Endod* 2017; **43**: 827-833 [PMID: 28343927 DOI: 10.1016/j.joen.2016.12.025]
- Gandhi A**, Kathuria A, Gandhi T. Endodontic-periodontal management of two rooted maxillary lateral incisor associated with complex radicular lingual groove by using spiral computed tomography as a diagnostic aid: a case report. *Int Endod J* 2011; **44**: 574-582 [PMID: 21342210 DOI: 10.1111/j.1365-2591.2011.01868.x]
- Katwal D**, Fiorica JK, Bleuel J, Clark SJ. Successful Multidisciplinary Management of an Endodontic-Periodontal Lesion Associated With a Palato-Radicular Groove: A Case Report. *Clin Adv Periodontics* 2020; **10**: 88-93 [PMID: 31562681 DOI: 10.1002/cap.10079]
- Corr A-Faria P**, Alcântara CE, Santos CR, Marques LS, Ramos-Jorge ML. Palatal radicular groove: clinical implications of early diagnosis and surgical sealing. *J Indian Soc Pedod Prev Dent* 2011; **29**: S92-S94 [PMID: 22169847 DOI: 10.4103/0970-4388.90753]
- Miao H**, Chen M, Otgonbayar T, Zhang SS, Hou MH, Wu Z, Wang YL, Wu LG. Papillary reconstruction and guided tissue regeneration for combined periodontal-endodontic lesions caused by palatogingival groove and additional root: a case report. *Clin Case Rep* 2015; **3**: 1042-1049 [PMID: 26734143 DOI: 10.1002/ccr3.441]
- Butera A**, Gallo S, Maiorani C, Molino D, Chiesa A, Preda C, Esposito F, Scribante A. Probiotic Alternative to Chlorhexidine in Periodontal Therapy: Evaluation of Clinical and Microbiological Parameters. *Microorganisms* 2020; **9** [PMID: 33383903 DOI: 10.3390/microorganisms9010069]
- Costa-Pinto AR**, Lemos AL, Tavará FK, Pintado M. Chitosan and Hydroxyapatite Based Biomaterials to Circumvent Periprosthetic Joint Infections. *Materials (Basel)* 2021; **14** [PMID: 33567675 DOI: 10.3390/ma14040804]
- Schäfer E**, Cankay R, Ott K. Malformations in maxillary incisors: case report of radicular palatal groove. *Endod Dent Traumatol* 2000; **16**: 132-137 [PMID: 11202870 DOI: 10.1034/j.1600-9657.2000.016003132.x]
- Mahmood A**, Sajid M, Jamil M, Tahir MW. Palato Gingival Groove. *Prof Med J* 2019; **26**: 559-562 [DOI: 10.29309/TPMJ/2019.26.04.3351]
- Antonson SA**, Antonson DE, Brener S, Crutchfield J, Larumbe J, Michaud C, Yazici AR, Hardigan PC, Alempour S, Evans D, Ocanto R. Twenty-four month clinical evaluation of fissure sealants on partially erupted permanent first molars: glass ionomer versus resin-based sealant. *J Am Dent Assoc* 2012; **143**: 115-122 [PMID: 22298552 DOI: 10.14219/jada.archive.2012.0121]
- Patro S**, MohaPatra S, MiShra SJC, Research D. Comparative evaluation of apical microleakage of retrograde cavities filled with glass ionomer cement, light-cured composite, mineral trioxide aggregate and biodentine. *J Clin Diag Res* 2019; **13**: 18-22 [DOI: 10.7860/JCDR/2019/32601.12609]
- Goel M**, Bala S, Sachdeva G. Comparative evaluation of MTA, calcium hydroxide and portland cement as a root end filling

- materials: a comprehensive review. *Indian J Dent Sci* 2011; **3**: 83-88
- 23 **Aydemir S**, Cimilli H, Gerni PM, Bozkurt A, URUCOGLU H, Chandler N, Kartal N. Comparison of the sealing ability of biodentine, iRoot BP plus and mineral trioxide aggregate. *Cumhur Dent J* 2016; **19**: 166-171
- 24 **Lu J**, Li Z, Wu X, Chen Y, Yan M, Ge X, Yu J. iRoot BP Plus promotes osteo/odontogenic differentiation of bone marrow mesenchymal stem cells via MAPK pathways and autophagy. *Stem Cell Res Ther* 2019; **10**: 222 [PMID: [31358050](#) DOI: [10.1186/s13287-019-1345-3](#)]
- 25 **Tualzik T**, Chopra R, Gupta SJ, Sharma N, Khare M, Gulati L. Effects of ozonated olive oil and photobiomodulation using diode laser on gingival depigmented wound: A randomized clinical study. *J Indian Soc Periodontol* 2021; **25**: 422-426 [PMID: [34667386](#) DOI: [10.4103/jisp.jisp_655_20](#)]
- 26 **Butera A**, Gallo S, Pascadopoli M, Luraghi G, Scribante A. Ozonized Water Administration in Peri-Implant Mucositis Sites: A Randomized Clinical Trial. *Appl Sci* 2021; **11**: 7812 [DOI: [10.3390/app11177812](#)]
- 27 **Forero-López J**, Gamboa-Martínez L, Pico-Porras L, Niño-Barrera JL. Surgical management with intentional replantation on a tooth with palato-radicular groove. *Restor Dent Endod* 2015; **40**: 166-171 [PMID: [25984480](#) DOI: [10.5395/rde.2015.40.2.166](#)]



Published by **Baishideng Publishing Group Inc**
7041 Koll Center Parkway, Suite 160, Pleasanton, CA 94566, USA

Telephone: +1-925-3991568

E-mail: bpgoffice@wjgnet.com

Help Desk: <https://www.f6publishing.com/helpdesk>

<https://www.wjgnet.com>

