

World Journal of *Clinical Cases*

World J Clin Cases 2022 June 16; 10(17): 5518-5933



MINIREVIEWS

- 5518** Occult hepatitis B — the result of the host immune response interaction with different genomic expressions of the virus
Gherlan GS
- 5531** Pulmonary complications of portal hypertension: The overlooked decompensation
Craciun R, Mocan T, Procopet B, Nemes A, Tefas C, Sparchez M, Mocan LP, Sparchez Z
- 5541** Ethical review of off-label drugs during the COVID-19 pandemic
Li QY, Lv Y, An ZY, Dai NN, Hong X, Zhang Y, Liang LJ

ORIGINAL ARTICLE

Case Control Study

- 5551** Gut peptide changes in patients with obstructive jaundice undergoing biliary drainage: A prospective case control study
Pavić T, Pelajić S, Blažević N, Kralj D, Milošević M, Mikolasevic I, Lerotic I, Hrabar D

Retrospective Cohort Study

- 5566** Longitudinal assessment of liver stiffness by transient elastography for chronic hepatitis C patients
Mezina A, Krishnan A, Woreta TA, Rubenstein KB, Watson E, Chen PH, Rodriguez-Watson C

Retrospective Study

- 5577** Clinical evaluation of prone position ventilation in the treatment of acute respiratory distress syndrome induced by sepsis
Xia WH, Yang CL, Chen Z, Ouyang CH, Ouyang GQ, Li QG
- 5586** Three-dimensional arterial spin labeling and diffusion kurtosis imaging in evaluating perfusion and infarct area size in acute cerebral ischemia
Jiang YY, Zhong ZL, Zuo M
- 5595** Intrathecal methotrexate in combination with systemic chemotherapy in glioblastoma patients with leptomeningeal dissemination: A retrospective analysis
Kang X, Chen F, Yang SB, Wang YL, Qian ZH, Li Y, Lin H, Li P, Peng YC, Wang XM, Li WB
- 5606** Hepatic epithelioid hemangioendothelioma: Clinical characteristics, diagnosis, treatment, and prognosis
Zhao M, Yin F
- 5620** Difference between type 2 gastroesophageal varices and isolated fundic varices in clinical profiles and portosystemic collaterals
Song YH, Xiang HY, Si KK, Wang ZH, Zhang Y, Liu C, Xu KS, Li X

- 5634** Assessment of incidental focal colorectal uptake by analysis of fluorine-18 fluorodeoxyglucose positron emission tomography parameters

Lee H, Hwang KH, Kwon KA

Observational Study

- 5646** "Zero ischemia" laparoscopic partial nephrectomy by high-power GreenLight laser enucleation for renal carcinoma: A single-center experience

Zhang XM, Xu JD, Lv JM, Pan XW, Cao JW, Chu J, Cui XG

- 5655** High Eckardt score and previous treatment were associated with poor postperoral endoscopic myotomy pain control: A retrospective study

Chen WN, Xu YL, Zhang XG

- 5667** Higher volume growth rate is associated with development of worrisome features in patients with branch duct-intraductal papillary mucinous neoplasms

Innocenti T, Danti G, Lynch EN, Dragoni G, Gottin M, Fedeli F, Palatresi D, Biagini MR, Milani S, Miele V, Galli A

Prospective Study

- 5680** Application of a new anatomic hook-rod-pedicle screw system in young patients with lumbar spondylolysis: A pilot study

Li DM, Li YC, Jiang W, Peng BG

META-ANALYSIS

- 5690** Systematic review of Yougui pills combined with levothyroxine sodium in the treatment of hypothyroidism

Liu XP, Zhou YN, Tan CE

CASE REPORT

- 5702** Allogeneic stem cell transplantation-A curative treatment for paroxysmal nocturnal hemoglobinuria with PIGT mutation: A case report

Schenone L, Notarantonio AB, Latger-Cannard V, Fremeaux-Bacchi V, De Carvalho-Bittencourt M, Rubio MT, Muller M, D'Aveni M

- 5708** Gray zone lymphoma effectively treated with cyclophosphamide, doxorubicin, vincristine, prednisolone, and rituximab chemotherapy: A case report

Hojo N, Nagasaki M, Mihara Y

- 5717** Diagnosis of spontaneous isolated superior mesenteric artery dissection with ultrasound: A case report

Zhang Y, Zhou JY, Liu J, Bai C

- 5723** Adrenocorticotrophic hormone-secreting pancreatic neuroendocrine carcinoma with multiple organ infections and widespread thrombosis: A case report

Yoshihara A, Nishihama K, Inoue C, Okano Y, Eguchi K, Tanaka S, Maki K, Fridman D'Alessandro V, Takeshita A, Yasuma T, Uemura M, Suzuki T, Gabazza EC, Yano Y

- 5732** Management of the palato-radicular groove with a periodontal regenerative procedure and prosthodontic treatment: A case report

Ling DH, Shi WP, Wang YH, Lai DP, Zhang YZ

- 5741** Combined thoracic paravertebral block and interscalene brachial plexus block for modified radical mastectomy: A case report
Hu ZT, Sun G, Wang ST, Li K
- 5748** Chondromyxoid fibroma of the cervical spine: A case report
Li C, Li S, Hu W
- 5756** Preterm neonate with a large congenital hemangioma on maxillofacial site causing thrombocytopenia and heart failure: A case report
Ren N, Jin CS, Zhao XQ, Gao WH, Gao YX, Wang Y, Zhang YF
- 5764** Simultaneous multiple primary malignancies diagnosed by endoscopic ultrasound-guided fine-needle aspiration: A case report
Yang J, Zeng Y, Zhang JW
- 5770** Neuroendocrine tumour of the descending part of the duodenum complicated with schwannoma: A case report
Zhang L, Zhang C, Feng SY, Ma PP, Zhang S, Wang QQ
- 5776** Massive hemothorax following internal jugular vein catheterization under ultrasound guidance: A case report
Kang H, Cho SY, Suk EH, Ju W, Choi JY
- 5783** Unilateral adrenal tuberculosis whose computed tomography imaging characteristics mimic a malignant tumor: A case report
Liu H, Tang TJ, An ZM, Yu YR
- 5789** Modified membrane fixation technique in a severe continuous horizontal bone defect: A case report
Wang LH, Ruan Y, Zhao WY, Chen JP, Yang F
- 5798** Surgical repair of an emergent giant hepatic aneurysm with an abdominal aortic dissection: A case report
Wen X, Yao ZY, Zhang Q, Wei W, Chen XY, Huang B
- 5805** Heterotopic ossification beneath the upper abdominal incision after radical gastrectomy: Two case reports
Zhang X, Xia PT, Ma YC, Dai Y, Wang YL
- 5810** Non-alcoholic Wernicke encephalopathy in an esophageal cancer patient receiving radiotherapy: A case report
Zhang Y, Wang L, Jiang J, Chen WY
- 5816** New approach for the treatment of vertical root fracture of teeth: A case report and review of literature
Zhong X, Yan P, Fan W
- 5825** Ultrasound-guided microwave ablation as a palliative treatment for mycosis fungoides eyelid involvement: A case report
Chen YW, Yang HZ, Zhao SS, Zhang Z, Chen ZM, Feng HH, An MH, Wang KK, Duan R, Chen BD
- 5833** Pulp revascularization on an adult mandibular right second premolar: A case report
Yang YQ, Wu BL, Zeng JK, Jiang C, Chen M

- 5841** Barrett's esophagus in a patient with bulimia nervosa: A case report
Gouda A, El-Kassas M
- 5846** Spontaneous gallbladder perforation and colon fistula in hypertriglyceridemia-related severe acute pancreatitis: A case report
Wang QP, Chen YJ, Sun MX, Dai JY, Cao J, Xu Q, Zhang GN, Zhang SY
- 5854** Beware of gastric tube in esophagectomy after gastric radiotherapy: A case report
Yurttas C, Wichmann D, Gani C, Bongers MN, Singer S, Thiel C, Koenigsrainer A, Thiel K
- 5861** Transition from minimal change disease to focal segmental glomerulosclerosis related to occupational exposure: A case report
Tang L, Cai Z, Wang SX, Zhao WJ
- 5869** Lung adenocarcinoma metastasis to paranasal sinus: A case report
Li WJ, Xue HX, You JQ, Chao CJ
- 5877** Follicular lymphoma presenting like marginal zone lymphoma: A case report
Peng HY, Xiu YJ, Chen WH, Gu QL, Du X
- 5884** Primary renal small cell carcinoma: A case report
Xie K, Li XY, Liao BJ, Wu SC, Chen WM
- 5893** Gitelman syndrome: A case report
Chen SY, Jie N
- 5899** High-frame-rate contrast-enhanced ultrasound findings of liver metastasis of duodenal gastrointestinal stromal tumor: A case report and literature review
Chen JH, Huang Y
- 5910** Tumor-like disorder of the brachial plexus region in a patient with hemophilia: A case report
Guo EQ, Yang XD, Lu HR
- 5916** Response to dacomitinib in advanced non-small-cell lung cancer harboring the rare delE709_T710insD mutation: A case report
Xu F, Xia ML, Pan HY, Pan JW, Shen YH
- 5923** Loss of human epidermal receptor-2 in human epidermal receptor-2+ breast cancer after neoadjuvant treatment: A case report
Yu J, Li NL

LETTER TO THE EDITOR

- 5929** Repetitive transcranial magnetic stimulation for post-traumatic stress disorder: Lights and shadows
Concerto C, Lanza G, Fisicaro F, Pennisi M, Rodolico A, Torrisi G, Bella R, Aguglia E

ABOUT COVER

Editorial Board Member of *World Journal of Clinical Cases*, Raden Andri Primadhi, MD, PhD, Assistant Professor, Surgeon, Department of Orthopaedics and Traumatology, Universitas Padjadjaran Medical School, Hasan Sadikin Hospital, Bandung 40161, Indonesia. randri@unpad.ac.id

AIMS AND SCOPE

The primary aim of *World Journal of Clinical Cases* (WJCC, *World J Clin Cases*) is to provide scholars and readers from various fields of clinical medicine with a platform to publish high-quality clinical research articles and communicate their research findings online.

WJCC mainly publishes articles reporting research results and findings obtained in the field of clinical medicine and covering a wide range of topics, including case control studies, retrospective cohort studies, retrospective studies, clinical trials studies, observational studies, prospective studies, randomized controlled trials, randomized clinical trials, systematic reviews, meta-analysis, and case reports.

INDEXING/ABSTRACTING

The WJCC is now indexed in Science Citation Index Expanded (also known as SciSearch®), Journal Citation Reports/Science Edition, Scopus, PubMed, and PubMed Central. The 2021 Edition of Journal Citation Reports® cites the 2020 impact factor (IF) for WJCC as 1.337; IF without journal self cites: 1.301; 5-year IF: 1.742; Journal Citation Indicator: 0.33; Ranking: 119 among 169 journals in medicine, general and internal; and Quartile category: Q3. The WJCC's CiteScore for 2020 is 0.8 and Scopus CiteScore rank 2020: General Medicine is 493/793.

RESPONSIBLE EDITORS FOR THIS ISSUE

Production Editor: Hua-Ge Yin, Production Department Director: Xiang Li, Editorial Office Director: Jin-Lai Wang.

NAME OF JOURNAL

World Journal of Clinical Cases

ISSN

ISSN 2307-8960 (online)

LAUNCH DATE

April 16, 2013

FREQUENCY

Thrice Monthly

EDITORS-IN-CHIEF

Bao-Gan Peng, Jerzy Tadeusz Chudek, George Kontogeorgos, Maurizio Serati, Ja Hyeon Ku

EDITORIAL BOARD MEMBERS

<https://www.wjgnet.com/2307-8960/editorialboard.htm>

PUBLICATION DATE

June 16, 2022

COPYRIGHT

© 2022 Baishideng Publishing Group Inc

INSTRUCTIONS TO AUTHORS

<https://www.wjgnet.com/bpg/gerinfo/204>

GUIDELINES FOR ETHICS DOCUMENTS

<https://www.wjgnet.com/bpg/GerInfo/287>

GUIDELINES FOR NON-NATIVE SPEAKERS OF ENGLISH

<https://www.wjgnet.com/bpg/gerinfo/240>

PUBLICATION ETHICS

<https://www.wjgnet.com/bpg/GerInfo/288>

PUBLICATION MISCONDUCT

<https://www.wjgnet.com/bpg/gerinfo/208>

ARTICLE PROCESSING CHARGE

<https://www.wjgnet.com/bpg/gerinfo/242>

STEPS FOR SUBMITTING MANUSCRIPTS

<https://www.wjgnet.com/bpg/GerInfo/239>

ONLINE SUBMISSION

<https://www.f6publishing.com>



Pulp revascularization on an adult mandibular right second premolar: A case report

Ye-Qing Yang, Bu-Ling Wu, Jun-Kai Zeng, Chong Jiang, Ming Chen

Specialty type: Dentistry, oral surgery and medicine

Provenance and peer review: Unsolicited article; Externally peer reviewed.

Peer-review model: Single blind

Peer-review report's scientific quality classification

Grade A (Excellent): A
Grade B (Very good): B
Grade C (Good): 0
Grade D (Fair): 0
Grade E (Poor): 0

P-Reviewer: Cappare P, Italy;
Ghaffar KA, Egypt

Received: December 13, 2021

Peer-review started: December 13, 2021

First decision: March 7, 2022

Revised: March 18, 2022

Accepted: April 3, 2022

Article in press: April 3, 2022

Published online: June 16, 2022



Ye-Qing Yang, Ming Chen, Department of Stomatology, Stomatological Hospital of Southern Medical University, Guangzhou 510280, Guangdong Province, China

Ye-Qing Yang, Jun-Kai Zeng, School of Stomatology, Southern Medical University, Guangzhou 510515, Guangdong Province, China

Bu-Ling Wu, Shenzhen Stomatology Hospital (Pingshan), Southern Medical University, Shenzhen 518118, Guangdong Province, China

Chong Jiang, Department of Stomatology, Guangdong Provincial People's Hospital; Guangdong Academy of Medical Sciences, Guangzhou 510080, Guangdong Province, China

Corresponding author: Ming Chen, MD, Attending Doctor, Department of Stomatology, Stomatological Hospital of Southern Medical University, No. 366 Jiangnan Avenue South, Haizhu District, Guangzhou 510280, Guangdong Province, China. kumiming@smu.edu.cn

Abstract

BACKGROUND

Pulp revascularization has become a new method for the treatment of periapical diseases in young permanent teeth in recent years. Through root canal flushing and disinfection, avoiding mechanical preparation, guiding apical stem cells into the root canal and promoting the continuous development of tooth roots, it has achieved good clinical curative effects. But in adult patients with chronic periapical periodontitis with immature roots and open apices, apical barrier technology is often used to treat these teeth.

CASE SUMMARY

Pulp revascularization of a 26-year-old patient's tooth was performed using cefaclor instead of minocycline and iRoot BP instead of mineral trioxide aggregate as intracanal medication. The case was followed up for 36 mo. Observations showed evidence of regression of clinical signs and symptoms, resolution of apical periodontitis and no discolouration of affected teeth.

CONCLUSION

For adult patients with chronic periapical periodontitis with immature roots and open apices, pulp revascularisation showed favourable results in treating these teeth.

Key Words: Pulp revascularization; Chronic periapical periodontitis; Immature roots; Open

apices; Abnormal central tip; Case report

©The Author(s) 2022. Published by Baishideng Publishing Group Inc. All rights reserved.

Core Tip: Pulp revascularization is especially suitable for young permanent teeth with incomplete apical development. However, few scholars have reported on adult teeth with apical periodontitis caused by an abnormal central tip being treated with dental pulp revascularization technology. The purpose of this case report was to describe the potential of using pulp revascularization to treat a permanent adult tooth.

Citation: Yang YQ, Wu BL, Zeng JK, Jiang C, Chen M. Pulp revascularization on an adult mandibular right second premolar: A case report. *World J Clin Cases* 2022; 10(17): 5833-5840

URL: <https://www.wjgnet.com/2307-8960/full/v10/i17/5833.htm>

DOI: <https://dx.doi.org/10.12998/wjcc.v10.i17.5833>

INTRODUCTION

Pulp revascularization has become a new method for the treatment of periapical diseases in young permanent teeth in recent years. Through root canal flushing and disinfection, avoiding mechanical preparation, guiding apical stem cells into the root canal and promoting the continuous development of tooth roots, it has achieved good clinical curative effects[1,2]. Initially, Holden *et al*[3] stimulated apical tissue bleeding to treat young permanent tooth periapical disease according to the mechanism of trauma healing caused by blood clots. They used the blood cells of necrotic teeth to regenerate tissue in the root canal but only formed approximately 2 mm of granulation tissue in the root tip. With the improvement of root canal disinfection and crown sealing technology, in 2001, Iwaya *et al*[4] placed antibiotics in the root canal for disinfection when treating a young permanent tooth patient with chronic periapical disease, stimulated apical bleeding and filled the root canal. Finally, the crown was tightly sealed with mineral trioxide aggregate (MTA). After 30 mo of follow-up, the root of the affected tooth continued to develop, the root canal wall thickened, the root tip closed, and an electrical activity test continued to show positive results[4]. An increasing number of clinicians have used this method and obtained similar results.

The biological mechanism of pulp revascularization is still unknown. The main process is thorough and effective root canal disinfection. Root canal disinfection and chemical irrigation are used to remove infectious materials in the root canal. Commonly used rinsing fluids include 1.5%-3% sodium hypochlorite solution and 17% EDTA solution[5]. After chemical preparation, the root canal is sealed with a triple antibacterial paste, which is generally composed of ciprofloxacin, metronidazole and minocycline[6,7]. During the treatment process, it is best to protect the residual dental pulp tissue, dental pulp stem cells and apical papillary stem cells. Studies have shown that stem cells that isolated from various problems of the oral cavity have emerged as important sources for bone and dental regulation, given stem cells plasticity, they can differentiate into specific cell lineages with a capacity of almost unlimited self-renewal and release of trophic/immunomodular factors[8-10]. These stem cells have different differentiation potentials induced by signalling molecules and the bioactive material MTA, which can form dental pulp and dentin and periodontal ligaments[11,12]. Subsequently, a regenerative scaffold based on blood clots is formed, and growth factors are provided. Some scholars have added platelet-rich plasma or platelet-rich fibrin[13]. The effect is good, but this approach involves blood product extraction and technical sensitivity. Its application prospects are still unknown. Finally, a tight crown seal is performed to provide a good environment for stem cell proliferation and differentiation, thereby promoting the continued development of tooth roots. Here we present a male adult patient with chronic periapical periodontitis with immature roots and open apices, and this tooth used pulp revascularisation to show a favourable result.

CASE PRESENTATION

Chief complaints

A 26-year-old man presented with an abscess for more than one month associated with a right mandibular posterior tooth.

History of present illness

A 26-year-old male presented for more than one month history of an abscess on the right mandibular posterior tooth. The patient did not receive any treatment for the affected tooth.

History of past illness

The patient had no history of any previous disease.

Personal and family history

The patient had no personal and family history.

Physical examination

An extraoral examination revealed no abnormalities. There were no palpable lymph nodes in the head and neck. An intraoral examination showed that the abscess was localized buccally in the periapical region of the right mandibular second premolar (Figure 1A). Pressing the abscess showed yellowish white pus discharging. The occlusal surface of the affected tooth showed an abnormal central cusp worn away, a mild response to percussion/palpation, a periodontal pocket probing depth within normal limits (3-4 mm), and no pathologic tooth mobility. The tooth did not show any response to cold and hot pulp sensitivity tests.

Imaging examinations

A radiographic examination revealed the presence of a periapical lesion associated with an immature root with an apical (Figure 1B).

FINAL DIAGNOSIS

Based on the patient's history and clinical and radiographic examinations, the right mandibular second premolar was diagnosed with chronic periapical periodontitis.

TREATMENT

Treatment options, including pulp revascularization technology and apical barrier technology, were presented to the patient. The advantages and disadvantage of the two technologies were discussed with the patient. The patient was informed that the outcome of pulp revascularization for adult permanent teeth with persistent apical periodontitis was unknown. The patient opted for pulp revascularization. The timeline of this case is presented in Table 1.

First treatment visit

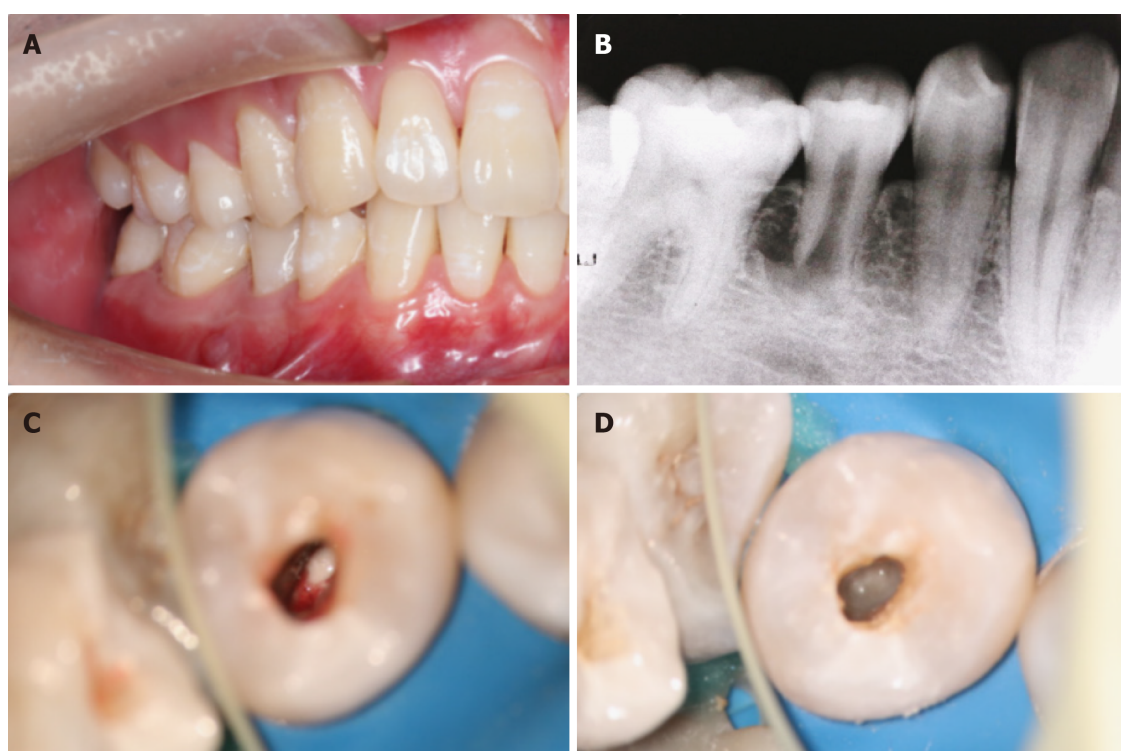
Local anaesthesia with 2% lidocaine containing 1:100000 epinephrine was administered. The tooth was isolated with a rubber dam, and the pulp cavity was accessed with a carbide bur under a microscope. Pus could be seen in the root canal (Figure 1C). The root canal was rinsed with 3% sodium hypochlorite and 17% EDTA and dried with sterile paper points. Granulation tissue could be seen at the apical. The working length (WL) 0.5 mm short of the radiographic apex was determined with an electronic apex locator and periapical radiography (WL = 15 mm). Due to the large apical foramen, chemical preparation was emphasized, and mechanical preparation was assisted. Low-concentration (0.1-1.0 mg/mL) triple antibiotic paste was used to seal the root canal (Figure 1D), which was composed of ciprofloxacin, metronidazole and cefaclor (1:1:1). The access cavity was closed with a sterile cotton pellet and temporary restorative material.

Second treatment visit

Two weeks after the first treatment visit, the localized sinus had subsided, and the tooth was asymptomatic (Figure 2A). Local anaesthesia with 2% mepivacaine without a vasoconstrictor was administered. The tooth was isolated with a rubber dam, and the seal was removed with a carbide bur under a microscope. Triple antibacterial paste in the canal was removed with copious amounts of 3% sodium hypochlorite and 17% EDTA irrigation and dried with paper points. A #10 K-file was used to penetrate the periapical tissue and provoke periapical bleeding into the canal, reaching the position of the enamel-cemental junction (Figure 2B). After the bleeding became semicoagulated, an absorbable gelatine sponge was placed as a stop point (Figure 2C), and then an iRoot BP of approximately 3-mm thickness was placed over the absorbable gelatine sponge (Figure 2D). A moist cotton pellet was placed over the iRoot BP, and the access cavity was closed with temporary restorative material.

Table 1 Timeline of the case

Timeline	Events	
September 30, 2018	First treatment visit	Triple antibiotic paste was used to seal the root canal
October 15, 2018	Second treatment visit	Penetrated the periapical tissue and provoked bleeding into the canal
October 16, 2018	Third treatment visit	The access cavity was restored with light-curing composite resin
April 23, 2019	6-mo follow-up	The periapical lesion had slightly decreased in size
October 22, 2019	12-mo follow-up	The periapical lesion was smaller than before
October 14, 2020	24-mo follow-up	The periapical lesion showed further radiographic evidence of healing
October 23, 2021	36-mo follow-up	Indicating reparation of the periapical lesion



DOI: 10.12998/wjcc.v10.i17.5833 Copyright ©The Author(s) 2022.

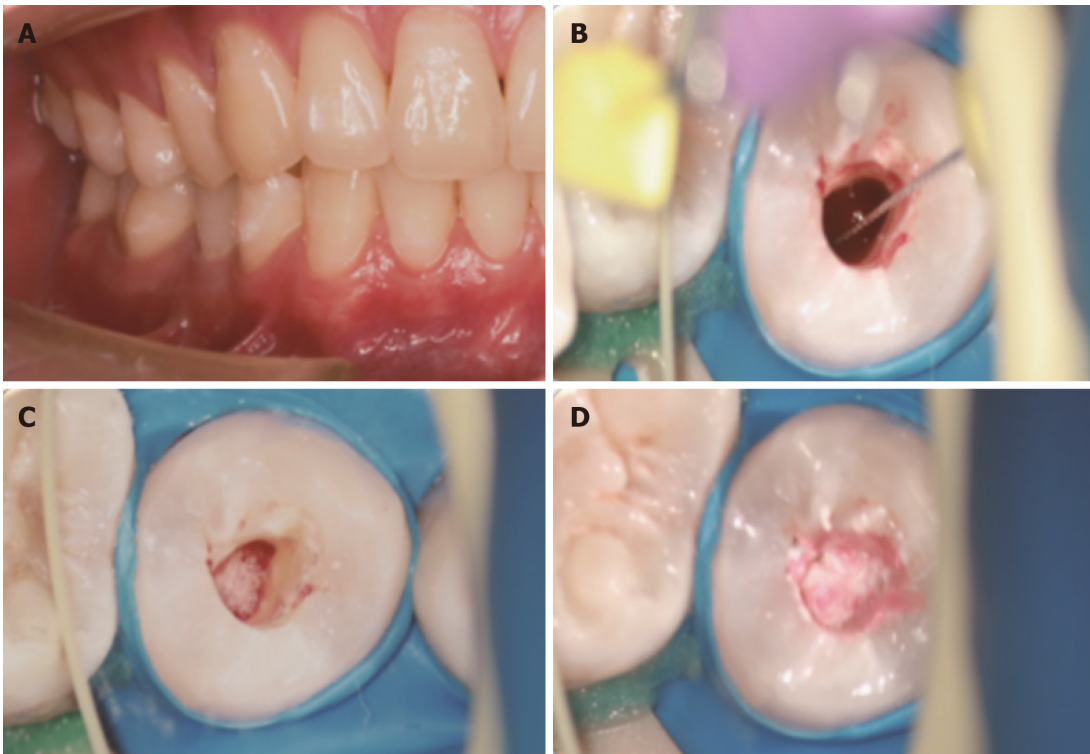
Figure 1 First treatment visit. A: Preoperative view; B: A preoperative periapical radiograph; C: Pus could be seen in the root canal; D: Triple antibiotic paste was used to seal the root canal.

Third treatment visit

One day after the second treatment visit, the temporary restorative material and cotton pellet were removed from the access cavity. It was determined that the iRoot BP had completely hardened. The access cavity was restored with light-curing composite resin.

OUTCOME AND FOLLOW-UP

At the 6-mo follow-up, the periapical lesion had slightly decreased in size (Figure 3C). At the 12-mo follow-up, the periapical lesion was smaller than before (Figure 3D). At the 24-mo follow-up visit, the periapical lesion showed further radiographic evidence of healing, showing the improvement of pulp revascularization treatment (Figure 3E). The same was observed at the 36-mo follow-up visits, indicating reparation of the periapical lesion (Figure 3F). At the same time, the affected teeth did not discolouration (Figure 4A and B). However, the tooth of the canal walls did not thicken, and the apex also did not appear to have closed and did not respond to pulp tests with cold, heat, and electric pulp tests.



DOI: 10.12998/wjcc.v10.i17.5833 Copyright ©The Author(s) 2022.

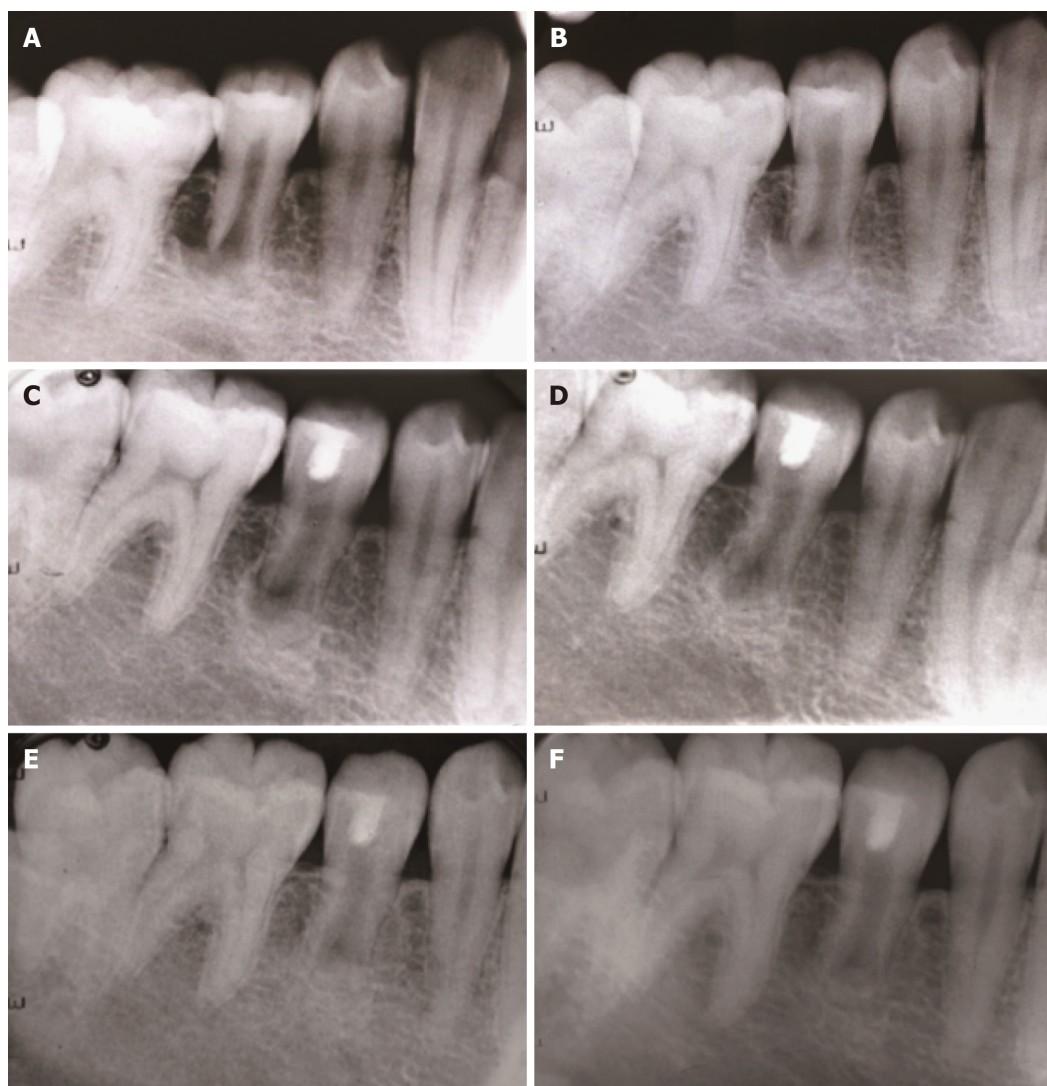
Figure 2 Second treatment visit. A: Second treatment visit view; B: A #10 K-file was used to provoke periapical bleeding into the canal; C: Placed an absorbable gelatine sponge; D: Placed an iRoot BP.

DISCUSSION

In the present case report, we have described the potential of using pulp revascularization to treat adult permanent teeth with apical periodontitis. In adult patients with chronic periapical periodontitis with immature roots and open apices, apical barrier technology is often used to treat these teeth. Apical barrier technology refers to the use of MTA to form an immediate artificial barrier in the apical area for sealing[14]. However, this technology has a high cost and difficult clinical manipulation. In addition, clinical treatment and follow-up visits found that apical barrier technology caused less root development and no thickening of the root wall or extension of the root length[15]. In this case, pulp revascularization with easy clinical manipulation was used, and the final effect on affected teeth was good. However, there is inadequate literature to support that pulp revascularization has a good effect on adult patients with immature roots and open apical teeth[15].

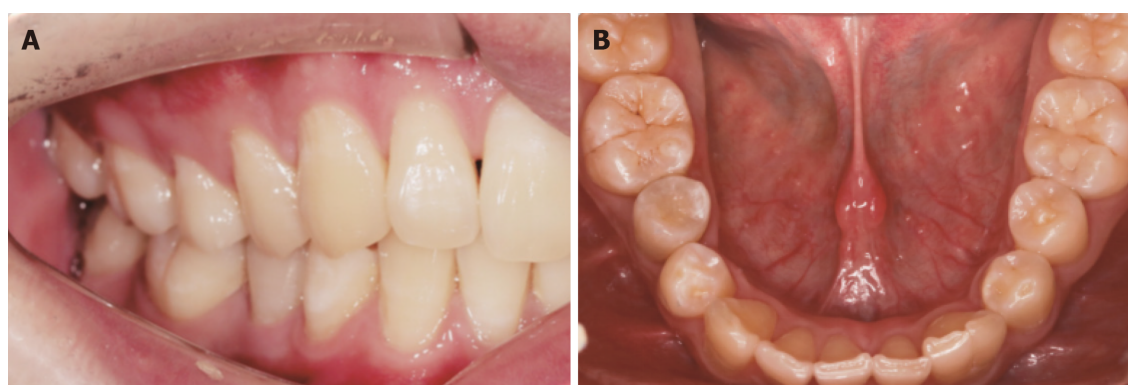
At present, there is no consistent standard for evaluating the efficacy of pulp revascularization. The curative effect has been mainly based on clinical manifestation, pulp vitality examination and radiographic examination. According to the American Association of Endodontists guidelines, the primary goals are healing apical periodontitis and eliminating clinical symptoms. Increased thickening of the canal walls and/or continued root development as well as a positive response to cold and hot pulp sensitivity tests are desirable but not essential to determine success[16]. In this case, the periapical lesions healed, but root development stopped and remained in a static state. The reason may be the lack and low activity of stem cells in adult permanent teeth, although stem cells cannot provide the best function. Therefore, the selection and implantation of endogenous or exogenous biological scaffolds may be a very important step in the treatment of adult permanent teeth. However, at present, there is no literature citing which kind of scaffold has a better curative effect on adult permanent teeth.

A common complication of revascularization is tooth discoloration. Previous studies have suggested that tooth discoloration is related to the triple antibiotic paste. Minocycline is considered to form a chelate with calcium ions in dentinal tubules, which changes the refractive index of teeth and causes tooth discoloration[17]. Cefaclor is an antibiotic alternative to minocycline. Thibodeau *et al*[18] and Dabbagh *et al*[19] proposed replacing minocycline with cefaclor and reported successful regenerative treatment using this technique. It has also been suggested that the possible mechanism of tooth discoloration may be related to the interaction between MTA and blood and the blockade of dentinal tubules [20]. In this case, there was no obvious discoloration of the affected teeth, which may be because cefaclor was used instead of minocycline and iRoot BP was used instead of MTA. Some studies have found that iRoot BP promotes increased alkaline phosphatase activity compared with MTA, and iRoot BP has better biocompatibility and repair performance and promotes the expression of factors related to



DOI: 10.12998/wjcc.v10.i17.5833 Copyright ©The Author(s) 2022.

Figure 3 Periapical radiographs. A: A preoperative periapical radiograph; B: An intraoperative periapical radiograph; C: At the 6-mo follow-up, a periapical radiograph; D: At the 12-mo follow-up, a periapical radiograph; E: At the 24-mo follow-up, a periapical radiograph; F: At the 36-mo follow-up, a periapical radiograph.



DOI: 10.12998/wjcc.v10.i17.5833 Copyright ©The Author(s) 2022.

Figure 4 Postoperative view. A and B: At the 36-mo follow-up, a postoperative view.

odontogenic differentiation, so it has a higher biomineralization ability and induces dentin differentiation[21]. Until a large number of reliable clinical cases prove that cefaclor and iRoot BP improve the success rate, this approach can be used according to the principle of evidence-based medicine.

CONCLUSION

In this case, it was possible to observe that pulp revascularisation in immature roots with open apical teeth was clinically and radiographically relatively successful, as was evident in the 36 mo of follow-up, with repair of the periapical lesion. Such facts demonstrate that immature roots with open apical teeth, necrotic pulp and apical periodontitis can be treated using revascularization. It may be preferable to fill the root canals with the host's own vital tissue rather than with artificial material. However, randomized, prospective clinical trials are needed to demonstrate that the treatment outcome of pulp revascularisation is better.

FOOTNOTES

Author contributions: Yang YQ wrote the main manuscript text, collected the case; Wu BL revised manuscript editing; Zeng JK and Jiang C collected data and prepared Figures; Chen M designed the study, performed critical revisions; all authors reviewed the manuscript; all authors read and approved the final manuscript.

Supported by General Program of National Natural Scientific Foundation of China, No. 81870755; Medical Scientific Research Foundation of Guangdong Province of China, No. A2022199; and Science Research Cultivation Program of Stomatological Hospital, Southern Medical University, No. PY2020018 and No. PY2021021.

Informed consent statement: Written informed consent was obtained from the patient for publication of this report and any accompanying images.

Conflict-of-interest statement: The authors declare no conflict of interest.

CARE Checklist (2016) statement: The authors have read the CARE Checklist (2016), and the manuscript was prepared and revised according to the CARE Checklist (2016).

Open-Access: This article is an open-access article that was selected by an in-house editor and fully peer-reviewed by external reviewers. It is distributed in accordance with the Creative Commons Attribution NonCommercial (CC BY-NC 4.0) license, which permits others to distribute, remix, adapt, build upon this work non-commercially, and license their derivative works on different terms, provided the original work is properly cited and the use is non-commercial. See: <https://creativecommons.org/licenses/by-nc/4.0/>

Country/Territory of origin: China

ORCID number: Ye-Qing Yang 0000-0002-7931-1009; Bu-Ling Wu 0000-0001-5499-0693; Jun-Kai Zeng 0000-0003-4515-011X; Chong Jiang 0000-0001-8324-4112; Ming Chen 0000-0003-3440-0232.

S-Editor: Gong ZM

L-Editor: A

P-Editor: Gong ZM

REFERENCES

- 1 **Saoud TM**, Huang GT, Gibbs JL, Sigurdsson A, Lin LM. Management of Teeth with Persistent Apical Periodontitis after Root Canal Treatment Using Regenerative Endodontic Therapy. *J Endod* 2015; **41**: 1743-1748 [PMID: 26279479 DOI: 10.1016/j.joen.2015.07.004]
- 2 **Brogni JK**, Vitali FC, Cardoso IV, Dos Santos JD, Prado M, Alves AMH, Duque TM. A second attempt at pulp revascularisation on an immature traumatised anterior tooth: a case report with two-year follow-up. *Aust Endod J* 2021; **47**: 90-96 [PMID: 33247881 DOI: 10.1111/aej.12466]
- 3 **Holden T**, Nygaard-Ostby B. [Treatment of pulp necrosis developing before the root is fully formed]. *Nor Tannlaegeforen Tid* 1968; **78**: 740-743 [PMID: 5257799]
- 4 **Iwaya SI**, Ikawa M, Kubota M. Revascularization of an immature permanent tooth with apical periodontitis and sinus tract. *Dent Traumatol* 2001; **17**: 185-187 [PMID: 11585146 DOI: 10.1034/j.1600-9657.2001.017004185.x]
- 5 **Zeng Q**, Nguyen S, Zhang H, Chebrolu HP, Alzebeid D, Badi MA, Kim JR, Ling J, Yang M. Release of Growth Factors into Root Canal by Irrigations in Regenerative Endodontics. *J Endod* 2016; **42**: 1760-1766 [PMID: 27871480 DOI: 10.1016/j.joen.2016.04.029]
- 6 **do Couto AM**, Espaladori MC, Leite APP, Martins CC, de Aguiar MCF, Abreu LG. A Systematic Review of Pulp Revascularization Using a Triple Antibiotic Paste. *Pediatr Dent* 2019; **41**: 341-353 [PMID: 31648664]
- 7 **Montero-Miralles P**, Martín-González J, Alonso-Ezpeleta O, Jiménez-Sánchez MC, Velasco-Ortega E, Segura-Egea JJ. Effectiveness and clinical implications of the use of topical antibiotics in regenerative endodontic procedures: a review. *Int Endod J* 2018; **51**: 981-988 [PMID: 29480932 DOI: 10.1111/iej.12913]
- 8 **Tetè G**, Capparè P, Gherlone E. New Application of Osteogenic Differentiation from HiPS Stem Cells for Evaluating the

- Osteogenic Potential of Nanomaterials in Dentistry. *Int J Environ Res Public Health* 2020; **17** [PMID: [32188154](#) DOI: [10.3390/ijerph17061947](#)]
- 9 **Cappare P**, Tetè G, Sberna MT, Panina-Bordignon P. The Emerging Role of Stem Cells in Regenerative Dentistry. *Curr Gene Ther* 2020; **20**: 259-268 [PMID: [32811413](#) DOI: [10.2174/1566523220999200818115803](#)]
- 10 **Tetè G**, D'Orto B, Nagni M, Agostinacchio M, Polizzi E, Agliardi E. Role of induced pluripotent stem cells (IPSCS) in bone tissue regeneration in dentistry: a narrative review. *J Biol Regul Homeost Agents* 2020; **34**: 1-10 [PMID: [33386051](#)]
- 11 **Kaukua N**, Shahidi MK, Konstantinidou C, Dyachuk V, Kaucka M, Furlan A, An Z, Wang L, Hultman I, Ahrlund-Richter L, Blom H, Brismar H, Lopes NA, Pachnis V, Suter U, Clevers H, Thesleff I, Sharpe P, Ernfors P, Fried K, Adameyko I. Glial origin of mesenchymal stem cells in a tooth model system. *Nature* 2014; **513**: 551-554 [PMID: [25079316](#) DOI: [10.1038/nature13536](#)]
- 12 **Chrepa V**, Henry MA, Daniel BJ, Diogenes A. Delivery of Apical Mesenchymal Stem Cells into Root Canals of Mature Teeth. *J Dent Res* 2015; **94**: 1653-1659 [PMID: [26195498](#) DOI: [10.1177/0022034515596527](#)]
- 13 **Ulusoy AT**, Turedi I, Cimen M, Cehreli ZC. Evaluation of Blood Clot, Platelet-rich Plasma, Platelet-rich Fibrin, and Platelet Pellet as Scaffolds in Regenerative Endodontic Treatment: A Prospective Randomized Trial. *J Endod* 2019; **45**: 560-566 [PMID: [30935618](#) DOI: [10.1016/j.joen.2019.02.002](#)]
- 14 **Torabinejad M**, Chivian N. Clinical applications of mineral trioxide aggregate. *J Endod* 1999; **25**: 197-205 [PMID: [10321187](#) DOI: [10.1016/S0099-2399\(99\)80142-3](#)]
- 15 **Kim SG**, Malek M, Sigurdsson A, Lin LM, Kahler B. Regenerative endodontics: a comprehensive review. *Int Endod J* 2018; **51**: 1367-1388 [PMID: [29777616](#) DOI: [10.1111/iej.12954](#)]
- 16 **AAE**. Clinical Considerations for a Regenerative Procedure. 2016
- 17 **Akçay M**, Arslan H, Yasa B, Kavrik F, Yasa E. Spectrophotometric analysis of crown discoloration induced by various antibiotic pastes used in revascularization. *J Endod* 2014; **40**: 845-848 [PMID: [24862714](#) DOI: [10.1016/j.joen.2013.09.019](#)]
- 18 **Thibodeau B**, Trope M. Pulp revascularization of a necrotic infected immature permanent tooth: case report and review of the literature. *Pediatr Dent* 2007; **29**: 47-50 [PMID: [18041512](#)]
- 19 **Dabbagh B**, Alvaro E, Vu DD, Rizkallah J, Schwartz S. Clinical complications in the revascularization of immature necrotic permanent teeth. *Pediatr Dent* 2012; **34**: 414-417 [PMID: [23211919](#)]
- 20 **Santos LGPD**, Chisini LA, Springmann CG, Souza BDM, Pappen FG, Demarco FF, Felipe MCS, Felipe WT. Alternative to Avoid Tooth Discoloration after Regenerative Endodontic Procedure: A Systematic Review. *Braz Dent J* 2018; **29**: 409-418 [PMID: [30517438](#) DOI: [10.1590/0103-6440201802132](#)]
- 21 **Lin J**, Zeng Q, Wei X, Zhao W, Cui M, Gu J, Lu J, Yang M, Ling J. Regenerative Endodontics Versus Apexification in Immature Permanent Teeth with Apical Periodontitis: A Prospective Randomized Controlled Study. *J Endod* 2017; **43**: 1821-1827 [PMID: [28864219](#) DOI: [10.1016/j.joen.2017.06.023](#)]



Published by **Baishideng Publishing Group Inc**
7041 Koll Center Parkway, Suite 160, Pleasanton, CA 94566, USA

Telephone: +1-925-3991568

E-mail: bpgoffice@wjgnet.com

Help Desk: <https://www.f6publishing.com/helpdesk>

<https://www.wjgnet.com>

