

# World Journal of *Clinical Cases*

*World J Clin Cases* 2022 June 26; 10(18): 5934-6340



**MINIREVIEWS**

- 5934** Development of clustered regularly interspaced short palindromic repeats/CRISPR-associated technology for potential clinical applications  
*Huang YY, Zhang XY, Zhu P, Ji L*
- 5946** Strategies and challenges in treatment of varicose veins and venous insufficiency  
*Gao RD, Qian SY, Wang HH, Liu YS, Ren SY*
- 5957** Diabetes mellitus susceptibility with varied diseased phenotypes and its comparison with phenome interactome networks  
*Rout M, Kour B, Vuree S, Lulu SS, Medicherla KM, Suravajhala P*

**ORIGINAL ARTICLE****Clinical and Translational Research**

- 5965** Identification of potential key molecules and signaling pathways for psoriasis based on weighted gene co-expression network analysis  
*Shu X, Chen XX, Kang XD, Ran M, Wang YL, Zhao ZK, Li CX*
- 5984** Construction and validation of a novel prediction system for detection of overall survival in lung cancer patients  
*Zhong C, Liang Y, Wang Q, Tan HW, Liang Y*

**Case Control Study**

- 6001** Effectiveness and postoperative rehabilitation of one-stage combined anterior-posterior surgery for severe thoracolumbar fractures with spinal cord injury  
*Zhang B, Wang JC, Jiang YZ, Song QP, An Y*

**Retrospective Study**

- 6009** Prostate sclerosing adenopathy: A clinicopathological and immunohistochemical study of twelve patients  
*Feng RL, Tao YP, Tan ZY, Fu S, Wang HF*
- 6021** Value of magnetic resonance diffusion combined with perfusion imaging techniques for diagnosing potentially malignant breast lesions  
*Zhang H, Zhang XY, Wang Y*
- 6032** Scar-centered dilation in the treatment of large keloids  
*Wu M, Gu JY, Duan R, Wei BX, Xie F*
- 6039** Application of a novel computer-assisted surgery system in percutaneous nephrolithotomy: A controlled study  
*Qin F, Sun YF, Wang XN, Li B, Zhang ZL, Zhang MX, Xie F, Liu SH, Wang ZJ, Cao YC, Jiao W*

- 6050** Influences of etiology and endoscopic appearance on the long-term outcomes of gastric antral vascular ectasia

*Kwon HJ, Lee SH, Cho JH*

#### Randomized Controlled Trial

- 6060** Evaluation of the clinical efficacy and safety of TST33 mega hemorrhoidectomy for severe prolapsed hemorrhoids

*Tao L, Wei J, Ding XF, Ji LJ*

- 6069** Sequential chemotherapy and icotinib as first-line treatment for advanced epidermal growth factor receptor-mutated non-small cell lung cancer

*Sun SJ, Han JD, Liu W, Wu ZY, Zhao X, Yan X, Jiao SC, Fang J*

#### Randomized Clinical Trial

- 6082** Impact of preoperative carbohydrate loading on gastric volume in patients with type 2 diabetes

*Lin XQ, Chen YR, Chen X, Cai YP, Lin JX, Xu DM, Zheng XC*

#### META-ANALYSIS

- 6091** Efficacy and safety of adalimumab in comparison to infliximab for Crohn's disease: A systematic review and meta-analysis

*Yang HH, Huang Y, Zhou XC, Wang RN*

#### CASE REPORT

- 6105** Successful treatment of acute relapse of chronic eosinophilic pneumonia with benralizumab and without corticosteroids: A case report

*Izhakian S, Pertzov B, Rosengarten D, Kramer MR*

- 6110** Pembrolizumab-induced Stevens-Johnson syndrome in advanced squamous cell carcinoma of the lung: A case report and review of literature

*Wu JY, Kang K, Yi J, Yang B*

- 6119** Hepatic epithelioid hemangioendothelioma after thirteen years' follow-up: A case report and review of literature

*Mo WF, Tong YL*

- 6128** Effectiveness and safety of ultrasound-guided intramuscular lauromacrogol injection combined with hysteroscopy in cervical pregnancy treatment: A case report

*Ye JP, Gao Y, Lu LW, Ye YJ*

- 6136** Carcinoma located in a right-sided sigmoid colon: A case report

*Lyu LJ, Yao WW*

- 6141** Subcutaneous infection caused by *Mycobacterium abscessus* following cosmetic injections of botulinum toxin: A case report

*Deng L, Luo YZ, Liu F, Yu XH*

- 6148** Overlapping syndrome of recurrent anti-N-methyl-D-aspartate receptor encephalitis and anti-myelin oligodendrocyte glycoprotein demyelinating diseases: A case report  
*Yin XJ, Zhang LF, Bao LH, Feng ZC, Chen JH, Li BX, Zhang J*
- 6156** Liver transplantation for late-onset ornithine transcarbamylase deficiency: A case report  
*Fu XH, Hu YH, Liao JX, Chen L, Hu ZQ, Wen JL, Chen SL*
- 6163** Disseminated strongyloidiasis in a patient with rheumatoid arthritis: A case report  
*Zheng JH, Xue LY*
- 6168** CYP27A1 mutation in a case of cerebrotendinous xanthomatosis: A case report  
*Li ZR, Zhou YL, Jin Q, Xie YY, Meng HM*
- 6175** Postoperative multiple metastasis of clear cell sarcoma-like tumor of the gastrointestinal tract in adolescent: A case report  
*Huang WP, Li LM, Gao JB*
- 6184** Toripalimab combined with targeted therapy and chemotherapy achieves pathologic complete response in gastric carcinoma: A case report  
*Liu R, Wang X, Ji Z, Deng T, Li HL, Zhang YH, Yang YC, Ge SH, Zhang L, Bai M, Ning T, Ba Y*
- 6192** Presentation of Boerhaave's syndrome as an upper-esophageal perforation associated with a right-sided pleural effusion: A case report  
*Tan N, Luo YH, Li GC, Chen YL, Tan W, Xiang YH, Ge L, Yao D, Zhang MH*
- 6198** Camrelizumab-induced anaphylactic shock in an esophageal squamous cell carcinoma patient: A case report and review of literature  
*Liu K, Bao JF, Wang T, Yang H, Xu BP*
- 6205** Nontraumatic convexal subarachnoid hemorrhage: A case report  
*Chen HL, Li B, Chen C, Fan XX, Ma WB*
- 6211** Growth hormone ameliorates hepatopulmonary syndrome and nonalcoholic steatohepatitis secondary to hypopituitarism in a child: A case report  
*Zhang XY, Yuan K, Fang YL, Wang CL*
- 6218** Vancomycin dosing in an obese patient with acute renal failure: A case report and review of literature  
*Xu KY, Li D, Hu ZJ, Zhao CC, Bai J, Du WL*
- 6227** Insulinoma after sleeve gastrectomy: A case report  
*Lobaton-Ginsberg M, Sotelo-González P, Ramirez-Renteria C, Juárez-Aguilar FG, Ferreira-Hermosillo A*
- 6234** Primary intestinal lymphangiectasia presenting as limb convulsions: A case report  
*Cao Y, Feng XH, Ni HX*
- 6241** Esophagogastric junctional neuroendocrine tumor with adenocarcinoma: A case report  
*Kong ZZ, Zhang L*

- 6247** Foreign body granuloma in the tongue differentiated from tongue cancer: A case report  
*Jiang ZH, Xu R, Xia L*
- 6254** Modified endoscopic ultrasound-guided selective N-butyl-2-cyanoacrylate injections for gastric variceal hemorrhage in left-sided portal hypertension: A case report  
*Yang J, Zeng Y, Zhang JW*
- 6261** Management of type IIb dens invaginatus using a combination of root canal treatment, intentional replantation, and surgical therapy: A case report  
*Zhang J, Li N, Li WL, Zheng XY, Li S*
- 6269** Clivus-involved immunoglobulin G4 related hypertrophic pachymeningitis mimicking meningioma: A case report  
*Yu Y, Lv L, Yin SL, Chen C, Jiang S, Zhou PZ*
- 6277** De novo brain arteriovenous malformation formation and development: A case report  
*Huang H, Wang X, Guo AN, Li W, Duan RH, Fang JH, Yin B, Li DD*
- 6283** Coinfection of *Streptococcus suis* and *Nocardia asiatica* in the human central nervous system: A case report  
*Chen YY, Xue XH*
- 6289** Dilated left ventricle with multiple outpouchings – a severe congenital ventricular diverticulum or left-dominant arrhythmogenic cardiomyopathy: A case report  
*Zhang X, Ye RY, Chen XP*
- 6298** Spontaneous healing of complicated crown-root fractures in children: Two case reports  
*Zhou ZL, Gao L, Sun SK, Li HS, Zhang CD, Kou WW, Xu Z, Wu LA*
- 6307** Thyroid follicular renal cell carcinoma excluding thyroid metastases: A case report  
*Wu SC, Li XY, Liao BJ, Xie K, Chen WM*
- 6314** Appendiceal bleeding: A case report  
*Zhou SY, Guo MD, Ye XH*
- 6319** Spontaneous healing after conservative treatment of isolated grade IV pancreatic duct disruption caused by trauma: A case report  
*Mei MZ, Ren YF, Mou YP, Wang YY, Jin WW, Lu C, Zhu QC*
- 6325** Pneumonia and seizures due to hypereosinophilic syndrome – organ damage and eosinophilia without synchronisation: A case report  
*Ishida T, Murayama T, Kobayashi S*
- 6333** Creutzfeldt-Jakob disease presenting with bilateral hearing loss: A case report  
*Na S, Lee SA, Lee JD, Lee ES, Lee TK*

**LETTER TO THE EDITOR**

- 6338** Stem cells as an option for the treatment of COVID-19  
*Cuevas-González MV, Cuevas-González JC*

**ABOUT COVER**

Editorial Board Member of *World Journal of Clinical Cases*, Cristina Tudoran, PhD, Assistant Professor, Department VII, Internal Medicine II, Discipline of Cardiology, "Victor Babes" University of Medicine and Pharmacy Timisoara, Timisoara 300041, Timis, Romania. cristina13.tudoran@gmail.com

**AIMS AND SCOPE**

The primary aim of *World Journal of Clinical Cases* (WJCC, *World J Clin Cases*) is to provide scholars and readers from various fields of clinical medicine with a platform to publish high-quality clinical research articles and communicate their research findings online.

WJCC mainly publishes articles reporting research results and findings obtained in the field of clinical medicine and covering a wide range of topics, including case control studies, retrospective cohort studies, retrospective studies, clinical trials studies, observational studies, prospective studies, randomized controlled trials, randomized clinical trials, systematic reviews, meta-analysis, and case reports.

**INDEXING/ABSTRACTING**

The WJCC is now indexed in Science Citation Index Expanded (also known as SciSearch®), Journal Citation Reports/Science Edition, Scopus, PubMed, and PubMed Central. The 2021 Edition of Journal Citation Reports® cites the 2020 impact factor (IF) for WJCC as 1.337; IF without journal self cites: 1.301; 5-year IF: 1.742; Journal Citation Indicator: 0.33; Ranking: 119 among 169 journals in medicine, general and internal; and Quartile category: Q3. The WJCC's CiteScore for 2020 is 0.8 and Scopus CiteScore rank 2020: General Medicine is 493/793.

**RESPONSIBLE EDITORS FOR THIS ISSUE**

Production Editor: *Ying-Yi Yuan*, Production Department Director: *Xu Guo*, Editorial Office Director: *Jin-Lei Wang*.

**NAME OF JOURNAL**

*World Journal of Clinical Cases*

**ISSN**

ISSN 2307-8960 (online)

**LAUNCH DATE**

April 16, 2013

**FREQUENCY**

Thrice Monthly

**EDITORS-IN-CHIEF**

Bao-Gan Peng, Jerzy Tadeusz Chudek, George Kontogeorgos, Maurizio Serati, Ja Hyeon Ku

**EDITORIAL BOARD MEMBERS**

<https://www.wjgnet.com/2307-8960/editorialboard.htm>

**PUBLICATION DATE**

June 26, 2022

**COPYRIGHT**

© 2022 Baishideng Publishing Group Inc

**INSTRUCTIONS TO AUTHORS**

<https://www.wjgnet.com/bpg/gerinfo/204>

**GUIDELINES FOR ETHICS DOCUMENTS**

<https://www.wjgnet.com/bpg/GerInfo/287>

**GUIDELINES FOR NON-NATIVE SPEAKERS OF ENGLISH**

<https://www.wjgnet.com/bpg/gerinfo/240>

**PUBLICATION ETHICS**

<https://www.wjgnet.com/bpg/GerInfo/288>

**PUBLICATION MISCONDUCT**

<https://www.wjgnet.com/bpg/gerinfo/208>

**ARTICLE PROCESSING CHARGE**

<https://www.wjgnet.com/bpg/gerinfo/242>

**STEPS FOR SUBMITTING MANUSCRIPTS**

<https://www.wjgnet.com/bpg/GerInfo/239>

**ONLINE SUBMISSION**

<https://www.f6publishing.com>



## Liver transplantation for late-onset ornithine transcarbamylase deficiency: A case report

Xiao-Hui Fu, Yu-Hui Hu, Jian-Xiang Liao, Li Chen, Zhan-Qi Hu, Jia-Lun Wen, Shu-Li Chen

**Specialty type:** Genetics and heredity

**Provenance and peer review:**

Unsolicited article; Externally peer reviewed.

**Peer-review model:** Single blind

**Peer-review report's scientific quality classification**

Grade A (Excellent): 0

Grade B (Very good): 0

Grade C (Good): C, C

Grade D (Fair): D

Grade E (Poor): 0

**P-Reviewer:** Enosawa S, Japan; Topal U, Turkey

**Received:** October 28, 2021

**Peer-review started:** October 28, 2021

**First decision:** December 27, 2021

**Revised:** January 10, 2022

**Accepted:** April 22, 2022

**Article in press:** April 22, 2022

**Published online:** June 26, 2022



**Xiao-Hui Fu, Yu-Hui Hu, Shu-Li Chen**, Department of Inherited Metabolic Disorders, The Affiliated Hospital of China Medical University and Shenzhen Children's Hospital, Shenzhen 518038, Guangdong Province, China

**Jian-Xiang Liao, Li Chen, Zhan-Qi Hu, Jia-Lun Wen**, Department of Neurology, The Affiliated Hospital of China Medical University and Shenzhen Children's Hospital, Shenzhen 518038, Guangdong Province, China

**Corresponding author:** Shu-Li Chen, PhD, Chief Doctor, Department of Inherited Metabolic Disorders, The Affiliated Hospital of China Medical University and Shenzhen Children's Hospital, No. 7019 Yitian Road, Futian District, Shenzhen 518038, Guangdong Province, China. [13008803656@163.com](mailto:13008803656@163.com)

### Abstract

#### BACKGROUND

Ornithine transcarbamylase deficiency (OTCD) is an X-linked inherited disorder and characterized by marked elevation of blood ammonia. The goal of treatment is to minimize the neurological damage caused by hyperammonemia. OTCD can be cured by liver transplantation (LT). Post-transplant patients can discontinue anti-hyperammonemia agents and consume a regular diet without the risk of developing hyperammonemia. The neurological damage caused by hyperammonemia is almost irreversible.

#### CASE SUMMARY

An 11.7-year-old boy presented with headache, vomiting, and altered consciousness. The patient was diagnosed with late-onset OTCD. After nitrogen scavenging treatment and a protein-free diet, ammonia levels were reduced to normal on the third day of admission. Nevertheless, the patient remained in a moderate coma. After discussion, LT was performed. Following LT, the patient's blood ammonia and biochemical indicators stabilized in the normal range, he regained consciousness, and his nervous system function significantly recovered. Two months after LT, blood amino acids and urine organic acids were normal, and brain magnetic resonance imaging showed a decrease in subcortical lesions.

#### CONCLUSION

LT can significantly improve partial neurological impairment caused by late-onset OTCD hyperammonemic encephalopathy, and LT can be actively considered when early drug therapy is ineffective.

**Key Words:** Ornithine transcarbamylase deficiency; Urea cycle disorder; Hyperammonemic encephalopathy; Liver transplantation; Case report

©The Author(s) 2022. Published by Baishideng Publishing Group Inc. All rights reserved.

**Core Tip:** There are differing views on the timing of liver transplantation (LT) for ornithine transcarbamylase deficiency (OTCD) and whether it makes sense to perform LT in a patient with severe neurological impairment. We report a case of late-onset OTCD with severe neurological impairment, whose nervous system function recovered after LT. In late-onset OTCD patients with severe neurological impairment, LT can be considered.

**Citation:** Fu XH, Hu YH, Liao JX, Chen L, Hu ZQ, Wen JL, Chen SL. Liver transplantation for late-onset ornithine transcarbamylase deficiency: A case report. *World J Clin Cases* 2022; 10(18): 6156-6162

**URL:** <https://www.wjgnet.com/2307-8960/full/v10/i18/6156.htm>

**DOI:** <https://dx.doi.org/10.12998/wjcc.v10.i18.6156>

## INTRODUCTION

Ornithine transcarbamylase deficiency (OTCD) is the most common urea cycle disorder, with an incidence of approximately 1/56500 to 1/80000 reported in the literature[1-4]. The 2019 Urea Cycle Disorders Diagnosis and Management guidelines recommend liver transplantation (LT) for patients with severe urea cycle disorders who do not have severe neurological impairment and have stable metabolic status[5]. Opinions regarding LT for children with pre-existing severe brain damage differ as LT does not restore pre-existing neurological damage and due to the high risk of LT in children with acute encephalopathy; there is no experience regarding the extent to which neurological damage can be restored after surgery[5]. We report a patient with late-onset OTCD with good neurological recovery after LT.

## CASE PRESENTATION

### Chief complaints

An 11.7-year-old boy was admitted to our hospital due to headache, vomiting and altered mental status.

### History of present illness

Two days before admission, the patient complained of a headache without obvious inducement, accompanied by vomiting 25 times. The headache did not improve with cold medication. He became unconscious 12 h before admission, and relevant tests were completed at a referring hospital. His blood ammonia was > 500  $\mu\text{mol/L}$ . He was referred to our hospital for further treatment.

### History of past illness

The patient was the product of a first pregnancy and first birth (G1P1) mother, and delivered by cesarean section at term with a birth weight of 3.0 kg. His perinatal condition was unremarkable, with no history of asphyxia. He was generally healthy and developed normally for a child of the same age. Prior to this episode, the family was not aware that the patient had OTCD.

### Personal and family history

The patient had no significant family history. No patients in the family had OTCD or symptoms associated with the disease.

### Physical examination

On physical examination, he was in a moderate comatose state [Glasgow coma score (GSC) 6] and was unresponsive to sound. His eyes could not be closed, the pupils were equally large and round, about 3 mm in diameter, and light reflex was delayed. There were no significant abnormalities on cardiopulmonary or abdominal examinations. Muscle strength in the limbs could not be tested, muscle tone was normal, and all pathological signs were negative.

### Laboratory examinations

Laboratory tests showed a significantly elevated blood ammonia level (Table 1). Liver function and coagulation times were abnormal. Blood tandem mass spectrometry showed moderately elevated glutamine. Citrulline and arginine were in the normal range. Urine organic acid gas phase mass spectrometry showed that uracil and orotic acid levels were elevated. Blood ammonia levels during the first week of admission are shown in Figure 1. During the remainder rest of his hospital stay, levels were in the normal range.

Whole exome gene testing revealed the *OTC* gene exon2 hemizygote variant c.119G > A (p.R40H), inherited from his mother. The missense mutation was located in the well-studied exon functional domain without benign variation [Pathogenic moderate (PM) 1]. The frequencies of all normal population databases (dsSNP, 1000 genomes) were less than 0.0005 (PM2). This is a variant with different amino acid changes at the same locus reported in the literature as pathogenic variants (PM5). Pathogenic missense mutations of this gene are common, and benign missense mutations are rare [Pathogenic supporting (PP) 2]. The literature reported that variant to caused impaired gene function as show by *in vitro* functional assays [Pathogenic strong (PS) 3]. In summary, according to American College of Medical Genetics (ACMG) guidelines, this variant is likely pathogenic (PM1 + PM2 + PM5 + PP2 + PS3).

### Imaging examinations

Brain magnetic resonance imaging (MRI) revealed that large patches of symmetrical high signal shadows on T2 weighted imaging (T2WI) and fluid attenuated inversion recovery in the cerebral hemispheres, and diffusion WI (DWI) revealed a significant high signal, more pronounced in the bilateral dorsal thalamus, caudate nucleus, lenticular nucleus, insula, cingulate gyrus and frontal lobe into the cortex at the falx.

## FINAL DIAGNOSIS

Hyperammonemic encephalopathy and ornithine transcarbamylase deficiency.

## TREATMENT

After admission, the patient underwent continuous hemodiafiltration (Disposable hemodialysate filter and supporting pipeline, Prismaflex M100 set, Gambro Industries, Meyzieu, France; blood flow velocity 150-300 mL/min, replacement velocity 1000-2500 mL/h, dialysis velocity 1500-5000 mL/h) to lower the blood ammonia level. The impairment of consciousness worsened, and the repeat blood ammonia level was 511.72  $\mu\text{mol/L}$ . Within a few hours, he fell into a severe coma (GSC 3) and developed central respiratory failure. We immediately provided ventilation, reduced intracranial pressure (mannitol and hypertonic sodium), nitrogen scavenger agents including sodium benzoate and arginine, antibiotics to inhibit ammonia production by intestinal bacteria, along with multiple nutritional support treatments.

On day 3, blood ammonia decreased to normal and was maintained in the normal range for the remainder of the hospital stay. The continuous hemodiafiltration parameters (blood flow velocity 120 mL/min, replacement velocity 500 mL/h, dialysis velocity 2500 mL/h) were gradually adjusted downwards. On day 6, the patient discontinued hemodiafiltration. On day 7, the patient's consciousness changed from deep coma to moderate coma. On day 12, the patient was weaned from the ventilator; however, he remained in a moderate coma.

On day 31, modified piggyback orthotopic LT (anastomosis of the donor inferior vena cava to the recipient inferior vena cava) was performed, the donor was deceased. Postoperatively, the patient was treated with tacrolimus, sodium mescaline, and methylprednisolone. On day 35 (day 4 after surgery), the patient was conscious (opened eyes autonomously, obeyed commands, verbal response was "T"). A repeat brain MRI more than 2 mo after transplantation showed that the previous subcortical lesions had largely disappeared; however, hydrocephalus was worse (Figure 2). He was discharged after 3 mo and underwent abdominal ventricular drainage at another hospital.

## OUTCOME AND FOLLOW-UP

At follow-up, 6 mo after surgery, he could sit, squat, and walk smoothly on his own. He could say simple superlatives, and his command execution rate was approximately 30%. He showed poor emotional control and a greater temper to his parents; however, he was gentler to strangers and his brother.

Table 1 Laboratory data

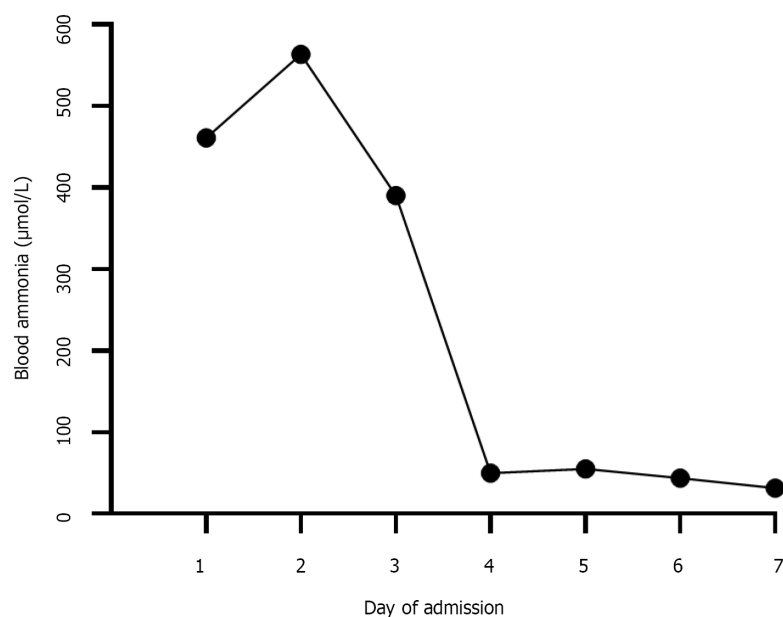
Parameter	On admission	After LT	Reference range
Blood ammonia, $\mu\text{mol/L}$	461.2 $\uparrow$	51.2	14-65
Blood lactic acid, $\text{mmol/L}$	4.47 $\uparrow$	0.78	0.5-2.2
APTT, s	37.3	24.1	26.1-40.7
PT, s	23.1 $\uparrow$	12.6	9.3-12.9
INR	2.030 $\uparrow$	1.10	0.72-1.15
Fibrinogen, g/L	1.88	2.36	1.57-3.93
ALT, U/L	73 $\uparrow$	44 $\uparrow$	0-40
AST, U/L	50 $\uparrow$	31	0-40
ALP, U/L	564 $\uparrow$	126	40-500
GGT, U/L	15	107 $\uparrow$	0-50
TBIL, $\mu\text{mol/L}$	30.8 $\uparrow$	4.0	0.9-17.1
IBIL, $\mu\text{mol/L}$	25.6 $\uparrow$	1.8	2-17
Albumin, g/L	45.5	41.9	35-55
Serum creatinine, $\mu\text{mol/L}$	63.5	42.3	64-104
Serum uric acid, $\mu\text{mol/L}$	442.90 $\uparrow$	365.6	90-420
Ceruloplasmin	24.4	absent	22-322
Blood amino acids			
Glutamine, $\mu\text{mol/L}$	66.28 $\uparrow$	15.83	1.0-55.0
Citrulline, $\mu\text{mol/L}$	14.7	14.19	5.50-45.00
Arginine, $\mu\text{mol/L}$	13.57	5.38	1.00-70.00
Urine organic acid			
Uracil, $\text{mmol/molCr}$	29.4 $\uparrow$	0.0	0.0-8.0
Urinary orotic acid, $\text{mmol/molCr}$	123.3 $\uparrow$	0.0	0.0-2.0

$\uparrow$ : Higher than the reference value; LT: Liver transplantation; APTT: Activated partial thromboplastin time; PT: Prothrombin time; INR: International normalized ratio; ALT: Alanine aminotransaminase; AST: Aspartate aminotransferase; ALP: Alkaline phosphatase; GGT:  $\gamma$ -glutamyl transpeptidase; TBIL: Total bilirubin; IBIL: Indirect bilirubin.

## DISCUSSION

OTCD can develop at any age. Depending on the time of onset, OTCD can be divided into the neonatal-onset type and the late-onset type (age of onset  $> 28$  d)[6]. Patients with neonatal onset usually present in the first few hours and days after birth with severe disease and high mortality. The clinical presentation of late-onset disease varies widely, with no specific clinical manifestations before initial onset. Acute onset of late-onset OTCD can be induced by infection, prolonged fasting, or fatigue. The outcome for conservative treatment is poor in patients with hyperammonemia crisis, and 5-year survival is approximately 45%[7].

Outcomes in urea cycle disorders are related to blood ammonia levels and the duration of the coma. According to a European questionnaire, patients with blood ammonia levels  $> 300$   $\mu\text{mol/L}$  or peak blood ammonia levels  $> 480$   $\mu\text{mol/L}$  during the first episode suffered neurological dysfunction[8]. Although patients with late-onset OTCD generally have better outcomes than those with neonatal onset, there is a higher incidence of residual neurological damage, and the mortality rate for late-onset OTCD with coma on the first episode is high. In a follow-up study that included 90 OTCD cases, 18 patients had coma as their first presentation and 6 of them died[9]. Among 16 genetically confirmed cases of late-onset OTCD reported in the Chinese literature[10], nine died shortly after hospital admission, suggesting the disease's aggressive nature at acute onset. In our case, the patient was physically fit and had normal development before the presentation. Headache and vomiting were the primary manifestations; these symptoms were not taken seriously until the onset of unconsciousness, which delayed the treatment. Although blood ammonia levels reduced to the normal range after aggressive treatment, neurological damage did not improve with the normalization of blood ammonia. The patient was in a



DOI: 10.12998/wjcc.v10.i18.6156 Copyright ©The Author(s) 2022.

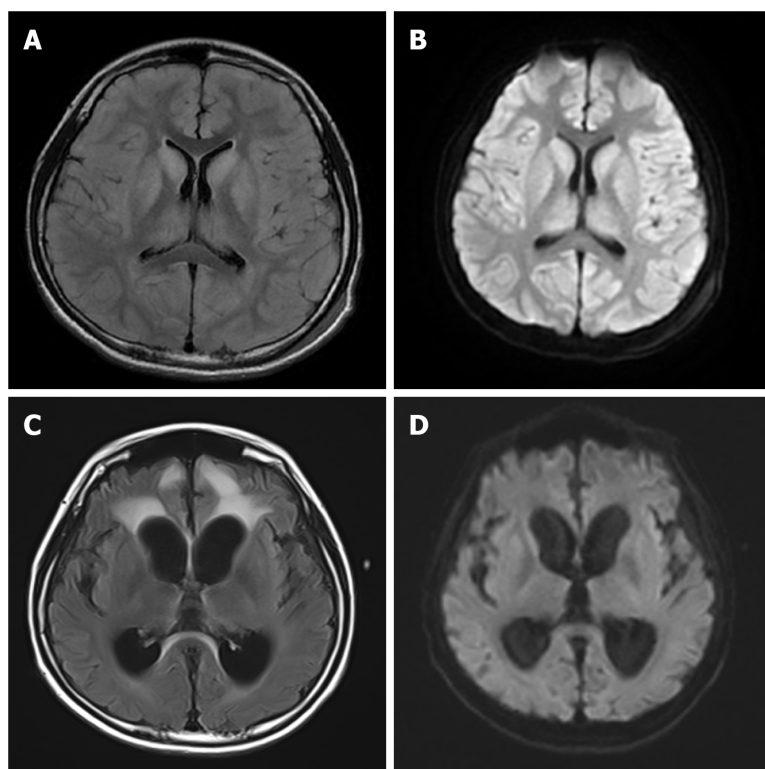
Figure 1 Blood ammonia changes during the first week of admission.

moderate coma before LT.

OTCD is treated with a low-protein diet and long-term oral ammonia-lowering medications. LT is the radical treatment for OTCD. After LT, patients no longer need to restrict their diet or take nitrogen scavenging agents[5]. Statistics on LT in patients with urea circulation disorders show that the 5-year survival rate of patients after LT can exceed 90% [11,12]. There is no consensus regarding the indications or timing of LT. It is now believed that LT should be performed in all patients with neonatal onset to prevent neurological damage[13]. The indications and timing of LT for late-onset OTCD must be determined by the clinical symptoms, including poor drug efficacy, recurrent episodes of hyperammonemia, growth retardation, and inability to strictly control the diet[14]. Although post-transplant patients require long-term immunosuppressive drugs, there is evidence that OTCD patients who underwent LT have a better quality of life than those who did not and no longer risked death due to sudden-onset hyperammonemia[11,15].

The present patient had an acute onset, a long duration of hyperammonemia, severe brain damage, and was in a moderate coma before LT. Therefore, the optimal time window for LT was missed, and the choice of LT and the extent to which the patient would recover from neurological damage after transplantation were a concern for his physicians and parents. Most LTs for OTCD patients are carried out in the context of stable metabolism, and there are few reports of LT in patients with severe neurological injury. Nevertheless, given the patient's inability to regain consciousness, we performed LT, and he was conscious 4 d later. After LT, he did not take nitrogen scavenging agents, and blood ammonia, liver, and kidney function biochemistry were maintained in the normal range at regular follow-up. Kawagishi *et al* [16] reported a patient who underwent LT for recurrent hyperammonemia due to late-onset OTCD, and blood ammonia was maintained in the normal range without further nitrogen scavenging agents after surgery. Nevertheless, at 16 mo after surgery showed no change in subcortical lesions. Brain MRI in our patient was repeated about 2 mo after surgery, and suggested a significant reduction in abnormal cranial signals compared with the previous MRI, indicating that LT was effective in the treatment of this patient. However, brain MRI showed that hydrocephalus had progressed and brain atrophy was present, suggesting that some neurological damage may not be reversed after LT.

Several studies have shown that LT could be used as a radical treatment which significantly improves the quality of life[11,17]. However, it is not clear whether LT is beneficial for OTCD patients who already have severe neurological damage. This case report suggests that LT can be attempted in children with late-onset OTCD, even if severe neurological impairment is already present. Neurological recovery after LT in this patient was unexpected; the recovery of higher functions such as emotional control and spatial thinking require long-term rehabilitation training and psychotherapy, and its effects need to be observed during follow-up.



DOI: 10.12998/wjcc.v10.i18.6156 Copyright ©The Author(s) 2022.

**Figure 2 Brain magnetic resonance imaging.** A: On admission, brain magnetic resonance imaging (MRI), T2 fluid attenuated inversion recovery (FLAIR) imaging showed a large symmetrical high signal, more pronounced in the bilateral dorsal thalamus, caudate nucleus, lenticular nucleus, insula, cingulate gyrus and frontal lobe into the cortex at the falx; B: On admission, a high signal was observed on diffusion weighted imaging (DWI) of bilateral dorsal thalamus, caudate nucleus, lenticular nucleus, insula, frontal lobe into the cortex at the falx; C: Two months after liver transplantation (LT), brain MRI, T2 FLAIR imaging showed that the cerebral sulcus fissure was widened and deepened bilaterally in the cerebral hemispheres, and the cortex was atrophied, with a patchy high signal in the frontal lobes bilaterally; D: Two months after LT, brain MRI, DWI did not show any significant abnormal signal, and the abnormal signal in the original bilateral cerebral hemispheric cortex, dorsal thalamus, basal ganglia area, insula, cingulate gyrus, and frontal and temporal lobes was no longer obvious.

## CONCLUSION

In summary, patients with late-onset OTCD and acute hyperammonemic encephalopathy are at high risk, and LT can significantly improve the neurological damage caused by this disease. As a radical cure for OTCD, LT should be considered more aggressively.

## FOOTNOTES

**Author contributions:** Hu YH, Liao JX, Chen L, Hu ZQ and Wen JL were responsible for the treatment and management of the patient; Fu XH and Chen SL collected the patient's clinical data and wrote the paper; all authors were involved in writing the manuscript and read and approved the final manuscript.

**Supported by** the Sanming Project of Medicine in Shenzhen, No. SZSM201812005.

**Informed consent statement:** Informed written consent was obtained from the patient for the publication of this report and any accompanying images.

**Conflict-of-interest statement:** The authors declare that they have no conflict of interest.

**CARE Checklist (2016) statement:** The authors have read the CARE Checklist (2016), and the manuscript was prepared and revised according to the CARE Checklist (2016).

**Open-Access:** This article is an open-access article that was selected by an in-house editor and fully peer-reviewed by external reviewers. It is distributed in accordance with the Creative Commons Attribution NonCommercial (CC BY-NC 4.0) license, which permits others to distribute, remix, adapt, build upon this work non-commercially, and license their derivative works on different terms, provided the original work is properly cited and the use is non-commercial. See: <https://creativecommons.org/licenses/by-nc/4.0/>

**Country/Territory of origin:** China

**ORCID number:** Xiao-Hui Fu 0000-0002-9000-224X; Yu-Hui Hu 0000-0002-6989-2460; Jian-Xiang Liao 0000-0001-9769-3365; Li Chen 0000-0002-9029-9581; Zhan-Qi Hu 0000-0001-5926-3962; Jia-Lun Wen 0000-0002-1399-5890; Shu-Li Chen 0000-0001-9989-6414.

**S-Editor:** Guo XR

**L-Editor:** Webster JR

**P-Editor:** Guo XR

## REFERENCES

- 1 **Wilcken B.** Problems in the management of urea cycle disorders. *Mol Genet Metab* 2004; **81** Suppl 1: S86-S91 [PMID: 15050980 DOI: 10.1016/j.ymgme.2003.10.016]
- 2 **Summar ML,** Koelker S, Freedenberg D, Le Mons C, Haberle J, Lee HS, Kirmse B, European registry and network for intoxication type metabolic diseases (E-IMD). The incidence of urea cycle disorders. *Mol Genet Metab* 2013; **110**: 179-180 [PMID: 23972786 DOI: 10.1016/j.ymgme.2013.07.008]
- 3 **Dionisi-Vici C,** Rizzo C, Burlina AB, Caruso U, Sabetta G, Uziel G, Abeni D. Inborn errors of metabolism in the Italian pediatric population: a national retrospective survey. *J Pediatr* 2002; **140**: 321-327 [PMID: 11953730 DOI: 10.1067/mpd.2002.122394]
- 4 **Kido J,** Nakamura K, Mitsubuchi H, Ohura T, Takayanagi M, Matsuo M, Yoshino M, Shigematsu Y, Yorifuji T, Kasahara M, Horikawa R, Endo F. Long-term outcome and intervention of urea cycle disorders in Japan. *J Inherit Metab Dis* 2012; **35**: 777-785 [PMID: 22167275 DOI: 10.1007/s10545-011-9427-0]
- 5 **Häberle J,** Burlina A, Chakrapani A, Dixon M, Karall D, Lindner M, Mandel H, Martinelli D, Pintos-Morell G, Santer R, Skouma A, Servais A, Tal G, Rubio V, Huemer M, Dionisi-Vici C. Suggested guidelines for the diagnosis and management of urea cycle disorders: First revision. *J Inherit Metab Dis* 2019; **42**: 1192-1230 [PMID: 30982989 DOI: 10.1002/jimd.12100]
- 6 **Division of genetics and metabolism,** Child diseases and health care branch, Chinese association for maternal and child health. Consensus on diagnosis and treatment of ornithine trans-carbamylase deficiency. *Zhejiang Daxue Xuebao Yixueban* 2020; **49**: 539-547 [PMID: 33210478 DOI: 10.3785/j.issn.1008-9292.2020.04.11]
- 7 **Wakiya T,** Sanada Y, Mizuta K, Umehara M, Urahasi T, Egami S, Hishikawa S, Fujiwara T, Sakuma Y, Hyodo M, Murayama K, Hakamada K, Yasuda Y, Kawarasaki H. Living donor liver transplantation for ornithine transcarbamylase deficiency. *Pediatr Transplant* 2011; **15**: 390-395 [PMID: 21585627 DOI: 10.1111/j.1399-3046.2011.01494.x]
- 8 **Enns GM.** Neurologic damage and neurocognitive dysfunction in urea cycle disorders. *Semin Pediatr Neurol* 2008; **15**: 132-139 [PMID: 18708004 DOI: 10.1016/j.spen.2008.05.007]
- 9 **Brassier A,** Gobin S, Arnoux JB, Valayannopoulos V, Habarou F, Kossorotoff M, Servais A, Barbier V, Dubois S, Touati G, Barouki R, Lesage F, Dupic L, Bonnefont JP, Ottolenghi C, De Lonlay P. Long-term outcomes in Ornithine Transcarbamylase deficiency: a series of 90 patients. *Orphanet J Rare Dis* 2015; **10**: 58 [PMID: 25958381 DOI: 10.1186/s13023-015-0266-1]
- 10 **Sun Y,** Li XM, Zhang TX, Li DL, Ji KQ, Yan CZ, Zhao YY. Clinical research of two cases of late-onset ornithine carbamoyltransferase deficiency. *Zhonghua Shenjingke Zazhi* 2019; **52**: 399-405 [DOI: 10.3760/ema.j.issn.1006-7876.2019.05.007]
- 11 **Morioka D,** Kasahara M, Takada Y, Shirouzu Y, Taira K, Sakamoto S, Uryuhara K, Egawa H, Shimada H, Tanaka K. Current role of liver transplantation for the treatment of urea cycle disorders: a review of the worldwide English literature and 13 cases at Kyoto University. *Liver Transpl* 2005; **11**: 1332-1342 [PMID: 16237708 DOI: 10.1002/Lt.20587]
- 12 **Molema F,** Martinelli D, Hörster F, Kölker S, Tangeraas T, de Koning B, Dionisi-Vici C, Williams M; additional individual contributors of MetabERN. Liver and/or kidney transplantation in amino and organic acid-related inborn errors of metabolism: An overview on European data. *J Inherit Metab Dis* 2021; **44**: 593-605 [PMID: 32996606 DOI: 10.1002/jimd.12318]
- 13 **Kido J,** Matsumoto S, Mitsubuchi H, Endo F, Nakamura K. Early liver transplantation in neonatal-onset and moderate urea cycle disorders may lead to normal neurodevelopment. *Metab Brain Dis* 2018; **33**: 1517-1523 [PMID: 29948653 DOI: 10.1007/s11011-018-0259-6]
- 14 **Wakiya T,** Sanada Y, Urahashi T, Ihara Y, Yamada N, Okada N, Ushijima K, Otomo S, Sakamoto K, Murayama K, Takayanagi M, Hakamada K, Yasuda Y, Mizuta K. Impact of enzyme activity assay on indication in liver transplantation for ornithine transcarbamylase deficiency. *Mol Genet Metab* 2012; **105**: 404-407 [PMID: 22264779 DOI: 10.1016/j.ymgme.2011.12.019]
- 15 **Foschi FG,** Morelli MC, Savini S, Dall'Aglio AC, Lanzi A, Cescon M, Ercolani G, Cucchetti A, Pinna AD, Stefanini GF. Urea cycle disorders: a case report of a successful treatment with liver transplant and a literature review. *World J Gastroenterol* 2015; **21**: 4063-4068 [PMID: 25852294 DOI: 10.3748/wjg.v21.i13.4063]
- 16 **Kawagishi N,** Satoh K, Enomoto Y, Akamatsu Y, Sekiguchi S, Satoh A, Fujimori K, Takasago Y, Ito T, Ohura T, Satomi S. Improved quality of life and unchanged magnetic resonance brain imaging after living donor liver transplantation for late-onset ornithine transcarbamylase deficiency: report of a case. *Surg Today* 2005; **35**: 1087-1091 [PMID: 16341494 DOI: 10.1007/s00595-005-3071-y]
- 17 **Kasahara M,** Sakamoto S, Horikawa R, Koji U, Mizuta K, Shinkai M, Takahito Y, Taguchi T, Inomata Y, Uemoto S, Tatsuo K, Kato S. Living donor liver transplantation for pediatric patients with metabolic disorders: the Japanese multicenter registry. *Pediatr Transplant* 2014; **18**: 6-15 [PMID: 24283623 DOI: 10.1111/ptr.12196]



Published by **Baishideng Publishing Group Inc**  
7041 Koll Center Parkway, Suite 160, Pleasanton, CA 94566, USA

**Telephone:** +1-925-3991568

**E-mail:** [bpgoffice@wjgnet.com](mailto:bpgoffice@wjgnet.com)

**Help Desk:** <https://www.f6publishing.com/helpdesk>

<https://www.wjgnet.com>

