

World Journal of *Clinical Cases*

World J Clin Cases 2022 June 26; 10(18): 5934-6340



MINIREVIEWS

- 5934** Development of clustered regularly interspaced short palindromic repeats/CRISPR-associated technology for potential clinical applications
Huang YY, Zhang XY, Zhu P, Ji L
- 5946** Strategies and challenges in treatment of varicose veins and venous insufficiency
Gao RD, Qian SY, Wang HH, Liu YS, Ren SY
- 5957** Diabetes mellitus susceptibility with varied diseased phenotypes and its comparison with phenome interactome networks
Rout M, Kour B, Vuree S, Lulu SS, Medicherla KM, Suravajhala P

ORIGINAL ARTICLE

Clinical and Translational Research

- 5965** Identification of potential key molecules and signaling pathways for psoriasis based on weighted gene co-expression network analysis
Shu X, Chen XX, Kang XD, Ran M, Wang YL, Zhao ZK, Li CX
- 5984** Construction and validation of a novel prediction system for detection of overall survival in lung cancer patients
Zhong C, Liang Y, Wang Q, Tan HW, Liang Y

Case Control Study

- 6001** Effectiveness and postoperative rehabilitation of one-stage combined anterior-posterior surgery for severe thoracolumbar fractures with spinal cord injury
Zhang B, Wang JC, Jiang YZ, Song QP, An Y

Retrospective Study

- 6009** Prostate sclerosing adenopathy: A clinicopathological and immunohistochemical study of twelve patients
Feng RL, Tao YP, Tan ZY, Fu S, Wang HF
- 6021** Value of magnetic resonance diffusion combined with perfusion imaging techniques for diagnosing potentially malignant breast lesions
Zhang H, Zhang XY, Wang Y
- 6032** Scar-centered dilation in the treatment of large keloids
Wu M, Gu JY, Duan R, Wei BX, Xie F
- 6039** Application of a novel computer-assisted surgery system in percutaneous nephrolithotomy: A controlled study
Qin F, Sun YF, Wang XN, Li B, Zhang ZL, Zhang MX, Xie F, Liu SH, Wang ZJ, Cao YC, Jiao W

- 6050** Influences of etiology and endoscopic appearance on the long-term outcomes of gastric antral vascular ectasia

Kwon HJ, Lee SH, Cho JH

Randomized Controlled Trial

- 6060** Evaluation of the clinical efficacy and safety of TST33 mega hemorrhoidectomy for severe prolapsed hemorrhoids

Tao L, Wei J, Ding XF, Ji LJ

- 6069** Sequential chemotherapy and icotinib as first-line treatment for advanced epidermal growth factor receptor-mutated non-small cell lung cancer

Sun SJ, Han JD, Liu W, Wu ZY, Zhao X, Yan X, Jiao SC, Fang J

Randomized Clinical Trial

- 6082** Impact of preoperative carbohydrate loading on gastric volume in patients with type 2 diabetes

Lin XQ, Chen YR, Chen X, Cai YP, Lin JX, Xu DM, Zheng XC

META-ANALYSIS

- 6091** Efficacy and safety of adalimumab in comparison to infliximab for Crohn's disease: A systematic review and meta-analysis

Yang HH, Huang Y, Zhou XC, Wang RN

CASE REPORT

- 6105** Successful treatment of acute relapse of chronic eosinophilic pneumonia with benralizumab and without corticosteroids: A case report

Izhakian S, Pertzov B, Rosengarten D, Kramer MR

- 6110** Pembrolizumab-induced Stevens-Johnson syndrome in advanced squamous cell carcinoma of the lung: A case report and review of literature

Wu JY, Kang K, Yi J, Yang B

- 6119** Hepatic epithelioid hemangioendothelioma after thirteen years' follow-up: A case report and review of literature

Mo WF, Tong YL

- 6128** Effectiveness and safety of ultrasound-guided intramuscular lauromacrogol injection combined with hysteroscopy in cervical pregnancy treatment: A case report

Ye JP, Gao Y, Lu LW, Ye YJ

- 6136** Carcinoma located in a right-sided sigmoid colon: A case report

Lyu LJ, Yao WW

- 6141** Subcutaneous infection caused by *Mycobacterium abscessus* following cosmetic injections of botulinum toxin: A case report

Deng L, Luo YZ, Liu F, Yu XH

- 6148** Overlapping syndrome of recurrent anti-N-methyl-D-aspartate receptor encephalitis and anti-myelin oligodendrocyte glycoprotein demyelinating diseases: A case report
Yin XJ, Zhang LF, Bao LH, Feng ZC, Chen JH, Li BX, Zhang J
- 6156** Liver transplantation for late-onset ornithine transcarbamylase deficiency: A case report
Fu XH, Hu YH, Liao JX, Chen L, Hu ZQ, Wen JL, Chen SL
- 6163** Disseminated strongyloidiasis in a patient with rheumatoid arthritis: A case report
Zheng JH, Xue LY
- 6168** CYP27A1 mutation in a case of cerebrotendinous xanthomatosis: A case report
Li ZR, Zhou YL, Jin Q, Xie YY, Meng HM
- 6175** Postoperative multiple metastasis of clear cell sarcoma-like tumor of the gastrointestinal tract in adolescent: A case report
Huang WP, Li LM, Gao JB
- 6184** Toripalimab combined with targeted therapy and chemotherapy achieves pathologic complete response in gastric carcinoma: A case report
Liu R, Wang X, Ji Z, Deng T, Li HL, Zhang YH, Yang YC, Ge SH, Zhang L, Bai M, Ning T, Ba Y
- 6192** Presentation of Boerhaave's syndrome as an upper-esophageal perforation associated with a right-sided pleural effusion: A case report
Tan N, Luo YH, Li GC, Chen YL, Tan W, Xiang YH, Ge L, Yao D, Zhang MH
- 6198** Camrelizumab-induced anaphylactic shock in an esophageal squamous cell carcinoma patient: A case report and review of literature
Liu K, Bao JF, Wang T, Yang H, Xu BP
- 6205** Nontraumatic convexal subarachnoid hemorrhage: A case report
Chen HL, Li B, Chen C, Fan XX, Ma WB
- 6211** Growth hormone ameliorates hepatopulmonary syndrome and nonalcoholic steatohepatitis secondary to hypopituitarism in a child: A case report
Zhang XY, Yuan K, Fang YL, Wang CL
- 6218** Vancomycin dosing in an obese patient with acute renal failure: A case report and review of literature
Xu KY, Li D, Hu ZJ, Zhao CC, Bai J, Du WL
- 6227** Insulinoma after sleeve gastrectomy: A case report
Lobaton-Ginsberg M, Sotelo-González P, Ramirez-Renteria C, Juárez-Aguilar FG, Ferreira-Hermosillo A
- 6234** Primary intestinal lymphangiectasia presenting as limb convulsions: A case report
Cao Y, Feng XH, Ni HX
- 6241** Esophagogastric junctional neuroendocrine tumor with adenocarcinoma: A case report
Kong ZZ, Zhang L

- 6247** Foreign body granuloma in the tongue differentiated from tongue cancer: A case report
Jiang ZH, Xu R, Xia L
- 6254** Modified endoscopic ultrasound-guided selective N-butyl-2-cyanoacrylate injections for gastric variceal hemorrhage in left-sided portal hypertension: A case report
Yang J, Zeng Y, Zhang JW
- 6261** Management of type IIb dens invaginatus using a combination of root canal treatment, intentional replantation, and surgical therapy: A case report
Zhang J, Li N, Li WL, Zheng XY, Li S
- 6269** Clivus-involved immunoglobulin G4 related hypertrophic pachymeningitis mimicking meningioma: A case report
Yu Y, Lv L, Yin SL, Chen C, Jiang S, Zhou PZ
- 6277** De novo brain arteriovenous malformation formation and development: A case report
Huang H, Wang X, Guo AN, Li W, Duan RH, Fang JH, Yin B, Li DD
- 6283** Coinfection of *Streptococcus suis* and *Nocardia asiatica* in the human central nervous system: A case report
Chen YY, Xue XH
- 6289** Dilated left ventricle with multiple outpouchings – a severe congenital ventricular diverticulum or left-dominant arrhythmogenic cardiomyopathy: A case report
Zhang X, Ye RY, Chen XP
- 6298** Spontaneous healing of complicated crown-root fractures in children: Two case reports
Zhou ZL, Gao L, Sun SK, Li HS, Zhang CD, Kou WW, Xu Z, Wu LA
- 6307** Thyroid follicular renal cell carcinoma excluding thyroid metastases: A case report
Wu SC, Li XY, Liao BJ, Xie K, Chen WM
- 6314** Appendiceal bleeding: A case report
Zhou SY, Guo MD, Ye XH
- 6319** Spontaneous healing after conservative treatment of isolated grade IV pancreatic duct disruption caused by trauma: A case report
Mei MZ, Ren YF, Mou YP, Wang YY, Jin WW, Lu C, Zhu QC
- 6325** Pneumonia and seizures due to hypereosinophilic syndrome – organ damage and eosinophilia without synchronisation: A case report
Ishida T, Murayama T, Kobayashi S
- 6333** Creutzfeldt-Jakob disease presenting with bilateral hearing loss: A case report
Na S, Lee SA, Lee JD, Lee ES, Lee TK

LETTER TO THE EDITOR

- 6338** Stem cells as an option for the treatment of COVID-19
Cuevas-González MV, Cuevas-González JC

ABOUT COVER

Editorial Board Member of *World Journal of Clinical Cases*, Cristina Tudoran, PhD, Assistant Professor, Department VII, Internal Medicine II, Discipline of Cardiology, "Victor Babes" University of Medicine and Pharmacy Timisoara, Timisoara 300041, Timis, Romania. cristina13.tudoran@gmail.com

AIMS AND SCOPE

The primary aim of *World Journal of Clinical Cases* (WJCC, *World J Clin Cases*) is to provide scholars and readers from various fields of clinical medicine with a platform to publish high-quality clinical research articles and communicate their research findings online.

WJCC mainly publishes articles reporting research results and findings obtained in the field of clinical medicine and covering a wide range of topics, including case control studies, retrospective cohort studies, retrospective studies, clinical trials studies, observational studies, prospective studies, randomized controlled trials, randomized clinical trials, systematic reviews, meta-analysis, and case reports.

INDEXING/ABSTRACTING

The WJCC is now indexed in Science Citation Index Expanded (also known as SciSearch®), Journal Citation Reports/Science Edition, Scopus, PubMed, and PubMed Central. The 2021 Edition of Journal Citation Reports® cites the 2020 impact factor (IF) for WJCC as 1.337; IF without journal self cites: 1.301; 5-year IF: 1.742; Journal Citation Indicator: 0.33; Ranking: 119 among 169 journals in medicine, general and internal; and Quartile category: Q3. The WJCC's CiteScore for 2020 is 0.8 and Scopus CiteScore rank 2020: General Medicine is 493/793.

RESPONSIBLE EDITORS FOR THIS ISSUE

Production Editor: *Ying-Yi Yuan*, Production Department Director: *Xu Guo*, Editorial Office Director: *Jin-Lei Wang*.

NAME OF JOURNAL

World Journal of Clinical Cases

ISSN

ISSN 2307-8960 (online)

LAUNCH DATE

April 16, 2013

FREQUENCY

Thrice Monthly

EDITORS-IN-CHIEF

Bao-Gan Peng, Jerzy Tadeusz Chudek, George Kontogeorgos, Maurizio Serati, Ja Hyeon Ku

EDITORIAL BOARD MEMBERS

<https://www.wjgnet.com/2307-8960/editorialboard.htm>

PUBLICATION DATE

June 26, 2022

COPYRIGHT

© 2022 Baishideng Publishing Group Inc

INSTRUCTIONS TO AUTHORS

<https://www.wjgnet.com/bpg/gerinfo/204>

GUIDELINES FOR ETHICS DOCUMENTS

<https://www.wjgnet.com/bpg/GerInfo/287>

GUIDELINES FOR NON-NATIVE SPEAKERS OF ENGLISH

<https://www.wjgnet.com/bpg/gerinfo/240>

PUBLICATION ETHICS

<https://www.wjgnet.com/bpg/GerInfo/288>

PUBLICATION MISCONDUCT

<https://www.wjgnet.com/bpg/gerinfo/208>

ARTICLE PROCESSING CHARGE

<https://www.wjgnet.com/bpg/gerinfo/242>

STEPS FOR SUBMITTING MANUSCRIPTS

<https://www.wjgnet.com/bpg/GerInfo/239>

ONLINE SUBMISSION

<https://www.f6publishing.com>



Nontraumatic convexal subarachnoid hemorrhage: A case report

Hong-Liang Chen, Bin Li, Chao Chen, Xiao-Xuan Fan, Wen-Bin Ma

Specialty type: Clinical neurology

Provenance and peer review:

Unsolicited article; Externally peer reviewed.

Peer-review model: Single blind

Peer-review report's scientific quality classification

Grade A (Excellent): 0

Grade B (Very good): 0

Grade C (Good): C, C

Grade D (Fair): 0

Grade E (Poor): 0

P-Reviewer: Diana F, Italy; Nag DS, India

Received: November 14, 2021

Peer-review started: November 14, 2021

First decision: December 10, 2021

Revised: December 17, 2021

Accepted: April 29, 2022

Article in press: April 29, 2022

Published online: June 26, 2022



Hong-Liang Chen, Bin Li, Chao Chen, Wen-Bin Ma, Department of Neurology, Binzhou Medical University Hospital, Binzhou 256600, Shandong Province, China

Xiao-Xuan Fan, Department of Clinical Medicine, Binzhou Medical University, Binzhou 256600, Shandong Province, China

Corresponding author: Wen-Bin Ma, MD, Associate Professor, Department of Neurology, Binzhou Medical University Hospital, No. 661 Huanghe 2nd Road, Binzhou 256600, Shandong Province, China. mawbin@163.com

Abstract

BACKGROUND

Nontraumatic convexal subarachnoid hemorrhage (cSAH) is a rare type of atypical subarachnoid hemorrhage. It mainly presents as a focal and transient neurological deficit with similar manifestations as transient ischemic attack.

CASE SUMMARY

We report a case of a 64-year-old man who visited the hospital with paroxysmal left-sided numbness and weakness is presented in this study. Computed tomography examination indicated a high-density image of the right frontal-parietal sulcus. Digital subtraction angiography showed severe stenosis at the right anterior cerebral artery A2-A3 junction (stenosis rate approximately 70%).

CONCLUSION

The findings of this case indicate that anterior cerebral artery stenosis may lead to the occurrence of cSAH.

Key Words: Nontraumatic convexal subarachnoid hemorrhage; Subarachnoid hemorrhage; Transient ischemic attack; Artery atherosclerosis stenosis; Case report

©The Author(s) 2022. Published by Baishideng Publishing Group Inc. All rights reserved.

Core Tip: This is a rare case of convexal subarachnoid hemorrhage (cSAH) with transient ischemic attack as the first presentation. We reported the whole course. This case indicated the clinical characteristics, laboratory findings, imaging examinations and adjustment of treatment and discussed the possible relation between anterior cerebral artery stenosis and the occurrence of cSAH.

Citation: Chen HL, Li B, Chen C, Fan XX, Ma WB. Nontraumatic convexal subarachnoid hemorrhage: A case report. *World J Clin Cases* 2022; 10(18): 6205-6210

URL: <https://www.wjgnet.com/2307-8960/full/v10/i18/6205.htm>

DOI: <https://dx.doi.org/10.12998/wjcc.v10.i18.6205>

INTRODUCTION

Nontraumatic convexal subarachnoid hemorrhage (cSAH) is a subtype of atypical SAH. Its bleeding site is mainly confined to one or more cerebral hemisphere convexocortical sulci with high incidence in the central sulcus. It does not affect the brain parenchyma, basal cistern, or interhemispheric fissure. It is characterized by low hemorrhage, and only the local cerebral cortex is involved. In addition, it is not associated with typical symptoms such as severe headache and meningeal irritation. In the present study, a case of a cSAH patient with transient ischemic attack (TIA) and a summary of relevant literature are presented.

CASE PRESENTATION

Chief complaints

A 64-year-old male was admitted to the hospital after experiencing paroxysmal left-sided numbness and weakness for 4 d.

History of present illness

These symptoms occurred 2-3 times a day and lasted approximately 20 min each time.

History of past illness

The patient had a clinical history of ischemic stroke and no history of hypertension, diabetes, coronary heart disease, or major trauma.

Personal and family history

The patient had no history of smoking or drinking, and no family history.

Physical examination

The systolic and diastolic blood pressure of the patient during admission was 130/80 mmHg. The patient presented with paroxysmal left hemiplegia without obvious inducement. The left limb could not move during the attack and was accompanied by numbness and discomfort on the left face, trunk, upper, and lower limbs; and the patient presented with dizziness. The National Institute of Health Stroke Scale score of the patient was 0.

Laboratory examinations

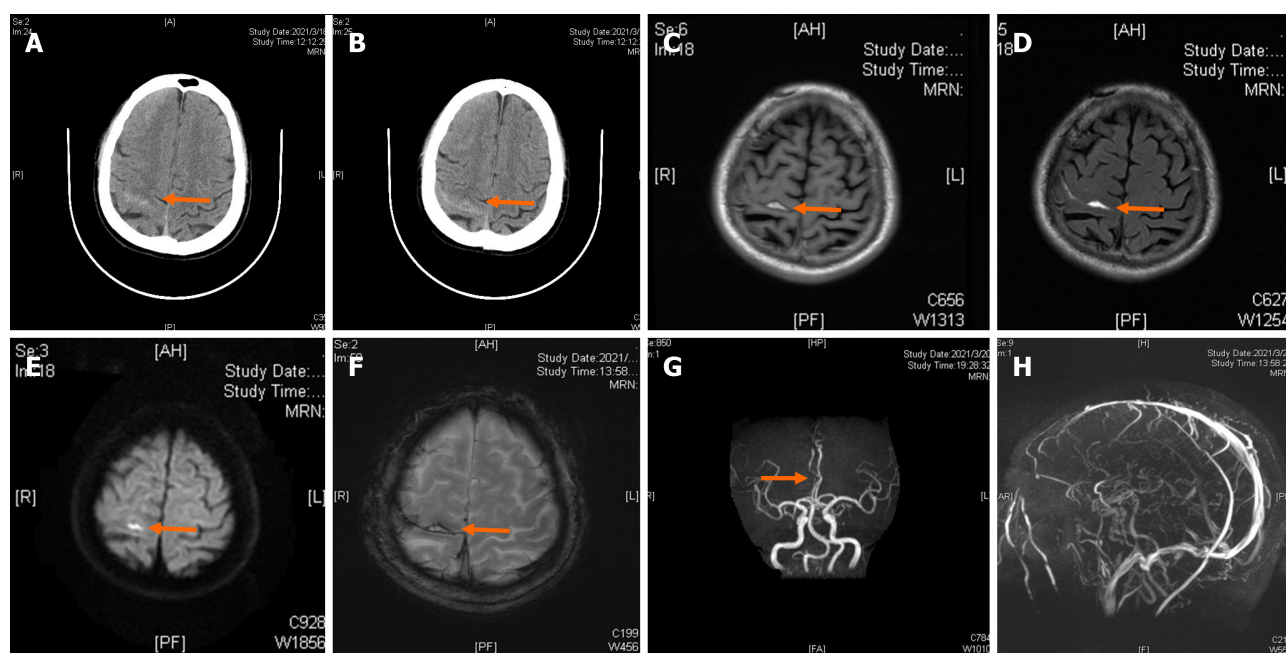
Routine clinical biochemistry showed normal results.

Imaging examinations

Computed tomography (CT) examination was performed during admission and showed a high-density image of the right frontal-parietal sulcus. Magnetic resonance imaging examination showed a slight increase in the T1 flair and a high T2 flair. Diffusion-weighted imaging (DWI) revealed high signal intensity, whereas susceptibility weighted imaging (SWI) showed slightly increased signal intensity in the right frontal lobe. Machine records activity results indicated short local stenosis of the right anterior cerebral artery of the A3 segment, and magnetic resonance venography revealed a thin contrast in the left transverse sinus and left sigmoid sinus (Figure 1). Severe stenosis was observed in the right anterior cerebral artery A2-A3 junction (stenosis rate approximately 70%), and mild stenosis was observed in the distal end of A3 (stenosis rate approximately 30%) through digital subtraction angiography (DSA) (Figure 2).

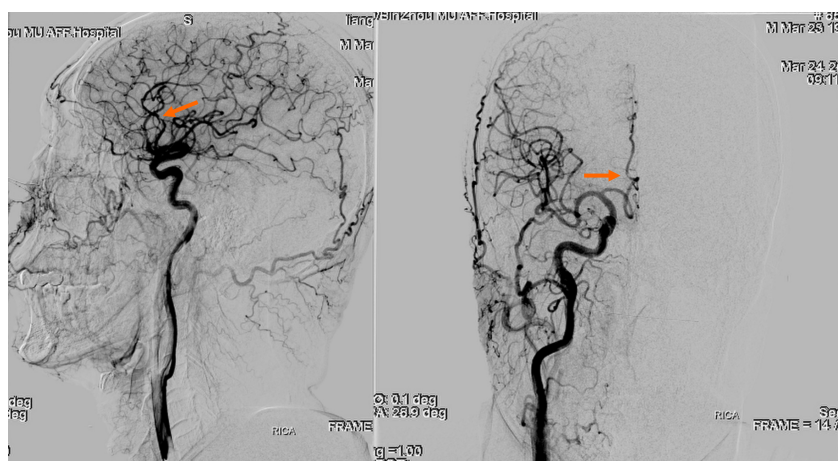
MULTIDISCIPLINARY EXPERT CONSULTATION

There is no multidisciplinary expert consultation.



DOI: 10.12998/wjcc.v10.i18.6205 Copyright ©The Author(s) 2022.

Figure 1 Computed tomography imaging. A and B: Axial computed tomography images showing a high-density image of right frontal-parietal sulcus; C: Magnetic resonance imaging showing slightly elevated T1-flair; D: Elevated T2-flair; E: Diffusion-weighted imaging revealed high signal intensity; F: Susceptibility weighted imaging showing slightly increased signal intensity in the right frontal; G: Machine records activity showing short local stenosis of the right anterior cerebral artery of A3 segment; H: Magnetic resonance venography revealed a thinner contrast in the left transverse sinus and left sigmoid sinus.



DOI: 10.12998/wjcc.v10.i18.6205 Copyright ©The Author(s) 2022.

Figure 2 Digital subtraction angiography showing severe stenosis in the right anterior cerebral artery A2-A3 junction.

FINAL DIAGNOSIS

The complete evidence supported the final diagnosis of cSAH.

TREATMENT

The patient was given blood pressure monitoring, cerebrovascular spasm prevention (nimodipine), cerebral protection, and other treatments.

OUTCOME AND FOLLOW-UP

The range of brain CT-showed bleeding was significantly reduced compared to the previous range after

9 d. The patient had no recurrence of paroxysmal left-sided numbness and weakness.

DISCUSSION

cSAH is a subtype of atypical SAH. Approximately 49% of patients with SAH present with TIA-like symptoms; therefore, the actual annual incidence is more than 5.1 cases in every 100000 people[1]. The etiology of cSAH is highly correlated with age, hypertension, coronary heart disease, and diabetes. Common causes of cSAH include cerebral amyloidosis (CAA), reversible cerebral vasoconstriction syndrome (RCVS), cortical vein thrombosis (CoVT), intracranial large artery atherosclerosis stenosis or occlusion, moyamoya disease, and vasculitis. Notably, CAA is the main cause, accounting for approximately 39% of all cSAH cases[1]. Transient sensorimotor dysfunction (TFNE) is the main symptom in cSAH patients above 60 years of age, and CAA is the common cause of disease, followed by intracranial atherosclerosis stenosis or occlusion[2,3]. In contrast, headache is the main clinical manifestation in patients under 60 years of age, whereas rCVS and CoVT are the main causes of cSAH in these patients [3]. Nakajima *et al*[4-5] reported that more than half of patients with cSAH presented with cerebral vascular occlusion and TFNE and were often misdiagnosed with transient cerebral ischemia. Notably, CAA is a progressive age-related cerebrovascular disease. The severity of the disease increases with age due to deposition of amyloid beta protein in the cortex and leptomeningeal vessels, which is the main cause of cSAH. A previous study reported that TFNE is the main characteristic clinical manifestation of CAA-induced cSAH, followed by cortical superficial siderosis (CSS) and rebleeding[6]. The incidence of hypercholesterolemia is lower in patients with CAA-induced cSAH than in patients with TIA. Cholesterol is negatively correlated with the incidence of nontraumatic intracerebral hemorrhage and aneurysmal hemorrhage[5]. Symptoms of cSAH are paroxysmal and include TIA attacks, seizures, and TFNE. This indicates that TIA attacks can occur as a result of ischemic infarction or may occur as a clinical manifestation of hemorrhagic stroke.

A previous study reported that hyperacute arterial ischemic stroke occurs in patients within 4.5 h and 6 days after a concurrent rate of cSAH 0.5%[4]. Acute changes in hemodynamics and damage to the blood brain barrier may be important mechanisms for the occurrence of cSAH. The incidence of SAH is associated with cerebrovascular disease risk factors such as hypertension, coronary heart disease, and diabetes, and this relationship can be explained by collateral circulation. ICA stenosis or occlusion and MCA stenosis or occlusion can promote the formation of Willis circle and the opening of PIA meningeal vessels, respectively[7-8].

CT scan is important for the diagnosis of cSAH. However, the sensitivity of CT decreases after a period of time. Notably, flair is highly sensitive to hemorrhage in the cerebral convexity cortex sulcus and is more effective in the diagnosis of acute and subacute SAH than plain CT scans. DWI and SWI are characterized by high sensitivity and accuracy in the diagnosis of SAH. Cerebrospinal fluid examination cannot confirm the diagnosis of cSAH; however, it helps in determining the etiology of the disease[9]. Notably, DSA is performed to further confirm the diagnosis when the cause of disease cannot be determined through noninvasive examination. Studies report that cSAH may be a marker of vascular fragility and a major risk factor for future lobar hemorrhage[10]. Cortical or watershed subarachnoid hemorrhage may be the result of excessive cerebral perfusion. High-grade stenosis is always a sign of hemodynamic compromise, and collateral circulation might be a predictor of excessive cerebral perfusion[11]. The clinical and imaging findings of the patient in the present study indicate a positive diagnosis of cSAH and rule out the possibility of CAA. The cause of the disease was initially considered to be atherosclerotic stenosis of the large cerebral artery; however, later severe stenosis of the anterior cerebral artery was considered the cause of the present case. It is speculated that the pathogenesis may be severe stenosis of the anterior cerebral artery, which can cause compensatory dilation and vulnerability of cortical lateral branch vessels in the corresponding region, when hemodynamic changes occur, such as a sudden increase in intracranial perfusion pressure, resulting in the rupture of the leptic lateral branch circulation vessels that have already undergone expansion or increased permeability, resulting in bleeding, or the arrival of embolus to the fragile collateral vessels causing blood vessel rupture and causing a small amount of bleeding, which as indicated by DSA examination. Intracranial artery stenosis/occlusion caused by cSAH is common in MCA. In summary, the findings of the present study indicate that ACA stenosis may lead to the occurrence of cSAH.

cSAH is treated using different treatment strategies depending on the cause of the disease. Antiplatelet therapy is used for intracranial artery stenosis or occlusion caused by arteriosclerosis, nimodipine is administered for reversible cerebral vasoconstriction syndrome, and steroid hormone is given for the treatment of vasculitis. Symptomatic therapy for cSAH includes reduction of intracranial pressure, anti-epilepsy drugs, and administration of drugs for lowering blood pressure. The prognosis of cSAH depends on the cause, and most patients present with good prognosis. However, CAA-induced intracranial hemorrhage is recurrent and associated with poor prognosis[12].

CONCLUSION

Symptoms of cSAH are complex and not easily detected during clinical investigations. The cause of the disease should be explored to minimize missed diagnosis and misdiagnosis.

FOOTNOTES

Author contributions: Ma WB conceived the study, participated in its design and draft the manuscript; Li B, Chen C and Fan XX collected data; Chen HL helped to draft the manuscript; all authors read and approved the final manuscript.

Supported by Research Fund of the Department of Science and Technology of Shandong Province, China, No. 2019WS328.

Informed consent statement: Written informed consent was obtained from the patient for publication of this case report.

Conflict-of-interest statement: The authors declare no conflict of interest.

CARE Checklist (2016) statement: The authors have read the CARE Checklist (2016), and the manuscript was prepared and revised according to the CARE Checklist (2016).

Open-Access: This article is an open-access article that was selected by an in-house editor and fully peer-reviewed by external reviewers. It is distributed in accordance with the Creative Commons Attribution NonCommercial (CC BY-NC 4.0) license, which permits others to distribute, remix, adapt, build upon this work non-commercially, and license their derivative works on different terms, provided the original work is properly cited and the use is non-commercial. See: <https://creativecommons.org/licenses/by-nc/4.0/>

Country/Territory of origin: China

ORCID number: Hong-Liang Chen 0000-0001-9434-9796; Bin Li 0000-0002-8721-4356; Chao Chen 0000-0003-0417-3809; Xiao-Xuan Fan 0000-0003-4912-6774; Wen-Bin Ma 0000-0001-5030-0093.

S-Editor: Xing YX

L-Editor: A

P-Editor: Xing YX

REFERENCES

- 1 **Khurram A**, Kleinig T, Leyden J. Clinical associations and causes of convexity subarachnoid hemorrhage. *Stroke* 2014; **45**: 1151-1153 [PMID: 24496391 DOI: 10.1161/STROKEAHA.113.004298]
- 2 **Kumar S**, Goddeau RP Jr, Selim MH, Thomas A, Schlaug G, Alhazzani A, Searls DE, Caplan LR. Atraumatic convexal subarachnoid hemorrhage: clinical presentation, imaging patterns, and etiologies. *Neurology* 2010; **74**: 893-899 [PMID: 20231664 DOI: 10.1212/WNL.0b013e3181d55efa]
- 3 **Martínez-Lizana E**, Carmona-Iragui M, Alcolea D, Gómez-Choco M, Vilaplana E, Sánchez-Saudinós MB, Clarimón J, Hernández-Guillamon M, Munuera J, Gelpi E, Gómez-Anson B, de Juan-Delago M, Delgado-Mederos R, Montaner J, Ois A, Amaro S, Blesa R, Martí-Fàbregas J, Lleó A, Fortea J. Cerebral amyloid angiopathy-related atraumatic convexal subarachnoid hemorrhage: an ARIA before the tsunami. *J Cereb Blood Flow Metab* 2015; **35**: 710-717 [PMID: 25735919 DOI: 10.1038/jcbfm.2015.25]
- 4 **Nakajima M**, Inatomi Y, Yonehara T, Hirano T, Ando Y. Nontraumatic convexal subarachnoid hemorrhage concomitant with acute ischemic stroke. *J Stroke Cerebrovasc Dis* 2014; **23**: 1564-1570 [PMID: 24630829 DOI: 10.1016/j.jstrokecerebrovasdis.2013.12.046]
- 5 **Stanton JED**, Chandratheva A, Wilson D, Hostettler IC, Islam S, Werring DJ. Clinical features distinguish cerebral amyloid angiopathy-associated convexity subarachnoid haemorrhage from suspected TIA. *J Neurol* 2020; **267**: 133-137 [PMID: 31583428 DOI: 10.1007/s00415-019-09558-9]
- 6 **Charidimou A**, Jäger RH, Fox Z, Peeters A, Vandermeeren Y, Laloux P, Baron JC, Werring DJ. Prevalence and mechanisms of cortical superficial siderosis in cerebral amyloid angiopathy. *Neurology* 2013; **81**: 626-632 [PMID: 23864315 DOI: 10.1212/WNL.0b013e3182a08f2c]
- 7 **Sato T**, Sakai K, Mimori M, Komatsu T, Sakuta K, Terasawa Y, Umehara T, Omoto S, Mitsumura H, Murakami H, Shimizu T, Matsushima S, Iguchi Y. Convexity Subarachnoid Hemorrhage Accompanied by Hyperacute Ischemic Stroke. *Cerebrovasc Dis* 2020; **49**: 70-78 [PMID: 31910410 DOI: 10.1159/000505013]
- 8 **Chandra RV**, Leslie-Mazwi TM, Oh D, Mehta B, Yoo AJ. Extracranial internal carotid artery stenosis as a cause of cortical subarachnoid hemorrhage. *AJNR Am J Neuroradiol* 2011; **32**: E51-2; author reply E53 [PMID: 21349955 DOI: 10.3174/ajnr.A2456]
- 9 **Refai D**, Botros JA, Strom RG, Derdeyn CP, Sharma A, Zipfel GJ. Spontaneous isolated convexity subarachnoid

- hemorrhage: presentation, radiological findings, differential diagnosis, and clinical course. *J Neurosurg* 2008; **109**: 1034-1041 [PMID: [19035716](#) DOI: [10.3171/JNS.2008.109.12.1034](#)]
- 10 **Raposo N**, Charidimou A, Roongpiboonsopit D, Onyekaba M, Gurol ME, Rosand J, Greenberg SM, Goldstein JN, Viswanathan A. Convexity subarachnoid hemorrhage in lobar intracerebral hemorrhage: A prognostic marker. *Neurology* 2020; **94**: e968-e977 [PMID: [32019785](#) DOI: [10.1212/WNL.0000000000009036](#)]
 - 11 **Diana F**, Frauenfelder G, Botto A, Saponiero R, Romano DG. Cerebral hyperperfusion syndrome after intracranial stenting: Case report and systematic review. *Interv Neuroradiol* 2021; **27**: 843-849 [PMID: [33884930](#) DOI: [10.1177/15910199211011860](#)]
 - 12 **Usmani N**, Ahmad FU, Koch S. Convexity subarachnoid hemorrhage in ischemic stroke. *J Neurol Sci* 2015; **348**: 259-261 [PMID: [25498843](#) DOI: [10.1016/j.jns.2014.11.031](#)]



Published by **Baishideng Publishing Group Inc**
7041 Koll Center Parkway, Suite 160, Pleasanton, CA 94566, USA

Telephone: +1-925-3991568

E-mail: bpgoffice@wjgnet.com

Help Desk: <https://www.f6publishing.com/helpdesk>

<https://www.wjgnet.com>

