

World Journal of *Clinical Cases*

World J Clin Cases 2022 June 26; 10(18): 5934-6340



MINIREVIEWS

- 5934** Development of clustered regularly interspaced short palindromic repeats/CRISPR-associated technology for potential clinical applications
Huang YY, Zhang XY, Zhu P, Ji L
- 5946** Strategies and challenges in treatment of varicose veins and venous insufficiency
Gao RD, Qian SY, Wang HH, Liu YS, Ren SY
- 5957** Diabetes mellitus susceptibility with varied diseased phenotypes and its comparison with phenome interactome networks
Rout M, Kour B, Vuree S, Lulu SS, Medicherla KM, Suravajhala P

ORIGINAL ARTICLE

Clinical and Translational Research

- 5965** Identification of potential key molecules and signaling pathways for psoriasis based on weighted gene co-expression network analysis
Shu X, Chen XX, Kang XD, Ran M, Wang YL, Zhao ZK, Li CX
- 5984** Construction and validation of a novel prediction system for detection of overall survival in lung cancer patients
Zhong C, Liang Y, Wang Q, Tan HW, Liang Y

Case Control Study

- 6001** Effectiveness and postoperative rehabilitation of one-stage combined anterior-posterior surgery for severe thoracolumbar fractures with spinal cord injury
Zhang B, Wang JC, Jiang YZ, Song QP, An Y

Retrospective Study

- 6009** Prostate sclerosing adenopathy: A clinicopathological and immunohistochemical study of twelve patients
Feng RL, Tao YP, Tan ZY, Fu S, Wang HF
- 6021** Value of magnetic resonance diffusion combined with perfusion imaging techniques for diagnosing potentially malignant breast lesions
Zhang H, Zhang XY, Wang Y
- 6032** Scar-centered dilation in the treatment of large keloids
Wu M, Gu JY, Duan R, Wei BX, Xie F
- 6039** Application of a novel computer-assisted surgery system in percutaneous nephrolithotomy: A controlled study
Qin F, Sun YF, Wang XN, Li B, Zhang ZL, Zhang MX, Xie F, Liu SH, Wang ZJ, Cao YC, Jiao W

- 6050** Influences of etiology and endoscopic appearance on the long-term outcomes of gastric antral vascular ectasia

Kwon HJ, Lee SH, Cho JH

Randomized Controlled Trial

- 6060** Evaluation of the clinical efficacy and safety of TST33 mega hemorrhoidectomy for severe prolapsed hemorrhoids

Tao L, Wei J, Ding XF, Ji LJ

- 6069** Sequential chemotherapy and icotinib as first-line treatment for advanced epidermal growth factor receptor-mutated non-small cell lung cancer

Sun SJ, Han JD, Liu W, Wu ZY, Zhao X, Yan X, Jiao SC, Fang J

Randomized Clinical Trial

- 6082** Impact of preoperative carbohydrate loading on gastric volume in patients with type 2 diabetes

Lin XQ, Chen YR, Chen X, Cai YP, Lin JX, Xu DM, Zheng XC

META-ANALYSIS

- 6091** Efficacy and safety of adalimumab in comparison to infliximab for Crohn's disease: A systematic review and meta-analysis

Yang HH, Huang Y, Zhou XC, Wang RN

CASE REPORT

- 6105** Successful treatment of acute relapse of chronic eosinophilic pneumonia with benralizumab and without corticosteroids: A case report

Izhakian S, Pertzov B, Rosengarten D, Kramer MR

- 6110** Pembrolizumab-induced Stevens-Johnson syndrome in advanced squamous cell carcinoma of the lung: A case report and review of literature

Wu JY, Kang K, Yi J, Yang B

- 6119** Hepatic epithelioid hemangioendothelioma after thirteen years' follow-up: A case report and review of literature

Mo WF, Tong YL

- 6128** Effectiveness and safety of ultrasound-guided intramuscular lauromacrogol injection combined with hysteroscopy in cervical pregnancy treatment: A case report

Ye JP, Gao Y, Lu LW, Ye YJ

- 6136** Carcinoma located in a right-sided sigmoid colon: A case report

Lyu LJ, Yao WW

- 6141** Subcutaneous infection caused by *Mycobacterium abscessus* following cosmetic injections of botulinum toxin: A case report

Deng L, Luo YZ, Liu F, Yu XH

- 6148** Overlapping syndrome of recurrent anti-N-methyl-D-aspartate receptor encephalitis and anti-myelin oligodendrocyte glycoprotein demyelinating diseases: A case report
Yin XJ, Zhang LF, Bao LH, Feng ZC, Chen JH, Li BX, Zhang J
- 6156** Liver transplantation for late-onset ornithine transcarbamylase deficiency: A case report
Fu XH, Hu YH, Liao JX, Chen L, Hu ZQ, Wen JL, Chen SL
- 6163** Disseminated strongyloidiasis in a patient with rheumatoid arthritis: A case report
Zheng JH, Xue LY
- 6168** CYP27A1 mutation in a case of cerebrotendinous xanthomatosis: A case report
Li ZR, Zhou YL, Jin Q, Xie YY, Meng HM
- 6175** Postoperative multiple metastasis of clear cell sarcoma-like tumor of the gastrointestinal tract in adolescent: A case report
Huang WP, Li LM, Gao JB
- 6184** Toripalimab combined with targeted therapy and chemotherapy achieves pathologic complete response in gastric carcinoma: A case report
Liu R, Wang X, Ji Z, Deng T, Li HL, Zhang YH, Yang YC, Ge SH, Zhang L, Bai M, Ning T, Ba Y
- 6192** Presentation of Boerhaave's syndrome as an upper-esophageal perforation associated with a right-sided pleural effusion: A case report
Tan N, Luo YH, Li GC, Chen YL, Tan W, Xiang YH, Ge L, Yao D, Zhang MH
- 6198** Camrelizumab-induced anaphylactic shock in an esophageal squamous cell carcinoma patient: A case report and review of literature
Liu K, Bao JF, Wang T, Yang H, Xu BP
- 6205** Nontraumatic convexal subarachnoid hemorrhage: A case report
Chen HL, Li B, Chen C, Fan XX, Ma WB
- 6211** Growth hormone ameliorates hepatopulmonary syndrome and nonalcoholic steatohepatitis secondary to hypopituitarism in a child: A case report
Zhang XY, Yuan K, Fang YL, Wang CL
- 6218** Vancomycin dosing in an obese patient with acute renal failure: A case report and review of literature
Xu KY, Li D, Hu ZJ, Zhao CC, Bai J, Du WL
- 6227** Insulinoma after sleeve gastrectomy: A case report
Lobaton-Ginsberg M, Sotelo-González P, Ramirez-Renteria C, Juárez-Aguilar FG, Ferreira-Hermosillo A
- 6234** Primary intestinal lymphangiectasia presenting as limb convulsions: A case report
Cao Y, Feng XH, Ni HX
- 6241** Esophagogastric junctional neuroendocrine tumor with adenocarcinoma: A case report
Kong ZZ, Zhang L

- 6247** Foreign body granuloma in the tongue differentiated from tongue cancer: A case report
Jiang ZH, Xu R, Xia L
- 6254** Modified endoscopic ultrasound-guided selective N-butyl-2-cyanoacrylate injections for gastric variceal hemorrhage in left-sided portal hypertension: A case report
Yang J, Zeng Y, Zhang JW
- 6261** Management of type IIb dens invaginatus using a combination of root canal treatment, intentional replantation, and surgical therapy: A case report
Zhang J, Li N, Li WL, Zheng XY, Li S
- 6269** Clivus-involved immunoglobulin G4 related hypertrophic pachymeningitis mimicking meningioma: A case report
Yu Y, Lv L, Yin SL, Chen C, Jiang S, Zhou PZ
- 6277** De novo brain arteriovenous malformation formation and development: A case report
Huang H, Wang X, Guo AN, Li W, Duan RH, Fang JH, Yin B, Li DD
- 6283** Coinfection of *Streptococcus suis* and *Nocardia asiatica* in the human central nervous system: A case report
Chen YY, Xue XH
- 6289** Dilated left ventricle with multiple outpouchings – a severe congenital ventricular diverticulum or left-dominant arrhythmogenic cardiomyopathy: A case report
Zhang X, Ye RY, Chen XP
- 6298** Spontaneous healing of complicated crown-root fractures in children: Two case reports
Zhou ZL, Gao L, Sun SK, Li HS, Zhang CD, Kou WW, Xu Z, Wu LA
- 6307** Thyroid follicular renal cell carcinoma excluding thyroid metastases: A case report
Wu SC, Li XY, Liao BJ, Xie K, Chen WM
- 6314** Appendiceal bleeding: A case report
Zhou SY, Guo MD, Ye XH
- 6319** Spontaneous healing after conservative treatment of isolated grade IV pancreatic duct disruption caused by trauma: A case report
Mei MZ, Ren YF, Mou YP, Wang YY, Jin WW, Lu C, Zhu QC
- 6325** Pneumonia and seizures due to hypereosinophilic syndrome – organ damage and eosinophilia without synchronisation: A case report
Ishida T, Murayama T, Kobayashi S
- 6333** Creutzfeldt-Jakob disease presenting with bilateral hearing loss: A case report
Na S, Lee SA, Lee JD, Lee ES, Lee TK

LETTER TO THE EDITOR

- 6338** Stem cells as an option for the treatment of COVID-19
Cuevas-González MV, Cuevas-González JC

ABOUT COVER

Editorial Board Member of *World Journal of Clinical Cases*, Cristina Tudoran, PhD, Assistant Professor, Department VII, Internal Medicine II, Discipline of Cardiology, "Victor Babes" University of Medicine and Pharmacy Timisoara, Timisoara 300041, Timis, Romania. cristina13.tudoran@gmail.com

AIMS AND SCOPE

The primary aim of *World Journal of Clinical Cases* (WJCC, *World J Clin Cases*) is to provide scholars and readers from various fields of clinical medicine with a platform to publish high-quality clinical research articles and communicate their research findings online.

WJCC mainly publishes articles reporting research results and findings obtained in the field of clinical medicine and covering a wide range of topics, including case control studies, retrospective cohort studies, retrospective studies, clinical trials studies, observational studies, prospective studies, randomized controlled trials, randomized clinical trials, systematic reviews, meta-analysis, and case reports.

INDEXING/ABSTRACTING

The WJCC is now indexed in Science Citation Index Expanded (also known as SciSearch®), Journal Citation Reports/Science Edition, Scopus, PubMed, and PubMed Central. The 2021 Edition of Journal Citation Reports® cites the 2020 impact factor (IF) for WJCC as 1.337; IF without journal self cites: 1.301; 5-year IF: 1.742; Journal Citation Indicator: 0.33; Ranking: 119 among 169 journals in medicine, general and internal; and Quartile category: Q3. The WJCC's CiteScore for 2020 is 0.8 and Scopus CiteScore rank 2020: General Medicine is 493/793.

RESPONSIBLE EDITORS FOR THIS ISSUE

Production Editor: *Ying-Yi Yuan*, Production Department Director: *Xu Guo*, Editorial Office Director: *Jin-Lei Wang*.

NAME OF JOURNAL

World Journal of Clinical Cases

ISSN

ISSN 2307-8960 (online)

LAUNCH DATE

April 16, 2013

FREQUENCY

Thrice Monthly

EDITORS-IN-CHIEF

Bao-Gan Peng, Jerzy Tadeusz Chudek, George Kontogeorgos, Maurizio Serati, Ja Hyeon Ku

EDITORIAL BOARD MEMBERS

<https://www.wjnet.com/2307-8960/editorialboard.htm>

PUBLICATION DATE

June 26, 2022

COPYRIGHT

© 2022 Baishideng Publishing Group Inc

INSTRUCTIONS TO AUTHORS

<https://www.wjnet.com/bpg/gerinfo/204>

GUIDELINES FOR ETHICS DOCUMENTS

<https://www.wjnet.com/bpg/GerInfo/287>

GUIDELINES FOR NON-NATIVE SPEAKERS OF ENGLISH

<https://www.wjnet.com/bpg/gerinfo/240>

PUBLICATION ETHICS

<https://www.wjnet.com/bpg/GerInfo/288>

PUBLICATION MISCONDUCT

<https://www.wjnet.com/bpg/gerinfo/208>

ARTICLE PROCESSING CHARGE

<https://www.wjnet.com/bpg/gerinfo/242>

STEPS FOR SUBMITTING MANUSCRIPTS

<https://www.wjnet.com/bpg/GerInfo/239>

ONLINE SUBMISSION

<https://www.f6publishing.com>



Management of type IIIb dens invaginatus using a combination of root canal treatment, intentional replantation, and surgical therapy: A case report

Jing Zhang, Na Li, Wu-Li Li, Xian-Yu Zheng, Song Li

Specialty type: Dentistry, oral surgery and medicine

Provenance and peer review:

Unsolicited article; Externally peer reviewed.

Peer-review model: Single blind

Peer-review report's scientific quality classification

Grade A (Excellent): 0
Grade B (Very good): B
Grade C (Good): C
Grade D (Fair): 0
Grade E (Poor): 0

P-Reviewer: Abu Hasna A, Brazil; Memis S, Turkey

Received: December 17, 2021

Peer-review started: December 17, 2021

First decision: January 26, 2022

Revised: February 8, 2022

Accepted: April 21, 2022

Article in press: April 21, 2022

Published online: June 26, 2022



Jing Zhang, Na Li, Wu-Li Li, Xian-Yu Zheng, Song Li, Stomatological Hospital and College, Key Laboratory of Oral Diseases Research of Anhui Province, Anhui Medical University, Hefei 230032, Anhui Province, China

Corresponding author: Song Li, PhD, Doctor, Professor, Stomatological Hospital and College, Key Laboratory of Oral Diseases Research of Anhui Province, Anhui Medical University, No. 69 Meishan Road, Hefei 230032, Anhui Province, China. 3197053337@qq.com

Abstract

BACKGROUND

Type IIIb dens invaginatus (DI) with a lateral canal located at the mid-third of the root is rarely reported. Here, we report a rare case of type IIIb DI in the left upper anterior tooth with a lateral canal that led to persistent periodontitis.

CASE SUMMARY

A 15-year-old female patient presented with a chief complaint of pain associated with recurrent labial swelling in the area of the left anterior tooth. A diagnosis of type IIIb DI and chronic periodontitis was made. Intentional replantation was performed after conventional endodontic treatment failed. After 6 mo, the patient was asymptomatic, but a sinus tract was observed. Cone-beam computed tomography images showed bone loss in the mesial of the mid-root. Based on methylene blue staining and microscopy images, the lateral foramen located at the middle third of the root was surgically treated. After 3 years of follow-up, the clinical findings and radiographic assessment presented a favorable prognosis of bone healing without root absorption or ankylosis.

CONCLUSION

Type IIIb DI with a lateral canal can be successfully treated by root canal treatment, intentional replantation, and surgical therapy.

Key Words: Dens invaginatus; Intentional replantation; Surgical therapy; Lateral canal; Case report

©The Author(s) 2022. Published by Baishideng Publishing Group Inc. All rights reserved.

Core Tip: Type IIIb dens invaginatus (DI) with a lateral canal located at the mid-third of the root is first reported. Here, we report a rare case of type IIIb DI in the left upper anterior tooth with a lateral canal that led to persistent periodontitis and it was successfully treated by a combination of root canal treatment, intentional replantation, and surgical therapy.

Citation: Zhang J, Li N, Li WL, Zheng XY, Li S. Management of type IIIb dens invaginatus using a combination of root canal treatment, intentional replantation, and surgical therapy: A case report. *World J Clin Cases* 2022; 10(18): 6261-6268

URL: <https://www.wjgnet.com/2307-8960/full/v10/i18/6261.htm>

DOI: <https://dx.doi.org/10.12998/wjcc.v10.i18.6261>

INTRODUCTION

Dens invaginatus (DI) is a dental developmental anomaly resulting from enamel enfolding into the dental papilla prior to calcification. DI occurs more often in permanent maxillary lateral incisors and less frequently in mandibular anterior and deciduous teeth[1]. Clinically, pits lined with enamel defects and dentin invaginated into the dental/teeth with DI are susceptible to caries due to microorganism accumulation, easily leading to pulp necrosis and periapical inflammation[2]. However, DI may be easily overlooked due to the absence of clinical signs of malformation.

The most widely known classification of DI into three types was made by Oehler[3] in 1957 based on the extent of invagination from the crown into the root. Type III is the most complicated form due to the more extreme anatomical complexity. Type IIIa refers to invagination penetrating through the root and forming a lateral foramen as a pseudoforamen, while type IIIb refers to invagination extending through the root with an apical foramen. There is usually no communication with the pulp, which lies compressed within the wall around the invagination process. However, to our knowledge, this is the first report of a tooth of type IIIb DI infected *via* a lateral canal.

DI poses a great challenge in endodontic treatment due to the development of malformations with distortion of the teeth. Canal irregularities and invagination may prevent mechanical and chemical preparation. Due to the anatomic variations of the complex root canal morphologies, various treatment options have been proposed, including sealing of the invagination, root canal treatment, intentional replantation, periapical microsurgery, and extraction[4-6]. Here, we report a complex case of type IIIb DI with a lateral canal. After endodontic treatment, intentional replantation, and periapical microsurgery, the clinical findings and radiographic assessment presented a favorable prognosis of effective periapical healing at a 3-year follow-up assessment.

CASE PRESENTATION

Chief complaints

A 15-year-old female patient presented to the Department of Endodontics, Anhui Medical University, China with a chief complaint of pain associated with recurrent labial swelling in the area of the left anterior tooth for the past 6 mo. The patient reported that she had undergone endodontic treatment 1 mo earlier with symptom recurrence.

History of present illness

The patient presented to the Department of Endodontics, Anhui Medical University, China, with a chief complaint of pain associated with recurrent labial swelling in the area of the left anterior tooth for the past 6 mo.

History of past illness

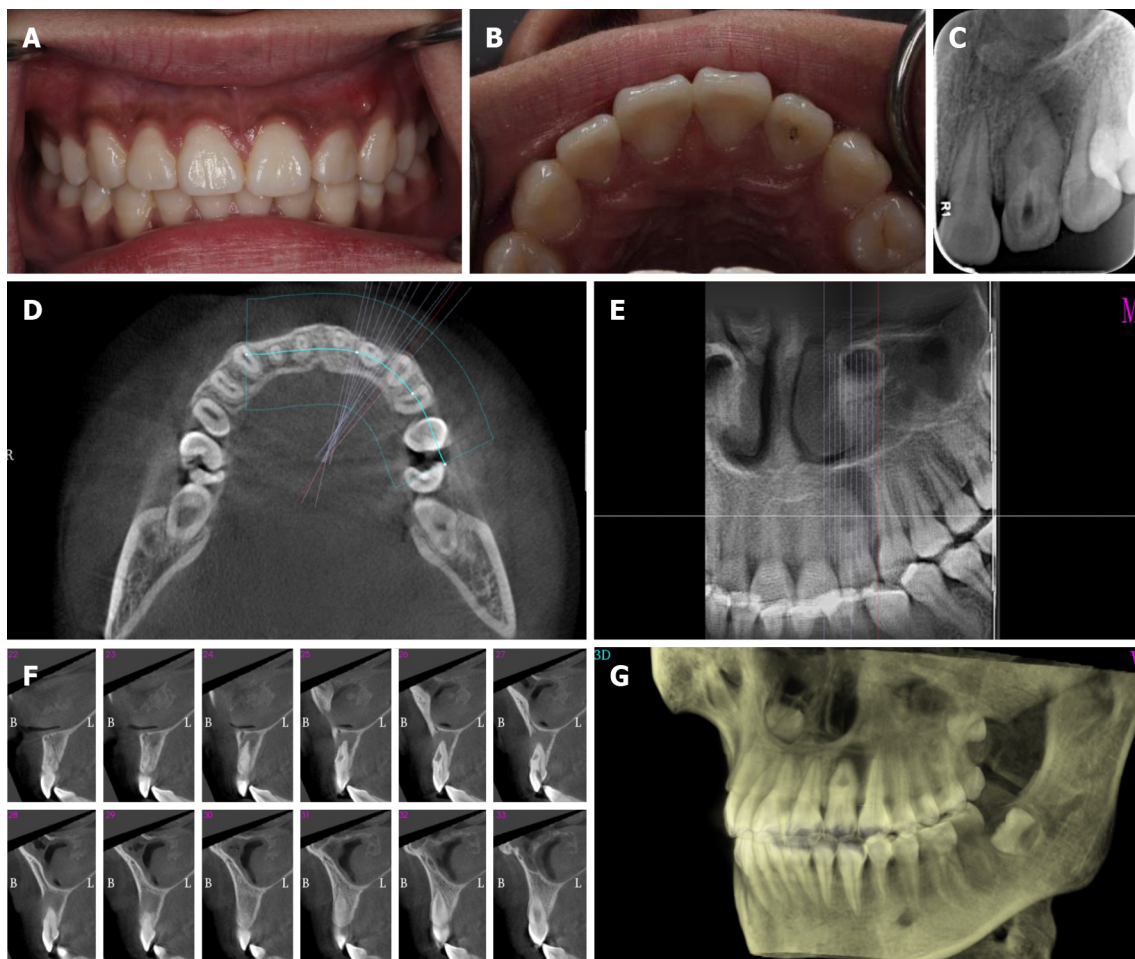
The patient reported that she had undergone endodontic treatment 1 mo earlier with symptom recurrence.

Personal and family history

The patient had a noncontributory personal and family history.

Physical examination

Oral examination revealed fluctuating buccal swelling with a sinus at the apical area (Figure 1A). Tooth 22 showed an intact crown with a palatal access cavity (Figure 1B). Sensitivity to vertical percussion and negativity to palpation and electric pulp testing were observed, whereas the response of adjacent teeth



DOI: 10.12998/wjcc.v10.i18.6261 Copyright ©The Author(s) 2022.

Figure 1 Preoperative photograph of the left upper anterior teeth. A: Labial view showing an intact left lateral incisor with a sinus on the distobuccal aspect; B: Palatal view showing tooth 22 with an access cavity; C: Radiograph showing the presence of dens invaginatus (DI) associated with a large periapical lesion; D-F: Cone-beam computed tomography images: Transverse view showing radiolucency surrounding tooth 22 (D), coronal view showing a DI extending to the apex of the root (E), and sagittal sections showing DI with a large periapical radiolucency (F); G: Three-dimensional reconstruction indicating loss of labial cortical plate.

was normal. The periodontal probing depths were within the normal range with slight mobility. Radiography showed an invagination of dentin lined by enamel into the pulpal space, expanded space in the middle of the teeth with a large periapical radiolucent lesion, and the presence of bone resorption (Figure 1C).

Laboratory examinations

The patient's blood test results were all normal.

Imaging examinations

A cone-beam computed tomography (CBCT) scan showed invagination extending from the crown into the root with an apical foramen associated with a large periapical radiolucent lesion, which caused variation in the main root canal. A well-defined unilocular periapical radiolucent lesion was observed. Sagittal CBCT images showed that a loop-shaped chamber separated the main root canal (Figure 1D-G).

FINAL DIAGNOSIS

A diagnosis of type IIIb DI and chronic periodontitis was made.

TREATMENT

Under rubber dam isolation, the temporary filling was removed, and access to the main and invaginated

canals was completed. Pulp vitality in the main canal and dens invaginatus canal confirmed necrosis. The total length of the canals was estimated to be 19 mm, and the canals were then thoroughly prepared to apical size 30 by the crown-down technique with a NiTi file. A large volume of pale-yellowish fluid drained from the canal. Following thorough irrigation with 5.25% sodium hypochlorite (NaOCl), the root canals were dried with paper points, and calcium hydroxide paste was placed into the two canals (Figure 2A). The coronal access was sealed with a 3-mm-thick temporary restorative material. The patient was scheduled to return after 2 wk.

Intentional replantation

As endodontic therapy failed and the aberrant anatomic structure hampered adequate disinfection and obturation, the patient was informed that root canal retreatment could not clean out the infected pulp tissue clearly and obturation could not seal the pseudo canal tightly. Intentional replantation and surgical treatment were chosen as the next treatment. After discussing the risk and the financial cost, her parents chose to perform intentional replantation at the 2-wk follow-up appointment (Figure 2B). The patient received 500 mg amoxicillin and 400 mg ibuprofen 30 min before surgery and was instructed to rinse with 0.2% chlorhexidine gluconate solution. After local anesthesia, a minimal portion of tooth 22 was extracted without any fracture. The crown was held by saline-soaked wet gauze to keep the teeth moist and to minimize damage to the periodontal ligament (PDL) (Figure 2C). Under the dental operating microscope, the apex of the tooth was resected with a high-speed handpiece for 3 mm, and the foramen was clearly and deeply prepared by ultrasonic tips. iBoot BP (Innovative BioCeramix Inc., Vancouver, Canada) was placed to completely seal the retrograde cavity (Figure 2D). Then, the tooth was gently replanted into the socket and fixed by a wire and composite resin splint (Figure 2E). The extraoral times were limited to under 13 min. A radiograph was taken to confirm that the depth of iBoot BP was approximately 5 mm (Figure 2F). After the surgery was performed, amoxicillin (500 mg, 3 times per day) was administered for 3 d to prevent wound infection. The patient was instructed to maintain a soft diet and use a 0.2% chlorhexidine gluconate oral rinse for 2 wk.

Two weeks after the procedure, the patient returned, and the wire and composite resin splint were removed. After removal of the temporary restorative material under rubber dam isolation, calcium hydroxide paste in the root canals was cleared by ultrasonication. After drying the canals with paper points, the canals were fully obturated with gutta percha, and iRoot BP (Innovative BioCeramix Inc.) was performed using a vertical condensation technique. Subsequently, tooth 22 was restored using acid-etch and composite resin Z350 (3M ESPE, MN, United States).

Unfortunately, 6 mo later, the patient returned pain-free, but the swelling (sinus tract) in the buccal maxillary region reappeared (Figure 3A and B). A gutta percha point in the draining sinus revealed point tracking to a large periapical lesion associated with the mesial surface of tooth 22 (Figure 3C and D).

Surgical treatment

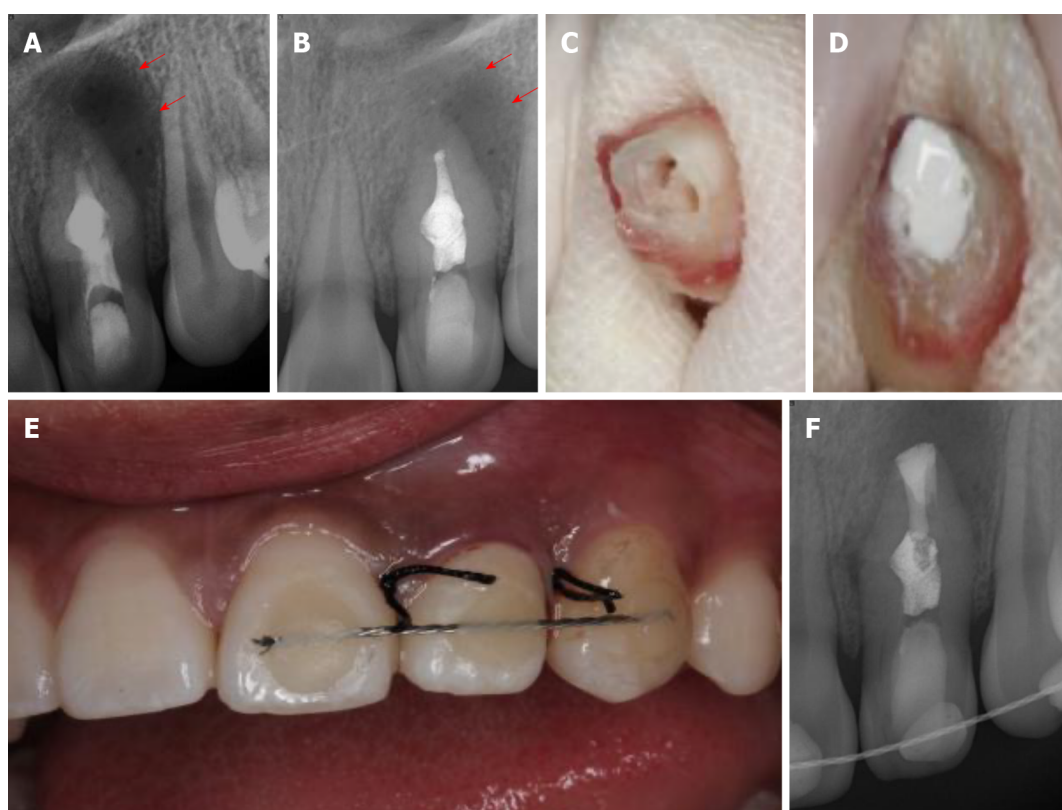
The patient refused the extraction and had a strong desire to preserve natural tooth 22. The patient and her parents agreed to perform endodontic microsurgery as a last resort to seal the lateral canal in the mesial of tooth 22. After local anesthesia, a full-thickness triangular mucoperiosteal flap was made to expose the mesial area of tooth 22. The root surface was stained with methylene blue to identify the lateral foramen. An L-shaped pit on the mid-root surface was observed, which was then prepared with an ultrasonic tip and obturated with iRoot BP (Figure 3E and F). The granulomatous tissues were curetted, and the surgical region was irrigated with 0.9% saline. Finally, the flap was repositioned and sutured. The sutures were removed after 2 wk.

OUTCOME AND FOLLOW-UP

At the 3-year recall evaluation, the patient had no painful symptoms. The radiograph image presented complete healing of the periapical lesion around the tooth root. Continuity of the periodontal ligament was observed, and intercortical bone had formed completely without any root resorption or ankylosis (Figure 4).

DISCUSSION

Treatment for DI varies depending on the invagination type, anatomy of the canal, level of pulp involvement, and morphology of the apex. To our knowledge, this is the first report of an infection of type IIb DI with a lateral canal resulting in the persistence of periapical damage. Microorganism contamination in the invagination easily inflames the pulp irreversibly and even causes pulp necrosis both in the main canal and the invagination canal, especially in patients with type III DI. In patients with type IIIa DI, endodontic treatment should be performed on the canals as if they were two independent canals[6]. In patients with type IIb, some authors recommend removing the extremely



DOI: 10.12998/wjcc.v10.i18.6261 Copyright ©The Author(s) 2022.

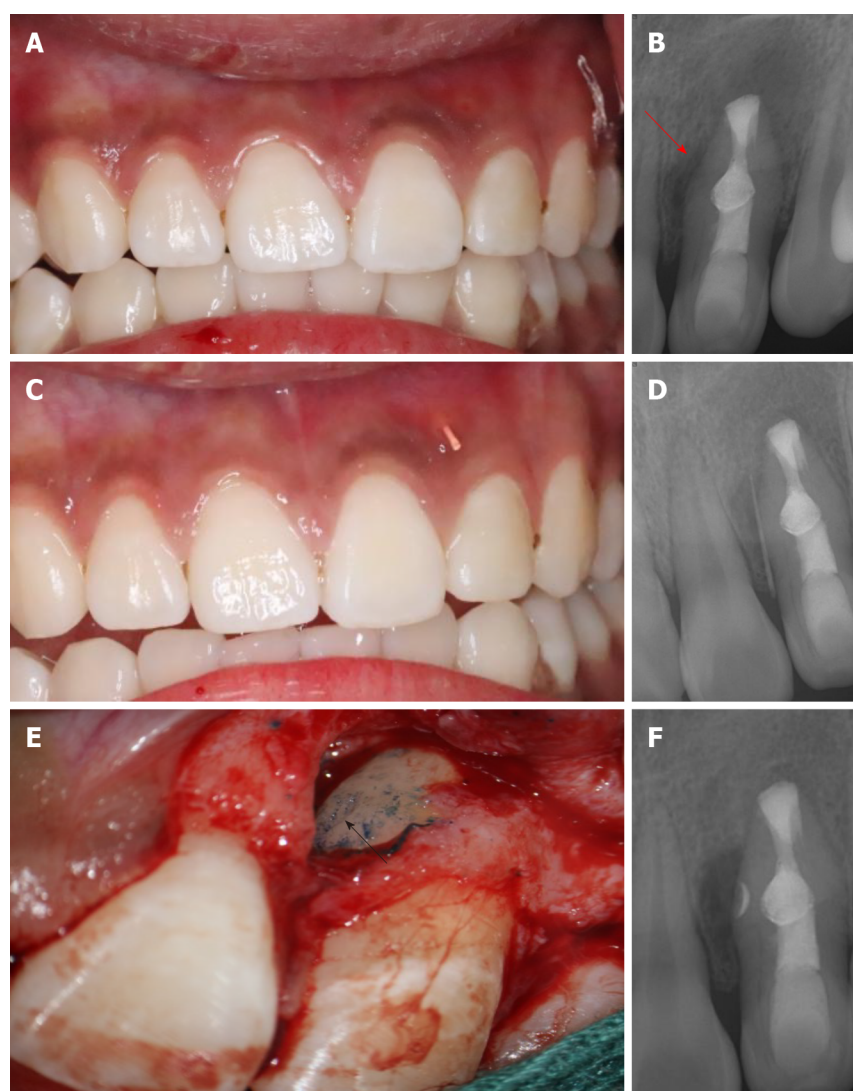
Figure 2 Canal disinfection and intentional replantation. A: Radiographic image showing that tooth 22 was placed with hydroxide paste; B: Radiographic image of tooth 22 at the 2-wk recall; C: Tooth 22 was extracted, and the apex of the tooth was resected; D: Obturation of root canal space and retroseal of the apex with iRoot BP; E: Replantation of tooth 22 with a composite resin splint; F: Radiographic image of the replantation of tooth 22 (red arrow indicates the boundaries of the lesion).

large anomalous invagination using ultrasonic instruments and combining the two canals as one space to allow for complete and sufficient disinfection[7]. The removal of the single and large canal was followed by obturation with mineral trioxide aggregate in the apical third. However, the elimination of invagination severely compromised the strength of the tooth and increased the risk of tooth fracture. Martins *et al*[7] reported that three Fibercore posts were applied to the root canal to reinforce the thin root wall. In this reported case, the invaginated cavity occupied the center of the canal and adhered labially to the canal wall. Removal of the invaginated hard tissue was impractical. Such removal would cause a thin outer shell of dentine to remain, which may result in a poor prognosis.

Successful root canal treatment is based on the complete removal of all infections in the entire root canal system[8]. However, due to the anatomical impediments of type IIIb DI that restrict instrument cleaning and sufficient shaping, chemomechanical preparation cannot effectively eliminate all the infected tissues in the main canal or the invagination canal, including lateral canals and apical ramifications[9]. This would cause root canal treatment to occasionally fail, resulting in the persistence of periapical damage. Since a conventional root canal, as the first alternative, had already been initiated and failed in this patient, surgical endodontic or intentional replantation was the second treatment option instead of tooth extraction[10].

Intentional replantation is defined as deliberate extraction of the teeth and visual endodontic manipulation followed by reinsertion back into the original socket. The advantages of intentional replantation are that the major procedure is performed visually and that it benefits inaccessible areas, including the morphological variation in type IIIb DI[11]. A recent systematic review demonstrated that the survival rate of intentional replantation was 90%[12]. In a retrospective study of ten cases of type IIIb DI with apical periodontitis treated by intentional replantation, the survival rate was 80%[13]. Due to its high survival rate, low invasiveness, and cost-effectiveness, intentional replantation is regarded as a reliable and viable treatment when root canal treatment fails. PDL is important for the success of intentional replantation. Yu *et al*[14] reported that PDL cells remained alive within 15 to 20 min, which was crucial for the ability of PDL cells to attach to the alveolus. In this patient, we limited the extraoral time to 13 min, leading to successful periradicular healing.

Unfortunately, the sinus tract in the buccal maxillary region was noted at six recall evaluations. In the initial radiograph, we focused on the morphological variation of DI and periapical infection while ignoring the lateral infection caused by organisms in the lateral canal. Considering the patient's wishes and with the aid of methylene blue staining, surgical treatment was attempted as the last resort to

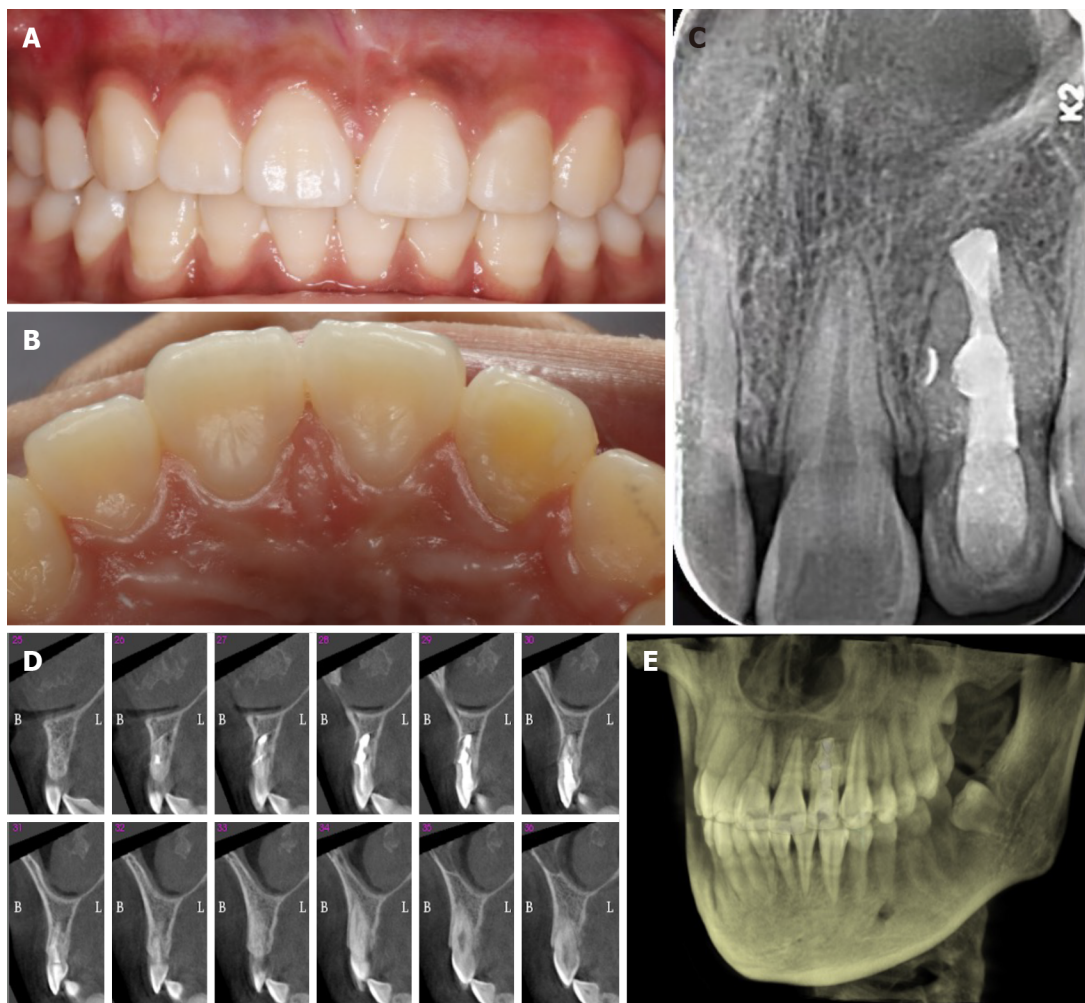


DOI: 10.12998/wjcc.v10.i18.6261 Copyright ©The Author(s) 2022.

Figure 3 Intraoral examination after 6 mo and surgical treatment. A: Labial view showing the left lateral incisor with a sinus on the mesiobuccal aspect; B: Radiograph image showing enlargement of a large periapical radiolucency (red arrow) around the mid-root of tooth 22; C: A gutta percha was placed into the sinus of tooth 22; D: Radiograph of tooth 22 with a gutta percha point in the sinus tract; E: Surgical confirmation of the L-shaped pit on the mid-root surface (black arrow); F: Postoperative radiograph.

obturate the lateral canal. Lateral canals are accessory canals that usually extend vertically to the main canal. They are not easily visible in preoperative radiographs[9]. Ricucci *et al*[9] assessed 500 representative extracted teeth that were scanned by microcomputed tomography. The authors found that lateral canals occurred more frequently in the apical third of the root than in the middle of the root. The shape and tortuosity of the lateral canals may vary among different teeth. Most of the lateral canals were curved and not circular, as reported in this patient, which increased the complexity of the treatment. The median diameter of the lateral canals is 67 μm , while the diameter of the main canals is two to three times larger[15,16]. Therefore, apical periodontitis occurs far more frequently than lateral periodontitis.

Some studies have reported that periradicular inflammation has no relationship with unfilled lateral canals[17], and some authors have argued that an insufficiently obturated lateral canal can lead to endodontic treatment failure. This was attributed to the patency of the lateral canal and microbiological involvement[18]. Kim and Kratchman[19] recommended resecting at least 3 mm of apical root to eliminate 98% of apical ramifications and 93% of lateral canals that exist within 3 mm of the root end. However, in this patient, the foramen of the later canal was located at the middle third of the root. Therefore, removal of 3 mm of root end by surgical treatment would not have benefited lateral periodontitis healing. To our knowledge, this is the first report of a tooth of type IIIB DI infected *via* the lateral canal located at the middle of the root.



DOI: 10.12998/wjcc.v10.i18.6261 Copyright ©The Author(s) 2022.

Figure 4 Follow-up photographs and radiograph. A: Three-year recall labial view; B: Three-year recall palatal view; C: Three-year recall radiograph. The obturated lateral canal was visualized; D: Sagittal sections showing bony healing; E: Three-dimensional reconstruction indicating continuous bony plates.

CONCLUSION

Type IIIb DI has a variety of atypical internal morphologic complexities, which presents a great challenge for treatment in the clinic. This reported case highlights the significance of awareness of type IIIb DI with a lateral canal in the middle of the root. This result indicated that complex type IIIb DI can be successfully treated by a combination of intentional replantation and surgical treatment when conventional endodontic therapy fails.

FOOTNOTES

Author contributions: Zhang J, Li N, and Li WL analyzed and interpreted the imaging findings; Zhang J and Zheng XY reviewed the literature and drafted the manuscript; Li S was the patient's dentist and was responsible for the revision of the manuscript; all authors issued final approval for the version to be submitted.

Supported by Health and Medical Research Fund of the Food and Health Bureau, Hong Kong, China, No. 06171376; Natural Science Foundation of Anhui Province, China, No. 2008085MH255; and Scientific Research Funding of Anhui Medical University, China, No.2020xkj148.

Informed consent statement: Consent was obtained from the patient's parents for publication of this report.

Conflict-of-interest statement: The authors declare that they have no conflicts of interest to disclose.

CARE Checklist (2016) statement: The authors have read the CARE Checklist (2016), and the manuscript was prepared and revised according to the CARE Checklist (2016).

Open-Access: This article is an open-access article that was selected by an in-house editor and fully peer-reviewed by external reviewers. It is distributed in accordance with the Creative Commons Attribution NonCommercial (CC BY-NC 4.0) license, which permits others to distribute, remix, adapt, build upon this work non-commercially, and license their derivative works on different terms, provided the original work is properly cited and the use is non-commercial. See: <https://creativecommons.org/licenses/by-nc/4.0/>

Country/Territory of origin: China

ORCID number: Jing Zhang 0000-0002-2774-8110; Na Li 0000-0002-0091-7797; Wu-Li Li 0000-0002-3684-7057; Xian-Yu Zheng 0000-0002-1631-8641; Song Li 0000-0003-1736-2852.

S-Editor: Yan JP

L-Editor: Wang TQ

P-Editor: Yan JP

REFERENCES

- 1 **Alkadi M**, Almohareb R, Mansour S, Mehanny M, Alsadhan R. Assessment of dens invaginatus and its characteristics in maxillary anterior teeth using cone-beam computed tomography. *Sci Rep* 2021; **11**: 19727 [PMID: 34611255 DOI: 10.1038/s41598-021-99258-0]
- 2 **Vier-Pelisser FV**, Pelisser A, Recuero LC, Só MV, Borba MG, Figueiredo JA. Use of cone beam computed tomography in the diagnosis, planning and follow up of a type III dens invaginatus case. *Int Endod J* 2012; **45**: 198-208 [PMID: 21978185 DOI: 10.1111/j.1365-2591.2011.01956.x]
- 3 **Oehlers FA**. Dens invaginatus (dilated composite odontome). I. Variations of the invagination process and associated anterior crown forms. *Oral Surg Oral Med Oral Pathol* 1957; **10**: 1204-18 contd [PMID: 13477660 DOI: 10.1016/0030-4220(57)90077-4]
- 4 **Ozbaz H**, Subay RK, Ordulu M. Surgical retreatment of an invaginated maxillary central incisor following overfilled endodontic treatment: a case report. *Eur J Dent* 2010; **4**: 324-328 [PMID: 20613922]
- 5 **Kumar H**, Al-Ali M, Parashos P, Manton DJ. Management of 2 teeth diagnosed with dens invaginatus with regenerative endodontics and apexification in the same patient: a case report and review. *J Endod* 2014; **40**: 725-731 [PMID: 24767572 DOI: 10.1016/j.joen.2013.10.030]
- 6 **Agrawal PK**, Wankhade J, Warhadpande M. A Rare Case of Type III Dens Invaginatus in a Mandibular Second Premolar and Its Nonsurgical Endodontic Management by Using Cone-beam Computed Tomography: A Case Report. *J Endod* 2016; **42**: 669-672 [PMID: 26874642 DOI: 10.1016/j.joen.2016.01.001]
- 7 **Martins JNR**, da Costa RP, Anderson C, Quaresma SA, Corte-Real LSM, Monroe AD. Endodontic management of dens invaginatus Type IIb: Case series. *Eur J Dent* 2016; **10**: 561-565 [PMID: 28042276 DOI: 10.4103/1305-7456.195176]
- 8 **Gallacher A**, Ali R, Bhakta S. Dens invaginatus: diagnosis and management strategies. *Br Dent J* 2016; **221**: 383-387 [PMID: 27713460 DOI: 10.1038/sj.bdj.2016.724]
- 9 **Ricucci D**, Siqueira JF Jr. Fate of the tissue in lateral canals and apical ramifications in response to pathologic conditions and treatment procedures. *J Endod* 2010; **36**: 1-15 [PMID: 20003929 DOI: 10.1016/j.joen.2009.09.038]
- 10 **Siqueira JF Jr**, Rôças IN, Hernández SR, Brisson-Suárez K, Baasch AC, Pérez AR, Alves FRF. Dens Invaginatus: Clinical Implications and Antimicrobial Endodontic Treatment Considerations. *J Endod* 2022; **48**: 161-170 [PMID: 34902355 DOI: 10.1016/j.joen.2021.11.014]
- 11 **Peer M**. Intentional replantation - a 'last resort' treatment or a conventional treatment procedure? *Dent Traumatol* 2004; **20**: 48-55 [PMID: 14998415 DOI: 10.1046/j.1600-4469.2003.00218.x]
- 12 **Mainkar A**. A Systematic Review of the Survival of Teeth Intentionally Replanted with a Modern Technique and Cost-effectiveness Compared with Single-tooth Implants. *J Endod* 2017; **43**: 1963-1968 [PMID: 29061358 DOI: 10.1016/j.joen.2017.08.019]
- 13 **Li N**, Xu H, Kan C, Zhang J, Li S. Retrospective Study of Intentional Replantation for Type IIb Dens Invaginatus with Periapical Lesions. *J Endod* 2022; **48**: 329-336 [PMID: 34999093 DOI: 10.1016/j.joen.2021.12.010]
- 14 **Yu YH**, Kim M, Kratchman S, Karabucak B. Surgical management of lateral lesions with intentional replantation in single-rooted mandibular first premolars with radicular groove: 2 case reports. *J Am Dent Assoc* 2022 [PMID: 35078591 DOI: 10.1016/j.adaj.2021.09.012]
- 15 **Ponce EH**, Vilar Fernández JA. The cemento-dentino-canal junction, the apical foramen, and the apical constriction: evaluation by optical microscopy. *J Endod* 2003; **29**: 214-219 [PMID: 12669885 DOI: 10.1097/00004770-200303000-00013]
- 16 **Xu T**, Tay FR, Gutmann JL, Fan B, Fan W, Huang Z, Sun Q. Micro-Computed Tomography Assessment of Apical Accessory Canal Morphologies. *J Endod* 2016; **42**: 798-802 [PMID: 26975416 DOI: 10.1016/j.joen.2016.02.006]
- 17 **Barthel CR**, Zimmer S, Trope M. Relationship of radiologic and histologic signs of inflammation in human root-filled teeth. *J Endod* 2004; **30**: 75-79 [PMID: 14977300 DOI: 10.1097/00004770-200402000-00003]
- 18 **Dammaschke T**, Witt M, Ott K, Schäfer E. Scanning electron microscopic investigation of incidence, location, and size of accessory foramina in primary and permanent molars. *Quintessence Int* 2004; **35**: 699-705 [PMID: 15470993]
- 19 **Kim S**, Kratchman S. Modern endodontic surgery concepts and practice: a review. *J Endod* 2006; **32**: 601-623 [PMID: 16793466 DOI: 10.1016/j.joen.2005.12.010]



Published by **Baishideng Publishing Group Inc**
7041 Koll Center Parkway, Suite 160, Pleasanton, CA 94566, USA

Telephone: +1-925-3991568

E-mail: bpgoffice@wjgnet.com

Help Desk: <https://www.f6publishing.com/helpdesk>

<https://www.wjgnet.com>

