

World Journal of *Clinical Cases*

World J Clin Cases 2022 June 26; 10(18): 5934-6340



MINIREVIEWS

- 5934** Development of clustered regularly interspaced short palindromic repeats/CRISPR-associated technology for potential clinical applications
Huang YY, Zhang XY, Zhu P, Ji L
- 5946** Strategies and challenges in treatment of varicose veins and venous insufficiency
Gao RD, Qian SY, Wang HH, Liu YS, Ren SY
- 5957** Diabetes mellitus susceptibility with varied diseased phenotypes and its comparison with phenome interactome networks
Rout M, Kour B, Vuree S, Lulu SS, Medicherla KM, Suravajhala P

ORIGINAL ARTICLE**Clinical and Translational Research**

- 5965** Identification of potential key molecules and signaling pathways for psoriasis based on weighted gene co-expression network analysis
Shu X, Chen XX, Kang XD, Ran M, Wang YL, Zhao ZK, Li CX
- 5984** Construction and validation of a novel prediction system for detection of overall survival in lung cancer patients
Zhong C, Liang Y, Wang Q, Tan HW, Liang Y

Case Control Study

- 6001** Effectiveness and postoperative rehabilitation of one-stage combined anterior-posterior surgery for severe thoracolumbar fractures with spinal cord injury
Zhang B, Wang JC, Jiang YZ, Song QP, An Y

Retrospective Study

- 6009** Prostate sclerosing adenopathy: A clinicopathological and immunohistochemical study of twelve patients
Feng RL, Tao YP, Tan ZY, Fu S, Wang HF
- 6021** Value of magnetic resonance diffusion combined with perfusion imaging techniques for diagnosing potentially malignant breast lesions
Zhang H, Zhang XY, Wang Y
- 6032** Scar-centered dilation in the treatment of large keloids
Wu M, Gu JY, Duan R, Wei BX, Xie F
- 6039** Application of a novel computer-assisted surgery system in percutaneous nephrolithotomy: A controlled study
Qin F, Sun YF, Wang XN, Li B, Zhang ZL, Zhang MX, Xie F, Liu SH, Wang ZJ, Cao YC, Jiao W

- 6050** Influences of etiology and endoscopic appearance on the long-term outcomes of gastric antral vascular ectasia

Kwon HJ, Lee SH, Cho JH

Randomized Controlled Trial

- 6060** Evaluation of the clinical efficacy and safety of TST33 mega hemorrhoidectomy for severe prolapsed hemorrhoids

Tao L, Wei J, Ding XF, Ji LJ

- 6069** Sequential chemotherapy and icotinib as first-line treatment for advanced epidermal growth factor receptor-mutated non-small cell lung cancer

Sun SJ, Han JD, Liu W, Wu ZY, Zhao X, Yan X, Jiao SC, Fang J

Randomized Clinical Trial

- 6082** Impact of preoperative carbohydrate loading on gastric volume in patients with type 2 diabetes

Lin XQ, Chen YR, Chen X, Cai YP, Lin JX, Xu DM, Zheng XC

META-ANALYSIS

- 6091** Efficacy and safety of adalimumab in comparison to infliximab for Crohn's disease: A systematic review and meta-analysis

Yang HH, Huang Y, Zhou XC, Wang RN

CASE REPORT

- 6105** Successful treatment of acute relapse of chronic eosinophilic pneumonia with benralizumab and without corticosteroids: A case report

Izhakian S, Pertzov B, Rosengarten D, Kramer MR

- 6110** Pembrolizumab-induced Stevens-Johnson syndrome in advanced squamous cell carcinoma of the lung: A case report and review of literature

Wu JY, Kang K, Yi J, Yang B

- 6119** Hepatic epithelioid hemangioendothelioma after thirteen years' follow-up: A case report and review of literature

Mo WF, Tong YL

- 6128** Effectiveness and safety of ultrasound-guided intramuscular lauromacrogol injection combined with hysteroscopy in cervical pregnancy treatment: A case report

Ye JP, Gao Y, Lu LW, Ye YJ

- 6136** Carcinoma located in a right-sided sigmoid colon: A case report

Lyu LJ, Yao WW

- 6141** Subcutaneous infection caused by *Mycobacterium abscessus* following cosmetic injections of botulinum toxin: A case report

Deng L, Luo YZ, Liu F, Yu XH

- 6148** Overlapping syndrome of recurrent anti-N-methyl-D-aspartate receptor encephalitis and anti-myelin oligodendrocyte glycoprotein demyelinating diseases: A case report
Yin XJ, Zhang LF, Bao LH, Feng ZC, Chen JH, Li BX, Zhang J
- 6156** Liver transplantation for late-onset ornithine transcarbamylase deficiency: A case report
Fu XH, Hu YH, Liao JX, Chen L, Hu ZQ, Wen JL, Chen SL
- 6163** Disseminated strongyloidiasis in a patient with rheumatoid arthritis: A case report
Zheng JH, Xue LY
- 6168** CYP27A1 mutation in a case of cerebrotendinous xanthomatosis: A case report
Li ZR, Zhou YL, Jin Q, Xie YY, Meng HM
- 6175** Postoperative multiple metastasis of clear cell sarcoma-like tumor of the gastrointestinal tract in adolescent: A case report
Huang WP, Li LM, Gao JB
- 6184** Toripalimab combined with targeted therapy and chemotherapy achieves pathologic complete response in gastric carcinoma: A case report
Liu R, Wang X, Ji Z, Deng T, Li HL, Zhang YH, Yang YC, Ge SH, Zhang L, Bai M, Ning T, Ba Y
- 6192** Presentation of Boerhaave's syndrome as an upper-esophageal perforation associated with a right-sided pleural effusion: A case report
Tan N, Luo YH, Li GC, Chen YL, Tan W, Xiang YH, Ge L, Yao D, Zhang MH
- 6198** Camrelizumab-induced anaphylactic shock in an esophageal squamous cell carcinoma patient: A case report and review of literature
Liu K, Bao JF, Wang T, Yang H, Xu BP
- 6205** Nontraumatic convexal subarachnoid hemorrhage: A case report
Chen HL, Li B, Chen C, Fan XX, Ma WB
- 6211** Growth hormone ameliorates hepatopulmonary syndrome and nonalcoholic steatohepatitis secondary to hypopituitarism in a child: A case report
Zhang XY, Yuan K, Fang YL, Wang CL
- 6218** Vancomycin dosing in an obese patient with acute renal failure: A case report and review of literature
Xu KY, Li D, Hu ZJ, Zhao CC, Bai J, Du WL
- 6227** Insulinoma after sleeve gastrectomy: A case report
Lobaton-Ginsberg M, Sotelo-González P, Ramirez-Renteria C, Juárez-Aguilar FG, Ferreira-Hermosillo A
- 6234** Primary intestinal lymphangiectasia presenting as limb convulsions: A case report
Cao Y, Feng XH, Ni HX
- 6241** Esophagogastric junctional neuroendocrine tumor with adenocarcinoma: A case report
Kong ZZ, Zhang L

- 6247** Foreign body granuloma in the tongue differentiated from tongue cancer: A case report
Jiang ZH, Xu R, Xia L
- 6254** Modified endoscopic ultrasound-guided selective N-butyl-2-cyanoacrylate injections for gastric variceal hemorrhage in left-sided portal hypertension: A case report
Yang J, Zeng Y, Zhang JW
- 6261** Management of type IIb dens invaginatus using a combination of root canal treatment, intentional replantation, and surgical therapy: A case report
Zhang J, Li N, Li WL, Zheng XY, Li S
- 6269** Clivus-involved immunoglobulin G4 related hypertrophic pachymeningitis mimicking meningioma: A case report
Yu Y, Lv L, Yin SL, Chen C, Jiang S, Zhou PZ
- 6277** De novo brain arteriovenous malformation formation and development: A case report
Huang H, Wang X, Guo AN, Li W, Duan RH, Fang JH, Yin B, Li DD
- 6283** Coinfection of *Streptococcus suis* and *Nocardia asiatica* in the human central nervous system: A case report
Chen YY, Xue XH
- 6289** Dilated left ventricle with multiple outpouchings – a severe congenital ventricular diverticulum or left-dominant arrhythmogenic cardiomyopathy: A case report
Zhang X, Ye RY, Chen XP
- 6298** Spontaneous healing of complicated crown-root fractures in children: Two case reports
Zhou ZL, Gao L, Sun SK, Li HS, Zhang CD, Kou WW, Xu Z, Wu LA
- 6307** Thyroid follicular renal cell carcinoma excluding thyroid metastases: A case report
Wu SC, Li XY, Liao BJ, Xie K, Chen WM
- 6314** Appendiceal bleeding: A case report
Zhou SY, Guo MD, Ye XH
- 6319** Spontaneous healing after conservative treatment of isolated grade IV pancreatic duct disruption caused by trauma: A case report
Mei MZ, Ren YF, Mou YP, Wang YY, Jin WW, Lu C, Zhu QC
- 6325** Pneumonia and seizures due to hypereosinophilic syndrome – organ damage and eosinophilia without synchronisation: A case report
Ishida T, Murayama T, Kobayashi S
- 6333** Creutzfeldt-Jakob disease presenting with bilateral hearing loss: A case report
Na S, Lee SA, Lee JD, Lee ES, Lee TK

LETTER TO THE EDITOR

- 6338** Stem cells as an option for the treatment of COVID-19
Cuevas-González MV, Cuevas-González JC

ABOUT COVER

Editorial Board Member of *World Journal of Clinical Cases*, Cristina Tudoran, PhD, Assistant Professor, Department VII, Internal Medicine II, Discipline of Cardiology, "Victor Babes" University of Medicine and Pharmacy Timisoara, Timisoara 300041, Timis, Romania. cristina13.tudoran@gmail.com

AIMS AND SCOPE

The primary aim of *World Journal of Clinical Cases* (WJCC, *World J Clin Cases*) is to provide scholars and readers from various fields of clinical medicine with a platform to publish high-quality clinical research articles and communicate their research findings online.

WJCC mainly publishes articles reporting research results and findings obtained in the field of clinical medicine and covering a wide range of topics, including case control studies, retrospective cohort studies, retrospective studies, clinical trials studies, observational studies, prospective studies, randomized controlled trials, randomized clinical trials, systematic reviews, meta-analysis, and case reports.

INDEXING/ABSTRACTING

The WJCC is now indexed in Science Citation Index Expanded (also known as SciSearch®), Journal Citation Reports/Science Edition, Scopus, PubMed, and PubMed Central. The 2021 Edition of Journal Citation Reports® cites the 2020 impact factor (IF) for WJCC as 1.337; IF without journal self cites: 1.301; 5-year IF: 1.742; Journal Citation Indicator: 0.33; Ranking: 119 among 169 journals in medicine, general and internal; and Quartile category: Q3. The WJCC's CiteScore for 2020 is 0.8 and Scopus CiteScore rank 2020: General Medicine is 493/793.

RESPONSIBLE EDITORS FOR THIS ISSUE

Production Editor: *Ying-Yi Yuan*, Production Department Director: *Xu Guo*, Editorial Office Director: *Jin-Lei Wang*.

NAME OF JOURNAL

World Journal of Clinical Cases

ISSN

ISSN 2307-8960 (online)

LAUNCH DATE

April 16, 2013

FREQUENCY

Thrice Monthly

EDITORS-IN-CHIEF

Bao-Gan Peng, Jerzy Tadeusz Chudek, George Kontogeorgos, Maurizio Serati, Ja Hyeon Ku

EDITORIAL BOARD MEMBERS

<https://www.wjgnet.com/2307-8960/editorialboard.htm>

PUBLICATION DATE

June 26, 2022

COPYRIGHT

© 2022 Baishideng Publishing Group Inc

INSTRUCTIONS TO AUTHORS

<https://www.wjgnet.com/bpg/gerinfo/204>

GUIDELINES FOR ETHICS DOCUMENTS

<https://www.wjgnet.com/bpg/gerinfo/287>

GUIDELINES FOR NON-NATIVE SPEAKERS OF ENGLISH

<https://www.wjgnet.com/bpg/gerinfo/240>

PUBLICATION ETHICS

<https://www.wjgnet.com/bpg/gerinfo/288>

PUBLICATION MISCONDUCT

<https://www.wjgnet.com/bpg/gerinfo/208>

ARTICLE PROCESSING CHARGE

<https://www.wjgnet.com/bpg/gerinfo/242>

STEPS FOR SUBMITTING MANUSCRIPTS

<https://www.wjgnet.com/bpg/gerinfo/239>

ONLINE SUBMISSION

<https://www.f6publishing.com>



Creutzfeldt-Jakob disease presenting with bilateral hearing loss: A case report

Seunghye Na, Se A Lee, Jong Dae Lee, Eek-Sung Lee, Tae-Kyeong Lee

Specialty type: Clinical neurology

Provenance and peer review:

Unsolicited article; Externally peer reviewed.

Peer-review model: Single blind

Peer-review report's scientific quality classification

Grade A (Excellent): A

Grade B (Very good): B

Grade C (Good): 0

Grade D (Fair): 0

Grade E (Poor): 0

P-Reviewer: Wang YJ, China; Xie Q, China

Received: February 9, 2022

Peer-review started: February 9, 2022

First decision: March 23, 2022

Revised: March 24, 2022

Accepted: April 22, 2022

Article in press: April 22, 2022

Published online: June 26, 2022



Seunghye Na, Department of Neurology, Incheon St. Mary's Hospital, The Catholic University of Korea, Incheon 21431, South Korea

Se A Lee, Jong Dae Lee, Department of Otorhinolaryngology-Head and Neck Surgery, Soonchunhyang University Bucheon Hospital, Bucheon 14584, South Korea

Eek-Sung Lee, Tae-Kyeong Lee, Department of Neurology, Soonchunhyang University Bucheon Hospital, Bucheon 14584, South Korea

Corresponding author: Eek-Sung Lee, MD, PhD, Assistant Professor, Department of Neurology, Soonchunhyang University Bucheon Hospital, 170, Jomaru-ro, Bucheon 14584, South Korea. eeksung@schmc.ac.kr

Abstract

BACKGROUND

Sporadic Creutzfeldt-Jakob disease (sCJD) is a prion disease characterized as a fatal transmissible neurodegenerative disorder. Dizziness is often the first presenting symptom of sCJD, but hearing loss as an early manifestation is very rare.

CASE SUMMARY

A 76-year-old man presented with bilateral sudden hearing impairment and dizziness for 10 d. He was taking medications for hypertension and diabetes. He denied any difficulty with activities of daily living or hearing impairment before the onset of symptoms. Pure tone audiometry showed bilateral severe hearing impairment. Brain magnetic resonance imaging (MRI) and laboratory tests were within normal limits. Given his diagnosis of sudden sensory hearing loss, the patient received corticosteroid treatment but it was ineffective. Two weeks later, he complained of aggravated gait impairment, disorientation, and cognitive impairment. Repeat brain MRI showed diffuse cortical high signal intensities on diffusion-weighted imaging. In cerebrospinal fluid analysis, the real-time quaking-induced conversion assay was positive, and 14-3-3 protein was detected in the by western blotting. Considering all the data, we diagnosed probable sCJD, and the patient's symptoms rapidly progressed into akinetic mutism.

CONCLUSION

For patients with abrupt bilateral hearing impairment, especially in the elderly, various differential diagnoses, including sCJD, should be considered.

Key Words: Case report; Creutzfeldt-Jakob disease; Bilateral hearing loss; Diffusion-

weighted imaging; Real-time quaking-induced conversion assay

©The Author(s) 2022. Published by Baishideng Publishing Group Inc. All rights reserved.

Core Tip: Hearing impairment as an initial manifestation of Creutzfeldt-Jakob disease is rare. However, it should be regarded as a differential diagnosis in an elderly patient with bilateral hearing impairment unresponsive to standard corticosteroid treatment. Repeat brain imaging including diffusion-weighted imaging and cerebrospinal fluid analysis will be helpful for diagnosis.

Citation: Na S, Lee SA, Lee JD, Lee ES, Lee TK. Creutzfeldt-Jakob disease presenting with bilateral hearing loss: A case report. *World J Clin Cases* 2022; 10(18): 6333-6337

URL: <https://www.wjgnet.com/2307-8960/full/v10/i18/6333.htm>

DOI: <https://dx.doi.org/10.12998/wjcc.v10.i18.6333>

INTRODUCTION

Sporadic Creutzfeldt-Jakob disease (sCJD) is a prion disease characterized as a fatal transmissible neurodegenerative disorder[1]. The key features of sCJD are rapidly progressive dementia and diverse symptoms including myoclonus, pyramidal and extrapyramidal symptoms, cerebellar disturbance, visual symptoms, and akinetic mutism. Among them, it is known that the most commonly reported presenting symptom is cognitive decline. In other presentations, dizziness is also often the first presenting symptom of sCJD, but hearing loss as an early manifestation is very rare[2]. Herein, we report a case of acute bilateral sensorineural hearing loss as the first manifestation of sCJD.

CASE PRESENTATION

Chief complaints

A 76-year-old man presented with bilateral sudden hearing impairment and dizziness for 10 d.

History of present illness

The hearing impairment first developed on the left side and then rapidly progressed to bilateral. He also reported dizziness that was aggravated by positional changes and accompanied by a slight gait imbalance, but he could walk without assistance.

History of past illness

He was taking medications for hypertension and diabetes for over ten years. He denied any difficulty with activities of daily living or hearing impairment before the onset of symptoms.

Personal and family history

No special history of personal and family.

Physical examination

The patient revealed no spontaneous nystagmus or gaze-evoked nystagmus. The bedside head impulse test was unremarkable. The other cranial nerves were unremarkable, and there was no limb ataxia.

Laboratory examinations

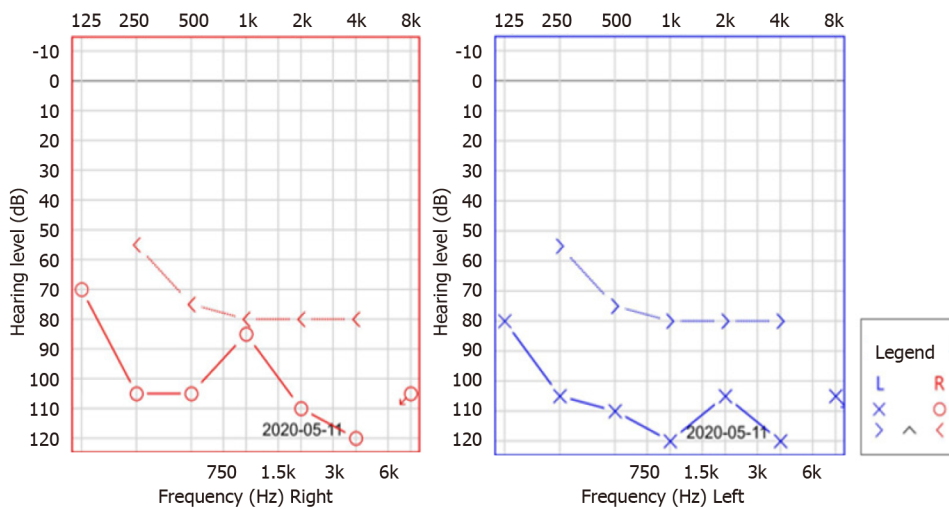
Laboratory tests including routine blood tests, autoimmune studies, thyroid function tests, and antibodies of the paraneoplastic syndrome were unremarkable except for an HbA1c of 8.1% and hyperglycemia. Pure tone audiometry (PTA) showed bilateral severe hearing impairment (Figure 1).

Imaging examinations

Brain magnetic resonance imaging (MRI) was within normal limits (Figure 2A).

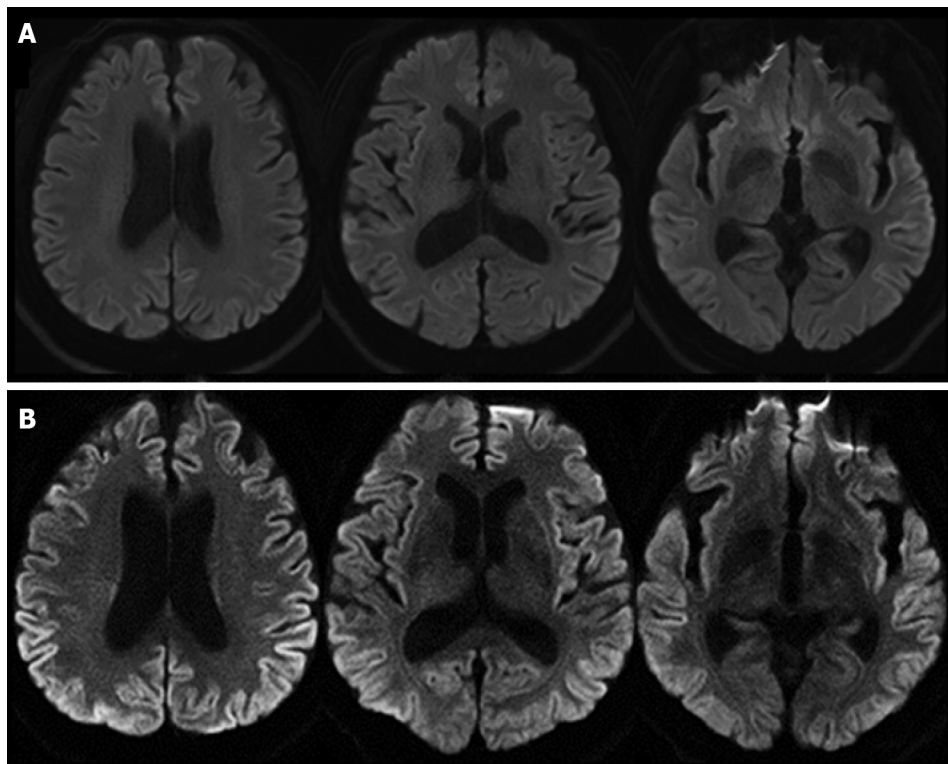
Further diagnostic work-up

Given his diagnosis of sudden sensory hearing loss, the patient received corticosteroid treatment (prednisolone 60 mg/d for 10 d and tapering) but it was ineffective. Two weeks later, however, he complained of aggravated gait impairment, word-finding difficulty, disorientation, and cognitive



DOI: 10.12998/wjcc.v10.i18.6333 Copyright ©The Author(s) 2022.

Figure 1 Pure tone audiometry. Pure tone audiometry revealed severe bilateral low- and high-frequency hearing loss.



DOI: 10.12998/wjcc.v10.i18.6333 Copyright ©The Author(s) 2022.

Figure 2 Findings of brain magnetic resonance imaging. A: The initial brain magnetic resonance imaging (MRI). The initial brain diffusion-weighted imaging was unremarkable; B: The follow-up brain MRI. The follow-up brain diffusion-weighted imaging showed high signal intensities in the bilateral frontal, temporal, parietal, and occipital cortices.

impairment. Repeat brain MRI showed high signal intensities in the frontal, temporal, parietal, and occipital cortices on diffusion-weighted imaging (Figure 2B). Cerebrospinal fluid (CSF) analysis revealed normal concentrations of protein and glucose without pleocytosis. However, the real-time quaking-induced conversion (RT-QuIC) assay was positive, and 14-3-3 protein was detected in the CSF by western blotting.

FINAL DIAGNOSIS

Considering all the data, we diagnosed probable sCJD. The amended diagnostic criteria added that the combination of cognitive decline, positive CSF RT-QuIC, and one or more typical CJD symptoms can draw the diagnosis of probable sCJD[3]. Because he had never undertaken neurosurgery dealing with a dura mater and the genetic analysis revealed that there was no mutation or polymorphism of the prion gene, we excluded the possibility of familial CJD or iatrogenic CJD. Moreover, our patient revealed a positive RT-QuIC test and met the criteria of probable sCJD.

TREATMENT

Because of the characteristics of sCJD, the intractable rapidly progressive dementia[1], he received conservative care.

OUTCOME AND FOLLOW-UP

The patient's symptoms rapidly progressed into akinetic mutism within only two months after the onset of bilateral hearing impairment.

DISCUSSION

This patient presented with an abrupt onset of bilateral hearing impairment and dizziness as the first manifestation of sCJD. Although he only complained of otologic symptoms and was diagnosed initially with bilateral sensorineural hearing loss, the patient then developed additional neurologic symptoms including cognitive decline and prominent gait imbalance, which rapidly progressed. The amended diagnostic criteria of sCJD area that the combination of positive CSF RT-QuIC and progressive cognitive impairment or any of typical CJD symptoms can draw the diagnosis of probable sCJD[3]. Our patient revealed a positive RT-QuIC test and met the criteria of probable sCJD. The possibilities of familial or iatrogenic CJD were excluded because there was no mutation or polymorphism of the prion gene and he had no history of epidemiological evidence. Although the etiology of sCJD has been unknown, many researchers assumed that the prion disease might be initiated by the stochastic misfolded cellular prion protein or mutations in the prion protein gene at ongoing neurogenesis areas[4].

Hearing impairment as an early symptom of sCJD has been described in a few reports[5,6]. Those patients were elderly, older than 65 years, and first complained of only suddenly developed bilateral hearing impairment and subjective unsteadiness. Our patient's hearing loss were also bilateral and unresponsive to steroid treatment. Postmortem studies in sCJD have revealed that the prion protein deposition in the brainstem is symmetrical and starts in the early stage of sCJD[7]. These neuropathologic characteristics account for the bilaterality of the hearing impairment in patients with sCJD.

The authors of a previous report conducted a brain MRI at the initial presentation, and it was within normal limit[5]. Our patient showed imaging findings that reflected his complaints and symptoms of sCJD. At his first visit when he complained of only hearing impairment and vague dizziness, the brain MRI was unremarkable. After other symptoms developed, however, repeat brain MRI revealed characteristic high signal intensities of the bilateral cerebral cortices, which were a clue for the diagnosis of sCJD.

Among the presenting symptoms of our patient, the dizziness was nonspecific and vague, but the hearing impairment was abrupt and very severe. Furthermore, the hearing difficulty was broad, from low to high frequency. When a patient with cognitive decline is suspected of having hearing difficulty, an appropriate evaluation is difficult because laboratory tests, such as pure tone audiometry, cannot be obtained without patient cooperation, and an accurate history of onset time and the pattern of the hearing impairment is needed. In sCJD, the most common presenting symptom is cognitive decline[3]. Thus, even if hearing impairment occurs in the early stage of sCJD, evaluations for the presence of hearing symptoms and otologic function under rapidly progressive cognitive decline are difficult. In our patient, however, the history of hearing impairment and the result of PTA were reliable because the patient did not complain of cognitive impairment at presentation.

CONCLUSION

The patient presented with sudden onset hearing impairment and dizziness, followed by progressive cognitive impairment and confusion. Repeat brain MRI revealed characteristic findings of sCJD, and the

RT-QuIC test was positive. For patients with abrupt bilateral hearing impairment, especially in the elderly, various differential diagnoses, including sCJD, should be considered. Moreover, when sCJD is suspected, close follow-up with thorough history taking and neurologic examinations and repeated workups that include brain diffusion-weighted imaging and CSF analysis will be helpful.

FOOTNOTES

Author contributions: Lee ES conceived and designed the study; Lee TK provided supervision; Lee ES and Lee collected the data; Lee SN wrote the first draft of the manuscript; Lee SA and Lee JD edited and contributed to critical revision; and All authors read and approved the final version of the manuscript for submission.

Supported by National Research Foundation of Korea, No. 2019R1C1C1006539.

Informed consent statement: The authors declare that this single case report has been performed in accordance with the ethical standards laid down in the 1964 Declaration of Helsinki.

Conflict-of-interest statement: The authors declare that they have no conflict of interest.

CARE Checklist (2016) statement: The authors have read the CARE Checklist (2016), and the manuscript was prepared and revised according to the CARE Checklist (2016).

Open-Access: This article is an open-access article that was selected by an in-house editor and fully peer-reviewed by external reviewers. It is distributed in accordance with the Creative Commons Attribution NonCommercial (CC BY-NC 4.0) license, which permits others to distribute, remix, adapt, build upon this work non-commercially, and license their derivative works on different terms, provided the original work is properly cited and the use is non-commercial. See: <https://creativecommons.org/licenses/by-nc/4.0/>

Country/Territory of origin: South Korea

ORCID number: Seunghee Na 0000-0001-8578-8578; Se A Lee 0000-0002-6263-1903; Jong Dae Lee 0000-0003-2866-9841; Eek-Sung Lee 0000-0003-3517-8207; Tae-Kyeong Lee 0000-0001-6913-4689.

Corresponding Author's Membership in Professional Societies: Korean Neurological Association.

S-Editor: Ma YJ

L-Editor: A

P-Editor: Ma YJ

REFERENCES

- Collins SJ, Lawson VA, Masters CL. Transmissible spongiform encephalopathies. *Lancet* 2004; **363**: 51-61 [PMID: 14723996 DOI: 10.1016/S0140-6736(03)15171-9]
- Rabinovici GD, Wang PN, Levin J, Cook L, Pravdin M, Davis J, DeArmond SJ, Barbaro NM, Martindale J, Miller BL, Geschwind MD. First symptom in sporadic Creutzfeldt-Jakob disease. *Neurology* 2006; **66**: 286-287 [PMID: 16434680 DOI: 10.1212/01.wnl.0000196440.00297.67]
- Hermann P, Laux M, Glatzel M, Matschke J, Knipper T, Goebel S, Treig J, Schulz-Schaeffer W, Cramm M, Schmitz M, Zerr I. Validation and utilization of amended diagnostic criteria in Creutzfeldt-Jakob disease surveillance. *Neurology* 2018; **91**: e331-e338 [PMID: 29934424 DOI: 10.1212/WNL.0000000000005860]
- Iacono D, Ferrari S, Gelati M, Zanusso G, Mariotto S, Monaco S. Sporadic Creutzfeldt-Jakob Disease: Prion Pathology in Medulla Oblongata-Possible Routes of Infection and Host Susceptibility. *Biomed Res Int* 2015; **2015**: 396791 [PMID: 26457299 DOI: 10.1155/2015/396791]
- Bigelow DC, Eisen MD, Yen DM, Saull SC, Solomon D, Schmidt DE. Otolaryngological manifestations of Creutzfeldt-Jakob disease. *Arch Otolaryngol Head Neck Surg* 1998; **124**: 707-710 [PMID: 9639484 DOI: 10.1001/archotol.124.6.707]
- Salazar R, Cerghet M, Ramachandran V. Bilateral hearing loss heralding sporadic Creutzfeldt-Jakob disease: a case report and literature review. *Otol Neurotol* 2014; **35**: 1327-1329 [PMID: 25122149 DOI: 10.1097/MAO.0000000000000485]
- Iwasaki Y, Hashizume Y, Yoshida M, Kitamoto T, Sobue G. Neuropathologic characteristics of brainstem lesions in sporadic Creutzfeldt-Jakob disease. *Acta Neuropathol* 2005; **109**: 557-566 [PMID: 15933870 DOI: 10.1007/s00401-005-0981-0]



Published by **Baishideng Publishing Group Inc**
7041 Koll Center Parkway, Suite 160, Pleasanton, CA 94566, USA

Telephone: +1-925-3991568

E-mail: bpgoffice@wjgnet.com

Help Desk: <https://www.f6publishing.com/helpdesk>

<https://www.wjgnet.com>

