

World Journal of *Clinical Cases*

World J Clin Cases 2022 July 6; 10(19): 6341-6758



Contents

Thrice Monthly Volume 10 Number 19 July 6, 2022

MINIREVIEWS

- 6341** Review of clinical characteristics, immune responses and regulatory mechanisms of hepatitis E-associated liver failure
Chen C, Zhang SY, Chen L
- 6349** Current guidelines for *Helicobacter pylori* treatment in East Asia 2022: Differences among China, Japan, and South Korea
Cho JH, Jin SY
- 6360** Review of epidermal growth factor receptor-tyrosine kinase inhibitors administration to non-small-cell lung cancer patients undergoing hemodialysis
Lan CC, Hsieh PC, Huang CY, Yang MC, Su WL, Wu CW, Wu YK

ORIGINAL ARTICLE

Case Control Study

- 6370** Pregnancy-related psychopathology: A comparison between pre-COVID-19 and COVID-19-related social restriction periods
Chieffo D, Avallone C, Serio A, Kotzalidis GD, Balocchi M, De Luca I, Hirsch D, Gonzalez del Castillo A, Lanzotti P, Marano G, Rinaldi L, Lanzone A, Mercuri E, Mazza M, Sani G
- 6385** Intestinal mucosal barrier in functional constipation: Does it change?
Wang JK, Wei W, Zhao DY, Wang HF, Zhang YL, Lei JP, Yao SK

Retrospective Cohort Study

- 6399** Identification of risk factors for surgical site infection after type II and type III tibial pilon fracture surgery
Hu H, Zhang J, Xie XG, Dai YK, Huang X

Retrospective Study

- 6406** Total knee arthroplasty in Ranawat II valgus deformity with enlarged femoral valgus cut angle: A new technique to achieve balanced gap
Lv SJ, Wang XJ, Huang JF, Mao Q, He BJ, Tong PJ
- 6417** Preliminary evidence in treatment of eosinophilic gastroenteritis in children: A case series
Chen Y, Sun M
- 6428** Self-made wire loop snare successfully treats gastric persimmon stone under endoscopy
Xu W, Liu XB, Li SB, Deng WP, Tong Q
- 6437** Neoadjuvant transcatheter arterial chemoembolization and systemic chemotherapy for the treatment of undifferentiated embryonal sarcoma of the liver in children
He M, Cai JB, Lai C, Mao JQ, Xiong JN, Guan ZH, Li LJ, Shu Q, Ying MD, Wang JH

- 6446** Effect of cold snare polypectomy for small colorectal polyps

Meng QQ, Rao M, Gao PJ

- 6456** Field evaluation of COVID-19 rapid antigen test: Are rapid antigen tests less reliable among the elderly?

Tabain I, Cucevic D, Skreb N, Mrzljak A, Ferencak I, Hruskar Z, Misic A, Kuzle J, Skoda AM, Jankovic H, Vilibic-Cavlek T

Observational Study

- 6464** Tracheobronchial intubation using flexible bronchoscopy in children with Pierre Robin sequence: Nursing considerations for complications

Ye YL, Zhang CF, Xu LZ, Fan HF, Peng JZ, Lu G, Hu XY

- 6472** Family relationship of nurses in COVID-19 pandemic: A qualitative study

Çelik MY, Kiliç M

META-ANALYSIS

- 6483** Diagnostic accuracy of ≥ 16 -slice spiral computed tomography for local staging of colon cancer: A systematic review and meta-analysis

Liu D, Sun LM, Liang JH, Song L, Liu XP

CASE REPORT

- 6496** Delayed-onset endophthalmitis associated with *Achromobacter* species developed in acute form several months after cataract surgery: Three case reports

Kim TH, Lee SJ, Nam KY

- 6501** Sustained dialysis with misplaced peritoneal dialysis catheter outside peritoneum: A case report

Shen QQ, Behera TR, Chen LL, Attia D, Han F

- 6507** Arteriovenous thrombotic events in a patient with advanced lung cancer following bevacizumab plus chemotherapy: A case report

Kong Y, Xu XC, Hong L

- 6514** Endoscopic ultrasound radiofrequency ablation of pancreatic insulinoma in elderly patients: Three case reports

Rossi G, Petrone MC, Capurso G, Partelli S, Falconi M, Arcidiacono PG

- 6520** Acute choroidal involvement in lupus nephritis: A case report and review of literature

Yao Y, Wang HX, Liu LW, Ding YL, Sheng JE, Deng XH, Liu B

- 6529** Triple A syndrome-related achalasia treated by per-oral endoscopic myotomy: Three case reports

Liu FC, Feng YL, Yang AM, Guo T

- 6536** Choroidal thickening with serous retinal detachment in BRAF/MEK inhibitor-induced uveitis: A case report

Kiraly P, Groznik AL, Valentinčič NV, Mekjavić PJ, Urbančič M, Ocvirk J, Mesti T

- 6543** Esophageal granular cell tumor: A case report

Chen YL, Zhou J, Yu HL

- 6548** Hem-o-lok clip migration to the common bile duct after laparoscopic common bile duct exploration: A case report
Liu DR, Wu JH, Shi JT, Zhu HB, Li C
- 6555** Chidamide and sintilimab combination in diffuse large B-cell lymphoma progressing after chimeric antigen receptor T therapy
Hao YY, Chen PP, Yuan XG, Zhao AQ, Liang Y, Liu H, Qian WB
- 6563** Relapsing polychondritis with isolated tracheobronchial involvement complicated with Sjogren's syndrome: A case report
Chen JY, Li XY, Zong C
- 6571** Acute methanol poisoning with bilateral diffuse cerebral hemorrhage: A case report
Li J, Feng ZJ, Liu L, Ma YJ
- 6580** Immunoabsorption therapy for Klinefelter syndrome with antiphospholipid syndrome in a patient: A case report
Song Y, Xiao YZ, Wang C, Du R
- 6587** Roxadustat for treatment of anemia in a cancer patient with end-stage renal disease: A case report
Zhou QQ, Li J, Liu B, Wang CL
- 6595** Imaging-based diagnosis for extraskeletal Ewing sarcoma in pediatrics: A case report
Chen ZH, Guo HQ, Chen JJ, Zhang Y, Zhao L
- 6602** Unusual course of congenital complete heart block in an adult: A case report
Su LN, Wu MY, Cui YX, Lee CY, Song JX, Chen H
- 6609** Penile metastasis from rectal carcinoma: A case report
Sun JJ, Zhang SY, Tian JJ, Jin BY
- 6617** Isolated cryptococcal osteomyelitis of the ulna in an immunocompetent patient: A case report
Ma JL, Liao L, Wan T, Yang FC
- 6626** Magnetic resonance imaging features of intrahepatic extramedullary hematopoiesis: Three case reports
Luo M, Chen JW, Xie CM
- 6636** Giant retroperitoneal liposarcoma treated with radical conservative surgery: A case report and review of literature
Lieto E, Cardella F, Erario S, Del Sorbo G, Reginelli A, Galizia G, Urraro F, Panarese I, Auricchio A
- 6647** Transplanted kidney loss during colorectal cancer chemotherapy: A case report
Pośpiech M, Kolonko A, Nieszporek T, Kozak S, Kozaczka A, Karkoszka H, Winder M, Chudek J
- 6656** Massive gastrointestinal bleeding after endoscopic rubber band ligation of internal hemorrhoids: A case report
Jiang YD, Liu Y, Wu JD, Li GP, Liu J, Hou XH, Song J

- 6664** Mills' syndrome is a unique entity of upper motor neuron disease with N-shaped progression: Three case reports
Zhang ZY, Ouyang ZY, Zhao GH, Fang JJ
- 6672** Entire process of electrocardiogram recording of Wellens syndrome: A case report
Tang N, Li YH, Kang L, Li R, Chu QM
- 6679** Retroperitoneal tumor finally diagnosed as a bronchogenic cyst: A case report and review of literature
Gong YY, Qian X, Liang B, Jiang MD, Liu J, Tao X, Luo J, Liu HJ, Feng YG
- 6688** Successful treatment of Morbihan disease with total glucosides of paeony: A case report
Zhou LF, Lu R
- 6695** Ant sting-induced whole-body pustules in an inebriated male: A case report
Chen SQ, Yang T, Lan LF, Chen XM, Huang DB, Zeng ZL, Ye XY, Wan CL, Li LN
- 6702** Plastic surgery for giant metastatic endometrioid adenocarcinoma in the abdominal wall: A case report and review of literature
Wang JY, Wang ZQ, Liang SC, Li GX, Shi JL, Wang JL
- 6710** Delayed-release oral mesalamine tablet mimicking a small jejunal gastrointestinal stromal tumor: A case report
Frosio F, Rausa E, Marra P, Boutron-Ruault MC, Lucianetti A
- 6716** Concurrent alcoholic cirrhosis and malignant peritoneal mesothelioma in a patient: A case report
Liu L, Zhu XY, Zong WJ, Chu CL, Zhu JY, Shen XJ
- 6722** Two smoking-related lesions in the same pulmonary lobe of squamous cell carcinoma and pulmonary Langerhans cell histiocytosis: A case report
Gencer A, Ozcibik G, Karakas FG, Sarbay I, Batur S, Borekci S, Turna A
- 6728** Proprotein convertase subtilisin/kexin type 9 inhibitor non responses in an adult with a history of coronary revascularization: A case report
Yang L, Xiao YY, Shao L, Ouyang CS, Hu Y, Li B, Lei LF, Wang H
- 6736** Multimodal imaging study of lipemia retinalis with diabetic retinopathy: A case report
Zhang SJ, Yan ZY, Yuan LF, Wang YH, Wang LF
- 6744** Primary squamous cell carcinoma of the liver: A case report
Kang LM, Yu DP, Zheng Y, Zhou YH
- 6750** Tumor-to-tumor metastasis of clear cell renal cell carcinoma to contralateral synchronous pheochromocytoma: A case report
Wen HY, Hou J, Zeng H, Zhou Q, Chen N

ABOUT COVER

Editorial Board Member of *World Journal of Clinical Cases*, Abdulqadir Jeprel Naswhan, MSc, RN, Director, Research Scientist, Senior Lecturer, Senior Researcher, Nursing for Education and Practice Development, Hamad Medical Corporation, Doha 576214, Qatar. anashwan@hamad.qa

AIMS AND SCOPE

The primary aim of *World Journal of Clinical Cases* (WJCC, *World J Clin Cases*) is to provide scholars and readers from various fields of clinical medicine with a platform to publish high-quality clinical research articles and communicate their research findings online.

WJCC mainly publishes articles reporting research results and findings obtained in the field of clinical medicine and covering a wide range of topics, including case control studies, retrospective cohort studies, retrospective studies, clinical trials studies, observational studies, prospective studies, randomized controlled trials, randomized clinical trials, systematic reviews, meta-analysis, and case reports.

INDEXING/ABSTRACTING

The WJCC is now indexed in Science Citation Index Expanded (also known as SciSearch®), Journal Citation Reports/Science Edition, Scopus, PubMed, and PubMed Central. The 2021 Edition of Journal Citation Reports® cites the 2020 impact factor (IF) for WJCC as 1.337; IF without journal self cites: 1.301; 5-year IF: 1.742; Journal Citation Indicator: 0.33; Ranking: 119 among 169 journals in medicine, general and internal; and Quartile category: Q3. The WJCC's CiteScore for 2020 is 0.8 and Scopus CiteScore rank 2020: General Medicine is 493/793.

RESPONSIBLE EDITORS FOR THIS ISSUE

Production Editor: Xu Guo; Production Department Director: Xiang Li; Editorial Office Director: Jin-Lai Wang.

NAME OF JOURNAL

World Journal of Clinical Cases

ISSN

ISSN 2307-8960 (online)

LAUNCH DATE

April 16, 2013

FREQUENCY

Thrice Monthly

EDITORS-IN-CHIEF

Bao-Gan Peng, Jerzy Tadeusz Chudek, George Kontogeorgos, Maurizio Serati, Ja Hyeon Ku

EDITORIAL BOARD MEMBERS

<https://www.wjgnet.com/2307-8960/editorialboard.htm>

PUBLICATION DATE

July 6, 2022

COPYRIGHT

© 2022 Baishideng Publishing Group Inc

INSTRUCTIONS TO AUTHORS

<https://www.wjgnet.com/bpg/gerinfo/204>

GUIDELINES FOR ETHICS DOCUMENTS

<https://www.wjgnet.com/bpg/GerInfo/287>

GUIDELINES FOR NON-NATIVE SPEAKERS OF ENGLISH

<https://www.wjgnet.com/bpg/gerinfo/240>

PUBLICATION ETHICS

<https://www.wjgnet.com/bpg/GerInfo/288>

PUBLICATION MISCONDUCT

<https://www.wjgnet.com/bpg/gerinfo/208>

ARTICLE PROCESSING CHARGE

<https://www.wjgnet.com/bpg/gerinfo/242>

STEPS FOR SUBMITTING MANUSCRIPTS

<https://www.wjgnet.com/bpg/GerInfo/239>

ONLINE SUBMISSION

<https://www.f6publishing.com>



Review of epidermal growth factor receptor-tyrosine kinase inhibitors administration to non-small-cell lung cancer patients undergoing hemodialysis

Chou-Chin Lan, Po-Chun Hsieh, Chun-Yao Huang, Mei-Chen Yang, Wen-Lin Su, Chih-Wei Wu, Yao-Kuang Wu

Specialty type: Critical care medicine

Provenance and peer review:

Unsolicited article; Externally peer reviewed.

Peer-review model: Single blind

Peer-review report's scientific quality classification

Grade A (Excellent): A

Grade B (Very good): B

Grade C (Good): 0

Grade D (Fair): 0

Grade E (Poor): 0

P-Reviewer: Hu QD, China; Rostoker G, France

Received: January 23, 2022

Peer-review started: January 23, 2022

First decision: March 23, 2022

Revised: April 1, 2022

Accepted: May 12, 2022

Article in press: May 12, 2022

Published online: July 6, 2022



Chou-Chin Lan, Chun-Yao Huang, Mei-Chen Yang, Wen-Lin Su, Chih-Wei Wu, Yao-Kuang Wu, Division of Pulmonary Medicine, Taipei Tzu Chi Hospital, Buddhist Tzu Chi Medical Foundation, New Taipei City 23142, Taiwan

Po-Chun Hsieh, Department of Chinese Medicine, Taipei Tzu Chi Hospital, Buddhist Tzu Chi Medical Foundation, New Taipei City 23142, Taiwan

Corresponding author: Yao-Kuang Wu, MD, Division of Pulmonary Medicine, Taipei Tzu Chi Hospital, Buddhist Tzu Chi Medical Foundation, New Taipei City 23142, Taiwan. drbfci@yahoo.com.tw

Abstract

Non-small-cell lung cancer (NSCLC) causes significant mortality worldwide. Patients with chronic renal failure have an increased risk of developing lung cancer. NSCLC Patients with chronic renal failure undergoing hemodialysis (HD) often exhibit poor performance, and chemotherapy is generally contraindicated. Oral epidermal growth factor receptor (EGFR)-tyrosine kinase inhibitors (TKIs) are effective treatment agents for NSCLC patients. However, the benefits and adverse effects of EGFR-TKIs in NSCLC undergoing HD are known. There are no clinical studies on the effects of EGFR-TKIs on NSCLC patients undergoing HD. We reviewed all previous case reports about EGFR-TKIs in NSCLC patients undergoing HD. It is difficult to design studies about the effects of EGFR-TKIs in patients undergoing HD, and this review is quite important. EGFR-TKIs are well tolerated in patients undergoing HD. The main routes of elimination of EGFR-TKIs are metabolism *via* the liver, and renal elimination is minor. The recommended doses and pharmacokinetics of these EGFR-TKIs for patients undergoing HD are similar to those for patients with normal renal function. The plasma protein binding of EGFR-TKIs is very high, and it is not necessary to adjust the dose after HD. In conclusion, EGFR-TKIs are effective and well tolerated in patients undergoing HD.

Key Words: Hemodialysis; Non-small-cell lung cancer; Epidermal growth factor receptor; Tyrosine-kinase inhibitors

©The Author(s) 2022. Published by Baishideng Publishing Group Inc. All rights reserved.

Core Tip: Lung cancer causes significant mortality worldwide. Patients with chronic renal failure increase the difficulty of treatment. Oral epidermal growth factor receptor (EGFR)-tyrosine kinase inhibitors (TKIs) are effective treatment agents for non-small-cell lung cancer (NSCLC) patients. According to this review, EGFR-TKIs are suitable for treating NSCLC patients undergoing hemodialysis (HD) owing to their good response rates and tolerance. The main routes of elimination of EGFR-TKIs are *via* the liver and excretion *via* feces. The recommended doses and pharmacokinetics of EGFR-TKIs for patients undergoing HD are similar to those with normal renal function. The plasma protein binding of EGFR-TKIs is high, and it is not necessary to adjust the dose after HD.

Citation: Lan CC, Hsieh PC, Huang CY, Yang MC, Su WL, Wu CW, Wu YK. Review of epidermal growth factor receptor-tyrosine kinase inhibitors administration to non-small-cell lung cancer patients undergoing hemodialysis. *World J Clin Cases* 2022; 10(19): 6360-6369

URL: <https://www.wjgnet.com/2307-8960/full/v10/i19/6360.htm>

DOI: <https://dx.doi.org/10.12998/wjcc.v10.i19.6360>

INTRODUCTION

Impact of lung cancers

Lung cancer causes significant mortality worldwide[1]. Lung cancer is classified into small-cell lung cancer (SCLC) and non-small-cell lung cancer (NSCLC), with NSCLC accounting for 80%–85% of lung cancer cases and adenocarcinoma accounting for 80% of NSCLC cases[1]. Despite the development of modern medicines, the outcomes of lung cancer remain poor[1]. The treatment of NSCLC depends strictly on the disease stage, and 80% of NSCLC patients are diagnosed at advanced (IIIB/IV) stages[1]. Since the lungs are often diagnosed at advanced stages and are unresectable, targeted therapy and chemotherapy are the major treatments for these patients[1].

In general, chronic renal failure (CRF) patients undergoing hemodialysis (HD) exhibit a higher incidence of cancers, including lung cancer[2]. The risk factors for developing cancers include smoking, air pollution, genetic susceptibility, and occupational exposure[1]. It is suspected that the reasons for the higher incidence of cancers in patients undergoing HD are further related to weakened immunity, chronic inflammation, malnutrition, and impaired DNA repair[2]. CRF increases the incidence of cancers as well as the difficulty in treating it. Therefore, the treatment of cancers in such patients is important.

For patients with cancer and CRF, who often exhibit poor performance, chemotherapy is generally contraindicated owing to its greater adverse effects (AEs). Moreover, chemotherapeutic drugs, such as cisplatin, are regarded as nephrotoxic agents and are not suitable for the treatment of CRF patients. Cisplatin is one of the most widely used chemotherapeutic agent for cancers. However, its clinical application is limited by its adverse effects, such as bone marrow suppression leading to hematopoietic abnormalities[3]. An increased incidence of adverse reactions to cisplatin has been reported in patients with renal insufficiency[4]. Therefore, the management of anti-cancer treatments for CRF patients undergoing HD is challenging.

Oral epidermal growth factor receptor (EGFR)-tyrosine kinase inhibitors (TKIs) are promising treatment agents for NSCLC patients. EGFR is a transmembrane receptor on the surface of epithelial cells and is considered an important molecular target in cancer treatment. EGFR gene mutation is a predictor of EGFR-TKI efficacy. EGFR-gene-activating mutations occur in 50%–60% of Asian and 10%–20% of Caucasian subjects with NSCLC[5]. Common mutations, including deletions in exon 19 and substitution of L858R in exon 21, comprise approximately 85% of EGFR mutations[5]. Rare mutations (about 15%) include point mutations, insertions, and deletions within exons 18–25 of the EGFR gene[5].

EGFR-TKIs exert low side effects and less impact on kidney function, and patients exhibit better tolerability for them[6]. EGFR-TKIs, including gefitinib and erlotinib (first-generation), afatinib (second-generation), and osimertinib (third-generation), have shown significant benefits, with improved overall response rates (ORRs), longer progression-free survival (PFS), and better overall survival rate (OS) in patients with NSCLC harboring EGFR mutations[6]. Lung cancer patients undergoing HD sometimes exhibit poor performance; EGFR-TKIs are often a treatment choice for such patients. Since physicians worry about AEs and nephrotoxicity of chemotherapy agents in patients undergoing HD, EGFR-TKIs are often an optional strategy for such patients. However, most clinical trials have excluded patients undergoing HD, and the applicability of EGFR-TKIs for such patients has not been studied. Therefore, we aimed to review the benefits, AEs, and pharmacokinetics of EGFR-TKIs in patients undergoing HD.

GEFITINIB

Clinical benefits of gefitinib

Gefitinib was approved for metastatic NSCLC patients with sensitive EGFR mutations in July 2015[7]. It has been demonstrated that using gefitinib as the first line of treatment for NSCLC with sensitive EGFR mutations results in an ORR of 62%–71%, PFS of 8–13 mo, and OS of 21–30 mo[7]. The common AEs are skin rash, acne, and diarrhea[7]. Most AEs resolve on their own or after medical treatment. Elevation in liver function test parameters has been observed, but these elevations are often not accompanied by any symptoms. The incidence of rare AEs, such as interstitial lung disease (ILD), is approximately 1%[7].

Clinical benefits of gefitinib in patients undergoing HD

Bersanelli *et al*[8] reported a 60-year-old female Caucasian non-smoker undergoing HD with right lung adenocarcinoma with mediastinal lymph nodes and bone metastasis. Her initial ECOG PS score was 0, and she received radiation therapy on the spine and was administered gemcitabine and cisplatin. Owing to progression of bone metastasis after three cycles of gemcitabine and cisplatin, second-line treatment with gefitinib was initiated. Gefitinib induced a good response of the disease to treatment for 7 years without complications. Del Conte *et al*[9] reported a 70-year-old male non-smoker undergoing HD with right middle lobe lung adenocarcinoma. The patient underwent right middle lobe lobectomy for pT1N0M0 NSCLC (stage IA). After 3.5 years from surgery, recurrent lung adenocarcinoma with deletion of 15 nucleotides of exon 19 was found. He received gefitinib and exhibited only a grade 1 cutaneous rash. After 2 years of gefitinib treatment, he was still in complete remission without serious AEs[9]. Bersanelli *et al*[8] and Del Conte *et al*[9] showed that gefitinib was effective and well tolerated in patients undergoing HD.

Pharmacokinetics of gefitinib in patients with normal renal function

Most gefitinib is metabolized by the liver and excreted *via* feces (86%), and a small portion (7%) is excreted *via* urine (Figure 1A)[10]. Approximately 90% of gefitinib binds to plasma proteins in the blood [10]. The half-life of gefitinib is 41 h, and steady-state plasma concentrations are attained by day 7–10 [11]. The maximum concentration (C_{max}) is attained 5 h (3–7 h) after oral dosing, the median C_{max} is 377 (168–781) ng/mL, the area under the curve of the plasma concentration from 0 to 24 h (AUC_{0-24}) is 4893 (698–13991) ng·hr/mL, and the trough concentration (C_{trough}) is 410 (115–1021) ng/mL[11].

Pharmacokinetics of gefitinib in patients undergoing HD

There are only two case reports on the pharmacokinetics of gefitinib in patients undergoing HD. Shinagawa *et al*[12] performed the first pharmacokinetic analysis of gefitinib in a 58-year-old female non-smoker undergoing HD for 8 years. She developed lung adenocarcinoma (pT1N0M0, stage IA) and underwent left lower lobectomy (LLL)[12]. Two years later, she had recurrent lung cancer, which had metastasized to the left subclavian lymph node, and meningitis. The EGFR mutation showed a deletion of 15 nucleotides in exon 19 in tumor tissues. She was administered 250 mg gefitinib daily. The C_{max} and C_{trough} of gefitinib were 410.4 and 102.7 ng/mL, respectively. The plasma concentrations were 308.3 and 272.2 ng/mL before and after HD (88% maintained throughout HD), respectively[12]. There were no serious AEs following gefitinib administration[12]. Luo *et al*[13] reported a 75-year-old female non-smoker with lung adenocarcinoma (pT1N0M0, stage IA) who underwent right lower lobectomy. Nine years later, she underwent HD due to hypertension. However, the lung cancer relapsed with multiple nodules in both lungs. EGFR mutations in the tumor tissue revealed an L858R mutation in exon 21. She was then administered 250 mg gefitinib daily. The C_{max} was 456 and 463 ng/mL on non-HD and HD days, respectively. The C_{trough} was 386 ng/mL. The plasma concentrations were 376 and 463 ng/mL before and after HD, respectively. The initial response to gefitinib was a decrease in tumor size, but the tumor increased in size after 8 mo of treatment. No severe AEs were reported after gefitinib administration.

The data on the pharmacokinetics of gefitinib in patients undergoing HD and normal renal function (NRF) are shown in Figure 2. These data revealed that the pharmacokinetics of gefitinib in patients undergoing HD were similar to subjects with NRF[12,13]. Since 90% of gefitinib is bound to plasma proteins[10], it was rational that 90% of gefitinib was retained in the blood after HD. In addition, these patients showed a good response to gefitinib and did not have elevated AEs[12,13].

ERLOTINIB

Clinical benefits of erlotinib

Erlotinib is a reversible EGFR-TKI that was approved in 2004 for patients harboring EGFR exon 21 L858R mutations and exon 19 deletion[6]. Previous studies using erlotinib as the first line of treatment for NSCLC with sensitive EGFR gene mutations showed an ORR of 58%–83%, PFS of 9.7–13 mo, and OS of 23–33 mo[14]. Common AEs included skin rash, diarrhea, nausea, anorexia, dermatitis acneiform,

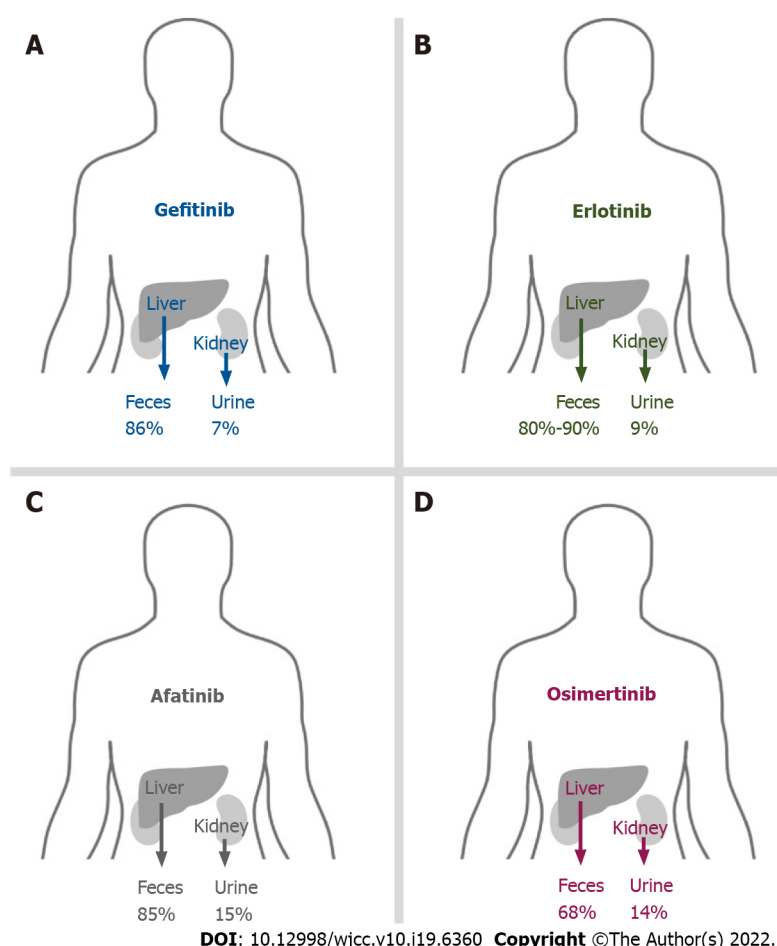


Figure 1 Main routines of elimination of epidermal growth factor receptor-tyrosine kinase inhibitors. A: 86% of gefitinib is metabolized by the liver and excreted *via* feces; B: 80%-90% of erlotinib is metabolized by the liver and excreted *via* feces; C: 85% of afatinib is metabolized by the liver and excreted *via* feces; D: 68% of osimertinib is metabolized by the liver and excreted *via* feces.

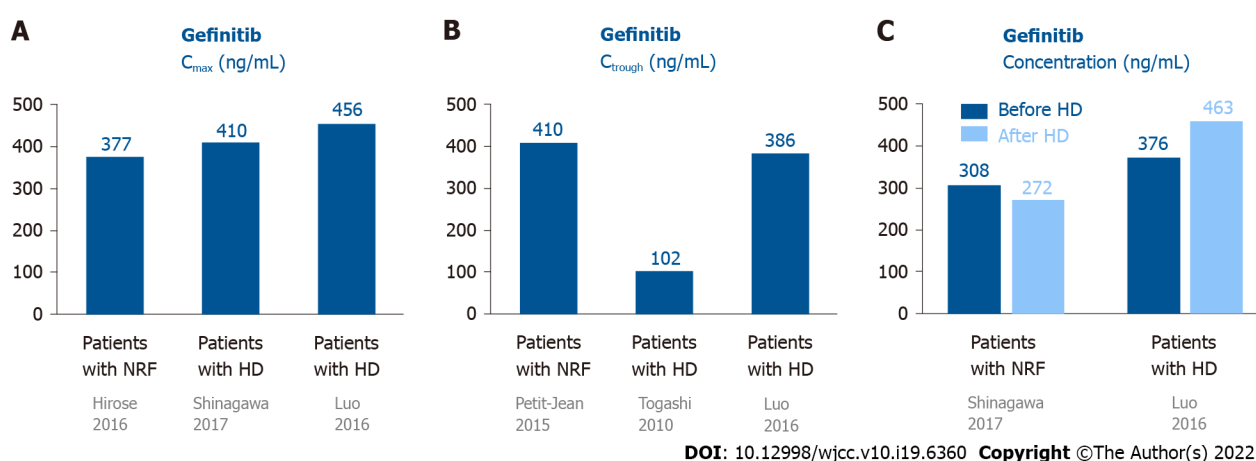


Figure 2 Pharmacokinetics of gefitinib in patients undergoing hemodialysis and those with normal renal function. A: The C_{max} of gefitinib in patients undergoing HD was similar to subjects with NRF; B: One patient showed the C_{trough} of gefitinib was 410 ng/mL. The two patients undergoing HD showed the C_{trough} of gefitinib was 102-386 ng/mL; C: The plasma concentration of gefitinib were similar in patients before and after HD. C_{max} : Maximum concentration; C_{trough} : Trough concentration; HD: Hemodialysis; NRF: Normal renal function.

fatigue, anemia, and ILD[14]. However, grade 3 or 4 AEs rarely occurred in subjects upon administration of erlotinib[6].

Pharmacokinetics of erlotinib in patients with NRF

Most erlotinib is metabolized by the liver and excreted *via* feces (80%–90%), and a small portion (9%) is excreted *via* urine (Figure 1B)[15]. Approximately 95% of erlotinib is bound to plasma proteins[15]. The half-life of erlotinib is 21.86 ± 28.35 h, and steady-state concentrations in plasma are attained by day 8–10[16]. The C_{\max} is attained 3.69 ± 3.21 h after dosing, and the median C_{\max} is 2290 ± 840 ng/mL. The median AUC_{0-24} is 35760 ± 15720 ng · hr/mL[16].

Pharmacokinetics of erlotinib in patients undergoing HD

Togashi *et al*[17] reported three NSCLC patients undergoing HD who were treated with erlotinib. Case 1 was a 74-year-old male ex-smoker undergoing HD for 5 years, who had lung adenocarcinoma (cT1N3M1, stage IV) without any EGFR mutations. Case 2 was a 74-year-old female non-smoker undergoing HD for 3 years, who had adenocarcinoma (cT2N0M0, stage IB) without any EGFR mutations. Initially, she received irradiation therapy with a dose of 54 Gy for the tumor. The tumor enlarged, with invasion to the chest wall, and metastasized to the hilar lymph node (cT3N1M0, IIIA). Case 3 was a 69-year-old male current smoker undergoing HD for 1 year, with lung squamous cell carcinoma (cT2N1M1, stage IV). All 3 patients were administered 150 mg erlotinib daily. Pharmacokinetic analyses of erlotinib were conducted on the first day (non-HD), eighth day (non-HD), and ninth day (HD) after administration[17]. For these 3 patients undergoing HD, the C_{\max} , C_{trough} , and AUC_{0-24} on day 1 were 960 ± 287 ng/mL, 338 ± 116 ng/mL, and 13944 ± 4590 ng · hr/mL, respectively. On day 8 without HD, the C_{\max} , C_{trough} , and AUC_{0-24} were 1638 ± 206 ng/mL, 494 ± 336 ng/mL, and 23285 ± 5338 ng · hr/mL, respectively. On day 9 (HD day), the C_{\max} was 1633 ± 338 ng/mL. The plasma concentrations of erlotinib before and after HD were 1465 ± 350 and 1360 ± 375 ng/mL, respectively. The pharmacokinetic parameters on the ninth day were similar to those on the eighth day, indicating that erlotinib was hardly eliminated by HD. In addition, the data of patients undergoing HD were similar to subjects with NRF. There were no serious AEs in these cases.

The data on the pharmacokinetics of erlotinib in patients undergoing HD and subjects with NRF are shown in Figure 3. These data suggested that the pharmacokinetics of erlotinib in patients undergoing HD were similar to subjects with NRF[16,17]. Since 95% of erlotinib is bound to plasma proteins[15], it was rational that most erlotinib was retained in the plasma after HD.

AFATINIB**Clinical benefits of afatinib**

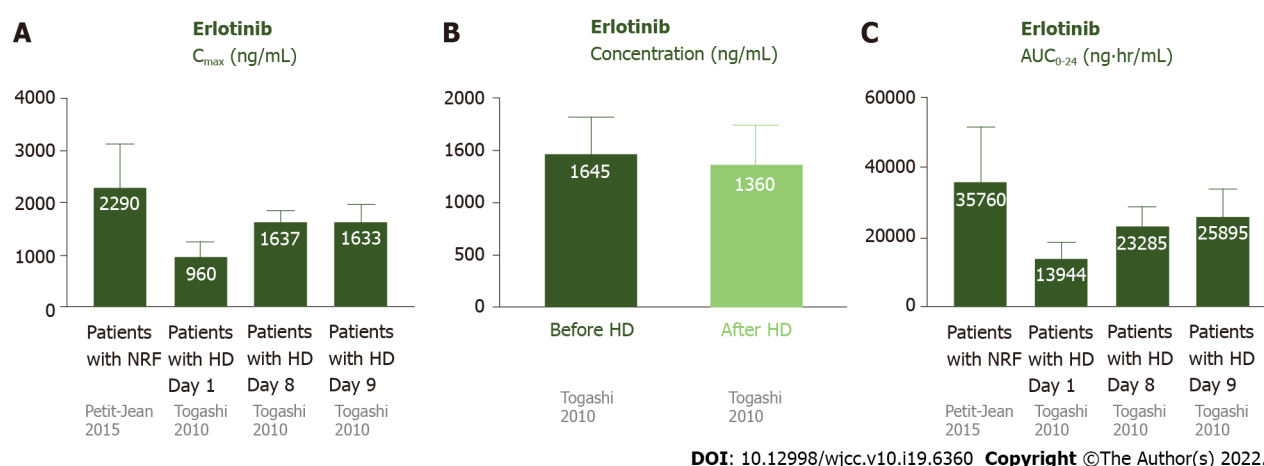
Afatinib is an irreversible covalent inhibitor of the Erb-B receptor tyrosine kinase family, including EGFR, Erb-B2 receptor tyrosine kinase 2/human epidermal growth factor receptor 2, and Erb-B4 receptor tyrosine kinase 4/human epidermal growth factor receptor 4[18]. It was approved by the Food and Drug Administration in 2013 for NSCLC with exon 21 L858R substitutions and exon 19 deletions[18]. Recent studies suggested that afatinib is effective against other uncommon mutations, such as L861Q in exon 21 and G719X in exon 18, and it was therefore approved by the Food and Drug Administration in 2018 for these uncommon EGFR mutations[18]. Previous studies using afatinib as the first line of treatment for NSCLC with sensitive EGFR gene mutations showed an ORR of 70%–81.8%, PFS of 13.4–15.2 mo, and OS of 27.9–49 mo[18]. The commonly reported AEs were diarrhea, skin rash, paronychia, mucosal inflammation, dry skin, stomatitis, skin fissures, nausea, dermatitis acneiform, and conjunctivitis[18]. Most AEs were of grade 1–2, and serious AEs were uncommon. However, serious AEs are more frequently reported for afatinib than for gefitinib and erlotinib[18].

Pharmacokinetics of afatinib in patients with NRF

Most afatinib is excreted through feces (85%), and a small amount (15%) is excreted *via* urine (Figure 1C)[19]. Approximately 95% of afatinib is bound to plasma proteins[20]. The half-life periods for 30 and 40 mg afatinib are 21.3 and 26.9 h, respectively[19]. Steady-state plasma concentrations are attained in approximately 8 d[19]. The C_{\max} is attained approximately 2–5 h after administration[20]. For daily administration of 30 mg afatinib, the median C_{\max} , C_{trough} , and AUC_{0-24} are 16.3 ng/mL, 15.1 ng/mL (8.1–38.1 ng/mL), and 189 ng · hr/mL, respectively[21,22]. For daily administration of 40 mg afatinib, the median C_{\max} , C_{trough} , and AUC_{0-24} are 25.2 ng/mL, 18.2–34.1 ng/mL, and 324 ng · hr/mL, respectively[21,22].

Clinical benefits of afatinib in patients undergoing HD

Yamaguchi *et al*[23] reported a 59-year-old male ex-smoker undergoing HD for 17 years and diagnosed with stage IV lung adenocarcinoma (cT4N3M1b) with multiple pulmonary, hepatic, and bony metastases. Analysis of EGFR mutations revealed a G719A point mutation in exon 18. The patient received oral afatinib (30 mg) daily. The treatment was well tolerated, with only mild skin rash and no diarrhea. The tumors shrank after 2 mo of treatment. Bersanelli *et al*[8] reported afatinib as a third-line treatment for an NSCLC patient undergoing HD. Initially, the patient received cisplatin and



DOI: 10.12998/wjcc.v10.i19.6360 Copyright ©The Author(s) 2022.

Figure 3 Pharmacokinetics of erlotinib in patients undergoing hemodialysis and those with normal renal function. A: The C_{max} of erlotinib was 2290 ± 840 ng/mL in patients with NRF. For the patients undergoing HD, the C_{max} was 1638 ± 206 ng/mL on day 8 and 1638 ± 206 ng/mL on day 9 (after steady state). The C_{max} was similar in patients with NRF and undergoing HD; B: The plasma concentrations of erlotinib were similar before and after HD; C: The AUC_{0-24} was 35760 ± 15720 ng·hr/mL in patients with NRF. For the patients undergoing HD, the AUC_{0-24} was 23285 ± 5338 ng·hr/mL on day 8 and 25895 ± 7747 ng·hr/mL on day 9. The AUC_{0-24} was similar in patients with NRF and undergoing HD. AUC_{0-24} : Area under the curve of the plasma concentration from 0 to 24 h; C_{max} : Maximum concentration; C_{trough} : Trough concentration; HD: Hemodialysis; NRF: Normal renal function.

gemcitabine (first-line) and gefitinib (second-line). After tumor progression, the patient was started on 30 mg afatinib daily. The treatment was well tolerated, with only mild asthenia. After 2 mo, the afatinib dosage was increased to 40 mg daily, which caused significant asthenia, vomiting, and nausea[8].

The United States prescribing information recommends that the dose of afatinib be decreased to 30 mg daily for subjects with renal impairment. However, this recommendation cannot be made for patients with severe renal impairment or those undergoing HD, as afatinib has not been studied in these populations[20]. Based on these two case reports, we suggest that 30 mg afatinib is safe and effective in patients undergoing HD[8,23].

Pharmacokinetics of afatinib in patients undergoing HD

Yamaguchi *et al* performed the first pharmacokinetic analysis of daily administration of 30 mg afatinib to patients undergoing HD[23]. The C_{trough} values were 10.2 (day 2), 15.7 (day 3), 22.8 (day 10), 27.3 (day 11), and 23.8 ng/mL (day 12). Steady-state concentrations were attained by day 12. Yamaguchi *et al*[23] suggested that daily administration of 30 mg afatinib was safe for patients undergoing HD. Imai *et al*[24] also performed pharmacokinetic analysis of daily administration of 30 mg afatinib as first-line afatinib therapy for three lung cancer patients undergoing HD. Case 1 was a 78-year-old male with stage IV adenocarcinoma (cT1bN0M1b) with an EGFR mutation (exon 19 deletion). Case 2 was a 75-year-old male ex-smoker with lung adenocarcinoma (pT1aN0M0) with an EGFR mutation (exon 19 deletion) undergoing HD. However, postoperative mediastinal lymph nodes recurred. Case 3 was a 62-year-old male non-smoker with adenocarcinoma (pT2aN1M0) with an EGFR mutation (exon 21 L858R). Multiple pulmonary metastases with malignant pleural effusion occurred after the surgery. The pharmacokinetic analyses of the 3 cases revealed that the C_{max} was 13.4 ± 6.2 and 51.7 ± 23.8 ng/mL on days 1 and 10, respectively, and the C_{trough} was 4.5 ± 2.3 and 28.3 ± 9.0 ng/mL on days 2 and 11, respectively. The principal AEs were skin rash, dry skin, diarrhea, and malaise, and no severe AEs were reported except 1 case of grade 3 diarrhea. All the patients were maintained at partial response until the article was published (135–456 d).

The data on the pharmacokinetics of afatinib in patients undergoing HD and subjects with NRF are shown in Figure 4. Since approximately 95% of afatinib is bound to plasma proteins[25], afatinib is poorly eliminated during HD. The pharmacokinetics of afatinib in the aforementioned patients undergoing HD were comparable with subjects with NRF[25].

OSIMERTINIB

Clinical benefits of osimertinib

Osimertinib selectively and potently inhibits sensitive EGFR gene mutations[26]. Osimertinib also has a good response in NSCLC with acquired EGFR T790M resistance after treatment with first- or second-generation EGFR-TKIs.

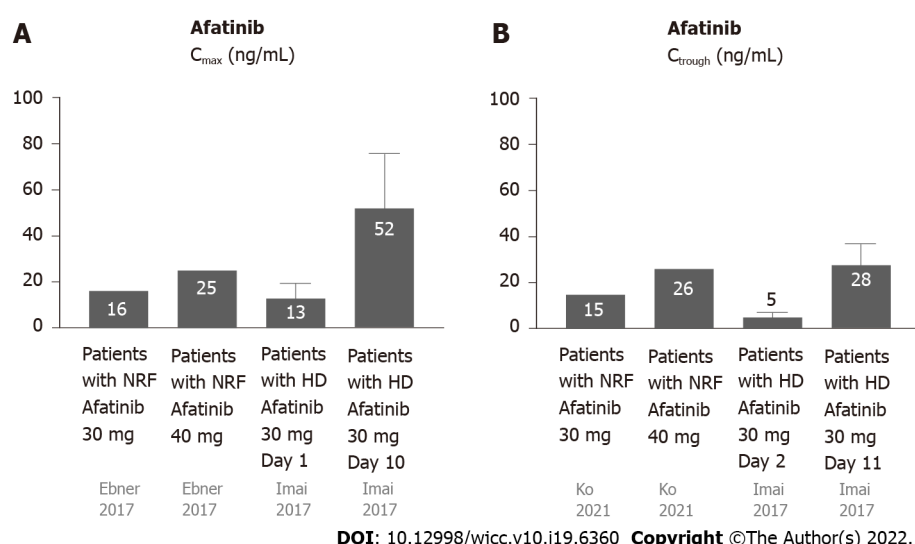


Figure 4 Pharmacokinetics of afatinib in patients undergoing hemodialysis and those with normal renal function. A: The C_{max} of afatinib 30 mg daily in patients with NRF was 16.3 ng/mL, while the C_{max} of afatinib 40 mg daily in patients with NRF was 25.2 ng/mL. The C_{max} of afatinib 30 mg daily in patients with HD was 13.4 ± 6.2 ng/mL on day 1 and 51.7 ± 23.8 ng/mL on day 10; B: The C_{trough} of afatinib 30 mg daily in patients with NRF was 15.1 ng/mL, while the C_{trough} of afatinib 40 mg daily in patients with NRF was 26 ng/mL. The C_{trough} of afatinib 30 mg daily in patients with HD was 4.5 ± 2.3 ng/mL on day 1 and 28.3 ± 9.0 ng/mL on day 11. C_{max}: Maximum concentration; C_{trough}: Trough concentration; HD: Hemodialysis; NRF: Normal renal function.

Therefore, it is an effective first-line treatment for NSCLC patients with activating EGFR mutations, and an effective second-line treatment for NSCLC patients with T790 M resistance mutations[26]. Previous studies using osimertinib as the first line of treatment for NSCLC with sensitive EGFR gene mutations showed an ORR of approximately 80%, PFS of 18.9 mo, and OS of 38.6 mo[26]. After administration of osimertinib as the second-line treatment for NSCLC patients with T790 M resistance mutations, the ORR was approximately 71%, PFS was approximately 10.1 mo, and OS was 26.8 mo[27]. The common AEs of osimertinib were skin rash and diarrhea, and the others were paronychia, dry skin, stomatitis, nausea, anorexia, headache, constipation, anemia, pruritus, fatigue, and cough[27]. Osimertinib has fewer serious AEs than the first- and second-generation TKIs[27].

Clinical benefits of osimertinib in patients undergoing HD

Iwafuchi *et al*[28] reported a 64-year-old female non-smoker undergoing HD with left lung adenocarcinoma (cT3N1M1a, stage IV, with malignant pleural effusion) with EGFR deletion in exon 19. She received gefitinib (first-line), erlotinib (second-line), taxotere (third-line), afatinib (fourth-line), and another six cycles of taxotere (fifth-line). After 5 years of treatment, the tumor was enlarged with liver and splenic metastases. For T790 M mutation, daily oral administration of 80 mg osimertinib was prescribed. The tumor improved to partial remission, and the liver and splenic metastases disappeared. The patient experienced no serious AEs and showed a good response. This case presented good effects and tolerability in patients undergoing HD even with sixth-line therapy.

Pharmacokinetics of osimertinib in patients with NRF

Most osimertinib is metabolized by the liver and excreted *via* feces (68%), and a small portion (14%) is excreted *via* urine (Figure 1D)[29]. The plasma protein binding ability of osimertinib is very high (98%) [30]. The half-life is 48.3 h, and steady state plasma concentrations are attained in approximately 10 d [30]. The time to attain C_{max} is 6 h (3–24 h) after dosing; the C_{max} and C_{trough} are 371 and 230 ng/mL, respectively[31].

Pharmacokinetics of osimertinib in patients undergoing HD

Tamura *et al*[32] reported the first pharmacokinetic analysis of osimertinib in patients undergoing HD. They reported a 72-year-old male ex-smoker with lung adenocarcinoma (T2aN3M1b, stage IV, with pleural and bone metastasis) with EGFR exon 19 deletion. He was initially receiving 250 mg gefitinib daily, but the treatment was discontinued, owing to liver toxicity, in 2 mo. After his recovery, he received 150 mg erlotinib daily and showed a good response. However, due to skin toxicity, the erlotinib dosage was gradually reduced to 50 mg daily. During the treatment, HD was initiated owing to worsening diabetic nephropathy. Four years after erlotinib treatment, the primary tumor was enlarged and had metastasized to the supraclavicular lymph nodes. The tumor tissue presented a T790M mutation in exon 20. He was initially administered 40 mg osimertinib daily for the previous liver and skin AEs of gefitinib and erlotinib. As treatment was well tolerated, pharmacokinetic analysis of osimertinib was performed 4 mo after administration[32]. Pharmacokinetic analysis of osimertinib (40

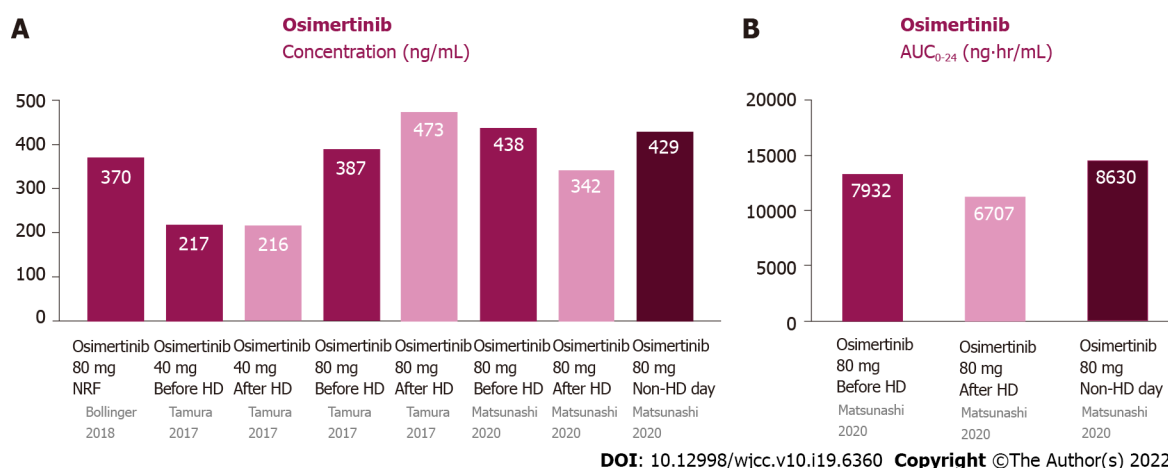


Figure 5 Pharmacokinetics of osimertinib in patients undergoing hemodialysis and those with normal renal function. A: Plasma concentrations of osimertinib were similar among pre-HD, post-HD, and non-HD days; B: The AUC₀₋₂₄ of osimertinib were similar among pre-HD, post-HD, and non-HD days. AUC₀₋₂₄: Area under the curve of the plasma concentration from 0 to 24 h; HD: Hemodialysis; NRF: Normal renal function.

mg daily) was performed on HD and non-HD days. The C_{max} was 218 and 217 ng/mL on HD and non-HD days, respectively. The osimertinib dosage was increased to 80 mg daily for only mild AEs. Pharmacokinetic analysis was performed after 6 d and revealed that the C_{max} was 388 and 473 ng/mL on HD and non-HD days, respectively. The patient received 80 mg osimertinib daily, without any AEs[32]. Matsunashi *et al*[29] reported a 66-year-old male undergoing HD with relapsed stage IV NSCLC with an EGFR mutation in exon 21 (L858R) 2 years after body radiotherapy. He received 80 mg osimertinib daily as first-line treatment. The C_{max} was 400-476 and 335-351 ng/mL before and after HD, respectively. When osimertinib was administered on HD days, the C_{max} was 430 ng/mL[29]. The AUC₀₋₂₄ before HD, after HD and on non-HD day were 7022-8842, 6376-7039 and 8631 ng·hr/mL.

The data on the pharmacokinetics of gefitinib in patients undergoing HD and subjects with NRF are shown in Figure 5. Since the protein binding ability of osimertinib is very high, its dialyzability rate is relatively low and it is minimally affected by HD[30]. The pharmacokinetic parameters on non-HD days were almost the same as those on HD days.

Limitations of this review

This review has several limitations. Firstly, the literature cited in this review on EGFR-TKIs in patients undergoing HD are all case reports. There have been no cohorts or randomized controlled trials with EGFR-TKIs in patients undergoing HD. However, it is difficult to conduct research on HD patients owing to their rarity. Therefore, this review is very important for providing recommendations for EGFR-TKIs in such patients. Secondly, this review focuses on EGFR-TKIs in lung cancer patients undergoing HD. It is unknown whether the conclusions drawn are applicable to other cancers.

CONCLUSION

There have been no clinical studies on EGFR-TKIs in NSCLC patients undergoing HD. We suggest that EGFR-TKIs are suitable for such patients. The recommended doses and pharmacokinetics of these EGFR-TKIs for patients undergoing HD are similar to those for patients with NRF. EGFR-TKI treatment is effective and well tolerated in patients undergoing HD.

FOOTNOTES

Author contributions: Lan CC, Hsieh PC, Huang CY, and Yang MC contributed to data curation; Lan CC and Hsieh PC contributed to formal analysis; Lan CC, Huang CY, Yang MC, Su WL, Wu CW, and Wu YK contributed to investigation; Lan CC and Wu YK contributed to conceptualization; Lan CC, Su WL, and Wu CW contributed to methodology; Lan CC, Hsieh PC, Huang CY, Yang MC, and Wu YK contributed to project administration; Lan CC and Wu YK contributed to funding acquisition; Lan CC, Wu YK, and Hsieh PC contributed to writing; Huang CY, Yang MC, and Wu YK contributed to validation; Lan CC and Hsieh PC contributed to the original draft; Lan CC contributed to review and editing; Wu YK contributed to supervision, visualization, review, and editing.

Supported by the Taipei Tzu Chi Hospital, Buddhist Tzu Chi Medical Foundation, No. TCRD-TPE-108-RT-4(3/3; and No. TCRD-TPE-109-59.

Conflict-of-interest statement: All authors declare no conflicts-of-interest related to this article.

Open-Access: This article is an open-access article that was selected by an in-house editor and fully peer-reviewed by external reviewers. It is distributed in accordance with the Creative Commons Attribution NonCommercial (CC BY-NC 4.0) license, which permits others to distribute, remix, adapt, build upon this work non-commercially, and license their derivative works on different terms, provided the original work is properly cited and the use is non-commercial. See: <https://creativecommons.org/licenses/by-nc/4.0/>

Country/Territory of origin: Taiwan

ORCID number: Chou-Chin Lan 0000-0001-9376-6539; Po-Chun Hsieh 0000-0002-0416-8797; Chun-Yao Huang 0000-0001-7919-9734; Mei-Chen Yang 0000-0002-6503-5189; Wen-Lin Su 0000-0002-9065-2058; Chih-Wei Wu 0000-0001-5242-6343; Yao-Kuang Wu 0000-0001-7898-6963.

S-Editor: Liu JH

L-Editor: Filipodia

P-Editor: Liu JH

REFERENCES

- 1 **Chang YS**, Tu SJ, Chen YC, Liu TY, Lee YT, Yen JC, Fang HY, Chang JG. Mutation profile of non-small cell lung cancer revealed by next generation sequencing. *Respir Res* 2021; **22**: 3 [PMID: 33407425 DOI: 10.1186/s12931-020-01608-5]
- 2 **Mok Y**, Balles SH, Sang Y, Coresh J, Joshi CE, Platz EA, Matsushita K. Albuminuria, Kidney Function, and Cancer Risk in the Community. *Am J Epidemiol* 2020; **189**: 942-950 [PMID: 32219380 DOI: 10.1093/aje/kwaa043]
- 3 **Moon HH**, Seo KW, Yoon KY, Shin YM, Choi KH, Lee SH. Prediction of nephrotoxicity induced by cisplatin combination chemotherapy in gastric cancer patients. *World J Gastroenterol* 2011; **17**: 3510-3517 [PMID: 21941418 DOI: 10.3748/wjg.v17.i30.3510]
- 4 **Aldossary SA**. Review on Pharmacology of Cisplatin: Clinical Use, Toxicity and Mechanism of Resistance of Cisplatin. *BPJ* 2019; **11**: 07-15 [DOI: 10.13005/bpj/1608]
- 5 **Harrison PT**, Vyse S, Huang PH. Rare epidermal growth factor receptor (EGFR) mutations in non-small cell lung cancer. *Semin Cancer Biol* 2020; **61**: 167-179 [PMID: 31562956 DOI: 10.1016/j.semcancer.2019.09.015]
- 6 **You JHS**, Cho WCS, Ming WK, Li YC, Kwan CK, Au KH, Au JS. EGFR mutation-guided use of afatinib, erlotinib and gefitinib for advanced non-small-cell lung cancer in Hong Kong - A cost-effectiveness analysis. *PLoS One* 2021; **16**: e0247860 [PMID: 33647045 DOI: 10.1371/journal.pone.0247860]
- 7 **Maemondo M**, Inoue A, Kobayashi K, Sugawara S, Oizumi S, Isobe H, Gemma A, Harada M, Yoshizawa H, Kinoshita I, Fujita Y, Okinaga S, Hirano H, Yoshimori K, Harada T, Ogura T, Ando M, Miyazawa H, Tanaka T, Saijo Y, Hagiwara K, Morita S, Nukiwa T; North-East Japan Study Group. Gefitinib or chemotherapy for non-small-cell lung cancer with mutated EGFR. *N Engl J Med* 2010; **362**: 2380-2388 [PMID: 20573926 DOI: 10.1056/NEJMoa0909530]
- 8 **Bersanelli M**, Tiseo M, Artioli F, Lucchi L, Ardizzoni A. Gefitinib and afatinib treatment in an advanced non-small cell lung cancer (NSCLC) patient undergoing hemodialysis. *Anticancer Res* 2014; **34**: 3185-3188 [PMID: 24922692]
- 9 **Del Conte A**, Minatel E, Schinella D, Baresic T, Basso SM, Lumachi F. Complete metabolic remission with Gefitinib in a hemodialysis patient with bone metastases from non-small cell lung cancer. *Anticancer Res* 2014; **34**: 319-322 [PMID: 24403481]
- 10 **Zhao C**, Han SY, Li PP. Pharmacokinetics of Gefitinib: Roles of Drug Metabolizing Enzymes and Transporters. *Curr Drug Deliv* 2017; **14**: 282-288 [PMID: 27396387 DOI: 10.2174/1567201813666160709021605]
- 11 **Hirose T**, Fujita K, Kusumoto S, Oki Y, Murata Y, Sugiyama T, Ishida H, Shirai T, Nakashima M, Yamaoka T, Okuda K, Ohmori T, Sasaki Y. Association of pharmacokinetics and pharmacogenomics with safety and efficacy of gefitinib in patients with EGFR mutation positive advanced non-small cell lung cancer. *Lung Cancer* 2016; **93**: 69-76 [PMID: 26898617 DOI: 10.1016/j.lungcan.2016.01.005]
- 12 **Shinagawa N**, Yamazaki K, Asahina H, Agata J, Itoh T, Nishimura M. Gefitinib administration in a patient with lung cancer undergoing hemodialysis. *Lung Cancer* 2007; **58**: 422-424 [PMID: 17643548 DOI: 10.1016/j.lungcan.2007.06.001]
- 13 **Luo J**, Ni L, Wang M, Zhong W, Xiao Y, Zheng K, Hu P. Pharmacokinetic analysis of gefitinib in a patient with advanced non-small cell lung cancer undergoing hemodialysis. *Thorac Cancer* 2016; **7**: 251-253 [PMID: 27042230 DOI: 10.1111/1759-7714.12263]
- 14 **Lin YT**, Chen JS, Liao WY, Ho CC, Hsu CL, Yang CY, Chen KY, Lee JH, Lin ZZ, Shih JY, Yang JC, Yu CJ. Clinical outcomes and secondary epidermal growth factor receptor (EGFR) T790M mutation among first-line gefitinib, erlotinib and afatinib-treated non-small cell lung cancer patients with activating EGFR mutations. *Int J Cancer* 2019; **144**: 2887-2896 [PMID: 30485437 DOI: 10.1002/ijc.32025]
- 15 **Evelina Cardoso**, Guidi M, Khoudour N, Pascaline Boudou-Rouquette, Fabre E, Tlemsani C, Arrondeau J, François Goldwasser, Vidal M, Schneider MP, Wagner AD, Widmer N, Blanchet B, Csajka C. Population Pharmacokinetics of Erlotinib in Patients With Non-small Cell Lung Cancer: Its Application for Individualized Dosing Regimens in Older Patients. *Clin Ther* 2020; **42**: 1302-1316 [PMID: 32631634 DOI: 10.1016/j.clinthera.2020.05.008]
- 16 **Petit-Jean E**, Buclin T, Guidi M, Quoix E, Gourieux B, Decosterd LA, Gairard-Dory AC, Ubeaud-Séquier G, Widmer N. Erlotinib: another candidate for the therapeutic drug monitoring of targeted therapy of cancer? *Ther Drug Monit* 2015; **37**: 2-21 [PMID: 24831652 DOI: 10.1097/FTD.0000000000000097]

- 17 **Togashi Y**, Masago K, Fukudo M, Terada T, Ikemi Y, Kim YH, Fujita S, Irisa K, Sakamori Y, Mio T, Inui K, Mishima M. Pharmacokinetics of erlotinib and its active metabolite OSI-420 in patients with non-small cell lung cancer and chronic renal failure who are undergoing hemodialysis. *J Thorac Oncol* 2010; **5**: 601-605 [PMID: [20234322](#) DOI: [10.1097/JTO.0b013e3181d32287](#)]
- 18 **de Marinis F**, Laktionov KK, Poltoratskiy A, Egorova I, Hochmair M, Passaro A, Migliorino MR, Metro G, Gottfried M, Tsoi D, Ostoros G, Rizzato S, Mukhametshina GZ, Schumacher M, Novello S, Dziadziuszko R, Tang W, Clementi L, Cseh A, Kowalski D. Afatinib in EGFR TKI-naïve patients with locally advanced or metastatic EGFR mutation-positive non-small cell lung cancer: Interim analysis of a Phase 3b study. *Lung Cancer* 2021; **152**: 127-134 [PMID: [33387727](#) DOI: [10.1016/j.lungcan.2020.12.011](#)]
- 19 **Stopfer P**, Marzin K, Narjes H, Gansser D, Shahidi M, Uttreuther-Fischer M, Ebner T. Afatinib pharmacokinetics and metabolism after oral administration to healthy male volunteers. *Cancer Chemother Pharmacol* 2012; **69**: 1051-1061 [PMID: [22200729](#) DOI: [10.1007/s00280-011-1803-9](#)]
- 20 **Keating GM**. Afatinib: A Review in Advanced Non-Small Cell Lung Cancer. *Target Oncol* 2016; **11**: 825-835 [PMID: [27873136](#) DOI: [10.1007/s11523-016-0465-2](#)]
- 21 **Wind S**, Schnell D, Ebner T, Freiwald M, Stopfer P. Clinical Pharmacokinetics and Pharmacodynamics of Afatinib. *Clin Pharmacokinet* 2017; **56**: 235-250 [PMID: [27470518](#) DOI: [10.1007/s40262-016-0440-1](#)]
- 22 **Ko R**, Shukuya T, Imamura CK, Tokito T, Shimada N, Koyama R, Yamada K, Ishii H, Azuma K, Takahashi K. Phase I study of afatinib plus bevacizumab in patients with advanced non-squamous non-small cell lung cancer harboring *EGFR* mutations. *Transl Lung Cancer Res* 2021; **10**: 183-192 [PMID: [33569303](#) DOI: [10.21037/tlcr-20-824](#)]
- 23 **Yamaguchi T HH**, Isogai S, Hayashi M, Uozu S, Goto Y, Nakanishi T, Sugiyama T, Itoh Y, Imaizumi K. Afatinib administration in a patient with non-small cell lung cancer harboring uncommon EGFR mutation G719A undergoing hemodialysis. *Cancer Treat Commun* 2015; **4**: 169-171 [DOI: [10.1016/j.ctr.2015.09.006](#)]
- 24 **Imai H**, Kaira K, Naruse I, Hayashi H, Iihara H, Kita Y, Mizusaki N, Asao T, Itoh Y, Sugiyama T, Minato K, Yamada M. Successful afatinib treatment of advanced non-small-cell lung cancer patients undergoing hemodialysis. *Cancer Chemother Pharmacol* 2017; **79**: 209-213 [PMID: [27900441](#) DOI: [10.1007/s00280-016-3201-9](#)]
- 25 **Peters S**, Zimmermann S, Adjei AA. Oral epidermal growth factor receptor tyrosine kinase inhibitors for the treatment of non-small cell lung cancer: comparative pharmacokinetics and drug-drug interactions. *Cancer Treat Rev* 2014; **40**: 917-926 [PMID: [25027951](#) DOI: [10.1016/j.ctr.2014.06.010](#)]
- 26 **Ramalingam SS**, Vansteenkiste J, Planchard D, Cho BC, Gray JE, Ohe Y, Zhou C, Reungwetwattana T, Cheng Y, Chewaskulyong B, Shah R, Cobo M, Lee KH, Cheema P, Tiseo M, John T, Lin MC, Imamura F, Kurata T, Todd A, Hodge R, Saggese M, Rukazenzov Y, Soria JC; FLAURA Investigators. Overall Survival with Osimertinib in Untreated, *EGFR*-Mutated Advanced NSCLC. *N Engl J Med* 2020; **382**: 41-50 [PMID: [31751012](#) DOI: [10.1056/NEJMoa1913662](#)]
- 27 **Liu J**, Li X, Shao Y, Guo X, He J. The efficacy and safety of osimertinib in treating nonsmall cell lung cancer: A PRISMA-compliant systematic review and meta-analysis. *Medicine (Baltimore)* 2020; **99**: e21826 [PMID: [32846826](#) DOI: [10.1097/MD.00000000000021826](#)]
- 28 **Iwafuchi Y**, Saito I, Narita I. Efficacy and Safety of Osimertinib in a Hemodialysis Patient With Advanced Non-Small Cell Lung Cancer. *Ther Apher Dial* 2017; **21**: 416-417 [PMID: [28332292](#) DOI: [10.1111/1744-9987.12531](#)]
- 29 **Matsunashi A**, Fujimoto D, Hosoya K, Irie K, Fukushima S, Tomii K. Osimertinib in a patient with non-small cell lung cancer and renal failure undergoing hemodialysis: a case report. *Invest New Drugs* 2020; **38**: 1192-1195 [PMID: [31486987](#) DOI: [10.1007/s10637-019-00851-y](#)]
- 30 **Planchard D**, Brown KH, Kim DW, Kim SW, Ohe Y, Felip E, Leese P, Cantarini M, Vishwanathan K, Jänne PA, Ranson M, Dickinson PA. Osimertinib Western and Asian clinical pharmacokinetics in patients and healthy volunteers: implications for formulation, dose, and dosing frequency in pivotal clinical studies. *Cancer Chemother Pharmacol* 2016; **77**: 767-776 [PMID: [26902828](#) DOI: [10.1007/s00280-016-2992-z](#)]
- 31 **Bollinger MK**, Agnew AS, Mascara GP. Osimertinib: A third-generation tyrosine kinase inhibitor for treatment of epidermal growth factor receptor-mutated non-small cell lung cancer with the acquired Thr790Met mutation. *J Oncol Pharm Pract* 2018; **24**: 379-388 [PMID: [28565936](#) DOI: [10.1177/1078155217712401](#)]
- 32 **Tamura T**, Takagi Y, Okubo H, Yamaguchi S, Kikkawa Y, Hashimoto I, Kaburagi T, Miura M, Satoh H, Hizawa N. Plasma concentration of osimertinib in a non-small cell lung cancer patient with chronic renal failure undergoing hemodialysis. *Lung Cancer* 2017; **112**: 225-226 [PMID: [28709627](#) DOI: [10.1016/j.lungcan.2017.07.007](#)]



Published by **Baishideng Publishing Group Inc**
7041 Koll Center Parkway, Suite 160, Pleasanton, CA 94566, USA

Telephone: +1-925-3991568

E-mail: bpgoffice@wjgnet.com

Help Desk: <https://www.f6publishing.com/helpdesk>

<https://www.wjgnet.com>

