

World Journal of *Clinical Cases*

World J Clin Cases 2022 July 6; 10(19): 6341-6758



Contents

Thrice Monthly Volume 10 Number 19 July 6, 2022

MINIREVIEWS

- 6341** Review of clinical characteristics, immune responses and regulatory mechanisms of hepatitis E-associated liver failure
Chen C, Zhang SY, Chen L
- 6349** Current guidelines for *Helicobacter pylori* treatment in East Asia 2022: Differences among China, Japan, and South Korea
Cho JH, Jin SY
- 6360** Review of epidermal growth factor receptor-tyrosine kinase inhibitors administration to non-small-cell lung cancer patients undergoing hemodialysis
Lan CC, Hsieh PC, Huang CY, Yang MC, Su WL, Wu CW, Wu YK

ORIGINAL ARTICLE

Case Control Study

- 6370** Pregnancy-related psychopathology: A comparison between pre-COVID-19 and COVID-19-related social restriction periods
Chieffo D, Avallone C, Serio A, Kotzalidis GD, Balocchi M, De Luca I, Hirsch D, Gonzalez del Castillo A, Lanzotti P, Marano G, Rinaldi L, Lanzone A, Mercuri E, Mazza M, Sani G
- 6385** Intestinal mucosal barrier in functional constipation: Dose it change?
Wang JK, Wei W, Zhao DY, Wang HF, Zhang YL, Lei JP, Yao SK

Retrospective Cohort Study

- 6399** Identification of risk factors for surgical site infection after type II and type III tibial pilon fracture surgery
Hu H, Zhang J, Xie XG, Dai YK, Huang X

Retrospective Study

- 6406** Total knee arthroplasty in Ranawat II valgus deformity with enlarged femoral valgus cut angle: A new technique to achieve balanced gap
Lv SJ, Wang XJ, Huang JF, Mao Q, He BJ, Tong PJ
- 6417** Preliminary evidence in treatment of eosinophilic gastroenteritis in children: A case series
Chen Y, Sun M
- 6428** Self-made wire loop snare successfully treats gastric persimmon stone under endoscopy
Xu W, Liu XB, Li SB, Deng WP, Tong Q
- 6437** Neoadjuvant transcatheter arterial chemoembolization and systemic chemotherapy for the treatment of undifferentiated embryonal sarcoma of the liver in children
He M, Cai JB, Lai C, Mao JQ, Xiong JN, Guan ZH, Li LJ, Shu Q, Ying MD, Wang JH

- 6446** Effect of cold snare polypectomy for small colorectal polyps

Meng QQ, Rao M, Gao PJ

- 6456** Field evaluation of COVID-19 rapid antigen test: Are rapid antigen tests less reliable among the elderly?

Tabain I, Cucevic D, Skreb N, Mrzljak A, Ferencak I, Hruskar Z, Misic A, Kuzle J, Skoda AM, Jankovic H, Vilibic-Cavlek T

Observational Study

- 6464** Tracheobronchial intubation using flexible bronchoscopy in children with Pierre Robin sequence: Nursing considerations for complications

Ye YL, Zhang CF, Xu LZ, Fan HF, Peng JZ, Lu G, Hu XY

- 6472** Family relationship of nurses in COVID-19 pandemic: A qualitative study

Çelik MY, Kiliç M

META-ANALYSIS

- 6483** Diagnostic accuracy of ≥ 16 -slice spiral computed tomography for local staging of colon cancer: A systematic review and meta-analysis

Liu D, Sun LM, Liang JH, Song L, Liu XP

CASE REPORT

- 6496** Delayed-onset endophthalmitis associated with *Achromobacter* species developed in acute form several months after cataract surgery: Three case reports

Kim TH, Lee SJ, Nam KY

- 6501** Sustained dialysis with misplaced peritoneal dialysis catheter outside peritoneum: A case report

Shen QQ, Behera TR, Chen LL, Attia D, Han F

- 6507** Arteriovenous thrombotic events in a patient with advanced lung cancer following bevacizumab plus chemotherapy: A case report

Kong Y, Xu XC, Hong L

- 6514** Endoscopic ultrasound radiofrequency ablation of pancreatic insulinoma in elderly patients: Three case reports

Rossi G, Petrone MC, Capurso G, Partelli S, Falconi M, Arcidiacono PG

- 6520** Acute choroidal involvement in lupus nephritis: A case report and review of literature

Yao Y, Wang HX, Liu LW, Ding YL, Sheng JE, Deng XH, Liu B

- 6529** Triple A syndrome-related achalasia treated by per-oral endoscopic myotomy: Three case reports

Liu FC, Feng YL, Yang AM, Guo T

- 6536** Choroidal thickening with serous retinal detachment in BRAF/MEK inhibitor-induced uveitis: A case report

Kiraly P, Groznik AL, Valentinčič NV, Mekjavić PJ, Urbančič M, Ocvirk J, Mesti T

- 6543** Esophageal granular cell tumor: A case report

Chen YL, Zhou J, Yu HL

- 6548** Hem-o-lok clip migration to the common bile duct after laparoscopic common bile duct exploration: A case report
Liu DR, Wu JH, Shi JT, Zhu HB, Li C
- 6555** Chidamide and sintilimab combination in diffuse large B-cell lymphoma progressing after chimeric antigen receptor T therapy
Hao YY, Chen PP, Yuan XG, Zhao AQ, Liang Y, Liu H, Qian WB
- 6563** Relapsing polychondritis with isolated tracheobronchial involvement complicated with Sjogren's syndrome: A case report
Chen JY, Li XY, Zong C
- 6571** Acute methanol poisoning with bilateral diffuse cerebral hemorrhage: A case report
Li J, Feng ZJ, Liu L, Ma YJ
- 6580** Immunoabsorption therapy for Klinefelter syndrome with antiphospholipid syndrome in a patient: A case report
Song Y, Xiao YZ, Wang C, Du R
- 6587** Roxadustat for treatment of anemia in a cancer patient with end-stage renal disease: A case report
Zhou QQ, Li J, Liu B, Wang CL
- 6595** Imaging-based diagnosis for extraskeletal Ewing sarcoma in pediatrics: A case report
Chen ZH, Guo HQ, Chen JJ, Zhang Y, Zhao L
- 6602** Unusual course of congenital complete heart block in an adult: A case report
Su LN, Wu MY, Cui YX, Lee CY, Song JX, Chen H
- 6609** Penile metastasis from rectal carcinoma: A case report
Sun JJ, Zhang SY, Tian JJ, Jin BY
- 6617** Isolated cryptococcal osteomyelitis of the ulna in an immunocompetent patient: A case report
Ma JL, Liao L, Wan T, Yang FC
- 6626** Magnetic resonance imaging features of intrahepatic extramedullary hematopoiesis: Three case reports
Luo M, Chen JW, Xie CM
- 6636** Giant retroperitoneal liposarcoma treated with radical conservative surgery: A case report and review of literature
Lieto E, Cardella F, Erario S, Del Sorbo G, Reginelli A, Galizia G, Urraro F, Panarese I, Auricchio A
- 6647** Transplanted kidney loss during colorectal cancer chemotherapy: A case report
Pośpiech M, Kolonko A, Nieszporek T, Kozak S, Kozaczka A, Karkoszka H, Winder M, Chudek J
- 6656** Massive gastrointestinal bleeding after endoscopic rubber band ligation of internal hemorrhoids: A case report
Jiang YD, Liu Y, Wu JD, Li GP, Liu J, Hou XH, Song J

- 6664** Mills' syndrome is a unique entity of upper motor neuron disease with N-shaped progression: Three case reports
Zhang ZY, Ouyang ZY, Zhao GH, Fang JJ
- 6672** Entire process of electrocardiogram recording of Wellens syndrome: A case report
Tang N, Li YH, Kang L, Li R, Chu QM
- 6679** Retroperitoneal tumor finally diagnosed as a bronchogenic cyst: A case report and review of literature
Gong YY, Qian X, Liang B, Jiang MD, Liu J, Tao X, Luo J, Liu HJ, Feng YG
- 6688** Successful treatment of Morbihan disease with total glucosides of paeony: A case report
Zhou LF, Lu R
- 6695** Ant sting-induced whole-body pustules in an inebriated male: A case report
Chen SQ, Yang T, Lan LF, Chen XM, Huang DB, Zeng ZL, Ye XY, Wan CL, Li LN
- 6702** Plastic surgery for giant metastatic endometrioid adenocarcinoma in the abdominal wall: A case report and review of literature
Wang JY, Wang ZQ, Liang SC, Li GX, Shi JL, Wang JL
- 6710** Delayed-release oral mesalamine tablet mimicking a small jejunal gastrointestinal stromal tumor: A case report
Frosio F, Rausa E, Marra P, Boutron-Ruault MC, Lucianetti A
- 6716** Concurrent alcoholic cirrhosis and malignant peritoneal mesothelioma in a patient: A case report
Liu L, Zhu XY, Zong WJ, Chu CL, Zhu JY, Shen XJ
- 6722** Two smoking-related lesions in the same pulmonary lobe of squamous cell carcinoma and pulmonary Langerhans cell histiocytosis: A case report
Gencer A, Ozcibik G, Karakas FG, Sarbay I, Batur S, Borekci S, Turna A
- 6728** Proprotein convertase subtilisin/kexin type 9 inhibitor non responses in an adult with a history of coronary revascularization: A case report
Yang L, Xiao YY, Shao L, Ouyang CS, Hu Y, Li B, Lei LF, Wang H
- 6736** Multimodal imaging study of lipemia retinalis with diabetic retinopathy: A case report
Zhang SJ, Yan ZY, Yuan LF, Wang YH, Wang LF
- 6744** Primary squamous cell carcinoma of the liver: A case report
Kang LM, Yu DP, Zheng Y, Zhou YH
- 6750** Tumor-to-tumor metastasis of clear cell renal cell carcinoma to contralateral synchronous pheochromocytoma: A case report
Wen HY, Hou J, Zeng H, Zhou Q, Chen N

ABOUT COVER

Editorial Board Member of *World Journal of Clinical Cases*, Abdulqadir Jeprel Naswhan, MSc, RN, Director, Research Scientist, Senior Lecturer, Senior Researcher, Nursing for Education and Practice Development, Hamad Medical Corporation, Doha 576214, Qatar. anashwan@hamad.qa

AIMS AND SCOPE

The primary aim of *World Journal of Clinical Cases* (WJCC, *World J Clin Cases*) is to provide scholars and readers from various fields of clinical medicine with a platform to publish high-quality clinical research articles and communicate their research findings online.

WJCC mainly publishes articles reporting research results and findings obtained in the field of clinical medicine and covering a wide range of topics, including case control studies, retrospective cohort studies, retrospective studies, clinical trials studies, observational studies, prospective studies, randomized controlled trials, randomized clinical trials, systematic reviews, meta-analysis, and case reports.

INDEXING/ABSTRACTING

The WJCC is now indexed in Science Citation Index Expanded (also known as SciSearch®), Journal Citation Reports/Science Edition, Scopus, PubMed, and PubMed Central. The 2021 Edition of Journal Citation Reports® cites the 2020 impact factor (IF) for WJCC as 1.337; IF without journal self cites: 1.301; 5-year IF: 1.742; Journal Citation Indicator: 0.33; Ranking: 119 among 169 journals in medicine, general and internal; and Quartile category: Q3. The WJCC's CiteScore for 2020 is 0.8 and Scopus CiteScore rank 2020: General Medicine is 493/793.

RESPONSIBLE EDITORS FOR THIS ISSUE

Production Editor: Xu Guo; Production Department Director: Xiang Li; Editorial Office Director: Jin-Lai Wang.

NAME OF JOURNAL

World Journal of Clinical Cases

ISSN

ISSN 2307-8960 (online)

LAUNCH DATE

April 16, 2013

FREQUENCY

Thrice Monthly

EDITORS-IN-CHIEF

Bao-Gan Peng, Jerzy Tadeusz Chudek, George Kontogeorgos, Maurizio Serati, Ja Hyeon Ku

EDITORIAL BOARD MEMBERS

<https://www.wjgnet.com/2307-8960/editorialboard.htm>

PUBLICATION DATE

July 6, 2022

COPYRIGHT

© 2022 Baishideng Publishing Group Inc

INSTRUCTIONS TO AUTHORS

<https://www.wjgnet.com/bpg/gerinfo/204>

GUIDELINES FOR ETHICS DOCUMENTS

<https://www.wjgnet.com/bpg/GerInfo/287>

GUIDELINES FOR NON-NATIVE SPEAKERS OF ENGLISH

<https://www.wjgnet.com/bpg/gerinfo/240>

PUBLICATION ETHICS

<https://www.wjgnet.com/bpg/GerInfo/288>

PUBLICATION MISCONDUCT

<https://www.wjgnet.com/bpg/gerinfo/208>

ARTICLE PROCESSING CHARGE

<https://www.wjgnet.com/bpg/gerinfo/242>

STEPS FOR SUBMITTING MANUSCRIPTS

<https://www.wjgnet.com/bpg/GerInfo/239>

ONLINE SUBMISSION

<https://www.f6publishing.com>



Retrospective Study

Self-made wire loop snare successfully treats gastric persimmon stone under endoscopy

Wen Xu, Xiao-Bo Liu, Sheng-Bao Li, Wei-Ping Deng, Qiang Tong

Specialty type: Medicine, research and experimental

Provenance and peer review: Unsolicited article; Externally peer reviewed.

Peer-review model: Single blind

Peer-review report's scientific quality classification

Grade A (Excellent): 0
Grade B (Very good): 0
Grade C (Good): 0
Grade D (Fair): 0
Grade E (Poor): 0

P-Reviewer: Wang KK, United States

Received: October 27, 2021

Peer-review started: October 27, 2021

First decision: March 11, 2022

Revised: March 26, 2022

Accepted: April 21, 2022

Article in press: April 21, 2022

Published online: July 6, 2022



Wen Xu, Xiao-Bo Liu, Wei-Ping Deng, Qiang Tong, Department of Gastroenterology, Taihe Hospital, Shiyan 442000, Hubei Province, China

Sheng-Bao Li, Department of Gastroenterology, Taihe Hospital, Hubei University of Medicine, Shiyan 442000, Hubei Province, China

Corresponding author: Wei-Ping Deng, PhD, Professor, Department of Gastroenterology, Taihe Hospital, No. 32 South Renmin Road, Shiyan 442000, Hubei Province, China.
173642105@qq.com

Abstract

BACKGROUND

Large gastric persimmon stones are generally resistant to standard endoscopic treatments. We applied an alternative endoscopic method using a hand-made snare for the treatment of large gastric phytobezoars.

AIM

To explore the clinical efficacy of a self-made wire loop snare to treat giant gastric persimmon stones.

METHODS

A retrospective study evaluated the clinical data of 38 patients with gastroliths admitted to Taihe Hospital in Shiyan City, Hubei Province, China, between March 2015 and October 2020. The patients were divided into observation ($n = 23$) and control ($n = 15$) groups. Patients in the observation group were treated with self-made wire loop snares for lithotripsy, and patients in the control group were treated with traditional foreign body forceps, snares, injection needles, and other tools. Successful stone removal, treatment time, and hospital stay were compared.

RESULTS

The average operating time was significantly shorter ($P < 0.001$) in the observation group (53.4 min) than that in the control group (172.8 min). The average hospital stay of the observation group (5.4 d) was significantly shorter ($P < 0.001$) than that in the control group (10.3 d). Successful one-time treatment was significantly more frequent ($P < 0.001$) in the observation group (87%) than in the control group (7%).

CONCLUSION

Self-made guidewire loop snares were successfully used to treat gastrolithiasis,

and were significantly more effective than foreign body forceps, snares, and other traditional methods.

Key Words: Gastric persimmon; Phytobezoars; Self-made snare; Endoscopy; Treatment

©The Author(s) 2022. Published by Baishideng Publishing Group Inc. All rights reserved.

Core tip: Endoscopic therapy is the first choice for gastrolithiasis. The commonly used method is cutting gastroliths into small pieces and then taking them out with foreign body forceps, snares, injection needles, and net baskets. However, these tools have insurmountable defects, such as cumbersome operation times and must be entered repeatedly, increasing the risk of damage to the patient's throat and esophagus, and has higher treatment costs. Since October 2016, our team has treated gastric persimmon stones with self-made snares. In this study, the advantages and disadvantages of self-made snares will be analyzed and compared with those of traditional tools.

Citation: Xu W, Liu XB, Li SB, Deng WP, Tong Q. Self-made wire loop snare successfully treats gastric persimmon stone under endoscopy. *World J Clin Cases* 2022; 10(19): 6428-6436

URL: <https://www.wjgnet.com/2307-8960/full/v10/i19/6428.htm>

DOI: <https://dx.doi.org/10.12998/wjcc.v10.i19.6428>

INTRODUCTION

Gastrolithiasis is a condition caused by ingestion of plants, hair, or minerals, such as calcium carbonate, barium, and bismuth that cannot be digested[1] and condense to form foreign bodies, or bezoars, commonly in the stomach[2]. The incidence of gastroliths is low, with an endoscopic detection rate of approximately 0.31%[3]. Gastric bezoars can be divided into phytobezoars, animal gastroliths, medicinal gastroliths, and mixed gastroliths[4]. Phytobezoars, are the most common, account for more than 90% and have various individual causes, such as eating large amounts of fiber-rich foods, gastric dysfunction, and anatomical factors, including stenosis, diverticuli, and tumor-induced gastrointestinal obstruction[5,6].

In China, phytobezoars are often caused by eating persimmons, hawthorns, and black dates. Gastric persimmon stones are the most common gastroliths, and they are usually large and difficult to treat[7, 8]. The risk factors for gastrolith occurrence include a history of gastric surgery, drinking alcohol, high blood pressure, diabetes, hypothyroidism, trichotillomania, anxiety, autumn and winter seasons, and residing in areas rich in hawthorns and persimmons[3,5]. The symptoms may include gastric outlet obstruction, abdominal pain, bloating, nausea, and vomiting[9]. Endoscopically, the condition often manifests as peptic ulcer, erosive gastritis, duodenitis, and reflux esophagitis[5]. Common complications include gastric ulcer, gastric perforation, and intestinal obstruction[9,10].

Endoscopic surgery is the preferred treatment for gastrolithiasis[10], and it commonly involves lithotripsy for cutting gastroliths into small pieces that are subsequently removed with foreign body forceps, snares, injection needles, net baskets, dual knives, electric snares, and guidewires[11]. Those tools have disadvantages such as operation times that are prolonged or difficult because of repeated entry and the risk of damage to the patient's throat and esophagus. A long operating time increases pain, and has high treatment costs[12]. Foreign body forceps that can be easily used to remove gastric persimmon stones have recently been introduced, but the equipment is expensive and most medical institutions have not purchased them. Hence, their use is currently limited[1].

Since October 2016, our team has treated gastric persimmon stones with self-made snares. In this study, the advantages and disadvantages of self-made snares were evaluated and compared with traditional tools.

MATERIALS AND METHODS

Study design and setting

This retrospective study collected the clinical data of patients with gastrolithiasis diagnosed by gastroscopy at the Digestive Endoscopy Center of Taihe Hospital, Shiyan City, Hubei Province, China between March 2015 and October 2020. The enrolled patients were divided into an observation group ($n = 23$) and a control group ($n = 15$). The patients in the observation group underwent endoscopic lithotripsy between October 2016 October 2020 with self-made guidewire loop snares. The patients in

the control group were treated between March 2015 and September 2016 by lithotripsy with traditional foreign body forceps, snares, or injection needles. The study protocol was reviewed and approved by Taihe Hospital's Ethics Committee, and written consent was obtained from all patients who participated. The study was conducted following the ethical guidelines of the Helsinki Declaration.

Inclusion criteria: Patients with a history of eating persimmons, evaluated by gastroscopy, computed tomography (CT), magnetic resonance imaging (MRI), and other modalities, and finally diagnosed with gastrolithiasis that involved large gastric persimmon stones of > 4 cm in diameter, were assessed for study inclusion. Study enrollment required gastroscopy showing successful removal of the persimmon stone from the stomach and the absence of residue. The study participants were considered cured and discharged.

Exclusion criteria: Patients with stones that were not persimmon stones, persimmon stones < 4 cm diameter, not treated endoscopically, with intestinal obstruction, gastric perforation, and other complications, lost to follow-up or with incomplete data, and those not considered appropriate for inclusion by the investigators were excluded.

Clinical information: Patient sex, age, underlying diseases, main clinical symptoms, size and location of the gastric persimmon stones, and other endoscopy findings (*e.g.*, peptic ulcer, reflux esophagitis), number of gastroscopy procedures, average operation time, and average hospital stay were included in the analysis.

Generation of the wire loop snares


A 0.025-inch diameter guidewire (Single-Use Guidewire; Olympus, Tokyo, Japan) (Figure 1A) was inserted into the biopsy tunnel of the gastroscope operation site and passed through the end of the gastroscope lens. An ultrafine endoscopic biopsy forceps (FB-231K; Olympus) (Figure 1B) was inserted into the biopsy channel. A transparent cap was placed on the front end of the gastroscope. The guidewire was passed through the lateral orifice at the head end of the biopsy forceps. The biopsy forceps were closed to clamp the guidewire, and the force was controlled to prevent the guidewire from detaching during traction or damage to the guidewire because of excessive force. The biopsy forceps were pulled back until the guidewire was pulled out from the biopsy channel. During the procedure, the guidewire was delivered into the biopsy channel synchronously to maintain an "O" shape of the guidewire loop snare extending out of the biopsy channel. Guidewire loop snares of different diameters were prepared (Figure 1C-H).

Treatment

Preoperative preparation: At 48 h before surgery, the patients in both groups were instructed to drink 100–200 mL of Coca-Cola once every 6 h. At 12 h before surgery, they began fasting. The patient was anesthetized with 10 mg intramuscular anisodamine, 10 mg intravenous diazepam, and 50 mg intramuscular pethidine.

Control group: A transparent cap was installed on the front end of the gastroscope and introduced to the stomach with the endoscope. The persimmon stone was gradually mashed, layer by layer, with foreign body forceps (FG-44NR-1; Olympus) (Figure 2A), snares (NOE342216-C; Olympus) (Figure 2B), and injection needles (NM-4L-1; Olympus) (Figure 2A and B). A wire basket was used to remove large pieces, and smaller pieces were discharged from the intestines. After treatment, the patients were instructed to consume Coca-Cola orally, following the same routine as the above. After surgery, patients were instructed to fast for 48 h after receiving gastroscopy. When residues were found, the above method for lithotripsy treatment was conducted and repeated until the persimmon stone completely disappeared.

Observation group: Before treatment, a self-made wire loop snare was used to install a transparent cap (D-201; Olympus) on the front end of the gastroscope (GIF260; Olympus). Both ends of the guidewire were tightened, and the guidewire loop on the lens end was retracted into the transparent cap. The endoscope entered the stomach. After the persimmon stone was found, the guidewire was positioned so that the diameter of the loop at the lens end was larger than the diameter of the persimmon stone. The persimmon stone was held and positioned in the greater curvature of the stomach. One end of the guidewire (A) of the operating part was fixed, the other end of the guidewire (B) was tightened. After the side of the guidewire was embedded in the persimmon stone, the B end was fixed and the A end was tightened. The guidewire was embedded on the other side of the persimmon stone. At that stage, the persimmon stone was divided into two parts. The procedures were repeated until the gastroliths were cut into small pieces with diameters ≤ 1.5 cm (Figure 2C-H). They smoothed the intestine, facilitated the removal of the cut gastrolith, and prevented intestinal obstruction. When the diameter of a gastric persimmon stone was extremely large, the surgery was performed in several steps to prevent repeated access to the endoscope that reduced the risk of throat, esophagus, and stomach wall damage, and the risk of anesthesia. After completing the treatment, fasting was continued, but the patients were instructed to drink 100–200 mL Coca-Cola every 6 h. After 48 h, gastroscopy was performed to



DOI: 10.12998/wjcc.v10.i19.6428 Copyright ©The Author(s) 2022.

Figure 1 Generation of the wire loop snares. A: A 0.025-inch diameter guidewire (Single-Use Guidewire; Olympus, Tokyo, Japan); B: An ultrafine endoscopic biopsy forcep (FB-231K; Olympus); C: The guidewire is pushed into the biopsy channel, and biopsy forceps is inserted into the biopsy channel afterward; D: The guidewire and biopsy forceps are passed through the endoscopic channel, and the front end of the gastroscope is covered by a transparent cap; E: The guidewire is passed through the lateral orifice at the head end of the biopsy forceps; F: The biopsy forceps are closed to clamp the guidewire; G: The biopsy forceps are pulled back until the guidewire is pulled out of the biopsy channel. During the procedure, the guidewire is delivered into the biopsy channel synchronously to keep an "O" shape of the loop snare extending from the biopsy channel; H: A guidewire loop snare with a variable diameter.

determine whether persimmon stones remained in the stomach and lithotripsy was repeated if residues were found.

Statistical methods

The statistical analysis was performed with SPSS software (version 22.0; IBM Corp., Armonk, NY, United States). Categorical variables were reported as numbers and percentages (%). Between-group differences were compared with χ^2 tests. Continuous variables were reported as means \pm SD, and between-group differences were compared by *t*-tests. $P < 0.05$ was considered statistically significant.

RESULTS

Patient baseline characteristics

The characteristics of the 38 patients included in the study are shown in Table 1. The observation group included 23 cases, with a median age of 63 (31–79) years and 74% males. The control group included 15 cases, with a median age of 58 (22–61) years and 67% females. The age and sex composition of the two groups and the presence of abdominal pain, abdominal distension, and vomiting were similar. Differences in melena and histories of hypertension, diabetes, coronary heart disease, and partial gastrectomy were not statistically significant.

Features of gastroliths

The locations of gastric persimmon stones in the two groups were similar. In the observation group, 11 (47.8%) were in the gastric corpus, four (17.4%) in the gastric fundus, five (21.7%) in the gastric antrum, and three (13.0%) in the remnant stomach. In the control group, nine (60.0%) stones were in the gastric corpus, three (20.0%) in the gastric fundus, two (13.3%) were in the gastric antrum, and one (6.7%) in the remnant stomach. The persimmon stones in the two groups were similar in size—between 4 and 9 (5.6 ± 1.7) cm in the observation group and 4 and 8 (5.5 ± 1.4) cm in the control group.

Upper digestive tract complications

The frequencies of digestive tract complications of persimmon stones were similar in both study groups. Concurrent stomach ulcers had the highest incidence (78.3% *vs* 73.3%), followed by duodenal ulcers (8.7% *vs* 6.7%) and esophagitis (8.7% *vs* 6.7%). The differences were not significant. During gastroscopy, a small number of patients were found to have other diseases, such as pyloric obstruction and gastric

Table 1 Clinical and upper endoscopic characteristics of patients

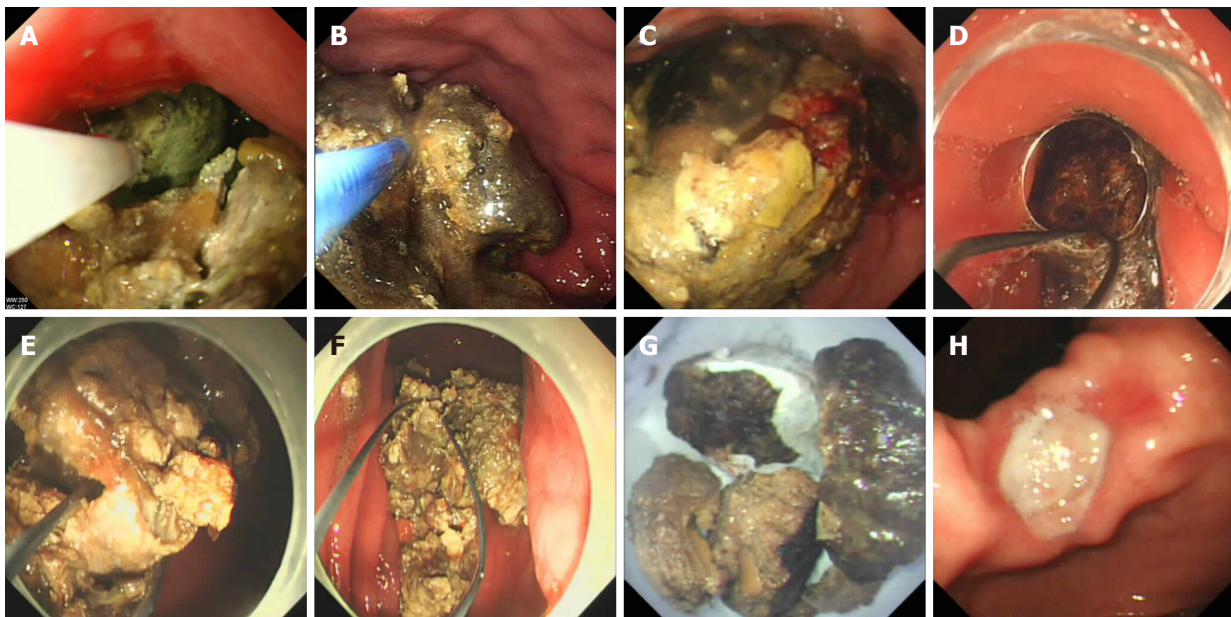
Variable	Observational group, <i>n</i> = 23	Control group, <i>n</i> = 15	Stats	<i>P</i> value
Male sex	17 (73.9)	10 (66.7)	0.013	0.91
Median age (yr), mean (range)	63 (31–79)	58 (22–61)	2.30	0.49
Main complaint				
Epigastric pain	23 (100)	14 (93.3)	0.048	0.83
Distention	12 (52.1)	8 (53.3)	0.005	0.94
Vomiting	5 (21.7)	3 (20.0)	0.017	0.90
Melena	2 (8.7)	2 (13.3)	0.203	0.65
Comorbidity				
Hypertension	21 (91.3)	11 (73.3)	1.061	0.30
Diabetes mellitus	6 (26.1)	2 (13.3)	0.287	0.59
Coronary heart disease	8 (34.8)	2 (13.3)	1.190	0.28
History of partial gastrectomy	3 (13.0)	1 (6.7)	0.007	0.93
Gastric phytobezoars location			1.022	0.80
Funds	4 (17.4)	3 (20.0)	–	–
Body	11 (47.8)	9 (60.0)	–	–
Antrum	5 (21.7)	2 (13.3)	–	–
Gastric remnant	3 (13.0)	1 (6.7)	–	–
Phytobezoar longest diameter in cm, mean ± SD (range)	5.6 ± 1.7 (4–9)	5.5 ± 1.4 (4–8)	0.190	0.721
Other endoscopic findings			0.394	0.941
Gastric ulcer	18 (78.3)	11 (73.3)	–	–
Duodenal ulcer	2 (8.7)	1 (6.7)	–	–
Reflux esophagitis	2 (8.7)	1 (6.7)	–	–
Other ¹	3 (13.0)	3 (20)	–	–
Number of passes			36.212	< 0.001
1	20	1	–	–
2	3	2	–	–
3	0	7	–	–
4	0	4	–	–
5	0	1	–	–
Operating time in min	53.4 ± 7.2	172.8 ± 13.5	35.536	< 0.001
Hospital stay in d	5.4 ± 1.2	10.3 ± 1.8	10.095	< 0.001

¹Pyloric obstruction, gastric cancer. Data are *n* (%) or mean ± SD, unless indicated otherwise.

cancer.

Treatment success rate

The 23 patients in the observation group were treated by endoscopic lithotripsy using self-made guidewire loop snares. Before discharge, all gastroliths had been emptied through the gastroscope and finally discharged through the intestine. The treatment success rate was 100%. In the 15 control group patients, traditional tools were used for lithotripsy or stone removal, with seven being treated with snares and wire baskets, three with snares and foreign-body forceps, three with injection needles and foreign-body forceps, and two with injection needles and wire baskets. No gastric stones were found before discharge. The success rate of the treatment was also 100%. In the observation group, the first treatment was successful in 20 patients, and three patients needed a second treatment. In the control group, the first treatment was successful in only one patient. Two patients required a second treatment,



DOI: 10.12998/wjcc.v10.i19.6428 Copyright ©The Author(s) 2022.

Figure 2 Endoscopic treatment of a persimmon stone. A and B: A gastric persimmon stone grasped with a foreign body plier (A) and with a traditional snare (B); C: Large gastric persimmon stones observed during endoscopy; D: After covering the front end of the gastroscope with a transparent cap, the guidewire loop is prepared and returned into the transparent cap to enter the stomach; E: The diameter of the guidewire loop snare is adjusted according to the diameter of the gastric persimmon stone. Both ends of the guidewire are then pulled back and forth, after which the stone is cut into small pieces by tightening the guidewire loop snare; F: Following repeated excision, the huge stone is cut into small pieces; G: The small pieces of persimmon stones are removed from the stomach; H: The entire stomach is carefully observed after removal of the stone, with discovery of a gastric ulcer in the incisura angularis.

seven required three treatments, four required four treatments, and one required five treatments. The one-time treatment success rate of the observation group was significantly higher than that of the control group (86.96% *vs* 6.67%, $P < 0.001$).

Operating time and hospital stay

The average operating time of the observation group was significantly lower than that of the control group (53.4 min *vs* 172.8 min), and the average hospital stay was significantly shorter than that of the control group (5.4 d *vs* 10.3 d, $P < 0.001$).

DISCUSSION

Patients with subtotal gastrectomy, vagus nerve amputation, or gastroparesis syndrome are prone to gastrolithiasis, which may be associated with factors like low gastric acid, gastric emptying disorder, and pyloric dysfunction that lead to conditions in which undigested food remains in the stomach for a long time[1]. In our study, 21.0% (8/38) of the patients had diabetes and 10.5% (4/38) had a history of gastric surgery, indicating that the formation of gastroliths was associated with physiological disorders of the stomach.

Gastrolithiasis is most often caused by eating the flesh of persimmons or dried persimmons, which contain highly astringent tannic acid, pectin, and other substances. In the presence of gastric acid, they combine with food proteins to form water-insoluble tannins that are deposited in the stomach and then bind to nondigestible plant fibers to form gastric stones[4]. Friction of the gastric stones against the stomach wall stimulates secretion of gastric acid, while the weight of the stones compresses the stomach wall. The formation of stones can lead to avascular necrosis of local tissues, gastric mucosal erosion, ulcers, bleeding, and perforation. Repeated stimulation can cause pyloric scar stenosis[8]. If a diagnosis of gastrolithiasis is confirmed, then the patient should be actively treated. Gastric ulcers are the most common complication of gastrolithiasis, with an incidence rate of approximately 60%–70%[8], which is consistent with the 63.2% (24/38) in this study. The results indicate that the upper digestive tract should be carefully evaluated after successful stone removal, especially the stomach, to check whether there are some other lesions.

Treatment of plant-based gastroliths include stone dissolution, endoscopy, and surgery. Litholytic treatments include sodium bicarbonate solution and a variety of protease preparations that can soften, shrink or dissolve gastric stones as a single treatment, or as an auxiliary treatment before and after endoscopic treatment[13]. If drugs and endoscopy are not effective, patients need surgery. The use of

Coca-Cola to treat gastroliths is a simple and easy solution that was first reported by Ladas *et al*[14] in 2002. Subsequent studies have reported the dissolution and disappearance of gastroliths by drinking or nasogastric feeding of Coca-Cola[15]. Multiple injections of Coca-Cola into the gastrolith have been performed to make the gastrolith soft enough for mechanical crushing[15]. Gastrolith fragments can be quickly disintegrated using Coca-Cola. The ingredients in Coca-Cola that dissolve plant-based gastroliths and the dissolution mechanism are currently unclear. The effect may depend upon the acidification of gastric contents by Coca-Cola, which has a pH of 2.6, and the release of CO₂ bubbles that fragment gastroliths[14].

Endoscopic mechanical lithotripsy is the primary method of treating large gastroliths. It involves the use of foreign body forceps, three-jaw forceps, injection needles, snares, net baskets, and other tools to cut gastroliths into small pieces under the direct view of the gastroscope. The pieces are then taken out or discharged through the intestines. Some hospitals use lasers or high-frequency electric lithotripsy simultaneously[1,13]. We used self-made wire loop snares to crush the stones mechanically. The treatment efficiency was significantly improved compared with controls, and the mean number of gastroscopy treatments for successful removal decreased from 3.13 to 1.13. The mean procedure time decreased by 119.4 min, and hospital stay decreased by 4.9 d.

Commercially available snares currently have small diameters and cannot completely surround stones to complete the cutting, and must be combined with foreign body forceps, injection needles, and other instruments. After the surface of the persimmon stone has been crushed, repeated cutting makes the persimmon stone smaller, but in this study, the operating time was long, and the treatment efficiency was low. Moreover, repeated access to the lens increases the risk of damage to the throat, esophagus, and stomach wall tissues. The snare wire is easily deformed during the cutting process[16]. In the control group, the patients needed three to five lithotripsy treatments to be cured, which increased the cost of treatment. The size of the self-made guidewire loop snare was adjustable, the persimmon stone was completely covered, cut into two pieces, then repeatedly cut into countless small pieces, and finally discharged through the intestine. In all 23 patients in the observation group, we cut the persimmon stone into countless small pieces, and during one procedure in 20 patients. Gastroscopy performed on the next day found that persimmon stones were completely removed from the stomach. Compared with traditional tools, the self-made guidewire loop snares significantly shortened the endoscopic lithotripsy time, reduced equipment-associated damage, shortened the hospital stay, and saved medical costs.

We have several points of experience with this technology: (1) Before surgery, 48 h of drinking Coca-Cola softened the surface of the persimmon stone, and thus made it easier to trap the persimmon stone with for the guidewire loop snare[15]. The softened persimmon stones were then easy to cut. Fasting and drinking Coca-Cola were recommended after lithotripsy, rechecking was performed by gastroscopy after 24 h; (2) Before lithotripsy, a transparent cap was placed on the front end of the gastroscope, and while cutting the persimmon stone, damage to the lens by the stone was prevented by maintaining a certain distance between it and the lens. This procedure ensured a clear endoscope lens for the entire operation; (3) While cutting the stone, the plastic-coated guidewire repeatedly rubbed against the stone, promoted peeling, and facilitated the operation. Using a bare guidewire with no plastic coating on the surface is recommended; (4) Before trapping the persimmon stone, the gastric cavity was filled with gas to ensure that the gastric mucosal folds were not trapped behind the stone in the blind area of the visual field. However, excessive inflation can cause cardia mucosal tears and postoperative abdominal distension. After the persimmon stone was trapped, it was moved to determine whether the snare had trapped the gastric mucosa; (5) In the cutting process, tightening one end of the guidewire after the other was better than simultaneously tightening both ends. When cutting was almost complete, the force needed to tighten the guidewire was reduced. When a miss was felt, tightening of the guidewire was stopped. This step prevented the guidewire loop from being pulled into the biopsy forceps and damaging the lens and the forceps; and (6) Intestinal obstruction was prevented by cutting the persimmon stones into small pieces with widths of less than 1.5 cm. In 23 patients, small pieces of persimmon stones were safely discharged through the intestines, and no intestinal obstructions occurred.

However, the study had some limitations. The sample size was small, and the retrospective design did not allow controlling for factors that could confound the comparison. A prospective randomized controlled study with a larger sample size is needed to verify the safety and effectiveness of these self-made wire loop snares.

CONCLUSION

Self-made guidewire loop snares were successfully used to treat gastrolithiasis, and were significantly more effective than foreign body forceps, snares, and other traditional methods.

ARTICLE HIGHLIGHTS

Research background

Two of the most important disadvantages of endoscopic treatment are the length of the procedure time and the risk of aspiration. Existing endoscopic devices are inadequate for large gastric phytobezoars; therefore, our team invented a hand-made tool to solve those problems.

Research motivation

Large gastric persimmon stones are generally resistant to standard endoscopic treatments. As such, a novel, better solution is needed.

Research objectives

The study objective was to explore the clinical efficacy of self-made wire loop snares in treating giant gastric persimmon stones.

Research methods

The clinical data of 38 patients with gastroliths and who were treated by endoscopic lithotripsy at Taihe Hospital were evaluated retrospectively. The study included an observation group of 23 patients treated with self-made wire loop snares and a control group of 15 patients treated with traditional foreign body forceps, snares, injection needles, and other tools. The rates of successful stone removal, the time needed to perform the treatment, and the length of the hospital stay, and medical costs were compared.

Research results

The self-made guidewire loop snares significantly shortened the lithotripsy time under gastroscopy, reduced equipment-associated damage, shortened hospital stay, and saved medical costs.

Research conclusions

We reported our experience using self-made guidewire loop snares for the endoscopic treatment of large gastric phytobezoars. The two main advantages of our snare are that the sheath and guidewire can be readily available in almost every endoscopy unit and the procedure can be performed with a standard gastroscope. Furthermore, the guidewire can be easily guided through the sheath to capture the bezoar, resulting in a significantly shorter procedure time than needed with other methods.

Research perspectives

The self-made snares successfully grasped large-sized gastric bezoars and fragmented them into small pieces in all patients. A prospective randomized controlled study and a larger patient sample is needed to confirm the safety and effectiveness of the self-made wire loop snare.

FOOTNOTES

Author contributions: Deng WP and Xu W conceived and designed this study; Xu W and Liu XB searched the literature and collected the data; Li SB and Tong Q performed the statistical analysis and interpreted the data; Xu W and Liu XB wrote the manuscript; All authors read and approved the final manuscript.

Supported by 2016 Joint Diagnostic Medicine Research Project of Taihe Hospital, No. 2016JD02.

Institutional review board statement: This study was approved by the Ethics Committee of the Shiyan Taihe Hospital, No. 2021KS041.

Conflict-of-interest statement: The authors declare that they have no conflicting interests.

Data sharing statement: Data sharing statement.

Open-Access: This article is an open-access article that was selected by an in-house editor and fully peer-reviewed by external reviewers. It is distributed in accordance with the Creative Commons Attribution NonCommercial (CC BY-NC 4.0) license, which permits others to distribute, remix, adapt, build upon this work non-commercially, and license their derivative works on different terms, provided the original work is properly cited and the use is non-commercial. See: <https://creativecommons.org/licenses/by-nc/4.0/>

Country/Territory of origin: China

ORCID number: Wen Xu 0000-0002-6348-4802; Xiao-Bo Liu 0000-0002-1250-2134; Sheng-Bao Li 0000-0001-9808-2099; Wei-Ping Deng 0000-0002-2563-1672; Qiang Tong 0000-0002-5375-8224.

S-Editor: Fan JR

L-Editor: Kerr C

P-Editor: Fan JR

REFERENCES

- 1 **Shah M**, Wan DQ, Liu Y, Rhoads JM. Gastric Bezoar: Retrieve it, Leave it, or Disbelieve it? *J Pediatr Gastroenterol Nutr* 2021; **72**: e31-e36 [PMID: [32833895](#) DOI: [10.1097/MPG.0000000000002923](#)]
- 2 **Aryannezhad S**, Sadeghian Y, Shapoori P, Valizadeh M, Barzin M. A rare case report of late-onset phytobezoar formation following laparoscopic sleeve gastrectomy: delayed redo bariatric surgery. *BMC Surg* 2021; **21**: 254 [PMID: [34022864](#) DOI: [10.1186/s12893-021-01254-8](#)]
- 3 **Liu LN**, Wang L, Jia SJ, Wang P. Clinical Features, Risk Factors, and Endoscopic Treatment of Bezoars: A Retrospective Analysis from a Single Center in Northern China. *Med Sci Monit* 2020; **26**: e926539 [PMID: [33027245](#) DOI: [10.12659/MSM.926539](#)]
- 4 **Paschos KA**, Chatzigeorgiadis A. Pathophysiological and clinical aspects of the diagnosis and treatment of bezoars. *Ann Gastroenterol* 2019; **32**: 224-232 [PMID: [31040619](#) DOI: [10.20524/aog.2019.0370](#)]
- 5 **Hemmasi G**, Zanganeh E, Hosseini SA, Alimadadi M, Ahmadi A, Hajiebrahimi S, Seyyedmajidi M. Risk factors, endoscopic findings, and treatments in upper gastrointestinal bezoars: multi-center experience in Iran. *Gastroenterol Hepatol Bed Bench* 2021; **14**: 160-164 [PMID: [33968343](#)]
- 6 **Chen WW**, Gao RL, Liu LS, Zhu ML, Wang W, Wang YJ, Wu ZS, Li HJ, Gu DF, Yang YJ, Zheng Z, Jiang LX, Hu SS. China cardiovascular diseases report 2015: a summary. *J Geriatr Cardiol* 2017; **14**: 1-10 [PMID: [28270835](#) DOI: [10.11909/j.issn.1671-5411.2017.01.012](#)]
- 7 **Tan F**, Mo H, He X, Pei H. An unusual case of gastric outlet obstruction caused by multiple giant persimmon phytobezoars. *Gastroenterol Rep (Oxf)* 2019; **7**: 74-76 [PMID: [28011861](#) DOI: [10.1093/gastro/gow042](#)]
- 8 **Lin L**, Wang C, Wu J, Liu K, Liu H, Wei N, Lin W, Jiang G, Tai W, Su H. Gastric phytobezoars: the therapeutic experience of 63 patients in Northern China. *Rev Esp Enferm Dig* 2020; **112**: 12-15 [PMID: [31599640](#) DOI: [10.17235/reed.2019.6400/2019](#)]
- 9 **Mejri A**, Trigui E. Phytobezoar: A train can hide another. *Int J Surg Case Rep* 2021; **81**: 105814 [PMID: [33887864](#) DOI: [10.1016/j.ijscr.2021.105814](#)]
- 10 **Wang TT**, He JJ, Liu J, Chen WW, Chen CW. Acute pancreatitis and small bowel obstruction caused by a migratory gastric bezoar after dissolution therapy: A case report. *World J Clin Cases* 2021; **9**: 3114-3119 [PMID: [33969098](#) DOI: [10.12998/wjcc.v9.i13.3114](#)]
- 11 **Jinushi R**, Yano T, Imamura N, Ishii N. Endoscopic treatment for a giant gastric bezoar: Sequential use of electrohydraulic lithotripsy, alligator forceps, and snares. *JGH Open* 2021; **5**: 522-524 [PMID: [33860105](#) DOI: [10.1002/jgh3.12491](#)]
- 12 **Blam ME**, Lichtenstein GR. A new endoscopic technique for the removal of gastric phytobezoars. *Gastrointest Endosc* 2000; **52**: 404-408 [PMID: [10968861](#) DOI: [10.1067/mge.2000.108407](#)]
- 13 **Özsoy Z**, Okan İ. Treatment of phytobezoars: Tailoring management to diverse presentations. *Turk J Surg* 2018; **34**: 33-37 [PMID: [29756104](#) DOI: [10.5152/turkjsurg.2017.3770](#)]
- 14 **Ladas SD**, Triantafyllou K, Tzathas C, Tassios P, Rokkas T, Raptis SA. Gastric phytobezoars may be treated by nasogastric Coca-Cola lavage. *Eur J Gastroenterol Hepatol* 2002; **14**: 801-803 [PMID: [12169994](#) DOI: [10.1097/00042737-200207000-00017](#)]
- 15 **Lee BJ**, Park JJ, Chun HJ, Kim JH, Yeon JE, Jeon YT, Kim JS, Byun KS, Lee SW, Choi JH, Kim CD, Ryu HS, Bak YT. How good is cola for dissolution of gastric phytobezoars? *World J Gastroenterol* 2009; **15**: 2265-2269 [PMID: [19437568](#) DOI: [10.3748/wjg.15.2265](#)]
- 16 **Misra SP**, Dwivedi M, Misra V. Endoscopic management of a new entity-plastobezoar: a case report and review of literature. *World J Gastroenterol* 2006; **12**: 6730-6733 [PMID: [17075994](#) DOI: [10.3748/wjg.v12.i41.6730](#)]



Published by **Baishideng Publishing Group Inc**
7041 Koll Center Parkway, Suite 160, Pleasanton, CA 94566, USA

Telephone: +1-925-3991568

E-mail: bpgoffice@wjgnet.com

Help Desk: <https://www.f6publishing.com/helpdesk>

<https://www.wjgnet.com>

