

World Journal of *Clinical Cases*

World J Clin Cases 2022 July 6; 10(19): 6341-6758



Contents

Thrice Monthly Volume 10 Number 19 July 6, 2022

MINIREVIEWS

- 6341** Review of clinical characteristics, immune responses and regulatory mechanisms of hepatitis E-associated liver failure
Chen C, Zhang SY, Chen L
- 6349** Current guidelines for *Helicobacter pylori* treatment in East Asia 2022: Differences among China, Japan, and South Korea
Cho JH, Jin SY
- 6360** Review of epidermal growth factor receptor-tyrosine kinase inhibitors administration to non-small-cell lung cancer patients undergoing hemodialysis
Lan CC, Hsieh PC, Huang CY, Yang MC, Su WL, Wu CW, Wu YK

ORIGINAL ARTICLE

Case Control Study

- 6370** Pregnancy-related psychopathology: A comparison between pre-COVID-19 and COVID-19-related social restriction periods
Chieffo D, Avallone C, Serio A, Kotzalidis GD, Balocchi M, De Luca I, Hirsch D, Gonzalez del Castillo A, Lanzotti P, Marano G, Rinaldi L, Lanzone A, Mercuri E, Mazza M, Sani G
- 6385** Intestinal mucosal barrier in functional constipation: Does it change?
Wang JK, Wei W, Zhao DY, Wang HF, Zhang YL, Lei JP, Yao SK

Retrospective Cohort Study

- 6399** Identification of risk factors for surgical site infection after type II and type III tibial pilon fracture surgery
Hu H, Zhang J, Xie XG, Dai YK, Huang X

Retrospective Study

- 6406** Total knee arthroplasty in Ranawat II valgus deformity with enlarged femoral valgus cut angle: A new technique to achieve balanced gap
Lv SJ, Wang XJ, Huang JF, Mao Q, He BJ, Tong PJ
- 6417** Preliminary evidence in treatment of eosinophilic gastroenteritis in children: A case series
Chen Y, Sun M
- 6428** Self-made wire loop snare successfully treats gastric persimmon stone under endoscopy
Xu W, Liu XB, Li SB, Deng WP, Tong Q
- 6437** Neoadjuvant transcatheter arterial chemoembolization and systemic chemotherapy for the treatment of undifferentiated embryonal sarcoma of the liver in children
He M, Cai JB, Lai C, Mao JQ, Xiong JN, Guan ZH, Li LJ, Shu Q, Ying MD, Wang JH

- 6446** Effect of cold snare polypectomy for small colorectal polyps

Meng QQ, Rao M, Gao PJ

- 6456** Field evaluation of COVID-19 rapid antigen test: Are rapid antigen tests less reliable among the elderly?

Tabain I, Cucevic D, Skreb N, Mrzljak A, Ferencak I, Hruskar Z, Misic A, Kuzle J, Skoda AM, Jankovic H, Vilibic-Cavlek T

Observational Study

- 6464** Tracheobronchial intubation using flexible bronchoscopy in children with Pierre Robin sequence: Nursing considerations for complications

Ye YL, Zhang CF, Xu LZ, Fan HF, Peng JZ, Lu G, Hu XY

- 6472** Family relationship of nurses in COVID-19 pandemic: A qualitative study

Çelik MY, Kiliç M

META-ANALYSIS

- 6483** Diagnostic accuracy of ≥ 16 -slice spiral computed tomography for local staging of colon cancer: A systematic review and meta-analysis

Liu D, Sun LM, Liang JH, Song L, Liu XP

CASE REPORT

- 6496** Delayed-onset endophthalmitis associated with *Achromobacter* species developed in acute form several months after cataract surgery: Three case reports

Kim TH, Lee SJ, Nam KY

- 6501** Sustained dialysis with misplaced peritoneal dialysis catheter outside peritoneum: A case report

Shen QQ, Behera TR, Chen LL, Attia D, Han F

- 6507** Arteriovenous thrombotic events in a patient with advanced lung cancer following bevacizumab plus chemotherapy: A case report

Kong Y, Xu XC, Hong L

- 6514** Endoscopic ultrasound radiofrequency ablation of pancreatic insulinoma in elderly patients: Three case reports

Rossi G, Petrone MC, Capurso G, Partelli S, Falconi M, Arcidiacono PG

- 6520** Acute choroidal involvement in lupus nephritis: A case report and review of literature

Yao Y, Wang HX, Liu LW, Ding YL, Sheng JE, Deng XH, Liu B

- 6529** Triple A syndrome-related achalasia treated by per-oral endoscopic myotomy: Three case reports

Liu FC, Feng YL, Yang AM, Guo T

- 6536** Choroidal thickening with serous retinal detachment in BRAF/MEK inhibitor-induced uveitis: A case report

Kiraly P, Groznik AL, Valentinčič NV, Mekjavić PJ, Urbančič M, Ocvirk J, Mesti T

- 6543** Esophageal granular cell tumor: A case report

Chen YL, Zhou J, Yu HL

- 6548** Hem-o-lok clip migration to the common bile duct after laparoscopic common bile duct exploration: A case report
Liu DR, Wu JH, Shi JT, Zhu HB, Li C
- 6555** Chidamide and sintilimab combination in diffuse large B-cell lymphoma progressing after chimeric antigen receptor T therapy
Hao YY, Chen PP, Yuan XG, Zhao AQ, Liang Y, Liu H, Qian WB
- 6563** Relapsing polychondritis with isolated tracheobronchial involvement complicated with Sjogren's syndrome: A case report
Chen JY, Li XY, Zong C
- 6571** Acute methanol poisoning with bilateral diffuse cerebral hemorrhage: A case report
Li J, Feng ZJ, Liu L, Ma YJ
- 6580** Immunoabsorption therapy for Klinefelter syndrome with antiphospholipid syndrome in a patient: A case report
Song Y, Xiao YZ, Wang C, Du R
- 6587** Roxadustat for treatment of anemia in a cancer patient with end-stage renal disease: A case report
Zhou QQ, Li J, Liu B, Wang CL
- 6595** Imaging-based diagnosis for extraskeletal Ewing sarcoma in pediatrics: A case report
Chen ZH, Guo HQ, Chen JJ, Zhang Y, Zhao L
- 6602** Unusual course of congenital complete heart block in an adult: A case report
Su LN, Wu MY, Cui YX, Lee CY, Song JX, Chen H
- 6609** Penile metastasis from rectal carcinoma: A case report
Sun JJ, Zhang SY, Tian JJ, Jin BY
- 6617** Isolated cryptococcal osteomyelitis of the ulna in an immunocompetent patient: A case report
Ma JL, Liao L, Wan T, Yang FC
- 6626** Magnetic resonance imaging features of intrahepatic extramedullary hematopoiesis: Three case reports
Luo M, Chen JW, Xie CM
- 6636** Giant retroperitoneal liposarcoma treated with radical conservative surgery: A case report and review of literature
Lieto E, Cardella F, Erario S, Del Sorbo G, Reginelli A, Galizia G, Urraro F, Panarese I, Auricchio A
- 6647** Transplanted kidney loss during colorectal cancer chemotherapy: A case report
Pośpiech M, Kolonko A, Nieszporek T, Kozak S, Kozaczka A, Karkoszka H, Winder M, Chudek J
- 6656** Massive gastrointestinal bleeding after endoscopic rubber band ligation of internal hemorrhoids: A case report
Jiang YD, Liu Y, Wu JD, Li GP, Liu J, Hou XH, Song J

- 6664** Mills' syndrome is a unique entity of upper motor neuron disease with N-shaped progression: Three case reports
Zhang ZY, Ouyang ZY, Zhao GH, Fang JJ
- 6672** Entire process of electrocardiogram recording of Wellens syndrome: A case report
Tang N, Li YH, Kang L, Li R, Chu QM
- 6679** Retroperitoneal tumor finally diagnosed as a bronchogenic cyst: A case report and review of literature
Gong YY, Qian X, Liang B, Jiang MD, Liu J, Tao X, Luo J, Liu HJ, Feng YG
- 6688** Successful treatment of Morbihan disease with total glucosides of paeony: A case report
Zhou LF, Lu R
- 6695** Ant sting-induced whole-body pustules in an inebriated male: A case report
Chen SQ, Yang T, Lan LF, Chen XM, Huang DB, Zeng ZL, Ye XY, Wan CL, Li LN
- 6702** Plastic surgery for giant metastatic endometrioid adenocarcinoma in the abdominal wall: A case report and review of literature
Wang JY, Wang ZQ, Liang SC, Li GX, Shi JL, Wang JL
- 6710** Delayed-release oral mesalamine tablet mimicking a small jejunal gastrointestinal stromal tumor: A case report
Frosio F, Rausa E, Marra P, Boutron-Ruault MC, Lucianetti A
- 6716** Concurrent alcoholic cirrhosis and malignant peritoneal mesothelioma in a patient: A case report
Liu L, Zhu XY, Zong WJ, Chu CL, Zhu JY, Shen XJ
- 6722** Two smoking-related lesions in the same pulmonary lobe of squamous cell carcinoma and pulmonary Langerhans cell histiocytosis: A case report
Gencer A, Ozcibik G, Karakas FG, Sarbay I, Batur S, Borekci S, Turna A
- 6728** Proprotein convertase subtilisin/kexin type 9 inhibitor non responses in an adult with a history of coronary revascularization: A case report
Yang L, Xiao YY, Shao L, Ouyang CS, Hu Y, Li B, Lei LF, Wang H
- 6736** Multimodal imaging study of lipemia retinalis with diabetic retinopathy: A case report
Zhang SJ, Yan ZY, Yuan LF, Wang YH, Wang LF
- 6744** Primary squamous cell carcinoma of the liver: A case report
Kang LM, Yu DP, Zheng Y, Zhou YH
- 6750** Tumor-to-tumor metastasis of clear cell renal cell carcinoma to contralateral synchronous pheochromocytoma: A case report
Wen HY, Hou J, Zeng H, Zhou Q, Chen N

ABOUT COVER

Editorial Board Member of *World Journal of Clinical Cases*, Abdulqadir Jeprel Naswhan, MSc, RN, Director, Research Scientist, Senior Lecturer, Senior Researcher, Nursing for Education and Practice Development, Hamad Medical Corporation, Doha 576214, Qatar. anashwan@hamad.qa

AIMS AND SCOPE

The primary aim of *World Journal of Clinical Cases* (WJCC, *World J Clin Cases*) is to provide scholars and readers from various fields of clinical medicine with a platform to publish high-quality clinical research articles and communicate their research findings online.

WJCC mainly publishes articles reporting research results and findings obtained in the field of clinical medicine and covering a wide range of topics, including case control studies, retrospective cohort studies, retrospective studies, clinical trials studies, observational studies, prospective studies, randomized controlled trials, randomized clinical trials, systematic reviews, meta-analysis, and case reports.

INDEXING/ABSTRACTING

The WJCC is now indexed in Science Citation Index Expanded (also known as SciSearch®), Journal Citation Reports/Science Edition, Scopus, PubMed, and PubMed Central. The 2021 Edition of Journal Citation Reports® cites the 2020 impact factor (IF) for WJCC as 1.337; IF without journal self cites: 1.301; 5-year IF: 1.742; Journal Citation Indicator: 0.33; Ranking: 119 among 169 journals in medicine, general and internal; and Quartile category: Q3. The WJCC's CiteScore for 2020 is 0.8 and Scopus CiteScore rank 2020: General Medicine is 493/793.

RESPONSIBLE EDITORS FOR THIS ISSUE

Production Editor: Xu Guo; Production Department Director: Xiang Li; Editorial Office Director: Jin-Lai Wang.

NAME OF JOURNAL

World Journal of Clinical Cases

ISSN

ISSN 2307-8960 (online)

LAUNCH DATE

April 16, 2013

FREQUENCY

Thrice Monthly

EDITORS-IN-CHIEF

Bao-Gan Peng, Jerzy Tadeusz Chudek, George Kontogeorgos, Maurizio Serati, Ja Hyeon Ku

EDITORIAL BOARD MEMBERS

<https://www.wjgnet.com/2307-8960/editorialboard.htm>

PUBLICATION DATE

July 6, 2022

COPYRIGHT

© 2022 Baishideng Publishing Group Inc

INSTRUCTIONS TO AUTHORS

<https://www.wjgnet.com/bpg/gerinfo/204>

GUIDELINES FOR ETHICS DOCUMENTS

<https://www.wjgnet.com/bpg/GerInfo/287>

GUIDELINES FOR NON-NATIVE SPEAKERS OF ENGLISH

<https://www.wjgnet.com/bpg/gerinfo/240>

PUBLICATION ETHICS

<https://www.wjgnet.com/bpg/GerInfo/288>

PUBLICATION MISCONDUCT

<https://www.wjgnet.com/bpg/gerinfo/208>

ARTICLE PROCESSING CHARGE

<https://www.wjgnet.com/bpg/gerinfo/242>

STEPS FOR SUBMITTING MANUSCRIPTS

<https://www.wjgnet.com/bpg/GerInfo/239>

ONLINE SUBMISSION

<https://www.f6publishing.com>



Choroidal thickening with serous retinal detachment in BRAF/MEK inhibitor-induced uveitis: A case report

Peter Kiraly, Alenka Lavrič Groznik, Nataša Vidovič Valentinčič, Polona Jaki Mekjavić, Mojca Urbančič, Janja Ocvirk, Tanja Mesti

Specialty type: Oncology

Provenance and peer review:

Unsolicited article; Externally peer reviewed.

Peer-review model: Single blind

Peer-review report's scientific quality classification

Grade A (Excellent): 0
Grade B (Very good): B
Grade C (Good): C
Grade D (Fair): 0
Grade E (Poor): 0

P-Reviewer: Au SCL, China;
Kapritsou M, Greece

Received: September 13, 2021

Peer-review started: September 13, 2021

First decision: January 10, 2022

Revised: November 12, 2021

Accepted: May 8, 2022

Article in press: May 8, 2022

Published online: July 6, 2022



Peter Kiraly, Alenka Lavrič Groznik, Nataša Vidovič Valentinčič, Polona Jaki Mekjavić, Mojca Urbančič, Eye Hospital, University Medical Centre Ljubljana, Grablovičeva 46, SI-1000 Ljubljana, Slovenia

Peter Kiraly, Oxford Eye Hospital, Oxford University Hospitals NHS Foundation Trust, OX3 9DU, Oxford, United Kingdom

Janja Ocvirk, Tanja Mesti, Department of Medical Oncology, Institute of Oncology Ljubljana, Faculty of Medicine, University of Ljubljana, Ljubljana 1000, Slovenia

Corresponding author: Tanja Mesti, PhD, Assistant Professor, Department of Medical Oncology, Institute of Oncology Ljubljana, Zaloška 2, Ljubljana 1000, Slovenia. tmesti@onko-i.si

Abstract

BACKGROUND

Immune checkpoint inhibitors have revolutionized the treatment of patients with unresectable metastatic malignant melanoma. In addition to systemic side effects, several usually mild ocular adverse effects have been reported. We report a case of rarely reported vision-threatening bilateral panuveitis with serous retinal detachment, thickened choroid, and chorioretinal folds associated with dabrafenib and trametinib targeted therapy for B-Raf proto-oncogene serine/threonine kinase (BRAF) mutant metastatic cutaneous melanoma.

CASE SUMMARY

A 59-year-old female patient with metastatic melanoma treated with dabrafenib and trametinib presented with blurry vision and central scotoma lasting for 3 d in both eyes. Clinical examination and multimodal imaging revealed inflammatory cells in the anterior chamber, mild vitritis, bullous multiple serous retinal detachments, and chorioretinal folds in both eyes. Treatment with dabrafenib and trametinib was suspended, and the patient was treated with topical and intravenous corticosteroids followed by oral corticosteroid treatment with a tapering schedule. One and a half months after the disease onset, ocular morphological and functional improvement was noted. Due to the metastatic melanoma dissemination, BRAF/mitogen-activated protein kinase inhibitors were reintroduced and some mild ocular adverse effects reappeared, which later subsided after receiving oral corticosteroids.

CONCLUSION

Patients on combination therapy with dabrafenib and trametinib may rarely develop severe bilateral panuveitis with a good prognosis. Further studies have to establish potential usefulness of ophthalmological examination for asymptomatic patients. Furthermore, appropriate guidelines for managing panuveitis associated with dabrafenib and trametinib should be established.

Key Words: Metastatic melanoma treatment; BRAF/MEK inhibitors; Dabrafenib and trametinib; Ocular adverse effects; Bilateral panuveitis; Case report

©The Author(s) 2022. Published by Baishideng Publishing Group Inc. All rights reserved.

Core Tip: The effectiveness of B-Raf proto-oncogene serine/threonine kinase (BRAF)/mitogen-activated protein kinase (MEK) inhibitor therapy in terms of prolonging survival has revolutionized the treatment of metastatic melanoma and other cancers. Consequently, widespread use in several metastatic cancers could be anticipated in the future. Therefore, all possible adverse effects should be described. We report a case of very rare and severe bilateral panuveitis with transient visual loss associated with treatment of metastatic malignant melanoma. The purpose of our case report is to raise awareness of possible severe bilateral panuveitis associated with immune checkpoint inhibitor therapy and to show that ocular symptoms subside with BRAF/MEK inhibitor discontinuation and/or systemic corticosteroids. Further studies should establish guidelines for panuveitis management and evaluate the importance of ophthalmological examination for asymptomatic patients.

Citation: Király P, Groznik AL, Valentinčič NV, Mekjavić PJ, Urbančič M, Ocvirk J, Mesti T. Choroidal thickening with serous retinal detachment in BRAF/MEK inhibitor-induced uveitis: A case report. *World J Clin Cases* 2022; 10(19): 6536-6542

URL: <https://www.wjgnet.com/2307-8960/full/v10/i19/6536.htm>

DOI: <https://dx.doi.org/10.12998/wjcc.v10.i19.6536>

INTRODUCTION

Targeted therapy drugs including B-Raf proto-oncogene serine/threonine kinase (BRAF) and mitogen-activated protein kinase (MEK) inhibitors have markedly improved the progression-free survival rate in unresectable BRAF mutant metastatic melanoma[1]. Both drugs inhibit the mitogen-activated protein kinase (MAPK) pathway and are commonly used in combination because BRAF inhibitor monotherapy resistance usually develops in 6-8 mo[2]. MEK inhibitors in combination help to overcome the described resistance, which further prolongs the overall survival[3]. Although benefits on overall survival rate are unequivocal, several adverse effects have been reported[4]. In patients on MEK inhibitor treatment, ocular adverse effects are very common, with an incidence of up to 90%. Ocular side effects range from blurred vision, periorbital oedema, and dry eyes to retinal toxicities such as MEK-associated retinopathy, retinal vein occlusion, and panuveitis[5]. A study reported ocular adverse effects in 22% of 568 patients treated with the BRAF inhibitor vemurafenib. The most common side effects were uveitis (4%), conjunctivitis (2.8%), and dry eyes (2.0%)[6]. A small case series of seven patients on vemurafenib treatment for metastatic melanoma reported bilateral non-granulomatous anterior uveitis as a side effect that responded well to local corticosteroid therapy, justifying continuation of vemurafenib treatment. In one patient, explosive bilateral panuveitis with hand movements visual acuity was described[7]. Although there are some published studies investigating ocular adverse effects with BRAF or MEK inhibitor monotherapy, there are only few case reports describing ocular side effect associated with the combination therapy with dabrafenib and trametinib[8-10]. Albertini *et al*[8] published a case report in which dabrafenib and trametinib therapy was associated with multifocal choroiditis reactivation and secondary choroidal neovascularization, which were successfully treated with ranibizumab. Another case report with the same combination therapy was published, reporting a patient with bilateral non-granulomatous panuveitis, pachychoroid, chorioretinal folds, and multiple foci of subretinal fluid accumulation. In this study, dabrafenib discontinuation and local corticosteroid treatment resulted in improved visual acuity and resolved serous neurosensory detachments[9]. Another article reporting a patient on dabrafenib and trametinib therapy described bilateral intermediate uveitis with late optic disc fluorescein leakage on angiography and 6/6 visual acuity[10].

CASE PRESENTATION

Chief complaints

A 59-year-old female patient presented to the University Eye Hospital complaining of vision worsening.

History of present illness

At presentation, the patient reported bilateral central scotoma and vision loss for about 3 d.

History of past illness

From childhood, the patient has had recurrent herpetic keratouveitis episodes in the right eye. From 2014, she has been treated at the Oncology Institute Ljubljana for skin melanoma. In 2014, she underwent surgical removal of skin melanoma in the abdominal area (Clark IV, Breslow 4mm, 5 mitoses/mm²) with no ulceration, one positive sentinel node in the left armpit, and 20 axillar lymph nodes with no metastasis. She had been treated with adjuvant high dose interferon alpha for 1 year. Afterwards, between 2017 and 2019, she underwent four melanoma metastases metastasectomies (R0) in different parts of the left breast, and radiotherapy (50 Gy) after the last metastasectomy. In July 2019, a fifth relapse (9 mm lesion) in the left breast was assessed by Positron emission tomography-computed tomography (PET-CT) and cytologically confirmed. After the patient refusing a mastectomy, systemic treatment with the checkpoint PD1 inhibitor pembrolizumab was initiated as PCR analysis confirmed BRAF V600E mutation. The treatment was discontinued after the fourth course, as she developed immune related pneumonitis that was successfully treated with oral corticosteroids. In January 2020, progression with new subcutaneous melanoma metastases under the left breast occurred and treatment with BRAF/MEK inhibitors (dabrafenib and trametinib) was prescribed. After the second course of treatment, PET-CT showed a complete response with metastases regression. At the time of presentation to the eye hospital, in August 2020, she was taking BRAF/MEK inhibitors for metastatic malignant melanoma (dabrafenib 150 mg twice daily and trametinib 2 mg once daily) with no side effects.

Personal and family history

Apart from the aforementioned past illnesses, the patient's personal and family history was unremarkable.

Physical examination

At presentation, the patient's best corrected visual acuity was 0.5 in both eyes measured using the Snellen chart, and her intraocular pressure was 21 mmHg in the right eye (RE) and 18 mmHg in the left eye (LE). She had corneal scarring on her RE, and non-granulomatous endothelial precipitates, anterior chamber cells 2+, and vitritis with cells 2+ in both eyes. Fundus examination revealed multiple serous exudative neurosensory detachment around the optic nerve discs, vascular arcades, and macula in both eyes.

Laboratory examinations

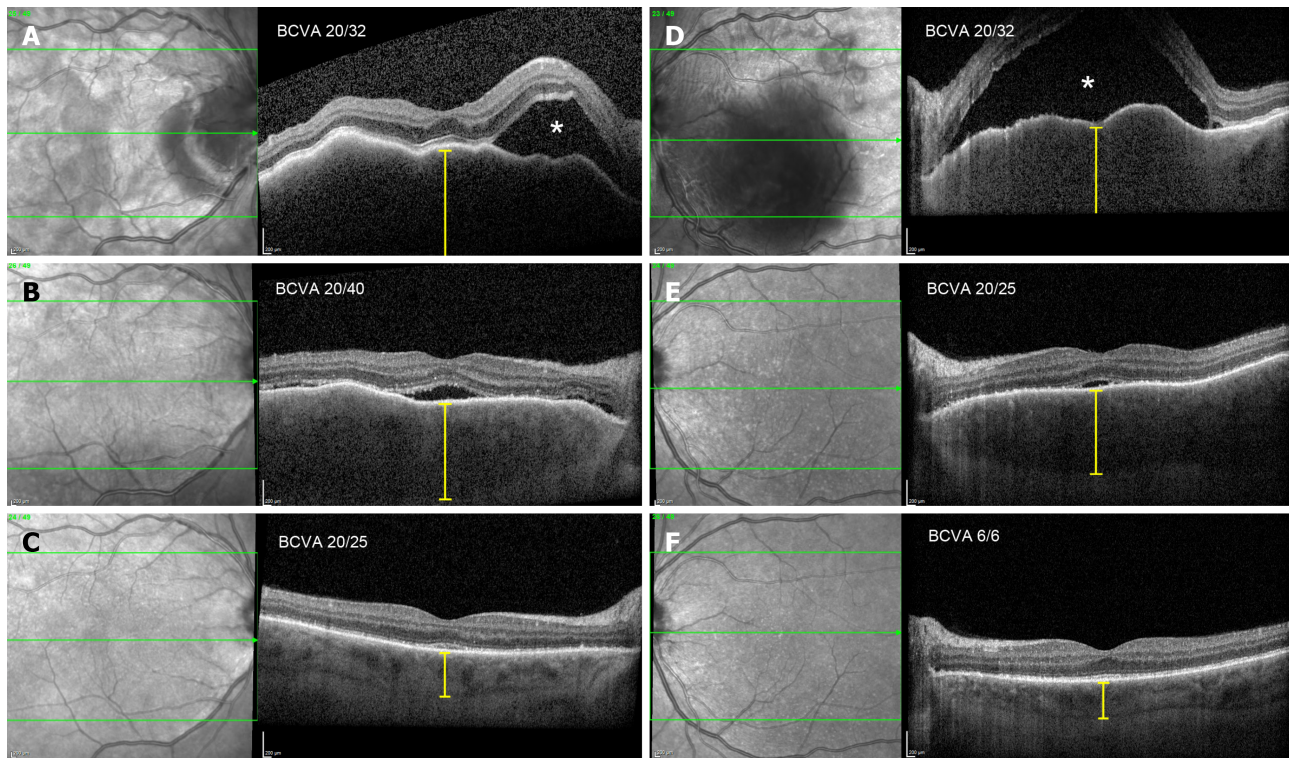
Blood tests excluded infectious uveitis causes [*Bartonella sp.*, *Borrelia sp.*, *Treponema pallidum*, *Toxoplasma gondii*, QuantiFERON-TB Gold (QFT)]. Only *Toxoplasma gondii* IgG antibodies were positive (66.40 IU/mL). Serum testing, aqueous, and vitreous humor samples to exclude herpetic infection were not obtained.

Imaging examinations

Optical coherence tomography (OCT) in the right eye revealed serous neurosensory retinal detachment temporal to the optic nerve disc, pachychoroid, and chorioretinal folds. OCT in the LE showed a subfoveal bullous serous exudative detachment with chorioretinal folds and pachychoroid (Figure 1). Fluorescein and indocyanine-green angiography revealed bilateral asymmetric (more in the LE) extensive leakage from the optic nerve discs and small hyperfluorescent spots at the upper temporal vascular arcade with leakage in the later phases. Moreover, in all four quadrants of the peripheral retina, extensive fluorescein leakage in later stages was observed (Figure 2) in both eyes. Echography revealed thickened choroid with lower internal reflectivity in both eyes, and serous retinal detachment in the LE. CT of the head and chest X-ray were unremarkable.

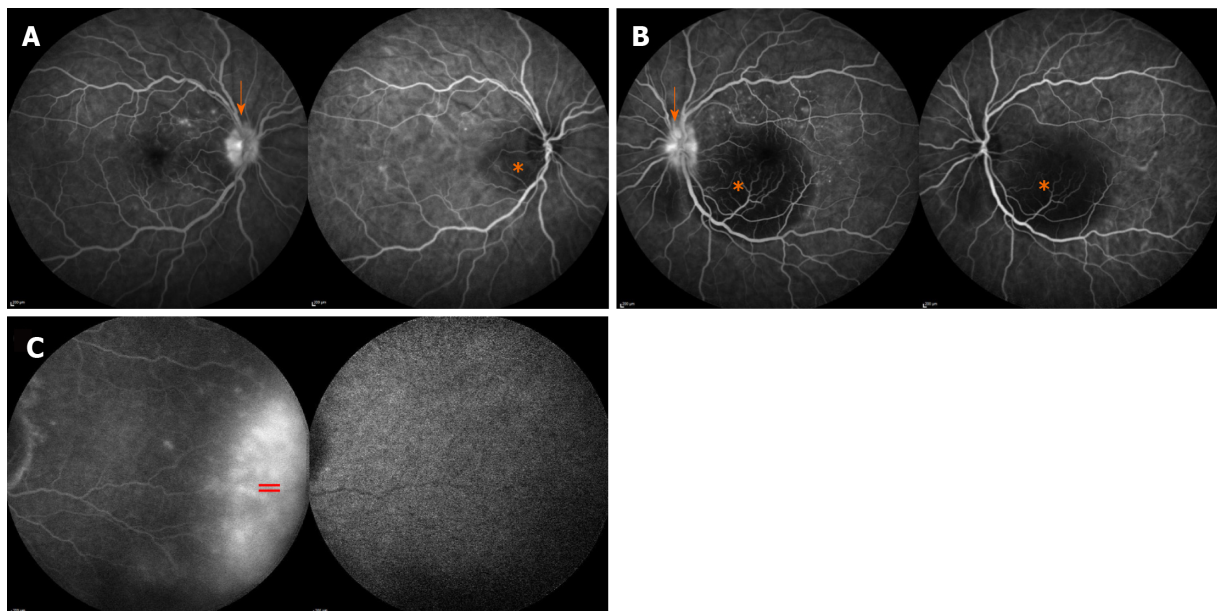
FINAL DIAGNOSIS

The final diagnosis of the presented case was bilateral immune checkpoint inhibitor-induced panuveitis.



DOI: 10.12998/wjcc.v10.i19.6536 Copyright ©The Author(s) 2022.

Figure 1 Optical coherence tomography morphological changes at presentation, 2 wk later, and 1 mo later. A (RE) and D (LE): Bullous exudative retinal detachment (white asterisk), chorioretinal folds, and thickened choroid (yellow caliper), at presentation; B (RE) and E (LE): Substantial resorption of subretinal fluid and partial resolution of chorioretinal folds and choroidal thickness, after 2 wk; C (RE) and F (LE): Complete resolution of subretinal fluid and chorioretinal folds, normal choroidal thickness, after 1 mo.



DOI: 10.12998/wjcc.v10.i19.6536 Copyright ©The Author(s) 2022.

Figure 2 Fluorescein and indocyanine-green angiography at presentation. A (RE) and B (LE): Blocked fluorescence in area of subretinal fluid accumulation (orange asterisk) and leakage of fluorescein from optic nerve disc (orange arrow); C: Extensive leakage of fluorescein at the retinal periphery (orange =).

TREATMENT

Due to the history of recurrent herpetic keratouveitis, the patient was empirically treated with intravenous acyclovir, topical corticosteroids, and mydriatics at presentation. After a negative infectious uveitis work-up, the patient was treated with intravenous methylprednisolone (500 mg) for 3 d.

Afterwards, steroid treatment was switched to oral methylprednisolone (64 mg) with a tapering schedule. Meanwhile, antiviral treatment with oral acyclovir (400 mg) twice daily was continued.

OUTCOME AND FOLLOW-UP

After the high dose systemic corticosteroid treatment with a tapering schedule, ocular morphological and functional outcomes improved. At the next follow-up, 1.5 mo after the ocular adverse effects onset, the patient's best corrected visual acuity improved to 0.7 (RE) and 1.0 (LE). Inflammation in the anterior chamber and vitritis resolved. OCT revealed complete subretinal fluid reabsorption and chorioretinal fold resolution.

As the cause of the ocular changes was not clear, the MEK inhibitor was discontinued first; however, choroidal thickening and subretinal fluid reoccurred after the second cycle. Therefore, the BRAF inhibitor was discontinued and the MEK inhibitor was reintroduced, but the choroidal thickening and subretinal fluid persisted. Meanwhile, the patient was on low-dose peroral maintenance corticosteroid therapy. Because of the persistence of ocular adverse effects, BRAF/MEK inhibitor treatment was terminated, which resulted in the resolution of ocular adverse effects.

The patient continued with the regular follow-ups. After progression of the melanoma half a year later with the dissemination in the lungs, the BRAF/MEK inhibitors were reintroduced (vemurafenib and cobimetinib) along with peroral methylprednisolone (16 mg). At the time of writing this article, the patient's ocular condition is unremarkable. She is on the second course of vemurafenib and cobimetinib treatment and her systemic condition is rapidly improving. The patient is not candidate for immunotherapy, as she developed grade 3 immune related pneumonitis.

DISCUSSION

Immunotherapy and targeted drugs therapy have recently become the new standard of care for patients with unresectable metastatic malignant melanoma, significantly improving the overall survival[3]. As with any new drug arrival on the market, the prevalence and severity of adverse effects are not well established. There are many published studies reporting ocular adverse effects associated with MEK or BRAF inhibitor monotherapy[5,6,11]; however, studies on combined therapy are lacking. To the best of our knowledge, there are only few published case reports reporting ocular adverse effects associated with dabrafenib and trametinib combined therapy[8-10]. Our case report closely resembles a case report published by Draganova *et al*[9], in which bilateral panuveitis, serous retinal detachment, chororetinal folds, and pachychoroid were described. In both case reports, dabrafenib and trametinib treatment was suspended, which resulted in significant functional and morphological improvement in 1-1.5 mo. After ruling out infectious causes of panuveitis, the patient was treated with intravenous corticosteroids (3 d) followed by oral corticosteroid treatment with a tapering schedule.

Because the patient had keratouveitis in the past and due to the immunosuppression with BRAF/MEK inhibitors, we started the treatment with oral acyclovir empirically at presentation. Although non-specific anterior uveitis and vitritis could be a sign of herpetic related panuveitis, multimodal imaging of the chorioretina excluded herpes simplex virus (HSV) involvement. In acute retinal necrosis (ARN) or progressive outer retinal necrosis (PORN), which are inflammatory conditions due to the varicella-zoster virus and HSV, necrotizing retinitis and occlusive arteritis are characteristic signs[12], which were not present in our patient. On the other hand, severe multiple subretinal serous retinal detachments and thick choroid, which were present in our patient, are not present in ARN and PORN. Serum testing for herpesvirus antibodies was not performed because it has been reported that it does not add any value in the diagnosis of ARN or PORN[12]. Of all blood tests, only *Toxoplasma gondii* IgG antibodies were positive. In adults, IgG antibodies against *Toxoplasma gondii* can be detected from 22.5% to more than 80% of people[13]. Due to the low diagnostic value of *Toxoplasma gondii* IgG antibodies and no other clinical signs suggesting ocular toxoplasmosis, this diagnosis was excluded.

The corticosteroid treatment paradigm for non-infectious uveitis is well established[14], which raises the question about corticosteroid treatment effectiveness in panuveitis induced by dabrafenib and trametinib. As described, after a consultation with our oncologist, we decided to discontinue the treatment with BRAF and MEK inhibitors, which resulted in the resolution of ocular adverse effects and metastatic melanoma dissemination. As seen in our case, stopping the BRAF and MEK inhibitor treatment can lead to melanoma dissemination, which can have an important impact on the survival. Since BRAF/MEK inhibitor treatment is the standard care for BRAF mutated melanoma patients, either in adjuvant or metastatic setting, we should be aware of possible ocular adverse effects including severe panuveitis. Moreover, due to the frequent ocular side effects of these medications, it might seem reasonable to schedule an ophthalmological examination for asymptomatic patients during the treatment. Along with the BRAF/MEK inhibitor treatment, patients could be treated with corticosteroids as well. The possibility of the adrenal gland suppression and other possible side effects of long-term corticosteroid treatment should be discussed with the patients.

The mechanism behind BRAF/MEK inhibitor induced panuveitis, which clinically closely resembles the Vogt-Koyanagi-Harada (VKH) disease[15], remains unclear. In the VKH disease pathogenesis, CD4+ and CD8+ cells (T cells) target melanocytic antigens in the choroid and RPE, which impair the outer blood retinal barrier[16]. BRAF/MEK inhibitors interfere with the MAPK pathway, which is involved in the T-cell receptor signaling pathway[17]. This interference could lead to similar changes in the choroid and RPE as observed in VKH disease[15].

CONCLUSION

In conclusion, MAPK pathway inhibition can very rarely lead to severe panuveitis in both eyes, which tends to resolve within months with treatment discontinuation and/or treatment with corticosteroids. Further studies are needed to determine optimal monitoring for these patients to exclude ocular adverse effects, and to establish treatment protocols if side effects occur.

FOOTNOTES

Author contributions: Király P was the patient's ophthalmologist, collected the patient's clinical data, reviewed the literature, designed the report, and wrote the paper; Groznik AL, Valentinčič NV, Mekjavić PJ, and Urbančič M were the patient's ophthalmologists and contributed to manuscript drafting; Mesti T and Ocvirk J were the patient's oncologists and contributed to manuscript drafting, writing, and editing.

Informed consent statement: Informed written consent was obtained from the patient for publication of this report and any accompanying images.

Conflict-of-interest statement: The authors declare that they have no conflict of interest to disclose.

CARE Checklist (2016) statement: The authors have read the CARE Checklist (2016), and the manuscript was prepared and revised according to the CARE Checklist (2016).

Open-Access: This article is an open-access article that was selected by an in-house editor and fully peer-reviewed by external reviewers. It is distributed in accordance with the Creative Commons Attribution NonCommercial (CC BY-NC 4.0) license, which permits others to distribute, remix, adapt, build upon this work non-commercially, and license their derivative works on different terms, provided the original work is properly cited and the use is non-commercial. See: <https://creativecommons.org/licenses/by-nc/4.0/>

Country/Territory of origin: Slovenia

ORCID number: Peter Király 0000-0002-7980-4401; Alenka Lavrič Groznik 28293; Nataša Vidovič Valentincic 20708; Polona Jaki Mekjavić 11537; Mojca Urbančič 25125; Janja Ocvirk 13541; Tanja Mesti 32614.

S-Editor: Xing YX

L-Editor: Wang TQ

P-Editor: Xing YX

REFERENCES

- 1 Grimaldi AM, Simeone E, Festino L, Vanella V, Strudel M, Ascierto PA. MEK Inhibitors in the Treatment of Metastatic Melanoma and Solid Tumors. *Am J Clin Dermatol* 2017; **18**: 745-754 [PMID: 28537004 DOI: 10.1007/s40257-017-0292-y]
- 2 Simeone E, Grimaldi AM, Festino L, Vanella V, Palla M, Ascierto PA. Combination Treatment of Patients with BRAF-Mutant Melanoma: A New Standard of Care. *BioDrugs* 2017; **31**: 51-61 [PMID: 28058658 DOI: 10.1007/s40259-016-0208-z]
- 3 Robert C, Karaszewska B, Schachter J, Rutkowski P, Mackiewicz A, Stroiakovski D, Lichinitser M, Dummer R, Grange F, Mortier L, Chiarion-Sileni V, Drucis K, Krajsova I, Hauschild A, Lorigan P, Wolter P, Long GV, Flaherty K, Nathan P, Ribas A, Martin AM, Sun P, Crist W, Legos J, Rubin SD, Little SM, Schadendorf D. Improved overall survival in melanoma with combined dabrafenib and trametinib. *N Engl J Med* 2015; **372**: 30-39 [PMID: 25399551 DOI: 10.1056/NEJMoa1412690]
- 4 Heinzerling L, Eigentler TK, Fluck M, Hassel JC, Heller-Schenck D, Leipe J, Pauschinger M, Vogel A, Zimmer L, Gutzmer R. Tolerability of BRAF/MEK inhibitor combinations: adverse event evaluation and management. *ESMO Open* 2019; **4**: e000491 [PMID: 31231568 DOI: 10.1136/esmoopen-2019-000491]
- 5 Méndez-Martínez S, Calvo P, Ruiz-Moreno O, Pardiñas Barón N, Leciñena Bueno J, Gil Ruiz MDR, Pablo L. OCULAR ADVERSE EVENTS ASSOCIATED WITH MEK INHIBITORS. *Retina* 2019; **39**: 1435-1450 [PMID: 30681641 DOI: 10.1097/IAE.0000000000002451]

- 6 **Choe CH**, McArthur GA, Caro I, Kempen JH, Amaravadi RK. Ocular toxicity in BRAF mutant cutaneous melanoma patients treated with vemurafenib. *Am J Ophthalmol* 2014; **158**: 831-837.e2 [PMID: [25036880](#) DOI: [10.1016/j.ajo.2014.07.003](#)]
- 7 **Guedj M**, Quéant A, Funck-Brentano E, Kramkimel N, Lellouch J, Monnet D, Longvert C, Gantzer A, Brézén AP. Uveitis in patients with late-stage cutaneous melanoma treated with vemurafenib. *JAMA Ophthalmol* 2014; **132**: 1421-1425 [PMID: [25125216](#) DOI: [10.1001/jamaophthalmol.2014.3024](#)]
- 8 **Albertini GC**, Corbelli E, Battaglia Parodi M, Bandello F. Choroidal Neovascularization in Multifocal Choroiditis after Dabrafenib and Trametinib. *Eur J Ophthalmol* 2017; **27**: e184-e186 [PMID: [28777388](#) DOI: [10.5301/ejo.5001013](#)]
- 9 **Draganova D**, Kerger J, Caspers L, Willermain F. Severe bilateral panuveitis during melanoma treatment by Dabrafenib and Trametinib. *J Ophthalmic Inflamm Infect* 2015; **5**: 17 [PMID: [26078801](#) DOI: [10.1186/s12348-015-0049-9](#)]
- 10 **Joshi L**, Karydis A, Gemenetzi M, Shao EH, Taylor SR. Uveitis as a Result of MAP Kinase Pathway Inhibition. *Case Rep Ophthalmol* 2013; **4**: 279-282 [PMID: [24474928](#) DOI: [10.1159/000357060](#)]
- 11 **Francis JH**, Habib LA, Abramson DH, Yannuzzi LA, Heinemann M, Gounder MM, Grisham RN, Postow MA, Shoushtari AN, Chi P, Segal NH, Yaeger R, Ho AL, Chapman PB, Catalanotti F. Clinical and Morphologic Characteristics of MEK Inhibitor-Associated Retinopathy: Differences from Central Serous Chorioretinopathy. *Ophthalmology* 2017; **124**: 1788-1798 [PMID: [28709702](#) DOI: [10.1016/j.ophtha.2017.05.038](#)]
- 12 **Powell B**, Wang D, Llop S, Rosen RB. Management Strategies of Acute Retinal Necrosis: Current Perspectives. *Clin Ophthalmol* 2020; **14**: 1931-1943 [PMID: [32764860](#) DOI: [10.2147/OPTH.S258488](#)]
- 13 **Garweg JG**, de Groot-Mijnes JD, Montoya JG. Diagnostic approach to ocular toxoplasmosis. *Ocul Immunol Inflamm* 2011; **19**: 255-261 [PMID: [21770803](#) DOI: [10.3109/09273948.2011.595872](#)]
- 14 **Kim JS**, Knickelbein JE, Nussenblatt RB, Sen HN. Clinical trials in noninfectious uveitis. *Int Ophthalmol Clin* 2015; **55**: 79-110 [PMID: [26035763](#) DOI: [10.1097/IIO.0000000000000070](#)]
- 15 **Joye A**, Suhler E. Vogt-Koyanagi-Harada disease. *Curr Opin Ophthalmol* 2021; **32**: 574-582 [PMID: [34545845](#) DOI: [10.1097/ICU.0000000000000809](#)]
- 16 **Crosson JN**, Laird PW, Debiec M, Bergstrom CS, Lawson DH, Yeh S. Vogt-Koyanagi-Harada-like syndrome after CTLA-4 inhibition with ipilimumab for metastatic melanoma. *J Immunother* 2015; **38**: 80-84 [PMID: [25658618](#) DOI: [10.1097/CJI.0000000000000066](#)]
- 17 **Proietti I**, Skroza N, Michelini S, Mambrin A, Balduzzi V, Bernardini N, Marchesiello A, Tolino E, Volpe S, Maddalena P, Di Fraia M, Mangino G, Romeo G, Potenza C. BRAF Inhibitors: Molecular Targeting and Immunomodulatory Actions. *Cancers (Basel)* 2020; **12** [PMID: [32645969](#) DOI: [10.3390/cancers12071823](#)]



Published by **Baishideng Publishing Group Inc**
7041 Koll Center Parkway, Suite 160, Pleasanton, CA 94566, USA

Telephone: +1-925-3991568

E-mail: bpgoffice@wjgnet.com

Help Desk: <https://www.f6publishing.com/helpdesk>

<https://www.wjgnet.com>

