

World Journal of *Clinical Cases*

World J Clin Cases 2022 July 6; 10(19): 6341-6758



Contents

Thrice Monthly Volume 10 Number 19 July 6, 2022

MINIREVIEWS

- 6341** Review of clinical characteristics, immune responses and regulatory mechanisms of hepatitis E-associated liver failure
Chen C, Zhang SY, Chen L
- 6349** Current guidelines for *Helicobacter pylori* treatment in East Asia 2022: Differences among China, Japan, and South Korea
Cho JH, Jin SY
- 6360** Review of epidermal growth factor receptor-tyrosine kinase inhibitors administration to non-small-cell lung cancer patients undergoing hemodialysis
Lan CC, Hsieh PC, Huang CY, Yang MC, Su WL, Wu CW, Wu YK

ORIGINAL ARTICLE

Case Control Study

- 6370** Pregnancy-related psychopathology: A comparison between pre-COVID-19 and COVID-19-related social restriction periods
Chieffo D, Avallone C, Serio A, Kotzalidis GD, Balocchi M, De Luca I, Hirsch D, Gonzalez del Castillo A, Lanzotti P, Marano G, Rinaldi L, Lanzone A, Mercuri E, Mazza M, Sani G
- 6385** Intestinal mucosal barrier in functional constipation: Does it change?
Wang JK, Wei W, Zhao DY, Wang HF, Zhang YL, Lei JP, Yao SK

Retrospective Cohort Study

- 6399** Identification of risk factors for surgical site infection after type II and type III tibial pilon fracture surgery
Hu H, Zhang J, Xie XG, Dai YK, Huang X

Retrospective Study

- 6406** Total knee arthroplasty in Ranawat II valgus deformity with enlarged femoral valgus cut angle: A new technique to achieve balanced gap
Lv SJ, Wang XJ, Huang JF, Mao Q, He BJ, Tong PJ
- 6417** Preliminary evidence in treatment of eosinophilic gastroenteritis in children: A case series
Chen Y, Sun M
- 6428** Self-made wire loop snare successfully treats gastric persimmon stone under endoscopy
Xu W, Liu XB, Li SB, Deng WP, Tong Q
- 6437** Neoadjuvant transcatheter arterial chemoembolization and systemic chemotherapy for the treatment of undifferentiated embryonal sarcoma of the liver in children
He M, Cai JB, Lai C, Mao JQ, Xiong JN, Guan ZH, Li LJ, Shu Q, Ying MD, Wang JH

- 6446** Effect of cold snare polypectomy for small colorectal polyps

Meng QQ, Rao M, Gao PJ

- 6456** Field evaluation of COVID-19 rapid antigen test: Are rapid antigen tests less reliable among the elderly?

Tabain I, Cucevic D, Skreb N, Mrzljak A, Ferencak I, Hruskar Z, Misic A, Kuzle J, Skoda AM, Jankovic H, Vilibic-Cavlek T

Observational Study

- 6464** Tracheobronchial intubation using flexible bronchoscopy in children with Pierre Robin sequence: Nursing considerations for complications

Ye YL, Zhang CF, Xu LZ, Fan HF, Peng JZ, Lu G, Hu XY

- 6472** Family relationship of nurses in COVID-19 pandemic: A qualitative study

Çelik MY, Kiliç M

META-ANALYSIS

- 6483** Diagnostic accuracy of ≥ 16 -slice spiral computed tomography for local staging of colon cancer: A systematic review and meta-analysis

Liu D, Sun LM, Liang JH, Song L, Liu XP

CASE REPORT

- 6496** Delayed-onset endophthalmitis associated with *Achromobacter* species developed in acute form several months after cataract surgery: Three case reports

Kim TH, Lee SJ, Nam KY

- 6501** Sustained dialysis with misplaced peritoneal dialysis catheter outside peritoneum: A case report

Shen QQ, Behera TR, Chen LL, Attia D, Han F

- 6507** Arteriovenous thrombotic events in a patient with advanced lung cancer following bevacizumab plus chemotherapy: A case report

Kong Y, Xu XC, Hong L

- 6514** Endoscopic ultrasound radiofrequency ablation of pancreatic insulinoma in elderly patients: Three case reports

Rossi G, Petrone MC, Capurso G, Partelli S, Falconi M, Arcidiacono PG

- 6520** Acute choroidal involvement in lupus nephritis: A case report and review of literature

Yao Y, Wang HX, Liu LW, Ding YL, Sheng JE, Deng XH, Liu B

- 6529** Triple A syndrome-related achalasia treated by per-oral endoscopic myotomy: Three case reports

Liu FC, Feng YL, Yang AM, Guo T

- 6536** Choroidal thickening with serous retinal detachment in BRAF/MEK inhibitor-induced uveitis: A case report

Kiraly P, Groznik AL, Valentinčič NV, Mekjavić PJ, Urbančič M, Ocvirk J, Mesti T

- 6543** Esophageal granular cell tumor: A case report

Chen YL, Zhou J, Yu HL

- 6548** Hem-o-lok clip migration to the common bile duct after laparoscopic common bile duct exploration: A case report
Liu DR, Wu JH, Shi JT, Zhu HB, Li C
- 6555** Chidamide and sintilimab combination in diffuse large B-cell lymphoma progressing after chimeric antigen receptor T therapy
Hao YY, Chen PP, Yuan XG, Zhao AQ, Liang Y, Liu H, Qian WB
- 6563** Relapsing polychondritis with isolated tracheobronchial involvement complicated with Sjogren's syndrome: A case report
Chen JY, Li XY, Zong C
- 6571** Acute methanol poisoning with bilateral diffuse cerebral hemorrhage: A case report
Li J, Feng ZJ, Liu L, Ma YJ
- 6580** Immunoabsorption therapy for Klinefelter syndrome with antiphospholipid syndrome in a patient: A case report
Song Y, Xiao YZ, Wang C, Du R
- 6587** Roxadustat for treatment of anemia in a cancer patient with end-stage renal disease: A case report
Zhou QQ, Li J, Liu B, Wang CL
- 6595** Imaging-based diagnosis for extraskeletal Ewing sarcoma in pediatrics: A case report
Chen ZH, Guo HQ, Chen JJ, Zhang Y, Zhao L
- 6602** Unusual course of congenital complete heart block in an adult: A case report
Su LN, Wu MY, Cui YX, Lee CY, Song JX, Chen H
- 6609** Penile metastasis from rectal carcinoma: A case report
Sun JJ, Zhang SY, Tian JJ, Jin BY
- 6617** Isolated cryptococcal osteomyelitis of the ulna in an immunocompetent patient: A case report
Ma JL, Liao L, Wan T, Yang FC
- 6626** Magnetic resonance imaging features of intrahepatic extramedullary hematopoiesis: Three case reports
Luo M, Chen JW, Xie CM
- 6636** Giant retroperitoneal liposarcoma treated with radical conservative surgery: A case report and review of literature
Lieto E, Cardella F, Erario S, Del Sorbo G, Reginelli A, Galizia G, Urraro F, Panarese I, Auricchio A
- 6647** Transplanted kidney loss during colorectal cancer chemotherapy: A case report
Pośpiech M, Kolonko A, Nieszporek T, Kozak S, Kozaczka A, Karkoszka H, Winder M, Chudek J
- 6656** Massive gastrointestinal bleeding after endoscopic rubber band ligation of internal hemorrhoids: A case report
Jiang YD, Liu Y, Wu JD, Li GP, Liu J, Hou XH, Song J

- 6664** Mills' syndrome is a unique entity of upper motor neuron disease with N-shaped progression: Three case reports
Zhang ZY, Ouyang ZY, Zhao GH, Fang JJ
- 6672** Entire process of electrocardiogram recording of Wellens syndrome: A case report
Tang N, Li YH, Kang L, Li R, Chu QM
- 6679** Retroperitoneal tumor finally diagnosed as a bronchogenic cyst: A case report and review of literature
Gong YY, Qian X, Liang B, Jiang MD, Liu J, Tao X, Luo J, Liu HJ, Feng YG
- 6688** Successful treatment of Morbihan disease with total glucosides of paeony: A case report
Zhou LF, Lu R
- 6695** Ant sting-induced whole-body pustules in an inebriated male: A case report
Chen SQ, Yang T, Lan LF, Chen XM, Huang DB, Zeng ZL, Ye XY, Wan CL, Li LN
- 6702** Plastic surgery for giant metastatic endometrioid adenocarcinoma in the abdominal wall: A case report and review of literature
Wang JY, Wang ZQ, Liang SC, Li GX, Shi JL, Wang JL
- 6710** Delayed-release oral mesalamine tablet mimicking a small jejunal gastrointestinal stromal tumor: A case report
Frosio F, Rausa E, Marra P, Boutron-Ruault MC, Lucianetti A
- 6716** Concurrent alcoholic cirrhosis and malignant peritoneal mesothelioma in a patient: A case report
Liu L, Zhu XY, Zong WJ, Chu CL, Zhu JY, Shen XJ
- 6722** Two smoking-related lesions in the same pulmonary lobe of squamous cell carcinoma and pulmonary Langerhans cell histiocytosis: A case report
Gencer A, Ozcibik G, Karakas FG, Sarbay I, Batur S, Borekci S, Turna A
- 6728** Proprotein convertase subtilisin/kexin type 9 inhibitor non responses in an adult with a history of coronary revascularization: A case report
Yang L, Xiao YY, Shao L, Ouyang CS, Hu Y, Li B, Lei LF, Wang H
- 6736** Multimodal imaging study of lipemia retinalis with diabetic retinopathy: A case report
Zhang SJ, Yan ZY, Yuan LF, Wang YH, Wang LF
- 6744** Primary squamous cell carcinoma of the liver: A case report
Kang LM, Yu DP, Zheng Y, Zhou YH
- 6750** Tumor-to-tumor metastasis of clear cell renal cell carcinoma to contralateral synchronous pheochromocytoma: A case report
Wen HY, Hou J, Zeng H, Zhou Q, Chen N

ABOUT COVER

Editorial Board Member of *World Journal of Clinical Cases*, Abdulqadir Jeprel Naswhan, MSc, RN, Director, Research Scientist, Senior Lecturer, Senior Researcher, Nursing for Education and Practice Development, Hamad Medical Corporation, Doha 576214, Qatar. anashwan@hamad.qa

AIMS AND SCOPE

The primary aim of *World Journal of Clinical Cases* (WJCC, *World J Clin Cases*) is to provide scholars and readers from various fields of clinical medicine with a platform to publish high-quality clinical research articles and communicate their research findings online.

WJCC mainly publishes articles reporting research results and findings obtained in the field of clinical medicine and covering a wide range of topics, including case control studies, retrospective cohort studies, retrospective studies, clinical trials studies, observational studies, prospective studies, randomized controlled trials, randomized clinical trials, systematic reviews, meta-analysis, and case reports.

INDEXING/ABSTRACTING

The WJCC is now indexed in Science Citation Index Expanded (also known as SciSearch®), Journal Citation Reports/Science Edition, Scopus, PubMed, and PubMed Central. The 2021 Edition of Journal Citation Reports® cites the 2020 impact factor (IF) for WJCC as 1.337; IF without journal self cites: 1.301; 5-year IF: 1.742; Journal Citation Indicator: 0.33; Ranking: 119 among 169 journals in medicine, general and internal; and Quartile category: Q3. The WJCC's CiteScore for 2020 is 0.8 and Scopus CiteScore rank 2020: General Medicine is 493/793.

RESPONSIBLE EDITORS FOR THIS ISSUE

Production Editor: Xu Guo; Production Department Director: Xiang Li; Editorial Office Director: Jin-Lai Wang.

NAME OF JOURNAL

World Journal of Clinical Cases

ISSN

ISSN 2307-8960 (online)

LAUNCH DATE

April 16, 2013

FREQUENCY

Thrice Monthly

EDITORS-IN-CHIEF

Bao-Gan Peng, Jerzy Tadeusz Chudek, George Kontogeorgos, Maurizio Serati, Ja Hyeon Ku

EDITORIAL BOARD MEMBERS

<https://www.wjgnet.com/2307-8960/editorialboard.htm>

PUBLICATION DATE

July 6, 2022

COPYRIGHT

© 2022 Baishideng Publishing Group Inc

INSTRUCTIONS TO AUTHORS

<https://www.wjgnet.com/bpg/gerinfo/204>

GUIDELINES FOR ETHICS DOCUMENTS

<https://www.wjgnet.com/bpg/GerInfo/287>

GUIDELINES FOR NON-NATIVE SPEAKERS OF ENGLISH

<https://www.wjgnet.com/bpg/gerinfo/240>

PUBLICATION ETHICS

<https://www.wjgnet.com/bpg/GerInfo/288>

PUBLICATION MISCONDUCT

<https://www.wjgnet.com/bpg/gerinfo/208>

ARTICLE PROCESSING CHARGE

<https://www.wjgnet.com/bpg/gerinfo/242>

STEPS FOR SUBMITTING MANUSCRIPTS

<https://www.wjgnet.com/bpg/GerInfo/239>

ONLINE SUBMISSION

<https://www.f6publishing.com>

Massive gastrointestinal bleeding after endoscopic rubber band ligation of internal hemorrhoids: A case report

Yu-Dong Jiang, Ying Liu, Jian-Di Wu, Gang-Ping Li, Jun Liu, Xiao-Hua Hou, Jun Song

Specialty type: Medicine, research and experimental

Provenance and peer review:

Unsolicited article; Externally peer reviewed.

Peer-review model: Single blind

Peer-review report's scientific quality classification

Grade A (Excellent): 0
Grade B (Very good): 0
Grade C (Good): C, C, C
Grade D (Fair): D
Grade E (Poor): 0

P-Reviewer: Bataga SM, Romania; Okasha H, Egypt; Tamburini AM, Italy

Received: December 20, 2021

Peer-review started: December 20, 2021

First decision: March 10, 2022

Revised: March 23, 2022

Accepted: May 12, 2022

Article in press: May 12, 2022

Published online: July 6, 2022



Yu-Dong Jiang, Ying Liu, Jian-Di Wu, Gang-Ping Li, Jun Liu, Xiao-Hua Hou, Jun Song, Division of Gastroenterology, Union Hospital of Tongji Medical College, Huazhong University of Science and Technology, Wuhan 430022, Hubei Province, China

Corresponding author: Jun Song, MD, Chief Physician, Professor, Division of Gastroenterology, Union Hospital of Tongji Medical College, Huazhong University of Science and Technology, No. 1277 Jiefang Road, Wuhan 430022, Hubei Province, China.

song111jun@126.com

Abstract

BACKGROUND

Rubber band ligation (RBL) using rigid anoscope is a commonly recommended therapy for grade I-III symptomatic internal hemorrhoids. Severe complications of RBL include pain, hemorrhage and sepsis. Flexible endoscopic RBL (ERBL) is now more commonly used in RBL therapy but few severe complications have been reported. Here we report on a case of massive bleeding after ERBL.

CASE SUMMARY

A 31-year-old female was admitted to the department of gastroenterology with a chief complaint of discontinuous hematochezia for 2 years. No previous history, accompanying diseases or drug use was reported. Physical examination and colonoscopy showed grade II internal hemorrhoids. The patient received ERBL therapy. Five days after ligation, the patient presented with mild hematochezia. On days 7 and 9 after ligation, she presented with a large amount of rectal bleeding, dizziness and weakness. Emergency colonoscopy revealed active bleeding and an ulcer in the anal wound. The patient received two sessions of hemoclipping on days 7 and 9 to treat the bleeding. No further bleeding was reported up to day 15 and she was discharged home. Although the hemorrhoid prolapse disappeared after ERBL, she was dissatisfied with the subsequent complications.

CONCLUSION

ERBL therapy is an effective treatment for symptomatic internal hemorrhoids with satisfactory short and long-term recovery. Pain and anal bleeding are the most frequently reported postoperative complications. Coagulation disorders complicate the increased risk of bleeding. Although rarely reported, our case reminds us that those patients without coagulation disorders are also at risk of massive life-threatening bleeding and need strict follow-up after ligation.

Key Words: Internal hemorrhoids; Endoscopy; Rubber band ligation; Complication; Bleeding; Case report

©The Author(s) 2022. Published by Baishideng Publishing Group Inc. All rights reserved.

Core Tip: Endoscopic rubber band ligation (ERBL) is an effective treatment for symptomatic internal hemorrhoids and few severe complications have been found. A 31-year-old female with grade II internal hemorrhoids received ERBL therapy. No previous history or coagulation disorder was reported. Meanwhile, she presented with delayed massive rectal bleeding after the ligation. Colonoscopy showed active bleeding and ulcers in the anal wound. Coagulation disorders were previously reported in relation to bleeding after ligation. However, this case reminds us that patients without coagulation disorders are also at risk for massive life-threatening bleeding after ERBL.

Citation: Jiang YD, Liu Y, Wu JD, Li GP, Liu J, Hou XH, Song J. Massive gastrointestinal bleeding after endoscopic rubber band ligation of internal hemorrhoids: A case report. *World J Clin Cases* 2022; 10(19): 6656-6663

URL: <https://www.wjgnet.com/2307-8960/full/v10/i19/6656.htm>

DOI: <https://dx.doi.org/10.12998/wjcc.v10.i19.6656>

INTRODUCTION

Internal hemorrhoids are a common lower gastrointestinal disease and a main cause of lower gastrointestinal bleeding[1,2]. Rubber band ligation (RBL) is a commonly recommended therapy for grade I-III symptomatic internal hemorrhoids[1,3,4]. However, several life-threatening complications have been reported including massive hemorrhage and perirectal sepsis[5,6]. Due to the development of flexible endoscopy, it has been more widely used for the treatment of internal hemorrhoids. Flexible endoscopy is feasible for ligation in both forward-view and retroflexion. The advantage of the retroflexion procedure is its easy operation in the anal zone, though it may induce more pain[7]. Several complications (pain, anal discomfort, lower gastrointestinal bleeding and early detachment) have been reported in endoscopic RBL (ERBL)[7]. However, few severe complications have been reported.

Here, we report on a case of internal hemorrhoid therapy which caused rare massive hemorrhage after ERBL. Furthermore, we reviewed the latest article involving the effects and complications of ERBL hoping to provide clinical reference for this therapy.

CASE PRESENTATION

Chief complaints

A 31-year-old Asian female presented with a chief complaint of discontinuous hematochezia for 2 years at the Department of Gastroenterology.

History of present illness

The patient generally had lower gastrointestinal bleeding occurring at the end of defecation 3-4 times *per week* along with several drops of bright red blood in the past 2 years. She frequently experienced prolapsed hemorrhoids that automatically retracted after defecation. Her stool habit was normal with a frequency of 1-2 times *per day*. The patient adjusted her lifestyle by reducing sedentary behaviors, stress and maintaining regular stool habits. However, these measures failed to improve her symptoms. Warm water baths and ointments could temporarily reduce bleeding but the patient was dissatisfied and required more aggressive treatment which included endoscopic therapy.

History of past illness

No other previous history or accompanied diseases were reported. The patient denied any use of anticoagulant or antiplatelet drugs.

Personal and family history

The patient denied any history of smoking, alcohol use or food and drug allergies. She had no family history of gastrointestinal tumors or genetic diseases.

Physical examination

The patient's temperature was 36.2 °C, heart rate was 80 bpm, breath rate was 18 bpm and blood pressure was 126/82 mmHg. Examination of the chest, lungs and abdomen showed no abnormalities. Examination of the anus showed prolapsed hemorrhoids during defecate movements (Figure 1A), and it was found to automatically retract after defecation. Digital rectal examination revealed enlarged hemorrhoids and no bloodstain was left on gloves.

Laboratory examinations

Regular preoperative examination, including routine blood work, liver and kidney function tests, coagulation function and electrocardiography was performed before ERBL. The patient's hemoglobin (Hb) was 112 g/L and no other abnormal results were reported.

Endoscopy

Flexible colonoscopy was performed under intraprocedural analgesia with Diprivan, which revealed normal colorectal mucosa and internal hemorrhoids with positive red color sign (Figure 1B).

FINAL DIAGNOSIS

The patient was diagnosed with grade II internal hemorrhoids and mild anemia.

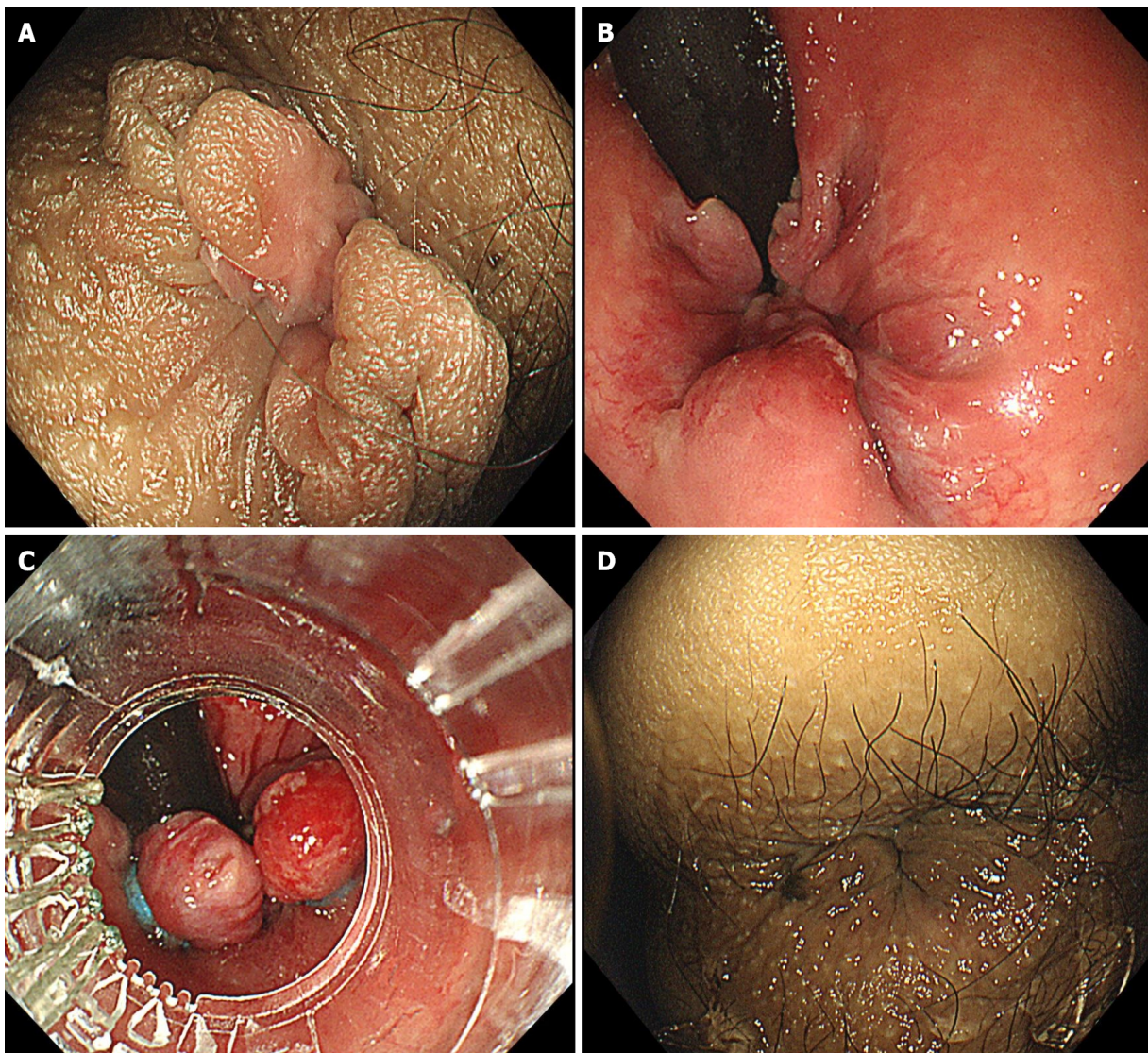
TREATMENT

For the convenience of the patient, we performed ERBL with endoscopic examination continuously. In order to manage the patient with better postoperative care, the patient underwent hospital admission. Following the colonoscopy examination, the patient was treated with ERBL therapy using Multiple Band Ligator (Boston Scientific, Speedband Superview Super 7™, 7 Bands). Five rubber bands were applied to the hemorrhoids (Figure 1C). She received Diprivan (Propofol Injection, 20 mL, 200 mg) for anesthesia during the endoscopic examination and ERBL therapy to avoid intraoperative pain. After ligation, the prolapsed hemorrhoid tissue was withdrawn into the anus (Figure 1D). After ERBL, the patient was advised to take a light diet to avoid bleeding and oral laxatives (10 mL, tid) were given to soften the stool.

OUTCOME AND FOLLOW-UP

Approximately 4 h after ligation, the patient felt mild anal pain and nausea. An intramuscular injection of 10 mg of Tramadol rapidly remitted the pain. 24 h after ligation, the patient was permitted to eat a light food diet. Lactulose (10 mL, tid, po) was given to soften the stool and to prevent post-ERBL bleeding. 5 d after ligation, the patient did not report rectal bleeding during defecation and the prolapse had significantly improved. Therefore, she was discharged to home following the doctors' advice.

On day 7 after ligation, she was sent to the emergency department with significant painless fresh rectal bleeding of approximately 400 mL, accompanied by systemic symptoms of dizziness and weakness. Emergency colonoscopy showed active oozing of blood in the anal wound (Figure 2A). Endoscopic electrocautery hemostatic forceps (FD-410LR, Olympus Corporation) was used first. However, it failed to stop the active bleeding. Then two hemoclips (ROCC-D-26-195-C, Micro-Tech (Nanjing) Co., Ltd, Maximum Span width = 10 mm) were applied to stop the bleeding. Finally, the patient was sent to the ward safely with a Hb level of 93 g/L (Figure 3). However, early on day 9, she suddenly presented with large amounts of rectal bleeding of over 800 mL and fainted during defecation. Blood pressure was 95/50 mmHg and pulse was 116 beats/min. Resuscitation with oxygen and intravenous fluids with electrolyte solution was initiated. She was immediately sent to the endoscopic department under electrocardiographic monitoring. Emergency colonoscopy showed that all rubber bands had slipped off leaving multiple bleeding ulcers in the anal wound (Figure 2B). Ischemic necrotic tissue containing 1 hemoclip was removed by forceps (FG-32L-1, Olympus Corporation), and 3 more hemoclips were placed and successfully stopped the bleeding (Figure 2C). The patient received fluid infusion for symptomatic treatment and omeprazole (200 mg qd iv) was used to prevent infection. Although the routine blood test revealed a Hb of merely 67 g/L (Figure 3), the patient refused blood transfusion. No further bleeding was reported until 15 d after ligation. A re-examination by colonoscopy on days 12 and 15 showed a gradually healed wound covered by ischemic scabs (Figure 2D and E). The patient was discharged home with moderate anemia and her Hb was 74 g/L (Figure 3). Although hemorrhoids prolapse disappeared after ERBL, she was dissatisfied with the subsequent complications. The duration of the hospitalization was 17 d, and the cost of the procedure was 1500\$, including



DOI: 10.12998/wjcc.v10.i19.6656 Copyright ©The Author(s) 2022.

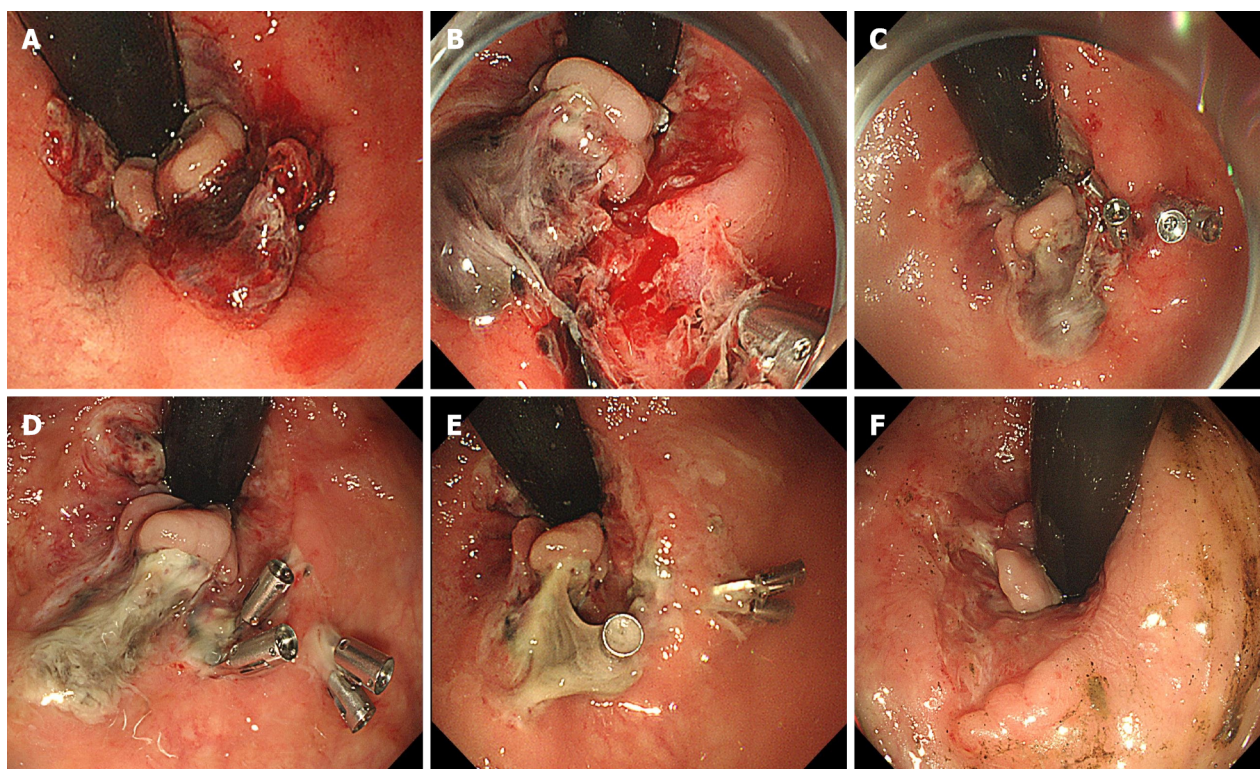
Figure 1 Endoscopic images of endoscopic rubber band ligation therapy. A: Prolapsed hemorrhoids in forward view before endoscopic rubber band ligation (ERBL); B: Retroflexion view of hemorrhoids before ERBL; C: Ligation of hemorrhoids during ERBL; D: the prolapsed hemorrhoid tissue was withdrawn into the anus after ERBL.

endoscopy + ligation therapy (800\$), drugs (200\$) and hospitalization (500\$).

Of 1 mo after ligation, we investigated the patient through a telephone call. No bleeding or hemorrhoids prolapse was reported. 3 mo after ligation, the patient received a re-examination and her Hb had reached 132 g/L. Colonoscopy revealed that the anal wound had healed and no hemorrhoids were found (Figure 2F).

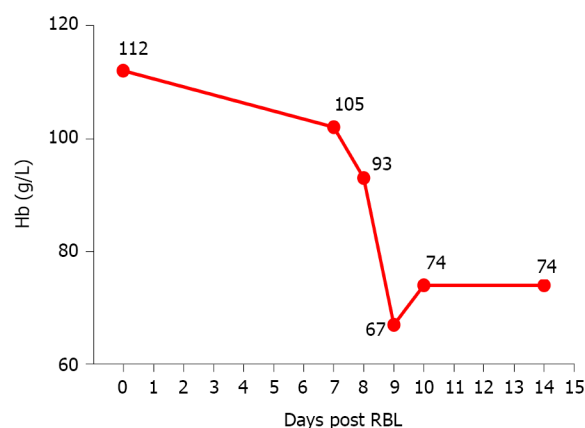
DISCUSSION

The use of RBL on internal hemorrhoids by grasping the hemorrhoidal tissue with an elastic rubber band and this ligation causes ischemic necrosis and cicatricial fixation of the hemorrhoidal tissue. Compared with surgical methods such as excisional hemorrhoidectomy, stapled hemorrhoidectomy and hemorrhoidal artery ligation, RBL with anoscopy causes fewer postoperative complications as well as a shorter hospitalization period[8-10]. Compared with other nonsurgical methods (sclerotherapy, infrared coagulation), RBL shows a higher efficacy and a lower recurrence rate and it is more effective for prolapsed hemorrhoids[10]. ERL has been more commonly used in the treatment of grade I-III internal hemorrhoids. The therapeutic effects of ERL have been verified by recent studies. In an observational study including 82 patients with grade I-IV internal hemorrhoids, Fukuda *et al* [11] reported a significant reduction in symptom scores within 4 wk after ERL in the retroflexed position [11]. Su *et al* [12] enrolled 576 patients with grade II-IV internal hemorrhoids in a 1-year follow-up study



DOI: 10.12998/wjcc.v10.i19.6656 Copyright ©The Author(s) 2022.

Figure 2 Endoscopic images during follow-up study. A: Active oozing of blood on 7 d post-endoscopic rubber band ligation (ERBL); B: Ulcer and active bleeding on 9 d post-ERBL; C: image after endoscopic hemostasis using clips; D: 12 d post-ERBL; E: 15 d post-ERBL; F: 3 mo post-ERBL.



DOI: 10.12998/wjcc.v10.i19.6656 Copyright ©The Author(s) 2022.

Figure 3 Curve of hemoglobin before and after endoscopic rubber band ligation therapy.

which showed that 93.58% of patients experienced at least one grade reduction in the severity of hemorrhoids after ERBL[12]. Another follow-up study including 759 patients reported that 87.0% had controlled bleeding and 83.1% had controlled prolapse rates within 5 years[13]. These results indicated that ERBL is a simple and well-tolerated treatment for symptomatic internal hemorrhoids with satisfactory short and long-term recovery[12,13]. New devices for ERBL have been developed in recent years and the more flexible gastroscope and transparent cap are increasingly used to assist ERBL operation[14]. Paikos *et al*[15] reported that the O'Regan disposable bander device showed good response with low complication rates in outpatients with symptomatic hemorrhoids[15]. Su *et al*[16] demonstrated that both small (9 mm) and large (13 mm) diameter devices showed equivalent effects on 218 cases of grade II-IV internal hemorrhoids[16]. Furthermore, ERBL has been proven to be safe for certain patients including those with liver cirrhosis and portal hypertension[17,18].

Although the therapeutic advantages of ERBL on traditional RBL with anoscopy have not been evidently revealed, ERBL is increasingly preferred by operators. Endoscopy is strongly recommended to

Table 1 Documents of massive life-threatening post-rubber band ligation/endoscopic rubber band ligation bleeding¹

Ref.	Number/total	Risk factor
Bat <i>et al</i> [23], 1993	6/512	5 of 6 had history of oral ASA intake
Marshman <i>et al</i> [27], 1989	2/241	Oral anti-coagulants
Lau <i>et al</i> [28], 1982	2/212	Not documented
Odelowo <i>et al</i> [6], 2002	1/none ²	Oral ASA
Beattie <i>et al</i> [24], 2004	2/none	Oral clopidogrel
Patel <i>et al</i> [25], 2014	2/none	Oral ASA
Soetikno <i>et al</i> [26], 2016	3/none	Oral ASA/warfarin

¹Massive bleeding means over 800 mL bleeding or symptomatic anemia that requires transfusion.

²None means case reports.

ASA: Aminosalicic acid.

exclude other severe diseases including colorectal ulcers and cancer which share similar bleeding symptoms[19,20]. Simultaneous endoscopic examination with hemorrhoid treatments provides convenience for these patients. Flexible endoscopy is feasible for ligation in both forward-view and retroflexion. The advantage of the retroflexion procedure is its easy operation and controllability. Fukuda *et al*[21] demonstrated that using an endoscope in both the forward and retroflexed positions assisted with the treatment of internal hemorrhoids and allowed for an easier evaluation of range, form and red color signs which are closely related to hemorrhoid symptoms[21]. More importantly, retroflexion in the anal zone provides a better view which can help to ligate above the dentate line to avoid post-RBL pain[7]. In randomized trials performed by Cazemier *et al*[7], ERBL showed similar efficacy and safety compared with traditional RBL using anoscopy and the recurrence rate of bleeding symptoms using the two methods was also comparable[7]. However, the study reported that ERBL is significantly easier to perform and requires fewer treatment sessions[7].

Currently, limited research has analyzed the complications of ERBL. Pain and anal bleeding were the most frequently reported postoperative complications. In a long-term follow-up study enrolling 759 patients, Su *et al*[13] reported that 12.3% of patients experienced mild anal pain 1-3 d after treatment, which was relieved by oral analgesia. Overall, 6.3% of patients had mild bleeding (some blood noted in tissue papers) 1-14 d after treatment and were cured by epinephrine injection[13]. Schleinstein *et al*[14] reported that 55.2% of patients had pain and 29.3% of patients had mild bleeding at 2 h post-ERBL and the rate declined to 25.9% of patients having pain and 10.3% of patients having bleeding at 10-14 d with observation or symptomatic treatment[14]. When compared with other treatments, Cazemier *et al*[7] reported increased postoperative pain in ERBL than with traditional RBL using anoscopy[7], however, such findings remain controversial. Therefore, ERBL is generally considered a cost-effective treatment in which most complications are mild and self-confined. Severe complications are rarely reported in single cases. Jutabha *et al*[22] reported 2 cases of severe pain among patients who took narcotic agents but no hospitalization was needed[22]. Su *et al*[13,16] reported a 3 mo duration of pain that required analgesia[16] and a death due to hepatic failure[13].

In previous RBL using anoscopy, bleeding after RBL usually occurs 10-14 d after RBL when the rubber bands slough[23]. Coagulation disorders were demonstrated to increase the risk of bleeding related to RBL. Massive life-threatening post-RBL bleeding was rare but well documented (Table 1). In a prospective study enrolling 512 patients, Bat *et al*[23] reported 6 cases of massive post-RBL bleeding, of which 5 patients had a recent history of aminosalicic acid (ASA) use[23]. Moreover, several case reports of life-threatening post-RBL bleeding had a history of ASA and clopidogrel[6,24,25]. Few cases of life-threatening post-ERBL bleeding have been reported and are also associated with coagulation disorders. Soetikno *et al*[26] reported 3 cases of severe bleeding after hemorrhoid ligation with a history of ASA/warfarin use. One of these patients accepted ERBL, resulting in an active bleeding vessel within the ulcer in the anal region[26]. Therefore, it is recommended that patients should stop anticoagulant/antiplatelet drugs in the perioperative period to prevent post-ERBL bleeding[6]. In contrast to previous reports, the patient in our case denied any use of anticoagulant/antiplatelet drug and the coagulation function examination was normal before ERBL. Furthermore, the patient underwent hospitalized observation and cautious postoperative care. She took a light diet and laxatives to soften the stool. However, all of those measures failed to prevent massive post-ERBL bleeding. No risk factors seemed to have been the clear cause of her massive bleeding.

CONCLUSION

In conclusion, ERBL is a safe and effective therapy for internal hemorrhoids with rare severe complications. However, our case reminds us that those patients who are also at risk of life-threatening bleeding and need strict follow-up after ligation, even if no coagulation disorder is present.

ACKNOWLEDGEMENTS

The authors thank the patient for her consent to share the whole diagnosis and treatment procedures.

FOOTNOTES

Author contributions: Jiang YD reviewed the literature and contributed to the manuscript drafting; Liu Y and Wu JD were the patient's primary doctors; Li GP collected the data; Liu J and Hou XH substantially contributed to the data analysis and literature review; Song J performed the therapy and was responsible for the revision of the manuscript.

Informed consent statement: Informed written consent was obtained from the patient prior to the study, agreeing for publication of this report and accompanying material.

Conflict-of-interest statement: All authors declare that they have no conflicts of interest.

CARE Checklist (2016) statement: The authors have read the CARE Checklist (2016), and the manuscript was prepared and revised according to the CARE Checklist (2016).

Open-Access: This article is an open-access article that was selected by an in-house editor and fully peer-reviewed by external reviewers. It is distributed in accordance with the Creative Commons Attribution NonCommercial (CC BY-NC 4.0) license, which permits others to distribute, remix, adapt, build upon this work non-commercially, and license their derivative works on different terms, provided the original work is properly cited and the use is non-commercial. See: <https://creativecommons.org/licenses/by-nc/4.0/>

Country/Territory of origin: China

ORCID number: Yu-Dong Jiang 0000-0001-5783-539X; Ying Liu 0000-0002-1213-3420; Jian-Di Wu 0000-0002-5239-3286; Gang-Ping Li 0000-0002-6033-6812; Jun Liu 0000-0003-4436-5729; Xiao-Hua Hou 0000-0002-3694-2126; Jun Song 0000-0002-0255-4547.

S-Editor: Fan JR

L-Editor: Filipodia CL

P-Editor: Fan JR

REFERENCES

- 1 Yamana T. Japanese Practice Guidelines for Anal Disorders I. Hemorrhoids. *J Anus Rectum Colon* 2017; **1**: 89-99 [PMID: 31583307 DOI: 10.23922/jarc.2017-018]
- 2 Peery AF, Crockett SD, Barritt AS, Dellon ES, Eluri S, Gangarosa LM, Jensen ET, Lund JL, Pasricha S, Runge T, Schmidt M, Shaheen NJ, Sandler RS. Burden of Gastrointestinal, Liver, and Pancreatic Diseases in the United States. *Gastroenterology* 2015; **149**: 1731-1741.e3 [PMID: 26327134 DOI: 10.1053/j.gastro.2015.08.045]
- 3 Provenzale D, Ness RM, Llor X, Weiss JM, Abbadessa B, Cooper G, Early DS, Friedman M, Giardiello FM, Glaser K, Gurudu S, Halverson AL, Issaka R, Jain R, Kanth P, Kidambi T, Lazenby AJ, Maguire L, Markowitz AJ, May FP, Mayer RJ, Mehta S, Patel S, Peter S, Stanich PP, Terdiman J, Keller J, Dwyer MA, Ogba N. NCCN Guidelines Insights: Colorectal Cancer Screening, Version 2.2020. *J Natl Compr Canc Netw* 2020; **18**: 1312-1320 [PMID: 33022639 DOI: 10.6004/jnccn.2020.0048]
- 4 van Tol RR, Kleijnen J, Watson AJM, Jongen J, Altomare DF, Qvist N, Higuero T, Muris JWM, Breukink SO. European Society of ColoProctology: guideline for haemorrhoidal disease. *Colorectal Dis* 2020; **22**: 650-662 [PMID: 32067353 DOI: 10.1111/codi.14975]
- 5 Duchateau A, Huyghe M. Perirectal sepsis after rubber band ligation of haemorrhoids : a case report. *Acta Chir Belg* 2014; **114**: 344-348 [PMID: 26021540]
- 6 Odelowo OO, Mekasha G, Johnson MA. Massive life-threatening lower gastrointestinal hemorrhage following hemorrhoidal rubber band ligation. *J Natl Med Assoc* 2002; **94**: 1089-1092 [PMID: 12510709]
- 7 Cazemier M, Felt-Bersma RJ, Cuesta MA, Mulder CJ. Elastic band ligation of hemorrhoids: flexible gastroscope or rigid proctoscope? *World J Gastroenterol* 2007; **13**: 585-587 [PMID: 17278225 DOI: 10.3748/wjg.v13.i4.585]
- 8 Shanmugam V, Thaha MA, Rabindranath KS, Campbell KL, Steele RJ, Loudon MA. Systematic review of randomized trials comparing rubber band ligation with excisional haemorrhoidectomy. *Br J Surg* 2005; **92**: 1481-1487 [PMID: 16000000]

- 16252313 DOI: 10.1002/bjs.5185]
- 9 **Grossi U**, Gallo G, Di Tanna GL, Bracale U, Ballo M, Galasso E, Kazemi Nava A, Zucchella M, Cinetto F, Rattazzi M, Felice C, Zanus G. Surgical Management of Hemorrhoidal Disease in Inflammatory Bowel Disease: A Systematic Review with Proportional Meta-Analysis. *J Clin Med* 2022; **11** [PMID: 35160159 DOI: 10.3390/jcm11030709]
 - 10 **Brown SR**, Tiernan JP, Watson AJM, Biggs K, Shephard N, Wailoo AJ, Bradburn M, Alshreef A, Hind D; HubBLE Study team. Haemorrhoidal artery ligation vs rubber band ligation for the management of symptomatic second-degree and third-degree haemorrhoids (HubBLE): a multicentre, open-label, randomised controlled trial. *Lancet* 2016; **388**: 356-364 [PMID: 27236344 DOI: 10.1016/S0140-6736(16)30584-0]
 - 11 **Fukuda A**, Kajiyama T, Arakawa H, Kishimoto H, Someda H, Sakai M, Tsunekawa S, Chiba T. Retroflexed endoscopic multiple band ligation of symptomatic internal hemorrhoids. *Gastrointest Endosc* 2004; **59**: 380-384 [PMID: 14997135 DOI: 10.1016/s0016-5107(03)02818-9]
 - 12 **Su MY**, Chiu CT, Wu CS, Ho YP, Lien JM, Tung SY, Chen PC. Endoscopic hemorrhoidal ligation of symptomatic internal hemorrhoids. *Gastrointest Endosc* 2003; **58**: 871-874 [PMID: 14652555 DOI: 10.1016/s0016-5107(03)02308-3]
 - 13 **Su MY**, Chiu CT, Lin WP, Hsu CM, Chen PC. Long-term outcome and efficacy of endoscopic hemorrhoid ligation for symptomatic internal hemorrhoids. *World J Gastroenterol* 2011; **17**: 2431-2436 [PMID: 21633644 DOI: 10.3748/wjg.v17.i19.2431]
 - 14 **Schleinstein HP**, Averbach M, Averbach P, Correa PAFP, Popoutchi P, Rossini LGB. ENDOSCOPIC BAND LIGATION FOR THE TREATMENT OF HEMORRHOIDAL DISEASE. *Arq Gastroenterol* 2019; **56**: 22-27 [PMID: 31141063 DOI: 10.1590/S0004-2803.201900000-15]
 - 15 **Paikos D**, Gatopoulou A, Moschos J, Koulaouzidis A, Bhat S, Tzilves D, Soufleris K, Tragiannidis D, Katsos I, Tarpagos A. Banding hemorrhoids using the O'Regan Disposable Bander. Single center experience. *J Gastrointest Liver Dis* 2007; **16**: 163-165 [PMID: 17592563]
 - 16 **Su MY**, Tung SY, Wu CS, Sheen IS, Chen PC, Chiu CT. Long-term results of endoscopic hemorrhoidal ligation: two different devices with similar results. *Endoscopy* 2003; **35**: 416-420 [PMID: 12701014 DOI: 10.1055/s-2003-38773]
 - 17 **Awad AE**, Soliman HH, Saif SA, Darwish AM, Mosaad S, Elfert AA. A prospective randomised comparative study of endoscopic band ligation vs injection sclerotherapy of bleeding internal haemorrhoids in patients with liver cirrhosis. *Arab J Gastroenterol* 2012; **13**: 77-81 [PMID: 22980596 DOI: 10.1016/j.ajg.2012.03.008]
 - 18 **Zaher T**, Ibrahim I, Ibrahim A. Endoscopic band ligation of internal haemorrhoids vs stapled haemorrhoidopexy in patients with portal hypertension. *Arab J Gastroenterol* 2011; **12**: 11-14 [PMID: 21429448 DOI: 10.1016/j.ajg.2011.01.009]
 - 19 **Ford AC**, Veldhuyzen van Zanten SJ, Rodgers CC, Talley NJ, Vakil NB, Moayyedi P. Diagnostic utility of alarm features for colorectal cancer: systematic review and meta-analysis. *Gut* 2008; **57**: 1545-1553 [PMID: 18676420 DOI: 10.1136/gut.2008.159723]
 - 20 **Madoff RD**, Fleshman JW; Clinical Practice Committee, American Gastroenterological Association. American Gastroenterological Association technical review on the diagnosis and treatment of hemorrhoids. *Gastroenterology* 2004; **126**: 1463-1473 [PMID: 15131807 DOI: 10.1053/j.gastro.2004.03.008]
 - 21 **Fukuda A**, Kajiyama T, Kishimoto H, Arakawa H, Someda H, Sakai M, Seno H, Chiba T. Colonoscopic classification of internal hemorrhoids: usefulness in endoscopic band ligation. *J Gastroenterol Hepatol* 2005; **20**: 46-50 [PMID: 15610445 DOI: 10.1111/j.1440-1746.2004.03536.x]
 - 22 **Jutabha R**, Jensen DM, Chavalitthamrong D. Randomized prospective study of endoscopic rubber band ligation compared with bipolar coagulation for chronically bleeding internal hemorrhoids. *Am J Gastroenterol* 2009; **104**: 2057-2064 [PMID: 19513028 DOI: 10.1038/ajg.2009.292]
 - 23 **Bat L**, Melzer E, Koler M, Dreznick Z, Shemesh E. Complications of rubber band ligation of symptomatic internal hemorrhoids. *Dis Colon Rectum* 1993; **36**: 287-290 [PMID: 8449135 DOI: 10.1007/BF02053512]
 - 24 **Beattie GC**, Rao MM, Campbell WJ. Secondary haemorrhage after rubber band ligation of haemorrhoids in patients taking clopidogrel--a cautionary note. *Ulster Med J* 2004; **73**: 139-141 [PMID: 15651778]
 - 25 **Patel S**, Shahzad G, Rizvon K, Subramani K, Viswanathan P, Mustacchia P. Rectal ulcers and massive bleeding after hemorrhoidal band ligation while on aspirin. *World J Clin Cases* 2014; **2**: 86-89 [PMID: 24749117 DOI: 10.12998/wjcc.v2.i4.86]
 - 26 **Soetikno R**, Asokkumar R, Sim D, Sato T, Kaltenbach T. Use of the over-the-scope clip to treat massive bleeding at the transitional zone of the anal canal: a case series. *Gastrointest Endosc* 2016; **84**: 168-172 [PMID: 26808814 DOI: 10.1016/j.gie.2016.01.041]
 - 27 **Marshman D**, Huber PJ Jr, Timmerman W, Simonton CT, Odom FC, Kaplan ER. Hemorrhoidal ligation. A review of efficacy. *Dis Colon Rectum* 1989; **32**: 369-371 [PMID: 2714125 DOI: 10.1007/BF02563683]
 - 28 **Lau WY**, Chow HP, Poon GP, Wong SH. Rubber band ligation of three primary hemorrhoids in a single session. A safe and effective procedure. *Dis Colon Rectum* 1982; **25**: 336-339 [PMID: 6979470 DOI: 10.1007/BF02553609]



Published by **Baishideng Publishing Group Inc**
7041 Koll Center Parkway, Suite 160, Pleasanton, CA 94566, USA

Telephone: +1-925-3991568

E-mail: bpgoffice@wjgnet.com

Help Desk: <https://www.f6publishing.com/helpdesk>

<https://www.wjgnet.com>

